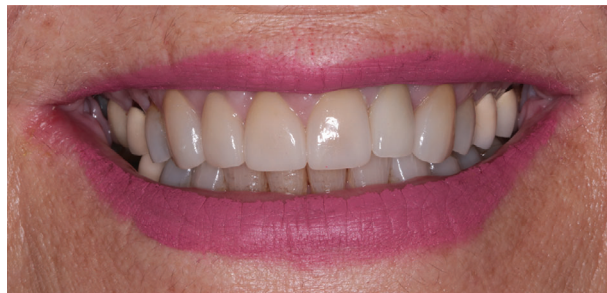
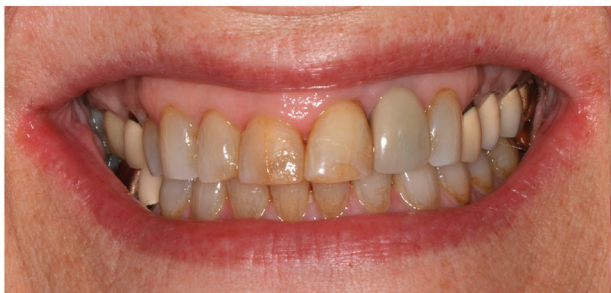
Dual Digitally Guided Crown Lengthening in Esthetic Area Compromised by Disharmonic Implant Crown

Nathalia Andrade,* Guilherme Moura,* Bartosz Maska,* Darnell Kaigler,* Gustavo Mendonça* and Hom-Lay Wang*



Introduction: A disharmonious smile results from excessive gingival exposure or gingival margin misalignment is a frequent finding in patients. The most common cause is altered passive eruption; however, in the case presented here, the esthetics of the smile is compromised also due to an inadequate implant placement and crown fabrication.

Case presentation: This case presented a combination of altered passive eruption and a buccally as well as deeply placed implant crown (#10) that led to disproportionate dimensions of an upper lateral incisor. Dual digitally guided crown lengthening surgical procedure for teeth #5 to #12 was performed aiming a better harmony of the smile. Treatment also included placement of tooth veneers and re-made of implant crown. A pleasant smile with appropriate colors and proportions was achieved. All esthetic and periodontal health parameters were maintained throughout the follow-up period (1 year).

Conclusion: The use of dual digitally guided crown lengthening help to accomplish precision and stability of esthetic outcome, as it guides for both, bone and soft tissue removal. Particularly, in challenging cases with high esthetic demand and complicated factors present, such as the case presented here, the digital approach provides tools to attain excellent treatment outcome. *Clin Adv Periodontics* 2022;12:26–31.

Key Words: crown lengthening; dental implant; 3d imaging, computer generated; dental esthetic.

Background

Contemporary dentistry seeks to meet patients' expectations and dental esthetic demands as well as guaranteeing the maintenance of health and function. A patient's smile can be esthetically compromised by excessive gingival exposure or a compromised gingival contour.^{1,2} The most common cause of this is due to altered passive eruption (APE), in which the gingiva margin exceeds the regular limits of the anatomical crown, causing disproportion between the teeth and gum.²

The crown-lengthening surgical procedure is applied for the correction of gingival disharmony.³ Liu and coworkers described a digitally guided, dual crown-lengthening technique can be used to provide references

for both gingivectomy and osteotomy.⁴ Another recent case report using 3D imaging and computer generated guide claimed that the employment of a digital guide aids the surgical procedure to increase its predictability.⁵ The literature on dual digital guides for crown-lengthening procedures is somehow limited as it is a new technique. Furthermore, to the best of our knowledge, no literature has reported utilizing the dual digitally guided crown lengthening for the treatment of complex esthetically demanding case that involved both teeth and implants.

Hence, the goal of this article is to demonstrate how the digitally guided, dual crown-lengthening can be used for the treatment of a case that involved APE with compromised gingival contour in one-side and a distortion of the patient's smile due to excessive height, mesial-distal extension, and a pronounced buccal profile because of a deeply placed dental implant and poorly fabricated upper lateral incisor crown in the other side.

*Department of Periodontics and Oral Medicine, School of Dentistry, University of Michigan, Ann Arbor, Michigan, USA

Received September 4, 2020; accepted January 17, 2021

doi: 10.1002/cap.10150

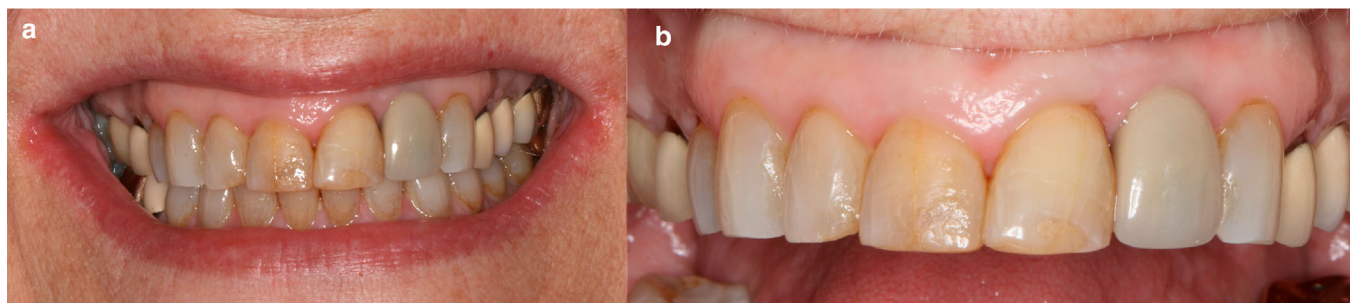


FIGURE 1 Initial clinical photos

Clinical Presentation

The patient presented here has electronically signed a consent for periodontal treatment received at the Department of Periodontics and Oral Medicine, University of Michigan School of Dentistry.

The patient, a 66-year-old female, was referred to the Graduate Periodontics Clinic (School of Dentistry, the University of Michigan) in May 2019 from the Prosthodontics Clinic for evaluation regarding her smile. She was unhappy with one esthetically compromised implant supported crown on tooth #10, gingival misalignment, the one-side overexposure of the maxillary gingiva when smiling, as well as the color of her overall anterior teeth appearance (Figure 1). The implant supported lateral incisor crown had exceeded the height of the central incisor and canine, had a buccal emergency profile, and bled upon probing (peri-implant mucositis). Possible etiological factors that led to the alveolar bone deficiency and the consequent of nonideal implant placement (too deep and slightly buccal) include but not limited to trauma, congenital abnormalities, atrophy, infection, periodontal disease, bone loss after tooth extraction, lack of interproximal bone, and poor surgical skill.⁶ A Seibert class II ridge defect (apico-coronal loss of tissue) was noted on #10.⁷

The patient presented in good general health. No periodontal or tooth issues were detected. At the clinical examination, a gingiva band 7–8 mm in width was attached, and the periodontal and peri-implant pockets' depths were ≤ 3 mm. No periapical radiolucency or bone loss at the radiographic examination was detected (Figure 2). The patient was determined and eager to start treatment.

Case Management

The treatment plan included a crown-lengthening of #5–12 under intravenous (IV) sedation, the installation of tooth veneers, and the replacement of the implant supported crown. Based on clinical examination and cone beam computed tomogram radiographic analyses, the patient has a thick tissue phenotype and is Coslet's type IB,² requiring gingivectomy and osseous surgery to establish 2–3 mm of supra-crestal tissue attachment.

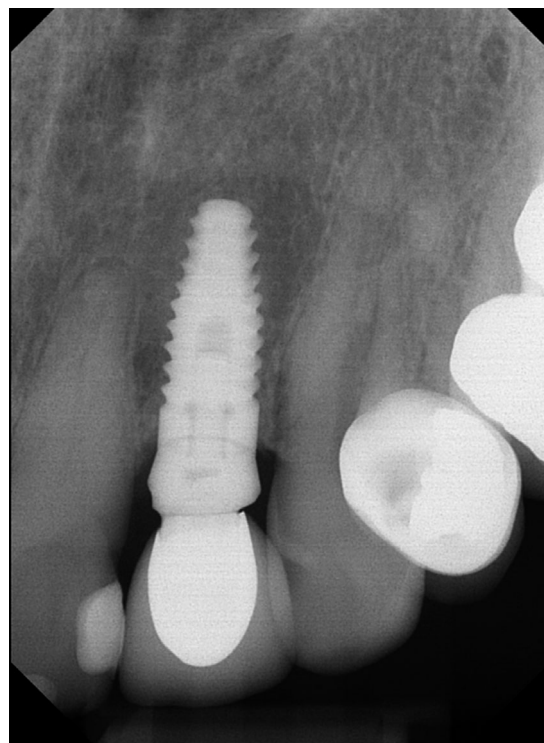


FIGURE 2 PA of implant #12

Initially, a 3D scan† was taken to perform a digital diagnosis wax-up, based on each tooth's cemento-enamel junction or a 0.75 ratio of proportion tooth width/length on #10 implant using a 3D modeling software[‡].⁸ At the same time, we sought to achieve improved visual agreement between the implanted crown and the natural teeth (Figure 3a and b). We pursued, during the treatment plan, a balance between sacrificing the attached gingiva and achieving an adequate esthetic outcome without compromising periodontal health and stability.

The dual digital surgical guide was designed, based on a digital wax-up, and printed[§] (Figure 3). The lower margin of the labial band assists the incision for the gingivectomy (this largely follows the anatomical landmark—cemento-enamel junction). If required, some further refinements of the incision can also be made freehand. The top margin of the labial band was used as a reference for bone removing - 2–3 mm above of the cemento-enamel junction

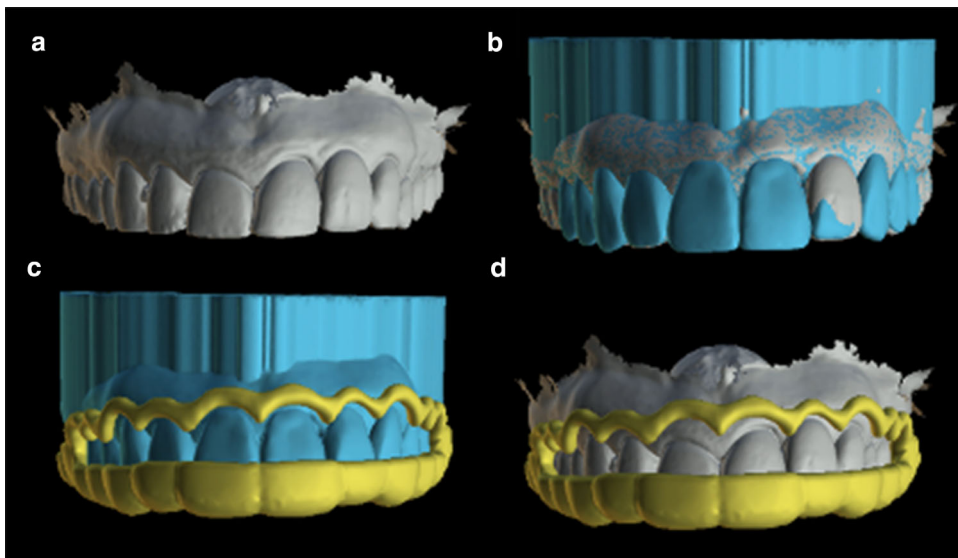


FIGURE 3 Digital wax up and dual surgical guide. (a) Initial scan. (b) Digital wax-up. (c) Surgical guide designed based on the digital wax-up. (d) Digital surgical guide on the top of initial scan showing amount of gingivectomy needed

(to create supracrestal tissue height). The guide assists and facilitates the process of bone removal in a more precise manner.

To reduce patient discomfort and anxiety, the surgical procedure was performed under (IV) sedation. Local anesthesia was induced using a 2% lidocaine solution with epinephrine at the ratio of 1:100,000. The guide was inserted into the mouth as a reference, and internal bevel incisions for gingivectomy were made from #5 to 12, which was followed by intrasulcular incisions with a 15c blade (Figure 4a and b). A full thickness flap was elevated beyond the mucogingival junction, and, using the guide as a reference, osteotomy was performed to attain a 2–3 mm distance from the future crown margins without removing the interproximal bone (Figure 4c–e).

The implant presented some granulation tissue and exposed threads that were cleaned with titanium curettes. In addition, the buccal profile of the crown was reduced as much as possible. The flap was repositioned using simple interrupted sutures with polyglactin 910 4–0 to stabilize the flap (Figure 4g). At the end of the procedure, we could appreciate how the new gingival margin position fitted well within the lower labial margin of the guide (Figure 4h).

The patient was prescribed with chlorhexidine gluconate (0.12%) mouth rinse to be used twice a day for 2 weeks, 600 mg of ibuprofen to be taken every 4–6 h for 5 days, and 500 mg of amoxicillin to be taken three times a day for 7 days.

Clinical Outcome

Postoperative healing was uneventful (Figure 5), provisional facets were installed 1 month after healing (June 2019), and definitive prostheses were digitally designed (Figure 6) and delivered 6 months after healing (December

2019), as recommended due to bone and tissue remodeling.⁹ The color and shape of ceramic crowns were chosen according to the patient's age and to provide successful esthetic and health results. Esthetics and periodontal health parameters, including the positioning of the gingival margin, the health of the attachment apparatus, peri-implant health, and the patient's satisfaction with the esthetics remained stable over a period of 1 year following the surgical treatment (Figure 7).

Discussion

Implants have shown high survival rates at long-term follow-up. However, implant esthetic concern is a common clinical findings noted in the anterior implants.¹⁰ In this case report, we have used a dual, digitally guided crown-lengthening procedure to correct gingival margin discrepancy caused by APE and an inappropriately positioned implant and crown shape.

An initial correct diagnosis and precision during the procedure are fundamental; incorrect gingivectomy or excessive bone removal can lead to gingival recession. Similarly, poor bone resection can result in only partial resolution. According to Pontoriero et al., after 12 months of healing, the coronal displacement of the gingival margin is usually about 3 mm at the interproximal and buccal/lingual sites, occurring particularly in patients with a thick phenotype.¹¹ Notably, insufficient and ragged bone removal is frequently observed regardless of the providers' level of experience.¹²

The use of computer design software has been proposed to achieve more predictable results in crown-lengthening procedures. Arias et al. described the digital smile approach (DSA) using presentation software application to preview the final esthetic outcome and to

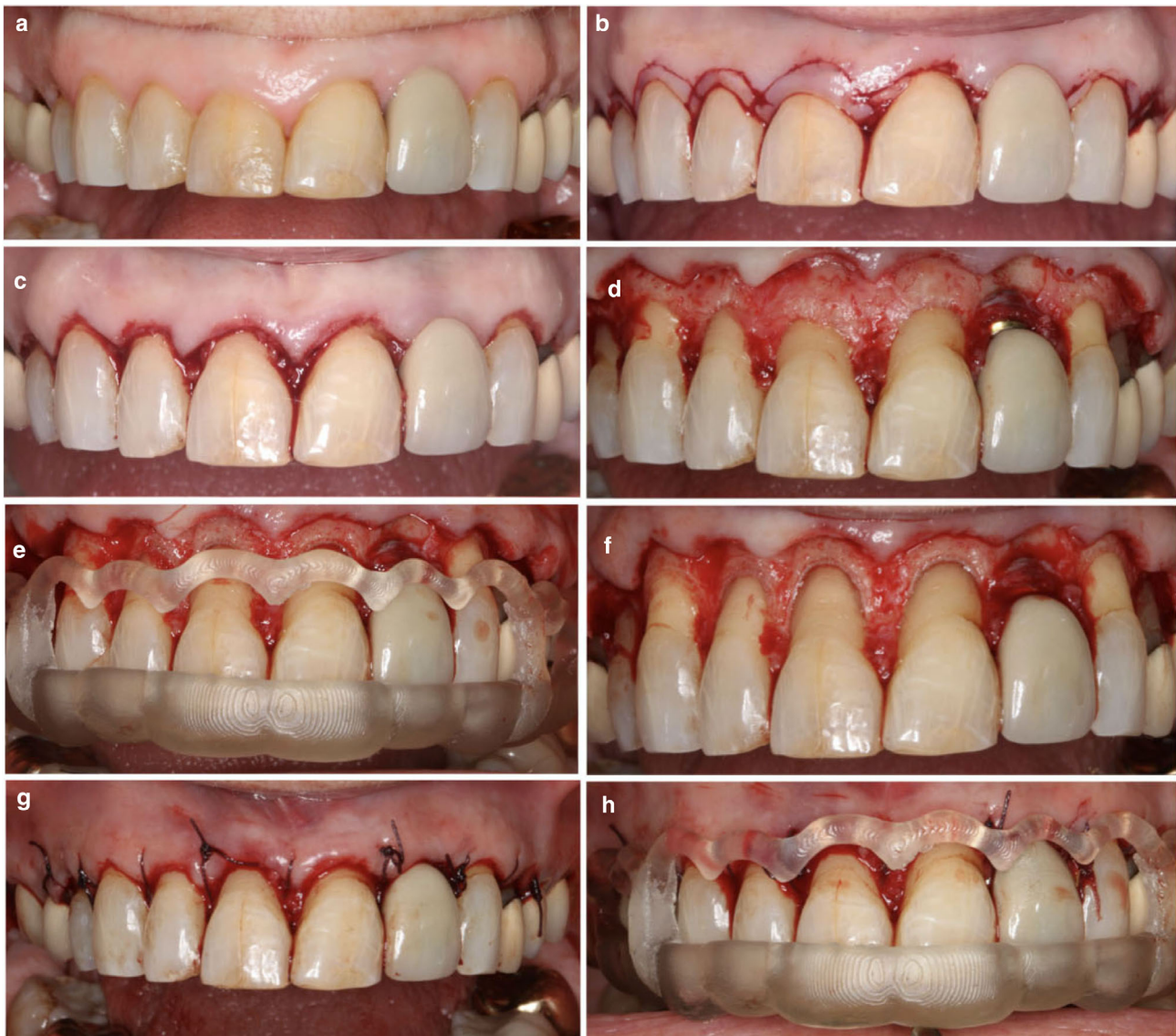

FIGURE 4 Photos of crown lengthening surgical procedure. (a) Initial clinical photo. (b) Gingivectomy incisions. (c) After excessive tissue was removed. (d) Full thickness flap. (e) Digital guide and new bone crest height after osteotomy. (f) New bone crest level after the guide was removed. (g) Flap adaptation and sutures. (h) Immediate post-op showing the new gingival margins fitting the guide

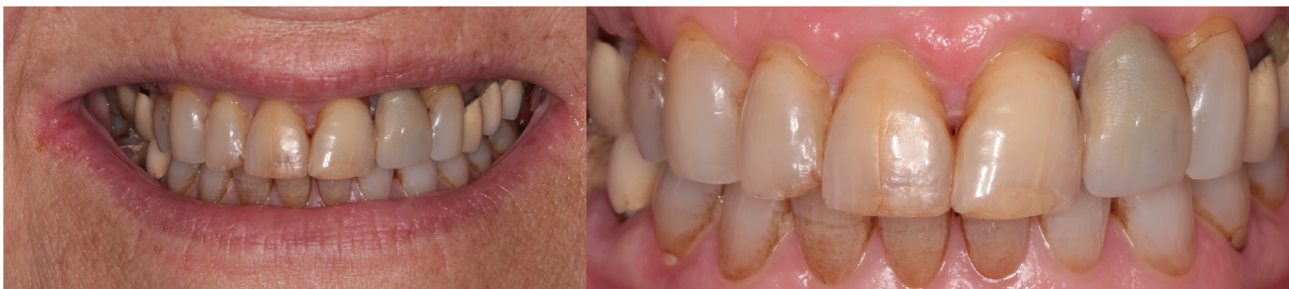

FIGURE 5 Photos of 1-month post op: (a) patient's smile and (b) intraoral

optimize the communication between dentists, technicians, and patients. However, this technique does not include a printable guide.¹³ Recently, the use of merged patient data with computer-aided design (CAD) and computer-aided manufacturing (CAM) technology has allowed the transfer of information from software to the

surgical field, facilitating high levels of accuracy.^{5,14} Due to the novelty of the procedure, we believe that further longitudinal-controlled studies are needed to evaluate the impact of factors like possible errors in the surgical guide as well as to compare the efficacy of digitally guided and freehand crown-lengthening procedures.

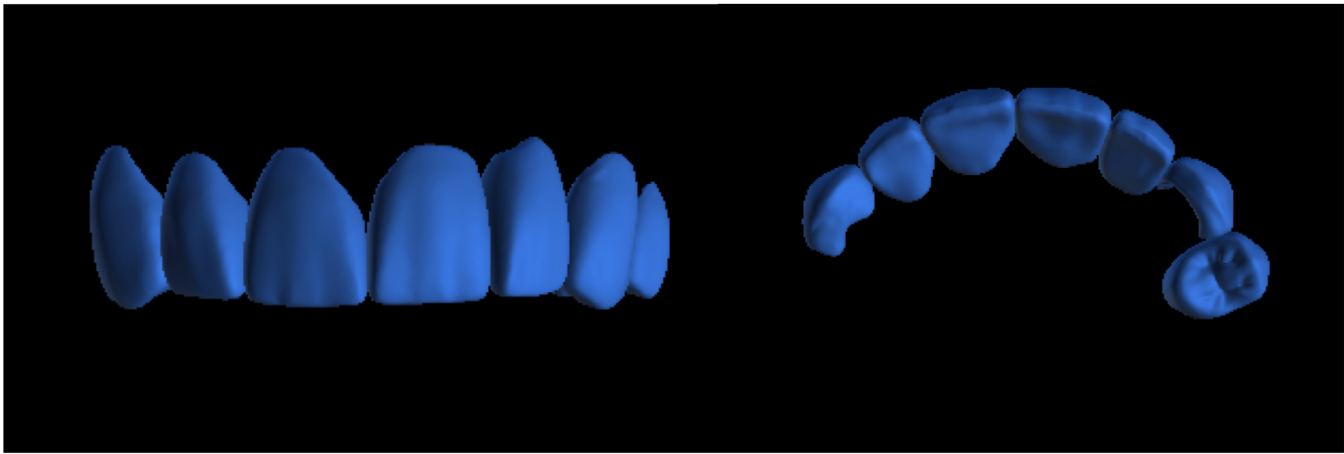


FIGURE 6 Digitally designed crowns

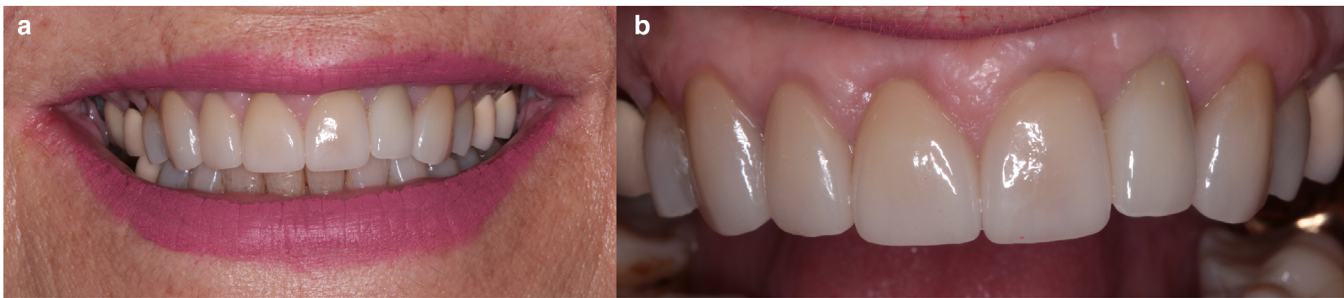


FIGURE 7 Six months follow up with crowns placed (a and b)

Our case was one of the first to use a dual digitally guided crown-lengthening procedure to address an esthetically demanding case that involved both teeth and implants. Other treatment options include hard and soft tissue grafts with possible multiple surgical procedures

that do not have a predictable outcome. Choosing to use a dual digitally guided crown-lengthening procedure helps to achieve predictable esthetic outcome, facilitate the interdisciplinary approach, and communicate with patient. ■

Summary

<p>Why is this case new information?</p>	<ul style="list-style-type: none"> ■ This case uses a dual digitally guided crown-lengthening procedure to successfully manage an esthetically demanding case that involved both teeth and implants.
<p>What are the keys to successful management of this case?</p>	<ul style="list-style-type: none"> ■ Dual digitally guided crown-lengthening procedure helped clinician to perform precise gingival incision as well as bone reduction that is needed for the crown lengthening. ■ The digital plan also allows clinician to preview the final outcome and test different possibilities of tooth shape to find an ideal match for the patient.
<p>What are the primary limitations to success in this case?</p>	<ul style="list-style-type: none"> ■ Mistake/distortion of digital plan that creates error in performing this procedure. ■ Lack of adequate keratinized tissue (≤ 2 mm) that limits the ability to use the first (lower guide) properly.

Acknowledgment

The authors do not have any financial interests, either directly or indirectly, in the products or information included in the paper.

Conflict of Interest

The authors declare no conflict of interest.

Author Contributions

All authors contributed to the case documentation, manuscript preparation, and final revision.

Correspondence

Hom-Lay Wang, DDS, MSD, PhD, Department of Periodontics and Oral Medicine, School of Dentistry, University of Michigan, 1011 North University Avenue, Ann Arbor, Michigan 48109-1078, USA.
Email: homlay@umich.edu

References

1. Chu S, Tan JH, Stappert CF, Tarnow DP. Gingival zenith positions and levels of the maxillary anterior dentition. *J Esthet Restor Dent.* 2009;21:113-120.
2. Coslet JG, Vanarsdall R, Weisgold A. Diagnosis and classification of delayed passive eruption of the dentogingival junction in the adult. *Alpha Omegan.* 1977;70:24-28.
3. Cairo F, Graziani F, Franchi L, Defraia E, Pini Prato GP. Periodontal plastic surgery to improve aesthetics in patients with altered passive eruption/gummy smile: a case series study. *Int J Dent.* 2012;2012:837658.
4. Liu X, Yu J, Zhou J, Tan J. A digitally guided dual technique for both gingival and bone resection during crown lengthening surgery. *J Prosthet Dent.* 2018;119:345-349.
5. Mendoza-Azpur G, Cornejo H, Villanueva M, Alva R, Barbisan de Souza A. Periodontal plastic surgery for esthetic crown lengthening by using data merging and a CAD-CAM surgical guide. *J Prosthet Dent.* 2020. <https://doi.org/10.1016/j.prosdent.2020.09.041>
6. Buser D, Martin W, Belser UC. Optimizing esthetics for implant restorations in the anterior maxilla: anatomic and surgical considerations. *Int J Oral Maxillofac Implants.* 2004;19:43-61.
7. Seibert JS. Reconstruction of deformed, partially edentulous ridges, using full thickness onlay grafts. Part II. Prosthetic/periodontal interrelationships. *Compend Contin Educ Dent.* 1983;4:549-562.
8. Chu SJ, Hochman MN, Fletcher P. A biometric approach to aesthetic crown lengthening: part II—interdental considerations. *Pract Proced Aesthet Dent.* 2008;20:529-536.
9. Deas DE, Moritz AJ, McDonnell HT, Powell CA, Mealey BL. Osseous surgery for crown lengthening: a 6-month clinical study. *J Periodontol.* 2004;75:1288-1294.
10. Hammerle CHF, Tarnow D. The etiology of hard- and soft-tissue deficiencies at dental implants: a narrative review. *J Periodontol.* 2018. <https://doi.org/10.1111/jcpe.12955>
11. Pontoriero R, Carnevale G. Surgical crown lengthening: a 12-month clinical wound healing study. *J Periodontol.* 2001;72:841-848.
12. Herrero F, Scott JB, Maropis PS, Yukna RA. Clinical comparison of desired versus actual amount of surgical crown lengthening. *J Periodontol.* 1995;66:568-571.
13. Arias DM, Trushkowsky RD, Brea LM, David SB. Treatment of the patient with gummy smile in conjunction with digital smile approach. *Dent Clin North Am.* 2015;59:703-716.
14. Passos L, Soares FP, Choi IGG, Cortes ARG. Full digital workflow for crown lengthening by using a single surgical guide. *J Prosthet Dent.* 2020;124:257-261.

○ indicates key references.