

Mangaonkar Abhishek (Orcid ID: 0000-0003-2458-9887)
Litzow Mark (Orcid ID: 0000-0002-9816-6302)
Shah Mithun Vinod (Orcid ID: 0000-0002-5359-336X)
McCullough Kristen B (Orcid ID: 0000-0003-4252-2619)
Patnaik Mrinal M (Orcid ID: 0000-0001-6998-662X)

Reduced intensity conditioning allogeneic hematopoietic stem cell transplantation in

VEXAS syndrome: Data from a prospective series of patients

Abhishek A. Mangaonkar MBBS*¹, Kimberly J. Langer APRN, CNP, DNP*¹, Terra L. Lasho PhD¹, Christy Finke¹, Mark R Litzow MD¹, William J Hogan MBBCh¹, Mithun V. Shah MD, PhD¹, Ronald S. Go MD¹, Gabriel Bartoo PharmD, RPh¹, Jade Kutzke PharmD, RPh¹, Kristen McCullough PharmD, RPh¹, Matthew Koster MD², Matthew Samec MD², Kenneth J. Warrington MD², Kaaren K. Reichard MD³, Horatiu Olteanu MD, PhD³, Mary Riwes DO³, Mrinal M. Patnaik MBBS, MD¹, Hassan Alkhateeb MD¹

¹Division of Hematology, Department of Medicine, Mayo Clinic, Rochester, MN

²Division of Rheumatology, Department of Medicine, Mayo Clinic, Rochester, MN

³Division of Hematopathology, Mayo Clinic, Rochester, MN

⁴Division of Hematology/Oncology, University of Michigan, Ann Arbor, MI

Running title: Allogeneic hematopoietic stem cell transplant in VEXAS

*These authors contributed equally.

Corresponding author(s):

Abhishek Mangaonkar, MBBS
Assistant Professor, Division of Hematology, Department of Medicine,
Mayo Clinic, Rochester
Email: mangaonkar.abhishek@mayo.edu

And

Hassan Alkhateeb
Assistant Professor, Division of Hematology, Department of Medicine,
Mayo Clinic, Rochester
Email: Alkhateeb.hassan@mayo.edu

This is the author manuscript accepted for publication and has undergone full peer review but has not been through the copyediting, typesetting, pagination and proofreading process, which may lead to differences between this version and the Version of Record. Please cite this article as doi: [10.1002/ajh.26786](https://doi.org/10.1002/ajh.26786)

This article is protected by copyright. All rights reserved.

To the Editor,

VEXAS (vacuoles, E1 enzyme, X-linked, autoinflammatory, somatic) syndrome occurs secondary to somatic mutations in the X-linked *UBA1* gene and presents with an adult-onset inflammatory syndrome with cytopenias and a predisposition to neoplasia (myeloid and plasma cell origin).¹ The precise incidence of VEXAS is still unknown but estimated at approximately 9% of all cases with relapsing polychondritis,² with cytopenias of varying severity occurring in almost all, and concurrent myelodysplastic syndrome (MDS) reported to occur in 25-55% VEXAS patients.^{1,3,4} Therapeutic strategies have involved the use of inflammation-directed therapy (glucocorticoids, JAK inhibitors, and anti-IL6 therapy) and/or clone-directed therapy with hypomethylating agents; however, responses have been largely underwhelming.⁴ Allogeneic hematopoietic stem cell transplantation (alloHCT) remains a potentially curative strategy; however, published reports are largely retrospective.^{5,6} In other words, *UBA1* mutations were identified in stored blood samples collected from patients prior to undergoing alloHCT. In the few prospective cases where VEXAS diagnosis was established prior to alloHCT, there was lack of uniformity in the transplant approach.⁵⁻⁷ Additionally, unique VEXAS-specific clinical challenges such as transplant-specific glucocorticoid dose tapering, appropriate indications, and complications remain undefined. We present one of the first prospective reports of VEXAS patients that underwent alloHCT using a uniform conditioning approach and graft versus host disease prophylaxis strategy.

Within the auspices of institutional review board approval, we designed a consensus document for pursuing alloHCT in VEXAS by involving multidisciplinary experts from transplant, hematology, rheumatology, pharmacology, and genetics. Testing for *UBAI* gene was carried out using Sanger sequencing (*supplementary methods*). Indications for alloHCT were pre-determined as one of the following: a) severe, glucocorticoid-refractory recurrent inflammatory symptoms (either relapsing polychondritis, vasculitis, Sweet syndrome or undifferentiated systemic symptoms in the setting of elevated inflammatory markers) , b) persistent (≥ 3 months) cytopenias, including need for packed red blood cell and/or platelet transfusions, c) co-existent myeloid malignancy or clonal abnormalities predictive of myeloid transformation (higher risk clonal somatic myeloid mutations or MDS-defining cytogenetic abnormalities). Four patients underwent allogeneic HCT at Mayo Clinic (Rochester, MN), while one was treated at the University of Michigan (Ann Arbor, MI, in consultation with Mayo Clinic). Conditioning regimen strategy was pre-determined as reduced intensity conditioning (RIC) with fludarabine (Flu) at a dose of 125 mg/m² over 5 days, and melphalan (Mel) 140 mg/m² (appropriate dose reductions in the setting of renal insufficiency was allowed). RIC was chosen due to the advanced age at presentation and to limit transplant-related mortality (TRM). Donor choices included both matched sibling (MSD) and matched unrelated donors (MUD) with T cell replete peripheral blood stem cell graft. Since VEXAS is a precursor clonal condition and not an advanced stage myeloid malignancy, graft versus leukemia (GVL) was deemed not necessary; and an intensive GVHD prophylaxis strategy (similar to haploidentical donor alloHCT) that involved post-transplant cyclophosphamide (PTCy, 50 mg/kg per dose, day+3 and +4), mycophenolate mofetil (MMF) till day+35, and tacrolimus (to be started day 5 post alloHCT and tapered over time as per investigator's preference) was planned (appropriate

substitutions in the setting of contra-indications to PTCy were allowed). Granulocyte colony stimulating factor (G-CSF) use post-transplant was avoided to limit exacerbating underlying systemic inflammation. Anti-inflammatory therapy (prednisone, tocilizumab, and ruxolitinib among others) prior to alloHCT was allowed (if patients were on prednisone at the time of alloHCT, it was recommended to switch to an equivalent dose of hydrocortisone in the peri-transplant period to limit interference with PTCy, followed by a slow taper left to investigator's discretion).

Overall, 5 patients (all males) with VEXAS have undergone allogeneic HCT with a median follow up of 9.6 (range: 2.9-16.2) months. Among these, 3 patients were diagnosed with *UBAI* p.Met41Thr variant (#1, #4, and #5), 1 with *UBAI* p.Met41Val (#2), and 1 with *UBAI* c.118-1G>C (splice variant, #3). The most common indication for alloHCT was refractory inflammatory symptoms (n=3, 60%), bone marrow failure with red blood cell transfusion dependence along with relapsing polychondritis (n=1), while 1 patient had both MDS (morphological diagnosis only without any karyotypic or molecular abnormalities), and relapsing polychondritis (n=1). Pre-transplant glucocorticoid-sparing therapies (**table 1**) included methotrexate, mycophenolate mofetil (MMF), decitabine, hydroxychloroquine, testosterone, cyclosporine, rituximab, adalimumab, abatacept, omalizumab, dapsone, leflunomide, etanercept, infliximab, ruxolitinib, and tocilizumab but these were not effective in reducing prednisone use or improving cytopenias. Types of donor included matched unrelated (matched at HLA-A, B, C, DR and DQ alleles, n=3), and matched sibling donors (n=2). Median time to neutrophil engraftment was 25 (range: 20-33) days, while median time to platelet engraftment was 33 (range: 24-51) days. All patients received Flu/Mel conditioning at the pre-specified dosing; however, PTCy/tacrolimus/MMF GVHD prophylaxis could be administered in only four patients

[one of the patients (#3) received tacrolimus and methotrexate GVHD prophylaxis due to sub-normal ejection fraction (48%) and mild left ventricular hypokinesis at pre-transplant assessment]. Post-transplant complications included encephalopathy due to secondary adrenal insufficiency (treated with stress doses of glucocorticoid, n=1), mucositis (grade II, n=2), bacteremia/sepsis (n=1), drug-induced rash/mild dermal hypersensitivity reaction (n=2), grade 1 acute skin GVHD (n=1), gastrointestinal infection (n=1), and metabolic acidosis (n=1). In patients with at least 100 days of follow-up post-allo HCT (#1, #2, #3, and #5, **table 1**), normalization of bone marrow morphology, that is, eradication of vacuoles in myeloid and erythroid precursors was achieved at day+100 (post allo-HCT), and they were weaned off glucocorticoid therapy. Similarly, inflammatory markers (CRP and ESR) normalized by day+100, and at least two patients (#1 and #2) have been successfully weaned off immunosuppressive therapy (**figure 1A and 1B**). One patient (#3) developed peri-transplant (day+1) metabolic (lactic) acidosis in the absence of sepsis, hypoperfusion or organ dysfunction. Clinically, this was self-limiting (resolved by day+8 without intervention), and attributed to metformin use. Mixed chimerism in both myeloid and lymphoid fractions was seen in three patients (#1, #2, and #5) in the absence of inflammatory markers (**figure 1B**). Although these 3 patients met criteria for neutrophil and platelet engraftment, mild/moderate thrombocytopenia and leukopenia remained persistent at varying degrees but without clinical symptoms. In two patients (#1 and #2), we demonstrated disappearance of *UBAI* mutant clone in peripheral blood through Sanger sequencing (although this is a not an MRD assay due to lower detection threshold at around 20% variant allele fraction). Further, in one patient (#1), donor chimerism improved to 95% in CD3 and 100% in CD33 fraction at long-term follow-up (day+444) with normalization of hematopoietic parameters (tacrolimus was weaned off completely at 109 days

post alloHCT), while in another patient (#2), stable mixed chimerism (50% in CD3 and CD33 fractions at day 322 post alloHCT) continues to persist along with mild leukopenia and thrombocytopenia (tacrolimus was weaned off at 292 days post alloHCT). To date, none of the patients developed grade II-IV acute GVHD or chronic GVHD.

To our knowledge, this is one of the first prospective reports of patients with VEXAS successfully treated with alloHCT following a consistent plan of reduced-intensity Flu/Mel conditioning. All patients are alive, and without any VEXAS-related inflammatory features; with normalization of inflammatory markers (ESR/CRP), and bone marrow morphology. Thus far, persistent cytopenias, infections, and mixed donor/recipient chimerism are among the observed post-transplant complications. Mixed chimerism (both myeloid and lymphoid) was observed in some patients; however, none of these patients experienced recurrent inflammatory symptoms or worsening cytopenias, suggesting that it should not warrant any immediate intervention in the absence of systemic inflammation, high-risk somatic myeloid mutations or myeloid neoplasia and progressive cytopenias. Long-term implications of mixed chimerism in VEXAS post alloHCT are yet to be determined. Self-limiting peri-transplant metabolic acidosis (lactic acidosis, in the absence of hypoperfusion or organ dysfunction) of uncertain etiology is a unique complication seen in one of our patients, also observed in other reports.⁸

In summary, we demonstrate feasibility and successful allogeneic hematopoietic stem cell transplantation approach for VEXAS syndrome. Patients with refractory inflammation, cytopenias, and concurrent MDS are all appropriate indications for alloHCT. With the increased awareness of VEXAS, larger prospective cohorts are necessary for identifying transplant strategies with best long-term outcomes.

Disclosures: None of the authors report any conflicts in relation to the manuscript.

Funding: None

Acknowledgements: Authors would like to acknowledge the patients and their families for their active cooperation, advocacy, and partnership. Graphical abstract was created using BioRender.com.

Author contributions: AM conceptualized and wrote the paper. KJL and HA played a major role in planning, data collection and revising the paper. TL and CF performed the UBA1 PCR assay. MRL, WJH, MVS, RSG, MK, MS, KJW, MR, and MMP contributed patients. GB, JK, and KM provided critical input in drug use and monitoring. KKR, and HO reviewed the pathology data. All authors played a role in writing the manuscript.

References:

1. Beck DB, Ferrada MA, Sikora KA, et al. Somatic Mutations in UBA1 and Severe Adult-Onset Autoinflammatory Disease. *N Engl J Med* 2020;383:2628-2638.
2. Ferrada MA, Sikora KA, Luo Y, et al. Somatic Mutations in UBA1 Define a Distinct Subset of Relapsing Polychondritis Patients With VEXAS. *Arthritis Rheumatol* 2021;73:1886-1895.
3. Ferrada MA, Savic S, Cardona DO, et al. Translation of cytoplasmic UBA1 contributes to VEXAS syndrome pathogenesis. *Blood* 2022;140:1496-1506.
4. Bourbon E, Heiblig M, Gerfaud Valentin M, et al. Therapeutic options in VEXAS syndrome: insights from a retrospective series. *Blood* 2021;137:3682-3684.

5. Diarra A, Duployez N, Fournier E, et al. Successful allogeneic hematopoietic stem cell transplantation in patients with VEXAS syndrome: a 2-center experience. *Blood Adv* 2022;6:998-1003.
6. Loschi M, Roux C, Sudaka I, et al. Allogeneic stem cell transplantation as a curative therapeutic approach for VEXAS syndrome: a case report. *Bone Marrow Transplant* 2022;57:315-318.
7. van Leeuwen-Kerkhoff N, de Witte MA, Heijstek MW, Leavis HL. Case report: Up-front allogeneic stem cell transplantation in a patient with the VEXAS syndrome. *Br J Haematol* 2022;199:e12-e15 (online ahead of print).
8. Al-Hakim A, Poulter JA, Mahmoud D, et al. Allogeneic haematopoietic stem cell transplantation for VEXAS syndrome: UK experience. *Br J Haematol* 2022. doi: 10.1111/bjh.18488 (online ahead of print).

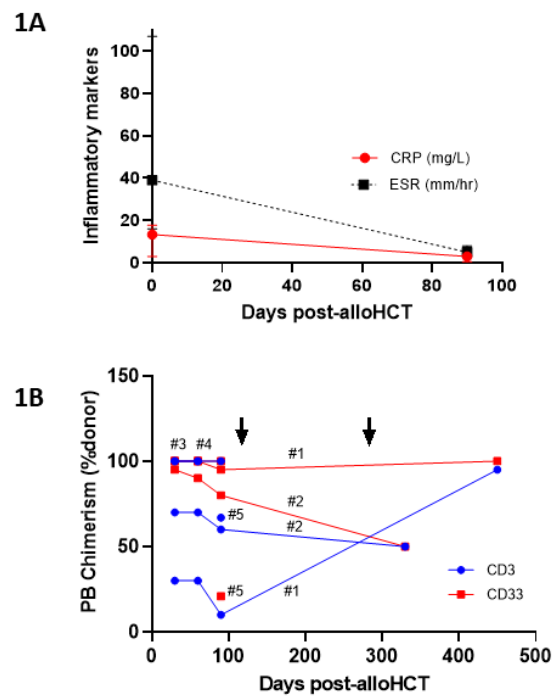
Figure legend:

Figure 1: Figure showing trajectory of inflammatory markers and donor chimerism in VEXAS patients who underwent allogeneic hematopoietic stem cell transplant (alloHCT). 1A shows gradual decline in the median values of C-reactive protein (pre-allo HCT versus day+100 post alloHCT, 13.3 versus 3 mg/L) and erythrocyte sedimentation rate (pre-alloHCT versus day+100 post alloHCT, 39 versus 5 mm/hr) after alloHCT. 1B shows dynamics of peripheral blood donor chimerism both in CD3 and CD33 fractions (arrows indicate time of complete discontinuation of immunosuppressive therapy post alloHCT in patient#1 and #2 from table 1).

Table 1: Table showing clinical indications, complications, and course following allogeneic HCT for patients with VEXAS syndrome.

Pt. #	Age at allo HCT (in yrs)	Sex	Mutation	Indication for alloHCT (HCT CI score prior to alloHCT)	Pre-alloHCT therapies	Donor	ABO (D/R)	CMV status (D/R)	Conditioning	GVHD Px	Post-transplant complications	PB Chimerism at Day+100 (± 10 days)	Last follow-up
1	63	M	UBAI p.Met41Thr	Transfusion-dependent anemia, polyarthritides (HCT CI score: 4)	Prednisone, MTX, MMF, decitabine, hydroxychloroquine, testosterone, cyclosporine, rituximab, tocilizumab, adalimumab, abatacept, lenalidomide	MUD	O+/O+	-/-	Flu/Mel	PTCy/Tac/MMF	Mucositis, Bacteremia, Encephalopathy/steroid withdrawal	10% donor in CD3 fraction, 95% donor in CD33 fraction	Alive post 485 days after alloHCT
2	60	M	UBAI p.Met41Val	Refractory inflammatory symptoms including urticarial vasculitis (HCT CI score: 0)	Prednisone, dapson, omalizumab, MMF	MSD	O+/O+	-/+	Flu/Mel	PTCy/Tac/MMF	Drug-induced rash	60% donor in CD3 fraction, 80% donor in CD33 fraction	Alive post 382 days after alloHCT
3	59	M	UBAI c. c.118-1G>C (splice variant)	Refractory inflammatory symptoms including migratory polyarthritides (HCT CI score: 5)	Prednisone, MTX, Leflunomide, adalimumab etanercept, infliximab, tocilizumab	MSD	O+/O+	-/-	Flu/Mel	Tac/MTX	Delayed count recovery, lactic acidosis (in the absence of sepsis or hypotension), weakness	100% donor in CD3 and CD33 fractions	Alive post 115 days after alloHCT
4	74	M	UBAI p. p.Met41Thr	Refractory inflammatory symptoms (HCT CI score: 4)	Prednisone, ruxolitinib, tocilizumab	MUD	O+/O+	-/-	Flu/Mel	PTCy/Tac/MMF	Mucositis, C difficile diarrhea, E-coli infection, grade I acute skin GVHD	100% donor in CD3 and CD33 fractions (at day+57)	Alive post 87 days after alloHCT
5	49	M	UBAI p.Met41Thr	MDS (morphological diagnosis only), relapsing polyarthritides (HCT CI score: 1)	Prednisone	MUD	O+/O+	-/-	Flu/Mel	PTCy/Tac/MMF	Mild dermal hypersensitivity reaction	67% donor in CD3 fraction, 27% donor in CD33 fraction	Alive post 288 days after alloHCT

Abbreviations: HCT=hematopoietic stem cell transplantation; CI=comorbidity index; MTX=methotrexate; MMF=mycophenolate mofetil; MUD=matched unrelated donor, MSD=matched sibling donor; CMV=cytomegalovirus; GVHD=graft versus host disease; PB=peripheral blood; Flu=Fludarabine, Mel=melphalan; PTCy=post-transplant cyclophosphamide; tac=tacrolimus; MMF=mycophenolate mofetil; N/A=not available.



AJH_26786_Figure 1 (final)_11.6.22_VEXAS HCT.tif

Allogeneic hematopoietic stem cell transplantation in VEXAS syndrome

