








## RESEARCH ARTICLE

# Metastatic melanoma of the heart: Retrospective cohort study and systematic review of prevalence, clinical characteristics, and outcomes

Alexander M. Balinski<sup>1</sup>  | Alexi L. Vasbinder<sup>2</sup>  | Connor C. Kerndt<sup>3</sup>  |  
Tonimarie C. Catalan<sup>2</sup> | Nathan P. Parry<sup>1</sup> | Rafey A. Rehman<sup>1</sup>  |  
Penelope Blakely<sup>2</sup>  | Raymond Y. Yeow<sup>2</sup>  | Monika J. Leja<sup>2</sup> | Christopher D. Lao<sup>4</sup> |  
Leslie A. Fecher<sup>4</sup> | Salim S. Hayek<sup>2</sup> 

<sup>1</sup>Oakland University William Beaumont School of Medicine, Rochester, Michigan, USA

<sup>2</sup>Department of Internal Medicine, Division of Cardiology, University of Michigan, Ann Arbor, Michigan, USA

<sup>3</sup>Department of Internal Medicine, Spectrum Health/Michigan State University College of Human Medicine, Grand Rapids, Michigan, USA

<sup>4</sup>Department of Internal Medicine, Division of Hematology/Oncology, University of Michigan, Ann Arbor, Michigan, USA

## Correspondence

Salim S. Hayek, MD, University of Michigan, Department of Internal Medicine, Division of Cardiology, 1500 E Medical Center Dr., Ann Arbor, MI 48109, USA.

Email: [shayek@med.umich.edu](mailto:shayek@med.umich.edu)

## Funding information

National Heart, Lung, and Blood Institute, Grant/Award Number: 1R01HL153384-01 and T32HL007853; National Institute of Diabetes and Digestive and Kidney Diseases, Grant/Award Number: 1R01DK12801201A1

## Abstract

**Background:** Cardiac metastasis of melanoma is rare and typically diagnosed post-mortem. Here we perform a retrospective cohort study and systematic review of patients with metastatic melanoma to characterize prevalence, clinical characteristics, and outcomes of cardiac metastasis.

**Methods:** We reviewed the electronic medical records of all outpatients with metastatic melanoma who underwent evaluation at the University of Michigan in Ann Arbor from January 2009 to January 2022, identifying patients with a clinical or histopathologic diagnosis of cardiac metastasis. We performed a systematic review of the literature to summarize the clinical characteristics and outcomes of patients with melanoma and cardiac metastasis.

**Results:** Overall, 23 of 1254 (1.8%) patients with metastatic melanoma were diagnosed with cardiac metastasis. Cardiac metastasis was reported in the right ventricle (65%), left ventricle (35%), and right atrium (35%). A total of 11 (48%) patients experienced at least one cardiovascular complication after the diagnosis of cardiac metastasis, the most common being arrhythmia (30%), heart failure (22%), and pericardial effusion (17%). Immunotherapy was more commonly used in patients with cardiac metastasis (80% vs 65%;  $p = 0.005$ ). Mortality at 2-years post-diagnosis was higher for patients with cardiac metastasis compared to those without (59% vs 37%;  $p = 0.034$ ). Progression of malignancy was the underlying cause of death of all patients.

**Conclusions:** Cardiac metastasis occurs in <2% of patients with metastatic melanoma, can affect all cardiac structures, and is associated with various cardiovascular complications and high mortality.

This is an open access article under the terms of the [Creative Commons Attribution](https://creativecommons.org/licenses/by/4.0/) License, which permits use, distribution and reproduction in any medium, provided the original work is properly cited.

© 2022 The Authors. *Cancer Medicine* published by John Wiley & Sons Ltd.

**KEYWORDS**

epidemiology, melanoma, metastasis, prognosis

## 1 | INTRODUCTION

Melanoma is a highly aggressive malignant tumor. The incidence of melanoma increases linearly after the age of 25 until the age of 50, after which the incidence slows, with a median age of diagnosis of 57 years.<sup>1</sup> There is a slight predilection of melanoma in men compared with women, with sex-related differences in survival.<sup>2-7</sup> The advent of targeted therapies and immunotherapy has led to a dramatic improvement in 5-year survival rates for metastatic melanoma, now greater than 50%.<sup>8,9</sup> Although melanoma has the potential to metastasize to virtually any organ, common areas of metastasis include the skin, subcutaneous tissue, lymph nodes, lungs, brain, liver, and bone.<sup>10</sup> Consequently, these tumors may present with a wide variety of symptoms depending on the location of metastasis.

Estimates of the incidence of cardiac metastases vary widely. Most cardiac metastases of melanoma are presumed to be clinically silent and diagnosed post-mortem, with 28%–64% of metastatic melanoma cases for whom autopsies were performed having heart involvement.<sup>11,12</sup> Ante-mortem diagnoses are either incidental or symptomatic and are estimated to occur in <2% of cases.<sup>13</sup> If identified ante-mortem, cardiac metastases appear to be associated with a poor prognosis but have demonstrated remission with adequate management.<sup>14</sup>

To date, the characterization of melanoma metastatic to the heart has been limited to case reports and small case series.<sup>12,15,16</sup> Here we perform a retrospective cohort study of over 1200 patients with metastatic melanoma and a systematic review of the literature to provide a comprehensive analysis of the frequency, clinical presentation, cardiovascular complications, and overall patient outcomes of patients with melanoma and cardiac metastasis.

## 2 | MATERIALS AND METHODS

### 2.1 | Retrospective cohort study

We conducted a retrospective cohort study of all patients with metastatic melanoma who received outpatient care at the University of Michigan Health System from January 2009 to January 2022. We identified 1254 adult patients ( $\geq 18$  years) based on referrals to the University of Michigan Melanoma Oncology clinic. Electronic medical records were reviewed to identify patients with melanoma and cardiac metastasis, defined as a diagnosis based on

imaging findings (echocardiogram, computed tomography, or magnetic resonance imaging) or histopathology. Data collected included demographics, date of metastatic melanoma diagnosis and treatment, diagnosis and clinical presentation of cardiac metastasis, cardiac imaging and biomarkers, and outcomes. Data were entered into REDCap (Nashville, TN), a secure HIPAA-compliant web-based application using a standardized data collection form. This study was approved by the Institutional Review Board at the University of Michigan under a waiver of informed consent.

### 2.2 | Systematic review

We performed a systematic review following guidelines set by the Preferred Reporting Systems for Systematic Reviews and Meta-Analysis (PRISMA).<sup>17</sup> Studies included in this review were identified after a comprehensive search of the Cochrane Library, EmBase, and PubMed databases from inception until January 2022. The search included keywords related to metastatic melanoma and the heart, such as “metastatic melanoma”, “cardiac metastasis”, “left ventricle”, “right ventricle”, “right atrium”, “left atrium”, “interatrial septum”, and “interventricular septum”. No limitations on dates of publication were placed. Studies were excluded if they were review articles, non-human, non-English, or not pertinent to this systematic review. Furthermore, the bibliographies of the relevant studies were searched to identify any additional studies of relevance. Last, the quality of the studies was assessed using the Oxford Center for Evidence Based Medicine (OCEBM) Levels of Evidence categorization.<sup>18</sup> The titles and abstracts of all the retrieved studies were assessed for inclusion by two authors (AMB and CCK). To be included, the studies must have reported the clinical characteristics of metastatic melanoma to the heart and its management, as well as relevant patient-level data of confirmed primary melanoma history, symptoms, patient presentation, tumor characteristics, and treatment strategies.

### 2.3 | Statistical analysis

We first report clinical characteristics stratified by the presence of cardiac metastasis as means and standard deviation for normally distributed continuous variables and frequencies and proportions for categorical variables. We

compared clinical characteristics, treatment modalities, and outcomes between those with and without cardiac metastasis using *t*-tests or chi-square tests for continuous and categorical variables, respectively. We created Kaplan–Meier curves to estimate survival associated with the development of cardiac metastasis with follow-up time beginning at the time of metastatic melanoma diagnosis until death or last known follow-up date. Differences in survival curves for those who did and did not develop cardiac metastasis were calculated using the log-rank test.

## 3 | RESULTS

### 3.1 | Retrospective cohort study

Overall, we identified 23 (1.8%) cases of melanoma metastasis to the heart out of 1254 patients with metastatic melanoma over a time span of 13 years (2009–2022). Patients with cardiac metastasis consisted of a higher percentage of men (57%), with a mean age at metastatic melanoma diagnosis of  $58 \pm 16$  years (Table 1 and Figure 1). The median (IQR) time from initial melanoma diagnosis to the identification of cardiac metastasis was 2.8 (1.2, 6.1) years. Patients with and without cardiac metastasis had similar demographics and comorbidities at the time of metastatic melanoma diagnosis except for race (Table 1). Compared with patients without known cardiac metastasis, patients with cardiac metastasis were more likely to be black (8.7% vs 0.9%;  $p = 0.009$ ).

Close to two-thirds (61%) of patients had at least one symptom at the time of diagnosis of cardiac metastasis, with the most common presenting symptoms being fatigue (35%) and dyspnea (30%) (Figure 2A). Most patients had no notable cardiac physical exam findings (Figure 2B). Cardiac metastasis commonly presented as a single cardiac mass (65%) in the right ventricle (65%), left ventricle (35%), or right atrium (35%) (Figure 2C). All cases were identified by diagnostic imaging, with a few cases confirmed histologically (13%). Treatment strategies for cardiac metastasis included immunotherapy (65%), targeted therapy (35%), radiation (25%), and surgery (15%) (Table 2, Figure 2D). Patients without cardiac metastasis were more likely to be treated with immunotherapy compared to those with cardiac metastasis (80% vs 65%;  $p = 0.005$ ), specifically nivolumab (42% vs 20%;  $p = 0.018$ ).

A total of 11 (48%) patients experienced at least one cardiovascular complication within one year after the diagnosis of cardiac metastasis with the most common being arrhythmia (30%), heart failure (22%), and pericardial effusion (17%) (Figure 3). Over a median (IQR) of 1.8 (0.6, 2.4) years, 548 (44%) patients with metastatic melanoma died. Mortality at 1-year post-diagnosis of

cardiac metastasis was 35%, with 57% of patients having died at two years. The median (IQR) time to death after cardiac metastasis was 0.7 (0.2, 1.3) years. At 2-year post-metastatic diagnosis, patients with cardiac metastasis had significantly higher mortality compared to patients without cardiac metastasis (59% vs 37%;  $p = 0.034$ ). The median survival time for patients with cardiac metastasis was 1.2 years compared with 4.4 years for patients without cardiac metastasis (Figure 4). Death was attributed to progression of malignancy in all causes, with no deaths attributed to cardiovascular causes.

### 3.2 | Systematic review

Our systematic literature review identified 1012 articles with 36 studies meeting inclusion criteria (Figure S1).<sup>19–50</sup> All studies received an evidence level of 4 based on the OCEBM Levels of Evidence categorization with a total of 40 individual cases of cardiac metastasis of melanoma identified from these studies.

Patients consisted of 50% men, with a mean age of presentation of  $52 \pm 14$  years and a mean time from primary melanoma diagnosis to diagnosis of cardiac metastasis of  $8 \pm 8$  years. Patients most commonly presented with dyspnea (40%) and non-specific physical exam findings (Figure 2A,B). Cardiac metastasis was most often identified as a single mass (83%) located in the left ventricle (30%), right atrium (30%), or right ventricle (23%) (Figure 2C). Most cases were histologically confirmed (80%) and treatment strategies most often involved surgical intervention (55%) or immunotherapy (25%) (Figure 2D). Twenty-eight (70%) cases reported outcomes. When reported, follow-up times ranged from 0 to 5 years, with an average of  $0.8 \pm 1.3$  years. A total of 26 (65%) cases described at least one cardiovascular complication within one year after the diagnosis of cardiac metastasis, with the most common being right ventricular obstruction (40%), arrhythmia (35%), and pericardial effusion (20%). Of the 11 (39%) patients who were reported deceased, the majority (91%) perished within one year of cardiac metastasis diagnosis with 2 (18%) deaths due to cardiovascular complications. Detailed descriptions of patient findings from the systematic review are further depicted in Table S1.

### 3.3 | Retrospective cohort study and systematic review comparison

Patient demographics were similar between our cohort study and systematic review. Presenting symptoms and physical exam findings were generally non-specific. Patients commonly presented with one cardiac tumor but our cohort

**TABLE 1** Cohort study metastatic melanoma patient comparative analysis

	No cardiac metastasis (n = 1231)	Cardiac metastasis (n = 23)	p-value
<b>Demographics</b>			
Age at diagnosis, mean (SD)	61 (15)	58 (16)	0.29
Male, n (%)	775 (63.0)	13 (56.5)	0.68
Race, n (%)			
White	1181 (95.9)	21 (91.3)	0.56
Black/African American	11 (0.9)	2 (8.7)	0.009
<b>Clinical characteristics</b>			
Smoking history, n (%)	620 (50.4)	14 (60.9)	0.32
Body mass index, mean (SD)	29 (6)	29 (5)	0.84
<b>Comorbidities, n (%)</b>			
Diabetes mellitus	190 (15.4)	2 (8.7)	0.37
Hypertension	515 (41.8)	13 (56.5)	0.16
Heart failure	64 (5.3)	1 (4.3)	0.99
Anemia	72 (5.8)	2 (8.7)	0.90
Hypothyroidism	145 (11.8)	1 (4.3)	0.44
Depression	268 (11.8)	3 (13.0)	0.45
Coagulopathy	81 (6.6)	1 (4.3)	0.99
<b>Primary site, n (%)</b>			
Upper extremity	220 (17.8)	4 (17.4)	0.95
Lower extremity	181 (14.7)	2 (8.7)	0.42
Trunk	342 (27.8)	8 (34.8)	0.46
Head/Neck	366 (29.7)	5 (13.0)	0.41
Other	122 (10.0)	4 (17.4)	0.24
<b>Treatments<sup>a</sup>, n (%)</b>			
Surgery	67 (5.4)	3 (15.0)	0.10
Targeted therapies	451 (36.7)	7 (35.0)	0.54
Temozolomide	71 (5.8)	2 (10.0)	0.55
Vemurafenib	131 (10.6)	2 (10.0)	0.76
Dabrafenib	305 (24.8)	4 (20.0)	0.42
Trametinib	307 (24.9)	2 (10.0)	0.07
Dabrafenib/Trametinib	286 (23.3)	2 (10.0)	0.10
Immunotherapy	986 (80.1)	13 (65.0)	0.005
Pembrolizumab	467 (37.9)	6 (30.0)	0.25
Ipilimumab	480 (39.0)	9 (45.0)	0.99
Nivolumab	517 (42.0)	4 (20.0)	0.19
Nivolumab/Ipilimumab	246 (20.0)	5 (25.0)	0.83
Radiation	246 (20.0)	5 (25.0)	0.83
<b>Outcomes, n (%)</b>			
Mortality at 2-years	415 (33.7)	13 (56.5)	0.034

<sup>a</sup>Treatment methods for metastatic melanoma; three patients with cardiac metastasis did not receive treatment (analyses out of 20).

study showed cardiac metastasis presented most often in the right ventricle (65%), whereas our systematic review showed cardiac metastasis presented most often in the left

ventricle (30%) and right atrium (30%). Treatment with immunotherapy was more common in our cohort study compared with our systematic review (65% vs 25%), whereas

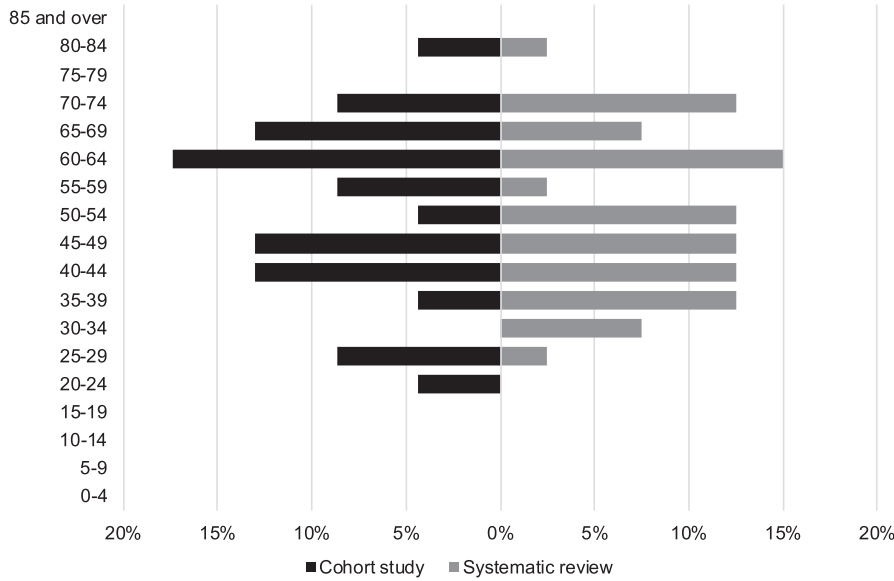


FIGURE 1 Patient population age distribution of patients with cardiac metastasis of melanoma comparing cohort study (black) vs systematic review (gray).

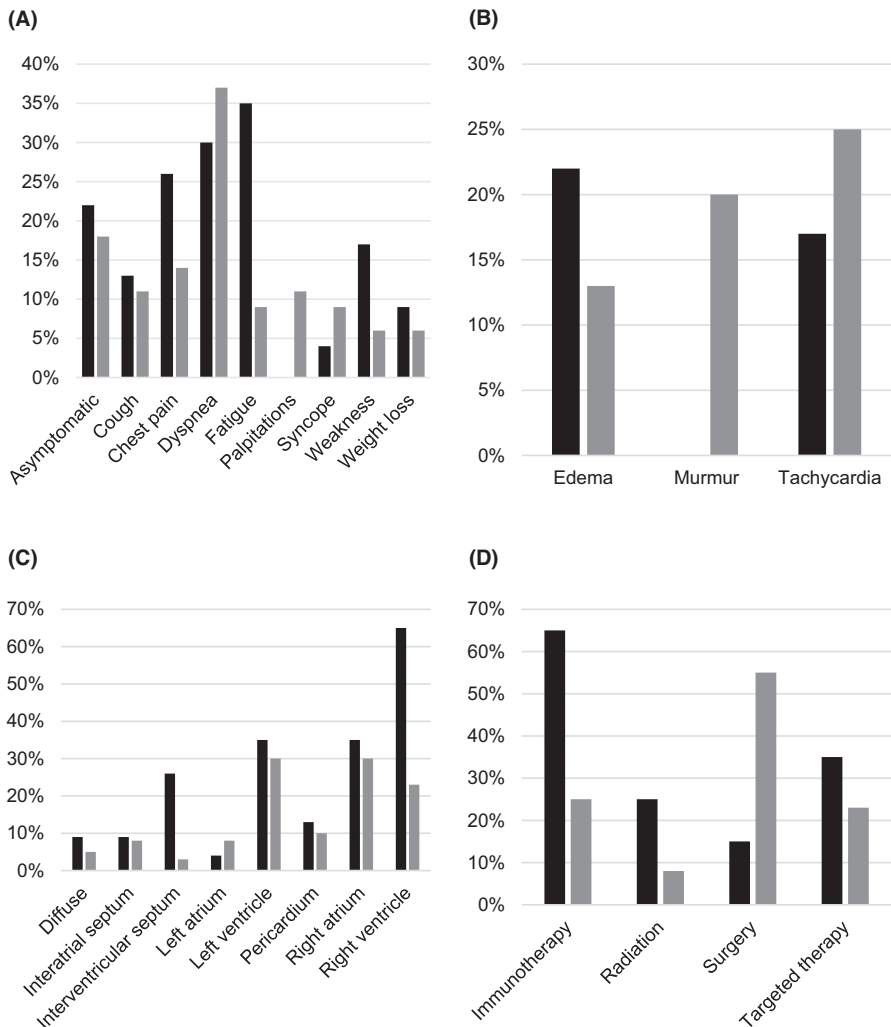


FIGURE 2 Comparison of the cohort study (black) vs systematic review (gray) patients: (A) symptoms at initial presentation, (B) physical exam findings at initial presentation, (C) cardiac metastasis of melanoma locations, and (D) cardiac metastasis of melanoma treatment strategies.

surgical intervention was used more often in our systematic review (55% vs 15%). Interestingly, mortality at 2-years was higher in our retrospective cohort study (59%) compared with our systematic review (39%).

#### 4 | DISCUSSION

In this retrospective cohort study of 1254 patients with metastatic melanoma over a 13-year period, cardiac

TABLE 2 Cohort study of detailed patient information

Sex/Age	Primary location	Signs and symptoms	Metastasis locations	Cardiac metastasis treatment	Follow-up from Cardiac Metastasis diagnosis (months)	Outcomes
F 73	Trunk	Nausea, epigastric pain	LV	Chemotherapy (NOS)	NR	NR
F 72	Nose	CP, epistaxis, weight gain, edema	RA, humerus	Median sternotomy, pericardial window, pembrolizumab, radiation	55	PD, DOD
M 74	Head	SOB, fatigue, nausea, syncope, weakness, diarrhea, hematochezia, back pain, dizziness, tingling, edema	RA, RV, IV septum, stomach	Dacarbazine, ipilimumab	4	PD, DOD
F 31	Lower extremity	Asymptomatic	RV, brain, liver, lung, cervical, thoracic, and lumbar spine, R eye	Radiation	10	PD, DOD
M 46	Back	Headache, R flank pain, tachycardia	RA, IA septum, brain, liver, lung	Dabrafenib, trametinib, ipilimumab, nivolumab, radiation	3	PD, intracranial hemorrhage, DOD
M 72	Upper extremity	Weight loss, L abdominal pain, intermittent night sweats	RV, brain, liver	Temozolomide, vemurafenib, ipilimumab	24	DOD
F 105	Head	Asymptomatic	Pericardium, lung, forehead	NR	10	DOD
M 66	Unknown	Asymptomatic	RV, brain, lung	Dabrafenib, trametinib	12	PD, DOD
M 44	Back	Cough, fatigue, weakness, tachycardia	LV, RV, IV septum, brain, lung, scalp, upper back	Ipilimumab, nivolumab	29	DOD
M 72	L ear	Cough, fatigue, headache	LV, brain, lung, spleen, R axilla	Ipilimumab, nivolumab	NR	NR
M 77	Trunk	Nausea, abdominal pain, constipation, decreased appetite, edema, tachycardia	RV, IV septum, liver, R groin	NR	0	PD, peritoneal carcinomatosis, acute renal failure, DOD
M 54	Trunk	Cough	LA, pericardium, lung, small bowel, thyroid	Pericardial window, ipilimumab	2	PD, DOD
M 72	Upper extremity	Fatigue, nausea, vomiting	RV, liver, lung	Pembrolizumab	16	PD, DOD

(Continues)

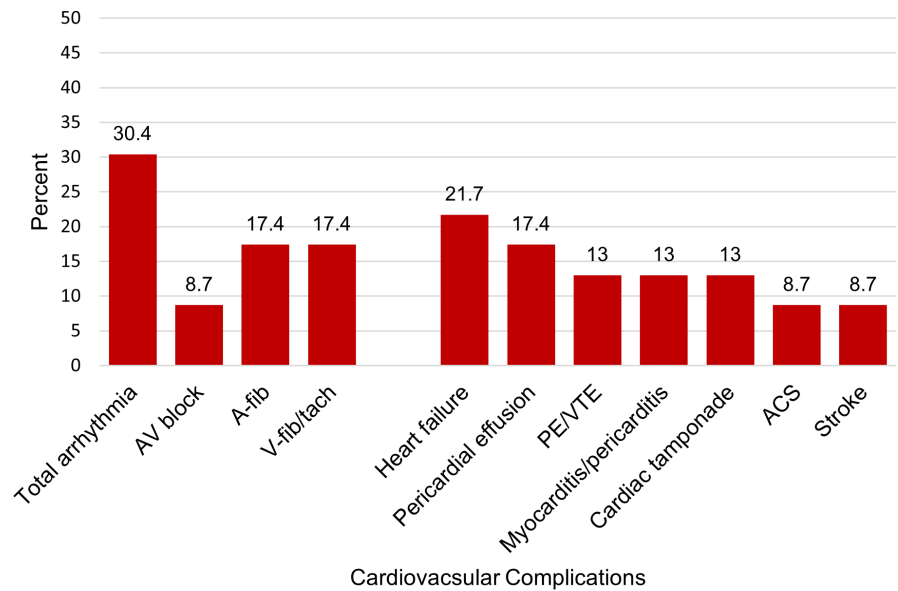
TABLE 2 (Continued)

Sex/Age	Primary location	Signs and symptoms	Metastasis locations	Cardiac metastasis treatment	Follow-up from Cardiac Metastasis diagnosis (months)	Outcomes
F 48	Neck	CP, SOB, fatigue, nausea, migraines, tachycardia	LV, RA, RV, IV septum, brain, liver, L thigh, stomach	Dabrafenib, trametinib, pembrolizumab, ipilimumab	25	DOD
M 59	Upper extremity	CP, SOB, sputum production	LV, RA, RV, IA septum, diffuse myocardium, brain, liver, lung, kidney, spleen	Median sternotomy, pericardial window, ipilimumab, radiation	5	Congestive heart failure, PD, DOD
F 34	Lower extremity	CP, SOB, fatigue, weakness, weight gain, edema	LV, RV, IV septum, brain, lower extremity, upper extremity, neck, kidney	Vemurafenib, dabrafenib, trametinib, melphalan, encorafenib, binimetinib, pembrolizumab, INF alfa-2b, talimogene laherparepvec	10	PD, DOD
F 54	Back	Altered mental status	Diffuse myocardium, brain, liver, kidney, spleen, spinal cord, eye, humerus, pelvis	NR	1	PD, multifocal cerebral infarction, DOD
F 76	R axilla	Asymptomatic	LV, hip	Pembrolizumab	NR	Remission
M 49	Back	Tinnitus, edema	Pericardium, RA, RV, brain, liver, thoracic spine, kidney, spleen	Temozolomide	2	PD, DOD
F 72	Vulva	Asymptomatic	RV, lymph node, vagina	Radiation	NR	NR
M 71	Trunk	CP, SOB, fatigue, weakness, weight loss, diarrhea	RA, RV, lung, stomach, pancreas, calf	NR	1	PD, DOD
M 48	Upper extremity	CP, SOB, fatigue	LV, RV, liver, pancreas, adrenal glands, spleen	Ipilimumab, nivolumab	NR	NR
F 75	Cervix	SOB	RA, RV, IV septum, lung, uterus, buttocks	NR	2	DOD

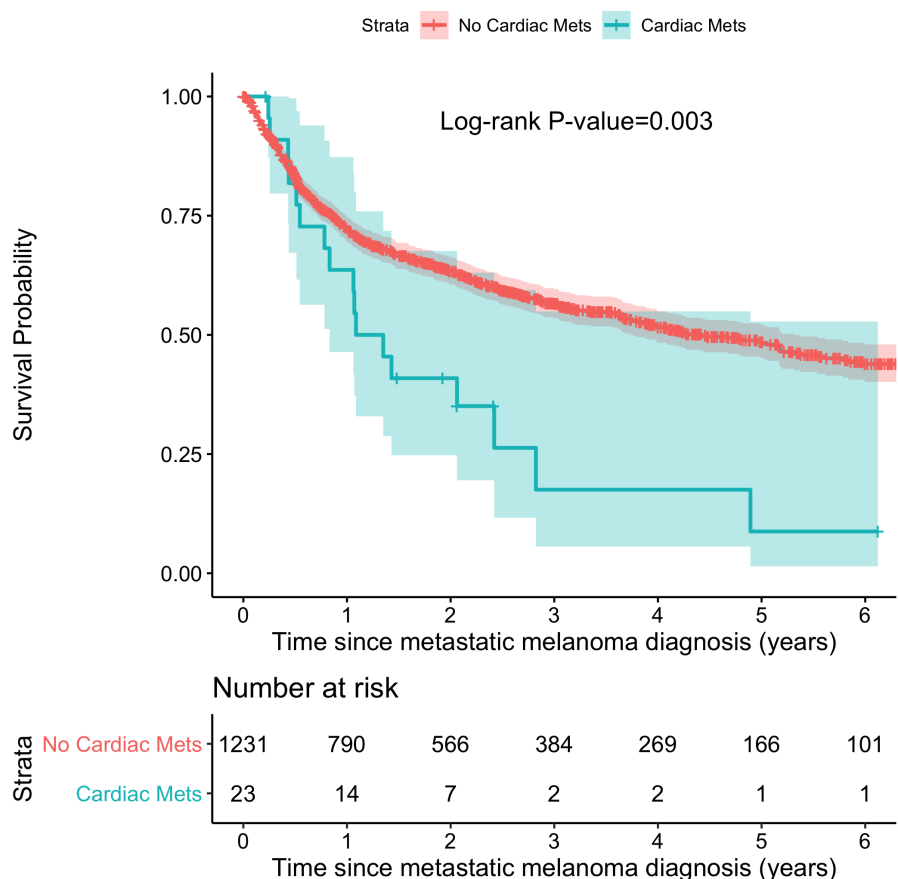
Abbreviations: CP, chest pain; DOD, died of disease; F, female; IA, interatrial; IV, interventricular; L, left; LA, left atrium; LV, left ventricle; M, male; NOS, not otherwise specified; NR, not reported; PD, progressive disease; R, right; RA, right atrium; RV, right ventricle; SOB, shortness of breath.

**FIGURE 3** Cumulative incidence of cardiovascular complications within one year after cardiac metastasis.

Abbreviations: ACS, acute coronary syndrome; AV, atrioventricular; A-fib, atrial fibrillation; PE, pulmonary embolism; V-fib, ventricular fibrillation; V-tach, ventricular tachycardia; VTE, venous thromboembolism.



**FIGURE 4** Kaplan–Meier survival curve stratified by cardiac metastasis.



metastasis occurred in <2% of patients and was associated with significantly worse mortality compared to patients with non-cardiac metastasis. Patients presented with a wide variety of symptoms and non-specific physical exam findings. Metastasis did not have a predilection for a specific cardiac structure, and a variety of cardiovascular complications occurred including arrhythmias, heart failure, and pericardial effusions. Treatment of

cardiac metastasis of melanoma commonly involved immunotherapy. Our systematic review of 1012 articles identified 40 additional cases which mostly supported the findings of our cohort study. The findings of our study highlight that cardiac metastasis from melanoma is an aggressive manifestation of this malignancy that can be difficult to identify clinically and is associated with worse outcomes.



Cardiac metastasis of melanoma can manifest as multiple small tumors, large masses, or infiltrative disease.<sup>12,51,52,53</sup> While other malignancies tend to involve the pericardium and epicardium, melanoma appears to have a particular propensity for endocardial involvement for reasons that are unknown.<sup>16</sup> While metastasis can involve any chamber of the heart, past studies have demonstrated that the right atrium is the most common location for cardiac involvement from metastatic melanoma.<sup>12,13,54</sup> Intracavitary metastases to the right atrium have been suggested to occur as a result of diffusion along the inferior vena cava, subsequently producing the intracavitary lesion.<sup>11</sup> Less frequently reported areas of cardiac metastases are the right ventricle and the left atrium.<sup>13</sup> Metastases to the left atrium are thought to arise in patients with lung cancer whose tumors embolize through the pulmonary circulation to the left atrium.<sup>11</sup> We found the most common locations of cardiac metastasis from melanoma included the left ventricle, right ventricle, and right atrium. To our knowledge, the involvement of the left ventricle has not been previously reported and may be related to the increased myocardial mass and vascularization of the left ventricle, which cardiac metastases of other malignancies have demonstrated a preference for.<sup>55</sup>

Cardiac involvement from metastatic melanoma typically occurs without specific clinical manifestations and is usually diagnosed post-mortem as a result.<sup>12</sup> Cases that are discovered ante-mortem are either incidental or symptomatic and cause non-specific symptoms such as fatigue, chest pain, exertional dyspnea, or leg edema, prompting a detailed cardiac evaluation.<sup>13</sup> Clinical findings are often a result of cardiac metastasis localization with arrhythmia due to conduction system or endomyocardial infiltration, heart failure due to an obstructive mass, and pericardial effusion.<sup>12,56,57</sup> In this study, the most common presenting symptoms were fatigue, dyspnea, and chest pain. Physical exam findings such as distant heart sounds, new murmurs, or a pericardial friction rub<sup>11</sup> may also be associated with cardiac involvement of metastatic melanoma but patients in this study did not demonstrate such specific physical exam findings.

Once diagnosed, the prognosis of cardiac metastasis from melanoma is poor. The average time between diagnosis of cardiac metastasis from melanoma and death has been reported to be two years.<sup>13</sup> Despite the poor prognosis, immunotherapy, targeted therapy, radiotherapy, and/or surgery can be useful to alleviate symptoms and reduce their cardiovascular impact.<sup>52,58,59,60</sup> While many patients in our retrospective cohort experienced at least one cardiovascular complication after the diagnosis of cardiac metastasis, all reported deaths were due to the progression of malignancy. Accordingly, the higher mortality in patients with cardiac metastasis compared to those without

is likely reflective of a higher tumor burden rather than a direct impact on the cardiovascular system.

In our systematic review, surgery was the main strategy utilized for tumor management and many patients experienced remission when surgery was implemented with the addition of other treatment options. Some cases opted for immunotherapy or targeted therapy as singular or combined therapies for patient treatment. Two patients died due to cardiovascular complications in our systematic review and both instances involved procedures (left ventriculotomy, endomyocardial biopsy) that may have further destabilized the integrity of a fragile myocardium, resulting in myocardial rupture. As some of our cases and other case reports predate the most modern and effective immunotherapies and targeted therapies, it is still to be determined how these therapies will impact the outcomes of patients with cardiac metastasis in the future.

#### 4.1 | Limitations

We sought to provide an estimate of incidence by performing a retrospective cohort study. Given the lack of systematic testing for cardiac metastasis or autopsy data, the incidence we report is likely an underestimate. We found a significantly higher 2-year mortality in patients with cardiac metastasis. However, the relatively small number of cases precludes performing stratified or multivariable analyses. While it is likely that the higher mortality in patients with cardiac metastasis reflects an increased tumor burden, the lack of systematic assessment of tumor burden precludes us from making definite conclusions. Similarly, findings from the cohort and systematic review suggest an endocardial rather than pericardial predilection of metastatic melanoma, however, these conclusions are not definite in the absence of systematic testing such as cardiac MRI or biopsy. Last, findings related to differences in race are exploratory at best and warrant validation.

## 5 | CONCLUSION

This is the largest cohort study investigating the prevalence, clinical presentation, treatment, and outcomes of metastatic melanoma of the heart and provides a contemporary characterization of the disease. Cardiac metastasis occurs in <2% of patients with metastatic melanoma but is associated with high mortality. Patients may present with a wide variety of symptoms, and clinicians should maintain a high index of suspicion for cardiac metastasis when patients present with fatigue, dyspnea, and a history of melanoma. Cardiac metastasis of melanoma may involve any chamber of the heart and a predilection for a specific cardiac structure is unclear.

Treatment strategies typically involve immunotherapy, targeted therapy, radiotherapy, or surgical intervention when indicated. Cardiovascular complications may occur after the diagnosis of cardiac metastasis of melanoma, however, with limited impact on mortality, which is predominantly due to progression of malignancy.

## AUTHORS' CONTRIBUTION

**Alexander M. Balinski:** Conceptualization, data curation, formal analysis, investigation, methodology, writing—original draft, and writing—review and editing; **Alexi L. Vasbinder:** Data curation, formal analysis, methodology, writing—original draft, and writing—review and editing; **Connor C. Kerndt:** Data curation, writing—original draft, and writing—review and editing; **Tonimarie C. Catalan:** Data curation; **Nathan P. Parry:** Formal analysis; **Rafey A. Rehman:** Data curation; **Pennelope Blakely:** Data curation; **Raymond Y. Yeow:** Writing—review and editing; **Monika J. Leja:** Writing—review and editing; **Christopher D. Lao:** Writing—review and editing; **Leslie A. Fecher:** Writing—review and editing; **Salim S. Hayek:** Conceptualization, formal analysis, investigation, methodology, project administration, supervision, writing—original draft, and writing—review and editing.

## ACKNOWLEDGMENTS

None.

## FUNDING INFORMATION

ALV is supported by an NHLBI-funded postdoctoral fellowship (T32HL007853). SSH is funded by the NHLBI (1R01HL153384-01) and the NIDDK (1R01DK12801201A1).

## CONFLICT OF INTEREST

None.



## DATA AVAILABILITY STATEMENT

The data that support the findings of this study are available on request from the corresponding author. The data are not publicly available due to privacy or ethical restrictions.

## ORCID

Alexander M. Balinski  <https://orcid.org/0000-0002-6509-7689>

Alexi L. Vasbinder  <https://orcid.org/0000-0002-1380-5364>

Connor C. Kerndt  <https://orcid.org/0000-0002-0435-619X>  
Rafey A. Rehman  <https://orcid.org/0000-0002-8463-5139>

Pennelope Blakely  <https://orcid.org/0000-0002-9677-3010>

Raymond Y. Yeow  <https://orcid.org/0000-0003-0985-3758>

Salim S. Hayek  <https://orcid.org/0000-0003-0180-349X>

## REFERENCES

- Rastrelli M, Tropea S, Rossi CR, Alaibac M. Melanoma: epidemiology, risk factors, pathogenesis, diagnosis and classification. *In Vivo (Brooklyn)*. 2014;28(6):1005-1012.
- Siegel R, Ma J, Zou Z, Jemal A. Cancer statistics, 2014. *CA Cancer J Clin*. 2014;64(1):9-29.
- Joose A, de Vries E, Eckel R, et al. Gender differences in melanoma survival: female patients have a decreased risk of metastasis. *J Invest Dermatol*. 2011;131(3):719-726.
- de Vries E, Bray FI, Coebergh JWW, Parkin DM. Changing epidemiology of malignant cutaneous melanoma in Europe 1953-1997. *Int J Cancer*. 2003;107:119-126.
- Robinson JK, Mallett KA, Turrisi R, Stapleton J. Engaging patients and their partners in preventive health behaviors the physician factor. *Arch Dermatol*. 2009;145(4):469-473.
- Swetter SM, Johnson TM, Miller DR, Layton CJ, Brooks KR, Geller AC. Melanoma in middle-aged and older men: a multi-institutional survey study of factors related to tumor thickness. *Arch Dermatol*. 2009;145(4):397-404.
- Joose A, Collette S, Suci S, et al. Superior outcome of women with stage I/II cutaneous melanoma: pooled analysis of four European Organisation for Research and Treatment of Cancer phase III trials. *J Clin Oncol*. 2012;30(18):2240-2247.
- Wolchok JD, Chiarion-Sileni V, Gonzalez R, et al. Long-term outcomes with nivolumab plus ipilimumab or nivolumab alone versus ipilimumab in patients with advanced melanoma. *J Clin Oncol*. 2022;40(2):127-137.
- Robert C, Karaszewska B, Schachter J, et al. Improved overall survival in melanoma with combined dabrafenib and trametinib. *N Engl J Med*. 2015;372(1):30-39.
- Tas F. Metastatic behavior in melanoma: timing, pattern, survival, and influencing factors. *J Oncol*. 2012;2012:647684.
- Bussani R, De-Giorgio F, Abbate A, Silvestri F. Cardiac metastases. *J Clin Pathol*. 2007;60(1):27-34.
- Glancy DL, Roberts WC. The heart in malignant melanoma. A study of 70 autopsy cases. *Am J Cardiol*. 1968;21(4):555-571.
- Wood A, Markovic SN, Best PJM, Erickson LA. Metastatic malignant melanoma manifesting as an intracardiac mass. *Cardiovasc Pathol*. 2010;19(3):153-157.
- Tyebally S, Chen D, Bhattacharyya S, et al. Cardiac tumors: JACC CardioOncology state-of-the-art review. *JACC Cardio Oncol*. 2020;2(2):293-311.
- Klatt EC, Heitz DR. Cardiac metastases. *Cancer*. 1990;65(6):1456-1459.
- MacGee W. Metastatic and invasive tumours involving the heart in a geriatric population: a necropsy study. *Virchows Arch A Pathol Anat Histopathol*. 1991;419(3):183-189.
- Moher D, Liberati A, Tetzlaff J, Altman DG, PRISMA Group. Preferred reporting items for systematic reviews and meta-analyses: the PRISMA statement. *PLoS Med*. 2009;6(7):e1000097.
- Burns PB, Rohrich RJ, Chung KC. The levels of evidence and their role in evidence-based medicine. *Plast Reconstr Surg*. 2011;128(1):305-310.
- Rosario RT, DiMaio DJ, Lapham RL, Sweeney M, Smalling R, Barasch E. Metastatic ocular melanoma to the left ventricle

- inducing near-syncope attacks in an 84-year-old woman. *Chest*. 2000;118(2):551-553.
20. Kolandjian NA, Patel SP, Papadopoulos NE, Bedikian AY. The left ventricle as the first site of uveal melanoma metastasis 13 years after treatment of the primary tumor. *Melanoma Res*. 2011;21(2):160-163.
  21. Jakate K, Yanagawa B, Cusimano RJ, Butany J. Uveal melanoma metastasising to the heart after 39 years. *J Clin Pathol*. 2010;63(12):1132-1133.
  22. Ruiz RS, El-Harazi S, Albert DM, Bryar PJ. Cardiac metastasis of choroidal melanoma. *Arch Ophthalmol*. 1999;117(11):1558-1559.
  23. Faustino M, Abecasis J, Freitas A, Gouveia R, Gil V. Symptomatic charcoal heart. *Eur Hear J Cardiovasc Imaging*. 2014;15(4):365.
  24. Catapano-Minotti G, Torracca L, Rizzo N, Corsonello A, Incalzi RA. A case of metastatic melanoma in the heart: does echocardiographic screening matter? *Melanoma Res*. 2008;18(3):239-240.
  25. Bertella E, Muri M, Negri F, et al. QUICK FIRE CASES-SESSION II 188. AN UNCOMMON METASTATIC MELANOMA. *Eur Hear J Cardiovasc Imaging*. 2017;18(suppl\_2):ii122.
  26. Park R, Vincent K, Abdelrahman AA, Krishnan M, Koppala J. An unusual presentation of recurring metastatic melanoma. *J Surg Case Rep*. 2016;2016(3):rjw030.
  27. Krüger T, Heuschmid M, Kurth R, Stock UA, Wildhirt SM. Asymptomatic melanoma of the superior cavo-atrial junction: the challenge of imaging. *World J Cardiol*. 2012;4(1):20-22.
  28. Tas F, Mudun A, Kirma C. Cardiac involvement in melanoma: a case report and review of the literature. *J Cancer Res Ther*. 2010;6(3):359-361.
  29. Mousseaux E, Meunier P, Azancott S, Dubayle P, Gaux JC. Cardiac metastatic melanoma investigated by magnetic resonance imaging. *Magn Reson Imaging*. 1998;16(1):91-95.
  30. Pedrotti P, Musca F, Torre M, et al. Cardiac metastatic melanoma: imaging diagnostic clues. *J Cardiol Cases*. 2015;12(2):33-36.
  31. Kontozis L, Soteriou M, Papamichael D, et al. Isolated right atrial metastasis of malignant melanoma mimicking a myxoma. *Hellenic J Cardiol*. 2011;52(3):281-284.
  32. Kumar M, Tigadi S, Azrin MA, Kim AS. Multimodality imaging of a right atrial cardiac mass. *Cureus*. 2019;11(5):e4705.
  33. Roubille F, Gahide G, Cayla G, et al. Recent malignant dyspnea. *Intern Med*. 2008;47(5):427-429.
  34. Mindell SM, Chernick AW, Sugarman MH, Zirkin RM, Bloom RE. Right ventricular metastatic melanoma 27 years after resection of the primary tumor. *Cancer*. 1989;63(6):1237-1239.
  35. Magnuson WJ, Halligan JB. Successful treatment of melanoma metastatic to the left atrium using external beam radiation therapy. *Oncology (Williston Park)*. 2010;24(7):650-653.
  36. Judge JM, Tillou JD, Slingluff CL, Kern JA, Kron IL, Weiss GR. Surgical management of the patient with metastatic melanoma to the heart. *J Card Surg*. 2013;28(2):124-128.
  37. Cicin I, Usta U, Sezer A, et al. Synchronous tonsil, gallbladder, and cardiac metastases without any other visceral metastases of malignant melanoma. *Onkologie*. 2009;32(4):197-199.
  38. Khan MA, Pham DC, Guthrie TH. An unusual presentation of metastatic melanoma. *Community Oncol*. 2011;8(10):445-446.
  39. Safa H, Glitza Oliva IC. Cardiac metastases in melanoma. *N Engl J Med*. 2019;380(9):858.
  40. Merer DM, Dutcher JP, Mercado A, et al. Case report: clinical findings and successful resection of melanoma metastatic to the right atrium. *Cancer Invest*. 1994;12(4):409-413.
  41. Ellis CJ, Dennison EM, Simpson IA. Imaging of cardiac metastatic melanoma: trans-oesophageal echocardiography or magnetic resonance imaging? *Int J Cardiol*. 1993;41(2):176-179.
  42. Beliaev AM, Ruygrok PN, Stephens R, Haydock DA. Multidisciplinary management of metastatic melanoma to the inter-atrial septum. *ANZ J Surg*. 2019;89(3):258-260.
  43. Babar A, Lak H, Chawla S, Mahalwar G, Maroo A. Metastatic melanoma presenting as a ventricular arrhythmia. *Cureus*. 2020;12(4):e7634.
  44. Haiduk J, Ziemer M. Pregnancy in a patient with metastatic uveal melanoma treated with nivolumab. *J Ger Soc Dermatol*. 2021;19(5):762-765.
  45. Poggi R, Pantaleo MA, Benedetti G, Biasco G. Cardiac metastasis of melanoma. *Melanoma Res*. 2005;15(4):315-316.
  46. Friedel I, Burchert W, Horstkotte D, Faber L. A rare case of cardiac melanoma mimicking hypertrophic cardiomyopathy. *Can J Cardiol*. 2017;33(7):950.e1-950.e3.
  47. Fontana A, Corsi D, Viganò E, Trocino G, Achilli F. Added value of real time three-dimensional echocardiography in the diagnosis of an apical right ventricular metastasis from malignant melanoma. *Echocardiography*. 2013;30(1):E16-E20.
  48. Durham CG, Hall JA, Fidone EJ, Mack R, Metting AL. Melanoma to the heart. *Proc (Bayl Univ Med Cent)*. 2016;29(4):428-429.
  49. Burn PR, Chinn R, King DM. Right atrial metastatic melanoma detected by dynamic contrast enhanced spiral CT. *Br J Radiol*. 1999;72(856):395-396.
  50. Steger CM, Mehmeti A, Fischler N. Metastatic melanoma. *BMJ Case Rep*. 2012;2012:bcr0220125754.
  51. Lobo A, Lewis JF, Conti CR. Intracardiac masses detected by echocardiography: case presentations and review of the literature. *Clin Cardiol*. 2000;23(9):702-708.
  52. Gibbs P, Cebon JS, Calafiore P, Robinson WA. Cardiac metastases from malignant melanoma. *Cancer*. 1999;85(1):78-84.
  53. Malouf JF, Thompson RC, Maples WJ, Wolfe JT. Diagnosis of right atrial metastatic melanoma by transesophageal echocardiographic-guided transvenous biopsy. *Mayo Clin Proc*. 1996;71(12):1167-1170.
  54. Bossert T, Van Son JAM, Autschbach R, Mohr FW. Resection of a right atrial metastatic melanoma with unknown origin of primary tumor. *Eur J Cardiothorac Surg*. 1999;15(3):373-375.
  55. Roberts WC. Primary and secondary neoplasms of the heart. *Am J Cardiol*. 1997;80(5):671-682.
  56. Emmot WW, Vacek JL, Agee K, Moran J, Dunn MI. Metastatic malignant melanoma presenting clinically as obstruction of the right ventricular inflow and outflow tracts. Characterization by magnetic resonance imaging. *Chest*. 1987;92(2):362-364.
  57. Houmsse M, Raman SV, Leier CV, Orsinelli DA. Metastatic melanoma of the left ventricle: cardiac imaging in the diagnosis and surgical approach. *Int J Cardiovasc Imaging*. 2004;20(6):523-526.
  58. Larkin J, Chiarion-Sileni V, Gonzalez R, et al. Five-year survival with combined nivolumab and ipilimumab in advanced melanoma. *N Engl J Med*. 2019;381(16):1535-1546.
  59. Robert C, Grob JJ, Stroyakovskiy D, et al. Five-year outcomes with dabrafenib plus trametinib in metastatic melanoma. *N Engl J Med*. 2019;381(7):626-636.

60. Fotouhi Ghiam A, Dawson LA, Abuzeid W, et al. Role of palliative radiotherapy in the management of mural cardiac metastases: who, when and how to treat? A case series of 10 patients. *Cancer Med.* 2016;5(6):989-996.

### SUPPORTING INFORMATION

Additional supporting information can be found online in the Supporting Information section at the end of this article.

**How to cite this article:** Balinski AM, Vasbinder AL, Kerndt CC, et al. Metastatic melanoma of the heart: Retrospective cohort study and systematic review of prevalence, clinical characteristics, and outcomes. *Cancer Med.* 2023;12:2356-2367. doi: [10.1002/cam4.5058](https://doi.org/10.1002/cam4.5058)