

Digital planning for two-implant supported overdenture and bone reduction guide using cone beam computed tomography: simple features for predictable outcomes

Running Title: BONE REDUCTION AND TWO-IMPLANT OVERDENTURE GUIDE

Priscila Ceolin Meneghetti DDS MS^{1,2}, Hamoun Sabri DMD PgC^{3,4},

Ebrahim Dastouri DMD³, Rafael Martins Afonso Pereira, DDS, MS^{1,3},

Wendel Teixeira, DDS MS PhD¹, Hom-Lay Wang DDS MSD PhD³,

Gustavo Mendonça DDS MS PhD¹

¹ Department of Biological and Materials Sciences & Prosthodontics, University of Michigan School of Dentistry, Ann Arbor, MI, USA

² School of Health and Life Sciences, Pontifical Catholic University of Rio Grande do Sul, Porto Alegre, Brazil

³ Department of Periodontics and Oral Medicine, University of Michigan School of Dentistry, Ann Arbor, MI, USA

⁴ Cranio-Maxillofacial Research Center, Shahid Beheshti University of Medical Sciences, Tehran, Iran

Correspondence to:

Gustavo Mendonça, DDS MS PhD

Clinical Professor,

Department of Biologic and Materials Sciences & Prosthodontics,

University of Michigan School of Dentistry,

1011 North University, room K1027,

Ann Arbor, MI 49109-1078

E-mail: mgustavo@umich.edu

Gustavo Mendonça, <https://orcid.org/0000-0003-2290-4046>

This is the author manuscript accepted for publication and has undergone full peer review but has not been through the copyediting, typesetting, pagination and proofreading process, which may lead to differences between this version and the [Version of Record](#). Please cite this article as [doi: 10.1111/jopr.13657](https://doi.org/10.1111/jopr.13657).

This article is protected by copyright. All rights reserved.

Rafael Martins Afonso Pereira, <https://orcid.org/0000-0002-1085-0813>

Hamoun Sabri, <https://orcid.org/0000-0001-6581-2104>

Conflict of Interest: The authors declare no conflict of interest regarding this technical note.

Accepted date January 22, 2023

ABSTRACT

The two-implant-supported mandibular overdenture is considered a reliable treatment option to restore masticatory function. Digital planning has shown to improve the precision and accuracy of the surgical procedure. The outcomes are indeed pertinent to the ideal 3D positioning of the implant placement. Recently, the use of cone-beam computed tomography (CBCT) and intraoral scan (IOS) have improved greatly the workflow of digital planning, however, the sophisticated technology caused confusion among the clinicians. The purpose of this case series was to exhibit the efficacy of a bone-supported guide in applying simultaneous implant placement and bone reduction solely based upon CBCT data. The bone reduction can therefore be determined accordingly, by adding windows to the guide, allowing the clinician to decide the amount of bone reduction as well as the location for implant placement. This novel surgical guide would not only fit properly on the bone, but also provide benefits of less-invasive surgery and the opportunity to place implants parallel. The digital workflow described not only simplifies the fabrication process, but also yields predictable surgical outcomes.

Keywords: overdenture, digital workflow, dental implants, surgical guide, digital dentistry, alveoloplasty

INTRODUCTION

This article is protected by copyright. All rights reserved.

Along with the rise of the implant dentistry era, conventional complete dentures also underwent a major transformation. One of these changes is the rehabilitation of mandibular edentulous ridge using two-implant-supported overdentures.¹ According to the latest evidence, this treatment is considered the minimum standard of care for edentulous patients.¹ More than two implants may also be placed for an implant-retained overdenture.²

Conventionally, the overdenture and its implant surgical guide fabrication are performed in the dental laboratory setup, which possess a high risk of operator bias and also an extensive treatment time due to the existence of several manual steps.^{2,3} Thanks to the recent advances in digital dentistry, the abovementioned hurdles can be eliminated when the principles of the two-implant-supported overdenture treatments are combined with state-of-the-art technology.^{3,4} Moreover, digitally designed surgical guides have been brought into dentistry and are widely being used for the precise implant placement in order to support implant retained prostheses.^{4,5} The use of digital technology in the reconstruction of the mandible by two-implant-supported overdentures has been reported in several studies.^{2,3,6-9} More specifically, a bone reduction guide in these cases was initially introduced by Ganz¹⁰ in 2006. Similar digital workflows were utilized later by other groups¹¹⁻¹³ as well. However, this consisted of designing two surgical guides for osteoplasty and implant drilling separately. Similar digital workflows have also been presented in all-on-four^{14,15} or other fixed prostheses^{16,17} cases.

Management of morphologic limitations of the edentulous ridge is vital. In the classic literature, Cawood and Howell⁴ classified the edentulous ridge types and assigned the knife-edge mandibular ridge as class IV. This ridge type is considered challenging for two-implant supported overdentures since it requires reshaping and reducing the alveolar ridge. In addition to this, the key factors in the treatment workflow are achieving parallelism between

the implants and placing them perpendicularly to the occlusal plane.³ Therefore, the fabrication of a surgical guide with the exact location and amount of ridge height reduction to facilitate ideal implant placement would be crucial. Moreover, several studies have reported successful outcomes of computer-guided flapless surgery for overdentures^{3,7,8} however, the bone reduction has not been discussed, and the studies in the literature addressing these issues are scarce. Thus, the objective of this technical report was to introduce a step-by-step guide for designing and fabricating a digital surgical guide, for bone reduction and implant placement together and based solely on cone-beam computed tomography (CBCT) images, which can be employed in cases when the previous denture is not in an ideal condition, there is lack of data regarding it, or the denture cannot be used for taking the CBCT due to any reason.

CLINICAL REPORT AND TECHNIQUE

Ideally, a prosthetically-driven implant positioning is mandatory to obtain long-term success in implant rehabilitations. To follow a digital workflow for placing two implants in the edentulous mandible, two situations are usually faced: 1) the patient already uses a denture in a good condition (occlusal vertical dimension (OVD)); 2) the patient's old denture needs to be replaced or they do not have a denture, where a new OVD should be established.

Regardless of the situation, it is important to acquire a new OVD and determine the required space for abutments and metal ring housing caps. To achieve this, a CBCT is required with the denture in position, with radiopaque markers on it for posterior software alignment. When using the implant studio software (3Shape), through the "Dual Scan" technique, a CBCT of the prosthesis is required. Dentures can also be scanned with an intraoral scanner and other software can also be used. A bite registration with radiopaque material could be necessary as well. If any of the mentioned steps are forgotten by the clinician, the patient would need to repeat some procedures, extending the treatment time. In an attempt to compensate for

possible mistakes and save time, two cases (#3 and 4) which were designed solely using CBCT scans without using the old dentures, are also presented in this technique report.

Patients presentation

Retrospectively, four cases were selected for demonstration purposes. All patients presented with the chief complaint of failing previous lower denture and following the clinical and para-clinical evaluations and diagnoses, all were planned to receive a new mandibular two-implant supported overdenture.

Pre-surgical protocol and treatment planning

The residual ridges at the sites of planned implants were convergent apico-coronally and their width was insufficient to cover the implants. To address the retention and function issues, the following procedures were proposed. 1) Bone reduction in the anterior mandible to facilitate the implant placement at the time of implant surgery; 2) A healing period of at least 3 months; and 3) Fabrication of a new implant-supported mandibular overdenture. The amount of bone reduction and type of implants placed are provided in Table 1. Considering the aforementioned factors, the digital planning of the cases was carried out. The objective was to direct the placement of the implants in an ideal 3D position, as well as to demarcate the amount of the ridge that should be reduced and removed. Thus, a unique guide was designed, combining alveoloplasty and implant placement.

Digital workflow

For this proposed digital workflow, the mandibular CBCT is solely sufficient and required. The CBCT images were obtained and saved in digital imaging and communication in medicine (DICOM) format. The implant positioning was achieved as follows; the implants were planned to be placed in the distal of the lateral incisors, and this distance was measured

based on the average size of lower incisors. Therefore, a distance around 15 to 17 mm was considered to place the implants, depending on the size of the arch. Additionally, a safe distance from the mental foramen was kept. The vertical position of the implants was addressed based on the width of the available surrounding bone. In some cases, bone graft was also required.

To design and fabricate the bone reduction and implant placement surgical guide, the following steps were performed:

1. Import CBCT DICOM files into the implant Studio Software (3Shape A/G, Copenhagen, Denmark) version 2022; (some cases were performed using an older version, thus the CBCTs were imported into the software BlueSkyPlan (BlueSkyBio LLC) first, to create a mandible model and export as an .STL file) (Fig 1).
2. Select the lower jaw and a bone supported guide.
3. Refine the bone surface.
4. Set up the panoramic view. Modify the position of the plane to adjust the cross-section where you want to obtain the panoramic curve (Fig 3).
5. Detect the inferior alveolar nerve for both sides.
6. Add and position the selected implants between mental foramens. Place the two implants parallel to each other, and perpendicular to the occlusal plane. After finalizing the vertical orientation (depth) of the implants, check the amount of bone above the implant platform that needs to be removed and confirm parallelism. Ideally, the implants should be covered completely by the remaining bone, otherwise bone grafting can be performed. At this step the level at which the bone reduction should be performed can be achieved and marked. Next, choose the respective implant sleeves (Fig 5).

7. To create a surgical guide, a line must be drawn surrounding the implants on the bone surface. Caution is required to have enough bone support and also the flap extension should be considered. Window openings should be added at the level of implant crest, guiding the bone reduction accurately and safely for the surgeon (Fig 6). This can be placed in the desired part of the surgical template. In the cases demonstrated in this study, the windows were placed in two separate openings at the implant sites and one opening between two implants (Case 1), one continuous window connecting two implant sites (Case 2), only one opening in the mid-part (Case 3), and two separate windows at implant sites (Case 4).

As described, the window openings for alveoloplasty guide can be placed in various parts of the guide and each of them has its own pros and cons (Table 1). The specific clinical scenarios and subsequent treatment approaches are described in Figures 7-10.

Surgical protocol

The four presented subjects underwent two-implant-supported overdenture surgery.

Following bilateral inferior alveolar nerve blocks and complementary local injections to achieve hemostasis, by the means of a midcrestal incision, a full-thickness flap was reflected. Next, the surgical guide was placed on the site, and stability was checked. Adjustments with a hand-piece bur can be performed if required to adjust the guide onto the bone surface. Owing to the anatomical arch shape of mandible, the guide can be fit perfectly on the bone, without moving laterally. This step was checked in all cases, as a result of which, the authors did not add any fixation pins to the novel guide. This also made it much easier to take out and place back repeatedly during the surgery for checking purposes. Following this step, the implant drilling protocol was performed first, and the level of the bone reduction was marked using a knife-edge burr through the designed windows on the surgical guide. Next, the surgical guide

was removed, and the ridge was reduced and flattened to the limits of the marked line in the previous step. Subsequently, implants were installed by a free hand approach. Cover screws were placed, and the flap was sutured. It should be noted that based on multiple factors the implants can also be placed using a fully guided method; if the implant system is compatible with guided implant placement (the system used here does not allow guided placement) and/or if the guide is still stable following the bone reduction. Overall, the following protocol is suggested: 1- implant drilling sequence, 2- osteoplasty, and 3-implant placement with or without the guide. The steps can be modified based on the clinician's judgement regarding the stability of the guide and utilized implant system.

DISCUSSION

In the subjects requiring rehabilitation of the masticatory system, precision, reduced treatment time, and more comfortable approaches are crucial.^{5,18} Implant-supported overdentures have been introduced as a replacement option for conventional dentures, bringing improved retention and masticatory function as well as esthetics and phonetics to patients.^{8,19} The combination of this treatment with the advances in digital dentistry have enhanced the desired outcomes even more. Previously, several reports have introduced and implemented a digital workflow to plan a surgical guide for the treatment of these patients. Ganz,¹⁰ Lanis and Tahmaseb,¹² Beretta et al,¹⁵ and Nikzad et al¹⁶ introduced digitally fabricated bone reduction guides for mandibular all-on-four or implant-supported fixed prostheses. However, all the previously designed guides consisted of two- or three-piece surgical guides (fixation pin, osteoplasty and implant placement), whereas this technical report presented a digitally fabricated surgical guide that allows for not only the residual ridge reduction but also the optimal implant positioning in two-implant-supported overdenture cases. This novel guide brings into action the two mentioned features at the same time using the state-of-the-art digital dentistry software using solely CBCT images.

Also, to the best of the authors' knowledge, this is the first report describing the digital workflow for two-implant-overdentures with bone reduction.

The previously described benefits of using digital guides consist of increased precision, minimal operator bias, and reduced amount of total pre-surgical time as a result of elimination of the laboratory processes.²⁰ In addition, the intra-operative phase of the treatment is also affected positively by the use of the introduced surgical guide.³ It is emphasized that free-hand placement of dental implants escalates the risk of errors and compromises achieving the ideal position as well as the parallelism concept.²¹ As demonstrated in this paper, the proposed surgical guide not only facilitates parallel implant placement, but also provides a reliable reference point (through the designed window) to mark-up the osteotomy level.

In addition, alveoloplasty is often indicated when dealing with a knife edge mandibular ridge at the time of implant placement²² and also to keep the implants leveled at the same height. This procedure is performed to create a smooth shelf of bone and also, adequate width for implant housing. However, clinicians can face several challenges such as mental nerve proximity, especially in atrophic ridges.²² The fact that the windows in the guide are designed based on the landmarks from CBCT images, adds value to this proposed guide and decreases the risk of complications. Moreover, this is applicable to different clinical scenarios and anatomic presentations thanks to the cutting-edge digital dentistry software that provides maximum flexibility in terms of designing surgical guides.²³

Despite the aforementioned advantages, the required sequence of utilizing the guide for site preparation (drilling first and then performing the bone reduction) might be challenging as conventionally the reverse sequence is followed in order to prepare the ridge for placing implants. Likewise, the digital workflow presented in this paper, requires

experience and knowledge in the utilized software, which might be time-consuming to follow. Nevertheless, a limitation to the introduced guide would be the possibility of lacking or losing stability during the surgery. Although the horizontal windows utilized in Cases 2 and 4 provide more stability of the guide, more flap reflection is needed. Nonetheless, the possible lack of stability can be solved by adding fixation pins to the guide which necessitates further research on this topic and different designs of the bone reduction window.

Similar studies proposed various designs for the same purpose,^{2,3,8,24} all of which reported improved patient-related outcomes and a more straightforward approach for the dentist. Nevertheless, none of the protocols addressed the need for utilizing a single guide that can provide guidance for both bone reduction and implant placement which is the novelty of the method introduced here. Overall, more simplified and more precise surgical execution can be carried out by the means of the proposed surgical guide.

Despite the mentioned benefits, it should be noted that the advantageous outcomes described are solely based on the experience of authors on a limited number of cases. Thus, as a result of the limitation of the framework of case reports, further experiments and ideally quantitative assessment and analysis would be beneficial to strengthen the reported outcomes.

CONCLUSION

Within its limitations, this technical report introduced a surgical guide composed of simultaneous bone reduction and implant placement further providing a step-by-step digital workflow for its fabrication.

ACKNOWLEDGMENTS

The authors gratefully thank the University of Michigan Periodontics residents Drs. Iya Ghassib, Liana Webber, Matthew Galli and Larissa Steigmann for the case documentations.

References

1. Feine J, Carlsson G, Awad M, Chehade A, Duncan W J, Gizani S, et al. The McGill consensus statement on overdentures. Mandibular two-implant overdentures as first choice standard of care for edentulous patients. *Gerodontology* 2002;19:3-4
2. Turkyilmaz I. Restoring edentulous mandible with an implant-retained overdenture in a day by means of flapless surgery and stereolithographic surgical guide: a case report. *J Oral Maxillofac Res.* 2019 Mar 31;10(1):e5.
3. An X, Chui Z, Yang HW, Choi BH. Digital workflow for fabricating an overdenture by using an implant surgical template and intraoral scanner. *J Prosthet Dent.* 2020;123(5):675-679.
4. Cawood JI, Howell RA: A classification of the edentulous jaws. *Int J Oral Maxillofac Surg* 1988;17:232-236
5. Brkovic-Popovic S, Stanisic-Sinobad D, Postic SD, Djukanovic D. Radiographic changes in alveolar bone height on overdenture abutments: a longitudinal study. *Gerodontology.* 2008;25(2):118-223.
6. El Aziz MSA, El Megid Tella EAESA. Fully digital workflow for reinforced mandibular implant overdenture - A novel method. *J Indian Prosthodont Soc.* 2022;22(2):205-209.
7. Sato D, Kanazawa M, Kim YK, Yokoyama S, Omura Y, Ozeki M et al. Immediate loading of two freestanding implants placed by computer-guided flapless surgery supporting a mandibular overdenture with magnetic attachments. *J Prosthodont Res.* 2016;60(1):54-62.
8. Velasco-Ortega E, Jiménez-Guerra A, Ortiz-Garcia I, Garrido NM, Moreno-Muñoz J, Núñez-Márquez E, et al. Implant treatment by guided surgery supporting overdentures in edentulous mandible patients. *Int J Environ Res Public Health.* 2021;18(22):11836.

9. Pimentel Ramirez EG, Sanchez S, Suarez F. Digital planning for implant retained overdentures. *Clin Dent Rev* **5**, 9 (2021). <https://doi.org/10.1007/s41894-021-00097-z>
10. Ganz SD. Techniques for the use of CT imaging for the fabrication of surgical guides. *Atlas Oral Maxillofac Surg Clin North Am.* 2006;14(1):75-97.
11. Menchini Fabris GB, Gelpi F, Giammarinaro E, Velasco Ortega E, Marconcini S, Covani U. A novel CAD/CAM-based surgical template for mandibular osteoplasty and guided implant insertion. *J Biol Regul Homeost Agents.* 2017;31(2 Suppl. 2):99-106.
12. Lanis A, Tahmaseb A. Computer-assisted bone reduction and static computer-guided implant surgery in a fully edentulous patient: a technique report. *Int J Comput Dent.* 2021;24(2):165-179.
13. Pikos MA, Magyar CW, Llop DR. Guided full-arch immediate-function treatment modality for the edentulous and terminal dentition patient. *Compend Contin Educ Dent.* 2015;36(2):116-128.
14. Faeghi Nejad M, Proussaefs P, Lozada J. Combining guided alveolar ridge reduction and guided implant placement for all-on-4 surgery: A clinical report. *J Prosthet Dent.* 2016;115(6):662-667.
15. Beretta M, Poli PP, Tansella S, Maiorana C. Virtually guided alveolar ridge reduction combined with computer-aided implant placement for a bimaxillary implant-supported rehabilitation: A clinical report. *J Prosthet Dent.* 2018;120(2):168-172.
16. Nikzad S, Azari A. A novel stereolithographic surgical guide template for planning treatment involving a mandibular dental implant. *J Oral Maxillofac Surg.* 2008;66(7):1446-1454.
17. Burgoa S, Jony de Moura E Costa A, Ventura D, Pinhata-Baptista OH, Gonzalez Cortes AR. Digital workflow for definitive immediately loaded complete-arch CAD-

CAM implant-supported prosthesis in 3 appointments without using intraoral scanning. *J Prosthet Dent.* 2022;S0022-3913(22)00361-4.

doi:10.1016/j.prosdent.2022.05.032

18. Fueki K, Kimoto K, Ogawa T, Garrett NR. Effect of implant-supported or retained dentures on masticatory performance: a systematic review. *J Prosthet Dent.* 2007;98(6):470-477.
19. Thomason JM, Feine J, Exley C, Moynihan P, Müller F, Naert I, et al. Mandibular two implant-supported overdentures as the first choice standard of care for edentulous patients--the York Consensus Statement. *Br Dent J.* 2009;207(4):185-186.
20. Duhn C, Thalji G, Al-Tarwaneh S, Cooper LF. A digital approach to robust and esthetic implant overdenture construction. *J Esthet Restor Dent.* 2021;33(1):118-126.
21. Kivovics M, Takács A, Péntzes D, Németh O, Mijiritsky E. Accuracy of dental implant placement using augmented reality-based navigation, static computer assisted implant surgery, and the free-hand method: An in vitro study. *J Dent.* 2022;119:104070.
22. Koyuncuoglu CZ, Metin S, Saylan I, Calisir K, Tuncer O, Kantarci A. Full-mouth rehabilitation of a patient with ectodermal dysplasia with dental implants. *J Oral Implantol.* 2014;40(6):714-721.
23. Meneghetti P, Moura GF, Tavelli L, Li J, Siqueira R, Wang HL, et al. A fully digital approach for implant fixed complete dentures: A case report. *J Esthet Restor Dent.* 2021;33(8):1070-1076.
24. Jeong SH, Kim S, Seong YW, Chang JS. Implant-retained overdenture delivery in 2 visits with a digital workflow. *J Prosthet Dent.* 2022;S0022-3913(22)00013-0.
doi:10.1016/j.prosdent.2021.12.023

Figures and Tables Legends

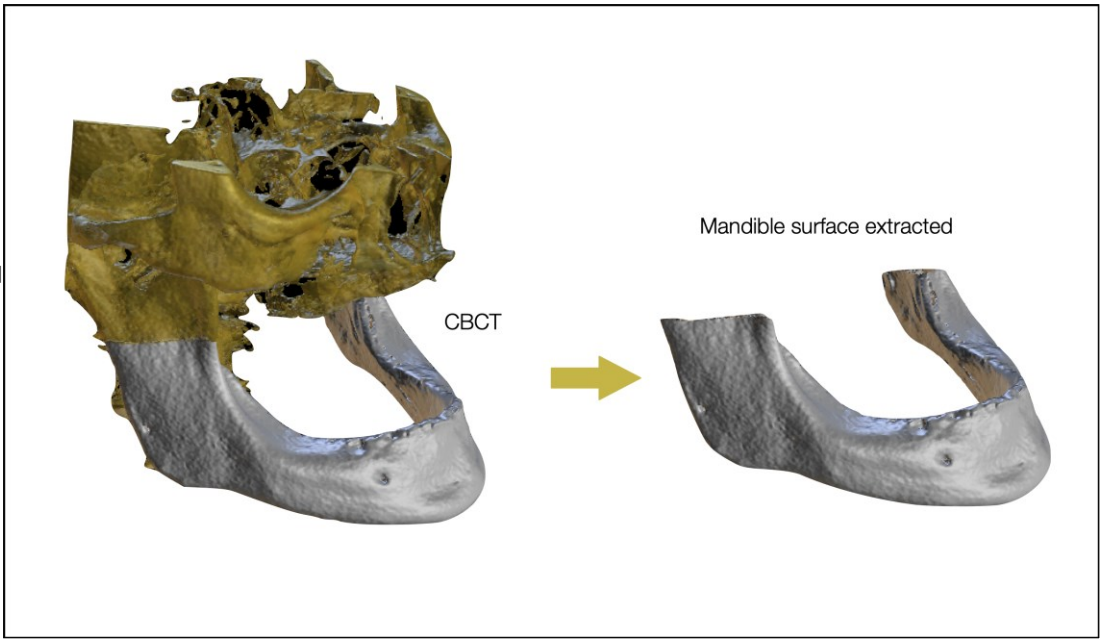


Figure 1. In BlueSkyBio (BSB) software, the mandible surface is extracted and exported as an STL file. (This step is not required when using the new version (2022) of Implant Studio software).

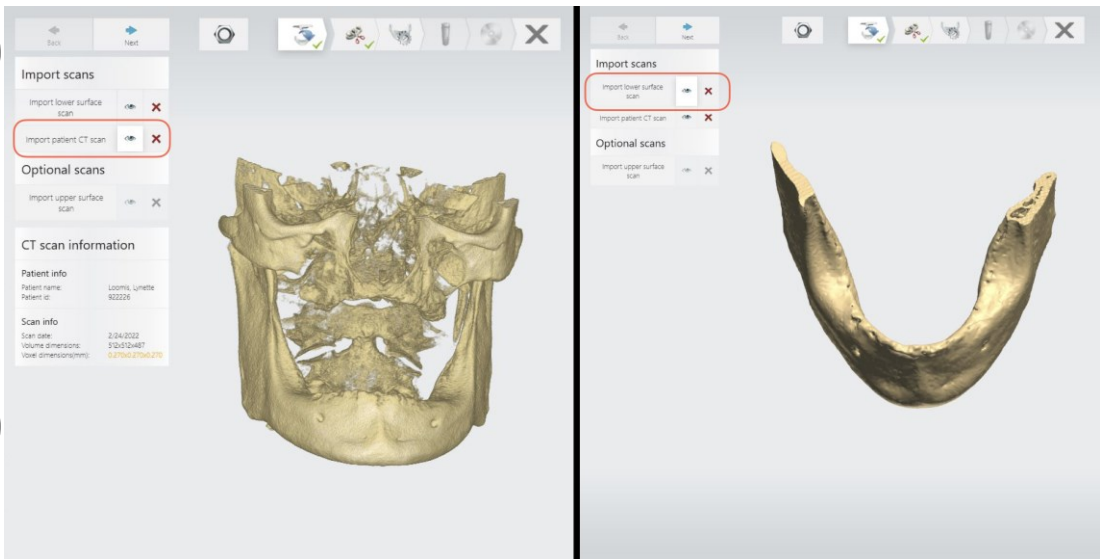


Figure 2. In 3Shape Implant Studio, import the CBCT and the scan surface (the STL file that was exported by BSB).

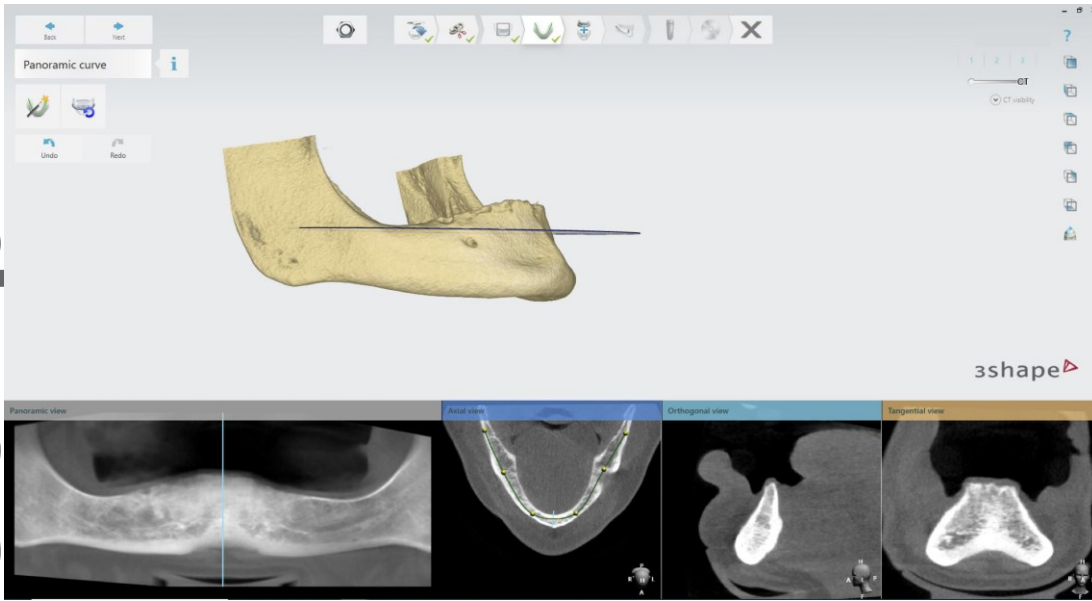


Figure 3. Set the occlusal plane and the panoramic curve.

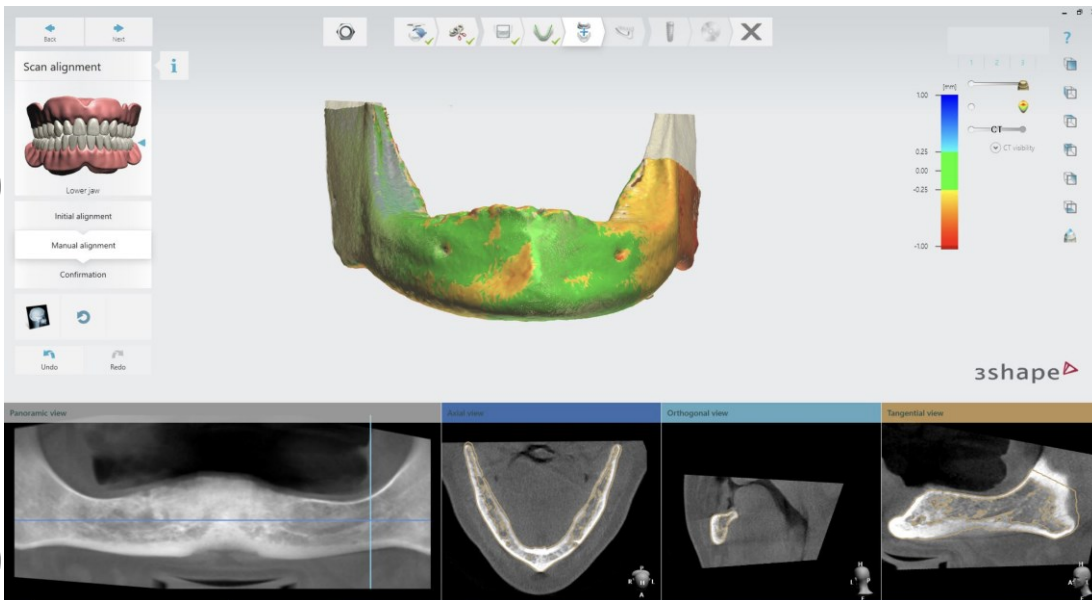


Figure 4. The scan Alignment (CBCT + STL) is performed and checked.

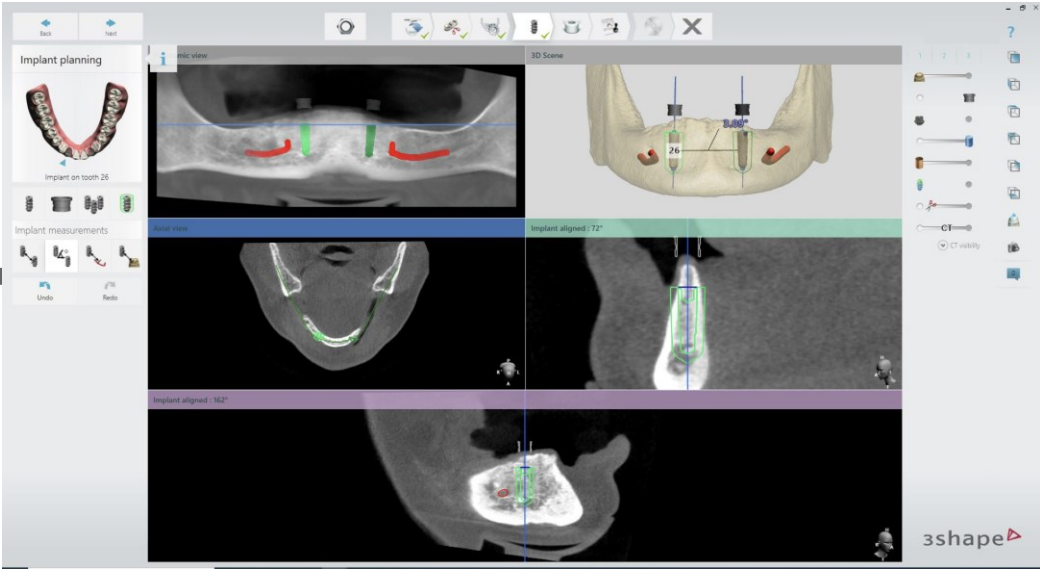


Figure 5. During the implant planning, select the implants and sleeves, check the implants parallelism, and also the amount of necessary bone reduction.

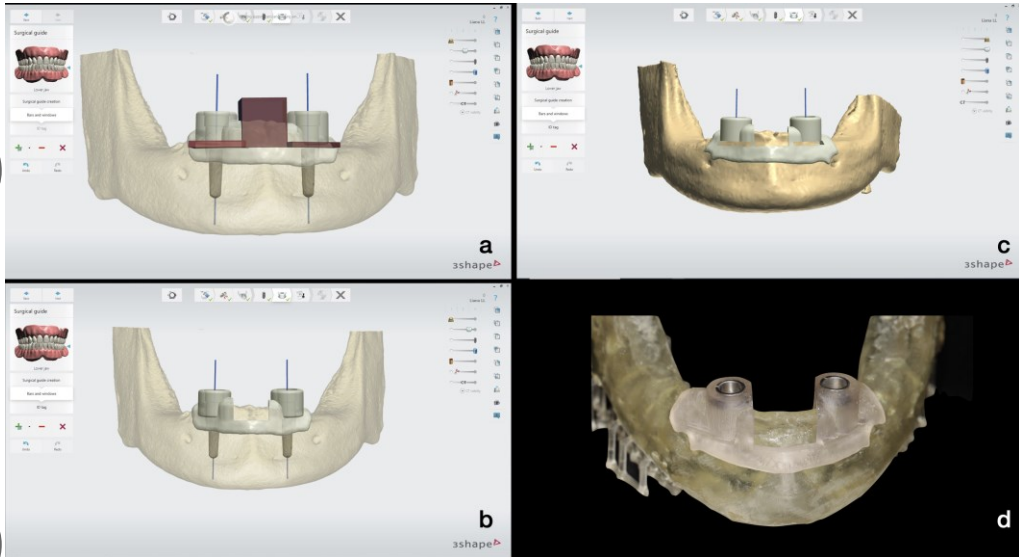


Figure 6. (a) Design the guide and create windows at the level of implants; (b) The use of transparency to check where the implant level is to perform bone reduction; (c) The final guide design; (d) 3D-printed and seated guide on the 3D-printed mandible to check the fit and stability.

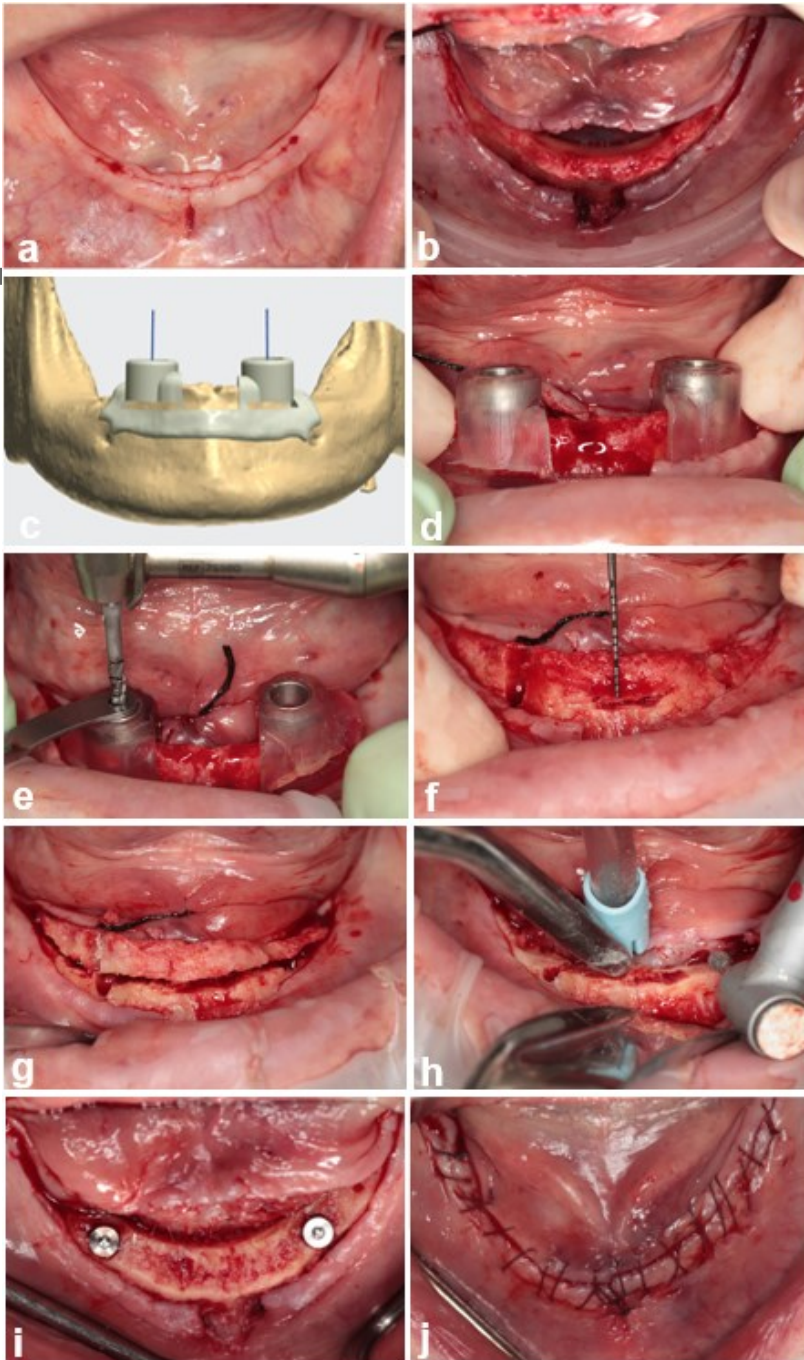


Figure 7. Case 1, A 53-year-old female presented. (a) Pre-operative clinical photograph indicates the deficient crestal width of the mandibular ridge. (b) A full-thickness flap was raised and secured by a 3-0 silk suture. (c) Digital guide designed in the 3Shape software; (d) Checking the seating of the guide on the bone; (e) Drilling protocol was performed; (f) 5 mm of the ridge height was marked by the means of the surgical guide window; and (g) the alveoplasty was performed. (h) Reshaping the ridge with high-speed diamond bur; (i) Installation of implants and cover screws (free-hand); (j) Flap closing using 4-0 poly-glycolic acid continuous sutures.

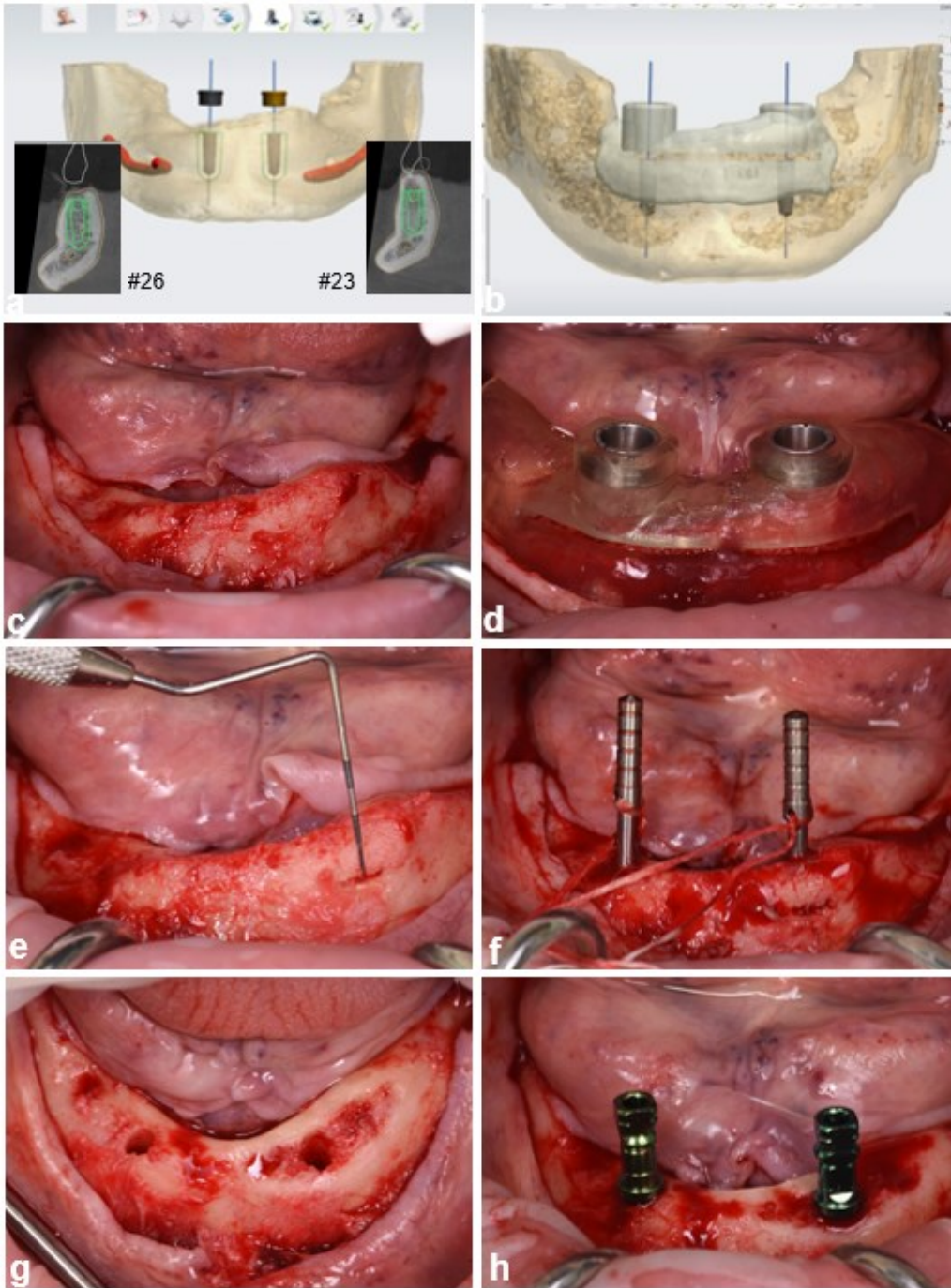


Figure 8. Case 2. (a) Digital implant planning in 3Shape software. (b) Surgical guide design with a horizontal window to perform the bone reduction. (c) Residual ridge after local anesthesia and raising of a full thickness flap. (d) Checking fitting of the guide. (e) The bone markup to perform approximately 5 mm bone reduction on the left side. (f) Bone after reduction with the drilling of implants. (g) Checking parallelism and depth of implants according to the plan. (h) Implants in position.

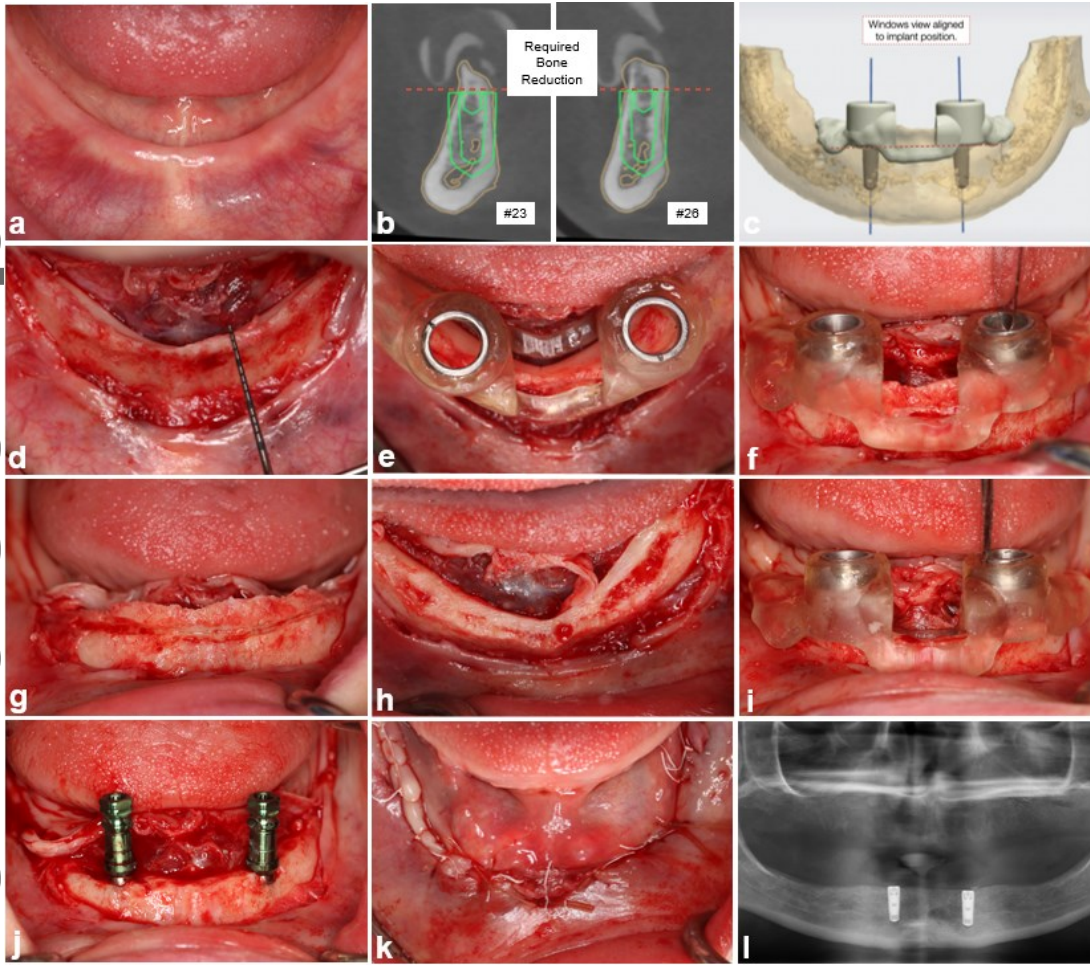


Figure 9. Case 3. A 77-year-old female, presented with the chief complaint of a loose lower denture. (a) Presence of an atrophic mandibular edentulous ridge; (b) Digital implant planning at #23 and #26 sites and amount of bone reduction required; (c) The surgical guide was designed and 3D-printed with one window being located at the mid-section of the guide; (d) The intraoperative measurements indicated maximum of 3 mm crestal ridge width; (e) Occlusal view of the surgical guide placed in the ridge; (f) Frontal view of the guide with the markup bone reduction (g) Extend the mark up with a bur; (h) Bone reduction performed (i) in this case, the drilling implant protocol was performed after bone reduction; (j) Implant placement was free-hand; (k) The flap was closed using 4-0 polytetrafluoroethylene sutures. (l) Final panoramic radiograph.

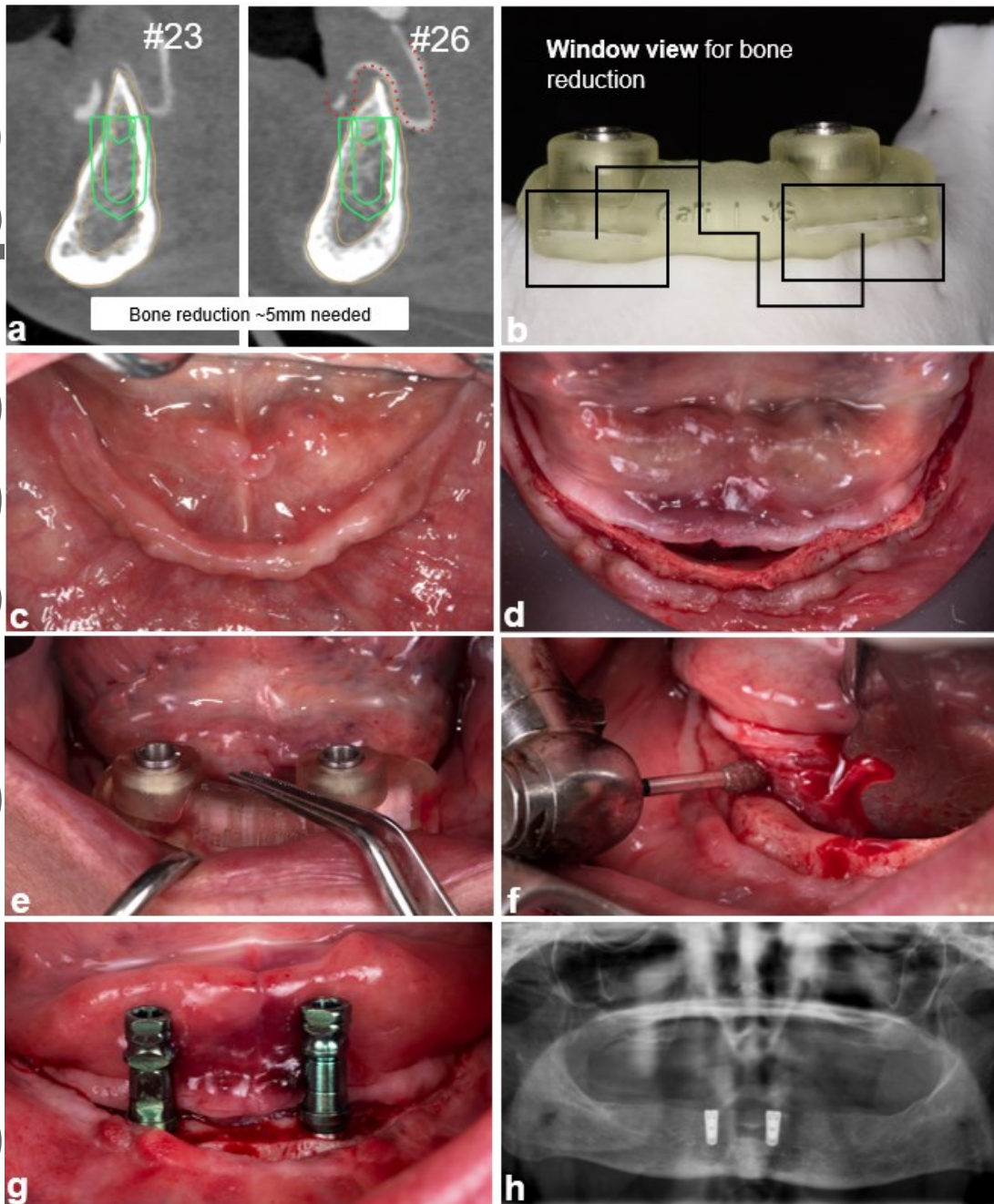


Figure 10. Case 4. A 77-year-old female patient. (a) The ridge height was planned to be reduced by around 4-5 mm by the use of surgical guide; (b) the 3D-printed surgical guide, with two horizontal window openings at the level of implant, seating on the 3D printed mandible model; (c) Pre-operative clinical photograph of the lower ridge; (d) Crestal flap raised exposing the thin bone; (e) The guide was placed to markup the bone reduction line; (f) Alveoloplasty protocol was performed; (g) Drilling protocol and implants placement; (h) Final panoramic X-ray. Note the achievement of parallelism concept.

Table 1. Characteristics of patients and the designed surgical guides (based on the location of window opening (for bone reduction) and respective pros and cons).

Patients

Case #	Age	Sex	Type of implant	Implant Location	Type of bone reduction guide (window)	Amount of bone reduction
1	53	F	Zimmer Tapered Screw-Vent MTX, 3.7 X 13	#23, #26	Implant Site Two-windows + Mid-Part Single Window	7 mm
2	74	M	Zimmer Tapered Screw-Vent MTX, 3.7 X 11.5	#23, #26	one continuous window connecting two implant sites	5 mm
3	77	F	Zimmer Tapered Screw-Vent MTX, 3.7 X 10.0	#23, #26	Mid-Part Single Window	5 mm
4	77	F	Zimmer Tapered Screw-Vent MTX, 3.7 X 10.0	#23, #26	Implant Site Two-windows	4-5 mm

Surgical Guides

Type of bone reduction guide (window)	Pros	Cons	Case #
Implant Site Two-windows + Mid-Part Single Window	More stability	More flap reflection for access	1
One continuous window connecting two implant sites	More stability	More flap reflection for access	2
Mid-Part Single Window	Less bulky and smaller size, less flap reflection, easier handling (placement), better view of the sitting	Fragile, less stability	3
Implant Site Two-windows	More stability	More flap reflection for access	4