

# Reiter's Disease: A Review With Special Attention to Cardiovascular and Neurologic Sequellae

Armin E. Good

*Eine lange Krankheitsdauer, eine langsame Erholung, die oft durch Rezidive unterbrochen wird und sich auf Jahre hinstrecken kann, geben der Krankheit etwas Unheimliches. . . diese Erkrankung (ist) noch heute in ein gewisses Dunkel gehüllt.\*<sup>1</sup>*

**T**HOUGH not the first description of the tetrad of urethritis, arthritis, conjunctivitis, and mucocutaneous lesions, Hans Reiter's report in 1916 was meticulous and detailed, reintroducing the syndrome into the medical literature.<sup>1a</sup> By common usage, Reiter's disease (RD) is the standard label.<sup>2</sup> When discussing late manifestations far afield from the presenting syndrome, it is conceptually useful to set up a distinct, admittedly tentative, disease entity. Diagnosis is based, however, on an acute syndrome including at least three members of the tetrad.

Several reviews have appeared.<sup>3,4</sup> The most useful basic reference is Csonka's study<sup>5</sup> containing a comprehensive analysis of the literature up to 1965 as well as contributions from the author's large experience with the disease. Early publications emphasized the excellent prognosis, reporting that the disease nearly always cleared completely following an attack.<sup>6</sup> With follow-up, it became apparent that the majority of patients suffered recurrences and had permanent articular complaints.<sup>7</sup> As attention has been directed to sequelae, reports of cardiac and neurologic manifestations have arrived on the scene. A recent leading article in the *British Medical Journal* concludes with the statement, "While deaths are rare and mostly due to cardiac or neurological lesions or to reactions to treatment, the prognosis for full functional restitution is only fair though still better than rheumatoid arthritis or classical ankylosing spondylitis."<sup>8</sup> This review will concentrate on these cardiac and neurologic lesions, prefaced by a historical overview of the disease.

## HISTORICAL REVIEW

RD has coalesced from three historical sources: as a complication of either urethritis or dysentery and from the disease termed *keratoderma blennorrhagica*. In each of these, arthritis and ophthalmitis were noted and a mix of mucocutaneous and urethral lesions and enteritis added in varying proportions.

---

\*A long duration of illness, and a slow recovery that may be drawn out for years and often interrupted by recurrences, give something uncanny to the disease . . . even today, this illness is shrouded in a certain darkness.

*From Veterans Administration Hospital and University of Michigan Medical Center, Ann Arbor, Mich.*

Armin E. Good, M.D.: *Associate Professor of Medicine, University of Michigan.*

© 1974 by Grune & Stratton, Inc.

There is now no fundamental reason for separating the dysenteric, venereal, and dermatologic syndromes.

#### *Venereal Reiter's Disease*

Hippocrates wrote that young men did not get gout until after sexual intercourse.<sup>9</sup> In the 18th Century, William Musgrave recognized arthritis after non-venereal urethritis,<sup>10</sup> and in the 19th Century, arthritis was thought to be a complication of urethral suppuration from any cause.<sup>11</sup>

Brodie<sup>12</sup> described the triad following nongonococcal urethritis and recognized the high risk of recurrence of stereotyped attacks lasting up to 1 yr, complicated sometimes by iritis. When his patients seemed to recover completely, he concluded that he had discovered effective therapy: colchicine, and copious bloodletting.

These sporadic or endemic cases seem to be precipitated by venereal infection, circumstantial evidence being especially strong when the disease shortly follows first sexual intercourse. Attacks average 3 mo in duration, though not uncommonly prolonged and associated with debility and inanition. As cure supervenes, the patient is often resurrected from a terrible prognosis. These are the patients who were told that they would never walk again, and go about now telling rheumatoid arthritis sufferers to use will power and get well.

#### *Postdysentery Reiter's Disease*

In the 18th Century, Stoll mentioned the full triad of urethritis, arthritis, and conjunctivitis after dysentery.<sup>13</sup> Postdysenteric arthritis and even conjunctivitis were well known by the close of the 19th Century. After shigellosis was defined, several remarkable clusters of Reiter's disease were reported during epidemics of *Shigella* dysentery<sup>3,14-17</sup> (Fig. 1). Although patients usually recovered completely, a few were noted to have prolonged attacks progressing to permanent deformity, especially in the feet. The list of affected joints could be neatly superimposed upon that for the venereal Reiter's syndrome, emphasizing the legs over the arms, concentrating at the knee and small joints of the feet, plus signs of acute lumbar or pelvic involvement.<sup>14</sup> The pathogenesis of the arthritis has been puzzling, since it occurs too late to be a manifestation of *Shigella* toxin, and organisms are virtually never isolated from the joints.<sup>15</sup>

#### *Keratoderma Blennorrhagica*

Meanwhile, another source of patients with arthritis falling within the spectrum described above, keratoderma blennorrhagica, also found its way into the pool of RD. This syndrome of urethritis, arthritis, and often conjunctivitis with peculiar and characteristic skin lesions was described in 1893.<sup>18</sup> The lesions, though they may first appear as straw-colored vesicles, are hard and horny from the beginning, unlike the vesicular lesions of any other disease (Fig. 2). At times the lesions may resemble rupioid psoriasis but relief map-like confluent keratotic lesions are distinct (Fig. 3). The pathology at some stage at least is that of pustular psoriasis with acanthosis, elongated rete pegs, microabscesses, and hyperkeratosis.<sup>19</sup> Patients with severe lesions and generalized erythroderm become debilitated, and deaths have been reported.<sup>20</sup> After attacks subside, chronic psoriasis vulgaris may evolve.<sup>21</sup>

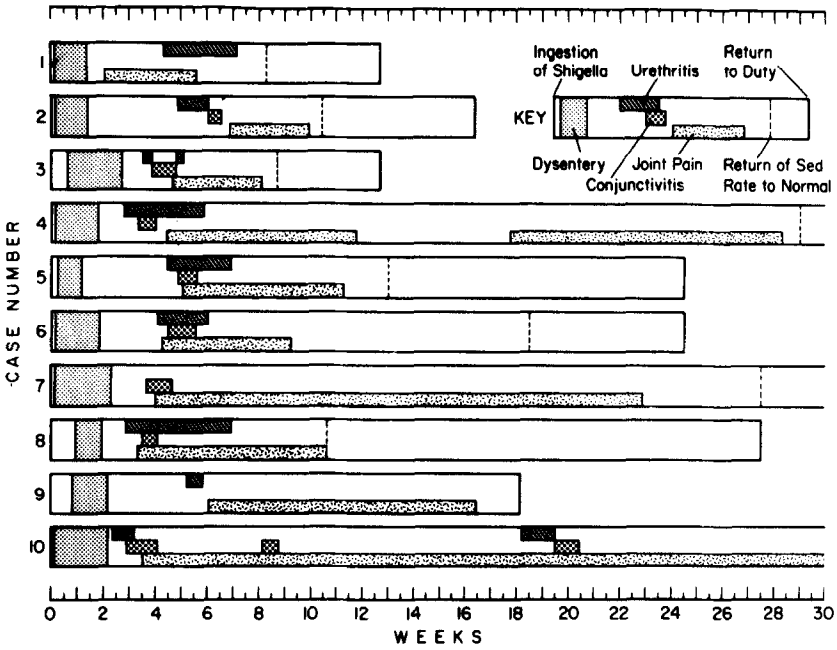


Fig. 1. Reiter's disease shipboard epidemic following *Shigella* infection. (With permission.<sup>17</sup>) Clinical manifestations of 10 patients.

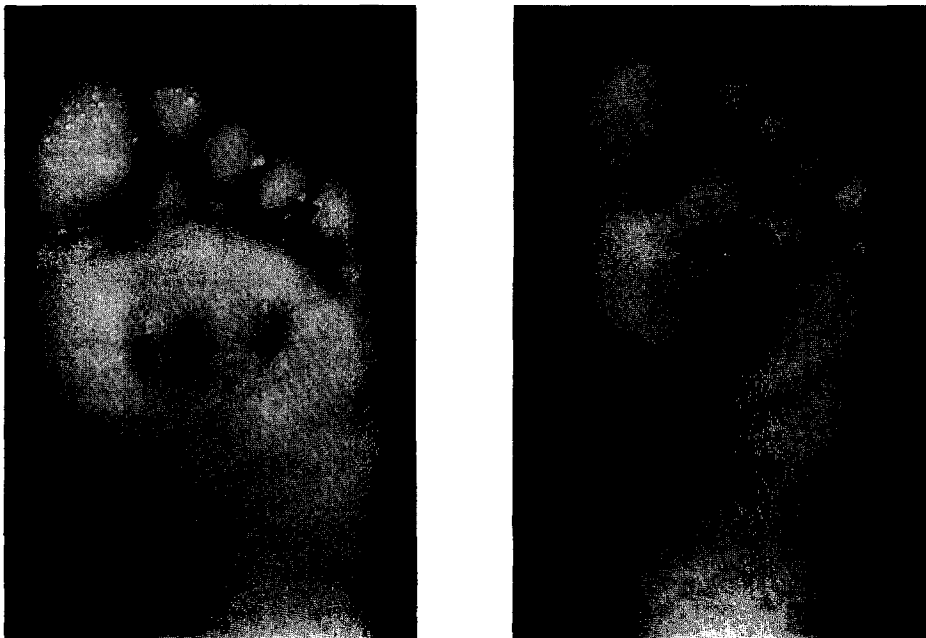
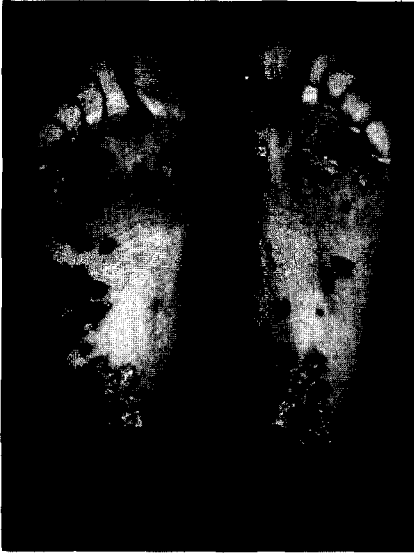
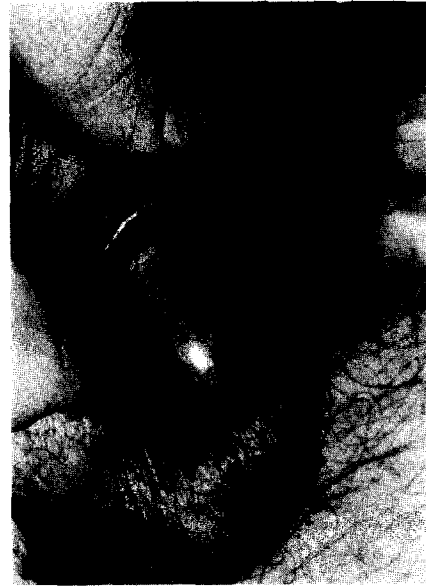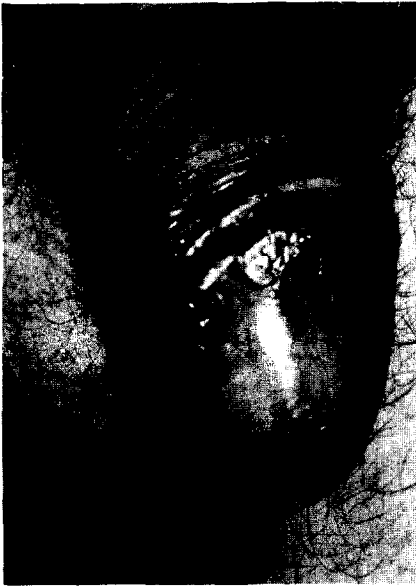Fig. 2. (A) Dark plantar nodules and smaller hyperkeratotic toe lesions. (B) Healing after desquamation of thickened epidermis (4 wk later).



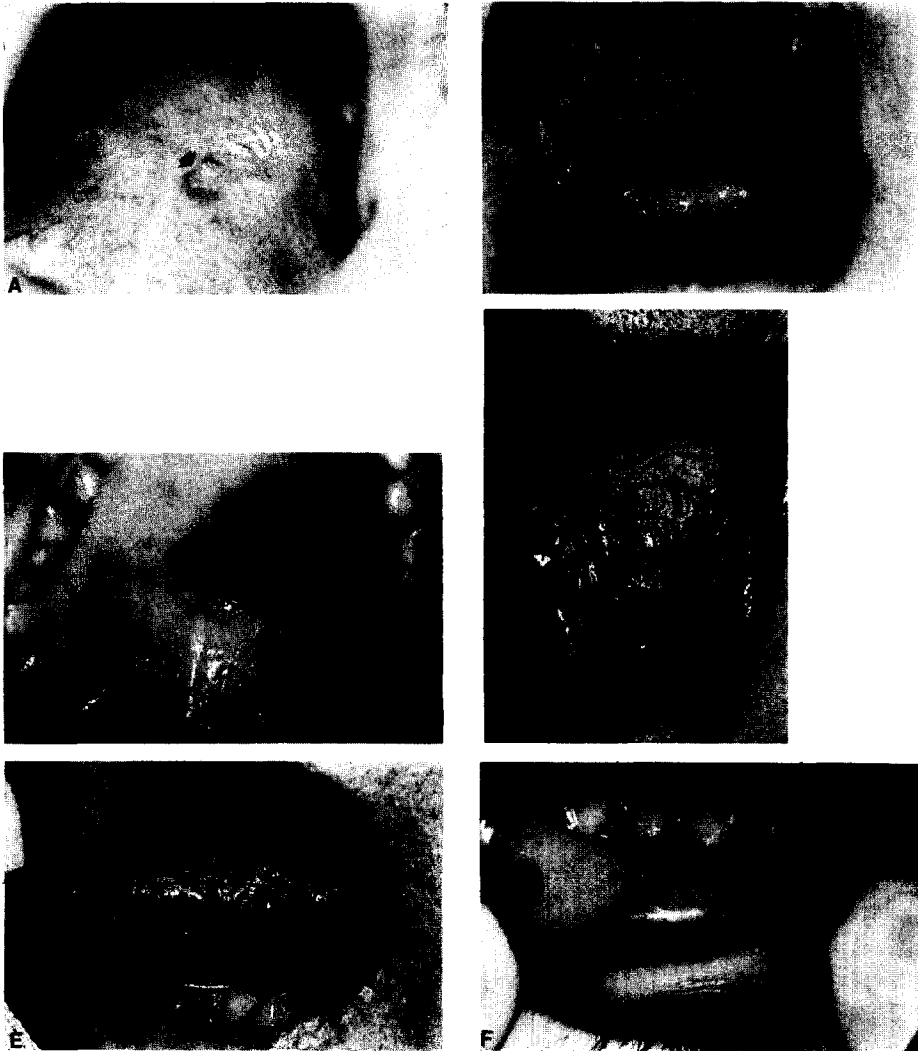**Fig. 3.** Typical plantar keratoderma blennorrhagica, showing geographic relief-map effect by coalescing, keratotic, desquamating lesions.

Balanitis was associated with keratoderma blennorrhagica in 1897<sup>22</sup> and later recognized as well with dysenteric and venereal Reiter's syndromes in as many as 80% of patients, compared to skin involvement in about 20%.<sup>23</sup> This penile lesion tends to be the earliest mucocutaneous manifestation, sometimes presaging the attack, as well as the most persistent<sup>5</sup> (Fig. 4).



**Fig. 4.** Balanitis. (A) Painless, superficial hyperemic ulcers with raised keratotic margins, showing early circinate coalescence near corona. (B) Multiple small dusky red velvety lesions scattered over glans.

Mouth lesions were described as early as 1900 as part of keratoderma blennorrhagica<sup>24</sup> and have subsequently been found increasingly in venereal and postdysentery RD with a top reported incidence of 40%.<sup>23</sup> Detection requires careful repeated search during the early weeks of the acute attacks. The lesions occur on the palate, tongue, buccal mucous membrane, lips, gums, tonsillar pillars, nasal septum, and pharynx (Fig. 5) and, with rare exceptions, are painless. Slight burning, loss of taste, and mild sore throat are sometimes noted by the patient.



**Fig. 5.** Oral lesions. (A) Palatal mucosa: early lesion appears as small opaque vesicle with granular surface, (see arrow). (B) Lesion has enlarged with bright red, hyperemic, purpuric appearance (2 wk later). (C) After further extension, attenuated late lesion showing a fading, coppery color (5 wk later). (D) Dorsum of tongue: brick-red color, extensive denudation of papillae, and superficial ulcers. (E) Same patient: lateral tongue: coalescing superficial ulcers showing raised circinate margins. (F) Lower lip: painless superficial hyperemic lesions of mucosa and lip.

Biopsy of these mouth, penile, and cutaneous lesions from whatever site, allowing for regional differences in keratin, yields a similar histopathology as described above, the most specific laboratory finding of RD.<sup>25</sup>

### *Eye Involvement*

Conjunctivitis is often the most transient part of the acute attack, usually occurring early. When conjunctivitis is severe, slit lamp examination may show signs of iritis, an increasing problem during late recurrences, often after other manifestations of RD are quiescent.

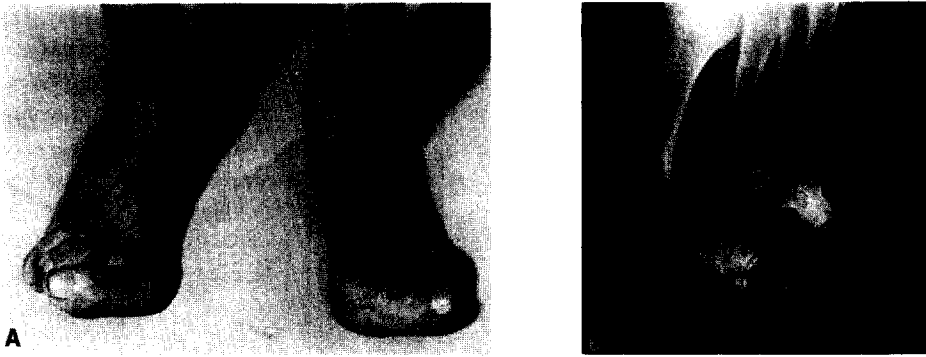### *Gonorrhea and Reiter's Disease*

Gonorrhea has had a central position in the history of RD. Probably one reason for the popularization of RD in the medical literature after 1942 was the introduction of antimicrobials, finally leading to a convincing separation of the two diseases. Until fairly recently, keratoderma blennorrhagica, chronic peripheral arthritis, and ankylosing spondylitis have been listed (wrongly) as lesions of chronic gonococcal infection. Though the urethritis of RD is characteristically abacterial, at times it is a mixed infection presenting as gonorrhea and followed by prolonged mucoid abacterial discharge after gonococci are eradicated. In some patients, RD has followed gonorrhea, responding promptly to penicillin, leaving no detectable nongonococcal urethritis behind.<sup>5</sup>

Of course, gonococci may mimic the entire Reiter's tetrad of urethritis, polyarthritis, conjunctivitis, and skin lesions. This calls for continued vigilance, even when dealing with a patient with a history of multiple attacks of RD, for if indeed an infective urethritis may activate RD, the patient is also a prime suspect for gonorrhea. In a recent case of RD beginning with urethritis, culture of discharge from an eye with failing vision led to a diagnosis of gonococcal ophthalmitis, blindness being narrowly averted by prompt treatment.<sup>26</sup> So far, physicians dealing with specific gonococcal arthritis continue to report prompt response to antibiotic treatment.<sup>27</sup> The possibility remains that resistant urethral neisserian strains, which respond only to exceptionally high doses of penicillin, will also produce an infective arthritis, erroneously diagnosed as RD because of failure to respond to routine antibiotic therapy.

### *Intermediate and Late Course*

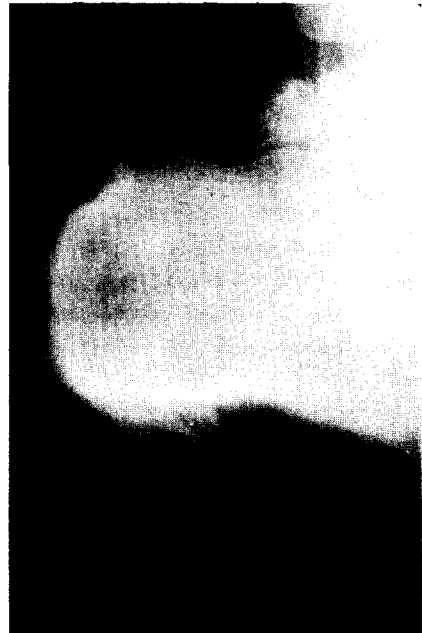
As the acute syndrome of RD was assembled from the dysenteric and venereal syndromes and keratoderma blennorrhagica and became separable from sometime coexisting gonococcal infection, the middle and late course of the disease has come under study. Recurrences were frequent, appearing in over one-half of the patients in Csonka's large series, with remissions varying from 3 mo to 36 yr.<sup>28</sup> He estimated the rate of recurrence to be 15% per year. Twenty of his 144 cases under long-term observation failed to show clear cut remissions, although disease activity fluctuated. Some chronic disability can be ascribed to residual destructive, deforming lesions (especially in the toes and metatarsophalangeal joints) incurred during previous prolonged acute attacks (Fig. 6); other signs such as synovial swelling, elevated erythrocyte sedimentation rates and progressive roentgenographic alterations indicate that ongoing



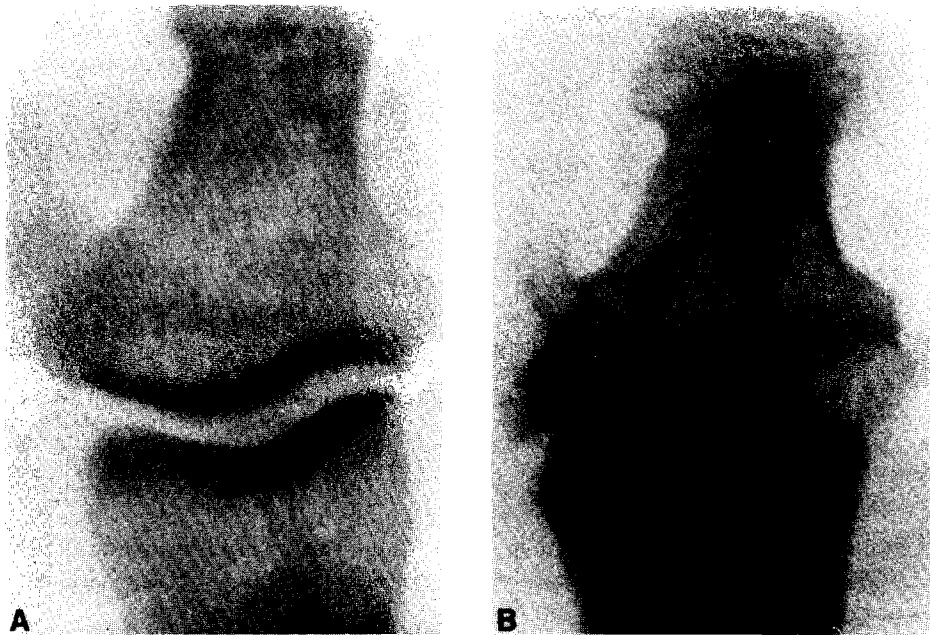**Fig. 6.** Late deformity of feet: patient aged 40 after three attacks of Reiter's disease beginning at age 13. (A) Extreme lateral subluxation of toes. (B) Radiograph, left forefoot: subluxation at metatarsophalangeal joints, bones well mineralized, rheumatoid juxtaarticular erosions are absent.

rheumatic activity is often present in these joints and in tenosynovium.<sup>4</sup> Pain corresponding to periostitis is also observed, often resulting in bony enlargement at the malleoli and calcaneus<sup>29</sup> (Fig. 7).

During this stage, patients are sometimes sent to the hospital with a mistaken diagnosis of gout because of chronic inflammation of the interphalangeal joint of the great toe (Fig. 8). After severe repeated attacks, the Launois deformity of the feet may develop, characterized as dorsal dislocation and lateral deviation of the toes usually associated with pes cavus and said to be the "most striking, extreme and specific deformity seen in Reiter's syndrome."<sup>5</sup>



**Fig. 7.** Heel involvement: lateral radiograph of calcaneus, showing fluffy periosteal calcinosis at inferior surface ("heel spur").



**Fig. 8. Late involvement of great toe: (A) Radiograph 2 yr. (B) Five years after acute Reiter's disease showing bony ankylosis at interphalangeal joint appearing concomitantly with chronic swelling and pain.**

In patients with persistent peripheral arthritis, rheumatoid arthritis has presented a problem in differential diagnosis. At the close of World War II, a popular diagnosis in North America was postgonococcal rheumatoid arthritis, a category probably filled mainly by RD. Time has demonstrated that the laboratory and histopathologic features of rheumatoid disease, such as the rheumatoid factor, antinuclear antibodies, and the necrobiotic rheumatoid granuloma are not associated with RD. Synovial biopsy from chronically involved joints is not usually helpful, however, in distinguishing the two diseases.<sup>25</sup> A valuable aid is determination of the synovial fluid hemolytic complement, which is normal to low in rheumatoid disease and elevated in RD, where the levels appear to be directly related to the severity and duration of joint inflammation.<sup>30</sup> Rarely, patients have had signs of both rheumatoid arthritis and RD.<sup>5,31,32</sup>

#### *Reiter's Disease and Ankylosing Spondylopathy*

First with postdysenteric RD<sup>33</sup> and soon with nondysenteric RD as well,<sup>34</sup> radiographic changes of sacroilitis were identified. Initially, this appeared to be incidental and often asymptomatic without other evidence for spondylitis; but with time, a spectrum of spinal arthritis evolved, usually mild, nondeforming, asymmetrical, and prone to skip areas, and sometimes progressing to the bamboo spine and kyphosis of advanced ankylosing spondylitis.<sup>7</sup> The latter is illustrated in the first American report of ankylosing spondylitis, which described two patients with recurrent attacks of "gonorrhoea" invariably followed by remittent peripheral arthritis, and finally by spinal rigidity with kyphosis.<sup>35</sup>



The incidence of sacroiliac changes and spinal involvement has varied greatly but seems to increase with duration of follow-up<sup>7</sup> (Fig. 9), severity of acute attacks, history of dysentery, and severe cutaneous lesions.<sup>36</sup> In 1969, a sampling of 100 patients from the 1944 Finnish epidemic of RD disclosed 32 with sacroiliitis, including 15 with spinal radiographic changes, and 14 with definite limitation of spinal motion. Seven had bamboo spine, but only three had a marked degree of thoracic kyphosis. Two patients from a control series of 100 hospital patients had radiographic changes similar to ankylosing spondylitis.<sup>37</sup> These findings are probably skewed in the direction of severity, since 169 patients who received questionnaires failed to come in, but, nevertheless, illustrate the overlap with ankylosing spondylitis.

In a comparative clinical and radiologic study of spondylitis accompanying various diseases,<sup>38</sup> McEwen et al., found that ankylosing spondylitis and spondylitis associated with ulcerative colitis and regional enteritis resembled each other closely and could be grouped together in a single category. A second category was constituted by spondylitis associated with RD and psoriasis. The differences between these categories are listed in Table 1. Marginal syndesmophytes, one of the hallmarks of ankylosing spondylitis, are vertical calcific bridges extending from the inferior margin of one vertebral body to the superior margin of the adjacent body (Fig. 10). These also predominated in Reiter's-psoriasis spondylitis. In the latter, however, in contrast to Category I, other than marginal types were common, occurring 50%–60% of patients after 6 yr. These are bridges, often tear-drop or comma shape, that seem to arise well beyond the margins, or even paravertebral ossifications separated by a distinct space from the vertebral body (Figs. 11 and 12). The pathogenetic significance of these lesions is indeterminate, but their presence in a patient without psoriasis should raise the question of Reiter's disease.

Finally, patients in the late inactive stage may present with a combination of

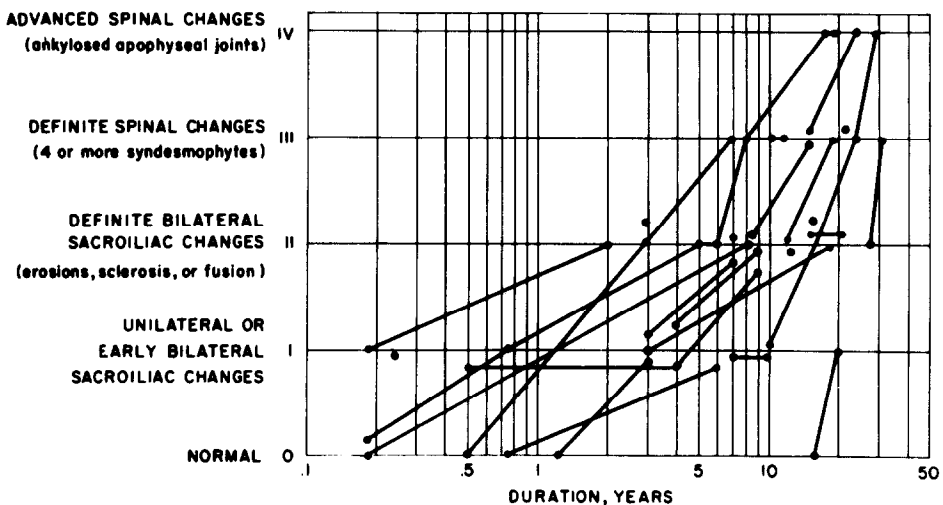


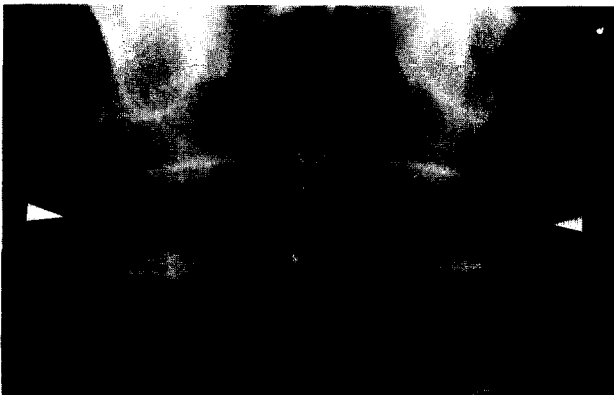Fig. 9. Progression of spinal radiographic changes in 25 Reiter's disease patients with abnormal sacroiliac films: each isolated dot or connected series of dots represents the findings from a single case. (With permission.<sup>127</sup>)

**Table 1. Differences Between Spondylitis of Categories 1 and 2\***


Category 1: Ankylosing Spondylitis and Spondylitis Associated with Ulcerative Colitis and Regional Enteritis	Category 2: Spondylitis Associated With Psoriasis and Reiter's Disease
Sacroiliac damage bilaterally symmetrical and severe even in early cases.	Sacroiliac damage sometimes unilateral or bilaterally asymmetrical in early cases
Lumbar straightening and dorsal kyphosis more frequent	Less
Greater frequency and severity of apophyseal joint involvement	Less
Squaring more frequent	Less
Greater frequency of syndesmophytes	Less
Bilaterally symmetrical arrangement of syndesmophytes more frequent	Less
Syndesmophytes almost exclusively of marginal type	Marginal syndesmophytes common
Other-than-marginal syndesmophytes, extremely rare	Other-than-marginal syndesmophytes common
Ligamentous ossification greater	Less
Syndesmophytic involvement extends progressively from lumbar region to dorsal and finally to cervical spine	Syndesmophytic involvement tends to progress in random fashion

\*With permission.<sup>38</sup>

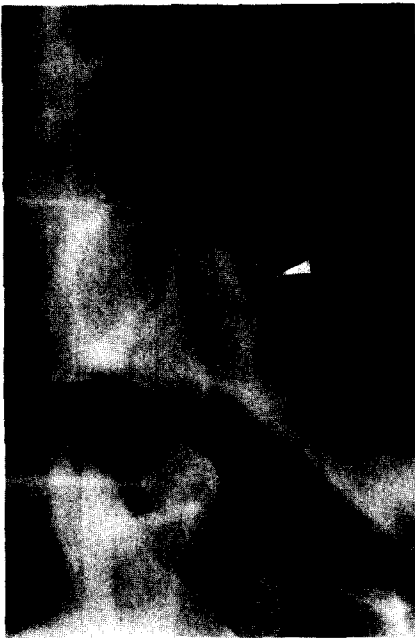peripheral deformities and back involvement. "Patients with stiff spines, stiff ankles and permanent changes in feet who otherwise have typical ankylosing spondylitis are, in my opinion, in many if not most instances, cases of missed Reiter's disease."<sup>39</sup> At this stage, the other portions of the tetrad are usually absent and long forgotten, if they ever did come to the patient's attention. Radiographic studies in such patients may point to a presumptive diagnosis of RD.<sup>40</sup> The characteristic pattern is sacroiliitis with concurrent, usually asymmetric involvement of the heels and various small joints of the lower extremities, particularly the interphalangeal joints of the great toes, but also the ankles and tarsals. Minor hand changes can occur as well at this stage, almost always though in conjunction with major involvement in the feet.



**Fig. 10.** Radiograph of D12-L1 interspace, showing marginal syndesmophytes (see arrows). From patient with ankylosing spondylitis.



**Fig. 11. Radiograph, L2-4, showing non-marginal body bridges (see arrows) that vault over the vertebral margins on the right. From patient with Reiter's disease.**



**Fig. 12. Radiograph, D10-12, showing tear-drop paravertebral ossification (see arrow) appearing during Reiter's disease.**

### *The Search for the Etiopathogenesis*

Our knowledge of the etiology of RD has advanced little since the original case report. By circumstantial evidence, RD appears to be precipitated by one or more infectious agents. As only a very small fraction of individuals at risk develop RD, there is speculation about genetic predisposition or environmental factors such as a second organism liberated by the inciting enteritis or urethritis.

*Genetic Factor.* The rarity of females with RD may be evidence of a genetic basis for the disease or simply reflect the small extent of the female urethra and the different venous drainage of the lower male genital tract by Batson's plexus. In the 1944 Finnish epidemic of postdysentery RD that predominately involved members of the armed forces, 10% of cases occurred in females (the proportion of females risk was not given).<sup>3</sup> In outbreaks of postdysentery RD occurring in five family units, 11 males and two females were involved.<sup>32</sup> Among cases in children, mostly associated with dysentery, a review of the literature indicates 17 boys and 4 girls.<sup>41,42</sup>

A family study has demonstrated increased psoriasis and ankylosing spondylitis among first degree relatives of RD patients.<sup>43</sup> A family with three males with RD over two generations and one with pure ankylosing spondylitis supports the genetic hypothesis.<sup>41</sup> However, other familial cases have included spouses and other unrelated participants, so that a common environmental factor also seems likely.

The use of histocompatibility typing in epidemiologic taxonomy to differentiate diseases that appear to be clinically homogeneous might contribute to the definition of the Reiter's-psoriasis interrelationship. Psoriasis is significantly associated with certain HL-A antigens, the first inherited disorder for which such a relation has been established. The prevalence of W-17 and HL-A13 specificities have been markedly increased in a population of psoriatics, W-17 defining a subgroup with higher incidence of affected relatives and earlier age of onset.<sup>44</sup>

*Microorganisms and RD.* Despite intensive efforts to implicate mycoplasmas, the available data do not support a role for this organism in RD and are controversial even for a role limited to nongonococcal urethritis.<sup>45</sup> The possibility that a fastidious mycoplasma not isolated by means of current techniques may trigger an immunopathologic mechanism at a distant site is difficult to exclude at this time.

Initial excitement about chlamydia infection as a cause of RD has subsided. The original proponents of this organism have tested 84 males with RD and found only 24 from whom the agent was recovered or who had significant complement fixation titers. They did find a married couple in which the wife had chlamydia inclusion conjunctivitis and the husband had RD with urethral and conjunctival scrapings positive for chlamydia. The authors continue to suspect that some cases of RD represent an unusual host response to the agent.<sup>46</sup>

Of all the infective agents "causing" RD, the one that has the most stature is still the original *Shigella*, worthy of a more concerted investigative attack than accorded to date. Because of imperfect isolation techniques from stool specimens and failure to employ rectal swabs, it is probable that many cases of shigellosis are missed. While a true carrier state is rare, infection may be inapparent or subclinical; these cases probably outnumber clinical cases by a considerable number.<sup>47</sup> Sexual intercourse, especially involving oral-genital and genital-anal contact could, on occasion, elevate shigellosis to the status of a venereal disease.

Mason-Bahr<sup>48</sup> has noted wide variability in the incidence of arthritis associated with epidemics of shigellosis, ranging from a low figure of 0% in the Fiji

Islands in 1910 to a high of 10% in the same place in 1897. He found that arthritis was usually associated with *S. dysenteriae*, sometimes with *S. flexneri*, and never with *S. sonnei*.

There are insufficient data about species and strain subtyping of organisms precipitating RD. Noers has reported a superbly executed study of an epidemic of Reiter's aboard a naval vessel in which time of exposure to a *Shigella*-infected meal was known.<sup>17</sup> Even in this microcosm, the *Shigella* species and strain subtypes were not elucidated, doubtless because of limitations of the laboratory at sea.

Shigellosis cannot be ruled out when there is no history of epidemic diarrhea. In developing countries smoldering prolonged outbreaks occur. A family outbreak of Reiter's disease followed *Shigella* diarrhea during a Mexican tour.<sup>49</sup>

Curiously, clusters of RD have not occurred with non-*Shigella* enteric disease epidemics such as cholera. In isolated cases, though, amebic dysentery,<sup>50</sup> salmonella, and Yersinia<sup>51</sup> bowel infections have been associated with RD as has a family outbreak of non-*Shigella* "turista" diarrhea.<sup>52</sup> Polyarthritides, though not other parts of the tetrad, occurred during diarrhea following a jejunoileostomy done in a patient for therapy of obesity.<sup>53</sup> Other infections sometimes appear to precipitate Reiter's disease. Several of our patients had onset associated with influenza in the 1918-19 pandemic. Respiratory tract infection<sup>5</sup> and even streptococcal pharyngitis<sup>54</sup> have been followed by RD.

*Immunopathologic Hypothesis.* An immunopathogenetic mechanism is tacitly assumed to explain the delay in the onset of RD following an inciting infection as well as the chronicity of inflammation. Serum immunoglobulin abnormalities are not a feature, but involved tissues have not yet been studied for immunoglobulin IgG deposits. Rheumatic fever is in many respects an enticing model for RD, though there appears to be a fundamental difference between the two in the inflammatory process, because aspirin and corticosteroids are remarkably ineffective for RD.<sup>55</sup>

### Therapy

The therapeutic problem of RD has not been solved. Supportive care such as nonspecific antiinflammatory drugs, analgesics and physical therapy is usually required. Most clinicians doubt whether drugs have any effect upon the course of the acute attack. One exception may be the use of methotrexate in the small group of patients with persistent, generalized, disabling dermatitis. On the basis of limited experience, it appears that both the skin and joint disease remit promptly with methotrexate, but long-term hepatotoxicity of the drug may interdict its general application.

A common sense approach intercritically is to ask the patient to avoid reinfection of the urethra, perhaps by using a condom. Tetracycline during and after attacks has not been shown to modify the course of the disease<sup>56</sup> but deserves additional evaluation by means of a long-term cooperative study.

## CARDIAC INVOLVEMENT

### *The Heart Disease of Ankylosing Spondylitis*

Nowhere are RD and ankylosing spondylitis intertwined as in the literature of so-called spondylitic heart disease, perhaps better termed Mallory's aortitis.

Discussing two cases in 1936,<sup>57,58</sup> Mallory described a disease of the aorta that mimicked syphilitic aortitis and was characterized by a similar patchy destruction of the elastic and muscle fibers of the media. The first patient had a course suggestive for RD, with an initial 35-lb weight loss and acute onset of arthritis in the feet; arthritis was in remission when aortic insufficiency was discovered 4 yr later. The second patient probably had RD, beginning at age 19, with painful swelling in his feet. Two attacks of "gonorrheal urethritis" occurred at 23 and 24; during these years he had attacks of pain and swelling in the wrists, feet, and in one heel. At age 24½ he had pain and stiffness in the low back, "proliferative changes" were noted in the X-rays of the right wrist, and the X-rays of the spine were negative. Later, he had a generalized flare including pain in the left sacroiliac joint, low back, and both wrists. At 26 he had sudden onset of aortic insufficiency and later died of a pulmonary embolus.

In 1957, Clark, Kulka, and Bauer<sup>59</sup> included these two patients in a series of 22 with aortic insufficiency. All but two had spondylitis (presumably the two described above by Mallory in 1936), and all but two had peripheral arthritis. Apparently, the peripheral arthritis was marked by remissions and exacerbations, and in 59% the aortic insufficiency became manifest during flares of joint disease; 59% had iritis and 18% had psoriasis. From nine patients with autopsies confirming aortitis, two detailed case histories were included. The arthritis in these was characteristic of RD, with attacks of joint swelling in the knees and feet at ages 18–23. One had joint flares associated with iritis. Back pain appeared 6–10 yr after onset and both developed ankylosing spondylitis.

Clark, Kulka, and Bauer described the following clinical setting of the heart disease: (1) murmur of aortic insufficiency was detected 11 years after onset of joint disease (range 1–29); (2) congestive heart failure appeared in ten, seven dying within 4 yr; (3) EKG's showed about one-third with first degree A–V block and one-third with left bundle branch block; (4) angina occurred in eight. In their nine autopsies, they defined the pathological picture as follows: (1) left ventricular hypertrophy; (2) dilated aortic valves with stretching of cusps; (3) discrete intimal plaques in the aorta centered about each commissure, reaching into the sinuses of Valsalva and extending up to 2.5 cm distally; (4) focal destruction of the media with inflammatory cell response.

Subsequently, pathologists have attempted to integrate Mallory's lesion with other idiopathic aortopathy and arteriopathy, and have emphasized that any level of the aorta or the proximal part of its great branches may be involved.<sup>60</sup> Indeed, one of Clark, Kulka, and Bauer's cases had an aneurysmal dilatation of the descending aorta. In patients with ankylosing spondylitis, distal aortic involvement has been reported<sup>61–65</sup> but not, as yet, stenosis of arterial branches. Coronary artery lesions have not been reported, though flow may be affected by distortion and ectasia of the sinuses of Valsalva and by aortic valvular insufficiency.

Dissections have demonstrated obliteration of the A–V node by extension of inflammation into the nonmuscular portion of the interventricular septum.<sup>66</sup> Patchy myocarditis has also been evident in early cases.<sup>67</sup>

With the 1958 publication of Graham and Smythe's study,<sup>68</sup> the aortic lesion became accepted as a complication of ankylosing spondylitis. These workers followed 519 patients with spondylitis and noted the prevalence of aortic in-

sufficiency to rise from 3.5% after a 15-yr duration to 10.1% after 30 yr. They found prolonged A-V conduction in 2.5% of the 15-yr and 8.5% of the 30-yr cases. In 183 patients with peripheral joint involvement, the prevalence of both aortic insufficiency and A-V block was doubled. Iritis and psoriasis also increased the risk of aortitis.

The clinicians noted other stigmata of RD in patients with cardiac involvement. Thirteen had acute polyarthritis early in the disease, and urethritis closely preceded the arthritis in nine of these. In four, mild spondylitis contrasted with severe peripheral joint disease. Autopsies were done on three of the series patients and on two others, confirming the lesions of Mallory and Clark et al.

Following the impetus of these pioneer studies, many patients with aortic insufficiency, A-V block, or both have been added to the literature of ankylosing spondylitis. No studies include prevalence of these signs in a control population. As few are supported by tissue diagnosis, these reports are certainly diluted by diverse lesions (the differential diagnosis of aortic insufficiency has become lengthy in recent years).

Excluding the recent literature of Reiter's heart disease, necropsy-confirmed case reports of arthritis with aortitis are listed in Table 2. Most of these were published in contributions dealing with ankylosing spondylitis. It is arresting that 22 of 23 (96%) had peripheral joint disease, many following a course characteristic for RD, and nine (41%) had a history of urethritis more or less related to attacks of arthritis.

If this aortitis is indeed a function of spondylitis, it is curious that proved aortitis has virtually been unreported in patients with "pure" ankylosing spondylitis, those without history of peripheral joint involvement. About one-half of patients diagnosed as ankylosing spondylitis should be free from history of peripheral arthritis. In Polley and Slocumb's series of 1035 patients with ankylosing spondylitis, 242 had onset in peripheral joints, and a total of 513 subsequently had peripheral joint disease.<sup>80</sup>

#### *Cardiac Involvement with Reiter's Disease*

Since 1934,<sup>81</sup> a small proportion of patients with acute RD has been reported with pericarditis and other electrocardiographic changes, especially prolongation of the PR interval. These EKG changes have been generally regarded as benign and self-limited but may also presage chronic heart disease, such as persistent A-V block<sup>82,83</sup> and aortitis.<sup>83</sup>

An estimation of the frequency of cardiac involvement in acute RD is provided by Paronen's study, which included EKG's in 320 of 344 postdysenteric patients.<sup>3</sup> Seven had clinical pericarditis and 16, EKG changes only, including prolonged PR interval, widened QRS complex, elevated ST segment, and flattened T waves. One hundred of Paronen's patients were restudied 20 yr later.<sup>37</sup> During their acute RD, six had had "myocarditis" and one had "pericarditis." Of these seven on follow-up, one showed "cardiac insufficiency, type unspecified," and one had total heart block. The remaining patients had normal cardiac findings on physical examinations except for one with mitral valvulitis ascribed to earlier rheumatic fever. Weinberger et al.<sup>4</sup> obtained EKG's in eight patients during acute RD, four of whom showed alterations; one, persistent RBB; one, inverted T waves during acute attacks; and two, transient first A V

**Table 2. Ankylosing Spondylitis Heart Disease: Review of Literature.**  
**Patients with Necropsy—confirmed Aortitis**  
**(Excluding Cases Published as Reiter's Heart Disease)**

Reference	Arthritis of Peripheral Joints	Iritis	Reiter's Stigmata
57	+	0	Arthritis onset in feet; 35 lb loss
58	+	0	Arthritis onset in feet and remittent course; heel spur; proliferative changes at wrist; recurrent urethritis
69	+	+	Remittent arthritis, recurrent urethritis
70, Case 1	+	0	Multiple attacks of urethritis associated with foot and ankle involvement
70, Case 2	+	0	None
71	+	+	Remittent arthritis
59, Case 1	+	0	Remittent arthritis, onset in feet
59, Case 2	+	+	Remittent arthritis associated with flares of iritis
72	+	0	Remittent arthritis
61	+	+	Remittent arthritis; onset with fever and weight loss; urethral "sore"
73	+	+	Remittent arthritis; onset with fever
62, Case 1	+	0	Remittent arthritis; urethritis; conjunctivitis; stomatitis; fever
62, Case 2	+	0	None
74	+	+	Fever
75	+	0	Remittent arthritis
76	+	0	Generalized exudative or pustular psoriasis resembling keratoderma blennorrhagica
66	+	+	Urethritis onset followed by polyarthritis
77	0	+	None
78, Case 1	+	0	Urethritis onset followed by arthritis
64	+	+	Remittent arthritis; residual deformity only in ankles and feet
67	+	0	Recurrent urethritis; remittent arthritis; periostitis of ankles and feet
79	+	0	Remittent arthritis
65	+	+	Recurrent gonorrhoea, associated with onset of arthritis

block. One of the latter seen during a recurrence 2 yr later had a normal EKG, but a diastolic murmur near the sternum was heard on one occasion.

In 1897, Jacquet<sup>84</sup> described a patient with fatal aortic insufficiency acquired during prolonged debilitating attacks of RD. In 1943 Schuermann<sup>85</sup> noted a diastolic murmur transmitted widely over the precordium 2 wk after acute RD; no followup was possible in this military case. In 1951, Pirani and Bennett<sup>86</sup> reported a 7-yr-old child with arthritis, iritis, pustular dermatitis, and nail lesions, who died of aortic insufficiency due to a typical Mallory aortitis. By hindsight, this could be viewed as a childhood case of RD or psoriatic arthropathy. In 1956, Gamp<sup>87</sup> reported a patient with aortic insufficiency and A-V block appearing 11 yr after the onset of RD. Baron,<sup>88</sup> at a Heberden Society Clinical Meeting in 1960, reported a male and a female with RD complicated by spondylitis and aortic insufficiency, the latter with necropsy demonstration of aortitis. In 1961, Csonka<sup>83</sup> published three cases of aortic insufficiency discovered in a long-term study of 215 patients with RD, and included a fourth



patient, a female with possible RD whose autopsy demonstrated typical medial aortopathy, the murmur in the latter case appearing within 1 yr of onset of arthritis. Rodnan and Benedek in 1964<sup>89</sup> added two patients with aortic insufficiency, one with necropsy proof of aortitis.

Schilling et al. in 1965<sup>36</sup> found three males with aortitis among 22 patients with chronic arthritis following acute dysentery or RD. They also had a female patient with incomplete criteria for RD, who developed aortic insufficiency.

Generally, aortic insufficiency has appeared several years after RD. In 1965 an exceptional case was reported in which the murmur was discovered on the fourth day of hospitalization during a first attack of RD.<sup>90</sup> This murmur persisted through follow-up 9 mo later. A unique example of bacterial endocarditis superimposed upon probable RD appeared in 1967 in a patient with no previous evidence of heart disease.<sup>91</sup>

A patient with postdysenteric arthropathy developed aortic insufficiency in the 27th year of his illness.<sup>92</sup> This was a disturbing case because a necrotic granuloma was found in the aortic valve leaflet reminiscent of a rheumatoid nodule, and evidence for aortitis was not included. Another RD patient with aortitis confirmed at necropsy, as well as two living patients with aortic insufficiency and A-V block, were added by Cluff in 1971.<sup>93</sup>

A diastolic murmur appeared within a 9-day period while a patient was being treated for subacute RD, 7 mo after A-V block had become established.<sup>94</sup> Cardiac catheterization data confirmed aortic valvular disease.

Paulus and Pearson<sup>95</sup> have collected five cases of aortic insufficiency in a group of 105 men with RD diagnosed between 1957 and 1969. One died of congestive failure and severe calcific coronary arteriosclerosis after aortic valve replacement; aortitis was not verified at necropsy, probably because sections from the root of the aorta were not obtained. A patient in the group, who had normal sacroiliac X-rays, died of cancer of the esophagus 2 yr after A-V block and 5 mo after aortic insufficiency appeared. Though the aorta appeared grossly normal at postmortem examination, areas of active inflammation and patchy destruction of the media were noted microscopically.

Two sudden deaths have been noted in patients with RD. One, a male of 43, died in the fourth month of his attack after experiencing chest pain; necropsy was not done.<sup>96</sup> The other died suddenly after 8 yr of A-V block with Wenkebach, the autopsy showing mild old rheumatic changes of the mitral and aortic valves and focal atherosclerosis of coronary arteries. It is probable that sections were not taken at the aortic root.<sup>97</sup>

In a patient with a fatal gastrointestinal hemorrhage at about the fifth month of a severe attack, postmortem examination demonstrated spotty accumulation of inflammatory cells in the myocardium "of the type seen in many infectious processes including viral infections."<sup>98</sup>

#### *Heart Disease in the Reviewer's Series*

Eleven patients with A-V block or aortic insufficiency have been identified among 164 cases of RD seen by this reviewer at the University of Michigan Medical Center and the Ann Arbor Veterans Administration Hospital (see Table 3). Since some patients were seen only once early or late in the disease

**Table 3. Cardiac Involvement with Reiter's Disease  
(Survey of 164 Patients, 110 With Electrocardiograms)**

A-V block only (PR > 0.20 sec)		
Discovered during acute attack		4
No follow-up	2	
PR normal on follow-up	2	
No heart disease	1	
Aortopathy and coronary artery disease	1	
Discovered during follow-up		3
Transient	1	
Permanent	2	
Aortic insufficiency (three also with A-V block)		4
Appeared during follow-up (heart normal during acute attacks)	2	
Referred for surgical treatment of aortic insufficiency (not seen during acute attacks)	2	
Total		11

without particular screening for cardiac involvement, the true incidence may be considerably greater. A survey for cardiac disease, done on 11 patients called in for a radiographic follow-up study in 1968, disclosed first degree A-V block in one patient with a previously normal EKG and led to the fortuitous discovery of aortic disease during the preclinical phase in another.

FJL, AAVAH, 362 24 9041.

In 1945, at age 24, and again in 1964 this white male had urethritis, conjunctivitis, fever, and polyarthritis, the latter clearing completely in about 1 yr. In 1964, physical examination of his heart and the EKG were normal, PR interval 0.16. In 1968, his joints were normal except for bony swelling at the left foot, blood pressure was 138/100, pulse was 116, and the heart was normal to auscultation. The EKG showed a nodal tachycardia. By 1970, symptoms of left-sided failure appeared; a murmur of aortic insufficiency was heard; and an EKG showed normal sinus rhythm, complete left bundle branch block, and a PR interval of 0.24 sec. X-rays of the spine and sacroiliac joints were normal. Cardiac catheterization showed aortic insufficiency, mild mitral regurgitation, pulmonary arterial hypertension, and a wedge pressure of 35 mm Hg. The patient died suddenly at home a few months later; permission for postmortem examination was not obtained.

This pilot survey of 11 unselected patients representing a total followup of 179 yr, indicates the need for periodic cardiac examination after RD.

### Discussion

In summary, no sharp line can be drawn between early "benign" EKG changes and late aortopathy, so that patients with early cardiac manifestations should be followed carefully. As with ankylosing spondylitis, the aortic insufficiency of RD is typically a late sequel, though exceptionally it has appeared within months.

Enough cases are at hand to establish that the aortopathy of RD is identical to that previously associated with ankylosing spondylitis. In point of fact, the lesion first entered the literature via patients who probably had RD. Some have regarded it as a stigma of RD, "any spondylitic who gets cardiomegaly, pericarditis, and conduction defects in an EKG with or without aortic insufficiency

should be reviewed as a possible case of RD."<sup>99</sup> In this view, aortitis is not a link between RD and AS, but rather defines variant cases of ankylosing spondylitis evolving from RD.

The aortitis is probably significantly under-reported.<sup>100</sup> First, the disease becomes symptomatic in middle-aged men, a high-risk group for atherosclerotic heart disease, and the aortitis may, in fact, overlap symptomatic atherosclerotic disease in some of these patients. Detection of the disease at autopsy requires an alert and well-informed prosector who should obtain sections of the aorta in numerous levels. Gross changes are frequently not evident. A superimposed atheroma may mask the underlying inflammatory process and the lesion may be confined to a single cusp.<sup>100</sup>

Published antemortem series of patients with aortic insufficiency or A-V block, undoubtedly diluted with various and sundry cardiac pathology, have a limited study value. Gross scrutiny at thoracotomy and microscopic examination of resected leaflets have been nearly useless in detection of the aortopathy. In the future, cardiac catheterization and contrast studies of the entire aorta should help define the scope of the disease.

#### NEUROLOGIC INVOLVEMENT WITH REITER'S DISEASE

In Table 4, literature references to patients with peripheral and in Table 5, to those with central nervous manifestations are grouped. During acute attacks of RD, both peripheral and central nervous system involvement have been reported.

##### *Peripheral Nervous Involvement*

Schittenhelm and Schlecht<sup>14</sup> collected 140 cases of arthritis during a *Shigella* epidemic, some of which grew out *dysenteriae* species and some a "nontoxic" species. A minority of patients satisfied criteria for RD, as only 20% had conjunctivitis, 6% urethritis, and virtually none mucocutaneous manifestations. The authors found few patients with neuropathy, reporting one patient with trigeminal neuralgia, one with peripheral facial palsy, and three with sciatica.

In contrast, Wilke<sup>101</sup> encountered prominent peripheral neurologic signs among troops ill with epidemic shigellosis in Russia in 1942, in most cases either *dysenteriae* or *flexneri* species. He made no attempt to enumerate his total

**Table 4. Review of Literature  
Peripheral Neurological Involvement With Reiter's Disease**

Reference	Description
15	Infectious polyneuritis, Guillian-Barre type
50	Polyneuritis, foot drop
105	Paresthesias, feet and legs
102, Case 1	Shoulder girdle palsy
102, Case 2	Lumbar radiculitis
4	Sciatica
103	Shoulder girdle neuritis
17	Intercurrent disk disease
105	Bilateral ulnar neuropathy

**Table 5. Review of Literature**  
**Central Nervous System Involvement With Reiter's Disease**

Reference	During Acute Attack	During Follow-up Period	Description
111	+		Nystagmus, clonus at patellas and ankles
112	+		Fatal meningoencephalitis
109	+		Optic neuritis
	+		Optic neuritis
110		+	Retrobulbar neuritis
113	+		Hemiplegia (history of epilepsy)
115	+		Cranial nerve palsies, pyramidal tract signs
114	+		Depression, headache, prolonged singultus, CSF proten 80mg%
102, Case 1	+		Meningoencephalitis, optic neuritis CSF changes
97	+	+	Delirium during acute attack; loss of consciousness, hemiparesis 23 yrs later
37	+	+	Encephalitis with acute attack; Parkinson's disease 12 yrs later
117		+	Pyramidal tract lesions, extrapyramidal and prob- ably cerebellar disturbance, aphasia, organic personality change, Jacksonian seizures, prob- able narcoleptic attacks
116		+	Paranoid schizophrenia
41		+	Chorea

cases of either dysentery or neuritis and included only oblique reference to RD, noting that not uncommonly neuritis was accompanied by conjunctivitis, arthritis, and nonspecific urethritis. Neurologic signs among his cases with and without RD were not dealt with separately. Most commonly, he found palsy of proximal limb muscles with minimal or absent sensory deficit, usually occurring as the diarrhea was subsiding. A number of patients had shooting pains and sensitive pressure points in the affected muscles. Some with minimal or no pain presented with progressive hip and shoulder atrophy, a "pseudomyopathic" form.

Somewhat later in the course of the epidemic, patients presented with prolonged diarrhea and persistently positive cultures from sigmoid colon ulcers. The relatively mild neuritis noted above tended to relapse at this stage and become widespread. Among these patients, truncal and cervical muscle palsy and bilateral facial palsy occurred. Superficial and deep sensory modalities were affected in this group. Spinal fluid showed an albumino-cytologic dissociation with marked increase in protein and little or no pleocytosis, the highest white cell count being 24. One patient with almost total extremity and truncal palsy died of pneumonia; autopsy employing routine staining methods showed no inflammatory change in the spinal cord.

As a result of Wilke's clinical description, the typical neurologic syndrome associated with RD is cited as a polyneuritis predominating in the hip and shoulder girdle, mainly motor, and almost always occurring as a sequel to bacillary dysentery. However, similar localized neuropathy has been observed in RD patients following amebic dysentery<sup>50</sup> and without a history of dysentery,<sup>102,103</sup>

nor was dysentery mentioned in a patient with infectious polyneuritis of the Guillian-Barre type.<sup>15</sup>

Sciatica or lumbar radiculitis has been reported in recent years<sup>4,17,102</sup> and may represent intercurrent degenerative lumbar intervertebral disk disease. It is also possible that acute spondylo-diskitis may contribute to radiculitis, as demonstrated by a patient who had radicular arm pain and a destructive cervical spinal lesion with subluxation at the third and fourth vertebrae 5 mo after onset of acute arthritis with keratoderma blennorrhagica.<sup>104</sup>

There are reports of peripheral neuropathy occurring in ill patients with extensive skin disease.<sup>105,106</sup> These recall early French<sup>84</sup> and German<sup>107</sup> descriptions of severe and widespread keratoderma blennorrhagica in which rapidly progressive muscle atrophy, disturbances of sensation, and hyperactive reflexes suggested a toxic neuropathy or myelopathy.

#### *Central Nervous Involvement*

During acute attacks of RD, patients occasionally have had signs of central nervous system disease. There have been a few reports of isolated manifestations such as facial palsy,<sup>108</sup> optic neuritis,<sup>102,109,110</sup> and nystagmus.<sup>111</sup>

Fatal meningoencephalitis following an attack of post-dysentery RD has been documented in a 59-yr-old woman.<sup>112</sup> Three months after onset of conjunctivitis and arthritis, she became withdrawn and verbalized paranoid delusions. This was followed by remittent fever, anorexia, lassitude, headache, and nuchal rigidity, until she became comatose and died in peripheral vascular collapse. Necropsy showed hyperemia and numerous lymphocytic and polymorphonuclear perivascular infiltrates in the brain stem, frontal lobes, and leptomeninges.

Another patient with a 22-yr history of psychomotor seizures had confusion, unconsciousness, and temporary hemiplegia during acute RD.<sup>113</sup> Headache, prolonged singultus, and elevation of the spinal fluid protein provided some evidence for acute encephalitis in a third case.<sup>114</sup>

Csonka<sup>115</sup> has reported a patient who developed stereotyped central signs during his fourth, fifth and seventh acute attacks of RD, none of which were accompanied by diarrhea. Manifestations included leg weakness and multiple brain stem manifestations such as ptosis, lateral nystagmus, unilateral facial palsy, diplopia due to lateral rectus palsy, and paresthesias over the face. He was mentally "normal" throughout. In each instance, the neurologic signs appeared and disappeared synchronously with the typical Reiter's triads.

Another convincing report of acute meningoencephalitis following an attack of RD is available.<sup>102</sup> Five weeks after the onset of arthritis, the patient developed a recurrence of conjunctivitis, slight fever, and became confused, verbalized paranoid delusions, and suffered a grand mal convulsion; the spinal fluid showed elevated protein and pleocytosis. After 2 days of unconsciousness with nuchal rigidity and signs of optic neuritis, the neurologic signs cleared and the spinal fluid returned to normal.

More recently, late central nervous manifestations have been mentioned in published reports, both with and without history of neuropsychiatric disorders during acute RD. After 23 yr of recurrent attacks of RD, a 44-yr-old man developed delirium during a flare of iritis. This was followed in 5 yr by A-V block

and chronic heart failure. Five years later, he became unconscious with "mild left cerebral impairment" and soon died. Necropsy showed evidence of minute old hemorrhages in the brain.<sup>97</sup>

A followup study of one hundred patients who had acute RD during 1944 Flexner-Shigella epidemic in Finland<sup>37</sup> disclosed a single late neurologic problem, postencephalitic Parkinson's disease, in a man who had suffered severe headaches for 2 mo during his acute RD. Another possible late sequel to this same 1944 epidemic occurred after a family outbreak of RD in which three sisters contracted dysentery from a woman employee of a military hospital in Finland.<sup>116</sup> All four of these females developed features of RD, especially the youngest sister, who had prolonged articular disability. In 1955, she had a recurrence of arthritis and dysuria associated with iritis, and schizophrenia was diagnosed, treated by leukotomy in 1958.

In 1970, a detailed report appeared of a patient with RD and chronic active encephalitis over a 9-yr period.<sup>117</sup> The illness began at age 23 with urethritis, a macular-papular leg rash, and acute disturbance of consciousness. Arthritis involving the feet and wrists appeared at age 25 and chronic back pain at age 32. At age 46 an attack of fever, peripheral arthritis, and urethritis recurred. The following year bilateral conjunctivitis was found. However, after age 39, superimposed upon the above manifestations of Reiter's disease, the patient also had changing and evolving neurologic problems, including disseminated pyramidal tract lesions, L-4 sensory loss, extrapyramidal and probably cerebellar disturbance, aphasia, persistent organic personality change, diminished libido and potency, Jacksonian seizures, probable narcoleptic attacks, disorientation, sleep disturbances, loss of ability to concentrate, and variable severe headaches. From the data included, the diagnosis of RD seems definite enough though not typical. Diarrhea occurred only once, 14 mo before the onset.

In a recent report, a childhood attack of postdysentery RD was followed in 7 yr by chorea.<sup>41</sup> A single antistreptolysin O titer was 250 U, but other evidence for rheumatic fever was not forthcoming. Two years later, an obsessive-compulsive neurosis was also diagnosed in this case.

Psychic problems during RD have received little direct attention in the literature, though case reports occasionally mention behavior problems during acute attacks. In their 16 patients, Weinberger et al. did not report neuropsychiatric problems except for two with depression, in one instance possibly due to water overload.<sup>4</sup> Csonka<sup>5</sup> has stated that many patients appeared depressed and unduly anxious. He was impressed by cases in which these symptoms developed during the course of the disease. In such patients, convalescence seemed unduly prolonged, followed by many ill-defined symptoms such as fatigue, "tired eyes," and impotence. He found that his patients appeared to associate their illness with irregular sexual practices and suffered from feelings of guilt. Simple psychotherapy to resolve conscious and near-conscious conflicts was helpful.

The lifelong medical history of Francis Parkman, the 19th Century American historian, has been reconstructed and analyzed by Atkinson,<sup>118</sup> who speculated that RD was an explanation for recurrent diarrhea, ophthalmitis, feelings of insanity, depression, seizures suggesting labyrinthitis, and arthritis. This case provides little more than an interesting footnote, since evidence for RD is tenuous.

*Neurologic Manifestations in the Reviewer's Series*

A compilation of the known neuropsychiatric problems in our series of 164 patients is given in Table 6. (See Appendix for reports of representative patients.)

The neuropsychiatric survey of 164 patients disclosed 20 patients with signs or symptoms limited to the period of acute RD. Eight had signs of possible central involvement only. Three of these had a single episode of "fainting"; one of these also had subsequent sleep disturbance for several weeks. One had nausea, vomiting, and headache followed by depression during each of three attacks. One patient had a prolonged depressive reaction. Two had stereotyped psychotic reactions during a total of four attacks manifested by antagonistic, hostile, and uncooperative behavior. (One of these abused alcohol and had signs of an old retrobulbar neuritis.)

**Table 6. Neuropsychiatric Signs and Symptoms Among 164 Patients With Reiter's Disease**

Patients with involvement during acute attacks only		20
Central signs only		
Loss of consciousness	3	8
Depression	1	
Depression plus nausea, vomiting, headache	1	
Psychosis	2	
Cranial nerve deficit	1	
Peripheral signs only		
Brachial plexitis	2	8
Sartorius muscle denervation	1	
Meralgia paresthetica	3	
L-5 radiculitis	1	
Polyneuropathy	1	
Central and peripheral signs		
L-4 radiculitis plus convulsive seizure	1	4
L-5 radiculitis plus memory disturbance	1	
Polyneuritis plus psychosis	2	
Patients with involvement both during and apart from acute attacks		14
	<u>Acute</u>	<u>Late</u>
Loss of consciousness	1	Seizures 7
Psychosis	4	Seizures and schizophrenia 4
Convulsive seizure	3	Paranoid psychosis 3
Hemihypesthesia	1	
Loss of consciousness and polyneuritis	1	
Schizoid effect and meralgia paresthetica	1	
Lumbar radiculitis	1	
Patients with involvement during late periods only		12
Central signs only		
Seizures	1	4
Schizoid personality	1	
Depression	2	
Peripheral signs only		
Meralgia paresthetica	2	8
Lumbar radicular (disk) syndrome	6	
<b>Total</b>		<b>46</b>

There was only a single case with cranial nerve involvement, a 52-year-old male, seen during his fourth attack of classical Reiter's triad, who developed a glossopharyngeal motor deficit (see Appendix, Case 1).

Eight patients had signs limited to the peripheral nervous system. Two had partial brachial palsy with sensory signs. One had weakness in a single leg associated with sartorius muscle denervation demonstrated by electromyogram and three unilateral meralgia paresthetica. One had mild peripheral polyneuropathy, and one had acute L-5 radiculitis.

Four had a combination of central and peripheral signs limited to the acute attacks. In two, the attack was associated with acute onset of L-5 radiculitis. One of these later had a single convulsive seizure preceded by an aura, the other had psychotic reactions with peripheral polyneuropathy; both were debilitated patients with extensive pustular dermatitis, erythroderm, and weight loss.

Fourteen patients had neuropsychiatric signs both during acute attacks and subsequently during chronic or intercritical periods. Eleven of these, listed in Table 7, had episodes more or less characteristic for seizure states. In two cases, the seizures began before age 20 and probably antedated the first signs of RD. Six had disturbances of consciousness during acute RD, variously described as obtunded, amnesic, syncopal, and three others had psychoses during acute RD, two of which were termed schizophrenia.

Three others in this group have not had a history of seizures. One had a lumbar radiculitis with acute RD, later he had a neuropsychiatric hospitalization on three occasions with diagnoses variously listed as depression and paranoid schizophrenia; he has also abused alcohol and shown a few episodes of violent, uncontrolled behavior. An EEG during sleep has demonstrated a significant temporal lobe dysrhythmia. The other had a fainting spell during acute RD. His main disability subsequently has been a paranoid personality disorder.

Twelve patients had neuropsychiatric signs recorded only during intercritical or later periods, apart from acute attacks. Six had lumbar intervertebral disk syndromes, and two had meralgia paresthetica. Four had central manifestations, including schizoid personality, depression, and grand mal seizures.

### *Discussion*

As with heart disease, our survey for neuropsychiatric problems was carried out retrospectively as a chart review, including patients seen only once as well as those followed for years, and was based in part upon old armed service records of uneven quality. It is not feasible to indicate the total patient years at risk. However, this raw data, largely anecdotal, appears to confirm the impression that neuropsychiatric sequelae are a feature of Reiter's disease.

During acute attacks some of the disturbance of consciousness, "amnesia" and behavior disorder can be ascribed to severe pain, hyperventilation, fever and drugs. There is little recorded evidence for encephalitis in terms of electroencephalographic and spinal fluid changes.

Even in acute RD, spondylitis may account for a measure of paresthesia and apparent weakness. High cervical spondylitis is commonly interpreted as headache. Elevated spinal fluid protein is sometimes found in RD in the absence of other signs of central nervous disease.<sup>119</sup> This recalls the modest elevation of



Table 7. Reiter's Disease Associated With Seizures

Patient	Birth	Onset RD	Neuropsychiatric Signs with Acute RD	Number of Acute Attacks	Onset Seizures	Description of Seizures	Number of Seizures	Comment
J.J.	1933	1953	Delirium	3	1959	Amnesic combative episodes precipitated by modest alcohol	4	1972: cluster headaches
J.S.K.	1925	1956	"Obtunded"	2	1965	Found unconscious	1	1959: tunnel vision, arteriogram negative. 1962: tremulous, headache, gait disturbance 1948: lues, penicillin treatment
W.K.	1921	1945	Unconscious 12 hr	3	1940	Grand mal, up to 15/yr few after 1957	innumerable	
E.E.K.	1947	1969	Convulsion, headache and vomiting	2	1969	Vomiting followed by grand mal	4	1970: impotent 1971: occasional myoclonic jerks Possible alcohol abuse
E.M.	1919	1941	Loss of consciousness, polyneuritis, CSF pleocytosis	3	1941	Nocturnal attacks of shouting and thrashing about	many	
R.S.Z.	1930	1947	Grand mal seizure	8-10	1947	Aura followed by grand mal	innumerable	1953: hospitalized for psychosis
V.D.D.	1900	1918	Acute psychosis	3	1949	Prodromal vertigo, falls unconscious, (occur only while upright)	5	1966: left C 6-8 radiculitis
J.R.B.	1920	1940	Acute psychosis "dementia praecox"	1	1942	Brief attacks called petit mal; 1946, onset Jacksonian seizures	10-20	1946: "depressed schizoid" 1949-53, 59: hospital treatment for schizophrenia
J.E.C.	1922	1945	Paresthesias "paranoid schizophrenia versus organic brain syndrome"	5	1959	Grand mal	several	1959: hospital treatment for schizophrenia; 1968: heart failure, dilated aorta, sudden death 1920's: schizophrenia diagnosed; 1943: skull fracture during seizure
J.K.	1899	1918	Hysteria hemihypesthesia	2-3	1937	Grand mal	many	
D.A.W.	1927	1947	Unconscious, acute schizophrenia	3	1966	Jacksonian	3	Seizures preceded symptomatic heart disease, presumably aortitis
W.B.S.	1926	1938	None	3	1945	Grand mal	several	Aortic insufficiency; 1967: death following heart surgery

the spinal fluid protein in 25%–42% of patients with ankylosing spondylitis,<sup>120</sup> perhaps due to funiculitis, for which Bechterew found evidence in one autopsied patient.<sup>121</sup> Three of our patients with neuropsychiatric symptoms had received Roentgen irradiation over the lumbar spine; none had evidence for transverse myelitis, a potential complication of excessive dosage.<sup>122</sup>

Pronounced peripheral polyneuropathy appears to be unusual with RD and limited mainly to patients with debility, severe weight loss, and generalized pustular psoriasis.

Three of our patients with seizures eventually had heart disease with more or less evidence for aortopathy. Since the neuropsychiatric disease occurred early, it seemed unlikely that cerebral ischemia due to heart disease played a role in their central nervous system disease. It is possible that the aortopathy may lead to stenosis of arteries arising from the aortic arch, though such a case has not yet been reported with ankylosing spondylitis or RD, perhaps because few arteriograms are included in the literature as yet.

Neither hypertension nor history of head trauma was recorded at the time seizures began in any patient. Alcohol abuse probably played a role in two or three patients, but none had evidence for chronic alcoholism or Wernicke-Korsakoff's psychosis. One had syphilis 8 yr after epilepsy began.

The curious frequency of paranoid psychosis, often associated with seizures, among our patients deserves investigation. In three cases, paranoid reactions or seizures may have preceded the first sign of RD. It is our impression that the paranoid states have fluctuated widely in any one patient, are mild, and tend to improve with time. It is interesting to note that encephalitis may begin with a paranoid state.<sup>123</sup> In two of our patients with paranoid psychosis, the disorder appeared during acute attacks of RD, but in four cases, psychosis was diagnosed later, appearing to be independent of flares of arthritis and other manifestations. Most of our patients with late seizure disorders and psychosis had neuropsychiatric problems during one or more acute attacks of RD.

Our finding of psychotic reactions, especially paranoia, and seizural disorders could be due to mere chance association. However, our experience contrasts with the reported rarity of psychosis during active rheumatoid arthritis. In Short, Bauer and Reynold's long-term study of 293 patients with rheumatoid arthritis,<sup>124</sup> neither psychosis nor seizures are mentioned.

Diarrhea was more frequent in our cases with neurologic involvement than those without. Diarrhea occurred during acute attacks in eight of the 15 with late psychosis or seizures and in ten of the 31 with acute neuropsychiatric symptoms or other late manifestations, and in only 19 of the remaining 118 patients. The frequency of diarrhea was surprising as it had been our impression that RD in North America is overwhelmingly postvenereal. In fact, several of our patients had onset of RD with epidemic or endemic diarrhea during wartime military service, so it is probable that some had RD following shigellosis. Neuropsychiatric manifestations have occurred in as many as one-third of some series of bacillary dysentery, and range from girdle mononeuritis to CNS signs such as vertigo, convulsive seizures, "postencephalitic" Parkinson's disease, and on occasion persist for many years as permanent sequelae.<sup>125</sup> The pathogenesis of these late cases is speculative as no neuro-

pathologic changes have been published. *Shigella dysenteriae* is the only species known to elaborate neurotoxin. As with arthritis the onset of neurologic signs is often delayed, suggesting an immunopathologic mechanism or entrance of another infective agent.

The neurologic manifestations of some patients with RD raise the question of Behcet's syndrome, in which neurologic signs may occur weeks to several decades after the initial manifestations and follow a fluctuating course. With Behcet's all parts of the central nervous system have been involved. Cranial nerve palsies, seizures, organic mental syndromes, aphasia, hemiparesis, extrapyramidal signs, cerebellar signs, and the Brown-Sequard syndrome have been reported. The most common feature is meningeal irritation with pleocytosis, usually less than 100 cells/mm<sup>3</sup>, and slight elevation of the CSF protein.<sup>126</sup> However, urethritis is a rare manifestation, X-ray changes in the joints and spine have not been documented, and the skin lesions are acneiform and pustular rather than psoriaform. RD patients with neurologic signs have not been reported with recurrent painful oral or genital lesions that are the hallmark of Behcet's syndrome.

Systemic lupus erythematosus is another rheumatic disease not uncommonly associated with seizures and psychosis. In most reports of RD with neurologic involvement seen after 1950, negative LE cell preparations or other tests for antinuclear antibodies have been included in the diagnostic workup. These were performed in 11 of our 12 patients with late seizures and were negative in all.

In summary, neuropsychiatric involvement in acute RD is characterized by occasional acute meningoencephalitis, acute psychotic reactions, and rare cranial nerve lesions. Chronically, there appears to be an excess of seizureal and personality disorders, especially paranoid states. Peripheral nervous system manifestations are typically isolated cervical or lumbar radiculopathy. Polyneuritis occurs in debilitated patients with widespread dermatitis.

## APPENDIX

### Case 1

J.J.K., Ann Arbor V.A. Hosp. No. 015895.

This 51-yr-old janitor was admitted on January 6, 1965 because of an attack of Reiter's disease of 7 wk duration.

At age 19, 7 days after his first sexual intercourse, he had urethritis followed by bilateral conjunctivitis, lumbosacral and right shoulder pain, and swelling of his right index finger and left fourth toe. Thirty days after onset, he had lesions on his tongue and palate. He recovered completely within 6 mo except for residual hammer toe deformity of the left fourth toe. During this illness, the serologic test for syphilis was found to be positive, and he was treated with salvarsan.

At age 26, he had urethritis, balanitis, and pain or swelling in his ankles, great toes, posterior heel, knees, hips, low back, left index finger, sternoclavicular joints, and the sternomanubrial articulation. There were also tongue and palatal lesions associated with slight burning. He was disabled for 10 mo.

At age 32, a serologic test for syphilis was negative; at 39 and 50, he received courses of penicillin when his serology was found to be slightly positive.

At 51, he had urethritis followed by severe abdominal pain and watery diarrhea lasting 3 days. One month after onset, he developed pain and limitation of motion of his neck followed by pain in his dorsal spine, low back, right ribs, and shoulder as well as painful swelling of his knees and left heel. Coincidentally with his neck pain he had mild dysphagia, his voice became

nasal in tone, and he had dysarthria. During swallowing he occasionally regurgitated liquids through his nose. By the time of admission 3 wk later, these symptoms had improved about 50%.

On physical examination he presented as a dull, irritable man who answered questions slowly. Mild limitation of rotation in the cervical spine, swelling and heat over the knees, old valgus deformities of the first toes, and a hammer toe deformity of the right third toe were noted. There were white, umbilicated lesions on the glans penis.

His voice was nasal or bleating in character. He was unable to whistle. The gag reflex was present, but the left side of the palate raised weakly and the uvula deviated to the left.

The hemoglobin was 11.7 sedimentation rate 53 mm/hr, and the urinalysis normal. The VDRL serologic test was weakly reactive and the fluorescent *Treponema* antibody test also weakly reactive. A latex fixation test for the rheumatoid factor was negative. The antistreptolysin O titer was 100 U, and the LE cell preparation was negative. Serum iron was 62  $\mu\text{g}\%$  with an unsaturated iron-binding capacity of 200  $\mu\text{g}\%$ . A lumbar puncture on January 16, 1965 showed normal dynamics. The cerebrospinal fluid analysis revealed no cells, a nonreactive VDRL, and a protein of 60 mg%. A repeat lumbar puncture on January 29 showed one white blood cell per high power field and a total protein of 74 mg%. X-rays of the cervical spine were normal; the sacroiliac joints showed early bilateral sclerosis and erosions. An upper gastrointestinal series on January 19 with special spot films at the proximal esophagus was normal.

The patient's mental status improved during the first hospital week. When seen by a neurologist on January 18, he was alert and performed quite well on memory and arithmetical testing. His speech had only minimal residual nasal quality. The palate rose well with phonation. The gag reflex was normal, though the uvula still deviated slightly to the left. The remainder of the neurologic examination was normal. During pulmonary function tests done February 15, 1968, he was able to develop 50–60 mm Hg at the mouth both with and without nose clips, indicating normal strength of the nasal airway-occluding mechanism.

His arthritis improved slowly; he was discharged on January 8, 1965 and seen in April, June, and December 1965 as an outpatient. On the latter date, his sedimentation rate was normal, his hemoglobin was 14.8, he had regained normal weight. Joint examination showed only mild cervical limitation in addition to old deformities of the feet. His uvula was no longer deviated. A calcaneal spur was discovered on X-ray of the right foot.

*Summary:* After two attacks of a venereal Reiter's syndrome, the patient developed a third attack following diarrhea. This was associated with mental changes, glossopharyngeal nerve deficit, and increased spinal fluid protein.

## Case 2

J.E.C. Ann Arbor, V.A. Hospital No. A-406.

In 1945, at age 23, this Army officer had conjunctivitis, nonspecific urethritis, polyarthritis, back pain, dermatitis, and transient first degree A-V block. He was treated with Roentgen radiation over the sacroiliac joints and hospitalized for 6 mo. Recurrent attacks of arthritis, some with urethritis and conjunctivitis, occurred in 1947, 1955, 1956, and 1957. In 1956, he had left meralgia paresthetica, and a murmur of mitral stenosis was heard.

In 1957 Roentgen radiation was again administered over the lumbar spine because of increasing back pain. No murmur was heard; cardiac fluoroscopy and the electrocardiogram were normal. A personality disturbance was noted, and a psychiatrist diagnosed paranoid schizophrenia vs. possible organic brain disease.

In 1958, he had visual and auditory hallucinations. In 1959, grand mal convulsions appeared followed by temporary incoherence and combativeness. He spent several months in a state mental hospital with a diagnosis of chronic brain syndrome. The epilepsy later was well controlled with diphenhydantoin and phenobarbital.

In 1968, after dyspnea and edema appeared, he was hospitalized in another institution for treatment of congestive failure. He had no history of angina or other chest pain. The blood pressure was 180/100 mm Hg. No murmurs were heard. There were no signs of arthritis or spondylitis. The neurologic examination was unremarkable, and the mental status was normal on maintenance therapy of chlorpromazine, diphenhydantoin, and phenobarbital. An electrocardiogram showed signs of left ventricular hypertrophy and T-wave changes; the PR interval was normal. Right and

left cardiac catheterization showed poor contractibility of both ventricles. A coronary angiogram demonstrated marked abnormality of the right and of the circumflex branch of the left coronary artery. A femoral arteriogram showed the distal aorta aneurysmally dilated, particularly just above the bifurcation. He was discharged on digoxin with diagnoses of coronary atherosclerosis and hypertension. He died suddenly at home 4 mo later; no necropsy was performed.

*Summary:* After 12 yr of recurrent signs of RD, epilepsy and mental disease, variously diagnosed as schizophrenia or organic brain disease, appeared. Transient signs of myocarditis during acute RD were followed in 23 yr by heart failure, when a dilated aorta and coronary artery disease were found.

### Case 3

D.A.W., Ann Arbor V.A. Hosp. No. 18415.

In 1947, this 20-yr-old soldier had severe febrile diarrhea during which he had temporary loss of consciousness. In 1948, peripheral arthritis, low back pain, fever, discharge from both eyes, skin lesions and a 20-lb weight loss occurred. Later in the year, a diagnosis of acute schizophrenia was made, and he was given a medical discharge from the Army. Repeated flares of arthritis and skin lesions ensued, each lasting several months. In 1954, a flare included pyuria without urethritis. In 1957, conjunctivitis occurred with the arthritis.

He was first seen at the Ann Arbor Veterans Administration Hospital in 1957 presenting with polyarthritis and widespread, pustular, psoriatic skin lesions. No heart murmur or electrocardiographic abnormality was found. Paranoid schizophrenia was confirmed by the psychiatric consultant, although felt to be in partial remission.

His skin disease fluctuated widely with periods of total remission. Ankylosing spondylitis became evident and progressed to disabling kyphosis. A lumbar osteotomy was done in 1962, increasing his height 6 in.

In 1965, a murmur of aortic insufficiency with a wide pulse pressure and first degree A-V block were found. Blood cultures, the VDRL serology for syphilis, and the antistreptolysin O titer were negative.

At home during 1966, he had intermittent twitching in his extremities and three attacks of loss of consciousness beginning as left-sided Jacksonian seizures. Soon afterward, diffuse hyperesthesia appeared over the legs. He was readmitted 6-mo later in a helpless fetal position with knees and hips maximally flexed, numerous large decubiti, and almost total body psoriasis. Sensory examination showed distal blunting and over-reacting to light touch and pin prick; delay was noted to stimuli beyond a critical threshold. The deep tendon reflexes were absent. Wasting was extreme, but no fasciculation was noted. Cardiac findings were unchanged. Blood pressure was 128/50/0 mm Hg. Routine laboratory studies showed normal electrolytes and serum creatinine. X-rays of the cervical spine with laminograms were difficult to interpret but did not show clear evidence of subluxation or fracture deformity. No evidence of interruption of the corticospinal tracts appeared during hospitalization. Later he had recurrent pseudomonas and staphylococcal septicemia and died with terminal gastrointestinal bleeding in 1967. Permission for necropsy was not granted.

*Summary:* Acute schizophrenia appeared soon after onset of a post-dysentery Reiter's syndrome. Most probably his acquired aortic insufficiency and A-V block were signs of aortitis. Later he became debilitated due to generalized psoriasis and spondylitis and almost total body ankylosis. In his last year of life, idiopathic Jacksonian seizures and peripheral neuropathy appeared.

### Case 4

J.R.B., Ann Arbor V.A. Hosp. No. A 5644

In 1940 at age 20, this soldier had prolonged nonspecific urethritis. Later in the year a diagnosis of paranoid schizophrenia was also recorded. In 1941, he had acute diarrhea and severe bitemporal headaches, followed by urethritis, conjunctivitis, and polyarthritis.

During 1942 he had several brief seizures diagnosed as petit mal. In 1946 Jacksonian seizures involved the right arm. In 1944, 1953, and 1955 there were recurrent urethritis, oligoarthritis, and back pain.

He was seen for the first time at the Ann Arbor Veterans Administration Hospital in 1957 because of abdominal pain, urethritis, and swelling of the left knee, a metacarpophalangeal, and a metatarsophalangeal joint. A diagnosis of Reiter's disease was made; a psychiatric consultant added the diagnosis of passive dependent personality disorder.

During 1962 he was treated at a state mental hospital for recurrent psychosis.

We examined him most recently in 1963 when the spine and peripheral joints were unremarkable. He was friendly, cooperative, not on any medications, and had no apparent psychiatric illness. Neurologic examination was negative. The bentonite flocculation test for the rheumatoid factor and a L.E. cell test were negative. The EEG was mildly abnormal with no focal or paroxysmal activity.

*Summary:* Following a triad during his initial postdysentery illness, dissociated signs of RD recurred for 16 yr. These were interspersed with a seizure disorder and a psychosis, the latter quite variable and subject to remission.

### Case 5

J.C.C. Ann Arbor V.A. Hosp. No. A3324.

In 1954, at age 25, this factory worker had an attack of urethritis, back pain, and weakness in his right leg associated with paresthesias over the lateral thigh. Chronic back pain continued intermittently until 1961 when he suffered a sequence of urethritis, balanitis, conjunctivitis, pain and swelling in his knees, and increased back pain.

He was seen for the first time at the Ann Arbor Veterans Administration Hospital 3 mo later. Physical examination showed a friendly, cooperative man with right conjunctivitis, circinate balanitis, and urethral discharge. The peripheral joints and spine were normal. Urethral culture disclosed no pathogens. The latex rheumatoid factor test and L.E. cell preparations were negative. An electromyogram showed no abnormalities in the muscles supplied by the lower lumbar and sacral segments. He was soon free of symptoms and discharged after 2 wk with a diagnosis of Reiter's disease.

In 1962 he was hospitalized on the psychiatric service for 5 mo with a diagnosis of personality disorder, passive-aggressive type with moderate alcoholism. He was again given inpatient psychiatric treatment for 2 mo in 1963, when a diagnosis of chronic, undifferentiated schizophrenia was made. The patient described occasional seizures characterized as facial grinning, extension of the right arm, flexion of the left arm, and thrashing wildly about. During a 30-min sleep study, an EEG showed a left anterior and midtemporal focal abnormality, compatible with clinical temporal lobe seizure phenomena.

He was treated briefly in 1966 on the neurology service because of a head injury. Diagnoses of schizophrenia, alcoholic intoxication, and cerebral concussion were made. Arthritis was in complete remission. The patient signed out against medical advice.

*Summary:* After onset of Reiter's disease, the course was complicated by a personality change culminating in schizophrenia. Though seizures were never documented, temporal lobe epilepsy was suspected. Alcohol abuse appeared to be a secondary problem.

### Case 6

E.L.Y. Ann Arbor V.A. Hosp. No. 076321.

In 1961, this 44-yr-old postal worker had balanitis followed by fever, intermittent diarrhea, pain in the lumbar and cervical spine, and joint swelling at the knees, feet, and ankles. His weight decreased from 220 to 131 lb. During the height of his febrile illness, he had paresthesias over the entire right side of his body as well as emotional lability, and passive-aggressive behavior. After a year he improved except for continued arthritis in his metatarsophalangeal joints.

When seen initially at the Ann Arbor Veterans Administration Hospital in 1962, arthritis in the metatarsal joints was present. He showed a demanding, hypochondriacal, labile personality. Extensive laboratory tests and radiographic studies were negative except for mild anemia. L.E. cell preparations and the latex fixation test for the rheumatoid factor were negative.

In 1963, he had nonspecific urethritis, circinate balanitis, and a scrotal dermatitis. A diagnosis of Reiter's disease was made. He regained most of his weight and improved greatly after 1963. By 1964, radiographs of the sacroiliac joints showed bilateral sclerosis and blurring of the joint margins. In 1967, he had dysuria with minor flare of arthritis.

In 1969, while hospitalized for treatment of a urethral stricture, he expressed paranoid delusions; a schizophrenic reaction was diagnosed and he was given 2 mo of inpatient psychiatric treatment. Since then, his paranoia had been mild and often inapparent. He has gradually developed ankylosing spondylitis with limitation of the cervical and lumbar spine and a mild loss of chest expansion.

*Summary:* Paranoid schizophrenia became evident in the eighth year of Reiter's disease. During his initial attack he had neurologic symptoms and psychotic behavior.

## REFERENCES

1. Reiter H: Die Reiterische Krankheit. *Dtsch Med Wochenschr* 82:1337, 1957
- 1a. Reiter H: Über eine bisher Unerkannte Spirochaeteninfektion (Spirochaetosis Arthritica). *Dtsch Med Wochenschr* 42:1535, 1916
2. Ruhl MJ, Sokoloff L: A thesaurus of rheumatology. *Arthritis Rheum* 7:97, 1965
3. Paronen I: Reiter's disease. A study of 344 cases observed in Finland. *Acta Med Scand (Suppl)* 212, 1948
4. Weinberger HJ, Ropes MW, Kulka JP, et al: Reiter's syndrome, clinical and pathologic observations. A long term study of 16 cases. *Medicine (Baltimore)* 41:35, 1962
5. Csonka G: Reiter's syndrome. *Ergeb Inn Med Kinderheilk* 23:125, 1965
6. Hollander JL: The diagnosis and treatment of Reiter's syndrome. *Med Clin N Am* 30:716, 1946
7. Good AE: Involvement of the back in Reiter's syndrome. *Ann Intern Med* 57:44, 1962
8. Editorial: Reiter's disease. *Br Med J* 3:386, 1971
9. Adams F: *The Genuine Works of Hippocrates*. Baltimore, William & Wilkins, 1939, p 315
10. Musgrave W: *De arthritide symptomatica*. Exeter. 1703, cited by Rolleston H: *The history of rheumatism in Great Britain*. *Br J Rheum* 2:189, 1940
11. Coulson W: On affections of the joints following operations on the genito-urinary organs. *Br Med J* :106, 1858
12. Brodie BC: *Pathological and Surgical Observation on Diseases of the Joints*, ed 1. London, Longman, 1818, p 58
13. Stoll M: (1776) cited by Huette: *De L'arthrite Dysenterique*, *Arch Gen Med* 14:129, 1869
14. Schittenhelm A, Schlecht H: *Über Polyarthritiden enterica*. *Dtsch Arch Klin Med* 126:329, 1918
15. Short CL: *Arthritis in Mediterranean theatre of operations*. *New Eng J Med* 236:383, 429, 468, 1947
16. Masbernard A: *Le syndrome de Fiesinger-Leroy-Reiter; enseignements par l'étude de 80 cas observés en Tunisie*. *Rev Rhum* 26:21, 1959
17. Noer HR: An "experimental" epidemic of Reiter's syndrome. *JAMA* 198:693, 1966
18. Vidal E: *Eruption généralisée et symétrique de croûtes cornées, avec chute des ongles, d'origine blennorrhagique coïncidant avec une polyarthrite de même nature*. *Ann Derm Syph (Paris)* 4:3, 1893
19. Shatin H, Canizares O, Ladany E: *Reiter's syndrome and keratosis blennorrhagica*. *Arch Derm* 81:551, 1960
20. Carr JL, Friedman M: *Keratodermia blennorrhagica*. Report of a case with autopsy. *Am J Path* 20:709, 1944
21. Khan MY, Hall WH: *Progression of Reiter's syndrome and psoriatic arthritis*. *Arch Intern Med* 116:911, 1965
22. Chauffard A: *Infection blennorrhagique grave avec productions cornées de la peau*. *Ann Derm Syph (Paris)* 793, 1897
23. Montgomery MM, Poske RM, Pilz GG, et al: *Reiter's syndrome*. *Gen Pract* 27:88, 1963
24. Stanislawski W: *Über einen Fall von gonorrhöischer Urethritis mit Affektion der Gelenke, symmetrische hornartigen Hautausschlag und Ausfallen der Nägel*. *Krankh. Harn Sex App* 5:643, 1900
25. Kulka JP: *The lesions of Reiter's syndrome*. *Arthritis Rheum* 5:195, 1962
26. Bork K, Kunde G: *Ophthalmoblennorrhoe bei Urethralgonorrhoe und konsekutive Iritis sowie Arthropathie trotz massiver Penicillinbehandlung (postgonorrhöisches Reiter-Syndrom)*. *Derm Mschr* 158:38, 1972
27. Garcia-Kutzback A, Masi AT, Dismuke SE: *A large-scale clinical analysis of acute infectious agent arthritis*. *Arthritis Rheum* 16:118, 1973
28. Csonka GW: *Recurrent attacks in Reiter's syndrome*. *Arthritis Rheum* 3:164, 1960
29. Baron JH: *Reiter's disease*. *Br J Clin Pract* 14:679, 1960
30. Schur PH, Austen KF: *Complement in the rheumatic diseases*. *Bull Rheum Dis* 22:666, 1971
31. Shalit IE, Wilske KR, Decker JL: *The*

occurrence of the mucocutaneous lesions of Reiter's syndrome ("keratosis blennorrhagica") in a patient with classical rheumatoid arthritis. *Arthritis Rheum* 7:177, 1964

32. Good AE: Reiter's disease, ankylosing spondylitis and rheumatoid arthritis occurring within a single family. *Arthritis Rheum* 14:753, 1971

33. Marche J: L'atteinte des articulations sacroiliaques dans le syndrome dit de Reiter. *Rev Rhum* 17:449, 1950

34. Ford DK: Natural history of arthritis following venereal urethritis. *Ann Rheum Dis* 12:177, 1953

35. Bradford EH: Ankylosis of the spine; three cases following rheumatism, two being of gonorrheal origin. *Ann Anat Surg* 7:279, 1883

36. Schilling F, Gamp A, Schackerl M: Das Reiter-Syndrom und seine Beziehungen zur Spondylitis ankylopoetica. *Ztschr Rheumaforschung* 24:342, 1965

37. Sairanen E, Paronen I, Mahonen H: Reiter's syndrome: a follow-up study. *Acta Med Scand* 185:57, 1969

38. McEwen C, DiTata D, Lingg C, et al: Ankylosing spondylitis and spondylitis accompanying ulcerative colitis, regional enteritis, psoriasis, and Reiter's disease. *Arthritis Rheum* 14:291, 1971

39. Hart RD: The ankylosing spondylopathies. *Clin Orthop* 74:7, 1971

40. Sholkoff SD, Gleckman MG, Steinbach HL: The radiographic pattern of polyarthritis in Reiter's syndrome. *Arthritis Rheum* 14:551, 1971

41. Lockie GN, Hunder GG: Reiter's syndrome in children. *Arthritis Rheum* 14:767, 1971

42. Ravin JG: Reiter's syndrome in children. A sequel to traveler's diarrhea. *J Ped Ophthal* 9:87, 1972

43. Lawrence J: A family study of Reiter's disease. Paper read to the Medical Society for the Prevention of Venereal Disease, 1965, cited by Wright V: The arthritis of ulcerative colitis, Reiter's disease and Behcet's syndrome, in Hill, AGS (ed): *Modern Trends in Rheumatology*. Vol 1. New York, Appleton-Century-Crofts, 1966, pp 342

44. White SH, Newcomer VD, Mickey MR, et al: Disturbance of HL-A antigen frequency in psoriasis. *New Eng J Med* 287:740, 1972

45. McCormack WM, Braun P, Lee YH, et al: The genital mycoplasmas. *New Eng J Med* 288:78, 1973

46. Dawson CR, Schachter J, Ostler HB, et al: Inclusion conjunctivitis and Reiter's syn-

drome in a married couple. *Arch Ophthal* 83:300, 1970

47. Grady GF, Keusch GT: Pathogenesis of bacterial diarrhea. *New Eng J Med* 285:831, 1971

48. Manson-Bahr PH: *The Dysenteric Disorders*. London, Cassel, 1939, p 71

49. Davies NE, Haverty JR, Boatwright M: Reiter's disease associated with Shigellosis. *South Med J* 62:1011, 1969

50. Graby H, Graby A: Syndrome de Fiesinger-Leroy avec polyneurite. *Cah Med* 4:93, 1949

51. Solem JH, Lassen J: Reiter's disease following *Yersinia enterocolitica* infection. *Scand J Infect Dis* 3:83, 1971

52. Engleman, EP: Psoriatic arthritis and Reiter's syndrome. *Postgrad Med* 51:79, 1972

53. Buchanan RF, Willkens RF: Arthritis after jejunio-ileostomy. *Arthritis Rheum* 15:644, 1972

54. Olhagen B: Chronic uro-polyarthritis in males. *Acta Med Scand* 168:339, 1960

55. Ford DK: Reiter's syndrome. *Bull Rheum Dis* 20:588, 1970

56. Popert AJ, Gill AJ, Laird SM: A prospective study of Reiter's syndrome. *Br J Ven Dis* 40:160, 1964

57. Mallory TB: Cabot case number 22141. *New Eng J Med* 214:693, 1936

58. Mallory TB: Cabot case number 22142. *New Eng J Med* 214:693, 1936

59. Clark WS, Kulka JP, Bauer W: Rheumatoid aortitis with aortic regurgitation. An unusual manifestation of rheumatoid arthritis (including spondylitis). *Am J Med* 22:580, 1957

60. Marquis Y, Richardson JB, Richie AC, et al: Idiopathic medial aortopathy and arteriopathy. *Am J Med* 44:939, 1968

61. Ansell BM, Bywaters EGL, Doniach I: The aortic lesion of ankylosing spondylitis. *Br Heart J* 20:507, 1958

62. Toone EC, Jr, Pierce EL, Henningar GR: Aortitis and aortic regurgitation associated with rheumatoid spondylitis. *Am J Med* 26:255, 1959

63. Duvernoy WFC, Schatz J: Rheumatoid spondylitis associated with aneurysmal dilatation of the entire thoracic aorta. *Henry Ford Hosp Med Bull* 14:309, 1966

64. Ball GV, Hathaway B: Ankylosing spondylitis with widespread arteritis. *Arthritis Rheum* 9:737, 1966

65. Somer T, Siltanen P: Aneurysm of the descending thoracic aorta, amyloidosis and renal carcinoma in a patient with ankylosing spondylitis. *Am J Med* 49:408, 1970



66. Sobin LH, Hagstrom JWC: Lesions of cardiac conduction tissue in rheumatoid aortitis. *JAMA* 180:1, 1962
67. Good AE: Spondylitic heart disease: a case report. *U Mich Med Center J* 34:272, 1968
68. Graham DC, Smythe HA: The carditis and aortitis of ankylosing spondylitis. *Bull Rheum Dis* 9:171, 1958
69. Macmahon HE, Magendantz H, Brugsch HG, et al: Clinicopathologic conference. *Bull Tufts-New Eng Med Center* 1:50, 1955
70. Schilder DP, Harvey WP, Hufnagel CA: Rheumatoid spondylitis and aortic insufficiency. *New Eng J Med* 255:11, 1956
71. Castleman B: Case records of the Massachusetts General Hospital (Case 42321). *New Eng J Med* 255:292, 1956
72. Valaitis J, Pilz CG, Montgomery MM: Aortitis with aortic valvular insufficiency in rheumatoid arthritis. *Arch Path* 63:207, 1957
73. Bowers D: Aortic valvular insufficiency associated with rheumatoid arthritis. *Can Med J* 79:560, 1958
74. Crow RS: Aortic incompetence in ankylosing spondylitis. *Br Med J* 2:271, 1960
75. Hope-Ross P, Bien EJ, Palladino VS, et al: Rheumatoid aortitis: report of an unusual case. *Ann Intern Med* 52:682, 1960
76. Reed WB, Becker SW, Rohde R, et al: Psoriasis and arthritis. *Arch Derm* 83:541, 1961
77. Cavailles J: L'insuffisance aortique de la spondylarthrite ankylosante. *Coeur Med Interne* 6:425, 1967
78. Weed CL, Kulander BG, Mazzarella JA, et al: Heart block in ankylosing spondylitis. *Arch Intern Med* 117:800, 1966
79. Shean CS, Ming Liu A: Complete heart block and aortic insufficiency in rheumatoid spondylitis. *Am J Card* 23:888, 1969
80. Polley HF, Slocumb CH: Rheumatoid spondylitis: a study of 1035 cases. *Ann Intern Med* 26:240, 1947
81. Master AM, Jaffe H: Electrocardiographic evidence of cardiac involvement in acute disease. *Proc Soc Exp Biol (NS)*. 31:931, 1934
82. Trier M: On Reiter's syndrome with special reference to cardiac complications and familial occurrence of the syndrome. *Acta Med Scand (Suppl)* 239, 123, 1950
83. Csonka GW, Litchfield JW, Oates JK: Cardiac lesions in Reiter's disease. *Br Med J* 1:243, 1961
84. Jacquet L, Ghika: Sur un cas d'arthroblennorrhagisme avec troubles trophiques. *Bull Soc Med Hop Paris* 111, 14:93, 1897
85. Schuermann H: Reitersche Krankheit mit Endokarditis und Myokarditis. *Med Clin* 39:327, 1943
86. Pirani CL, Bennett GA: Rheumatoid arthritis: report of three cases progressing from childhood and emphasizing certain systemic manifestations. *Bull Hosp Joint Dis* 12:335, 1951
87. Gamp A: Zur Klinik und Prognose der Reiter'schen Krankheit. *Munch Med Wochenschr* 98:334, 1956
88. Heberden Society, Clinical Meeting, Feb. 26, 1960. *Ann Rheum Dis* 19:183, 1960
89. Rodnan GP, Benedek TG, Shaver JA, et al: Reiter's syndrome and aortic insufficiency. *JAMA* 189:889, 1964
90. Dechelotte J: Les endocardites au cours du syndrome de Fiessinger-Leroy-Reiter. *Coeur Med Interne* 5:81, 1966
91. Bontoux D, Bastin R, Coste F: Spondylarthrite ankylosante (syndrome oculo-urethro-synovial?) insuffisance aortique et endocardite bacterienne. *Rev Rhum* 34:592, 1967
92. Siguier F, Godeau P, Herreman G, et al: Insuffisance aortique, spondylarthrite ankylosante et syndrome de Fiessinger-Leroy-Reiter. A propos d'une observation anatomo-clinique. *Coeur Med Interne* 9:457, 1970
93. Cluff JM: Spinal bridging and carditis in Reiter's disease. *Ann Rheum Dis* 30:171, 1971
94. Block SR: Reiter's syndrome and acute aortic insufficiency. *Arthritis Rheum* 15:218, 1972
95. Paulus HE, Pearson CM, Pitts W: Aortic insufficiency in five patients with Reiter's syndrome. A detailed clinical and pathological study. *Am J Med* 53:464, 1972
96. Lever WF, Crawford GM: Keratosis blennorrhagica without gonorrhoea (Reiter's disease). *Arch Derm Syph* 49:389, 1944
97. Mori K, Zak FG: A case of Reiter's syndrome with complete autopsy. *Acta Derm Venereol (Stockh.)* 40:362, 1960
98. Denko CW, von Haam E: Reiter's syndrome. Clinico-pathological study of a fatal case. *JAMA* 186:632, 1964
99. Dixon ASJ: "Rheumatoid arthritis" with negative serological reaction. *Ann Rheum Dis* 19:209, 1960
100. Kulka JP: Proceedings, annual meeting of the American Rheumatism Association, June 20-21, 1958, San Francisco. Discussion of papers 2 and 3. *Arthritis Rheum* 2:31, 1959
101. Wilke G: Polyneuritiden nach chronischer Enterocolitis, insbesondere nach Ruhr. *Dtsch Med Wochenschr* 69:443, 1943
102. Oates JK, Hancock JAH: Neurological symptoms and lesions occurring in the

course of Reiter's disease. *Am J Med Sci* 238:79, 1959

103. Catterall RD, Rooney KJ, Kirby B: Neuralgic amyotrophy in Reiter's disease. *Br J Vener Dis* 41:62, 1965

104. Kersley GD: Degenerative rheumatoid changes. *J Bone Joint Surg* 36B:238, 1954

105. Auckland G: Keratoderma blennorrhagica. *Br J Vener Dis* 27:143, 1951

106. Metz J, Metz G: Zur Therapie der schweren Verlaufsform v. Reiterschen Krankheit. *Munch Med Wochenschr* 40:1278, 1971

107. Rost G: Seltene Komplikation der Gonorrhoe: hyperkeratotische Exantheme und universelle, ankylosierende Arthritis. *Derm Ztschr* 18:233, 1911

108. Csonka G: *Br Med J*, in press

109. Zewi M: Morbus Reiteri. *Acta Ophthalmol (Kbh)* 25:47, 1947

110. Lindsay-Rea R: A case of Reiter's disease. *Trans Ophthalmol Soc U K* 67:241, 1947

111. Usseglio G, Zancan B: Il morbo di Reiter. *Arch Sci Med* 69:79, 1940

112. Lauda E: Zur Klinik und Therapie des Reiterschen Syndroms *Wien Klin Wochenschr* 58:55, 1946

113. Lafon R, Pages P, Roux J, Temple JP, Minvielle J: Syndrome de Fiessinger-Leroy-Reiter, avec infiltrats pulmonares labiles et hémiplégie regressive. Organismes L dans les sécrétions uretrales. *Rev Neurol* 92:611, 1955

114. Mavioglu H: Fiessinger-Leroy-Reiter's syndrome. *Missouri Med* 55:228, 1958

115. Csonka G: Involvement of the nervous system in Reiter's syndrome. *Ann Rheum Dis* 17:334, 1958

116. Larson S: A report on four women. *Acta Rheum Scand* 17:295, 1971

117. Klempel K: Zentralnervöse Ausfälle beim Reiter-Syndrom. *Schweiz Arch Neurol Neurochir Psychiatr* 106:283, 1970

118. Atwater EC: The lifelong sickness of Francis Parkman 1823-1893. *Bull Hist Med* 41:413, 1967

119. Hall WH, Finegold S: Study of 23 cases of Reiter's syndrome. *Ann Intern Med* 38:533, 1953

120. Boland EW, Headley NE, Hench PS: The cerebrospinal fluid in rheumatoid spondylitis. *Ann Rheum Dis* 7:196, 1948

121. Bechterew W von: Neue Beobachtungen und pathologisch-anatomische Untersuchungen Über Steifigkeit der Wirbelsäule. *Dtsch Z Nervenheilk* 15:44, 1899

122. Cruickshank B: Pathology of ankylosing spondylitis. *Clin Orthop* 74:43, 1971

123. Misra PC, Hay GG: Encephalitis presenting as acute schizophrenia. *Br Med J* 1:532, 1971

124. Short CL, Bauer W, Reynolds WE: Rheumatoid Arthritis. Cambridge, Harvard Univ Pr, 1957

125. Baker AB: *Clinical Neurology*, ed. 2 New York, Hoeber-Harper, 1962, p 881

126. Swartz MN, Dodge PR: Bacterial meningitis. A review of selected aspects. General clinical features, special problems and unusual meningeal reactions mimicking bacterial meningitis (continued) *New Eng J Med* 272:898, 1965

127. Good AE: Reiter's disease and ankylosing spondylitis. *Acta Rheum Scand* 11:305, 1965