

SIMULTANEOUS, CONTRALATERAL HYPERNEPHROMA AND RENAL TRANSITIONAL CELL CARCINOMA

MICHAEL W. McDONALD, M.D.

JOHN W. KONNAK, M.D.

From the Department of Surgery, Section of Urology,
University of Michigan Medical Center, Ann Arbor, Michigan

ABSTRACT — *The second case of simultaneous, contralateral hypernephroma and renal transitional cell carcinoma is described. Methods of managing bilateral renal tumors are reviewed.*

Simultaneous, bilateral renal tumors are unusual occurrences, particularly when the histologic types differ. This report describes the second case of simultaneous, contralateral hypernephroma and renal transitional cell carcinoma.

Case Report

A fifty-five-year-old white man was admitted to an outside hospital with a two-month history of hematuria and right flank pain. Excretory urography with tomography was performed which showed a filling defect in the right renal pelvis and a mass in the lower pole of the left kidney (Fig. 1A). Arteriography was interpreted

as showing a vascular mass in the lower pole of the left kidney and a mass in the right renal pelvis supplied by small arterial vessels (Fig. 1B and C). An incidental finding was an abdominal aortic aneurysm below the renal arteries. Inferior venacavagram was normal. Ultrasonography demonstrated a mass lesion in the lower pole of the left kidney and an echo pattern in the right renal pelvis compatible with blood clot or tumor.

Because of a lack of facilities for hemodialysis, should this need arise, the patient was transferred to the University of Michigan. Upon arrival at our Center physical examination was unremarkable. Complete blood count revealed

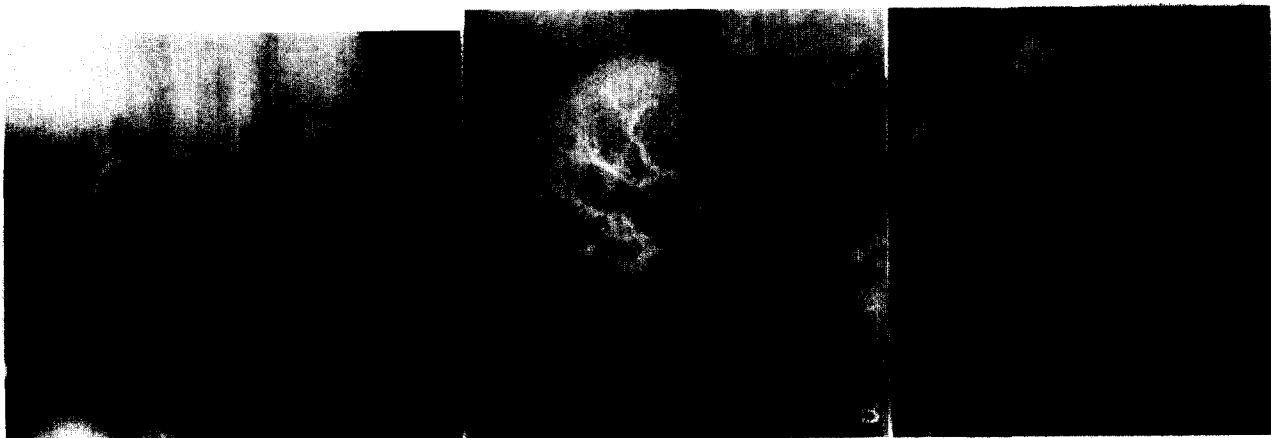

FIGURE 1. (A) Nephrotomogram showing defect in right renal pelvis and mass in lower pole of left kidney. (B) Arteriogram showing small arterial vessels supplying mass in right renal pelvis. (C) Vascular mass in lower pole of left kidney.

hematocrit of 39 and white blood cell count of 7,700/mm³. Serum electrolytes were normal. Serum creatinine was 1.0 mg., blood urea nitrogen 17 mg., calcium 8 mg., and bilirubin 0.9 mg. per 100 ml.; serum glutamic oxaloacetic transaminase 20 I.U., serum glutamic pyruvic transaminase 11 I.U., lactic dehydrogenase 125 I.U., and alkaline phosphatase 79 I.U. per milliliter. Urinalysis showed 5–10 red blood cells per high-power field. Chest x-ray film and barium enema were normal.

Cystoscopy was performed. The ureteral orifices and bladder mucosa were normal. A right ureteral catheter was placed to collect urine for cytologic examination. This was reported as urothelial atypia.

Right renal exploration was carried out through a flank incision with excision of the twelfth rib. The renal pelvis was approached posteriorly and opened. A mass was excised together with a large portion of the renal pelvis, and the pelvis was closed. During surgery the right kidney was isolated from surrounding tissues with a polyethylene drape. The right flank wound was then irrigated with sterile water. After closure of this incision the patient was placed in the supine position, and a transabdominal left radical nephrectomy was performed. There was no evidence of metastatic disease within the abdomen. Evaluation of the aorta revealed a 5-cm. fusiform aneurysm below the level of the renal vessels. Pathology report returned transitional cell carcinoma (grade II) of the right renal pelvis and hypernephroma of the left kidney, without evidence of extrarenal invasion.

Postoperatively the patient was anuric and became azotemic with serum creatinine reaching 13 mg./100 ml. A right retrograde ureteral catheter was placed on the fourth postoperative day. A hydronephrotic drip was obtained at this time and serum creatinine fell rapidly. The ureteral catheter was removed on the eighth postoperative day, and the urine output remained good with serum creatinine stable at 2.1 mg./100 ml. The transient anuria was attributed to obstruction caused by surgical edema of the right renal pelvis or a blood clot. An excretory urogram obtained after discharge was normal except for minimal surgical distortion of the renal pelvis (Fig. 2).

Comment

Jozsi *et al.*¹ reported the first patient with simultaneous, contralateral renal transitional

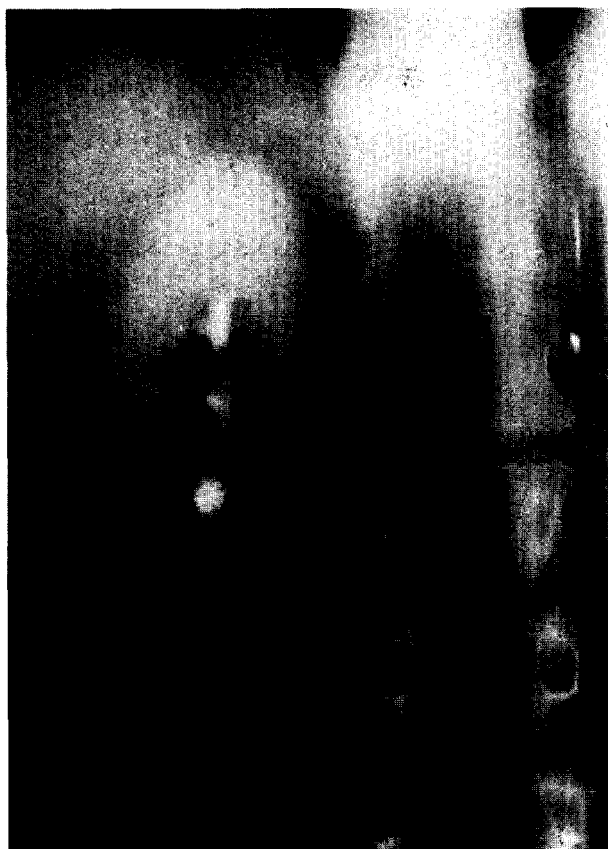


FIGURE 2. Postoperative nephrotomogram with minimal surgical distortion of right renal collecting system.

cell carcinoma and hypernephroma, although Villegas² mentioned an autopsy case. Our case is the second reported in a living patient.

Bilateral renal tumors of identical histology have been reported more frequently. This phenomenon has been described with hypernephroma,³⁻¹² transitional cell carcinoma,¹³⁻¹⁷ Wilms tumor,^{18,19} squamous cell carcinoma,²⁰ angiomyolipoma,²¹ and metastatic disease.^{22,23} The incidence of bilaterality has been estimated at 1.8 per cent in hypernephroma,⁸ 3.5 per cent in transitional cell carcinoma,¹⁴ and 3-10 per cent in Wilms tumor.¹⁹ Von Hippel-Lindau disease is associated with bilateral hypernephroma^{24,25} and tuberous sclerosis with bilateral angiomyolipoma.²¹

Reported therapy has varied. Finkbeiner, Moyad, and Herwig³ reported 3 patients with bilateral simultaneous hypernephroma, each of whom were treated with unilateral radical nephrectomy and contralateral partial nephrectomy. McLoughlin¹³ described a case of simultaneous bilateral renal pelvis transitional cell carcinoma managed with unilateral nephrectomy and contralateral benchwork excision of

tumor with subsequent autotransplantation. Stroup *et al.*,⁴ have recommended bilateral nephrectomy with hemodialysis and eventual transplantation as the best means for enhancing survival. Ehrlich *et al.*¹⁸ described bilateral Wilms tumor treated with bilateral nephrectomy and transplantation but stated that this should be a last resort only if other methods of treatment were not possible. Williams supported this viewpoint.²⁶

In a situation as difficult as simultaneous bilateral renal malignancies, management must obviously be individualized. In the case reported by Jozsi *et al.*,¹ the transitional cell carcinoma was localized to the left upper pole calyceal system and was amenable to partial nephrectomy through a transabdominal approach with contralateral radical nephrectomy. In the present case the transitional cell carcinoma was in the renal pelvis, and a flank approach was used to allow unobstructed access to this area. The alternative of transabdominal exploration with right nephrectomy and left partial nephrectomy was not chosen because it was thought that more renal parenchyma could be saved from the right kidney, and also because of the belief that a radical nephrectomy on the side of the usually more aggressive neoplasm, the hypernephroma, was indicated.

At the present time the most rational approach to simultaneous bilateral renal tumors would appear to consist of in situ partial nephrectomy for preservation of renal parenchyma, with resort to benchwork surgery or bilateral nephrectomy and transplantation only when the more conservative procedure cannot be done.

Addendum

A recurrence of transitional cell carcinoma of the right renal pelvis developed in this patient. He underwent right nephrectomy and is currently on hemodialysis.

Ann Arbor, Michigan 48109
(DR. KONNAK)

References

1. Jozsi BP, Wise HA, Quilter TN, and Evans W: Bilateral simultaneous kidney tumors of dissimilar cell type: a case report

with emphasis on operative approach, *J. Urol.* **116**: 655 (1976).

2. Villegas AC: Bilateral primary malignant renal tumors of dissimilar histogenesis, report of 2 cases and review of the literature, *ibid.* **98**: 450 (1976).

3. Finkbeiner A, Moyad R, and Herwig K: Bilateral simultaneously occurring adenocarcinoma of the kidney, *ibid.* **116**: 26 (1976).

4. Stroup RF, Shearer JK, Traurig AR, and Lytton B: Bilateral adenocarcinoma of the kidney treated by nephrectomy: a case report and review of the literature, *ibid.* **111**: 272 (1974).

5. Hollabaugh RS, Cheek RC, and Sellers KD: A surgical approach to bilateral hypernephroma using "benchwork" excision and autotransplantation, *Am. Surg.* **42**: 411 (1976).

6. Calne, RY: Treatment of bilateral hypernephromas by nephrectomy, excision of tumor and autotransplantation. Report of 3 cases, *Lancet* **2**: 1164 (1973).

7. York WN, and Mawn TJ: Aggressive surgical management of bilateral adenocarcinoma of the kidney, *Cancer* **31**: 1160 (1973).

8. Vermillion CD, Skinner DG, and Pfister RC: Bilateral renal cell carcinoma, *J. Urol.* **108**: 219 (1972).

9. Small MP, Anderson EE, and Atwill WH: Simultaneous bilateral renal cell carcinoma. Case report and review of the literature, *ibid.* **100**: 8 (1968).

10. Krumbach RW, and Ansell JS: Partial resection of the right kidney and radical removal of the left kidney in a patient with bilateral hypernephroma, *Surgery* **45**: 585 (1959).

11. Wickham, JEA: Conservative renal surgery for adenocarcinoma. The place of bench surgery, *Br. J. Urol.* **47**: 25 (1975).

12. Beraha D, Block N, and Politano V: Simultaneous surgical management of bilateral hypernephroma: an alternative therapy, *J. Urol.* **115**: 648 (1976).

13. McLoughlin MC: The treatment of bilateral synchronous renal pelvic tumors with bench surgery, *ibid.* **114**: 463 (1975).

14. Bogaard TP, and Goldstein AMB: Bilateral transitional cell carcinoma of the renal pelvis with unilateral non-functioning kidney, *ibid.* **113**: 565 (1975).

15. Harvard BM, and Evans JS: Simultaneous bilateral transitional cell carcinoma of the renal pelvis, *ibid.* **91**: 14 (1964).

16. Colston JAC Jr.: Bilateral papillary carcinoma of renal pelvis, *ibid.* **83**: 355 (1960).

17. Carroll G: Bilateral transitional cell carcinoma of the renal pelvis, *ibid.* **93**: 132 (1965).

18. Ehrlich R, Goldman R, and Kaufman JJ: Surgery of bilateral Wilms tumors: the role of renal transplantation, *ibid.* **111**: 277 (1974).

19. DeLorimier AA, Belzer FO, Kountz SL, and Kushner J: Treatment of bilateral Wilms' tumor, *Am. J. Surg.* **122**: 275 (1971).

20. Thompson IM, and Schneider J: Bilateral squamous cell carcinoma of the kidney, *J. Urol.* **79**: 807 (1958).

21. Waldbaum RS, Marshall V, Muecke EC, and Watson R: Tuberculous sclerosis with bilateral angiomyolipomas of the kidney: case report with 8 year followup, *ibid.* **106**: 180 (1971).

22. Zincke H, and Furlow WL: Metastatic squamous cell epithelioma of the kidney: report of a case of bilateral involvement and review of the literature, *ibid.* **109**: 971 (1973).

23. Newman LB, Morgan TE, Bucy TG, and Wise L: Choriocarcinoma and bilateral renal metastases, *Urology* **5**: 658 (1975).

24. Mullin EM, White RD, Peterson LJ, and Paulson DF: Bilateral renal cancers in von Hippel-Lindau disease, *ibid.* **7**: 475 (1976).

25. Kaplan C, Sayre GP, and Greene LF: Bilateral nephrogenic carcinoma in Lindau-von Hippel's disease, *J. Urol.* **86**: 36 (1961).

26. Williams GM: Treatment of bilateral cancer of the kidney by radical excision and transplantation, *ibid.* **111**: 271 (1974).