

Giant Arteriovenous Malformation of the Vein of Galen in an Adult

Keith L. Black, M.D. and Saeed M. Farhat, M.D.

Department of Surgery, Section of Neurosurgery, University of Michigan and St. Joseph Mercy Hospital, Ann Arbor, Michigan

Black KL, Farhat SM. Giant arteriovenous malformation of the vein of Galen in an adult. *Surg Neurol* 1984;22:382-6.

A case of a large vein of Galen malformation in a 29-year-old man is presented. A two-staged surgical procedure, first with ligation of the feeding vessels, and followed later by thrombectomy, allowed successful surgical treatment of this lesion.

KEY WORDS: Vein of Galen, malformation; Thrombosis; Surgical ligation; Aneurysm

Vein of Galen aneurysms comprise less than 1% of all arteriovenous malformations [19]. The experience with these lesions suggest three distinctive clinical presentations: that of the neonate, that of the infant, and that of the older child or adult [11,13]. In neonates the initial presentation is typically that of congestive heart failure, and death secondary to congestive heart failure and myocardial infarction is the usual sequela despite heroic surgical and medical treatment [4]. Infants usually present with hydrocephalus, and older children or adults typically present with seizures, headaches, and symptoms of subarachnoid hemorrhage. The older the patient at the time of presentation the better the prognosis, primarily because of the absence of associated cardiac problems.

Less than fifty cases of vein of Galen malformations in adults are reported in the literature [1,7,9,13,14,20,21]. This report describes the presentation of a giant malformation of the vein of Galen in an adult and the surgical treatment of the lesion.

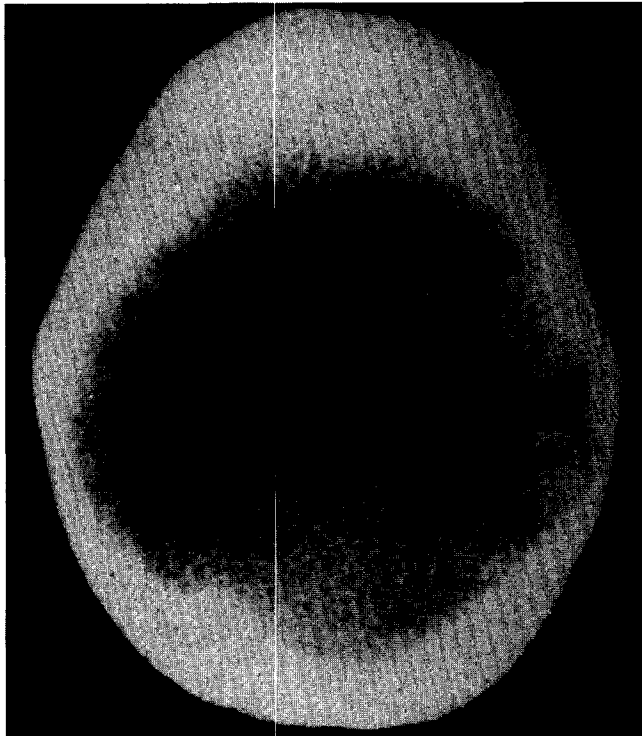
Case Report

A 29-year-old right-handed man presented on June 25, 1983, with a 9-month history of progressive headaches, difficulty seeing to his right at night, nausea, and vom-

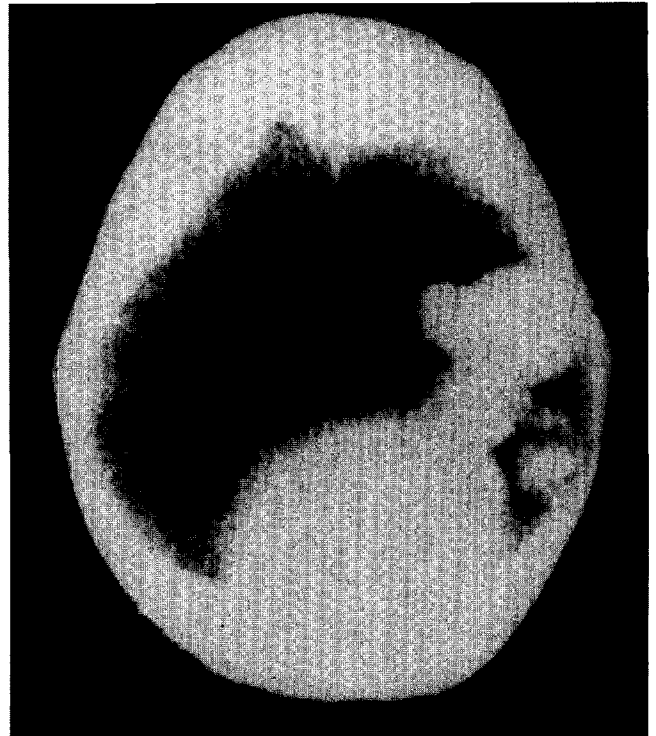
iting. Examination on admission revealed a right homonymous hemianopsia and bilateral papilledema. Babinski's sign was present on the right and his uvula deviated to the right. A bruit could be heard over the occipital area, louder on the right side. A computed tomography scan revealed a large enhancing mass in the posterior parietooccipital region containing small flecks of calcification and forward displacement of the lateral ventricles (Figure 1). Arteriogram showed a large vein of Galen malformation in the left occipital parietal area supplied by two enlarged posterior temporal branches of the left middle cerebral artery (Figure 2). Both anterior cerebral arteries were supplied by the right internal carotid artery and the posterior cerebral arteries were hypoplastic.

A two-staged surgical procedure was planned. First, the two feeding vessels would be ligated to allow the malformation to thrombose; later an elective thrombectomy would be performed. On July 6, 1983, the patient was brought to the operating room and a temporal parietal incision was used to approach the malformation. The bone was extremely thin above the mastoid and external auditory canal and slightly discolored. The cortex in the parietal area had a yellowish discoloration suggestive of previous bleeding. Two large branches of the middle cerebral artery could be seen emptying into the malformation (Figure 3). When temporary clips were placed on these vessels, the malformation became softer and an arteriolized vein adjacent to the lesion immediately became venous in nature. The two feeding vessels were doubly ligated. After the operation the patient was alert and oriented. Thirty-six hours later he had a seizure, became unresponsive, and had a respiratory arrest. He was intubated, hyperventilated, and given intravenous mannitol and Lasix. His level of consciousness improved somewhat. A computed tomography scan showed a decrease in the size of the malformation, edema, and a left to right shift from the midline (Figure 4). An arteriogram showed partial thrombosis of the vessels feeding the malformation, and no filling of the malformation was evident (Figure 5). The patient was taken back to the operating room and

Address reprint requests to: Keith L. Black, M.D., Section of Neurosurgery, University of Michigan Hospital, 1405 E. Ann Street, Ann Arbor, Michigan 48109.

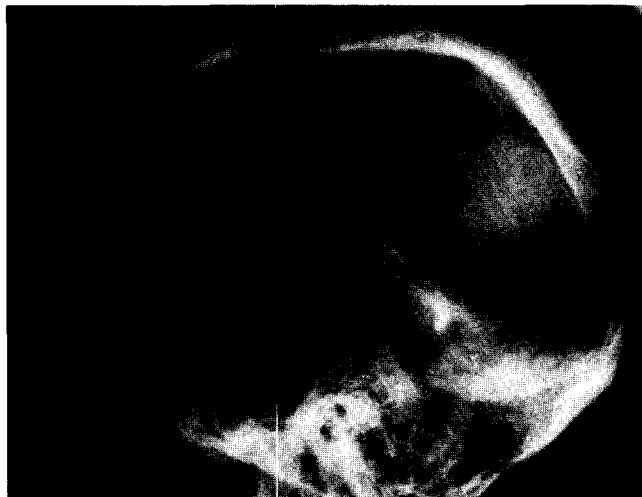

A

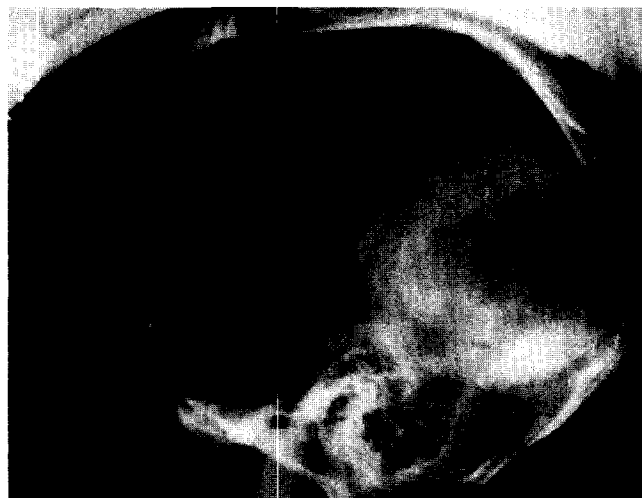

B

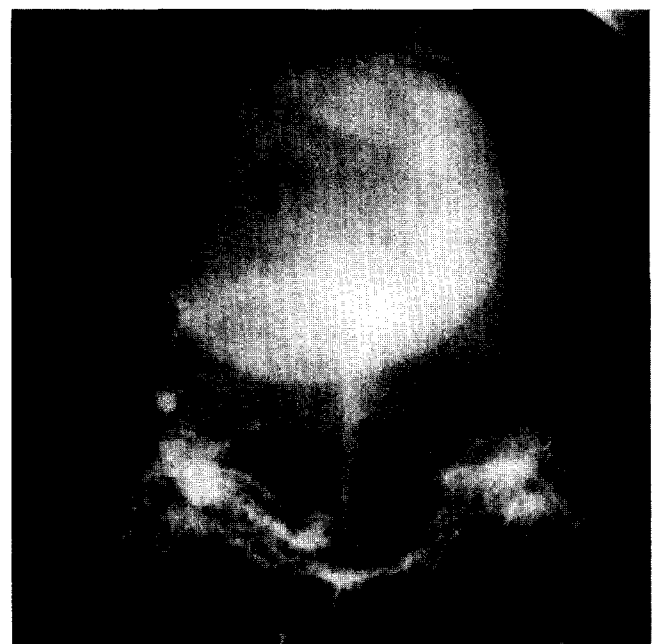
Figure 1. (A) Computed tomography without contrast-medium enhancement of vein of Galen malformation before first craniotomy. (B) Computed tomography of malformation with contrast-medium enhancement.



A



B



C

Figure 2. Carotid angiography demonstrating vein of Galen malformation. (A) Arterial phase, lateral view. (B) Venous phase, lateral view. (C) Anteroposterior view.




Figure 3. (Above) Operative photograph of vein of Galen malformation. Two enlarged feeding vessels (FV) from the middle cerebral artery are shown. The wall of the aneurysmal dilatation (AD) is seen, and the adjacent arterIALIZED vein (V) is now venous in nature after ligation of feeding vessels. Area of yellowish discoloration (Y) is suggestive of previous bleeding.

the tense wall of the aneurysmal dilatation was opened. Approximately 100 mL of gelatinous blood was evacuated, and good decompression was achieved. Fresh bleeding was evident from an opening into the wall of the aneurysmal dilatation near the level of the petrous bone. A clip was placed across this opening through the aneurysmal cavity. After the operation a right hemiparesis was present, but this improved over 3 weeks. Repeat angiography and computed tomography scan were consistent with thrombosis of the malformation (Figures 6 and 7). When last seen on October 10, 1983, he had

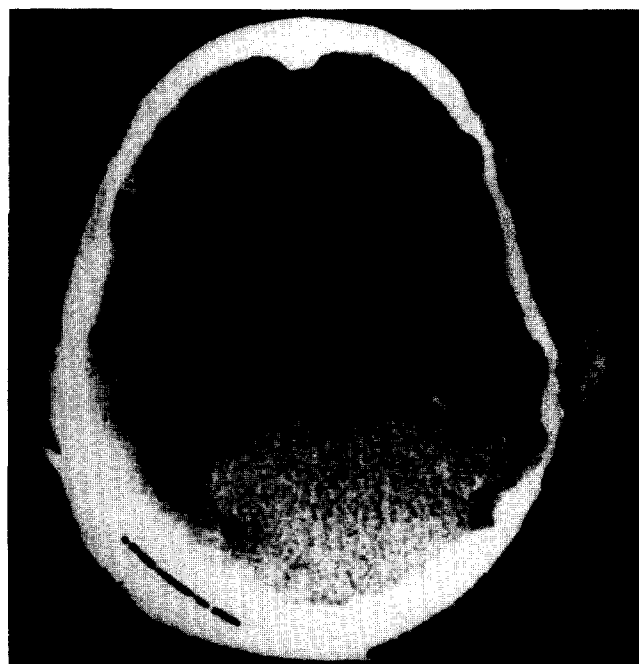

Figure 4. (Right) Computed tomography seen without contrast-medium enhancement 36 hours after first craniotomy, which shows decrease in the size of the malformation. Surrounding edema is evident and a left-to-right shift from the midline is present.

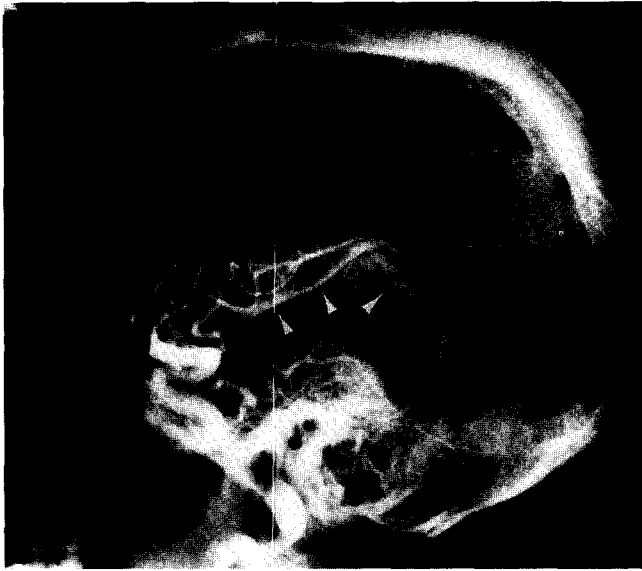

Figure 5. Carotid angiography 36 hours after first craniotomy. Partial thrombosis of the vessels previously supplying the malformation is evident (arrows). Flow is increased in left middle cerebral branches surrounding the malformation. There is no filling of the malformation demonstrated.

a slight pronator drift on the right and extinction of sensation on the right with double simultaneous stimulation. The right homonymous hemianopsia remained. His papilledema was disappearing but he had some evidence of optic atrophy. His neurological examination was otherwise normal. He has no further complaints of headache or nausea.

Figure 6. Carotid angiography 2 weeks after second craniotomy. No filling of malformation is seen.

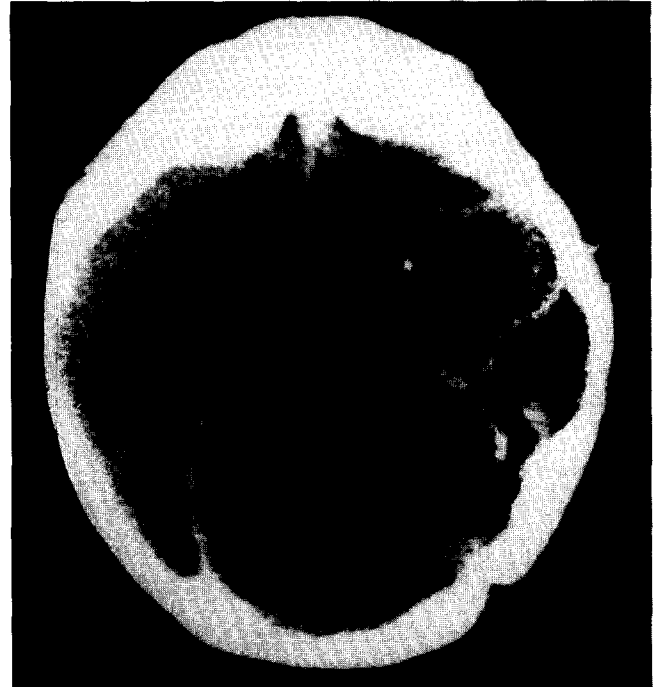
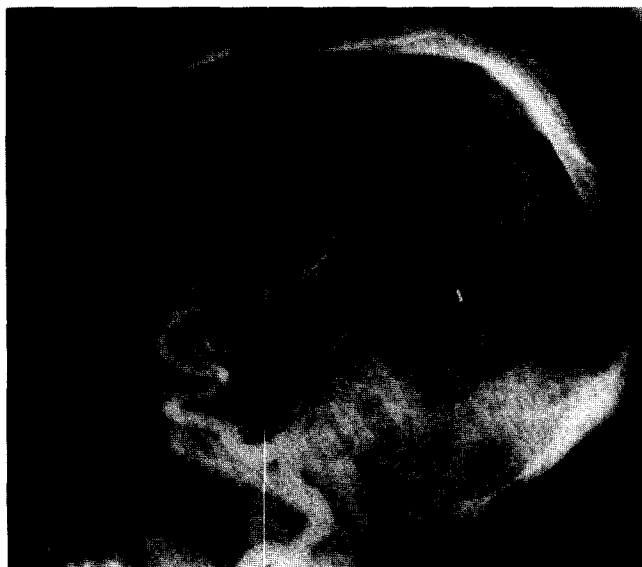
Figure 7. Computed tomography with contrast-medium enhancement 2 months after craniotomy. The malformation is completely thrombosed. Some displacement of the falx is still present.

Discussion

Less than 25% of reported arteriovenous malformations involving the Galenic system have been in older children and adults. Hydrocephalus, which is most common in infants, is reported in only 30% of adult cases [13]. Intracranial bruits, common in infants, are rarely heard in neonates or adults [11].

The arterial supply to vein of Galen malformations results from persistent channels during embryologic development [9,16,18]. The posterior cerebral arteries, posterior choroidal arteries, and thalamic perforating arteries usually supply the malformation, but supply from the anterior circulation is sometimes reported. Multiple arterial feeders supplying the malformation, which are usually the rule in neonates [10], and which make operation extremely difficult [4,5], are uncommon in adults.

In this case, only a few flecks of calcification could be identified in the malformation. Rimlike calcification is common, however, in adult vein of Galen malformations as a result of the chronic increase in venous pressure [21]. Calcification in younger patients is generally associated with thrombosis of the malformation.

Complete thrombosis at the time of diagnosis has permitted successful surgical excision in a few reported cases [7,8,12,17]. Thrombosis of the malformation subsequent to ligation of the feeding vessels has been reported in one case [6]. In the present case a two-staged

surgical approach was planned. First, the feeding vessels would be ligated, allowing the malformation to thrombose, and later an elective thrombectomy would be performed.

Unfortunately, our patient developed vasogenic edema after ligating the feeding vessels to the giant malformation and deteriorated 36 hours after the operation. Cerebral vessels surrounding a large arteriovenous malformation adjust to the chronic state of low perfusion pressure secondary to the sump effect of the malformation. When the feeding arteries are occluded, the surrounding vasculature is subjected to a rapid increase in perfusion pressure to which it can no longer autoregulate. The cerebral capillaries become exposed to a high intravascular pressure, and vasogenic edema subsequently develops [15,22]. Due to the mass effect of the edema, the thrombectomy had to be performed on an emergent basis for decompression.

If resolution of symptoms has occurred after ligation of the feeding vessels with thrombosis of the malformation, thrombectomy is not required. If symptoms attributable to a mass lesion remain after thrombosis of the malformation, then thrombectomy with decompression can be an important adjunct to successful surgical treatment of these lesions.

References

1. Agee OF, Greer M. Anomalous cephalic venous drainage in association with aneurysm of the great vein of Galen. *Radiology* 1967;88:725-9.
2. Agee OF, Musella R, Tweed CG. Aneurysm of the great vein of Galen. Report of two cases. *J Neurosurg* 1969;31:346-51.
3. Alpers BJ, Forster FM. Arteriovenous aneurysm of great cerebral vein and arteries of circle of Willis. *Arch Neurol Psychiatry* 1945;54:181-5.
4. Amacher AL, Shillito J. The syndromes and surgical treatment of aneurysms of the great vein of Galen. *Neurosurg* 1973;39:89-98.
5. Boldrey E, Miller ER. Arteriovenous fistula (aneurysm) of the great cerebral vein (of Galen) and the circle of Willis. Report on two patients treated by ligation. *Arch Neurol Psychiatry* 1949;62:778-83.
6. Carson JV, Brooks BS, Gammal TE, Massey CE, Beveridge WD, Allen MB. Adult arteriovenous malformation of the vein of Galen: a case report with pre- and postoperative computed tomographic findings. *Neurosurg* 1980;7:495-8.
7. Coptly M, Bedard F, Turcotte JF. Successful removal of an entirely calcified aneurysm of the vein of Galen. *Surg Neurol* 1980;14:396-400.
8. Dean DF. Management of clotted aneurysm of the vein of Galen. *Neurosurg* 1981;8:589-92.
9. French LA, Peyton WT. Vascular malformations in the region of the great vein of Galen. *J Neurosurg* 1954;11:488-98.
10. Gagnon J, Boileau G. Anatomical study of an arteriovenous malformation drained by the system of Galen. *J Neurosurg* 1960;17:75-80.
11. Gold AP, Ransohoff J, Carter S. Vein of Galen malformation. *Acta Neurol Scand* 1964;40(suppl 11):5-31.
12. Heinz ER, Schwartz JF, Sears RA. Thrombosis in the vein of Galen malformation. *Br J Radiol* 1968;41:424-8.
13. Hoffman HJ, Chuang S, Hendrick EB, Humphreys RP. Aneurysms of the vein of Galen. Experience at the Hospital for Sick Children, Toronto. *J Neurosurg* 1982;57:316-22.
14. Litvak J, Yahr MD, Ransohoff J. Aneurysms of the great vein of Galen and midline cerebral arteriovenous anomalies. *J Neurosurg* 1960;17:945-54.
15. Luessenhop AJ, Ferraz FM, Rosa L. Estimate of the incidence and importance of circulatory breakthrough in the surgery of cerebral arteriovenous malformation. *Neurol Res* 1982;4:177-90.
16. O'Brien MS, Schechter MM. Arteriovenous malformations involving the Galenic system. *AJR* 1970;110:50-5.
17. Olin MS, Eltomey AA, Dunsmore RH, Roberts MP. Thrombosed vein of Galen aneurysm. *Neurosurg* 1982;10:258-62.
18. Padget DH. Development of cranial venous system in man, from viewpoint of comparative anatomy. *Contrib Embryol* 1957;36:81-140.
19. Perret G, Nishioka H. Report on the cooperative study of intracranial aneurysms and subarachnoid hemorrhage. Section VI. Arteriovenous malformations. *J Neurosurg* 1966;25:467-90.
20. Shealy CN, LeMay M. Unusual vascular malformations and the value of cerebral arteriography in patients with mass lesions. *J Neurosurg* 1964;21:461-8.
21. Siqueira EB, Murray KJ. Calcified aneurysms of the vein of Galen: report of a presumed case and review of the literature. *Neurochirurgia (Stuttg)* 1972;3:106-112.
22. Spetzler RF, Wilson CB, Weinstein P, Mehdorn M, Townsend J, Telles D. Normal perfusion pressure breakthrough theory. *Clin Neurosurg* 1978;25:651-72.