

soon after cardiac transplantation, but the recipient patients seldom show a postoperative precordial murmur attributable to valve dysfunction. This is not surprising, because mild forms of valvular regurgitation detected by Doppler are often clinically inaudible.⁵ Overt signs of tricuspid regurgitation and right ventricular failure were observed in 2 patients with residual postoperative pulmonary hypertension of moderate degree. This minor form of multivalvular regurgitation is usually transient; the abnormalities detected in the 4 cardiac valves tend to disappear during the first 3 months.

The pathophysiology of such multivalvular regurgitation is unclear. Despite the anecdotal description of valve infiltration in severe forms of cardiac rejection leading to death,⁷ we found no relation between early cardiac rejection detected by endomyocardial biopsy and presence or severity of valvular regurgitation (Table I). In some patients rejection developed when valvular regurgitation had disappeared, and detection of regurgitation was not necessarily associated with the presence of rejection. It is uncertain if more severe forms of rejection can lead to valve dysfunction. Neither can changes in left ventricular function or dilatation account for transient valvular regurgitation. There was a correlation between calculated left ventricular mass and the presence of valvular regurgitation. Absolute left ventricular mass is often increased at 1 to 2 weeks after cardiac transplantation, irrespective of the

presence or absence of rejection, and there is a gradual reduction of calculated left ventricular weight thereafter (Table I). We believe that early postoperative increased left ventricular mass is due to cardiac edema related to both manipulation and transport of the donor heart, and in fact myocardial edema is systematically seen in the first few cardiac biopsies performed. Although not detectable by ultrasound, mild edema of the cardiac valves or papillary muscles may be the cause of these transient valve abnormalities, and its reabsorption would normalize valve function. The low reabsorption rate of myocardial edema could be due to the lack of cardiac lymphatic drainage.

References

1. Krayenbuehl HP, Jenni R. The impact of ultrasound Doppler studies on clinical cardiology. A critical appraisal. *Eur Heart J* 1985;6:96-104.
2. Ballester M, Pons G, Obrador D, Carreras F, Cladellas M, Abadal ML, Amengual MJ, Bonnín O, Padró JM, Arís A, Caralps JM. Ciclosporina en el trasplante cardíaco: un tratamiento en evolución. *Med Clin (Barc)*, 1986; 86:600-603.
3. Billingham ME. Some recent advances in cardiac pathology. *Hum Pathol* 1979;10:367-386.
4. Devereux RB, Reichek N. Echocardiographic determination of left ventricular mass in man. Anatomic validation of the method. *Circulation* 1977;55: 613-618.
5. Pons-Lladó G, Carreras-Costa F, Ballester-Rodés M, Augé-Sampera JM, Crexells-Figueras C, Oriol-Palou A. Pulsed Doppler patterns of left atrial flow in mitral regurgitation. *Am J Cardiol*, 1986;57:806-810.
6. Hatle L, Angelsen B. *Doppler Ultrasound in Cardiology*. Philadelphia: Lea & Febiger, 1985:97.
7. Rose AG, Uys CJ. Pathology of acute rejection. In: Cooper DKC, Lanza RP, eds. *Heart Transplantation*. Lancaster, England: MTP Press Ltd., 1984:157-176.

Potential for Reversibility of Pulmonary Vascular Obstructive Disease in Children After Cardiac Transplantation

DOUGLAS M. BEHRENDT, MD
DENNIS CROWLEY, MD
KAREN UZARK, RN, MS

Patients with pulmonary vascular obstructive disease (PVOD) are usually not considered candidates for orthotopic cardiac transplantation, because the normal donor's right ventricle may be unable to function because of an acute increase in afterload, especially in the postischemic situation of the arrested and transported donor heart. The accepted guideline is that pulmonary vascular resistance (PVR) must be 8 Wood units (mm Hg/liters/min) or lower during maximal medical management.^{1,2} Patients whose PVR is between 4 and 8 Wood units are marginal candidates. Combined heart-lung transplantation or heterotopic

cardiac transplantation is generally believed to be necessary when the PVR is 8 units. However, among children with a variety of congenital defects, PVOD is often reversible after correction, especially when correction is performed at a young age. This was the case in the patient described herein whose cardiac transplantation was successful despite a PVR of nearly 13 Wood units.

A 14-year-old, 36-kg girl was admitted because of easy fatigability and dyspnea. At age 3 years a patent ductus arteriosus had been ligated and at age 12 a sequential pacemaker inserted because of complete heart block and increasing symptoms. During the next year, symptoms of congestive heart failure worsened and mitral regurgitation appeared. Medications included digoxin, aldactazide and Nitroderm®. In 1984, she sustained a cerebrovascular accident due to an embolus from a mural thrombus in her left ventricle. She had good neurologic recovery but became essentially bedridden because of her cardiomyopathy.

Cardiac catheterization was performed on February 20, 1985, and showed severe left ventricular dysfunction, mitral regurgitation and pulmonary hypertension (Table I). The PVR of 12.9 Wood units in room air appeared to preclude orthotopic cardiac transplantation. Addition of nitroprusside did not lower the resistance measured. Graded doses of dobutamine with and without added oxygen were administered,

From the Departments of Surgery and Pediatrics, University of Michigan, Ann Arbor, Michigan 48109. Manuscript received February 10, 1986; revised manuscript received April 8, 1986, accepted April 9, 1986.

TABLE I Right Heart Catheterization Data Before and After Cardiac Transplantation

	PAP (mm Hg)		Mean PWP (mm Hg)	CO (liters/min)	PR (liters/min/mm Hg)
	S/D	Mean			
Before Transplantation*					
Date					
9/83	45/20	28	18	2.9	6.9
2/85	85/57	65	40	2.8	12.9
*2/85	74/60	54	34	3.0	6.6
Meds + O ₂					
After Transplantation (May 85)					
Week					
1	62/22	35	17	2.8	6.4
2	58/21	32	17	4.5	6.0
3	64/18	41	17	2.8	8.5
4	60/36	44	16	3.5	8
6	55/20	35	11
8	49/23	34	12	4.4	5
9	45/20	30	9	4.3	4.9
10	46/18	30	10	4.3	4.6
12	41/17	26	12	3.3	4.2
14	40/16	25	11	3.15	4.4
17	36/16	24	9	3.2	4.7
19	32/16	26	11	3.7	4.0
21	42/16	30	8	4.1	5.3

* Pretransplantation catheterization data obtained during sequential pacing; posttransplantation data obtained during sinus rhythm.

† Medications: digoxin, captopril, Nitroderm®, Lasix®, dobutamine (15 $\mu\text{g}/\text{kg}/\text{min}$), and 93% FIO₂.

CO = cardiac output; Meds = medications; PAP = pulmonary artery pressure; PR = pulmonary resistance; PWP = pulmonary wedge pressure.

and the optimal result was achieved with 15 $\mu\text{g}/\text{kg}/\text{min}$ of dobutamine during 93% oxygen inhalation, which decreased the PVR to 6.6 Wood units (Table I).

Because of her severe and increasing symptoms and her young age, orthotopic cardiac transplantation was performed on May 10, 1985. A 55-kg onsite donor was used and the ischemic time was 84 minutes. An extracorporeal membrane oxygenator was prepared for postoperative right ventricular support if needed. Her postoperative course, however, was uncomplicated. She was initially treated with dobutamine (5 $\mu\text{g}/\text{kg}/\text{min}$), isoproterenol (0.1 $\mu\text{g}/\text{kg}/\text{min}$) and nitroglycerin (4 $\mu\text{g}/\text{kg}/\text{min}$), and arterial PO₂ was maintained above 100 torr. Pulmonary artery systolic pressure was 36 to 50 mm Hg during the first day with simultaneous arterial systolic pressure between 116 and 136 mm Hg. She was extubated 12 hours postoperatively but maintained on a FIO₂ of 0.40. Dobutamine was discontinued on the second postoperative day. Therapy with oral hydralazine and captopril was begun on the second day. During this interval the pulmonary artery systolic pressure remained 45 to 55 mm Hg with a simultaneous arterial systolic pressure of 108 to 152 mm Hg. She was discharged on the 20th postoperative day with cyclosporine, prednisone, Procardia®, hydralazine, captopril and hydrochlorothiazide. Subsequent cardiac catheterizations at the time of endomyocardial biopsy have documented a progressive decrease in PVR (Fig. 1, Table I). She has remained well with steady improvement in exercise tolerance and has returned to school, although she has had several rejection episodes.

This case demonstrates that in some instances, patients with severe PVOD may survive orthotopic cardiac transplantation. Even when the calculated PVR exceeds 8 Wood units, there may be progressive improvement postoperatively if the patient survives the initial postoperative phase. The young age of the pa-

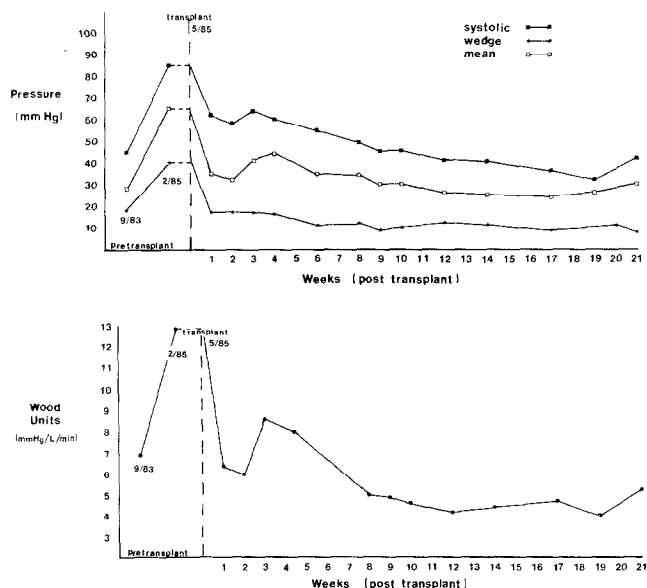


FIGURE 1. Changes in pulmonary artery pressure (*top*) and resistance (*bottom*) after transplantation. Measurements made on room air.

tient reported may have been an important factor in reversibility of PVOD.

Several precautions are suggested in managing such patients: (1) A trial of various drugs can be performed in the catheterization laboratory preoperatively to determine which are most effective in lowering pulmonary artery pressure. (2) This combination can then be used in the early postoperative period along with a high FIO₂ for pulmonary vasodilation. (3) Pulmonary artery pressure should be monitored postoperatively as a guide to administration of these agents. (4) A larger-than-usual donor heart can be used in the hope that this might be better able to cope with an elevated PVR than a heart of usual size. (5) An on-site donor should be used so that the perioperative depression of right ventricular function³ from ischemia is minimized. (6) Finally, some means of mechanical cir-

culatory assistance should be available to provide support for the right ventricle during the immediate postoperative period should it be unable to function adequately because of an abruptly increased afterload. We and others have used extracorporeal membrane oxygenation successfully for this purpose.⁴

References

1. Pennock JL, Oyer DE, Duty BA, Jamieson SW, Bieber CP, Wallwork J, Stevenson EB, Shumway NE. Cardiac transplantation in perspective for the future. *J Thorac Cardiovasc Surg* 1982;83:168-177.
2. Thompson ME. Selection of candidates for cardiac transplantation. *Heart Transpl III* 1983;65-69.
3. Stinson EB, Caves PK, Griep RB, Oyer PE, Rider AK, Shumway NE. Hemodynamic observations in the early period after human heart transplantation. *J Thorac Cardiovasc Surg* 1975;69:264-270.
4. Copeland JL, Emery RW, Levinson MM, Copeland J, McAleer MG, Riley JE. The role of mechanical support and transplantation in treatment of patients with end-stage cardiomyopathy (abstr). *Circulation* 1985;72:suppl II:II-7-II-12.

Left Ventricular Diastolic Characteristics of Cardiac Sarcoidosis

LIP-BUN TAN, MRCP, DPhil
SHAUGHAN DICKIE, DCR
WILLIAM J. McKENNA, MD

We report a patient with systemic sarcoidosis and cardiac involvement that manifested as left ventricular (LV) diastolic dysfunction detected by echocardiography and radionuclide angiography.

A 59-year-old white housewife presented with a 10-year history of right leg lymphedema and ulceration over the left hallux, which progressed 9 years later to bilateral leg lymphedema with gross left foot ulceration and scattered cutaneous nodules around the left knee. She had mild dyspnea on walking 200 yards up a gentle slope and dryness of the eyes. Her heart rate was 90 beats/min and blood pressure was 140/80 mm Hg. Biopsy from the ulcers and the cutaneous nodules showed noncaseating granulomas. The Kveim test was strongly positive. A tuberculin test was negative at 1:100 concentration. There were enlarged lymph nodes in the mesenteric root and para-aortic region seen on abdominal computed tomographic scan. A gallium isotope scan showed increased uptake over the lacrimal and salivary glands, the spleen and heart.

The electrocardiogram showed abnormal T-wave flattening in the anterolateral leads. A 24-hour electrocardiogram showed sinus rhythm with no arrhythmia or heart block. An M-mode echocardiogram demonstrated a thickened LV wall and ventricular septum

with giant presystolic A waves¹ (Fig. 1). Cross-sectional echocardiography showed 2 discrete areas of increased echoes in the septum and in the lateral LV wall. Technetium-99m equilibrium blood pool scanning with serial mode acquisition revealed normal systolic indexes (LV ejection fraction 71%, Fig. 2) but abnormal diastolic indexes (Table I).

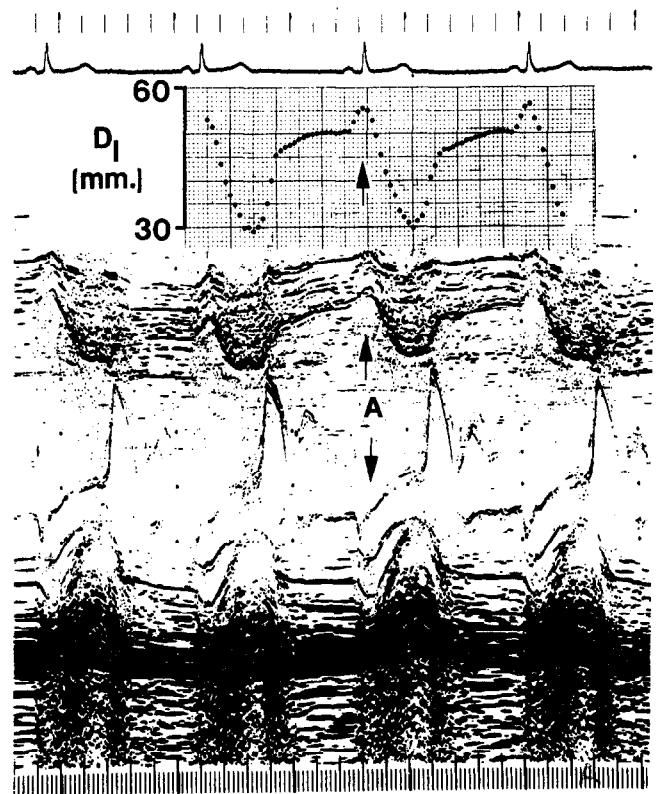


FIGURE 1. M-mode echocardiogram at the time of diagnosis of sarcoidosis. "A" denotes the giant A wave due to atrial contraction. D₁ is the internal dimension of the left ventricle obtained from the M-mode echocardiogram.

From the Division of Cardiovascular Disease, Royal Postgraduate Medical School, Du Cane Road, London W12 OHS, England. Manuscript received March 4, 1986; revised manuscript received May 12, 1986, accepted May 13, 1986.