

# An Unusual Manifestation of Pulmonary Artery Perforation During Pulmonary Artery Catheter Insertion

Lawrence O. Larson, MD and Bruce A. Crider, MD

**P**ULMONARY ARTERY balloon-tipped catheters are commonly inserted in critically ill patients as a source of physiologic data useful in planning management and evaluating the efficacy of treatment. Pulmonary artery perforation with resultant massive hemoptysis is a known complication of the use of these catheters, with an occurrence of 0.064% in one large series.<sup>1</sup> The perforations with hemorrhage reported in this series occurred during the period after insertion rather than during actual insertion of the catheter. Various mechanisms for pulmonary artery injury during the insertion of these catheters have been proposed,<sup>2</sup> but no incidence for pulmonary artery injury during insertion has been reported. A case is reported which describes the immediate production of organized blood clots after pulmonary artery rupture during insertion and positioning of a pulmonary artery balloon-tipped catheter.

## CASE REPORT

A 75-year-old white woman with a history of mild hypertension, asymptomatic premature ventricular contractions (PVCs), and a myocardial infarction 22 years prior to admission was admitted for evaluation of a severe episode of chest pain five days prior to admission. This episode occurred at rest and was of approximately twelve hours' duration. Cardiac catheterization revealed normal overall left ventricular function with posterobasal hypokinesis. Aortic root pressure was 140/73 mmHg, while left ventricular pressure was 140/11 mmHg. Coronary angiography revealed a high-grade proximal stenosis of the left anterior descending coronary artery, proximal occlusion of the right coronary artery, and subtotal occlusion of the distal obtuse marginal branch of the left circumflex artery. No right heart catheterization was performed. The patient was discharged after catheterization and scheduled for readmission for coronary artery bypass grafting.

On readmission 2 weeks later, the above history was confirmed and additional history obtained. The patient's hypertension had been present for 5 years, but was well controlled by captopril, 25 mg, twice daily. Because of

intolerance to quinidine, disopyramide, procaine, and tocainide, the patient's PVCs had been treated with flecainide, 100 mg twice daily, with complete remission of her palpitations. The patient's only other medication was diltiazem, 60 mg, four times daily. History revealed an occasional cough productive of white sputum but no history of hemoptysis. There was no history of orthopnea, paroxysmal nocturnal dyspnea, or congestive heart failure. Physical examination revealed: height, 64"; weight, 145.5 lb; pulse, 68 beats per minute; and blood pressure, 150/70 mmHg. Lungs were clear to percussion and auscultation. Cardiac exam revealed a regular sinus rhythm with a grade ii/vi systolic ejection murmur at the apex. A bruit was heard over the left carotid artery. Admitting chest x-ray revealed no active pathologic process. Prothrombin and activated partial thromboplastin time were normal. Other laboratory values on admission were within normal limits. Electrocardiogram revealed first-degree heart block with evidence of an old myocardial infarction, but no evidence of acute ischemia.

On the morning of the scheduled surgery, after premedication with morphine sulfate, 6 mg, intramuscularly (IM); lorazepam, 2 mg, orally; and diltiazem, 60 mg, orally, the patient was brought to the holding room for insertion of peripheral venous, left radial arterial, and pulmonary artery catheters. The insertion of peripheral venous catheters and the left radial arterial catheter proceeded without incident. Right internal jugular cannulation with an Arrow percutaneous sheath (product number AK-09804, Reading, PA) was also accomplished without incident. A Shaw Oximetrix model P7110 balloon-tipped pulmonary artery catheter was attached to a Hewlett-Packard Model 1290C transducer, and pressures were monitored using a Spacelabs Model 514 monitor (Shaw, Mountain View, CA; Hewlett-Packard, Andover, MA; Spacelabs, Inc, Redmond, WA). Patency of the proximal and distal lumens of the catheter was confirmed and, after calibration, the response of the pressure-monitoring system was confirmed by tapping the tip of the catheter and observing an appropriate deflection of the displayed trace. The catheter balloon was inflated and observed to be intact and to inflate symmetrically. The catheter was then inserted through the introducer sheath to the 20-cm mark and the balloon inflated with 1.5 mL of air. Pressures at this point were 15/7 mmHg with a mean pressure of 10 mmHg. The catheter was then advanced slowly and observed by pressure monitoring to pass through the right ventricle and into the pulmonary artery when 35 cm of the catheter had been inserted. Pulmonary artery pressures were 28/8 mmHg. When 47 cm of the catheter had been inserted and no wedge tracing was obtained, the balloon was deflated and the catheter was withdrawn into the right ventricle, a process that took approximately eight to ten seconds. As the catheter reached the right ventricle, the patient began to cough vigorously and within one minute produced approximately 250 mL of gross blood containing five fragments of apparent tissue measuring in aggregate 5 × 5 × 1 cm. This tissue was resistant to fracture by digital pressure and produced multi-

---

*From the Department of Anesthesiology, University of Michigan Hospitals, Ann Arbor.*

*Address reprint requests to Lawrence O. Larson, MD, Department of Anesthesiology, D2202 Medical Professional Building, Ann Arbor, MI 48109-0718.*

*© 1988 by Grune & Stratton, Inc.  
0888/6296/88/0206-0014\$03.00/0*

plc small air bubbles when compressed. Because the appearance of the tissue was that of hemorrhagic lung tissue it was sent for pathologic examination.

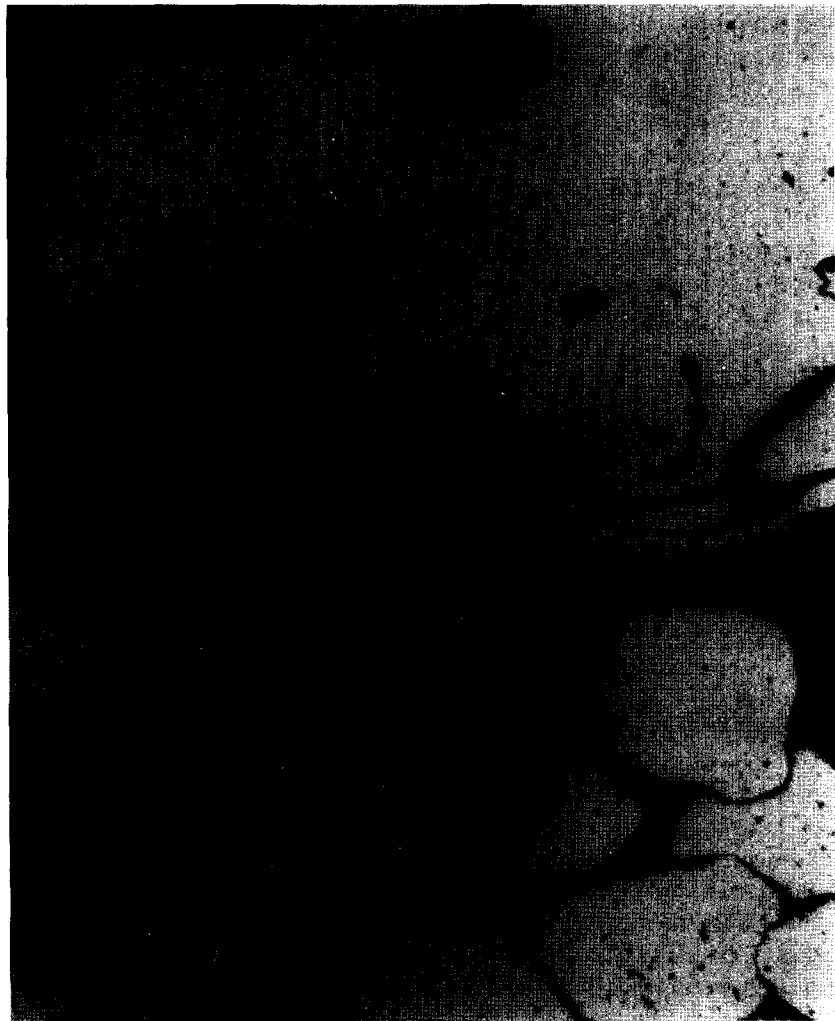The pulmonary artery catheter was immediately withdrawn and the patient turned on her right side and given oxygen, 6 L/min, by nasal cannula. Over the next ten minutes her hemoptysis subsided to the production of occasional blood-streaked sputum. Portable chest x-ray revealed an infiltrate in the right midlung field compatible with pulmonary artery rupture. Arterial blood gases performed five minutes after apparent pulmonary artery perforation revealed pH, 7.37; PaO<sub>2</sub>, 80.2 mmHg; PaCO<sub>2</sub>, 31.4 mmHg; and base excess, -5.1, with the patient receiving nasal oxygen at 3 L/min. An hour later, repeat analysis revealed pH, 7.40; PaO<sub>2</sub>, 171 mmHg; PaCO<sub>2</sub>, 35.6 mmHg; and base excess, -1.7, with the patient still receiving nasal oxygen at 3 L/min. The proposed surgery was cancelled and the patient transferred to the thoracic intensive care unit for observation, where she continued to intermittently produce blood-streaked sputum over the next ten to 12 hours. She was transferred to the floor the next morning and discharged home asymptom-

atic two days later. Pathologic examination of the "tissue" expectorated revealed blood clot and trapped epithelium (Fig 1).

Two weeks after discharge the patient was readmitted and coronary artery bypass grafting was performed without incident. Admission chest x-ray was interpreted as showing no acute disease processes, while arterial blood gases were normal. For monitoring her procedure, a central venous pressure catheter was used rather than a pulmonary artery catheter.

#### DISCUSSION

Several reports have detailed both the variety and incidence of complications resulting from the use of balloon-tipped pulmonary artery catheters.<sup>1-4</sup> Patient conditions that are thought to increase the chance of hemorrhagic complications related to the use of pulmonary artery catheters include anticoagulation, pulmonary



**Fig 1. Photomicrograph of expectorated clot illustrating entrapped air that produced air bubbles with firm digital pressure (H & E, original magnification  $\times 500$ ).**

hypertension, hypothermia,<sup>2</sup> and chronic steroid therapy,<sup>5</sup> none of which was present in this case. In a large series, Shah et al<sup>1</sup> reported the following incidences of hemorrhagic complications: intrapulmonary hemorrhage, 0.064%; minor pulmonary infarction, 0.064%; right ventricular perforation, 0.016%; and death secondary to uncontrollable pulmonary hemorrhage, 0.016%. In view of this and other reports<sup>3,4</sup> of relatively low complication rates attributable to the use of balloon-tipped pulmonary artery catheters, it is generally felt that the use of these catheters is justified in the care of critically ill patients.<sup>1-3</sup> Rao et al<sup>6</sup> have specifically supported monitoring of pulmonary artery pressures by means of these catheters in patients undergoing coronary artery bypass grafting after myocardial infarction.

Proposed mechanisms for pulmonary artery rupture associated with the use of balloon-tipped pulmonary artery catheters fall generally into two categories: those caused by the pressure of balloon inflation and those caused by perforation of the pulmonary artery by the tip of the catheter.<sup>7</sup> Golden et al<sup>8</sup> first suggested balloon inflation as a cause of pulmonary artery rupture in 1973. Since this report, others<sup>9-14</sup> have mentioned this relationship in case reports of pulmonary artery rupture associated with catheter use. Barash et al<sup>2</sup> have suggested three mechanisms by which this might occur (Fig 2). Balloon pressures as high as 1,000 mmHg have been measured in a human cadaver study.<sup>7</sup> This cadaver study also found that pulmonary artery rupture occurred at pressures as low as 975 mmHg. If the balloon were the offending agent in the present case, the most probable mechanism would be that depicted in Fig 2A, since neither a flat tracing nor a wedge tracing was observed during catheter placement.

Two mechanisms by which the catheter tip might cause pulmonary artery rupture have been suggested (Fig 3).<sup>2</sup> Advancement of the catheter while the balloon is deflated creates obvious dangers (Fig 3A) and should not occur when proper technique is followed during catheter placement. However, uncontrolled advancement of the catheter while the balloon is deflated may occur when the heart is manipulated during coronary artery bypass grafting, leading to the frequent recommendation that pulmonary artery catheters be withdrawn variable distances during

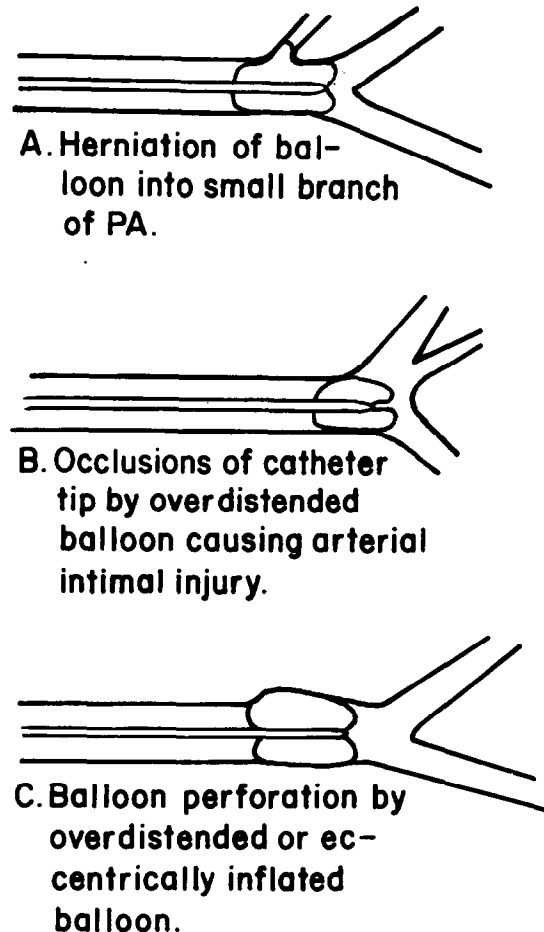
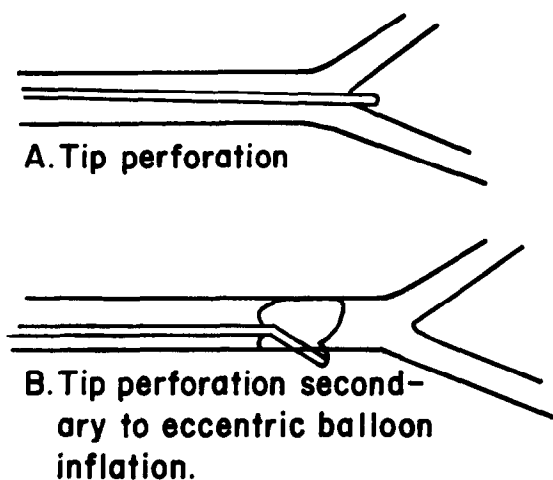


Fig 2. Proposed mechanisms by which excessive or eccentric balloon inflation might cause pulmonary artery rupture. PA, pulmonary artery.

cardiopulmonary bypass. Eccentric balloon inflation is an uncontrollable event that can lead to rupture of the pulmonary artery by the catheter tip (Fig 3B). Barash et al<sup>2</sup> have demonstrated that symmetrical inflation of the balloon during testing outside the body does not guarantee symmetrical inflation within the pulmonary artery, making this mechanism a possible cause of pulmonary artery rupture in this case. The fact that neither a flat tracing nor a wedge tracing was observed at any time during attempted catheter placement in this case makes this mechanism of rupture unlikely.

Barash et al<sup>2</sup> have formulated guidelines for the safe placement of balloon-tipped pulmonary artery catheters, which were followed assiduously in this case. The mechanism of rupture in this case is therefore difficult to delineate.



**Fig 3.** Proposed mechanisms by which the catheter tip might cause PA perforation.

Although rupture by the catheter tip secondary to eccentric balloon inflation cannot be excluded, it is unlikely for the reasons noted above. In the authors' opinion, the more likely mechanism of rupture in this case is that depicted in Fig 2A.

The origin of the clot that was expectorated by the patient in this case is even more obscure than the etiology of the pulmonary artery rupture. By gross examination the clot did not appear fresh. By microscopic examination it was determined to be not more than four to five days old. In an effort to arrive at a unified explanation for the events described in this case, two hypotheses have been considered. First, the patient could have suffered a recent asymptomatic pulmonary artery thrombosis that deflected the catheter tip,

causing pulmonary artery rupture. This hypothesis has been rejected because it cannot be explained how this volume of clot could migrate through the pulmonary artery rupture into a sufficiently large bronchus so that it might be subsequently expectorated. Second, despite the absence of previous hemoptysis, the patient may have bled into the tracheobronchial tree prior to catheter placement. The clot may then have been produced by the coughing stimulated by bleeding into the tracheobronchial tree subsequent to pulmonary artery rupture. This hypothesis is not supported by either the patient history or the negative preoperative chest x-ray.

Only minimal treatment of the pulmonary artery rupture was necessary since bleeding rapidly subsided to minimal levels. The patient was turned on her right side immediately since a majority of pulmonary artery catheters have been shown to enter the right pulmonary artery.<sup>15</sup> The fact that this was true in this case was rapidly confirmed with a portable chest x-ray. Further diagnostic and treatment modalities such as angiography, bronchoscopy, insertion of a double-lumen endotracheal tube, and pneumonectomy or lobectomy, which have been suggested,<sup>2</sup> were not necessary in this case because of the patient's benign course.

A case of pulmonary artery rupture during placement of a balloon-tipped pulmonary artery catheter has been described in which the mechanism is in doubt. The origin of the relatively organized blood clot expectorated by the patient immediately after pulmonary artery rupture is unexplained.

#### REFERENCES

1. Shah KB, Rao TLK, Laughlin S, et al: A review of pulmonary artery catheterization in 6,245 patients. *Anesthesiology* 61:271-275, 1984
2. Barash PG, Nardi D, Hammond G, et al: Catheter-induced pulmonary artery perforation. *J Thorac Cardiovasc Surg* 82:5-12, 1981
3. Katz JD, Cronau LH, Barash PG, et al: Pulmonary artery flow-guided catheters in the perioperative period. *JAMA* 237:2832-2834, 1977
4. Elliott CG, Zimmerman GH, Clemmer TP: Complications of pulmonary artery catheterization in the care of critically ill patients. *Chest* 76:647-652, 1979
5. Louis JF, Takiff H, Schechter MS, et al: Vessel rupture by balloon catheters complicating chronic steroid therapy. *AJR* 144:1073-1074, 1985
6. Rao TLK, Jacobs HK, El-Etr AA: Reinfarction following anesthesia in patients with myocardial infarction. *Anesthesiology* 59:499-505, 1983
7. Hardy JF, Morissette M, Taillefer J, et al: Pathophysiology of rupture of the pulmonary artery by pulmonary artery balloon-tipped catheters. *Anesth Analg* 62:925-930, 1983
8. Golden MS, Pinder T Jr, Anderson WT, et al: Fatal pulmonary hemorrhage complicating use of a flow-directed balloon-tipped catheter in a patient receiving anticoagulant therapy. *Am J Cardiol* 32:865-867, 1973
9. Page DW, Teres D, Hartshorn JW: Fatal hemorrhage from Swan-Ganz catheter. *N Engl J Med* 291:260, 1974
10. Haapaniemi J, Gadowski R, Naini M, et al: Massive hemoptysis secondary to flow-directed thermodilution catheters. *Cathet Cardiovasc Diagn* 5:151-157, 1979

11. Pape LA, Haffajee CI, Markis JE, et al: Fatal pulmonary hemorrhage after use of the flow-directed balloon-tipped catheter. *Ann Intern Med* 90:344-347, 1979
12. Forman MB, Obel IWP: Pulmonary haemorrhage following Swan-Ganz catheterization in a patient without severe pulmonary hypertension. *S Afr Med J* 58:329-331, 1980
13. Rosenbaum L, Rosenbaum SH, Askanazi J, et al: Small amounts of hemoptysis as an early sign of pulmonary artery rupture by a pulmonary arterial catheter. *Crit Care Med* 9:319-320, 1981
14. Shin B, Ayella RJ, McAslan TC: Pitfalls of Swan-Ganz catheterization. *Crit Care Med* 5:125-127, 1977
15. Benumof JL, Saidman LJ, Arkin DB, et al: Where pulmonary arterial catheters go: Intrathoracic distribution. *Anesthesiology* 48:336-338, 1977