

EEG 03784

14-and-6 Hz positive bursts in childhood encephalopathies¹

Ivo Drury

Department of Neurology, University of Michigan Medical School, Ann Arbor, MI (U.S.A.)

(Accepted for publication: 5 December 1988)

Summary 14-and-6 Hz positive bursts, a benign epileptiform variant, have also been described in comatose children with liver disease, chiefly Reyes syndrome. To determine the incidence of this pattern in children in stupor or coma, 154 portable EEGs in 111 children with mental status changes were reviewed. Seven children showed 14-and-6 Hz bursts in the setting of moderate to marked background slowing. They were similar to positive bursts seen in normals in location, duration, morphology, frequency and repetition rate. They differed in being readily activated by stimulation. The etiology was toxic/metabolic in 4 cases, primary cerebral insult in 2 cases and a combination of the two in 1 case. Amongst an age-matched control population, 5 of 75 showed 14-and-6 Hz positive bursts in stage I or II sleep. There were no statistically significant differences in incidence rates between the 2 groups.

14-and-6 Hz positive bursts may occur in diverse encephalopathies of childhood, not just Reyes syndrome. The similar incidence rate, morphology and topography to normals suggest that the presence of these wave forms in encephalopathies represents persistence of a normal EEG feature rather than an expression of some underlying pathophysiological process.

Key words: Positive bursts; Childhood encephalopathy; Effect of stimulation

14-and-6 Hz positive bursts are a benign epileptiform variant seen chiefly in teenagers during drowsiness and light sleep. They have also been described in patients in stupor or coma, usually from hepatic encephalopathy, and are thought to have a particular association with Reyes syndrome in children. The occurrence of positive bursts in a few children with encephalopathies of diverse origin in this laboratory led to a review of their incidence in children and young adults with altered consciousness and comparison with a control population.

Materials and methods

Two hundred and twelve portable EEGs were performed on 147 patients aged 2–21 years, with altered mental status between January 1st, 1986, and December 31st, 1987, at the University of Michigan Hospitals. Recordings included longitudinal bipolar, transverse bipolar and referential

TABLE I
Grades of background EEG abnormalities.

-
- I. Alpha predominant. Excess intermixed theta. Synchronous. Reactive.
 - II. Theta predominant. Intermixed delta. Synchronous. Reactive.
 - III. Delta predominant. Synchronous. Reactive.
 - IV. Delta predominant, usually polymorphic and asynchronous. Minimal or no reactivity.
 - V. Burst suppression. Alpha coma. Electroencephalographic silence.
-

¹ Presented in part at the American EEG Society Meeting, October 1988.

Correspondence to: Ivo Drury, M.D., EEG Laboratory, University Hospital 1B300/0036, 1500 E. Medical Center Drive, Ann Arbor, MI 48109-0036 (U.S.A.).

(ipsilateral ear and Cz) montages, with electrodes applied according to the international 10–20 system. Each study was reviewed, grading background EEG abnormalities on a I–V scale, explained in Table I, and searching for positive bursts. Patients with normal EEGs or grade V abnormalities (burst suppression, alpha coma, isoelectric activity) were excluded, and 6 records were not available for review, leaving 154 studies of 111 patients. The positive bursts were examined to identify their predominant frequency, site of maximal amplitude, morphology, duration, repetition rate, response to stimulation and presence on follow-up EEGs. The medical records of the patients showing 14-and-6 Hz bursts were reviewed to identify the underlying illness, findings on neurological examination and results of laboratory studies (Table III).

The control population was 184 psychiatric inpatients, aged 2–21 years, who had EEGs performed during the same time interval. A minimum of 5 continuous minutes of EEG during stage I or II sleep (Rechtschaffen and Kales 1968) on a referential (ipsilateral ear) montage was necessary for inclusion as a member of the control group. This requirement was satisfied in 75 patients. The

TABLE II

Occurrence of positive bursts with degree of background slowing.

EEG grade	No. of cases	No. with 14-and-6
I	5	0
II	33	0
III	66	4 (6%)
IV	50	3 (6%)

interval of time was based on the normative data of Eeg-Olofsson (1971), who showed that 96% of patients with 14-and-6 Hz positive bursts demonstrated them during 5 min of light sleep. The controls had a variety of psychiatric syndromes, especially drug abuse, depression, schizophrenia and behavioral disorders, none of which have any particular association with changes on scalp EEG (Low 1979).

Results

Study group

Table II shows the numbers of patients with positive bursts in the different grades of EEG

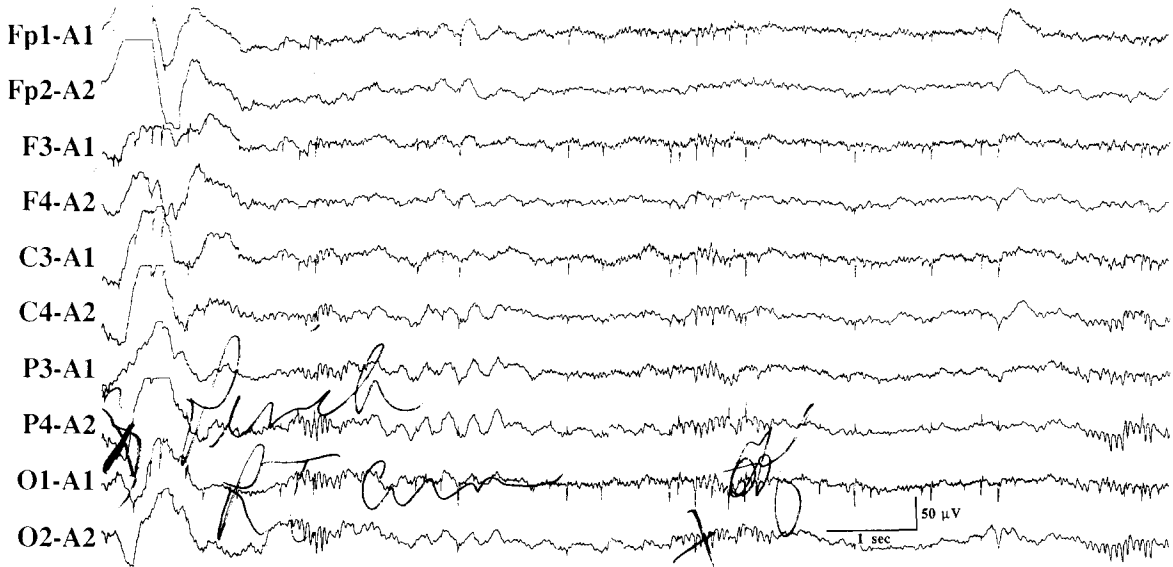


Fig. 1. Case no. 2. 13 years. Lupus cerebritis. Moderate to marked background slowing. Noxious stimulation provoked synchronous burst of high amplitude slow waves and a series of three 15 Hz positive bursts.

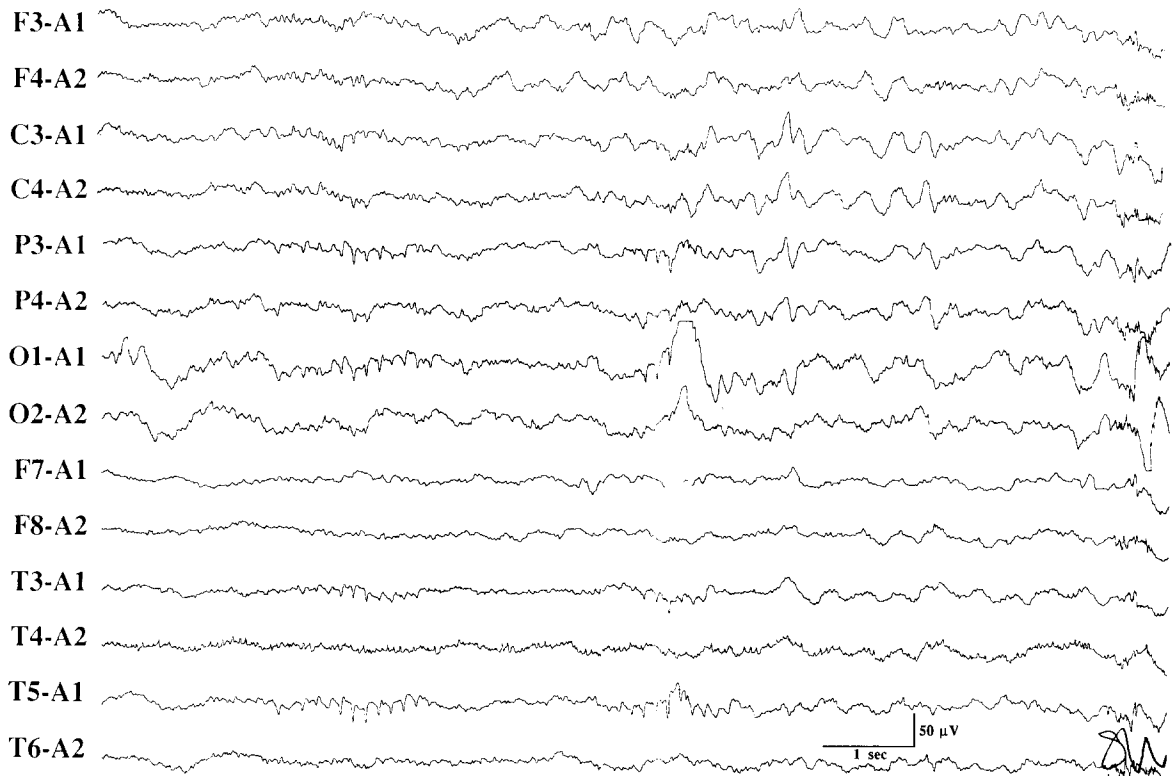


Fig. 2. Case no. 3. 5 years. Hemolytic uremic syndrome. Moderate to marked background slowing. Two 6 Hz positive bursts from left posterior quadrant.

slowing. None of 38 cases with grades I and II slowing showed positive bursts. All 7 patients with 14-and-6 Hz positive bursts had grade III or IV slowing. The difference between the occurrence of positive bursts in grades III and IV slowing compared with grades I and II slowing was not statistically significant.

The bursts had a predominant frequency of 12–15 Hz in 5 cases (Fig. 1) and 6 Hz alone in 2 cases (Fig. 2). All retained the typical morphology, consisting of comb-like, surface positive wave forms of 400–1500 msec duration and maximum amplitude posteriorly. They were always well visualized on referential montages and could be identified on bipolar montages when the background amplitude was very low. The repetition rate was frequent, as short as every 3 sec (Fig. 1) and not longer than 40 sec apart. The bursts were always sporadic, never periodic. Responsiveness to stimulation was tested in 6 cases. In 4 patients,

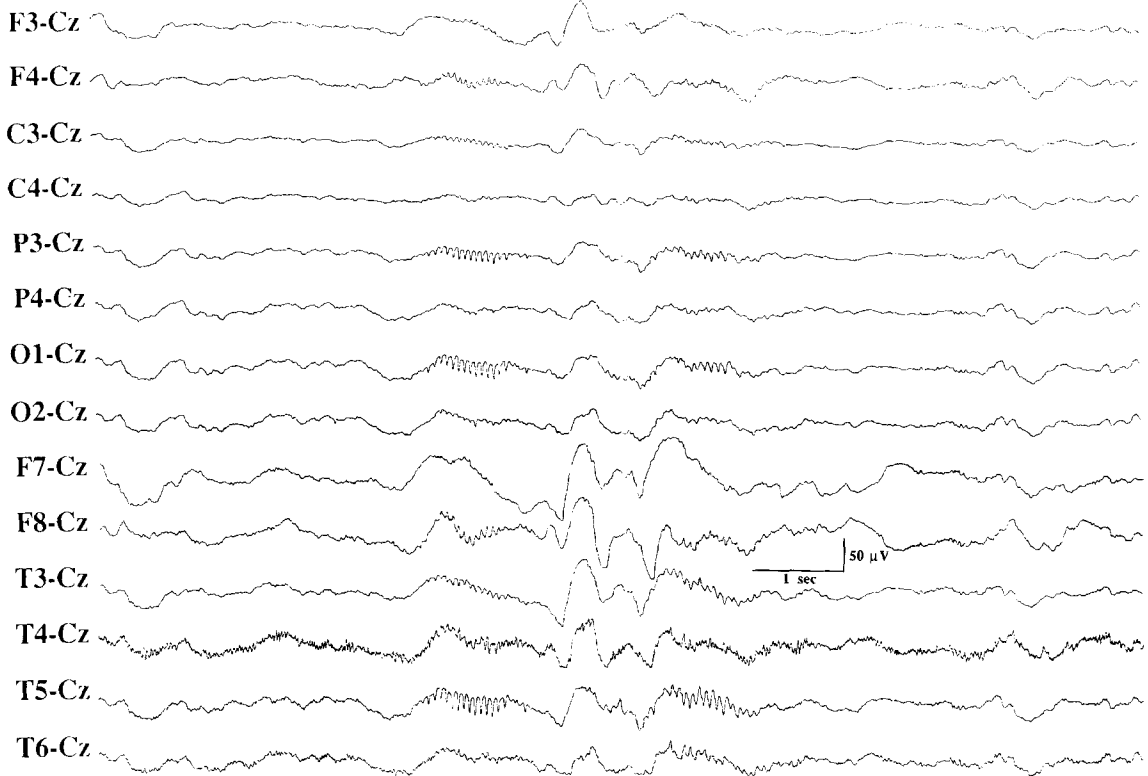
auditory and/or noxious stimuli consistently provoked the bursts (Fig. 1). In 2 patients, the responses were inconsistent and judged not to have a definite relationship to the stimulus.

Six follow-up EEGs were done in 5 patients. Only case no. 7 continued to show bursts in the second EEG, done 48 h later when background slowing was even more prominent (Fig. 3B). Three EEGs with grade III abnormalities and 2 EEGs with grade I abnormalities showed no positive bursts.

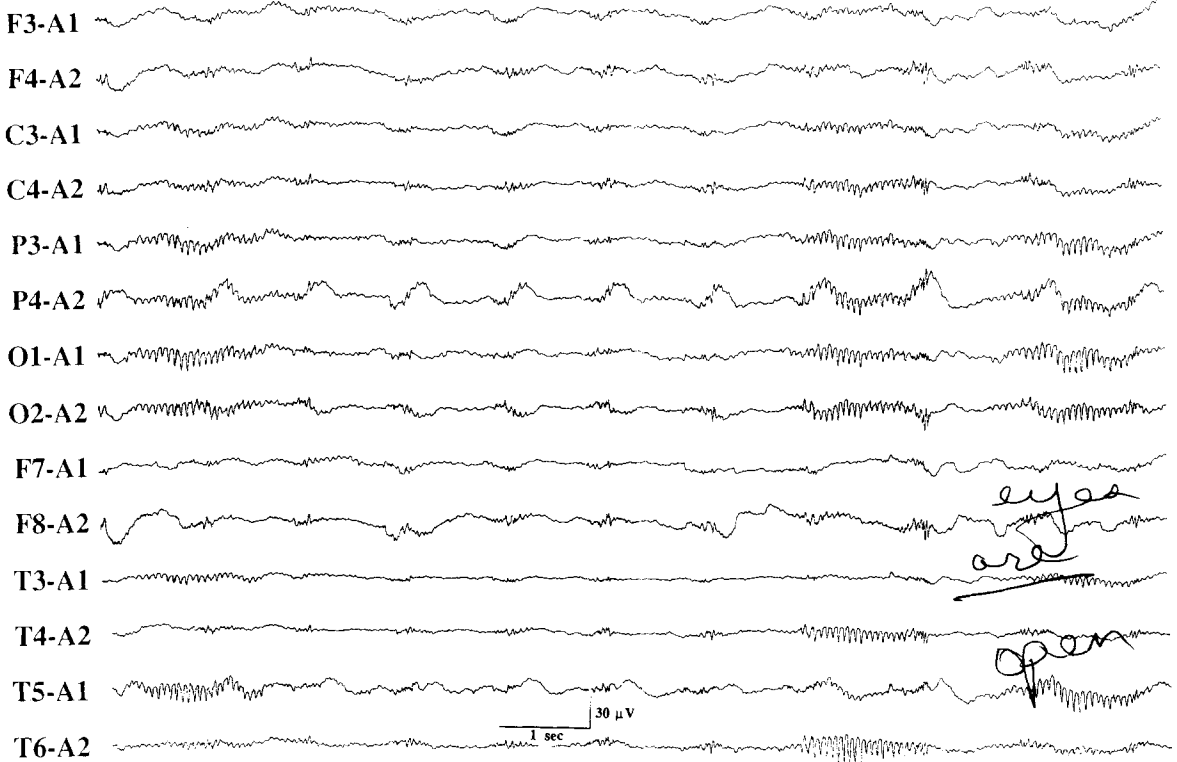
Control group

Of the 75 controls, 5 showed 14-and-6 Hz bursts in stage I or II sleep. All 5 were amongst the 53 patients aged 11–21 years, giving an incidence of 9.4% in this group. In 4 of the 5, the bursts were infrequent. In 1 they repeated every 3–5 sec. The morphology and topography of the wave forms were identical to those described in normal sub-

A



B



jects and seen in the study group. Stimulation did not provoke positive bursts in any record. One of the 5 had a follow-up EEG in sleep which did not show positive bursts.

Table IV summarizes the differences between the study and control groups as a whole and for the age groups 2–10 and 11–21 years. Statistical comparisons using chi-square analysis showed no significant differences between these groups.

Discussion

14-and-6 Hz positive bursts were first described by Gibbs and Gibbs (1951). In normal subjects the bursts are typically a mixture of 14-and-6 Hz surface positive wave forms lasting from 500 to 1000 msec, occurring in drowsiness and sleep of children and young adults, with a maximum incidence at 13–15 years and an amplitude emphasis in the posterior temporal region (Lombroso et al. 1966; Klass and Westmoreland 1985).

Two early reports noted the occurrence of positive bursts in patients with hepatic coma. Poser and Ziegler (1958) described a middle-aged man in coma with alcoholic cirrhosis and Silverman (1964) a man in his twenties comatose from a fulminant viral hepatitis, both showing 14-and-6 Hz bursts. Yamada et al. (1976, 1977) noted the occurrence of these bursts in comatose children with Reyes syndrome and suggested a particular association between the two entities. More recently two reports documented occurrence of positive bursts in stuporous or comatose adults from causes other than hepatic disease (Ford and Freeman 1982; Falcon 1986).

This is the first study that has looked at the incidence of positive bursts in a large series of encephalopathies and contrasted it with a control population. No statistically significant differences were found between the incidence rates for the groups as a whole and the 2 separate age groups of 2–10 and 11–21 years. The higher incidence in

the second decade is in keeping with studies in normals (Eeg-Olofsson 1971). These incidence rates are lower than those described in normal populations, but this is most probably due to the inclusion of patients as young as 2 and as old as 21. The choice of psychiatric patients for a control population was dictated by the need for a large series of patients free of neurological and systemic disease. Studies which have utilized proper control groups and appreciated the strong age dependency for expression of the pattern have shown no difference in the incidence of positive bursts among normal subjects and patients with various behavioral problems (Wiener et al. 1966).

Yamada et al. (1977) contended that the frequency of positive bursts is in general slower than 14 Hz and becomes faster or slower with EEG improvement or deterioration. The illustrations in Yamada's two papers, however, show many discharges of 13–14 Hz. We found no relationship between the frequency of the positive bursts and the degree of background slowing.

Four of the 6 patients who were stimulated during their EEGs showed consistent provocation of the discharges. It is known that in some subjects 14-and-6 Hz bursts were provoked by auditory and somatosensory stimuli (Kennard 1961; Kooi 1968). This feature has not been systematically studied in normal subjects or patients with encephalopathy. It may represent the return to a more alert state when positive bursts are more likely to be seen.

Frequent repetition rate of the discharges was noted in these patients similar to that described by Yamada et al. (1977). However, Lombroso et al. (1966) and Eeg-Olofsson (1971) show that some normal subjects will have very frequent discharges. In one study (Eeg-Olofsson 1971), the median repetition rate of the bursts was once every 30 sec with a range of 6–300 sec. Amongst the 7 patients, repetition rates ranged from every 3 to 40 sec when visualized on referential montages. One of the 5 members of the control group had

Fig. 3. A: case no. 7. 18 years. Refractory leukemia. Uncontrollable gastrointestinal bleeding: Marked background slowing. Two 13–15 Hz positive bursts associated with rhythmic delta activity. B: case no. 7. Follow-up EEG after 48 h. More marked background slowing, respiratory artifact (maximum at F8 and P4), and three 15 Hz positive bursts unaffected by eye opening or closure.

TABLE III
Clinical and EEG findings in patients with positive bursts.

Case no.	Age	Level of consciousness	LFTs *	Etiology	Grade of background slowing	Frequency of bursts (Hz)	Repetition rate (sec)	Duration and morphology	Site of amplitude maximum	Stimulation	F/U * EEGs
1	17	Coma	NT *	Resolving pentobarb. coma. Sagittal sinus thrombosis. Intracerebral hemorrhage.	4	14	40	800 msec typical	T5/6	Activating	Grade I No 14 and 6
2	13	Coma	SGOT 117 NH ₄ 26 Bili. 0.3	Lupus cerebritis.	4	15	5	800 msec typical	T5/6	Activating	Grade III No 14 and 6
3	5	Stupor	SGOT 80 Bili 0.7 Creat. 4.4	Hemolytic uremic syndrome.	3	6	16	800 msec typical	T5/6	Activating	Grade I No 14 and 6 Grade III No 14 and 6
4	10	Stupor	NT	Mental retardation dev. delay. Resp. arrest.	3	14	13	800 msec typical	T5/6	NR *	None
5	19	Coma	SGOT 17 Bili. 0.2	Drug overdose (baclofen, valium)	3	12	10	600 msec typical	T5/6	NR	Grade III No 14 and 6
6	4	Stupor	SGOT 34-90 Bili. 0.4-0.8	Congenital heart disease. Renal transplant. Pulmonary edema.	3	6	8	1000 msec typical	T5/6	NT	None
7	18	Coma	NH ₄ 183 Bili. 3.1	Acute leukemia. Pancytopenia. GI bleed.	4	15	10	1000 msec typical	T5/6	Activating	Grade IV 14 and 6 present

F/U = follow-up; LFTs = liver function tests; N = normal; NR = no response; NT = not tested; T5/6 = posterior temporal electrodes of international 10-20 system. Normal laboratory values: SGOT, 2-35 IU/l; bilirubin, 0.1-0.9 mg/dl; NH₄, 11-35 μmol/l; creatinine, 0.6-1.3 mg/dl.

TABLE IV

Occurrence of positive bursts in different age groups in study and control groups.

Group	Total no.	No. with 14-and-6		
		2-21 years	2-10 years	11-21 years
Study	111	7 (6.3%)	3/63 (4.8%)	4/48 (8.3%)
Control	75	5 (6.6%)	0/22	5/53 (9.4%)

extremely frequent discharges occurring at 3-5 sec intervals. A larger number of cases would be necessary to judge real differences in repetition rate between the two groups. It should be recognized that positive bursts may be more readily identified in encephalopathic states, where an overall simplification of the background EEG activities can render the positive bursts more conspicuous.

Resolution of the bursts with improvement of EEG has been felt to be significant and indicative of a causal relationship between the encephalopathy and the bursts. Amongst the 8 patients described by Yamada et al. (1976, 1977), 1 of the 5 survivors who had follow-up EEGs showed 14-and-6 Hz bursts that were much less frequent than when encephalopathic. Two studies of normal populations reexamined patients who had positive bursts on their first EEG. Eleven of 20 patients studied by Long and Johnson (1968) and 45 of the 62 cases studied by Eeg-Olofsson (1971) showed positive bursts on follow-up. The studies of Yamada et al. (1976, 1977) and the present one may have failed to demonstrate recurrence because of small sample sizes.

This study shows that 14-and-6 Hz positive bursts occur in diverse encephalopathies of childhood, not just Reyes syndrome. The bursts show a similar incidence rate to the normal population and retain the typical morphology and topography of these wave forms. Their presence in these different childhood encephalopathies suggests that they are a normal wave form which is selectively preserved and more resistant to underlying structural or metabolic processes than other background features of drowsiness and sleep.

The author appreciates the assistance of Dr. Chris W. Vanderzant for his review and editorial assistance and Mrs. Suzanne French-Willis for preparation of the manuscript.

References

- Eeg-Olofsson, O. The development of the electroencephalogram in normal children from the age of 1 through 15 years. 14 and 6 Hz positive spike phenomenon. *Neuropädiatrie*, 1971, 2: 405-427.
- Falcon, J. 14 and/or 6 Hz positive bursts recorded in comatose patients. *Electroenceph. clin. Neurophysiol.*, 1986, 64: 24P.
- Ford, R.G. and Freeman, A.M. Positive spike bursts in a comatose adult. *Electroenceph. clin. Neurophysiol.*, 1982, 53: 29P.
- Gibbs, E.L. and Gibbs, F.A. Electroencephalographic evidence of thalamic and hypothalamic epilepsy. *Neurology*, 1951, 1: 136-144.
- Kennard, M.A. EEG changes occurring with drowsiness in emotionally disturbed children. *Electroenceph. clin. Neurophysiol.*, 1961, 13: 305-306.
- Klass, D.W. and Westmoreland, B.F. Nonpileptogenic epileptiform electroencephalographic activity. *Ann. Neurol.*, 1985, 18: 627-635.
- Kooi, K.A. Involuntary movements associated with 14-and-6-per-second positive waves. Report of a case with electroencephalographic studies. *Neurology*, 1968, 18: 997-1002.
- Lombroso, C.T., Schwartz, I.H., Clark, D.M., Muench, H. and Barry, J. Ctenoids in healthy youths. Controlled study of 14-and-16-per-second positive spiking. *Neurology*, 1966, 16: 1152-1158.
- Long, M.T. and Johnson, L.C. 14-and-6-per-second positive spikes in a nonclinical male population. *Neurology*, 1968, 18: 714-716.
- Low, M.D. Evaluation of psychiatric disorders and the effects of psychotherapeutic and psychotomimetic agents. In: D. Klass and D. Daly (Eds.), *Current Practice of Clinical Electroencephalography*. Raven Press, New York, 1979: 395-410.
- Poser, C.M. and Ziegler, D.K. Clinical significance of 14 and 6 per second positive spike complexes. *Neurology*, 1958, 8: 903-912.
- Rechtschaffen, A. and Kales, A. (Eds.). *A Manual of Standardized Terminology, Techniques and Scoring Systems for Sleep Stages of Normal Subjects*. U.S. Department of Health, Education and Welfare, Neurological Information Network, Bethesda, MD, 1968.
- Silverman, D. 14 and 6 per second positive spike pattern in a patient with hepatic coma. *Electroenceph. clin. Neurophysiol.*, 1964, 16: 395-398.
- Wiener, J.M., Delano, J.G. and Klass, D.W. An EEG study of delinquent and nondelinquent adolescents. *Arch. Gen. Psychiat.*, 1966, 15: 144-150.
- Yamada, T., Tucker, R.P. and Kooi, K.A. 14 and 6 c/sec positive bursts in comatose patients. *Electroenceph. clin. Neurophysiol.*, 1976, 40: 645-653.
- Yamada, T., Young, S. and Kimura, J. Significance of positive spike bursts in Reyes syndrome. *Arch. Neurol.*, 1977, 34: 376-380.