

FIELD INVESTIGATIONS OF THE PERFORMANCE OF AIR BAG DEPLOYMENTS IN FRONTAL COLLISIONS*

DONALD F. HUELKE and JAMIE L. MOORE

University of Michigan Transportation Research Institute, 2901 Baxter, Ann Arbor, MI 48109, U.S.A.

(Received 15 August 1992; in revised form 7 February 1993)

Abstract—This paper documents field investigations of “air bag” crashes selected from a large group of air bag crashes in file at the University of Michigan Transportation Research Institute (UMTRI). A full range of crashes are presented with injury levels of AIS 1–2 to AIS 5–6. Most occupants sustained minor injuries. Those not wearing the lap-shoulder belt (3-point belt) had more minor injuries than the restrained. The occurrence of higher level injuries (AIS ≥ 2) was found more often in the nonbelted.

INTRODUCTION

The air bag (air cushion) is the supplemental restraint system for lap-shoulder-belted front seat occupants. Steering wheel air bags are currently standard equipment on many car models. As with many of the other safety features, the air bag has been well tested in the laboratory setting and in planned crashes on the proving grounds of the automobile companies. As would be expected, the air bag met all of the in-house requirements and were offered to the motoring public as the manufacturing capability became available for the individual model cars. Case histories of the air bag crashes are sparse, for few have been presented in the medical or engineering literature. We have prepared two other reports presenting different case histories than those included herein. (Huelke, Roberts, and Moore 1991; Huelke, Moore, and Öström 1992).

The effectiveness of an occupant injury countermeasure of an automobile safety feature can be assessed by only investigations of real-world crashes in the various impact environments. It was expected that the air bag, like the lap-shoulder belt, the high penetration resistant windshield, and the antiburst door locks, would be an additional safety feature for the reduction of serious injuries and fatalities.

MATERIALS AND METHODS

In order to identify “air bag” crashes we established an “early alert” system for notification of air

bag deployments. In that this field accident investigation program was sponsored by Chrysler Corporation, Nissan Motor Company, Ltd., and Ford Motor Corporation, letters were sent to their dealerships, to private body-repair shops, and to selected salvage lots to notify them of the research program and requesting that they alert us to any air bag deployments via an 800 toll-free telephone number. Additionally, “Wanted” posters were included as a reminder of our program (Fig. 1). A similar poster was distributed to all of the Michigan State Police posts, and contacts were also made with Sheriff’s Departments as well as police agencies in the area of the University of Michigan. Several insurance companies cooperated by providing information on air bag-equipped cars in crashes. As our toll-free number became distributed throughout the country, we received numerous calls from drivers involved in air bag crashes, who reported their crash details directly to us. To date we have received over 1,900 calls about air bag crash deployments.

The fact that an air bag deploys does not mean that the car was in a high-speed crash. First we established the types of crashes that were to be investigated. Frontal crashes were of prime interest, with rear-end and offset side crashes not high on our priority list, for it was expected that in the majority of these nonfrontal crashes the bag would not deploy. When a call was received via our “early alert” notification program, we would determine the type of crash and the extent or dollar amount of damage. This information was readily available from the body-shop personnel. If the vehicle was selected for detailed investigation, the driver and/or front right passenger was contacted by telephone in order

*Presented at the annual conference of the Association for the Advancement of Automotive Medicine, Portland, Oregon, October 5–7, 1992.

WANTED!

CRASHES INVOLVING ANY CARS WITH:

- AIR BAGS •
- AUTOMATIC SEAT BELTS •
- REAR SHOULDER BELTS (WORN) •

FOR: A scientific research program — on the effectiveness of automobile restraint systems — at The University of Michigan Transportation Research Institute, Dr. Don Huelke.



ANYTIME
CALL: 1-800-423-7507

Please provide:

- your name, telephone number
- time and date of call
- police report number
- brief details about the crash (damage, injury)
- when best to return a call to you

If possible, quickly estimate damages.
DO NOT HESITATE TO CALL !

Fig. 1. Poster distributed to car dealerships, body shops, and police.

to determine the extent of injuries. In the more serious injury or fatality cases, detailed medical or autopsy reports were reviewed. Vehicle crash details were recorded using the University of Michigan In-depth Vehicle Occupant Report (UMIVOR). Multiple photographs of the exterior and interior of the car were taken. Injury severity was coded using the Abbreviated Injury Scale (AIS) with the highest injury level "maximum" presented as MAIS. Travel throughout the continental United States was required in order to investigate the various air bag crashes.

To date we have investigated approximately 275 crashes, a selection being presented here. Injuries in "the other car" are not known.

RESULTS

It is important at the outset to indicate that the air bag is not the "polio vaccine" for traffic medicine

and should not be thought as the end-all in occupant protection, and that the air bag must be considered as a supplemental restraint system for the lap-shoulder belted front seat occupant.

Presented below are a series of crashes which range from extremely serious with fatality, extremely serious with survival, to less severe crashes with AIS-1 or -2 level injuries.

Case 1 (UM-FMA-046). A 1990 Lincoln Town Car driven by a 73-year-old female left the interstate highway for an unknown reason, traveled in the grassy median, and struck a large overhead highway sign support pole. It was estimated the car was traveling at more than 97 kmph when the crash occurred (Fig. 2). Frontal damage extent was 137 cm.

Interior damage was extremely severe with catastrophic compartment crush. The forward movement of the rear occupants loaded the front seats. There were four female occupants in the car, ranging in age from 69 years to 74 years. None of the women



Fig. 2. High speed pole crash. 1990 Lincoln Town Car. All four occupants killed.

was restrained, and all were pronounced dead at the scene. Both the driver- and passenger-side air bags deployed. The occupants sustained numerous fractures, severe internal injuries, and multiple superficial injuries; MAIS 5, MAIS 6.

Case 2 (UM-2934-91). In this collision the impact was so severe that the crash was totally unsurvivable for both front seat occupants. This 1991 Cadillac DeVille was traveling on a two-lane roadway when the driver entered the right shoulder in an

attempt to pass a turning vehicle. The driver lost control, crossed the centerline, and struck a 1987 Ford Econoline E-150 Van head-on. There was extensive damage to the front of the Cadillac (132 cm) (Fig. 3). The 79-year-old female driver (161 cm, 45 kg) was wearing the 3-point restraint; the air bag deployed. She sustained the following injuries: complete separation of C1 from the base of the skull (impact force), multiple rib fractures on both sides (shoulder belt, air bag), and fractures of the right




Fig. 3. Severe car to van crash. Elderly female driver died from multiple injuries.




Fig. 4. Frontal offset crash. Lap-shoulder belted driver with deployed air bag sustained only minor injuries.

tibia (lower instrument panel) and right humerus (steering wheel, upper instrument panel); MAIS 6. The 81-year-old, right-side male passenger (164 cm, 68 kg) was wearing the 3-point restraint and was also fatally injured; MAIS 5.

The cases below illustrate that air bags are designed to supplement the protection given by a 3-point belt. Air bags activate only once during an accident; therefore, only the belts can help restrain occupants in multiple-impact collisions.

Case 3 (UM-2981-92). This was a violent multiple-impact crash; the air bag in the 1990 Lincoln Town Car significantly reduced the driver's injury level, along with the 3-point belt. The car entered the intersection where it struck the side of a 1982 Ford Mustang. The damage was concentrated at the front right of the Town Car (Fig. 4). After the impact, both cars rotated and struck again, damaging the right rear quarter panel of the Town Car. The car was equipped with driver's side and passenger's side air bags, which deployed during the first crash sequence. The 16-year-old, 3-point restrained male driver (183 cm, 90 kg) continued forward and to the right in the first impact where his left thigh contacted the steering column and his right thigh contacted the mid-panel (bruises; he also sustained a small laceration to the left side of his nose (air bag); MAIS 1.

Case 4 (UM-NAB-013). In this severe crash the air bag significantly reduced the injury level, along

with the 3-point restraint. A 1977 Plymouth Gran Fury attempted a left turn in front of a 1990 Infiniti M30 that was traveling at an estimated speed of about 72 kph. The two cars struck head-on. After impact, both cars rotated and struck again, damaging the left rear quarter panel of the M30 (36 cm of crush). The maximum crush to the front of the M30 was about 64 cm (Fig. 5).

The air bag of the M30 deployed during the first crash sequence. The 3-point restrained male driver (180 cm, 82 kg) sustained the following minor (AIS 1) injuries: cervical and thoracic strain (impact force), contusions across the abdomen and chest (3-point belt), contusion left knee (lower instrument panel), contusion right lower leg (center console trim piece), contusion right anterior forearm and abrasions (air bag), and first-degree thermal burns to the top of the right hand (air bag gas); MAIS 1. The two front seat occupants in the Plymouth were not wearing their safety belts and were seriously injured.

In some extremely high speed crashes we have found a number of true "success" stories, some of which are documented below.

Case 5 (UM-2939-91). This is a severe crash where the driver was protected by the air bag. This 1991 Ford Taurus police car was on an emergency call when the driver failed to negotiate a left curve at the crest of a hill. The car went off the right side of the roadway and struck a large tree. There was extensive damage to the front end (74 cm) (Fig. 6).

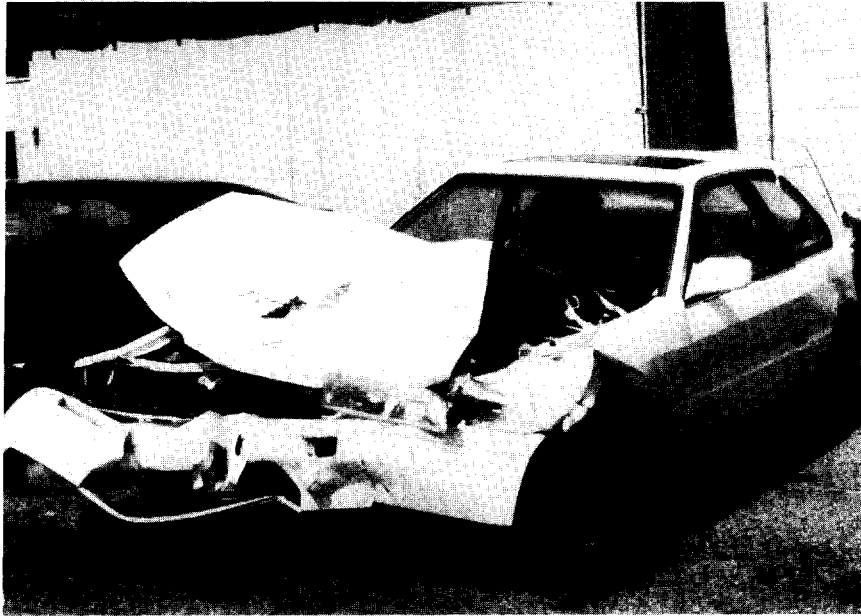


Fig. 5. Multiple minor injuries sustained by a belted driver. Dorsal right hand burn from the air bag gas.

The 28-year-old, lap-shoulder belted male driver (180 cm, 91 kg) sustained a hairline fracture of the sternum (shoulder belt), contusions of the left neck, across the abdomen (3-point restraint), of the anterior right forearm (transmission selector), the left forearm (steering wheel), a sprained right ankle (brake pedal), and a tongue laceration (bit down with teeth); MAIS 2.

Case 6 (UM-2979-92). In an attempted left turn this 1991 Chevrolet Caprice four-door sedan was struck head-on by a 1984 Chevrolet Blazer traveling at a driver-estimated speed of 72 kph. The front of the Caprice was severely damaged (Fig. 7). The 85-year old, belted male driver (185 cm, 86 kg) sustained a thoracic strain (impact force). No injuries were reported from the air bag; MAIS 1.



Fig. 6. Severe frontal crash; air bag deployed and lap shoulder belt worn. Most severe injury was a sprain of the ankle.



Fig. 7. An 85-year-old belted driver sustained minor injuries in this car-to-car crash. No injuries reported from the deployed air bag.

Case 7 (UM-CCA-055). This is another “success story” where the driver benefitted from the air bag and 3-point restraint. This 1990 Plymouth Acclaim had been traveling at a speed of about 88 kph in the far right lane on a four-lane divided highway behind a slow-moving tractor-trailer. As the Acclaim entered the left lane in order to pass, the

tractor-trailer also moved into the left lane. The front right of the Acclaim struck the rear of the trailer. The damage to the front right of the Acclaim was extensive (85 cm) (Fig. 8).

The 23-year-old, restrained male driver (185 cm, 84 kg) sustained a contusion across his shoulder (shoulder portion of the belt), contusions to both



Fig. 8. Extensive damage to a 1990 Plymouth Acclaim that struck the rear of a semi-trailer at high speed. Only minor injuries were sustained by the driver, who was protected by the lap shoulder belt and the airbag.




Fig. 9. Severe frontal damage with only minor injuries to the restrained driver. Air bag contact produced a contusion of the nose and a hand abrasion.

knees (lower instrument panel, multiple lacerations to his right fingers and forearm (upper central panel or flying glass), and multiple abrasions to his right upper arm; MAIS 1.

Case 8 (UM-2994-92). This severe crash occurred when a 1988 Chrysler LeBaron, traveling at an estimated speed of 100 kph, struck the rear of a 1984 Ford Mustang that had been stopped on the highway due to engine trouble (Fig. 9). The 44-year-

old restrained, male driver (173 cm, 74 kg) sustained a contusion to his nose and an abrasion to the dorsum of the left hand (air bag), and a contusion across his left shoulder (shoulder portion of belt); MAIS 1.

Case 9 (UM-CCA-073). In this crash a 1992 Dodge Caravan crossed the center line and struck a 1979 Oldsmobile Station Wagon head-on. The frontal damage was extremely severe to the front of the Caravan (68 cm) (Fig. 10). The 52-year-old, re-

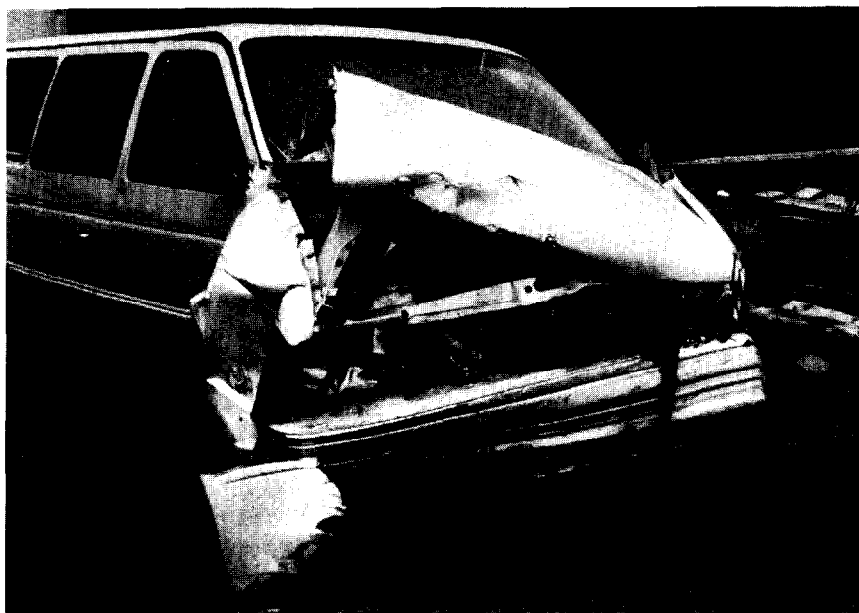

Fig. 10. Dodge Caravan—head-on crash into an Oldsmobile station wagon. Minor injuries to the restrained driver.




Fig. 11. Air bag protection to an unrestrained driver. Minor injuries reported.

strained male driver (183 cm, 84 kg) sustained multiple lacerations to arms, knees, and ankles. In addition, he sustained some chest muscle strain and contusions (restraint); MAIS 1.

In the following five cases the occupants were not wearing the 3-point restraints.

Case 10 (UM-2876-91). Attempting to complete a left turn a 1991 Mercury Sable Station Wagon was struck head-on by a 1989 Ford Bronco. The frontal damage to the Sable was 57 cm (Fig. 11). The 42-year-old, unrestrained female driver (164 cm, 56 kg) sustained minor contusions and abrasions to the lower extremities (lower instrument panel and steering column), and she was "sore all over"; MAIS 1.

Case 11 (UM-2909-91). This crash occurred when the driver swerved to avoid an oncoming vehicle, went off the road, and impacted two trees. The damage to the front of this 1991 Cadillac Eldorado was 54 cm (Fig. 12). The 30-year-old, unbelted female driver (163 cm, 64 kg) sustained cervical strain (impact force), contusions to both temples (air bag), contusions to both anterior forearms (air bag), and contusions to both knees (lower instrument panel); MAIS 1.

Case 12 (UM-2912-91). A 1991 Ford Mustang went out of control on the wet road, went onto the off-road area, and struck two trees (Fig. 13). The 21-year-old, unbelted male driver (180 cm, 77 kg) sustained a contusion behind his left ear (head rest),

lumbar strain (impact force), and a contusion to his right knee (lower instrument panel); MAIS 1.

Case 13 (UM-2889-91). A 1982 Ford LTD crossed the centerline and struck the front left of a 1990 Cadillac DeVille equipped with a driver's side air bag. The damage to the front of the Cadillac was fairly extensive (maximum crush 144 cm). The total delta V was calculated to be 57 kph (Fig. 14). The 35-year-old, unbelted female driver (170 cm, 57 kg) sustained the following injuries: fractures of the right tibia (lower instrument panel), right toe (foot controls, floor), and left fibula and left ankle (lower instrument panel and floor). Also noted were three left rib fractures and a chest contusion (air bag) and multiple abrasions and contusions to her left foot, right knee, right lower leg, and left hand and fingers; MAIS 2.

Case 14 (UM-CCA-027). A 1966 White 9564 TD Wrecker was towing a 1974 Freightliner 6 × 4 truck that had stopped to make a left turn. A 1988 Chrysler LeBaron struck the rear of the Freightliner (the towed vehicle). The damage to the front of the LeBaron was 58 cm (Fig. 15). The 47-year-old, unbelted male driver (178 cm, 72 kg) sustained a fractured right femur (lower instrument panel), a chin abrasion and a chest contusion (air bag), and cervical strain (impact force); MAIS 3. The air bag provided excellent protection to his head and torso.

Some believe that the manual seat belts need not be worn since their car is equipped with an air




Fig. 12. Head and arm contusions were sustained from the deployed air bag in this car-to-tree crash. All injuries were rated as AIS-1.

bag. Below are two cases in which the occupants were not wearing the 3-point belts and sustained head injuries from contacting the windshield or sunvisor.

Case 15 (UM-CCA-071). The driver of this 1991 Plymouth Voyager was traveling about 88 kph on the interstate when he struck the rear of a 1989 Ford

F-125 pickup truck that had stopped. The maximum crush to the front of the van was 19 cm (Fig. 16).

The unbelted 23-year-old male driver (193 cm, 89 kg) continued to move forward and rotated upward and over the deployed air bag. His head contacted the top left area of the windshield causing a 6 cm laceration to the left side of his forehead and




Fig. 13. Car-tree crash. Unbelted driver had minor injuries. No injuries were related to the air bag.

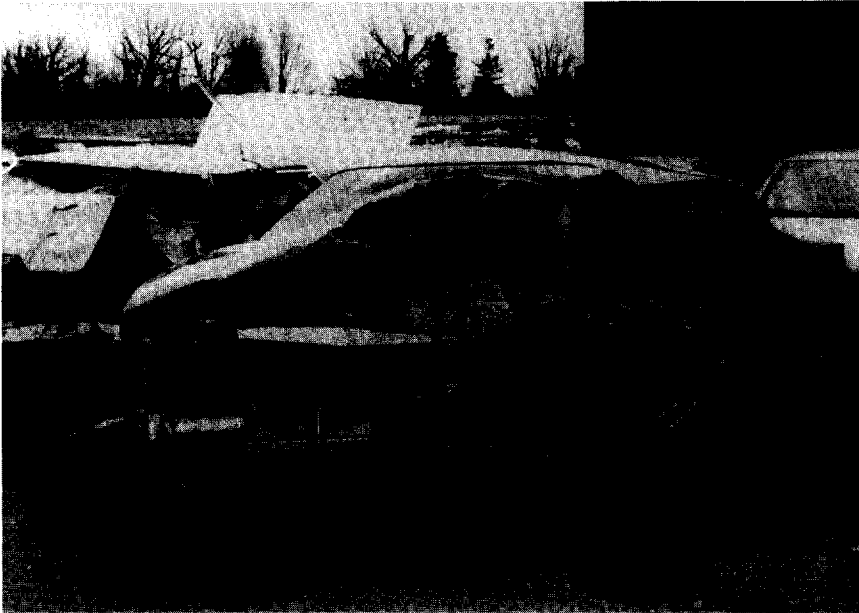


Fig. 14. Severe heavy frontal crash in-line with the unrestrained driver. Lower extremity fractures sustained by impact to the lower instrument panel and the foot controls. Three rib fractures and a chest contusion were related to the air bag.

a concussion. Small lacerations to both of his hands (flying glass), contusions to both knees (lower instrument panel), and to his left forearm (armrest) were reported along with cervical and thoracic strain (impact force); MAIS 2.

Case 16 (UM-2980-92). A 1991 Lincoln Town Car was traveling on a two-lane, snow- and ice-covered roadway. An oncoming car lost control on the slippery road, crossed the centerline, and was struck by the Town Car. The damage to the front




Fig. 15. Chin and chest contusion from air bag contact sustained by an unbelted driver. Fracture of the femur was due to lower instrument panel contact.

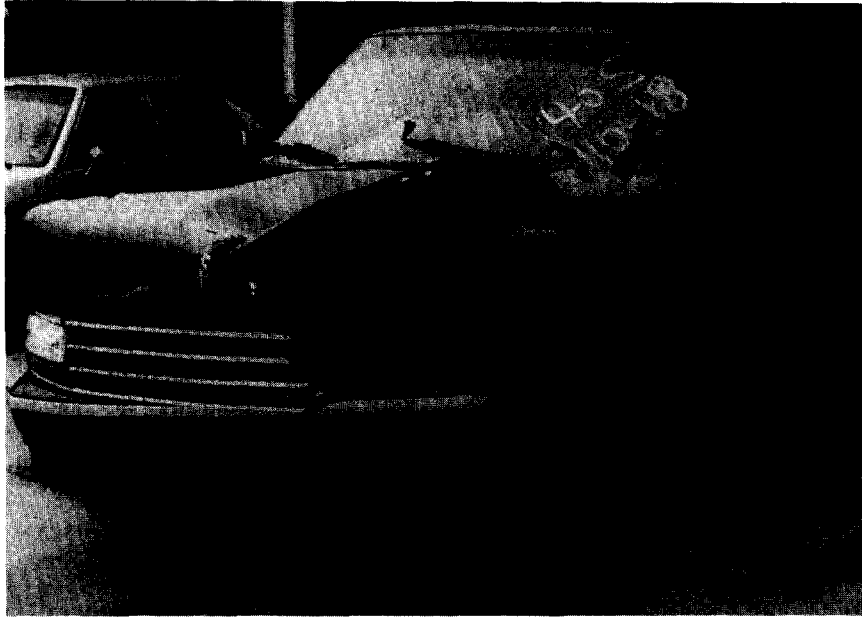


Fig. 16. No air-bag-related injuries to the unbelted driver of this 1990 Plymouth Voyager.

of the Town Car was 31 cm (Fig. 17). The driver-side air bag deployed. The 68-year-old, unbelted female driver (163 cm, 81 kg) sustained the following injuries: an 8 cm laceration left upper area of the scalp and a slight concussion (sunvisor), abrasions both knees (lower instrument panel), multiple abrasions

to the dorsum of left hand (air bag), and cervical strain (impact force); MAIS 2.

The unrestrained 69-year-old, right-side female passenger (157 cm, 77 kg) (no instrument panel air bag) moved forward during the crash, and her head contacted the windshield causing a forehead laceration.

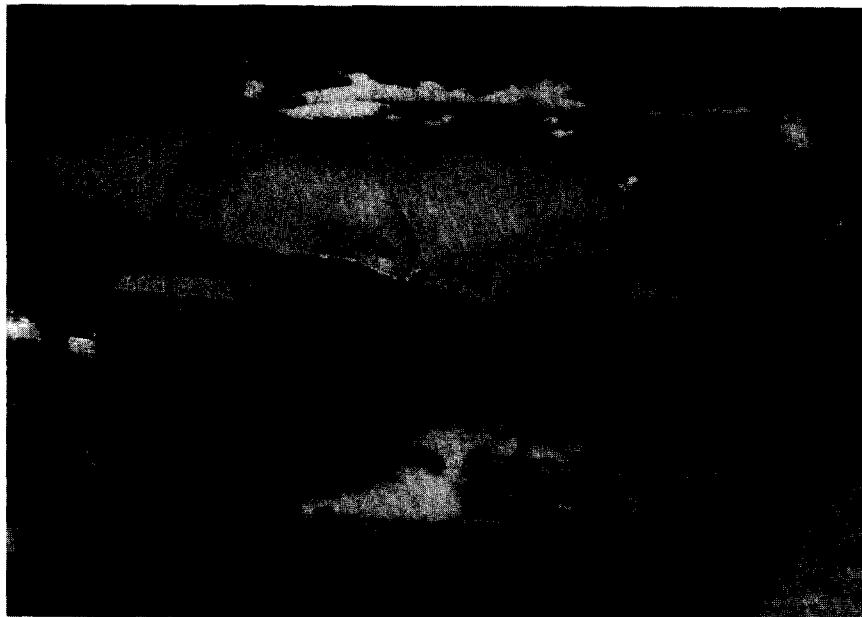


Fig. 17. Elderly unbelted driver was briefly concussed from sun visor contact. Multiple hand abrasions from air bag contact.

tion. She also had contusions to the top of her right hand (glove box area) and a laceration inside her mouth (teeth); MAIS 1.

ADDITIONAL FINDINGS

A variety of interesting anecdotal cases are relative to air bag deployments.

1. The driver thought that the illuminated air bag light on the instrument panel (the fault indicator) was an indication that the car was equipped with an air bag.

2. The air bag deployed at a relatively minor impact. The owner/driver did not want to report this event to the insurance company. Therefore he repacked the air bag into the steering wheel container and taped the air bag in place.

3. A female driver wore gloves made of synthetic material that melted in the area of the base of the thumb caused by escaping gasses from the bag vent port on the back side of the bag.

4. It was reported that dealership personnel told the customer that the air bag would not deploy unless the safety belt was fastened.

5. Infrequently, immediately following the crash, a haze is produced when the air bag deploys. Drivers and good Samaritans thought that these cars were on fire.

6. Some believe that exposure to an air bag deployment will cover the occupants with hazardous and poisonous gasses and residue requiring special

precautions to be taken by EMT and fire rescue personnel.

BAG-INDUCED INJURIES

In a number of cases the occupants sustained facial erythema (redness) or face/neck abrasions due to the air bag deployment. Figures 18 and 19 illustrate the worst of the minor facial injury cases that we have studied to date. We have however, identified a few cases of eye abrasions (corneal abrasion, sclera laceration) due to interaction with the air bag. However, in the newer model cars, facial abrasions are being noted less frequently.

DISCUSSION

As might be expected, the air bag is performing well, even in very severe frontal crashes. However, we do have the outliers of survival of the elderly in severe frontal crashes, to the few cases of abrasions of sclera. Additionally, it must be pointed out that there have been very few papers presented in the medical literature on injuries related to the air bag, and most of those detailed eyeball injuries (Beckerman and Elberger 1991; Larkin 1991; Lubeck and Green 1988; Mishler 1991; Rimmer and Shuler 1991; Steinman 1992). It appears that most individuals sustain but minor injuries when the air bag deploys. In our series many of the crashes were nonspectacu-

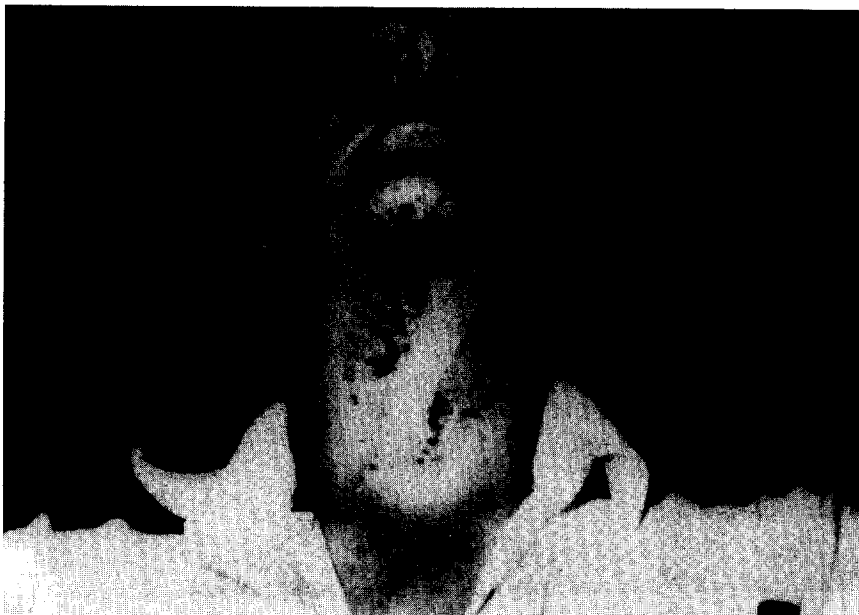


Fig. 18. Under chin crusted abrasion from the first generation air bag.

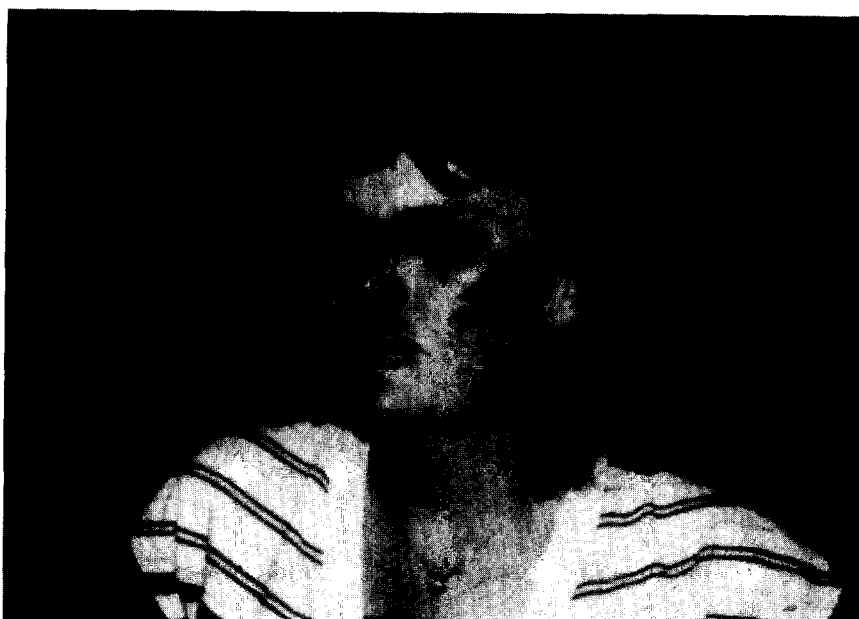

Fig. 19. Drivers had turned her head to the right preimpact. Abrasions to upper lip and left cheek from air bag contact.

lar and therefore one would not expect a high injury level.

In those cases where the 3-point belts were worn, injuries were at the AIS-1 level. Such injuries are mainly contusions to the knees and legs from contact with the lower instrument panel; contusions to the abdomen, chest, or shoulders from the belt webbing; and cervical or lumbar strain. If facial air bag injuries were noted, they were minor, consisting of facial or throat erythema or abrasions.

The damage profiles on some of the crashed cars were similar. In some the drivers were belted, in others they were unrestrained. In the cases of the unrestrained drivers they had primarily AIS-1 level injuries, but in each of these cases there were more AIS-1 injuries, and in a third of these unbelted drivers, an occasional AIS-2 injury.

We believe that only by field investigations can the actual effectiveness or the potential for injury reduction by the air bag be determined. The air bag has proven its role as a supplemental restraining system to the 3-point lap-shoulder belt for reducing facial injuries caused by contact with the steering assembly, and in the higher speed crashes the air bag offers additional protection the head, neck, and torso. Data on air bag effectiveness in other than the frontal crashes are basically nonexistent, although a few cases have been identified. Because of this there is a need for an ongoing investigative program. Most important, we believe, such an activity not only identifies the effectiveness of the air bag system, but

identifies some of the outliers, i.e. the lifesaving effectiveness of air bags in high-speed crashes or the unexpected and unusual events related to air bag deployment. These outlier types of cases cannot be directly studied in the laboratory or with planned car crashes with dummies.

In our studies we have found that over 75% of occupants involved in air bag crashes were wearing the 3-point restraint, and together they provided significant occupant protection. Needless to say, in other than frontal crashes, the air bag cannot be expected to be the primary or significant restraint system, and reliance must be made on the available lap-shoulder belt.

In a study of the seating positions of drivers in simulated laboratory car environments, it was found that the driver's chin can be as close as 240 mm to the steering-wheel hub under normal driving conditions (Schneider et al. 1991). Additional forward movement of the driver's head may occur during a crash but prior to full air bag deployment, particularly in low-speed impact near the threshold of air bag sensor firing. Cases involving facial erythema or abrasion may therefore occur when the face of the driver is less than 240 mm from the wheel hub at the time of facial interaction with the deploying air bag. Additionally bag leading-edge velocity, whether at full pressure or shear action developed when undergoing inflation; bag excursion; bag depth; bag denier; etc. may all play a role in the production of the minor facial injuries noted in this study.

REFERENCES

- Beckerman, B.; Elberger, S. Air bag ear. *Ann. Emerg. Med.* 20:195-196; July 1991.
- Huelke, D. F.; Roberts, J. F.; Moore, J. L. Air bags in crashes. 13th Intl. Tech. Conf. on ESV, Paris, France, 91-S1-W-19, 1991.
- Huelke, D. F.; Moore, J. L.; Öström, M. Air bag injuries and occupant protection. *J. Trauma* 33:894-898; 1992.
- Larkin, G. L. Airbag-mediated corneal injury. *Am. J. Emerg. Med.* 9:444-446; 1991.
- Lubeck, D.; Greene, J. S. Corneal injuries. *Emerg. Med. Clin. North Am.* 6:1, 73-94; 1988.
- Mishler, K. E. Hyphema caused by air bag. *Arch. Ophthalmol.* 109:1635; 1991.
- Rimmer, S.; Shuler, J. D. Severe ocular trauma from a driver's-side air bag. *Arch. Ophthalmol.* 109:774, 1991.
- Reed, M. P.; Schneider, L. W.; Burney, R. E. Investigation of airbag-induced skin abrasion. *Proc. 36th Stapp Car Crash Conf.*, 1992 Warrendale, PA; pp 1-12.
- Steinmann, R. A 40-year-old woman with an air bag-mediated injury. *J. Emerg. Nurs.* 18(4):308-310; August 1992.