

# NORTH AMERICAN BLASTOMYCOSIS

ARTHUR C. CURTIS, M.D., AND FLORANTE C. BOCOBO, M.D.

ANN ARBOR, MICH.

*From the Department of Dermatology and Syphilology, University of Michigan Medical School*

(Received for publication Nov. 26, 1956.)

**N**ORTH American blastomycosis (Gilchrist's disease) is a granulomatous, infectious disease caused by the fungus, *Blastomyces dermatitidis* (Gilchrist and Stokes, 1898). The malady, in its cutaneous form, was first described by Gilchrist<sup>1</sup> in 1894. A few years later, together with Stokes, he was able to isolate and culture the causative organism which he designated as *B. dermatitidis*.<sup>23</sup> The first description of the disease in its systemic form was made by Walker and Montgomery<sup>4</sup> in 1902.

The first reports by Gilchrist were followed by an era of confusion during which the disease was confounded with other entities, particularly cryptococcosis and candidiasis, all caused by morphologically similar budding organisms. Nineteen new names were suggested for the causative fungus. During the last two decades, however, a clearer picture of the disease process has emerged, particularly as a result of studies by the Duke Medical School group, headed by Smith, Martin, and Conant. Numerous clinical and laboratory reports have contributed significantly to a fuller understanding of the disease, but there are still some fundamental questions to be answered. Excellent review articles on North American blastomycosis are available.<sup>5-18</sup>

## GEOGRAPHICAL DISTRIBUTION

Martin and Smith<sup>9</sup> found in 1939 that 98 per cent of 340 proved cases of blastomycosis had the origin of their disease within the United States. Of the two cases originating elsewhere, one was from Canada<sup>19</sup> and the other from England.<sup>20</sup> Presumptive cases were reported from the Philippines, Egypt, and Russia, and inadequately described cases from Canada, Puerto Rico, Costa Rica, Russia, England, China, South America, France, and Mexico.

The majority of patients who develop blastomycosis in the United States come from the Southeastern and the Midwestern states. Sporadic cases have been reported from all states. Schwarz and Goldman,<sup>21</sup> in a recent questionnaire survey sent to 1,569 dermatologists and 403 chest surgeons throughout the United States, had reported to them 101 cases of North American blastomycosis diagnosed and/or treated during the first 6 months of 1953. They considered the disease to be common throughout the United States. The presence of blastomycosis in Canada has been confirmed beyond doubt by a number of relatively

recent reports.<sup>11,22-26</sup> On the other hand, acceptable evidence for its indigenous occurrence in Mexico is still lacking. Martinez-Baez<sup>27</sup> proved an infection by *B. dermatitidis* in a Mexican farmer with demonstration of the organism. His claim that the infection in this patient was native to Mexico, however, was made less tenable by the fact that the patient worked as a migratory worker for 8 months in California 4 years prior to the onset of clinical symptoms.

Case reports from countries outside the North American continent appear from time to time in the literature. With an increasing general interest in and knowledge of medical mycology, more physicians are aware of the possibility of the occurrence of North American blastomycosis in their own countries. Proved or presumptively proved cases have recently been reported from India,<sup>28,29</sup> Spain,<sup>30</sup> Germany,<sup>31</sup> Hungary,<sup>32</sup> Tunisia,<sup>33,34</sup> Venezuela,<sup>35</sup> Italy,<sup>36</sup> and Australia.<sup>37</sup> Modern facilities for travel, affording greater opportunities for individuals from endemic areas to develop disease in other parts of the world, complicate the situation, as exemplified by case reports of North American blastomycosis among U. S. Armed Forces personnel at foreign stations in France,<sup>38</sup> Okinawa,<sup>39</sup> and Japan.<sup>40</sup>

#### EPIDEMIOLOGY

The precise mode of infection is not yet fully known. It is generally presumed to be exogenous, with the infective saprophytic form of the organism existing in nature. Unlike *Coccidioides immitis*, *Histoplasma capsulatum*, *Cyptococcus neoformans*, and *Sporotrichum schenckii*, *Blastomyces dermatitidis* has not been indubitably isolated from nature. Stober<sup>6</sup> claimed the isolation of an organism similar to *B. dermatitidis* from a rotting wooden plank in the home of one of his patients but this has not been confirmed. Nonetheless, the soil is strongly suspected as the natural reservoir of the organism. Emmons<sup>41</sup> successfully cultured *B. dermatitidis* in sterilized soil in the laboratory.

The occurrence of natural infection in dogs<sup>42-45</sup> and horses<sup>46</sup> suggests the existence of animal reservoirs. The organism has not as yet been isolated from wild animals. With the latest report of Newberne, Neal, and Heath,<sup>45</sup> a total of 30 cases of canine North American blastomycosis have been described in the literature. Apparently the disease pattern in dogs is similar to that in man. Pulmonary and cutaneous involvement were the most salient findings. The sole report of infection in a horse dealt with involvement of the udder of a mare proved by histopathologic sections.

The manner of transmission of the disease has remained a provocative problem. The infectivity of *B. dermatitidis* (Figs. 1 and 2) has been proved beyond any reasonable doubt by successful animal inoculation with either the mycelial or yeast phase of the organism.<sup>47-49</sup> Lesions on the chorioallantoic membrane of the chick embryo have been produced with the yeast phase.<sup>50</sup> Open skin lesions and body secretions or exudates, such as sputum and pus that gain access to the outside, teem with the tissue forms of the organism and provide excellent opportunities for contagion. Yet no direct natural transmission from man to man has been acceptably proved. A few, isolated cases of accidental mechanical inoculation through a break in the skin have been reported in laboratory

Fig. 1.

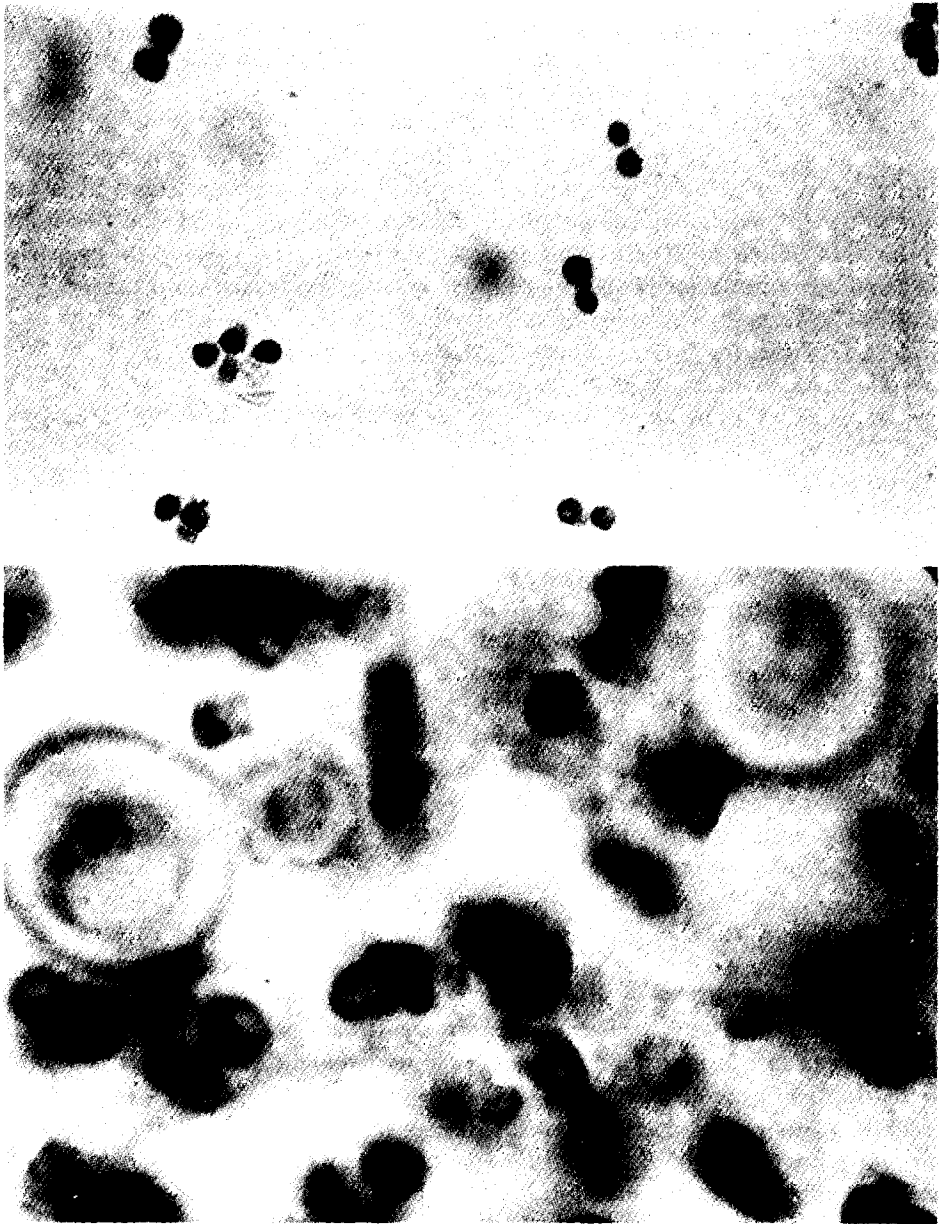


Fig. 2.

Fig. 1.—*Blastomyces dermatitidis*, yeast phase on blood agar, incubated at 37° C. showing single budding of the yeast cells or organisms shortly after budding has occurred. Occasionally single abortive hyphae may be seen extending from the yeast cells in a tubelike manner. ( $\times 450$ ; reduced  $\frac{1}{4}$ .)

Fig. 2.—*Blastomyces dermatitidis* in tissue showing budding, double-refractive cellular walls and granulomatous infiltrate. The yeast cells are similar to Fig. 1 or to those seen here when a direct mount is made from pus, from the border of a granulomatous lesion or from an abscess, except for the abundance of associated polymorphonuclear cells. ( $\times 1,500$ ; reduced  $\frac{1}{4}$ .)

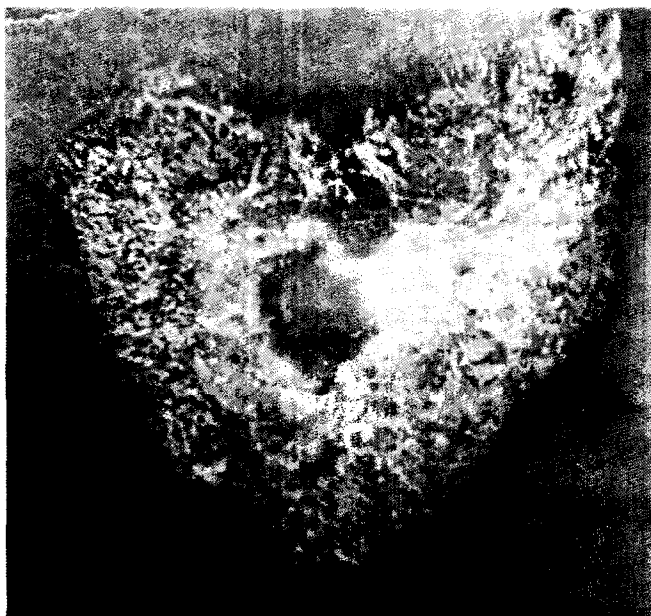


Fig. 3.

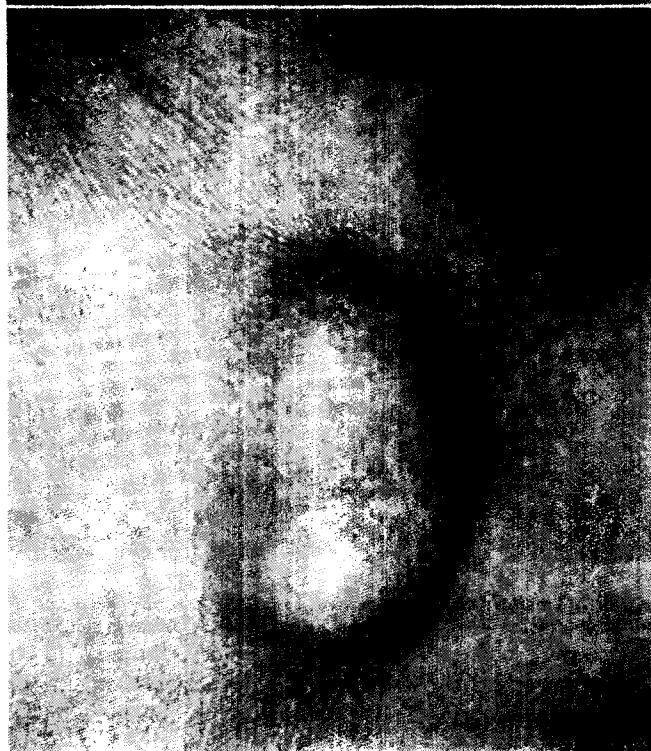

Fig. 4.

Fig. 3.—A typical granulomatous lesion of the skin due to North American blastomycosis. The border is raised, verrucous, and sharply limited. Tiny abscesses make up this border and pressure on them with a glass slide emits pus which allows direct examination and early diagnosis by identifying the single budding organisms. The center shows various degrees of scarring depending on the duration of the lesion.

Fig. 4.—An abscess due to North American blastomycosis arising from the bony sternum and following a blastomycotic pneumonia by some weeks. Later other lesions appeared of the granulomatous as well as the abscess type.

workers and pathologists<sup>13,51,52</sup> handling cultures or infected clinical material. Schwarz and Baum<sup>53</sup> did not encounter a Blastomycin skin test reactor among 58 hospital workers and 48 home contacts in close association with patients having active disease. He opined that *B. dermatitidis* possesses a low index of contagiousness.

The skin and lungs are looked upon as the most probable entry of the infection. Appearance of initial skin lesions (Fig. 3) have been preceded by skin injury from thistles, thorns, slivers, nails, cinders, clams, and dog bites. This antecedent trauma has been regarded as a predisposing factor. As a result of their review of 60 cases, Schwarz and Baum<sup>13,54</sup> proposed a revolutionary concept to which we also subscribe: that practically all cases of North American blastomycosis are pulmonary in origin, including most cases hitherto regarded as primarily cutaneous.(Fig 4.) Consequent to this thesis that the disease is essentially a pulmonary infection, a parallelism between the disease pattern of North

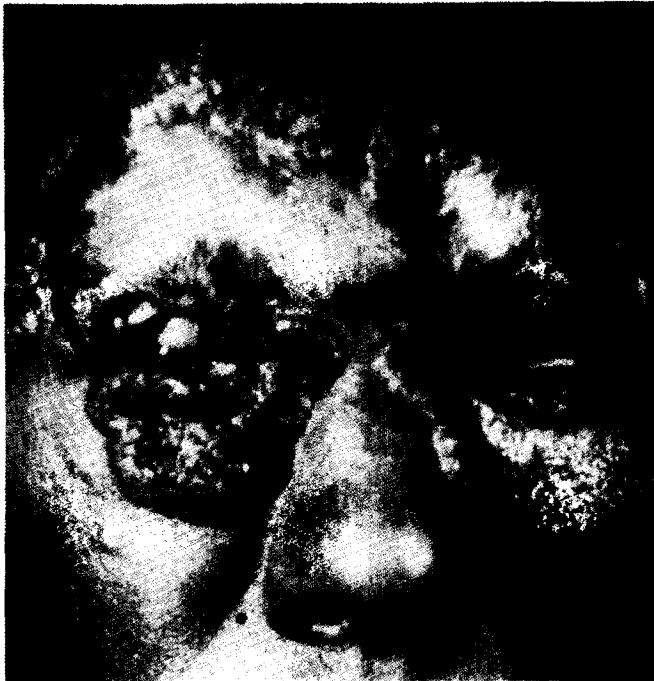

Fig. 5.—Typical North American blastomycosis with scarring, atrophy, activity, and healing. The "centrifugal character of growth" of the granulomatous lesions is well illustrated.

American blastomycosis and those of coccidioidomycosis and histoplasmosis was drawn.<sup>55,56</sup> Studies on the two latter mycoses have proved the occurrence of two clinical forms—the frequent, benign, primary type and the rare, generalized, fatal form (Figs. 5 and 6). Primary infection is usually by inhalation of infective spores. If the evolution of the epidemiologic knowledge on North American blastomycosis were to follow that of coccidioidomycosis and histoplasmosis, it is essentially still at the stage where only the rare, fatal, disseminated disease

is known for certain. Coccidioidomycosis and histoplasmosis were recognized in this form long before the discoveries of the mild primary infections. In an attempt to demonstrate the existence of a prevalent benign North American blastomycosis, Furcolow and associates<sup>55</sup> conducted a skin test survey with tuberculin, Histoplasmin, and Blastomycin among 7,194 school children in Hamilton County, Ohio. No supporting evidence was obtained. The 12 per cent positive reactions to Blastomycin were regarded as cross reactions to Histoplasmin. Only one child was a Blastomycin reactor with a negative Histoplasmin reaction. The possibility of the occurrence of widespread, mild infections cannot be dismissed on the strength of negative results of skin test surveys alone. Subclinical and spontaneously healing cases of North American blastomycosis have been reported.<sup>15,17,57</sup> A more significant development is a report of the appearance of the disease in an epidemic form. Bonoff<sup>39</sup> reported 23 cases of acute pulmonary blastomycosis among the U. S. Army personnel in Okinawa,

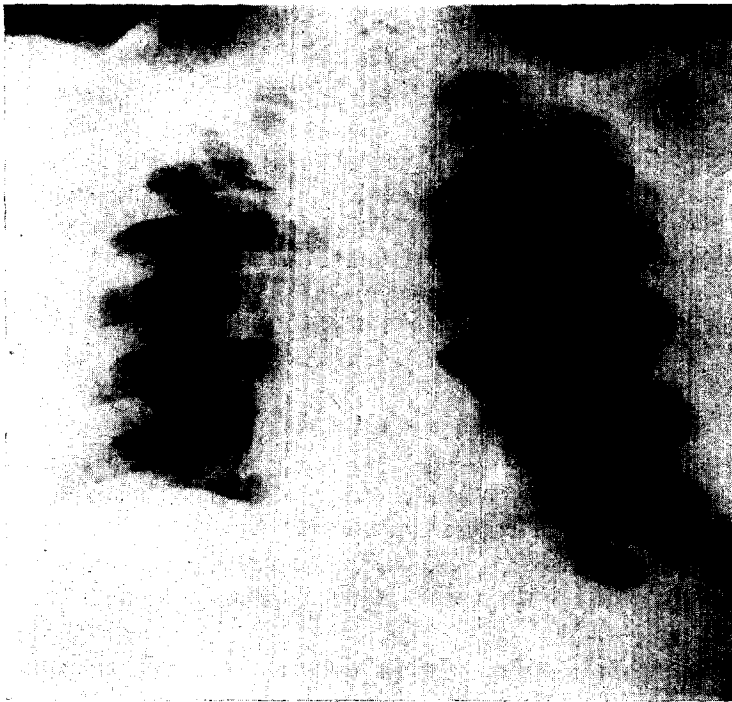


Fig. 6.—Chest of A. W. (Table I) showing both right and left upper lobe involvement with North American blastomycosis. His chest cleared with some scarring after 3.0 Gm. of stilbamidine methionate and he has remained free of the disease since 4 years and 8 months. He is now alleged to have far-advanced tuberculosis of the lungs. (From Curtis and Harrell, A. M. A. Arch. Dermat. & Syph. **66**:676, 1952.)

but unfortunately, his claims of demonstration of *B. dermatitidis* in the sputum and urine were not authenticated by cultures. A verified epidemic was observed by Smith and his associates<sup>57</sup> in Grifton, Pitt County, North Carolina. The sudden appearance of 10 pulmonary cases in the locality provided an excellent opportunity for epidemiologic investigations. A survey of the town population revealed a number of individuals with positive Blastomycin and negative Histoplasmin skin tests. The source of infection, however, was not traced.

## CLINICAL FEATURES

*Age.*—The infection may appear in any age group. The youngest recorded patient with proved North American blastomycosis was 5 months old.<sup>57</sup> Kunkel and his colleagues<sup>15</sup> and Sutliff, Kyle, and Hobson<sup>16</sup> each had an 84-year-old patient in their own series. Most cases, however, occur between the ages of 30 and 50 years and the average age of incidence falls within the fourth decade of life.

*Sex.*—The disease is definitely more common in men than in women. The reported ratio of men to women ranges from 4.3:1 to 15:1. The reason for this sex distribution is presumed to be the greater exposure of men to infection by reason of their occupations and other activities.

*Race.*—No race is immune. The racial distributions in the different reported series of cases probably mirror the normal proportions of the races in the general population of the given locality.

*Occupation.*—Many authors regard North American blastomycosis as a disease of the poorer working class, who have more exposure to dust, soil, wood, and vegetation. However, no special occupational relationships can be definitely claimed for the disease.

*Signs and Symptoms.*—Since Gilchrist's first report and the demonstration a few years later by Walker and Montgomery of systemic involvement, North American blastomycosis has been classically divided into the localized cutaneous and the disseminated forms. The two types are divergent in clinical course, prognosis, and response to therapy and were thought to be due to different portals of the infection. The studies of Schwarz and Baum<sup>13,54</sup> and Wilson and his associates<sup>52</sup> change this older concept and align blastomycosis more closely with coccidioidomycosis.

*Cutaneous Form.*—The skin lesion usually first appears as an innocuous-looking papulopustule on some exposed area of the body, most frequently the face, wrists, hands, ankles, and feet (Fig. 7). The scalp, palms, soles, and mucous membranes are generally not affected. No portion of the body surface, however, may be considered absolutely exempt. The initial lesion enlarges slowly and may take months, even years, to develop into a fullblown, verrucous, ulcerative granuloma. A typical lesion is elevated and crusted. Upon removal of the crusts, surface bleeding is easily induced. The surface is wartlike with irregular papillary elevations bathed in a seropurulent discharge. The most characteristic feature is the border which is elevated, sloped abruptly into, and sharply delineated from, the adjacent normal skin, violaceous in color, and pin-pointed with miliary abscesses. The lesion extends peripherally and as it increases in size, the central portions tend to heal with formation of soft, thin, atrophic scars. This central scar may still exhibit miliary abscesses which may act as foci of recurrences.

The lesions may be single or multiple. If multiple, they often are in close proximity to each other, but may be remote from one another. They are arciform in configuration, and coalesced lesions present serpiginous contours. The

usual size is from 3 to 4 inches in width, but may attain surprising dimensions up to 12 inches, involving the trunk or whole extremities. The regional lymphatics are seldom involved in this form. (Fig. 8.)




Fig. 7.—A patient with North American blastomycosis treated by curette and cautery followed by fractional roentgen ray therapy totaling 480r in air. Since most North American blastomycosis is a systemic disease, this form of therapy is rarely curative although it was in this instance.

Subjective symptoms are relatively mild, or even absent, and the general health of the patient is unimpaired except in the presence of secondary bacterial infections. The clinical course is marked by chronicity with long periods of remissions and recrudescences.



Contrary to prevailing opinion, Schwarz and Baum<sup>13,56</sup> considered the vast majority of the skin lesions described above as secondary to a healed or undiscovered primary focus in the lungs. This conception is gaining more proponents.<sup>15,52</sup> Wilson and associates<sup>52</sup> suggest, and we concur in the opinion, that cutaneous North American blastomycosis is a rare, but distinct clinical entity, represented so far only by 4 proved cases of definite cutaneous inoculation of




Fig. 8.—A patient with North American blastomycosis of the wrist, ankle, back, and lungs treated with 3.0 Gm. of stilbamidine (A. W., Table I) who rapidly recovered and 4 years and 8 months later had no evidence of recurrence. The wrist lesion before treatment is typical of the disease. The scarring following treatment in the second photograph is also typical. One should remember that the lungs or other organs may also scar. Neither stilbamidine nor 2-hydroxystilbamidine give a satisfactory amount of "cure" in systemic North American blastomycosis.

the organism with later chancre formation and regional lymphatic involvement. In tuberculosis, syphilis, yaws, sporotrichosis, coccidioidomycosis, and cat-scratch fever such a chancriform syndrome is expected.

*Systemic Form.*—This can involve any organ of the body but probably begins in the pulmonary tract most frequently. The presenting signs and symptoms depend upon the organ or organs affected and the extent of involvement. There is no clinical syndrome characteristic of the systemic disease, the clinical picture being that of any chronic infection with suppuration or fibrosis of the different organs. The tissues most frequently involved are the lungs, skin, subcutaneous tissues, and bones. The least commonly affected is the gastrointestinal tract. Many patients, especially in the advanced stages of the disease, demonstrate involvement of multiple organ systems.

The onset is frequently associated with respiratory symptoms of cough, productive sputum, hemoptysis such as may be found in other lung infections, whether bacterial, viral, or rickettsial. It usually begins insidiously, but in certain instances it may be an acute and fulminant<sup>55,59,60</sup> and blastomycotic pneumonia. The symptoms consist of chills, fever, productive cough, hemoptysis, chest pain, loss of weight, night sweats, and dyspnea. These may be transient and so mild as to be missed by the patient, but they may progress to dominate the clinical picture, which is so easily mistaken for pulmonary tuberculosis, carcinoma, or abscess. The infection may even assume a miliary form. The mediastinum and the pleura may be involved and the formation of sinuses through the chest wall may occur. The physical signs depend upon the nature of the lesion and are often those of consolidation with fullness, increased vocal fremitus, decreased breath sounds, and râles. Progressive cases eventually acquire the appearance of any chronic, generalized, debilitating infection with inanition, anemia, and extreme loss of weight and strength.

With progression, the disease disseminates from the pulmonary focus. Dissemination may happen even when the primary lesion shows a tendency to involute, as demonstrated by Schwarz and Baum.<sup>13</sup> In this case, the patient first seeks medical care for complaints referable to the organs secondarily affected via hemotogenous spread. The pulmonary focus may escape clinical recognition and be discovered only on autopsy or by a chance culture of the sputum in the face of negative x-rays.

In a number of instances, secondary involvement of the skin appears as the first sign of systemic disease. The lesions develop in unexposed parts of the body, like the trunk, as painful, deep subcutaneous nodules. These are actually abscesses with a marked tendency to break through the skin and assume the characteristics of the lesions described as primary cutaneous.

Involvement of the skeletal system is not uncommon. Martin and Smith,<sup>9</sup> Reeves and Pedersen,<sup>61</sup> Cherniss and Waisbren,<sup>18</sup> and Kunkel and associates<sup>15</sup> found the incidence of osseous and arthritic involvement in their own series 50, 47, 53, and 31 per cent, respectively. The symptoms, mainly pain and loss of function, are those of localized or diffuse osteomyelitis or periostitis and septic arthritis. In 63 cases reviewed by Jones and Martin,<sup>62</sup> 13 patients complained initially of arthritic pains in the back or one of the extremities. The ribs, vertebrae and skull bones, and the intervertebral knee, and elbow joints are more

commonly invaded. Invasion is attained either by direct extension or hematogenous metastasis. Blastomycosis of the vertebral axis simulates spinal tuberculosis with extensive bone destruction, marked narrowing of the disc space, vertebral body collapse, and associated paravertebral infection that may be manifested clinically as a psoas abscess.<sup>63</sup> In the long bones, the disease process tends to involve the epiphyses and extend directly to the adjacent joints.

Involvement of other organs is less frequently encountered. Cases affecting the genitourinary tract were reviewed by Moore and Halpern,<sup>64</sup> and Schwarz and Baum.<sup>13</sup> Symptoms listed were pyuria, hematuria, dysuria, prostatic enlargement, dribbling, and urinary retention. The female genital organs are also involved, though rarely.<sup>65</sup> Noojin and Praytor<sup>66</sup> recently recorded a patient who developed systemic blastomycosis during the second trimester of her pregnancy. A normal child was born.

Blastomycosis of the central nervous system is rather uncommon.<sup>9,13</sup> Depending upon the nature and location of the lesions, localizing symptoms of single or multiple abscesses in the brain or the spinal cord and manifestations of focal or diffuse meningitis are obtained.

Other seats of infection occasionally described are the eyes,<sup>67-69</sup> larynx,<sup>15,71,72</sup> gastrointestinal tract, adrenals, and thyroid.

*Roentgenography.*—Although sometimes a blastomycotic process may be suspected from a roentgenogram, there is no single diagnostic feature in the roentgenographic appearance of the disease. The pulmonary picture varies considerably from acute bilateral, massive, pneumonic consolidations to the small fibrotic, strandlike lesions of the quiescent stage.<sup>11,15,18,73-76</sup> Other lesions described are small patchy pneumonitis, lobular consolidation, mass granulomas located near the hilum and projecting into the lung fields with irregular outlines like neoplasms, "coin" lesions, lobar atelectasis, pleural thickening with or without effusion, small infrequent cavitations with thin walls and hazy outlines, and miliary shadows. Hilar and mediastinal lymphadenopathy with or without parenchymal involvement is frequent. The roentgenographic findings are usually mistakenly diagnosed as pulmonary tuberculosis or neoplasm. The other pulmonary conditions considered for differential diagnosis are acute pneumonias, lymphoblastoma, sarcoid, and pneumoconiosis. We have also seen pulmonary symptoms, productive and slightly bloody sputum, and a positive culture in the face of negative anteroposterior, lateral x-ray films, and a negative bronchoscopic examination.

When systemic disease is suspected, roentgenographic examination of the skeletal system is advisable. The picture of osseous involvement is, like the pulmonary, nonspecific.<sup>73,77,78</sup> The appearance is pre-eminently that of bone destruction with little or no proliferative reaction or new bone formation. The areas are punched out with sharp delineation from the adjacent normal bone. The lesions, however, are less cystlike than those occurring in coccidioidomycosis. In the long bones, these areas are located frequently at or near the epiphyseal lines and the plates may reveal any associated joint involvement. Extensive destruction of the vertebral bodies causes collapse with compression of the spinal cord. A bulging of the psoas shadow suggestive of the presence of a psoas abscess may be present.

Roentgenographically, blastomycosis of the bone may be confused with tuberculosis, sarcoma, coccidioidomycosis, actinomycosis, syphilis, myeloma, and bone cysts.

*Clinical Laboratory Examinations.*—The findings are those of infection. There is leukocytosis and neutrophilia, particularly in the presence of secondary bacterial infection. The erythrocyte sedimentation rate is increased. When the disease is sufficiently long-standing, hypochromic anemia develops. Blood cultures are very rarely positive, even though Schwarz and Baum<sup>13</sup> in their histopathologic examinations were able repeatedly to demonstrate the organisms in the blood vessels of even uninvolved organs.

#### PATHOLOGY

Pathologically, North American blastomycosis is a suppurative granuloma with a very close resemblance to tuberculosis. The gross appearance of the skin lesions and the tubercle-like nodules and abscesses in soft tissues and visceral organs is typical of the disease. The pulmonary lesions vary. There may be focal or diffuse pneumonic consolidation, formation of single or multiple abscesses, and miliary distribution of small tubercle-like nodules. Cavities are claimed to be infrequent and usually small, although dimensions up to 7 cm. in diameter may be attained.<sup>78,79,80</sup> Schwarz and Baum<sup>13</sup> encountered a relatively high incidence of adhesive pleuritis, endobronchial lesions, and regional lymphadenopathy. They repeatedly found evidences of scarring and healing.

The bone lesions are essentially destructive in nature, with formation of abscesses, separation of sequestra, and development of chronic discharging sinuses through the overlying tissues and skin.

Dissemination apparently occurs through the lymphatic and hematogenous routes and by direct extension.

Baker<sup>81</sup> has detailed the reaction of the body tissues to invasion by *B. dermatitidis*. This response is essentially granulomatous, with varying combinations of suppuration, necrosis, and fibrosis. The typical microscopic picture is that of a tubercle-like lesion with epithelioid cells, plasma cells, lymphocytes, polymorphonuclear leukocytes, multinucleated giant cells, cellular debris, and the tissue forms of the organism itself. The proportion of the different cellular infiltrates to each other varies from case to case depending more upon the stage of the disease than the location of the lesion. In the more chronic cases, lymphocytic infiltration and fibrosis, showing attempts of healing, predominate; while in the more acute stage, where frank abscesses occur, the polymorphonuclear leukocytes overwhelm the granulomatous infiltrate. The granulomatous nature of the lesion may even be absent, as illustrated by the cases of primary inoculation cutaneous blastomycosis described by Wilson and his colleagues.<sup>52</sup> Histopathologic sections of the skin lesions demonstrate a dense inflammatory infiltrate of lymphocytes and polymorphonuclear leukocytes with numerous blastomycetes. The overlying epidermis in one of the cases was normal, in contrast to the pseudoepitheliomatous hyperplasia commonly observed in the other types of skin lesions.

The mimicry by North American blastomycosis of the tissue reactions of tuberculosis is so close that many authors consider them indistinguishable on a morphologic basis alone. Several,<sup>15,81</sup> however, hold the presence of pyogenic microabscesses and fibrosis as ground for strong suspicion and vigorous search for the casual organism. Caseation necrosis is not so frequent and characteristic as in tuberculosis. The identifying landmark in the histologic picture is the tissue form of the organism which may be seen scattered among the infiltration cells, between the tissue cells, or in the giant cells. The number of organisms in a given lesion varies. The lesion may teem with the organisms or may show rare ones only after diligent examination of many sections. The organisms appear in histopathologic preparations as spherical or oval bodies ranging usually from 5 to 20  $\mu$  in diameter. The cell walls are sharply delineated and thick, with a double-contoured appearance. The cytoplasm is granular and vacuolated. Single budding forms are often encountered, although in certain instances they may be very difficult to demonstrate. The daughter bud usually rests on a broad base.

Staining with the periodic acid-Schiff method of Hotchkiss and McManus is a valuable adjunct in the demonstration and study of the organisms in tissue sections.<sup>82,83</sup> It is only supplementary, however, to cultural identification.

The tissue forms of *Blastomyces dermatitidis* must be differentiated from those of the other systemic fungi, *Histoplasma capsulatum*, *Coccidioides immitis*, *Blastomyces brasiliensis*, *Candida albicans*, and *Cryptococcus neoformans*. *Histoplasma capsulatum* is distinguished by its smaller size of 2 to 5  $\mu$  in diameter and intracytoplasmic location in the reticuloendothelial elements of the body. On the other hand, the nonbudding, endosporulating spherules of *Coccidioides immitis*, when mature, are much larger with a range of 20 to 80  $\mu$  in diameter. *Blastomyces brasiliensis* is also larger, having diameters up to 60  $\mu$  and characterized by multiple budding. The buds are connected by narrower processes and may be found all along the periphery of the mother cell. The budding yeast forms of *Candida albicans* are associated with filamentous pseudohyphae. Hyphal elements of *Blastomyces dermatitidis* have not been demonstrated in tissues. *Cryptococcus neoformans* possesses a remarkably thick capsule well seen in India ink preparations.

The distinguishing features cited above are true for typical cases. However, in certain instances differentiation may be very difficult. This is true with histoplasmosis when occasional miniature forms of *Blastomyces dermatitidis*<sup>13,84-88</sup> or giant forms of *Histoplasma capsulatum*<sup>89</sup> do occur. The budding of *Blastomyces dermatitidis* may not be demonstrated, which may cause mistakes in diagnosis inasmuch as the nonbudding forms simulate the immature endospores of *Coccidioides immitis* of the same size. *Blastomyces brasiliensis* with single buds<sup>90</sup> is easily mistaken for *Blastomyces dermatitidis* which, furthermore, may even rarely show multiple budding. *Cryptococcus neoformans* may occasionally be denuded of its thick capsule, depriving the examiner of this differentiating point. These different situations emphasize the essentiality of cultural procedures in recognizing these fungi.

## DIAGNOSIS

As previously stated, there is no diagnostic pattern in the clinical history and manifestations of North American blastomycosis. Even the typical cutaneous granuloma is only suggestive. Clinical diagnosis based on history and physical findings is, at most, presumptive and made unequivocal only by positive demonstration and identification of the causative organism in the laboratory. The procedures are neither elaborate nor expensive, and the only essential requisite is familiarity with *B. dermatitidis*.

*Direct Microscopic Examination.*—The specimens examined with this procedure are fresh, allegedly infected clinical materials such as pus, sputum, urine, cerebrospinal fluid, scrapings from skin lesions, prostatic fluid and effusions. The clinical means of obtaining these specimens, such as aspiration of subcutaneous abscesses and of joints, spinal tap, prostatic massage, and collection of urine and sputum samples, are standard. Specimens from cutaneous lesions are best obtained by rupturing the small abscesses on the active borders and collecting the exuding purulent material. Weisel and Landis<sup>75</sup> have recommended bronchoscopy as a diagnostic aid in pulmonary blastomycosis. Acree, Decamp, and Ochsner<sup>91</sup> were able to establish the presence of an acute blastomycotic lung abscess by needle aspiration.

Wet mounts of the specimens are prepared on slides with 10 per cent potassium hydroxide in order to "clear" the preparation. Spinal fluid, urine, and other less cellular specimens are mounted directly. These cover slip preparations are examined under the microscope with subdued light. The organisms appear as previously described in stained sections, with the added feature of refractility of the thick, double-contoured walls. They may be difficult to find and may be confused with other cellular elements, air bubbles, or oil droplets. Failure to demonstrate the organism by direct examination of fresh mounts does not necessarily rule out blastomycosis.

*Cultural Procedures.*—Even when the tissue phase of *B. dermatitidis* is recognized in fresh or stained specimens, it is a wise policy to confirm this by isolation and identification of the organism in cultures. All specimens for laboratory examination should be subjected to cultural procedures. Positive identification of the organism by cultural means from suspected clinical specimens makes the clinical diagnosis practically indisputable in view of the rarity of isolating of *B. dermatitidis* from nature or from uninfected individuals.

The specimens are planted on Sabouraud's dextrose agar for incubation at room temperature and on blood agar or beef infusion dextrose agar at 37° C. The addition of streptomycin and penicillin to the media helps in keeping down bacterial contamination. When contaminants are present, subcultures of suspicious colonies should be made to avoid overgrowth by the faster developing contaminants. The growth generally takes 10 days to 3 weeks to appear, but this period may be as brief as 3 days or may extend to 5 weeks, so that it is advisable to keep the cultures for at least 5 to 6 weeks before discarding.

*Blastomyces dermatitidis* grows in its mycelial phase at room temperature. It develops as a white, cottony aerial growth or as a folded, membranous colony

with spiny, coremial projections from the surface. The colonies tan with age. Microscopic examination reveals numerous round, oval or pyriform conidia measuring 3 to 5 microns in diameter and borne singly on short lateral sterigmas. These small spores are easily broken off from their attachments and are found lying free in wet mounts made from cultures. At 37° C. on blood agar or beef infusion dextrose agar, the growth is slower. The colonies are small, heaped up, waxy, and relatively easy to pick up from the surface of the agar. Microscopic examination reveals the single budding tissue phase, not infrequently associated, however, with short abortive hyphal filaments. The mycelial phase at room temperature and yeast phase at 37° C. are reversible, depending upon the temperature of incubation. This biphasic character of *Blastomyces dermatitidis* is valuable in its cultural differentiation from other pathogenic fungi, inasmuch as it automatically rules out organisms like *Coccidioides immitis*, *Cryptococcus neoformans*, and *Candida albicans*, capable of growing only in one form in ordinary culture media. The other fungi which are biphasic in nature and easily confused with *Blastomyces dermatitidis* are *Histoplasma capsulatum* and *Blastomyces brasiliensis*. *Histoplasma capsulatum* is differentiated by the production of tuberculate chlamydo spores in its mycelial phase and the smaller size of the yeast forms. The distinguishing feature of *Blastomyces brasiliensis* is its multiple budding at 37° C. *Sporotrichum schenckii* is also biphasic but the absence of cottony aerial growth and the black pigmentation of its mycelial colonies is characteristic together with the grouped disposition of its conidia. The yeast phase is small and may be cigar-shaped.

*Animal Inoculation.*—The production of disease in laboratory animals by inoculation of suspected clinical materials or cultures is ordinarily not resorted to for diagnosis. When positive, it becomes a valuable diagnostic tool for it establishes not only the presence of the organism but also its virulence. The mouse has been found most suitable for this purpose. Intraperitoneal or intravenous inoculation is followed by the appearance of suppurative nodular lesions in the liver, spleen, lungs, and lymph nodes. Material from these lesions as well as peritoneal washings show the typical yeastlike tissue forms.

*Biopsy.*—Not too commonly, suspicion of the presence of blastomycosis is first expressed by the histopathologist upon examination of surgically removed tissues for diagnosis and/or treatment of other conditions, such as tuberculosis or carcinoma. In a number of cases, the diagnosis is made only at the autopsy table. Biopsy is a valuable diagnostic procedure, particularly if the biopsy material is cultured as well as sectioned. Skin biopsies are best taken from the typical borders of the verrucous granulomas. Bronchoscopy, thoracotomy, prostatectomy, and needle aspiration of the liver or lung have been utilized for biopsy purposes.

*Skin Test.*—Cutaneous hypersensitiveness in a patient with North American blastomycosis is demonstrated by a skin test using a vaccine of the killed yeast-phase organisms or a culture filtrate called Blastomycin. The Blastomycin skin test is akin to tuberculin with a similar technique of performance, reading, and significance. The intradermal injections of 0.1 ml. of standardized antigen in dilutions of 1:10 to 1:100,000, depending upon the degree of sensitivity, re-

sults in the appearance of maximal erythema with central induration in 24 to 48 hours. In very sensitive individuals, if the more concentrated antigen is used, a sterile abscess may develop.<sup>92</sup> In the average patient, it is customary to start with a 1:1,000 dilution of the commercially available Blastomycin.

A positive Blastomycin skin test generally indicates a past or present infection. Although only presumptive diagnostic evidence, the test is particularly helpful in mild or obscure cases or in cases where materials for biopsy or culture are not easily accessible. Its full significance, however, has not been established as yet because of the lack of opportunities to investigate the disease in large series, in contrast to the frequent sizable skin test surveys on tuberculosis, coccidioidomycosis, and histoplasmosis. The results obtained with Blastomycin skin test are not as constant as those of the latter three diseases. The test is negative in the early stages of the disease, in mild localized cutaneous cases, and in the overwhelming or terminal phases when anergy occurs. Disturbing results were reported by Smith<sup>76</sup> in the form of negative results in at least 25 per cent of patients with early proved blastomycosis and positive skin tests in 3 healthy medical students and 10 patients with no evidence of active disease. An important misleading factor is the occurrence of cross reactions with Histoplasmin and Coccidioidin<sup>93</sup> and the antigen of *Blastomyces brasiliensis*,<sup>94</sup> apparently due to a common antigen. Cross reactions between Histoplasmin and Blastomycin are frequent. Patients with histoplasmosis may even give larger Blastomycin skin reactions than patients with proved blastomycosis. Mistakes arising from these cross reactions are obviated, however, if the Coccidioidin, Histoplasmin, and Blastomycin skin tests are performed simultaneously on all patients suspected of these mycotic infections, inasmuch as the skin reactions to the homologous antigens are significantly larger.

*Complement Fixation Tests.*—The sera of patients with blastomycosis are able to fix complement with suspensions or extracts of *B. dermatitidis* as antigens.<sup>95,96</sup> Like a positive Blastomycin skin test, a positive complement fixation test is only presumptive, but it has been found useful in detecting cases and spurring greater efforts aimed at more definitive diagnosis by demonstration of the organism through mycologic or histopathologic studies. The complement fixing titer is generally zero or low in early, mild, or subclinical infection or in well-localized cutaneous disease. Two of the 4 cases of primary inoculation cutaneous blastomycosis followed by Wilson and associates<sup>92</sup> had no or slightly detectable complement-fixing antibodies. The titer increases with progression of the disease and remains high through the terminal stages.<sup>97,98</sup> In our experience a negative Blastomycin skin test and high complement fixation test signify a poor prognosis. With the recovery of the patient, the antibodies gradually disappear from circulation. The passive transfer of these antibodies from mother to child has been demonstrated by Noojin and Praytor.<sup>66</sup>

Unfortunately, sera from patients with histoplasmosis, coccidioidomycosis, or blastomycosis, both North and South American, cross react.<sup>93,98-102</sup> The major cross-over occurs between histoplasmosis and blastomycosis. It is desirable to perform the complement fixation tests simultaneously with the 3 types of antigens, for the homologous serum generally shows a higher titer.



Other serologic tests like the precipitin and collodion agglutination tests have not gained general acceptance. The interpretation of their results is more difficult.

#### DIFFERENTIAL DIAGNOSIS

Because of the protean nature of its manifestations, North American blastomycosis is easily confused with many other conditions. Misdiagnosed cases have reached the autopsy table before the organisms were accidentally discovered. The differential diagnosis depends upon the presenting signs and symptoms of the organ or organs most extensively involved.

The cutaneous lesions are mistaken for tuberculosis verrucosa cutis, lupus vulgaris, nodulo-ulcerative syphilid, gumma, squamous and basal cell carcinoma, mycosis fungoides, iododerma, sporotrichosis, coccidioid and paracoccidioid granulomas, chromoblastomycosis, actinomycosis, cryptococosis, trichophytic granuloma, granuloma inguinale, anthrax, tularemia, pyoderma vegetans, yaws, and cutaneous leishmaniasis. The primary inoculation type of cutaneous blastomycosis is to be differentiated from other chancriform diseases such as primary inoculation tuberculosis, sporotrichosis, tularemia, syphilis, yaws, American leishmaniasis, and cat-scratch fever.

The respiratory symptoms associated with the usual onset of systemic (pulmonary) North American blastomycosis simulate the common cold, influenza, or pneumonia. The differential considerations in the more developed systemic disease are tuberculosis, syphilis, primary and metastatic malignancies, pulmonary abscess, pneumonias, sarcoid, lymphoblastoma, pneumoconiosis, multiple myeloma, tularemia, pyemia, osteomyelitis, psoas abscess, histoplasmosis, coccidioidomycosis, South American blastomycosis, sporotrichosis, cryptococcosis, candidiasis, and actinomycosis.

In making the differential diagnosis of blastomycosis, the possibility that it may occur simultaneously in the same patient with other disease such as tuberculosis,<sup>103,104</sup> carcinoma,<sup>105,106</sup> sarcoidosis,<sup>107</sup> and histoplasmosis<sup>87</sup> must be borne in mind.

#### PROGNOSIS

In untreated cases, the prognosis of the classical cutaneous blastomycosis is good as regards life expectancy, but its chronic recurrent course extends through many years. The risk of conversion into the graver systemic form is ever present, but fortunately rarely occurs. No definite conclusion was drawn by Wilson and his colleagues<sup>52</sup> as regards the prognosis of the cases of primary inoculation type of cutaneous blastomycosis they described, but they were inclined to believe that this form tends to heal spontaneously.

The systemic disease, with involvement of visceral organs, has a foreboding prognosis. Its high fatality rate has been accepted by many on the strength of previous clinical reports. Recently, however, conflicting data have been reported. Kunkel and associates<sup>15</sup> recorded 7 deaths among 25 proved and presumptive cases and the series of 18 cases reported by Sutliff, Kyle, and Hobson<sup>16</sup> included only 2 deaths. The contention that subclinical and/or spontaneously healing North American blastomycosis exists remains to be confirmed in larger numbers of patients.

In the evaluation of prognosis, much help can be obtained from a study of the immunologic picture of the patient. As early as 1939, Martin and Smith<sup>9</sup> suggested the use of the complement fixation titer of the serum as a measure of the extent of infection and the negative skin test as an indication of anergy brought about by extensive, overwhelming disease. In subsequent papers,<sup>97,108,109</sup> they confirmed the value of the complement fixation test and the cutaneous test in prognostication. A favorable outcome is generally expected in patients with a negative complement fixation test and a positive skin test. On the other hand, a high titer of complement-fixing antibodies and a negative skin reaction usually means a grave prognosis.

#### TREATMENT

The treatment of North American blastomycosis, especially the systemic form, has been unsatisfactory, as evidenced by the multitude of therapeutic modalities used to control the disease. Recently, however, the emergence of a number of promising chemotherapeutic agents is changing the dismal picture.

*Cutaneous Blastomycosis.*—Skin lesions may undergo complete regression with apparent cure under treatment but the clinical improvement is often only temporary and recurrences are frequent, especially after cessation of therapy.

Since its first use by Gilchrist, iodide therapy has been most extensively used, with some success. Iodides are given in the form of a saturated solution of potassium iodide orally or of sodium iodide intravenously. Andrews<sup>110</sup> found that a mixture of equal parts of ammonium, sodium, and potassium iodides is better tolerated than potassium iodide alone. The importance of determining the cutaneous hypersensitiveness of the patient by skin testing before instituting treatment, especially with iodides, has been repeatedly emphasized in the literature. This is to avoid untoward reactions, and even fatal dissemination, which may occur when a patient with a strongly positive skin test is given iodides. When a positive skin test is obtained, reduction of the cutaneous hypersensitivity of the patient is strongly advised by means of hyposensitization with vaccine before treatment is initiated. Vaccine has also been utilized therapeutically by some authors with variable results. The technical details of iodide therapy and hyposensitization by vaccine are amply described by Conant and co-workers.<sup>111</sup>

Surgical procedures are also of some value in certain types of the disease. Complete excision with or without skin grafting can be done on the smaller, localized lesions. Cauterization, electrocoagulation, cryotherapy or curettage has been combined with iodide therapy and roentgenotherapy, but the greater risk of dissemination accompanying these procedures has been admitted.

Roentgen therapy is another noteworthy therapeutic aid. It has been used to eradicate small, early lesions<sup>112</sup>, but is generally combined with iodides and minor surgical procedures. The usual dose given is 75 to 100 roentgen units through 1 to 2 mm. Al once a week for 10 to 14 weeks.<sup>110,113</sup>

The best results are admittedly obtained through combination of iodide therapy, surgical procedures, roentgen therapy, and vaccine hyposensitization. Lesions that are recalcitrant to the above regimes should be treated with the newer chemotherapeutic agents. Local application of silver nitrate, bichloride of mercury, copper sulfate, phenol, and gentian violet are not generally accepted.

*Systemic Blastomycosis.*—Before the advent of the aromatic diamidines, iodide therapy was the recommended treatment. Its use, however, is empirical and although temporary improvement, and even cure, may occur, it does not essentially alter the course of the disease. It may even affect the disease adversely. Previously, it was widely employed because of the lack of any more efficacious treatment. The reports of successful treatment with the following agents are mainly unconfirmed: undecylenic acid,<sup>80,114</sup> Aureomycin,<sup>115</sup> colloidal copper sulfate,<sup>116</sup> ether,<sup>117</sup> and penicillin.<sup>118</sup>

The most revolutionary development in the treatment of North American blastomycosis was the introduction of the aromatic diamidines. A few members of this group of chemical compounds had been in use for the treatment of trypanosomiasis and leishmaniasis at the time Elson<sup>119</sup> reported the *in vitro* effectiveness of Propamidine against *B. dermatitidis*. The knowledge gained from the clinical experience with the use of the drugs on these tropical diseases was applied with facility to the treatment of North American blastomycosis. The first attempt to use an aromatic diamidine to control this disease was made in 1950 by Colbert, Strauss, and Green<sup>120</sup> with Propamidine. Stilbamidine was first used with success by Schoenbach and associates<sup>121</sup> the next year although Cherniss and Waisbren<sup>18</sup> recently claimed the fortuitous treatment with stilbamidine of a patient with systemic blastomycosis misdiagnosed as multiple myeloma in 1948. This first report by Schoenbach and his associates was followed by numerous descriptions of clinical experiences on the use of stilbamidine and its closely allied compound, 2-hydroxystilbamidine, in the treatment of North American blastomycosis.<sup>15,16,18,26,40,103,104,122-244</sup> These accumulating experiences testify to the clinical efficacy of these drugs. It is true that remarkable improvement and apparent cures have been attained in a significant number of cases with their use, but they do not control the disease in all cases. Treatment failures, especially in the form of recurrences, have been recorded as more cases are treated and observed for longer periods (Fig. 9).

The pharmacology and mode of administration of stilbamidine and 2-hydroxystilbamidine have been exhaustively reviewed<sup>123,124,131,132,145,146</sup> elsewhere. Further observations of the posttherapeutic course of the cases of blastomycosis treated in the University of Michigan Medical Center with the aromatic diamidines has been described in a previous paper.<sup>142</sup> Table I summarizes the salient features of the poststilbamidine periods in 6 patients. The longest period a patient was observed after the institution of treatment was 4 years and 9 months. The total doses received by Case 2 of 22.5 Gm. of stilbamidine and 21.3 Gm. of 2-hydroxystilbamidine, by Case 5 of 17.8 Gm. of stilbamidine, and by Case 6 of 18.2 Gm. of 2-hydroxystilbamidine certainly are massive in comparison to the average recommended dosages of 3 to 5 Gm. of stilbamidine and 9 to 12 gm. of 2-hydroxystilbamidine. The optimum dosages and mode of administration of these drugs remain to be determined. In the more recent treatment courses given to these patients, the individual doses were increased to 300 mg. stilbamidine and/or 450 mg. of 2-hydroxystilbamidine without any untoward reactions. The relapses in 4 of the 6 patients underscore the occurrence of treatment failures in spite of the relatively huge doses given in futile attempts

to control the disease. The appearance of toxic neuropathy in the same number of patients constitutes another complication of the drug stilbamidine which is claimed to be avoided by the use of the more stable, less toxic but also less effective 2-hydroxystilbamidine. Toxic neuropathy has appeared in 50 to 60 per cent of the reported cases of North American blastomycosis under Stilbamidine therapy and does not seem to be related entirely to the total amount administered. The occurrence of therapeutic relapses and toxic reactions detract from the clinical value of the diamidines in the treatment of blastomycosis. The final answer to the search for the ideal chemotherapeutic agent in the treatment of North American blastomycosis may yet come from the growing list of anti-fungal antibiotics such as Rimocidin, Fradycin, Mycostatin, and Amphotericin which may parallel the achievements of penicillin, Terramycin, streptomycin, and other antibacterial antibiotics in microbial infections.

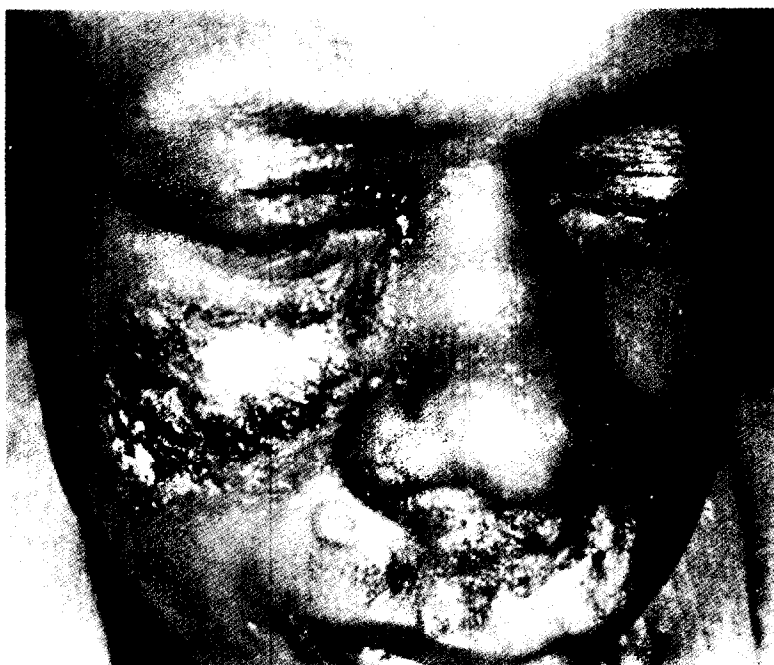

Fig. 9.—G. G. (Table I) now has had more than 22.5 Gm. of stilbamidine and more than 21.3 Gm. of 2-hydroxystilbamidine (he is now under hospital treatment for a relapsing disease). Although his organism has shown increasing tolerance to the drugs, he still can be controlled by larger doses and prolonged treatment. (From Curtis and Harrell, *A. M. A. Arch. Dermat. & Syph.* **66**:676, 1952.)

Surgical procedures are of certain value in systemic blastomycosis. Incision and drainage of large pockets of pus is recommended. Urinary obstruction due to prostatic involvement requires surgery. Excision of laryngeal,<sup>147,148</sup> prostatic,<sup>64</sup> and uterine<sup>65</sup> lesions has been attempted. Levitas and Baum<sup>149</sup> regard it worth while to excise isolated, metastatic lesions of the skin or peripheral bones with the possibility of an arrest of the primary focus in the lungs. Even if the visceral lesions remain active, they still suggest extirpation of skin lesions by reason of avoiding cosmetic deformities and eradicating these lesions as foci of further dissemination and of possible contagion.

TABLE I. FOLLOW-UP OF 6 CASES UNDER STILBAMIDINE THERAPY

PATIENT	AGE	SEX	RACE	ORGANS INVOLVED	DRUG GIVEN	TOTAL DOSE (GM.)	FOLLOW-UP PERIOD FROM INSTITUTION OF TREATMENT	NEUROPATHY	THERAPEUTIC OUTCOME
1. A. W.	42	M	C	Lungs and skin	Stilbamidine methionate	3.0	4 yr., 8 mo.	None	No apparent recurrence. Patient admitted in another hospital on June 7, 1956, for diagnosis of advanced pulmonary tuberculosis
2. G. G.	42	M	C	Lungs, skin, bones, joint, prostate	Stilbamidine isethionate 2-hydroxystilbamidine isethionate	22.5 21.3	4 yr., 9 mo.	Present	Recurrent but each recurrence controlled by treatment
3. D. H.	36	F	W	Lungs, skin, subcutaneous tissue	Stilbamidine isethionate	3.3	3 yr., 11 mo.	Present	Recurrent
4. M. D.	37	F	W	Lungs, skin	Stilbamidine isethionate	3.0	9 mo. until June 30, 1953. Patient not heard from since then	Present	No apparent recurrence.
5. E. I.	37	M	W	Lungs, skin	Stilbamidine isethionate	17.8	3 yr., 5 mo.	Present	Recurrent
6. C. R.	47	M	W	Lungs, skin, oral mucous membranes	Stilbamidine isethionate 2-hydroxystilbamidine	2.7 18.2	2 yr., 6 mo.	None	Recurrent

With greater use of stilbamidine and an acceptance of the concept of the lung being the primary focus, interest in the value of lung resection in the treatment of pulmonary blastomycosis has increased.<sup>15,22,40,80,91,114,135,149-161</sup> Excisional surgery appears reasonably indicated in the few instances where a localized pulmonary focus exists without evidence of dissemination. The usual pulmonary lesions when discovered, however, are often diffuse and do not lend themselves to surgical treatment or may be associated with other visceral foci. Management of pulmonary blastomycosis today is comparable to that of pulmonary tuberculosis where surgical intervention has become a valuable adjunct to chemotherapy. In a like manner, pulmonary resection in blastomycosis is reserved for the residual, irreparably damaged tissues after diamidine therapy. In instances of required diagnostic thoracotomy or therapeutic surgery of misdiagnosed pulmonary lesions, postoperative courses of diamidines are indicated.

Supportive general measures for the blastomycotic patient, such as bed rest and good nutrition, are the same as for any other severe debilitating infection.

## REFERENCES

1. Gilchrist, T. C.: Protozoan Dermatitis, *Cutan. and Genito-Urin. Dis.* **12**:496, 1894.
2. Gilchrist, T. C.: A Case of Blastomycotic Dermatitis in Man, *J. Hopkins Hosp. Rep.* **1**:269, 1896.
3. Gilchrist, T. C., and Stokes, W. R.: A Case of Pseudolupus Vulgaris Caused by Blastomyces, *J. Exper. Med.* **3**:53, 1898.
4. Walker, J. W., and Montgomery, F. H.: Further report of a Previously Recorded Case of Blastomycosis of the Skin; Systemic Infection with Blastomyces; Death; Autopsy, *J.A.M.A.* **38**:867, 1902.
5. Hektoen, L.: Systemic Blastomycosis and Coccidioidal Granuloma, *J.A.M.A.* **49**:1071, 1907.
6. Stober, A. M.: Systemic Blastomycosis, *Arch. Int. Med.* **13**:509, 1914.
7. Wade, H. W., and Bel, G. S.: A Critical Consideration of Systemic Blastomycosis, *Arch. Int. Med.* **18**:103, 1916.
8. D'Aunoy, R., and Beven, J. L.: Systemic Blastomycosis, *J. Lab. & Clin. Med.* **16**:124, 1930.
9. Martin, D. S., and Smith, D. T.: Blastomycosis (American Blastomycosis, Gilchrist's Disease). I. Review of Literature. II. A Report of Thirteen New Cases, *Am. Rev. Tuberc.* **39**:275, 488, 1939.
10. Friedman, L. L., and Signorelli, J. J.: Blastomycosis: A Brief Review of the Literature and A Report of a Case Involving the Meninges, *Ann. Int. Med.* **24**:385, 1946.
11. Starrs, R. A., and Klotz, M. O.: North American Blastomycosis (Gilchrist's Disease). I. A Study of the Diseases From a Review of the Literature. II. An Analysis of Canadian Reports and Description of a New Case of the Systemic Type, *Arch. Int. Med.* **82**:1, 1948.
12. Benham, R. W.: Cryptococcosis and Blastomycosis, *Ann. N. Y. Acad. Sc.* **50**:1299, 1950.
13. Schwarz, J., and Baum, G. L.: Blastomycosis, *Am. J. Clin. Path.* **21**:999, 1951.
14. Howles, J. K., and Black, C. I.: Cutaneous Blastomycosis (A Report of 58 Unpublished Cases), *J. Louisiana Med. Soc.* **105**:72, 1953.
15. Kunkel, W. M., Jr., Weed, L. A., McDonald, J. R., and Clagett, O. T.: North American Blastomycosis—Gilchrist's Disease: A Clinicopathologic Study of Ninety Cases, *Surg., Gynec. & Obst.* **99**:1, 1954.
16. Sutliff, W. D., Kyle, J. W., and Hobson, J. L.: North American Blastomycosis: Clinical Forms of the Disease and Treatment with Stilbamidine and 2-Hydroxystilbamidine, *Ann. Int. Med.* **41**:80, 1954.
17. Weed, L. A.: North American Blastomycosis, *Am. J. Clin. Path.* **25**:37, 1955.
18. Cherniss, E. I., and Waisbren, B. A.: North American Blastomycosis: A Clinical Study of 40 Cases, *Ann. Int. Med.* **44**:105, 1956.
19. Shepherd, F. J., and Rhea, L. I.: A Fatal Case of Blastomycosis, *J. Cutan. Dis.* **29**:588, 1911.
20. Dowling, G. B., and Elworthy, R. R.: Case of Blastomycetic Dermatitis, *Proc. Roy. Soc. Med.* **19**:4, 1925.
21. Schwarz, J., and Goldman, L.: Epidemiological Study of North American Blastomycosis, *A.M.A. Arch. Derm. & Syph.* **71**:84, 1955.

22. Solway, L. J., Kohan, M., and Pritzner, H. G.: A Case of Disseminated Blastomycosis, *Canad. M.A.J.* **41**:331, 1939.
23. McLaren, J. A.: North American Blastomycosis, *Canad. M.A.J.* **60**:26, 1949.
24. Aszkanazy, C. L., Barrie, H. J., and Crockston, J. H.: Systemic Blastomycosis, *Canad. M.A.J.* **65**:55, 1951.
25. Simard, L. C., Gelinac-MacKay, C., and Germain, C.: Quatre cas de Blastomyose Nord-Américaine, *Union méd. Canad.* **82**:276, 1953.
26. Gaumont, R.: Onze cas de blastomyose Nord-Américaine dans la région de Québec, *Laval méd.* **18**:1319, 1953.
27. Martinez-Baez, M., Reyes Mota, A., and Gonzalez Ochoa, A.: Blastomycosis Norteamericana en Mexico, *Rev. Inst. salub. y enferm. trop.* **14**:225, 1954.
28. Mukherjee, B. B.: North American Blastomycosis, *J. Indian M.A.* **23**:22, 1953.
29. Andleigh, H. S.: Blastomycosis in India; Case, *Indian J. M. Sc.* **5**:59, 1951.
30. Fernandez Garcia, E., and Rodriguez de Ledesma, J.: Consideraciones sobre un caso de blastomycosis—verruosca de Gilchrist en su forma generalizada, *Rev. clín. españ.* **50**:56, 1953.
31. Jung, H.: Disseminierte Gilchristische blastomykose und Sporotrichom der Mamma mit Bild und Kulturdemonstrationen, *Arch. Dermat. u. Syph.* **191**:482, 1950.
32. Loevei, E., and Bogsch, A.: Beobachtungen an einheimischen Lungen-Blastomykosefällen (Morbus Gilchristi), *Fortschr. Geb. Roentgenstrahlen* **81**:449, 1954.
33. Broc, R., and Haddad, N.: Tumeur bronchique a "Scopulariopsis Americana" détermination précoce d'une maladie de Gilchrist, *Bull. Soc. Méd. Hôp. Paris* **68**:679, 1952.
34. Vermeil, C., Gordeef, A., and Haddad, N.: Sur un cas tunisien de mycose généralisée mortelle, *Ann. Inst. Pasteur* **86**:636, 1954.
35. Polo, F. H., Brass, K., and De Montemayor, L.: Enfermedad de Gilchrist en Venezuela; Primer caso; estudio clinico; comprobacion histologica; aislamiento y determinacion de la primera cepa Suramericana de Blastomyces dermatitidis, *Rev. san. caracas* **19**:217, 1954.
36. Gambini, G.: Su un caso di Blastomycosi Neoplastiforme da Blastomyces dermatitidis Gilchrist et Stokes, 1898, emen, Moore (1933), *Arch. Ital. sci. med. col. parasitol.* **29**:41, 1948.
37. MacMillan, H.: Report of a Case of Localized Blastomycosis, *Australian J. Dermat.* **3**:38, 1955.
38. Brody, M.: Blastomycosis, North American Type. A Proved Case from the European Continent, *Arch. Dermat. & Syph.* **56**:529, 1947.
39. Bonoff, C. P.: Acute Primary Pulmonary Blastomycosis, *Radiology* **54**:157, 1950.
40. Matsumoto, K. K., Anastazio, D. S., Lamashey, T. L., Ayres, W. W., and Cuttle, T. D.: North American Blastomycosis Treated with Pulmonary Resection and Stilbamidine, *Am. J. M. Sc.* **229**:172, 1955.
41. Emmons, C. W.: The Isolation From Soil of Fungi Which Cause Disease in Man, *Tr. New York Acad. Sc.* **14**:51, 1951.
42. Ramsey, F. K., and Carter, G. R.: Canine Blastomycosis in the United States, *J. Am. Vet. M. A.* **120**:93, 1952.
43. Robbins, E. S.: North American Blastomycosis in the Dog, *J. Am. Vet. M. A.* **125**:391, 1954.
44. Menges, R. W., McClellan, J. T., and Ausherman, R. J.: Canine Histoplasmosis and Blastomycosis in Lexington, Kentucky, *J. Am. Vet. M. A.* **124**:202, 1954.
45. Newberne, J. W., Neal, J. D., and Heath, M. K.: Some Clinical and Microbiological Observations on Four Cases of Canine Blastomycosis, *J. Am. Vet. M. A.* **127**:942, 1955.
46. Benbrook, E. A., Bryant, J. B., and Saunders, L. Z.: A Case of Blastomycosis in the Horse, *J. Am. Vet. M. A.* **112**:475, 1948.
47. Baker, R. D.: Experimental Blastomycosis in Mice, *Am. J. Path.* **18**:463, 1942.
48. Heilman, F. R.: Production of Rapidly Fatal Blastomycosis in Mice For Testing Chemotherapeutic Agents, *J. Invest. Dermat.* **9**:87, 1947.
49. Nelson, L. M.: Experimental Reactions of American Blastomycosis in Guinea Pigs, *J. Invest. Dermat.* **5**:257, 1942.
50. Meyer, E., and Ordal, Z. J.: Action of Streptothricin and Other Antibiotic Agents on Blastomyces dermatitidis Infections of Chick Embryo, *J. Infect. Dis.* **79**:199, 1946.
51. Evans, N. A.: Clinical Report of a Case of Blastomycosis of the Skin From Accidental Inoculation, *J.A.M.A.* **40**:1772, 1903.
52. Wilson, J. W., Cawley, E. P., Weidman, F. D., and Gilmer, W. S.: Primary Cutaneous North American Blastomycosis, *A.M.A. Arch. Dermat. & Syph.* **71**:37, 1955.
53. Schwarz, J., and Baum, G. L.: Results of Skin Tests in Contacts of Blastomycotic Patients, *J. Invest. Dermat.* **18**:3, 1952.
54. Schwarz, J., and Baum, G. L.: North American Blastomycosis (Geographic Distribution, Pathology and Pathogenesis), *Docum. neerl. et indones. morbis trop.* **5**:29, 1953.
55. Furcolow, M. L., Schwarz, J., Hewell, B. A., and Grayston, J. I.: Incidence of Tuberculin, Histoplasmin and Blastomycin Reactors Among a Group of School children, *Am. J. Pub. Health* **43**:1523, 1953.

56. Schwarz, J., and Furcolow, M. L.: Some Epidemiologic Factors and Diagnostic Tests in Blastomycosis, Coccidioidomycosis, and Histoplasmosis, *Am. J. Clin. Path.* **25**:261, 1955.
57. Smith, J. G., Jr., Harris, J. S., Conant, N. F., and Smith, D. T.: An Epidemic of North American Blastomycosis, *J.A.M.A.* **155**:641, 1955.
58. Schwarz, J., and Baum, G. L.: Primary Cutaneous Mycoses, *Arch. Dermat.* **71**:143, 1955.
59. Baker, R. D., Warrick, G. W., and Noojin, R. O.: Blastomycotic Pneumonia, A Report of a Fatal Case of 22 Days Duration, *Arch. Int. Med.* **90**:718, 1952.
60. Steen, L. H., Foxworthy, D. T., and Baker, L. A.: Acute Blastomycotic Pneumonia: Report of a Fatal Case of Short Duration Diagnosis by Needle Biopsy of Lung, *A.M.A. Arch. Int. Med.* **93**:464, 1954.
61. Reeves, R. J., and Pedersen, R.: Fungous Infection of Bone, *Radiology* **62**:55, 1954.
62. Jones, R. R., and Martin, D. S.: Blastomycosis of Bone, *Surgery* **10**:931, 1941.
63. Baylin, J. J., and Wear, J. M.: Blastomycosis and Actinomycosis of Spine, *Am. J. Roentgenol.* **69**:395, 1953.
64. Moore, M., and Halpern, L. K.: Blastomycosis Involving the Prostate: Report of Two Cases, One With and One Without Cutaneous Lesions, *J. Urol.* **60**:612, 1948.
65. Hamblen, E. C., Baker, R. D., and Martin, D. S.: Blastomycosis of the Female Reproductive Tract, *Am. J. Obst. & Gynec.* **30**:345, 1935.
66. Noojin, R. O., and Praytor, H. B.: Systemic Blastomycosis Complicated With Pregnancy, Report of a Case with Clinical Course and Immunologic Reactions, *J.A.M.A.* **147**:749, 1951.
67. Cassady, J. V.: Uveal Blastomycosis, *Arch. Opth.* **35**:84, 1946.
68. Birge, H. L.: Ocular Aspects of Mycotic Infections, *A.M.A. Arch. Opth.* **47**:354, 1952.
69. Theodorides, E., and Koutrokikos, D.: Blastomycosis of the Conjunctiva: Report of 2 Additional Cases, *Am. J. Opth.* **36**:978, 1953.
70. Sinksey, R. M., and Anderson, W. B.: Miliary Blastomycosis with Metastatic Spread to Posterior Uvea of Both Eyes, *A.M.A. Arch. Opth.* **54**:602, 1955.
71. Ranier, A.: Primary Laryngeal Blastomycosis: Review of Literature and Report of Case, *Am. J. Clin. Path.* **21**:444, 1951.
72. Thornell, W. C.: Blastomycosis of the Larynx, *Ann. Otol., Rhin. & Larynx.* **64**:1155, 1955.
73. Smith, D. T.: *Fungus Diseases of the Lungs*, Springfield, Illinois, 1947, Charles C Thomas, Publishers.
74. Good, C. A.: Fungus Disease of the Lungs: Review of Roentgenologic Manifestations, *Texas J. Med.* **47**:817, 1951.
75. Weisel, W., and Landis, F. B.: Endobronchial Lesions in Pulmonary Blastomycosis, *J. Thoracic Surg.* **25**:570, 1953.
76. Smith, D. T.: Problems in the Diagnosis of Pulmonary Mycoses, *Texas J. Med.* **51**:787, 1955.
77. Alfred, K. S., and Harbin, M.: Blastomycosis of Bone. Report of a Case, *J. Bone & Joint Surg.* **32-A**:887, 1950.
78. Thompson, W. F.: Blastomycosis of Bone: Report of a Case, *J. Bone & Joint Surg.* **35-A**:777, 1953.
79. Feld, D. D., and Cadden, A. V.: Systemic Blastomycosis, *Dis. Chest* **16**:473, 1949.
80. Takaro, T., Hopkins, J. E., and Murphy, J. D.: The Treatment of Pulmonary Blastomycosis, *Dis. Chest* **28**:293, 1955.
81. Baker, R. D.: Tissue Reactions in Human Blastomycosis, *Am. J. Path.* **18**:479, 1942.
82. Pillsbury, D. M., and Kligman, A. M.: A New Histochemical Tool for the Definitive Diagnosis of Fungus Infection, *Tr. N. Y. Acad. Sc.* **13**:145, 1951.
83. Starr, G. F., Dawe, C. J., and Weed, L. A.: Use of Periodic Acid-Schiff Stain in Identification of Pathogenic Fungi in Tissues, *Am. J. Path.* **25**:76, 1955.
84. Manwaring, J. H.: Unusual Forms of Blastomyces Dermatitis in Human Tissues, *Arch. Path.* **48**:421, 1949.
85. Tompkins, V., and Schleifstein, J.: Small Forms of Blastomyces dermatitidis in Human Tissues, *Arch. Path.* **55**:432, 1953.
86. Tuttle, J. G., Lichtwardt, H. E., and Altshuler, C. H.: Systemic North American Blastomycosis: Report of A Case with Small Forms of Blastomycetes, *Am. J. Clin. Path.* **23**:890, 1953.
87. Layton, J. M., McKee, A. P., and Stamler, F. W.: Dual Infection with Blastomyces dermatitidis and Histoplasma capsulatum. Report of a Fatal Case in Man, *Am. J. Clin. Path.* **23**:904, 1953.
88. Moore, M.: Morphologic Variation in Tissue of the Organisms of the Blastomyces and Histoplasmosis, *Am. J. Path.* **31**:1049, 1955.
89. Schwarz, J.: Giant Forms of Histoplasma capsulatum in Tissue Explants, *Am. J. Clin. Path.* **23**:898, 1953.
90. MacKinnon, J. E., and Vinelli, H.: Caracteres Diferenciales de Paracoccidiodes brasiliensis y Blastomyces dermatitidis en los tejidos. Utilidad de la coloracion con el carmin de best, *An. Fac. med. Montevideo* **35**:299, 1950.



91. Acree, P. W., Decamp, P. T., and Ochsner, A.: Pulmonary Blastomycosis; A Critical Analysis of Medical and Surgical Therapies, with a Report of Six Cases, *J. Thoracic Surg.* **28**:175, 1954.
92. Benham, R. W.: The Fungi of Blastomycosis and Coccidioidal Granuloma, *Arch. Dermat. & Syph.* **30**:385, 1934.
93. Emmons, C. W., Olson, B. J., and Eldridge W. W.: Studies of the Role of Fungi in Pulmonary Disease. I. Cross Reactions of Histoplasmin, *Pub. Health Rep.* **60**:383, 1945.
94. Friedman, L., and Conant, N. F.: Immunologic Studies on the Etiologic Agents of North and South American Blastomycoses. I. Comparison of Hypersensitivity Reactions, *Mycopathologia* **6**:310, 1953.
95. Martin, S. S.: Complement Fixation in Blastomycosis, *J. Infect. Dis.* **57**:291, 1935.
96. Martin, D. S., and Smith, D. T.: Laboratory Diagnosis of Blastomycosis by Culture and by Complement Fixation, *J. Bact.* **31**:70, 1936.
97. Martin, D. S.: Practical Application of Some Immunologic Principles to Diagnoses and Treatment of Certain Fungous Infections, *J. Invest. Dermat.* **4**:471, 1941.
98. Campbell, C. C., and Brinkley, G. E.: Serologic Diagnosis with Respect to Histoplasmosis, Coccidioidomycosis, and Blastomycosis and the Problem of Cross Reactions, *J. Lab. & Clin. Med.* **42**:896, 1953.
99. Howell, A.: Studies of Fungus Antigens. I. Quantitative Studies of Cross Reactions Between Histoplasmin and Blastomycin in Guinea Pigs, *Pub. Health Rep.* **62**:631, 1947.
100. Hazen, E. L., and Tahler, E. D.: Complement Fixation Test in Histoplasmosis, Blastomycosis and Coccidioidomycosis, *Rep. New York Dept. Health*, **79**, 1948.
101. Salvin, S. B.: The Serologic Relationships of Fungus Antigens, *J. Lab. & Clin. Med.* **34**:1096, 1949.
102. Friedman, L., and Conant, N. F.: Immunologic Studies on the Etiologic Agents of North and South American Blastomycoses. II. Comparison of Serologic Reactions, *Mycopathologia* **6**:317, 1953.
103. Black, T. C., and Wilson, H. M.: Co-existent Pulmonary Tuberculosis and Systemic Blastomycosis, *Am. Rev. Tuberc.* **68**:615, 1953.
104. Stillians, A. W., and Klemptner, H. E.: Blastomycosis in Tuberculous Patient, *J.A.M.A.* **153**:560, 1953.
105. Fuller, T. E.: Report of Case of Blastomycosis of Larynx Complicating Carcinoma, *J. Arkansas M. Soc.* **33**:37, 1936.
106. Abraham, A., and Luddecke, H. F.: North American Blastomycosis and Bronchial Carcinoma, *Dis. Chest* **28**:687, 1955.
107. Hiatt, J. S., Jr. and Lide, T. H.: Blastomycosis Complicating Boeck's Sarcoid: Case, *North Carolina M. J.* **10**:650, 1949.
108. Smith, D. T.: Immunologic Types of Blastomycosis: A Report on 40 Cases, *Ann. Int. Med.* **31**:463, 1949.
109. Martin, D. S.: Practical Applications of Immunologic Principles in Diagnosis and Treatment of Fungus Infections, *Ann. New York Acad. Sc.* **50**:1376, 1950.
110. Andrews, G. C.: *Diseases of the Skin*, Philadelphia, 1954, W. B. Saunders Co.
111. Conant, N. F., Smith, D. T., Baker, R. D., Callaway, J. L., and Martin, D. S.: *Manual of Clinical Mycology*, Philadelphia, 1954, W. B. Saunders Co.
112. Clarkson, W., and Barker, A.: Blastomycosis with Report of Three Cases, *Virginia M. Month.* **60**:83, 1933.
113. Rigdon, R. H., and Winkler, C. H., Jr.: Cutaneous Blastomycosis, *J. Arkansas M. Soc.* **42**:95, 1946.
114. Hopkins, J. E. T., and Murphy, J. D.: Pulmonary Resection and Undecylenic Acid in Systemic Blastomycosis, *J. Thoracic Surg.* **23**:409, 1952.
115. McVay, L. V., and Carroll, D. S.: Aureomycin in the Treatment of Systemic North American Blastomycosis, *Am. J. Med.* **12**:289, 1952.
116. Bergstrom, V. W., Nugent, G., and Snider, M. C.: Blastomycosis. Report of a Case with Involvement of the Skin and Bones, *Arch. Dermat. & Syph.* **36**:70, 1937.
117. Fishman, J.: Systemic Blastomycosis, with a New Form of Therapy, *U. S. Nav. Med. Bull.* **43**:758, 1944.
118. Benedek, T.: Blastomycosis (Gilchrist) (North American Type). The First Case on Record Successfully Treated with Penicillin. With a Survey of Literature Concerning the Treatment of Deep-seated Mycosis by Penicillin and/or Sulfonamides, *Urol. & Cutan. Rev.* **53**:216, 1949.
119. Elson, W. O.: The Antibacterial and Fungistatic Properties of Propamidine, *J. Infect. Dis.* **76**:193, 1945.
120. Colbert, J. W., Jr., Strauss, M. J., and Green, R. H.: The Treatment of Cutaneous Blastomycosis with Propamidine, *J. Invest. Dermat.* **14**:17, 1950.
121. Schoenbach, E. B., Miller, J. M., Ginsberg, M., and Long, P. H.: Systemic Blastomycosis Treated with Stilbamidine, *J.A.M.A.* **146**:1317, 1951.
122. Snapper, I., Schneid, B., McVay, L., and Lieben, F.: Pharmacology and Therapeutic Value of Diamidine Derivatives—Particularly of 2-Hydroxystilbamidine, *Tr. N. Y. Acad. Sc.* **14**:269, 1952.

123. Schoenbach, E. B., Miller, J. M., and Long, P. H.: Treatment of Systemic Blastomycosis with Stilbamidine, *Ann. Int. Med.* **37**:31, 1952.
124. Curtis, A. C., and Harrell, E. R.: Use of Two Stilbene Derivatives (Diethylstilbestrol and Stilbamidine) in Treatment of Blastomycosis, *Arch. Dermat. & Syph.* **66**:676, 1952.
125. Fink, J. C., Vanderploeg, D. E., and Moursund, M. P.: Stilbamidine in the Treatment of Cutaneous Blastomycosis, *J.A.M.A.* **151**:1395, 1953.
126. Pariser, H., Levy, E. D., and Rawson, A. J.: Treatment of Blastomycosis With Stilbamidine, *J.A.M.A.* **152**:129, 1953.
127. Forsey, R. R., and Jackson, R.: Toxic Psychosis Following Use of Stilbamidine in Blastomycosis, *A.M.A. Arch. Dermat. & Syph.* **68**:89, 1953.
128. Cummins, C. R., Bairstow, B., and Baker, L. A.: Stilbamidine in Treatment of Disseminated Blastomycosis, *Arch. Int. Med.* **92**:98, 1953.
129. Marshak, L. C.: Cutaneous Blastomycosis Treated with 4,4'-Stilbenedicarboxyamidine (Stilbamidine), *A.M.A. Arch. Dermat. & Syph.* **68**:94, 1953.
130. Rodriguez, J.: Stilbamidine (4,4'-Stilbenedicarboxyamidine) Therapy in Blastomycosis, *Arch. Dermat. & Syph.* **68**:95, 1953.
131. Smith, D. T.: Stilbamidine Therapy in Blastomycosis, *GP* **8**:69, 1953.
132. Snapper, I., and McVay, L. V.: Treatment of North American Blastomycosis with 2-Hydroxystilbamidine, *Am. J. Med.* **15**:603, 1953.
133. Otsfeld, A. M.: Effect of Stilbamidine on Cutaneous Blastomycosis, *Am. J. Med.* **15**:746, 1953.
134. Myhr, L. B.: Systemic Blastomycosis: Report of a Case Treated with Stilbamidine, *Am. Pract.* **5**:64, 1954.
135. Sealy, W. C., Collins, J. P., and Menefee, E. E.: Pulmonary Blastomycosis; The Influence of Immunologic Findings on the Selection of Patients for Operation, *J. Thoracic Surg.* **27**:238, 1954.
136. Burr, A. H., and Huffines, T. R.: Blastomycosis of Prostate Treated with Stilbamidine, *J. Urol.* **71**:464, 1954.
137. Weinberg, B. J., Lawrence, C. H., and Buchholz, A.: Systemic Blastomycosis Treated With 2-Hydroxystilbamidine, *A.M.A. Arch. Int. Med.* **94**:493, 1954.
138. Slaughter, J. C., Jr.: Stilbamidine in Treatment of Widely Disseminated Blastomycosis (With Two Year Follow-up), *Arch. Dermat. & Syph.* **70**:663, 1954.
139. Colsky, J.: Treatment of Systemic Blastomycosis With 2-Hydroxystilbamidine, *Arch. Int. Med.* **93**:795, 1954.
140. Marx, F. J., and Berenbaum, A. A.: Systemic Blastomycosis: Cause of an Obscure Infection in a Non-endemic Area, *New England J. Med.* **251**:56, 1954.
141. White, M. C., Jr., and Owen, E. T.: The Surgical Treatment of Pulmonary Blastomycosis, *Am. Surgeon* **20**:981, 1954.
142. Harrell, E. R., Bocobo, F. C., and Curtis, A. C.: A Study of North American Blastomycosis and its Treatment with Stilbamidine and 2-Hydroxystilbamidine, *Ann. Int. Med.* **43**:1076, 1955.
143. Knight, V. H., Jr., and Wilson, W. W.: Systemic Blastomycosis; Report of a Case, *J. Florida M. A.* **42**:275, 1955.
144. Kuhn, B. H.: Stilbamidine-resistant North American Blastomycosis, *Arch. Dermat.* **73**:556, 1956.
145. Schoenbach, E. B., and Greenspan, E. M.: The Pharmacology, Mode of Action and Therapeutic Potentialities of Stilbamidine, Pentamidine, Propamidine and Other Aromatic Diamidines—A Review, *Medicine* **27**:327, 1948.
146. Smith, D. T.: Therapy for the Systemic Fungous Infections, *New York J. Med.* **54**:2303, 1954.
147. Dennis, F. L.: Blastomycosis of the Upper Respiratory Tract with Report of a Case Primary in the Larynx, *Ann. Otol. Rhin. & Laryng.* **27**:571, 1918.
148. Jackson, C.: Blastomycosis of the Larynx, *Arch. Otolaryng.* **3**:99, 1926.
149. Levitas, J. R., and Baum, G. L.: Surgical Aspects of Blastomycosis, *Surgery* **33**:93, 1953.
150. Hughes, F. A., Whitaker, N. W., Lowry, C. C., Polk, J. W., Foley, F. E., and Fox, J. R.: Resection for Pulmonary Mycotic Disease, *Dis. Chest* **25**:334, 1954.
151. Vuechner, H. A., Anderson, A. E., Strug, L. H., Seabury, J. H., and Peabody, J. W., Jr.: Pulmonary Resection in the Treatment of Blastomycosis, *J. Thoracic Surg.* **25**:468, 1953.