

VARIATIONS IN A-V AND V-A CONDUCTION DEPENDENT
UPON THE TIME RELATIONS OF AURICULAR
AND VENTRICULAR SYSTOLE: THE
SUPERNORMAL PHASE

EDWARD M. KLINE, M.D., JEROME W. CONN, M.D., AND
FRANCIS F. ROSENBAUM, M.D.
ANN ARBOR, MICH.

IN 1912, Adrian and Lucas¹ designated as the "supernormal phase" a biological phenomenon which they demonstrated in injured excitable tissue. They found that there was a short period during recovery from a previous stimulus in which the tissue became hypersensitive to new stimuli. They showed, further, that this supernormal excitability of nervous tissue was accompanied by a supernormal variation in conductivity. For example, it was shown that an impulse which was ordinarily unable to traverse a depressed zone in a nerve was conducted if it followed a transmitted impulse by an interval of 0.015 to 0.1 second. Adrian² pointed out later that an acid medium was necessary for the existence of the supernormal phase.

Ashman³ produced varying degrees of A-V block in the turtle heart and observed the existence of a supernormal phase in some of the specimens that had been handled repeatedly. He produced an A-V block which was just complete for impulses arriving every fifteen to twenty seconds. When, however, an auricular impulse was sent in about three or four seconds after one of the regularly blocked impulses, it was transmitted. In other words, when an impulse was timed to fall in the supernormal phase of the preceding blocked impulse, it traversed a block through which it could not pass at any other time. Ashman showed, too, that if one impulse passed the block, the following impulses could also be transmitted providing that each impulse occurred during the supernormal phase of the preceding beat.

The existence of a supernormal phase in the human heart was first suggested by Lewis and Master.⁴ In their first case, one of complete heart block, A-V transmission occurred whenever the P-wave fell between the summit and the end of the T-wave of the preceding idioventricular systole. This zone, which they likened to the supernormal phase of Adrian and Lucas, was found to lie between the limits of 0.425 and 0.708 second after the initial movement of the QRS complex. In their second case, one of partial heart block with dropped beats, the zone of effective auricular impulses could not be so sharply defined.

From the Department of Internal Medicine, University of Michigan Medical School, Ann Arbor. This study was assisted by a grant to Frank N. Wilson from the Horace H. Rackham School of Graduate Studies.

Received for publication Sept. 19, 1938.

Wilson and Herrmann⁵ reported a case of paroxysmal complete heart block which is strikingly similar to the first case described in this article. The data pertaining to this case were re-examined and again reported by Ashman and Herrmann,⁶ who found that periods of complete heart block were preceded by periods of gradual auricular slowing. When the length of the cardiac cycle measured from 0.90 to 1.10 seconds, a period of complete heart block followed. Such periods of block were usually interrupted when an auricular systole followed an idioventricular beat by 0.31 to 0.795 second. A critical zone during which the conducting mechanism was reactive to an auricular impulse was therefore present.

Wolfert⁷ reported a case of complete heart block with occasional ventricular responses. He found that when auricular systole occurred 0.45 to 0.74 second after the beginning of the preceding QRS complex, the impulse was transmitted. Wolfert stated that although a supernormal recovery phase could explain the occasional transmitted beat, he preferred to attribute it to an improved nutritional state of the depressed zone during that short period of the cardiac cycle. His chief reason for rejecting the concept of the supernormal phase was the fact that at the time of his report no good evidence existed that a supernormal phase occurred in the mammalian heart.

The purpose of this report is to demonstrate in two cases of heart block the existence of a supernormal phase in conductivity. In the first case an impulse arising in the ventricle frequently established in the depressed zone a supernormal phase during which an auricular impulse passed. This successful A-V conduction produced another supernormal phase during which the next auricular impulse was transmitted. In the second case, impulses arising in the auricle produced in the depressed zone a supernormal phase permitting retrograde conduction.

CASE 1.—E. P., a 45-year-old, white male laborer, was admitted to the University Hospital Sept. 21, 1937, complaining of fainting spells. He stated that he had enjoyed good health until six months before admission, when he experienced his first attack of syncope. Attacks had become more frequent so that they occurred almost daily. During attacks he had noticed some irregularity of the heart which he described as "missed beats." There was no history of rheumatic fever or syphilis.

On physical examination, the patient was a well-developed adult male who did not appear severely ill. On several occasions during the examination there occurred transient pronounced pallor of the face, accompanied by a staring facial expression and momentary disorientation. During these attacks, which lasted only a few seconds, the patient was pulseless. In similar but more severe attacks, syncope occurred and ventricular asystole lasted as long as five seconds. Recovery was characterized by intense flushing of the face and the return of normal cardiac rhythm. Except for the cardiovascular findings to be described, the physical examination revealed no abnormalities. The pulse was small and sustained. The blood pressure in the left arm was 138/110, and in the right arm 108/92. The heart was not enlarged on percussion. A loud, rough systolic murmur, transmitted to the vessels of the neck, was heard at the aortic area, where a systolic thrill could be felt. Along the left border of the sternum in the third intercostal space a soft, blowing, high-pitched, diastolic murmur was heard. Both aortic stenosis and aortic insufficiency

were thought to be present. At times, when the beating was irregular, auricular sounds could be heard to the left of the sternum (Fig. 4.1). There were no signs suggesting congestive cardiac failure.

The urine, blood, and stool were normal. The blood Kahn reaction for syphilis was negative. An orthodiagram revealed definite cardiac enlargement; the frontal plane area was 38 per cent and the total transverse diameter 25 per cent above the average for normal subjects of the patient's height and weight. No calcification of the aortic valve could be made out. Roentgenologic examinations of the spine, soft tissues of the neck, and upper gastrointestinal tract demonstrated no abnormalities.

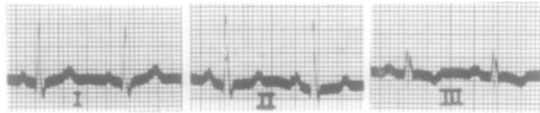


Fig. 1.—Case 1. Sept. 21, 1937. Day of admission. No spontaneous attacks. Carotid sinus pressure not applied.

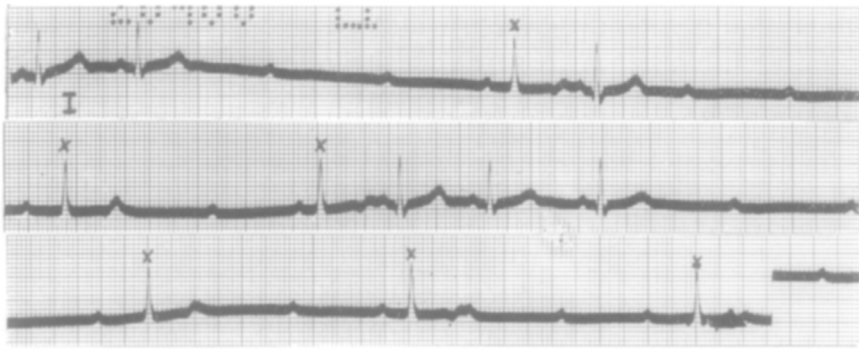


Fig. 2.—Case 1. Sept. 22, 1937. Lead I taken during spontaneous attacks of syncope. Idioventricular beats marked X. Continuous tracing.

The first electrocardiogram, taken when the patient was having no spontaneous attacks, was normal (Fig. 1). The heart rate was 83 per minute and the P-R interval 0.18 second. On the following day there were frequent spontaneous Adams-Stokes attacks. These were relieved by the hypodermic injection of 0.5 c.c. of adrenalin hydrochloride (1:1000 dilution). The electrocardiogram (Fig. 2) taken during these seizures showed repeated intervals of complete heart block associated with ventricular standstill or very slow idioventricular rhythm. The periods of complete heart block were separated by short intervals of normal rhythm. Similar episodes of complete heart block could be induced by carotid sinus pressure. Electrocardiograms were taken to demonstrate the effect of carotid sinus stimulation before (Fig. 3A) and after (Fig. 3B) the injection of 0.5 c.c. of adrenalin hydrochloride. These indicate that the drug prevented prolonged ventricular standstill by inducing the prompt onset of idioventricular beats.*

Figure 4A is a record taken 30 minutes after the hypodermic injection of 0.0012 gm. of atropine sulfate. There is no essential difference between this curve and those showing intermittent heart block. Twenty minutes after a second, similar

*From the examination of Fig. 3B it may not be at once apparent that complete A-V dissociation is present. The presence of idioventricular beats is indicated by variations in the form of the QRS deflections. These beats are represented by the ventricular complexes which show the larger R-waves and smaller S-waves.

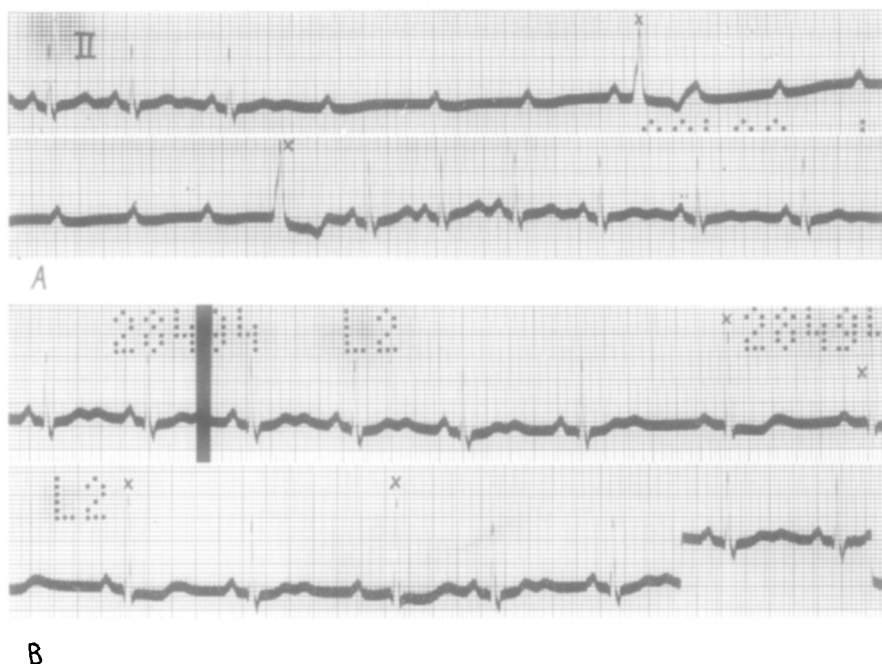

Fig. 3.—Case 1. Sept. 23, 1937. Lead II. *A*, before adrenalin; *B*, after adrenalin. Note the long ventricular asystole after carotid stimulation, in *A*. The heavy vertical line in *B* represents left carotid pressure. Idioventricular beats marked *X*. *A*₁ and *A*₂ continuous. *B*₁ and *B*₂ continuous.

dose of atropine sulfate, however, the ventricles (Fig. 4*B*) responded normally to the auricular impulses. At this time the normal rhythm could not be disturbed by carotid sinus stimulation (Fig. 4*C*).

Ephedrine sulfate in doses of 0.025 gm. four to six times daily for a period of six days failed to cause any change in the cardiac mechanism or in the frequency

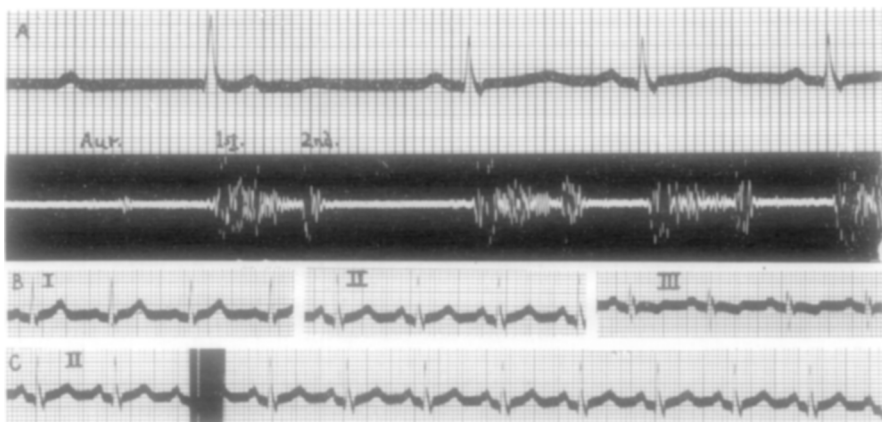


Fig. 4.—Case 1. Sept. 24, 1937. *A*, thirty minutes after atropine sulfate subcutaneously. Note the double auricular sound and the coarse murmur throughout systole. Microphone placed in the third intercostal space, left of sternum. Idioventricular beat in *A*. *B*, twenty minutes after second dose of atropine sulfate. Normal rhythm undisturbed by carotid sinus stimulation in *C*. Heavy vertical line in *C* represents left carotid pressure.

of the periods of asystole. Atropine sulfate by mouth in doses of 0.0004 gm. three to four times daily for a period of five days was also without demonstrable effect.

On Oct. 13, 1937, twenty-three days after the patient entered the hospital, the electrocardiogram showed for the first time partial heart block with three to one response and ventricular escape after each dropped beat (Fig. 5). Except for a brief period of one to one response which resulted from carotid sinus stimulation on Oct. 25, 1937, partial heart block persisted throughout the remainder of the period of hospitalization. With this change in the cardiac mechanism the syncopal attacks disappeared despite increased exercise and frequent carotid sinus stimulation. The patient was discharged from the hospital Oct. 27, 1937. At a check-up examination on April 4, 1938, he stated that he had been working and had had no attacks since leaving the hospital. At this time the electrocardiogram showed complete heart block with abnormal ventricular complexes.

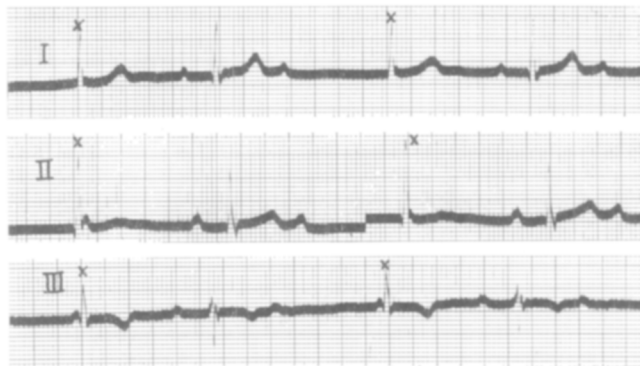


Fig. 5.—Case 1. Oct. 13, 1937. Partial heart block with ventricular escape. Similar to all records obtained during the remainder of hospital course. Idioventricular beats marked X.

Examination of those electrocardiograms showing complete heart block demonstrates several constant relationships. First, complete heart block interrupted the normal rhythm only when there was auricular slowing (Figs. 2, 3A, 3B), regardless of whether this occurred spontaneously or as the result of carotid sinus stimulation. Secondly, normal rhythm was never re-established unless the first transmitted auricular impulse was preceded by an idioventricular beat (Figs. 2, 3, 4). Since not all idioventricular beats were followed by a resumption of one to one response, we compared the time relations of those beats which were followed by resumption of normal rhythm with those which were not.

In order to study these phenomena, two types of measurements were made. All P-P intervals were measured and placed in two groups. In one group were those which were followed by a conducted auricular impulse and in the second were those which were not. Measurements from the initial deflection of the QRS complex of each idioventricular beat to the following P-wave were treated in a similar manner.

From the first set of figures a chart (Chart I) was constructed after the method of Lewis and Master.⁴ This chart shows clearly that the transmitted auricular impulses fall within a definite zone. The upper

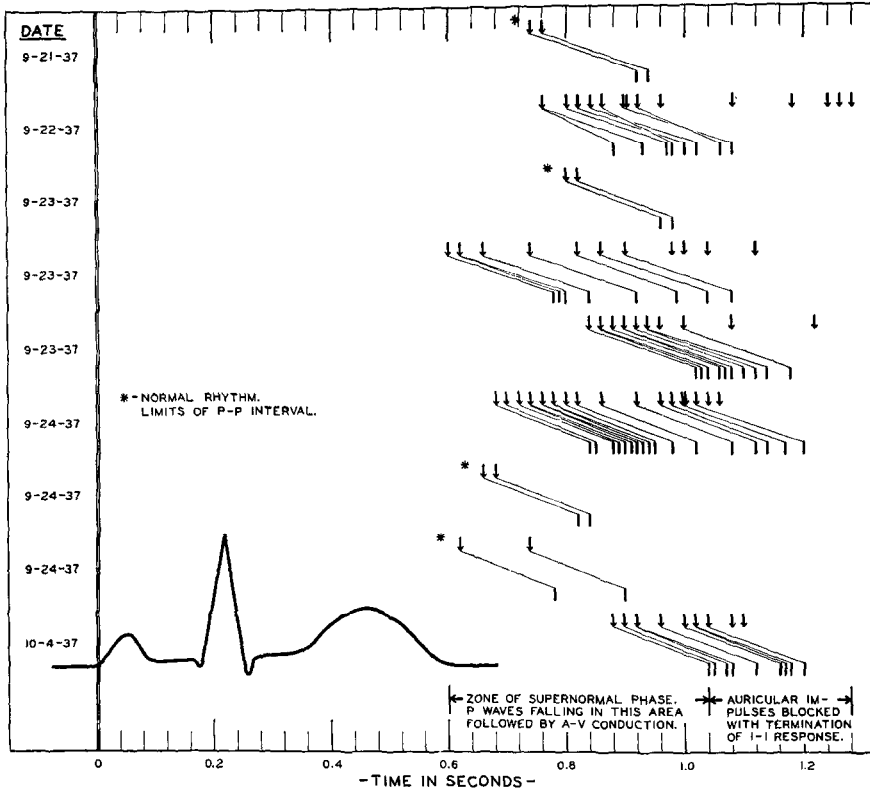


Chart I.

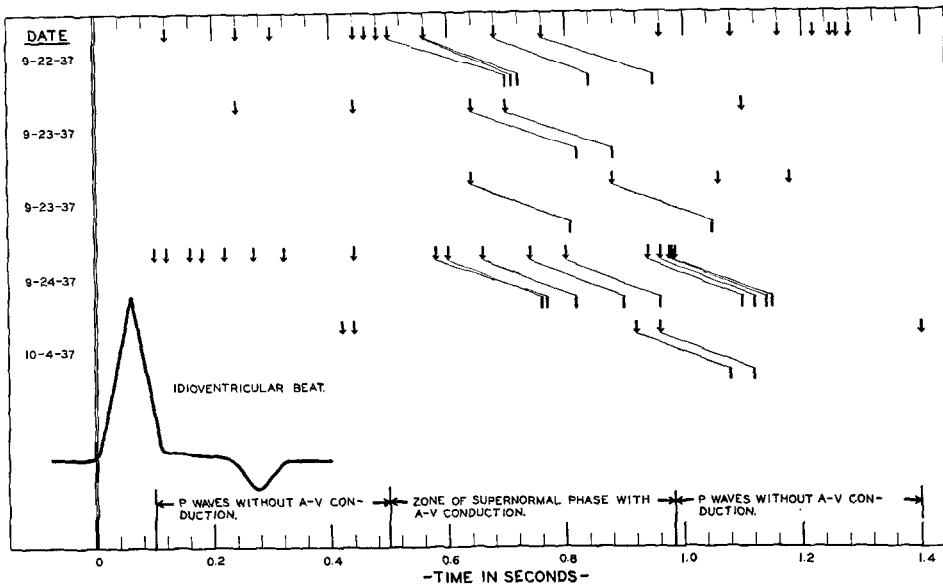


Chart II.

limit of this zone lies between 0.92 second and 1.04 seconds, the lower limit lies at least 0.6 second after the preceding P-wave. No opportunity was afforded to test the lower limit further. Although all of the P-R intervals are within normal limits (varying from 0.12 to 0.19 second) there is no apparent correlation between the length of the P-R interval and the position any particular transmitted impulse occupies within the zone specified. This is in contrast to the findings of Lewis and Master,⁴ who reported in their first case a gradual lengthening of the P-R interval from 0.120 to 0.168 second as the upper limit of the "responsive phase" was reached.

In a similar way it may be demonstrated (Chart II) that there is resumption of one to one response when the P-wave follows an idioventricular beat by an interval of at least 0.50 second. When this interval is 0.90 second transmission frequently fails, and when it is 0.98 second it invariably fails. In as much as failure of A-V conduction is always associated with auricular slowing and is never re-established unless an idioventricular beat occurs, it is clear that fatigue and recovery of the junctional tissues do not explain the observed phenomena.

Although there was apparently a pronounced vagal instability, the variations in vagal tone which occurred are not sufficient to explain the observations made. An increase in vagal tone might explain the onset of the block, but a decrease in vagal tone cannot explain the return of normal conduction. In all instances ventricular standstill was accompanied by auricular acceleration; yet in no instance (this is tested twenty-one times) was there re-establishment of A-V conduction until an idioventricular beat occurred.

We believe, therefore, that a supernormal phase was present during the recovery period of the junctional tissues. The characteristics of the tissue in the region where block occurred were such that the penetration of an impulse into this region from below, or the successful transmission of an impulse from above, was the only circumstance which induced supernormal conductivity. As might be anticipated, the boundaries of the interval during which the depressed region conducted varied slightly from day to day, particularly its upper boundary. Nevertheless, the limits of this interval remained remarkably constant, considering the variety of circumstances under which observations were made.

Chronic complete heart block ultimately occurred, and it is probable that the conduction defect was due to an organic lesion. Since it has been adequately shown that the existence of a supernormal recovery phase is an abnormal phenomenon associated with tissue injury, it is logical to assume that conditions were such as to favor its production in this case. In none of our records in which there was partial block was there evidence that a supernormal phase played a role in determining the cardiac mechanism. Rather, there were indications that recovery and fatigue were acting in the ordinary way; in one instance, when

auricular slowing was produced by carotid sinus pressure, there was continuous, although prolonged, A-V conduction for a short period (Fig. 6).

A review of the electrocardiograms published by Cheer and T'Ang,⁸ and Sachs and Traynor,⁹ which show paroxysmal complete heart block, suggests that the peculiarities of conduction which they observed might also be explained by assuming the occurrence of a supernormal phase during the recovery period of the junctional tissues.

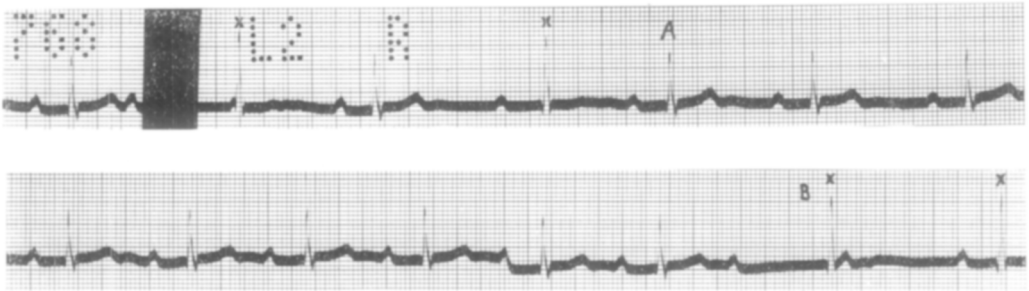


Fig. 6.—Case 1. Oct. 25, 1937. Beginning at A and terminating at B are eighteen responses of the ventricle to the slowed auricle. Result of right carotid pressure. Heavy vertical line represents right carotid pressure. Idioventricular beats marked X. Record is not continuous.

CASE 2.—O. S., a 68-year-old white woman, was admitted to the University Hospital for the first time on Sept. 8, 1933. She then complained of intermittent vaginal bleeding which had been present for two years. There were no symptoms referable to the cardiovascular system.

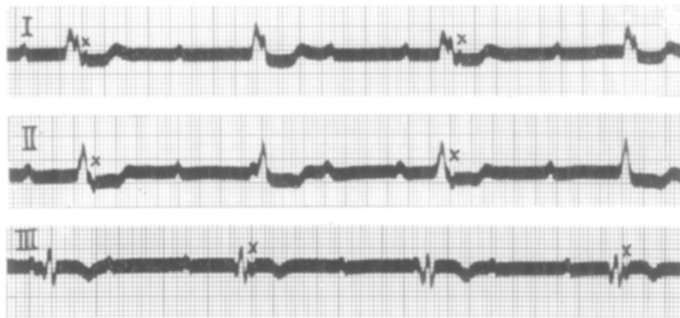


Fig. 7.—Case 2. Dec. 8, 1933. Complete heart block with abnormal ventricular complexes. Ventricular rate 35 per minute. QRS interval 0.14 second. Premature P-waves marked X in all leads, inverted in II and III. QRS-P interval 0.12 to 0.14 second.

On physical examination the patient was very obese. The heart was not enlarged. The heart rate was approximately 84 per minute and the beating was regular. There were no murmurs. The blood pressure was 200/118. A few râles were heard at the bases of the lungs, but there were no other signs suggestive of cardiac failure. Pelvic examination revealed adenocarcinoma of the cervix, a diagnosis proved by biopsy. Radium and deep roentgenotherapy were employed with good immediate result and there has been no recurrence of the tumor.

After leaving the hospital the patient began to notice edema and severe dyspnea. When re-examined on December 7, 1933, the blood pressure was essentially unchanged, but the heart rate was only 37 per minute. The beating was regular. All of the signs of moderate congestive cardiac failure were present. The presence of complete heart block was confirmed by an electrocardiogram (Fig. 7) taken Dec. 8, 1933. The ventricular complexes of this record are strikingly abnormal, and the QRS interval measures 0.14 second. In addition, some of the ventricular complexes are deformed by premature P deflections which are inverted in Leads II and III.

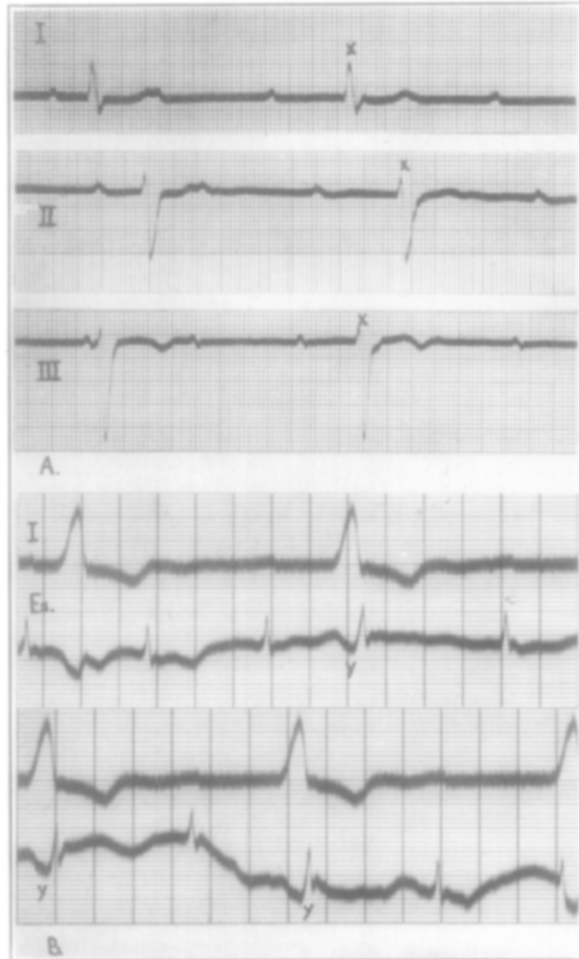


Fig. 8.—Case 2. Dec. 6, 1937. *A.* Complete heart block with abnormal ventricular complexes. Note in all leads slight deformation of the terminal part of the QRS complexes marked X; interpreted as abnormal P-waves. *B.* Esophageal lead. Frequent premature auricular contractions following ventricular beats marked Y. R-P interval measures 0.115 to 0.135 second. Record continuous.

A few days after the patient was admitted to the ward auricular fibrillation developed. The ventricular beating became irregular, indicating that the ventricles were responding to the fibrillating auricles. The ventricular rate was relatively slow and after the longer pauses ventricular escape frequently occurred. The ventricular complexes of the idioventricular beats were of the same form as those recorded previously, but the ventricular complexes of the sequential beats were of a

more normal type. They displayed pronounced left axis deviation, but the QRS interval was about 0.11 second. Deflections of this kind suggest the presence of incomplete left bundle branch block. Digitalis had been given just prior to these developments and when it was discontinued the auricular fibrillation disappeared and normal sinus rhythm returned. There was no further change in the contour of the ventricular complexes.

It was not until four years later that the patient was again examined. At this time complete A-V block was again present. In Lead III (Fig. 8A) occasional differences in the termination of the S-wave near the isoelectric line (Fig. 8A, marked X) suggest the occurrence of premature inverted P-waves similar in origin to those recorded in the tracings taken four years earlier (Fig. 7). In order to demonstrate auricular deflections to better advantage, esophageal leads were taken. The most satisfactory for our purpose is that taken with the esophageal electrode 35 cm. from the patient's lips (Fig. 8B).

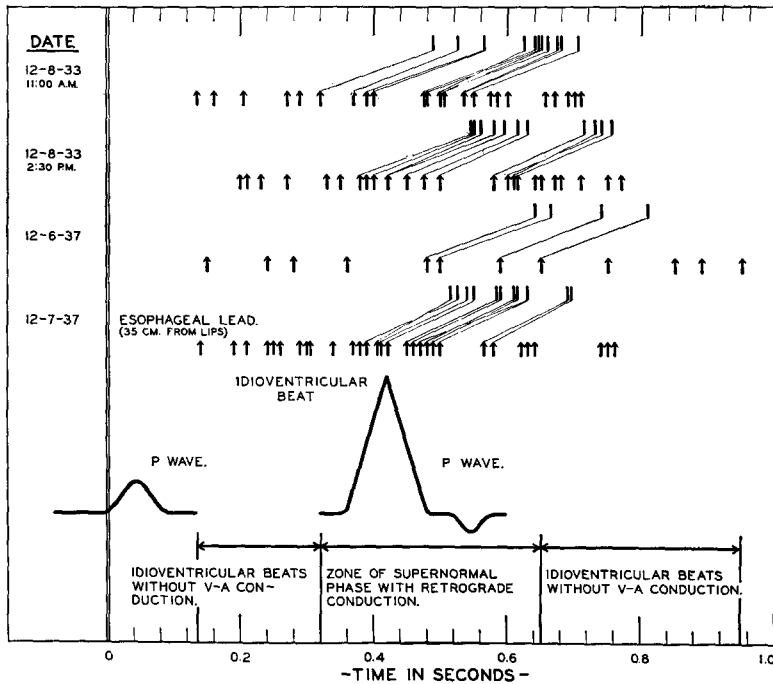


Chart III.

Measurements made from the beginning of each QRS complex deformed by a premature P-wave to the preceding P deflection show that these deformed complexes fall during a well-defined interval. Over the four-year period of observation the limits of this interval are fairly constant. Its extreme limits extend from 0.32 second to 0.65 second after the preceding P-wave.

If we assume that the premature P-waves represent retrograde conduction, an explanation based on the concept of the supernormal phase is suggested. In this instance the supernormal phase is produced by the penetration of the auricular impulse into the region of depressed

conductivity and permits retrograde conduction. A chart (Chart III) illustrating this mechanism has been constructed after the same plan as that used for Case 1.

Cases of a similar kind have frequently been reported in the literature. Some writers (Cohn and Fraser,¹⁰ Wilson and Robinson,¹¹ and Barker¹²) have considered the abnormal premature P-waves to be the result of impulses arising in the lower auricular or upper junctional tissue. Others (Danielopolu and Danulesco,¹³ and Wolfert and McMillan¹⁴) believed that they were due to the occasional retrograde transmission of one of the idioventricular impulses. In these cases it is possible that supernormal conductivity was present, although the examination of the published tracings does not prove this conclusively.

DISCUSSION

Supernormal conductivity in Case 1 was produced by penetration of a ventricular impulse into the depressed region and by successful A-V transmission through it. It is of interest to point out that during the periods of asystole there was always auricular acceleration until the P-P intervals were within the boundaries of the supernormal phase as outlined in Chart I. However, there was never resumption of A-V transmission until an idioventricular beat occurred. This indicates that auricular impulses were ineffective in modifying the conducting properties of the blocked zone unless they passed completely through it. On the other hand, the idioventricular impulses were able to set up a supernormal phase in spite of the fact that they never passed the region of block.

An opposite situation was present in Case 2. Here auricular impulses which presumably penetrated but did not pass the depressed region were effective in producing supernormal conductivity. In view of what has been said regarding Case 1 it is logical to expect that successful V-A transmission would also produce a supernormal phase. If such were the case, A-V transmission should have been resumed if the following P-wave fell within the supernormal phase produced by the retrograde impulse. Since each retrograde impulse was followed by a compensatory pause before discharge of the next auricular systole, this systole was always too late to reach the depressed region during the supernormal period.

Why a supernormal phase in atrioventricular conductivity should lead in one case to improved A-V conduction and in another case to improved V-A conduction is not altogether clear.

SUMMARY

Two cases of transient complete heart block are reported in which there was a supernormal phase in the conductivity of the depressed region. In the first case, penetration of the depressed zone by an impulse arising in the ventricle produced a supernormal phase during

which A-V conduction occurred. The conducted impulse in turn gave rise to a supernormal phase which permitted the next impulse to pass, so that normal sinus rhythm was established. It was maintained until auricular slowing caused the auricular impulse to fall outside of the period of supernormal conductivity. In the second case, impulses arising in the auricle produced in the depressed zone a supernormal phase which permitted retrograde conduction.

The authors wish to acknowledge their appreciation of the valuable suggestions and assistance of Dr. Frank N. Wilson and Dr. Franklin D. Johnston in this study.

REFERENCES

1. Adrian, E. D., and Lucas, K.: On the Summation of Propagated Disturbances in Nerve and Muscle, *J. Physiol.* **44**: 68, 1912.
2. Adrian, E. D.: Recovery Process of Excitable Tissues, *J. Physiol.* **54**: 1, 1920.
3. Ashman, R.: Conductivity in Compressed Cardiac Muscle: II. Supernormal Phase in Conductivity in Compressed Auricular Muscle of the Turtle Heart, *J. Physiol.* **74**: 140, 1925.
4. Lewis, T., and Master, A. M.: Supernormal Recovery Phase, Illustrated by Two Clinical Cases of Heart Block, *Heart* **11**: 371, 1924.
5. Wilson, F. N., and Herrmann, G. R.: Some Unusual Disturbances of the Mechanism of the Heart Beat, *Arch. Int. Med.* **31**: 923, 1923.
6. Ashman, R., and Herrmann, G. R.: Supernormal Phase in Conduction and a Recovery Curve for the Human Junctional Tissues, *AM. HEART J.* **1**: 594, 1926.
7. Wolferth, C. C.: So-called Supernormal Recovery Phase of Conduction in Heart Muscle, *AM. HEART J.* **3**: 706, 1928.
8. Cheer, S. N., and T'Ang, T. K.: Transient Complete Heart Block With Adams-Stokes Attacks and Normal Auriculo-Ventricular Conduction Between Attacks, *Chinese M. J.* **46**: 1081, 1932.
9. Sachs, A., and Traynor, R. L.: Paroxysmal Complete Auriculo-Ventricular Heart Block, *AM. HEART J.* **9**: 267, 1933.
10. Cohn, A. E., and Fraser, F. R.: The Occurrence of Auricular Contractions in a Case of Incomplete and Complete Heart Block Due to Stimuli Received from the Contracting Ventricles, *Heart* **5**: 141, 1914.
11. Wilson, F. N., and Robinson, G. C.: I. Two Cases of Complete Heart Block Showing Unusual Features, *Arch. Int. Med.* **21**: 166, 1918.
12. Barker, P. S.: The Occurrence of Auricular Beats Due to Stimulation of the Auricles by the Contracting Ventricles During Complete Heart Block, *AM. HEART J.* **1**: 349, 1926.
13. Danielopolu, D., and Danulesco, V.: Sur la Conductibilite Retrograde et sur la Phase Refractaire de l'Oreillette, *Arch. d. mal. du Coeur* **15**: 365, 1922.
14. Wolferth, C. C., and McMillan, T. M.: Observations on the Mechanism of Relatively Short Intervals in Ventriculoauricular and Auriculo-Ventricular Sequential Beats During High Grade Heart Block, *AM. HEART J.* **4**: 521, 1929.