

Preliminary Report

SERIAL ARTERIOGRAPHY OF THE DOG: A SIMPLIFIED TECHNIQUE

THOMAS L. DENT, M.D. AND S. MARTIN LINDENAUER, M.D.

SERIAL ARTERIOGRAPHY OF THE infradiaphragmatic arterial system of the dog is useful in many chronic experimental situations. There are disadvantages to repeated arterial cannulation to obtain such arteriograms. The small fragile arteries of the dog make Seldinger needle catheterization difficult. Direct exposure of the artery may be utilized but it is time-consuming, and a new site of cannula insertion is frequently necessary for each arteriogram. Fluoroscopy is necessary to insure accurate placement of the catheter tip each time an arteriogram is performed in order to obtain comparable serial arteriograms. Laboratories that are not equipped with fluoroscopy, therefore, may experience difficulty in obtaining reproducible serial arteriograms.

We have developed a method for serial arteriography which requires no fluoroscopic equipment. It is simple and efficient, and gives accurate reproducible results.

METHOD

Adult mongrel dogs, weighing 22-40 pounds were anesthetized with an intravenous injection of Pentobarbital (15 mg./pound) and intubated. Serial arteriograms were required in a study of femoral arteriovenous fistula and ureteral ligation. An X-ray plate was placed under the dog and, under sterile conditions, the lower abdominal aorta was exposed through a midline incision. The median sacral artery or

From the Department of Surgery, Section of General Surgery, University of Michigan Medical Center and the Veterans Administration Hospital, Ann Arbor, Michigan 48104.

Submitted for publication September 3, 1971.

the right or left internal iliac artery was isolated and ligated 1 cm. from its origin. An incision was made proximal to the ligature and a polyethylene catheter (usually PE 190) was introduced into the artery and threaded a pre-measured distance cephalad (Fig. 1B). A second ligature was then tied around the catheter and artery, and the lower ligature was used to doubly secure the catheter. A baseline arteriogram was then obtained using 50% Hypaque injected through the catheter. A subcutaneous pocket was created by dissecting the edge of the skin wound away from the abdominal muscles on the right side. The catheter was then filled with a heparin-saline solution (1000 units/cc.), tied at its end, and coiled gently in the subcutaneous pocket (Fig. 1A). The linea alba was then approximated, allowing the catheter to emerge from the peritoneal cavity between interrupted sutures, and the skin was closed.

At weekly intervals the animals were anesthetized and placed on an X-ray plate in the same position, being careful to maintain the same distance from X-ray source to plate. A 2- to 3-cm. vertical skin incision was made, or the previous incision reopened, over the subcutaneous pocket and the coiled catheter was retrieved. The catheter was untied, soft thrombus was spontaneously extruded by arterial pressure or gently suctioned with a syringe, and an arteriogram obtained by a similar injection of 50% Hypaque. The catheter was then refilled with heparin-saline solution, tied, and gently recoiled in the subcutaneous pocket. The pocket was filled with 0.5 gram Kanamycin in 5 cc. saline, and the skin was closed.

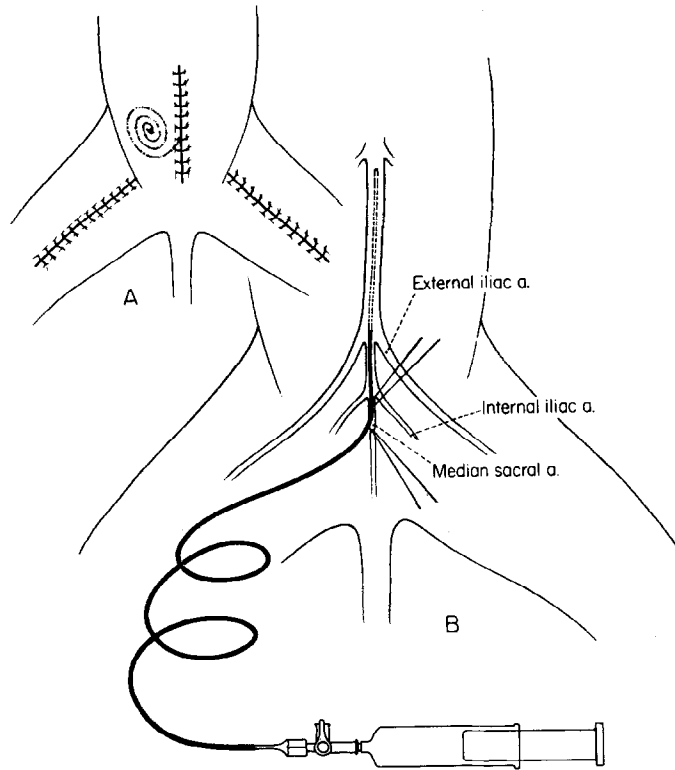


Fig. 1. Method of placement of catheter. The catheter may be permanently positioned at any level of the abdominal aorta. A. Subcutaneous pocket for catheter.

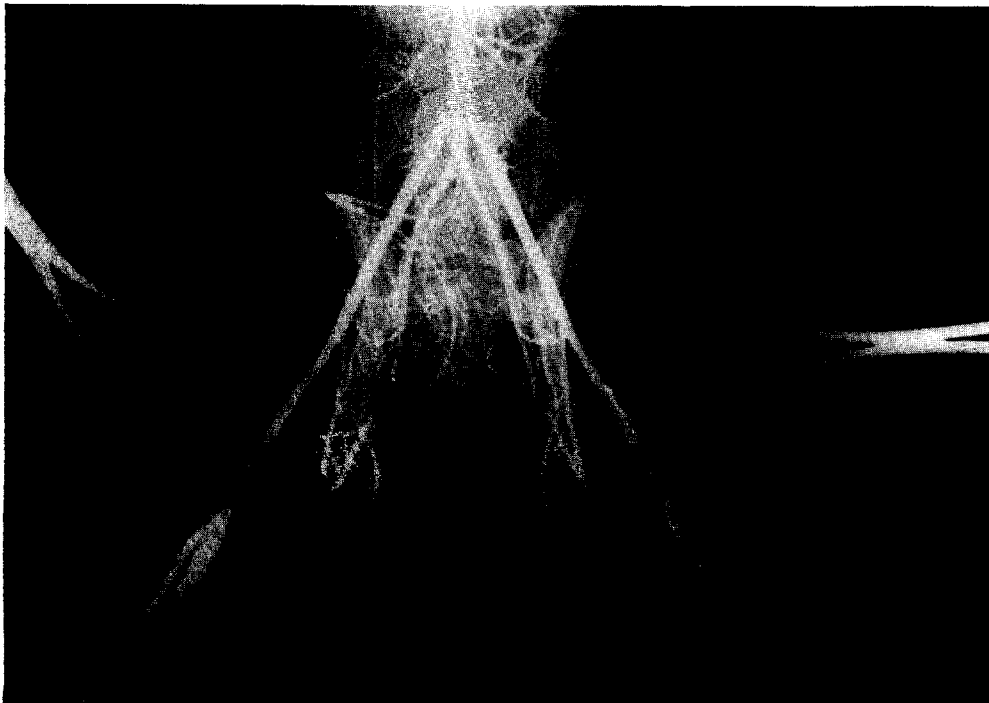

Fig. 2. Arteriogram showing lower abdominal, pelvic, and groin arterial system. An arteriovenous fistula and a femorofemoral bypass have been constructed in the right and left groins, respectively. The tip of the catheter is at bifurcation of aorta.

RESULTS

Twenty-four dogs underwent a total of 143 arteriograms through the implanted catheters. Each dog underwent weekly arteriography until his contribution to the study was completed. There were only two instances of catheter failure. One catheter was extruded at 4 weeks and another was occluded at 3 weeks with a thrombus which could not be removed. Both dogs had a new catheter placed in an internal iliac artery. No dog had to be removed from either study because of catheter diffi-

culties. No dog died as a direct result of catheter implantation or arteriography. The average number of weekly arteriograms obtained was six. The longest time any one dog underwent serial arteriography was 10 weeks.

With some practice in timing of the injection and exposure of the single X-ray film, an arteriogram of excellent quality could be obtained routinely (Figs. 2 and 3). These were easily reproducible and allowed precise comparative measurements of the arterial system to be made each week.

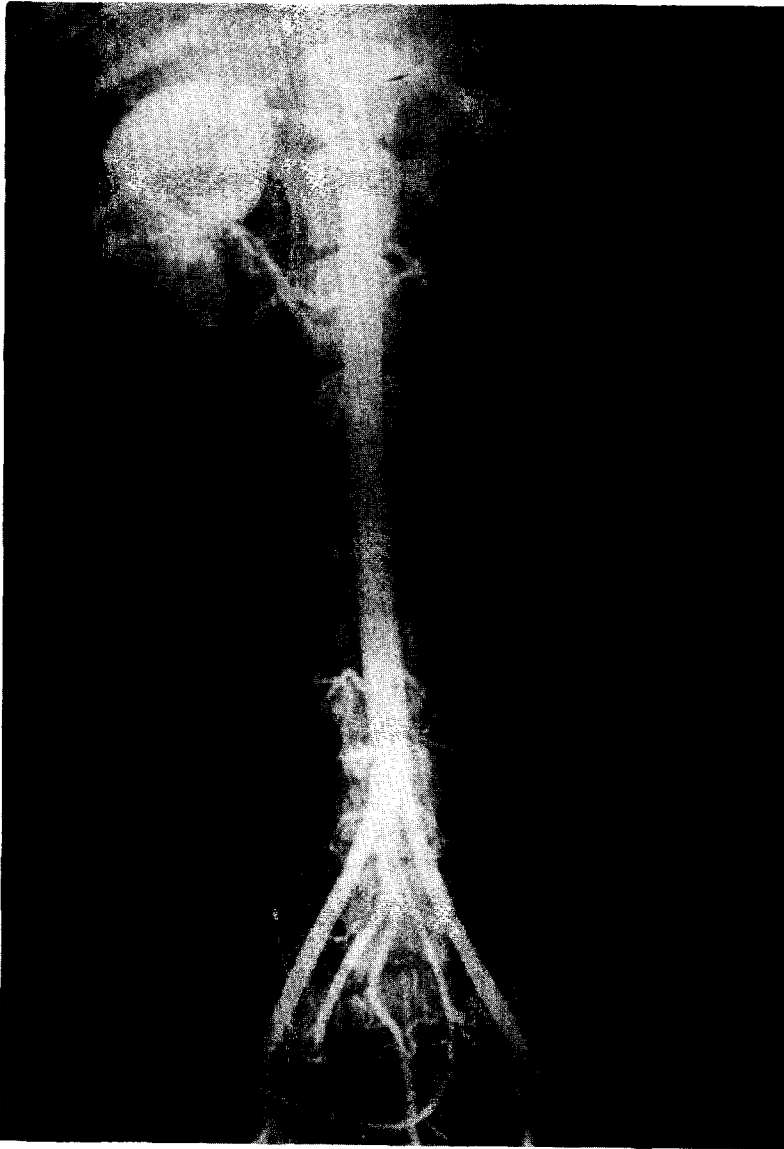

Fig. 3. Arteriogram showing abdominal aorta and its branches. The tip of the catheter is at the level of renal arteries.

COMMENT

Minor catheter difficulties were encountered. There were three occasions when small amounts of thrombus which could not be extracted had to be injected into the aorta to obtain catheter patency. No arteriographic or physical evidence of distal arterial embolus was seen in these dogs. The polyethylene catheters became slightly fragile during prolonged usage and several cracked. This problem was easily corrected by careful handling of the catheters and by leaving a 10- to 12-inch length of catheter coiled in the subcutaneous pocket, and then sacrificing the cracked distal part of the catheter.

An early problem of abscess formation around the catheter in the subcutaneous pocket was eliminated by instilling 0.5 gram Kana-

mycin in 5 cc. saline into the pocket after each arteriogram. Healing about the coiled catheter was then so rapid that the pocket was usually totally obliterated after 1 week.

If a catheter became occluded with a thrombus or was extruded, a new catheter could be inserted in an alternate artery (medial sacral, right or left internal iliac).

SUMMARY

A new technique for serial arteriography of the infradiaphragmatic arterial system in the experimental animal has been developed. Utilizing this technique 143 arteriograms have been obtained at weekly intervals in 24 dogs for up to 10 weeks. Advantages of the method are reproducible results, inexpensive equipment required, and ease of obtaining high-quality arteriograms.