

Clinical Report

Microcephaly, Jejunal Atresia, Aberrant Right Bronchus, Ocular Anomalies, and XY Sex Reversal

Catherine E. Keegan,¹ Eric Vilain,⁴ Mansoor Mohammed,⁵ Jessica Lehoczky,² William B. Dobyns,⁶ Steven M. Archer,³ and Jeffrey W. Innis^{1,2*}

¹Department of Pediatrics, University of Michigan Medical School, Ann Arbor, Michigan

²Department of Human Genetics, University of Michigan Medical School, Ann Arbor, Michigan

³Department of Ophthalmology, University of Michigan Medical School, Ann Arbor, Michigan

⁴Departments of Human Genetics and Pediatrics, University of California, Los Angeles, California

⁵Spectral Genomics, Houston, Texas

⁶Departments of Human Genetics, Neurology, and Pediatrics, The University of Chicago, Chicago, Illinois

We present a patient with microcephaly, jejunal atresia, aberrant right tracheobronchial tree, mild left blepharoptosis, and corectopia (irregular pupil), left sectoral iris stromal hypoplasia and peripheral anterior synechia, and 46,XY sex reversal. Testosterone and dihydrotestosterone (DHT) levels were within normal limits for a male infant at 3 weeks of age. Gonadectomy at age 18 months revealed immature testis tissue and no evidence of Müllerian structures. PCR amplification of the androgen receptor (AR) gene and flanking genomic regions revealed no evidence for deletion. Array-comparative genomic hybridization (array-CGH) for assessment of gene dosage in other regions of the genome was normal. This patient represents a multiple anomaly disorder similar to intestinal atresia—ocular anomalies—microcephaly syndrome (MIM#243605) but incorporating 46,XY sex reversal with testicular tissue, demonstrating a defect in the sexual differentiation pathway.

© 2003 Wiley-Liss, Inc.

KEY WORDS: microcephaly; jejunal atresia; ocular anomalies; sex reversal

INTRODUCTION

Sex reversal, characterized by a genetic sex that does not correspond to the phenotypic sex, is a compelling abnormality of human development. Both male to female reversal in XY individuals and female to male reversal in XX individuals occurs [McElreavey and Fellous, 1999; Vaiman and Pailhoux, 2000]. Sex reversal is often recognized in females who fail to undergo normal pubertal development and in children who are being evaluated for other malformations. Several mechanisms of sex reversal are known although the basis for isolated XY sex reversal is found in only 15% of patients [McElreavy et al., 1992].

Congenital microcephaly is defined as a birth head circumference of two or more standard deviations (SD) below the mean [Dobyns, 2002]. In patients with primary microcephaly (microcephaly in the absence of other anomalies), at least six genetic loci have been mapped over the past several years [Jackson et al., 1998; Jamieson et al., 1999; Roberts et al., 1999; Shrimpton et al., 1999; Jamieson et al., 2000; Moynihan et al., 2000; Pattison et al., 2000; Shrimpton et al., 2000].

Atresia of the small bowel presents in the neonatal period with bilious vomiting and abdominal distention, with distended loops of bowel seen on plain films. Simple intestinal atresias are generally thought to result from intrauterine vascular insults. Little has been written on the genetics of intestinal atresias. However, the syndrome of apple-peel jejunal atresia, microcephaly, and ocular anomalies (MIM#243605) has been reported in at least four patients [Stromme et al., 1993; Slee and Goldblatt, 1996; Stromme and Andersen, 1997; Celli et al., 2000].

We present a patient with microcephaly, jejunal atresia, aberrant right bronchus, mild left blepharoptosis and corectopia (irregular pupil), and XY sex reversal. This combination of malformations, similar to intestinal atresia—ocular anomalies and microcephaly syndrome is unique in its association with sex reversal.

*Correspondence to: Jeffrey W. Innis, M.D., Ph.D., Department of Human Genetics, MS II, 4811, Ann Arbor, MI 48109-0618. E-mail: innis@umich.edu

Received 29 April 2003; Accepted 24 June 2003

DOI 10.1002/ajmg.a.20455

MATERIALS AND METHODS

Patient Material

These studies were approved by the Institutional Review Board at each institution. After informed consent, a venous blood sample was obtained from the patient for lymphocyte immortalization and for genomic DNA preparation and analysis. Genomic DNA was prepared by standard methods.

SRY and *SOX9* Sequencing

SRY was sequenced using the following primers:

- *SRY*-5' (amplifying the 5'-region of *SRY*),
- forward: gtt gag ggc gga gaa atg caag,
- reverse: agc tgg tgc tcc att ctt gag,
- *SRY*-3' (amplifying the 3'-region of *SRY*),
- forward: cgc att cat cgt gtg gtc tcg,
- reverse: aca tag gca ggc tca ctt ctgg.

SOX9 was sequenced according to Kwok et al. [1995].

WNT4 Gene Dosage

Fluorescent in situ hybridization was performed on the patient's lymphocytes using a P1 clone containing the entire human *WNT4* gene, described in Jordan et al. [2001].

Androgen Receptor (AR) Deletion Analysis

PCR primers corresponding to the sequence tagged sites (STSs) DXS7498, AR (exon 4) and AR 3'-UTR [Schueler et al., 2000] were used to amplify genomic DNA from the patient using standard PCR conditions. All STSs were on the X chromosome in the region of the AR, allowing a deletion to be easily detected in an XY individual. Genomic DNA from an unrelated, normal male was used as a positive control.

Array-Comparative Genomic Hybridization (Array-CGH)

Patient genomic DNA (test-DNA) and reference genomic DNA (a sample with no known chromosomal abnormality) were digested, labeled, and hybridized to human bacterial artificial chromosome (BAC) array 3 megabase (MB) (Spectral GenomicsTM, Houston, TX) containing 1,003 non-overlapping BAC and PAC clones spotted in duplicate. These microarrays provide an average of 3 MB resolution for detection of chromosomal imbalances throughout the genome. Hybridization methods and microarray analysis were performed as described [Gunn et al., 2003].

CASE SUMMARY AND RESULTS

This female infant was conceived by non-consanguineous, normocephalic parents. A prenatal ultrasound showed an abdominal bubble consistent with a possible intestinal atresia and poor head growth. An amniocentesis was not performed. The pregnancy was complicated

by premature labor at 27 weeks and was treated with bed rest. There was progression of labor at 32 weeks gestation, and the patient was born by spontaneous vaginal delivery. The birth weight was 1.58 kg. The pediatric genetics service was consulted secondary to jejunal atresia and microcephaly. At that time, her weight was 1.58 kg (50%). Her length was 43 cm (50–75%), and her head circumference was 25 cm (greater than –3 SD). Her head was oxycephalic, with a flat occiput. Anterior and posterior fontanelles were open. Her facial features and the remainder of the physical examination were normal. A slightly prominent clitoris was noted, although it was within the normal range for a 32-week infant. A blood karyotype at the 550-band level revealed 46,XY. Endocrinologic evaluation revealed testosterone and dihydrotestosterone (DHT) levels of 51 and 12 ng/dl, respectively, at age 17 days. Repeat levels at age 22 days revealed increasing levels of testosterone (133 ng/dl) and DHT (31 ng/dl), reflective of the normal pattern seen in male infants during the first few months of life. Androstenedione (114 ng/dl), cortisol (14 µg/dl), dehydroepiandrosterone (DHEA) (337 ng/dl), 17-OH pregnenolone (426 ng/dl), and 17-OH progesterone (65 ng/dl) were all within normal limits at age 17 days. Jejunal atresia was repaired in the neonatal period by excision of the atretic segment and end-to-end anastomosis. Pathology showed histologic changes consistent with a jejunal web. An abdominal ultrasound failed to visualize a uterus, ovaries, or testes; a small fluid-filled mass was noted in the retrovesicular area. A voiding cystourethrogram showed a normal female urethra and a blind vaginal pouch. A pelvic MRI showed a fluid-filled cyst, which was thought to be a Müllerian remnant, and a primitive gonad was visualized on the left side. Kidneys were normal.

The patient was again evaluated at the age of 7 months (corrected gestational age of 5 months). At that time, she was rolling from back to stomach, sitting unassisted for a few seconds, transferring objects, smiling, laughing, and cooing. She remained microcephalic with a head circumference of 36.2 cm (greater than –4 SD). Her physical examination showed oxycephaly and a flat occiput. Her anterior fontanelle was open. She had left ptosis and a small capillary hemangioma near the right eyebrow. Genital exam showed moderate clitoromegaly. No gonads were palpated. The remainder of the examination was normal. She was also evaluated at 7 months of age by a pediatric ophthalmologist for possible ptosis and was diagnosed with mild left blepharoptosis and left corectopia (irregularity of the pupil), both of which were not visually medically significant. A head CT with bone windows showed open cranial sutures, persistently open Sylvian fissures, foreshortened frontal lobes, and a simplified gyral pattern consisting of abnormally shallow sulci with reduced number of gyri. The corpus callosum, brainstem, and cerebellum appeared normal. A prometaphase blood karyotype at the 750–850 band level was normal. A 7-dehydrocholesterol level was normal.

Psychometric testing at the prematurity-corrected age of 13 months using the Bayley scales of infant development revealed a mental development index of

82 and a psychomotor development index of 70, both measures within the mildly delayed range.

At age 18 months, she underwent bilateral gonadectomy. Intraoperatively, gonads were identified at the internal ring of the inguinal canal bilaterally; there was no evidence of a uterus or other Müllerian structures. Histological examination revealed normal-appearing testis; there was no evidence of ovarian tissue or fallopian tube structures.

Between ages 18 and 30 months, she was hospitalized three times for pneumonia requiring IV antibiotics. A work-up for gastroesophageal reflux disease, including a standard barium contrast-enhanced upper GI series and pH probe, was normal. A bronchoscopy subsequently revealed aberrant right bronchial anatomy, in which the tracheobronchus to the right-upper lobe was shown to arise above the carina.

Upon evaluation at age 39 months, she had severe allergies to many foods, including nuts, fish, and eggs, among others. Developmentally, she was able to move up and down stairs using one leg at a time. She could run, throw, or kick a ball and climb a ladder on the playground. She could feed herself, drink from a cup, place pegs in holes, and thread a necklace. She was easily distracted and had difficulty with two-command sequencing. She could speak in short sentences and ask questions. She was described as very sociable, particularly with adults she does not know. Her height was 86.5 cm (<5%), weight 10.2 kg (<5%), and head circumference was 41.2 cm (greater than -5 SD) (Fig. 1). On ophthalmology exam at this age she had a normal right anterior segment. The left eye had sectoral iris stromal hypoplasia associated with a peripheral anterior synechia, and there was a focal area of stromal edema in the cornea adjacent to the limbus, overlying the peripheral anterior synechia. MRI of the head at this age (Fig. 2) revealed no ventricular hydrocephalus, and findings were consistent with the prior CT scan.

Prior to our discovery of normal testicular tissue at surgery, we initiated studies to identify the presumed disrupted step in the sexual determination or differentiation pathways. No mutations were found in the *SRY* or *SOX9* genes, and the *WNT4* gene was not duplicated as assessed by fluorescence in situ hybridization. After discovery of normal testis tissue, we hypothesized that a deletion or rearrangement involving the *AR* gene might explain her phenotype. PCR analysis using short tandem repeat markers from Xq revealed that the region of the X chromosome containing and flanking the *AR* gene was not deleted. Finally, as a test of the results of our standard chromosome analyses, we carried out a comparison of gene dosage using array comparative genomic hybridization. Array-CGH analysis of the patient's DNA to BAC microarrays did not reveal any alteration across the genome using an array with a resolution of approximately one BAC/PAC clone every 3 MB (data not shown).

DISCUSSION

This report describes a patient with XY sex reversal in addition to jejunal atresia, aberrant tracheobronchial

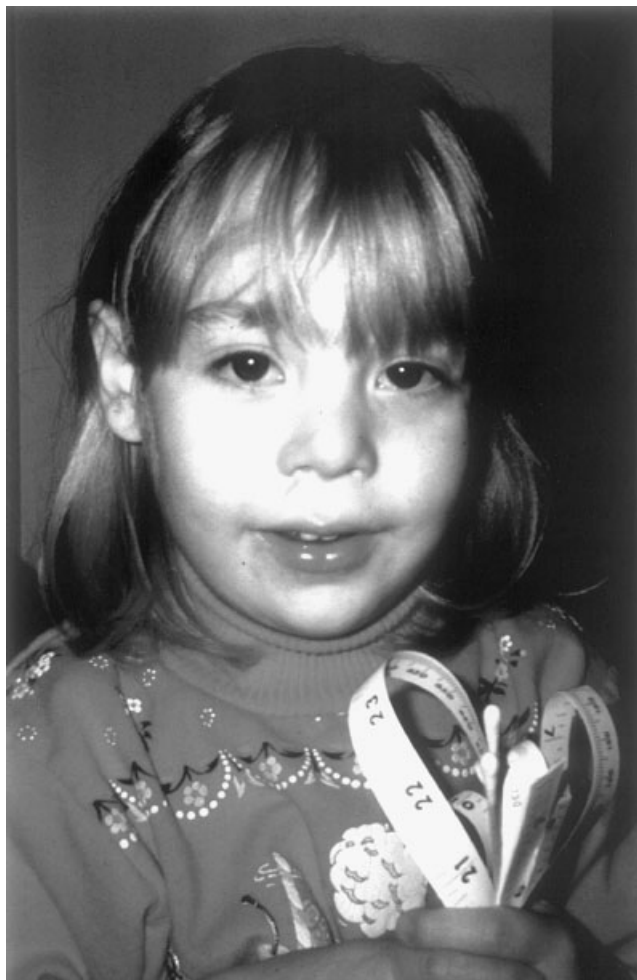

Fig. 1. Photographs depicting facial features of the patient at age 39 months.

tree, microcephaly, and psychomotor development in the mildly delayed range. This patient has normal female external genitalia with the exception of mild clitoromegaly, a blind vaginal pouch, no Müllerian structures, and testicular gonadal histology.

The absence of Müllerian structures points to normal function of steroidogenic factor-1, Müllerian inhibiting substance (MIS) and the MIS-receptor [Warne and Zajac, 1998]. The presence of testicular tissue and normal testosterone and DHT level places the defect in the sexual differentiation pathway possibly downstream of the *AR* [Warne and Zajac, 1998]. It is not surprising that *SRY* and *SOX9* sequences were normal given the presence of testicular tissue and the unique phenotype. Deletions and duplications of other portions of the human genome have been found to be associated with 46,XY sex reversal [Bennett et al., 1993; Wilkie et al., 1993; Bardoni et al., 1994; Wieacker et al., 1996; McDonald et al., 1997; Jordan et al., 2001]. Chromosome 1p32 or Xp21.3 duplication, and 9p24 or 10q26 deletions associated with sex reversal are typically large

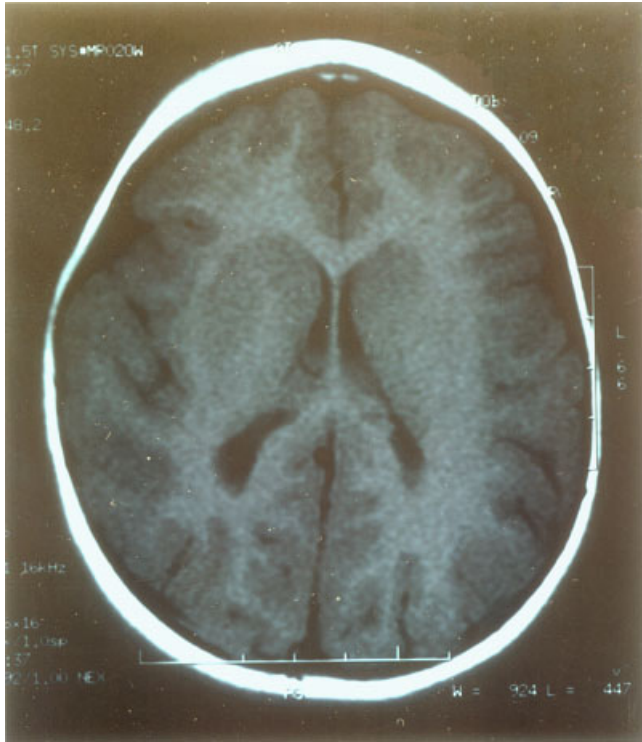


Fig. 2. Axial T1-weighted MR scan through the frontal horns, demonstrating abnormally short frontal lobes and simplified gyral pattern.

and would have been picked up by regular chromosome analysis or by array-CGH. In addition, translocations causing monosomy 9p24-associated sex reversal [McDonald et al., 1997] would also have been observed by regular karyotype. Patients with sex reversal and duplication of Xp21.3 (*DSS*) have partial gonadal dysgenesis with impaired testis formation [Bardoni et al., 1994]. We had planned to examine for duplication of Xp21.3 or deletion of 9q33 (where the steroidogenic factor-1 gene is located), but the unexpected pathology results suggested that these analyses were unnecessary.

While the genital phenotype in our patient resembles complete androgen insensitivity, we have ruled out a genomic deletion that encompasses the *AR* gene. A point mutation in the *AR* gene would not be expected to give rise to jejunal atresia, microcephaly, or the other developmental anomalies. Indeed, the proposed diagnostic criteria for androgen insensitivity syndrome specifies the absence of extragenital abnormalities [Gottlieb et al., 1999]. While a normal ratio of testosterone to DHT was seen in our patient, we have not ruled out a defect in 5- α reductase function. This could be explained by a deletion of one allele containing the 5- α reductase type II gene disrupting additional genes in combination with a point mutation on the other allele. Evaluation of 5- α reductase activity could exclude this possibility. An intriguing possibility is that the defect in our patient is downstream of the *AR*, possibly in a downstream target gene or a coactivator of *AR*. While several coactivators of *AR* have been

described [Heinlein and Chang, 2002], very few downstream target genes of *AR* have been identified [Nitsche and Hiort, 2000].

At least six genetic loci for primary autosomal recessive microcephaly have been mapped within the past few years [Jackson et al., 1998; Jamieson et al., 1999; Roberts et al., 1999; Shrimpton et al., 1999; Jamieson et al., 2000; Moynihan et al., 2000; Pattison et al., 2000; Shrimpton et al., 2000]. An additional locus for congenital microcephaly and 2-ketoglutaric aciduria in Amish children was recently mapped by Kelley et al. [2002]. Our patient's MRI findings are consistent with microcephaly with simplified gyral pattern, the phenotype described previously in a series of children with severe primary congenital microcephaly [Barkovich et al., 1998]. In addition, our patient had only mild developmental delays, similar to Group 1 in that study [Barkovich et al., 1998]. Whether this phenotype corresponds to that of the children in which the mapping studies were performed remains to be determined. Nevertheless, we have not excluded the possibility that our patient has a contiguous gene defect that encompasses one of these previously mapped loci.

Children with *ARX* mutations have X-linked lissencephaly, agenesis of the corpus callosum, enlarged ventricles, and ambiguous genitalia (XLAG) [Dobyns et al., 1999; Bienvenu et al., 2002; Kitamura et al., 2002; Stromme et al., 2002]. The cortex is thick, the head circumference is usually normal or mildly small, and all patients have severe seizures. All *ARX* null mutations have a very severe XLAG phenotype. Children with other mutations have a heterogeneous brain phenotype with mental retardation, severe seizures (most often infantile spasms), and dystonia. None have jejunal atresia or aberrant tracheobronchial anatomy. Thus, despite the compelling combination of simplified gyral pattern and sex reversal of our patient, it is unlikely that *ARX* is abnormal in our patient. Indeed, a gross deletion of the *ARX* locus in our patient was ruled out by successful *ARX*-specific PCR (data not shown).

There are few syndromes that incorporate jejunal atresia. Two syndromes deserve discussion. Feingold syndrome (MIM#164280) incorporates tracheoesophageal fistula, microcephaly and small palpebral fissures, duodenal atresia, and digital anomalies [Feingold, 1975; Innis et al., 1997] and references therein). It has been mapped to 2p23-p24 [Celli et al., 2000]. Although Feingold syndrome does not involve the jejunum, the proximal intestinal, cranial, and tracheoesophageal triad is compelling in light of the anomalies in our patient. Our patient did not have digital anomalies, which makes Feingold syndrome less likely.

Reports describing only four patients with apple-peel jejunal atresia, severe microcephaly, and ocular anomalies (MIM#243605) may represent a closer phenotypic overlap with our patient. This syndrome is associated with a normal karyotype and variable mental function [Stromme et al., 1993; Slee and Goldblatt, 1996; Stromme and Andersen, 1997; Bellini et al., 2002]. Stromme et al. [1993] reported two sisters with the condition. In the older sister, ocular anomalies of the right eye included microphthalmia and microcornea,

with corneal clouding without a clear corneal scleral limbus, a shallow anterior chamber, epicanthus, esotropia, and an irregular, dilated pupil. The left eye was normal. The younger affected sister had, in the left eye at 2 weeks of age, a corneal opacity that extended from the sclera into the upper nasal quadrant of the cornea. She also had epicanthal folds bilaterally. CT scan was reported normal in both girls. In the sporadic, male child reported by Slee and Goldblatt [1996], head CT scans at 8 weeks and 9 months of age revealed normal brain architecture, but the patient developed hydrocephalus by 9 months. His ocular abnormalities were bilateral and primarily affected the anterior chamber. Problems identified included marked, diffuse corneal clouding and vascularization, particularly peripherally, a very rudimentary right iris, and no apparent anterior chamber of the left eye. The left eye also had a peripheral descemetocoele and buphthalmos with a corneal diameter of 13.5 mm. The case reported by Bellini et al. [2002] had bilateral corneal leukoma, more prominent in the left eye and funduscopy was not possible due to the corneal clouding. MRI of the brain showed microcephaly, normal myelination, and no malformation of the brain or ocular system. CT scan in the latter case showed no calcifications. No report of this syndrome identified abnormal tracheobronchial anatomy or sex reversal. However, the combination of jejunal atresia, microcephaly, and ocular defects in our patient is quite suggestive, even though she did not have leukoma nor apple-peel variety jejunal atresia. The fact that only four patients have been described with this condition, two of which are sporadic and all of which have unrelated parents, suggests that the inheritance pattern is not clear. If our patient has this latter syndrome, then sex reversal may represent an expansion of the potential phenotype. However, the two boys reported so far had no indication of sexual ambiguity [Slee and Goldblatt, 1996; Bellini et al., 2002].

We hypothesize that the constellation of major anomalies is related in its etiology and is suggestive of either a microdeletion causing a disruption of several genes, or disruption of a single gene that regulates sexual differentiation, jejunal development, lung bronchial branching, ocular development, and brain growth.

ACKNOWLEDGMENTS

We thank the family for their patience and help in the preparation of this manuscript.

REFERENCES

- Bardoni B, Zanaria E, Guioli S, Florida G, Worley KC, Tonini G, Ferrante E, Chiumello G, McCabe ER, Fraccaro M, et al. 1994. A dosage sensitive locus at chromosome Xp21 is involved in male to female sex reversal. *Nat Genet* 7:497–501.
- Barkovich AJ, Ferriero DM, Barr RM, Gressens P, Dobyns WB, Truwit CL, Evrard P. 1998. Microlissencephaly: A heterogeneous malformation of cortical development. *Neuropediatrics* 29:113–119.
- Bellini C, Mazzella M, Arioni C, Fondelli MP, Serra G. 2002. "Apple-peel" intestinal atresia, ocular anomalies, and microcephaly syndrome: Brain magnetic resonance imaging study. *Am J Med Genet* 110:176–178.
- Bennett CP, Docherty Z, Robb SA, Ramani P, Hawkins JR, Grant D. 1993. Deletion 9p and sex reversal. *J Med Genet* 30:518–520.
- Bienvenu T, Poirier K, Friocourt G, Bahi N, Beaumont D, Fauchereau F, Ben Jeema L, Zemni R, Vinet MC, Francis F, Couvert P, Gomot M, Moraine C, van Bokhoven H, Kalscheuer V, Frints S, Gez J, Ohzaki K, Chaabouni H, Fryns JP, Desportes V, Beldjord C, Chelly J. 2002. ARX, a novel Prd-class-homeobox gene highly expressed in the telencephalon, is mutated in X-linked mental retardation. *Hum Mol Genet* 11:981–991.
- Celli J, van Beusekom E, Hennekam RC, Gallardo ME, Smeets DF, de Cordoba SR, Innis JW, Frydman M, Konig R, Kingston H, Tolmie J, Govaerts LC, van Bokhoven H, Brunner HG. 2000. Familial syndromic esophageal atresia maps to 2p23-p24. *Am J Hum Genet* 66:436–444.
- Dobyns WB. 2002. Primary microcephaly: New approaches for an old disorder. *Am J Med Genet* 112:315–317.
- Dobyns WB, Berry-Kravis E, Havernick NJ, Holden KR, Viskochil D. 1999. X-linked lissencephaly with absent corpus callosum and ambiguous genitalia. *Am J Med Genet* 86:331–337.
- Feingold M. 1975. Case report 30. *Synd Ident* 3:16–17.
- Gottlieb B, Pinsky L, Beitel LK, Trifiro M. 1999. Androgen insensitivity. *Am J Med Genet* 89:210–217.
- Gunn SR, Mohammed M, Reveles XT, Viskochil DH, Palumbos JC, Johnson-Pais TL, Hale DE, Lancaster JL, Hardies LJ, Boespflug-Tanguy O, Cody JD, Leach RJ. 2003. Molecular characterization of a patient with central nervous system dysmyelination and cryptic unbalanced translocation between chromosomes 4q and 18q. *Am J Med Genet* 120A:127–135.
- Heinlein CA, Chang C. 2002. Androgen receptor (AR) coregulators: An overview. *Endocr Rev* 23:175–200.
- Innis JW, Asher JH Jr, Poznanski AK, Sheldon S. 1997. Autosomal dominant microcephaly with normal intelligence, short palpebral fissures, and digital anomalies. *Am J Med Genet* 71:150–155.
- Jackson AP, McHale DP, Campbell DA, Jafri H, Rashid Y, Mannan J, Karbani G, Corry P, Levene MI, Mueller RF, Markham AF, Lench NJ, Woods CG. 1998. Primary autosomal recessive microcephaly (MCPH1) maps to chromosome 8p22-pter. *Am J Hum Genet* 63:541–546.
- Jamieson CR, Govaerts C, Abramowicz MJ. 1999. Primary autosomal recessive microcephaly: Homozygosity mapping of MCPH4 to chromosome 15. *Am J Hum Genet* 65:1465–1469.
- Jamieson CR, Fryns JP, Jacobs J, Matthijs G, Abramowicz MJ. 2000. Primary autosomal recessive microcephaly: MCPH5 maps to 1q25-q32. *Am J Hum Genet* 67:1575–1577.
- Jordan BK, Mohammed M, Ching ST, Delot E, Chen XN, Dewing P, Swain A, Rao PN, Elejalde BR, Vilain E. 2001. Up-regulation of WNT-4 signaling and dosage-sensitive sex reversal in humans. *Am J Hum Genet* 68:1102–1109.
- Kelley RI, Robinson D, Puffenberger EG, Strauss KA, Morton DH. 2002. Amish lethal microcephaly: A new metabolic disorder with severe congenital microcephaly and 2-ketoglutaric aciduria. *Am J Med Genet* 112:318–326.
- Kitamura K, Yanazawa M, Sugiyama N, Miura H, Iizuka-Kogo A, Kusaka M, Omichi K, Suzuki R, Kato-Fukui Y, Kamiirisa K, Matsuo M, Kamijo S, Kasahara M, Yoshioka H, Ogata T, Fukuda T, Kondo I, Kato M, Dobyns WB, Yokoyama M, Morohashi K. 2002. Mutation of ARX causes abnormal development of forebrain and testes in mice and X-linked lissencephaly with abnormal genitalia in humans. *Nat Genet* 32:359–369.
- Kwok C, Weller PA, Guioli S, Foster JW, Mansour S, Zuffardi O, Punnett HH, Dominguez-Steglich MA, Brook JD, Young ID, et al. 1995. Mutations in *SOX9*, the gene responsible for Campomelic dysplasia and autosomal sex reversal. *Am J Hum Genet* 57:1028–1036.
- McDonald MT, Flejter W, Sheldon S, Putzi MJ, Gorski JL. 1997. XY sex reversal and gonadal dysgenesis due to 9p24 monosomy. *Am J Med Genet* 73:321–326.
- McElreavey K, Fellous M. 1999. Sex determination and the Y chromosome. *Am J Med Genet* 89:176–185.
- McElreavey K, Vilain E, Abbas N, Costa JM, Souleyreau N, Kucheria K, Boucekkin C, Thibaud E, Brauner R, Flamant F, et al. 1992. XY sex reversal associated with a deletion 5' to the SRY "HMG box" in the testis-determining region. *Proc Natl Acad Sci USA* 89:11016–11020.
- Moynihan L, Jackson AP, Roberts E, Karbani G, Lewis I, Corry P, Turner G, Mueller RF, Lench NJ, Woods CG. 2000. A third novel locus for primary autosomal recessive microcephaly maps to chromosome 9q34. *Am J Hum Genet* 66:724–727.
- Nitsche EM, Hiort O. 2000. The molecular basis of androgen insensitivity. *Horm Res* 54:327–333.

- Pattison L, Crow YJ, Deeble VJ, Jackson AP, Jafri H, Rashid Y, Roberts E, Woods CG. 2000. A fifth locus for primary autosomal recessive microcephaly maps to chromosome 1q31. *Am J Hum Genet* 67:1578–1580.
- Roberts E, Jackson AP, Carradice AC, Deeble VJ, Mannan J, Rashid Y, Jafri H, McHale DP, Markham AF, Lench NJ, Woods CG. 1999. The second locus for autosomal recessive primary microcephaly (MCPH2) maps to chromosome 19q13.1-13.2. *Eur J Hum Genet* 7:815–820.
- Schueler MG, Higgins AW, Nagaraja R, Tentler D, Dahl N, Gustashaw K, Willard HF. 2000. Large-insert clone/STS contigs in Xq11-q12, spanning deletions in patients with androgen insensitivity and mental retardation. *Genomics* 66:104–109.
- Shrimpton AE, Daly KM, Hoo JJ. 1999. Mapping of a gene (*MRXS9*) for X-linked mental retardation, microcephaly, and variably short stature to Xq12-q21.31. *Am J Med Genet* 84:293–299.
- Shrimpton AE, Braddock BR, Hoo JJ. 2000. Narrowing the map of a gene (*MRXS9*) for X-linked mental retardation, microcephaly, and variably short stature at Xq12-q21.31. *Am J Med Genet* 92:155–156.
- Slee J, Goldblatt J. 1996. Further evidence for a syndrome of “apple peel” intestinal atresia, ocular anomalies, and microcephaly. *Clin Genet* 50:260–262.
- Stromme P, Andersen W. 1997. Developmental aspects in apple peel intestinal atresia-ocular anomalies-microcephaly syndrome. *Clin Genet* 52:133.
- Stromme P, Dahl E, Flage T, Stene-Johansen H. 1993. Apple peel intestinal atresia in siblings with ocular anomalies and microcephaly. *Clin Genet* 44:208–210.
- Stromme P, Mangelsdorf ME, Shaw MA, Lower KM, Lewis SM, Bruyere H, Lucherath V, Gedeon AK, Wallace RH, Scheffer IE, Turner G, Partington M, Frints SG, Fryns JP, Sutherland GR, Mulley JC, Gez J. 2002. Mutations in the human ortholog of *Aristaless* cause X-linked mental retardation and epilepsy. *Nat Genet* 30:441–445.
- Vaiman D, Pailhoux E. 2000. Mammalian sex reversal and intersexuality: Deciphering the sex-determination cascade. *Trends Genet* 16:488–494.
- Warne GL, Zajac JD. 1998. Disorders of sexual differentiation. *Endocrinol Metab Clin North Am* 27:945–967.
- Wieacker P, Missbach D, Jakubiczka S, Borgmann S, Albers N. 1996. Sex reversal in a child with the karyotype 46,XY, dup (1) (p22.3p32.3). *Clin Genet* 49:271–273.
- Wilkie AO, Campbell FM, Daubeney P, Grant DB, Daniels RJ, Mullarkey M, Affara NA, Fitchett M, Huson SM. 1993. Complete and partial XY sex reversal associated with terminal deletion of 10q: Report of 2 cases and literature review. *Am J Med Genet* 46:597–600.