
CLINICAL REVIEW

The concept that squamous cell carcinoma of the head and neck metastasizes to regional lymph nodes in a predictable distribution has become generally accepted. Clinical application of this concept has decreased the morbidity of treatment through selective modifications of the radical neck dissection and through more accurate application of irradiation to target the nodal basins at risk. Appropriate application of this more selective treatment requires an understanding of the patterns of lymphatic drainage to the neck. This beautifully illustrated review is highlighted by color figures depicting the site specific distribution of metastatic neck nodal sites. The information presented draws heavily from the classic article by Lindberg from 1972 which is updated by review of more contemporary articles. Advances in the use of positron emission tomography (PET) and active research investigating lymphoscintigraphy with sentinel node biopsy are expected to continue to advance the understanding of lymphatic drainage patterns.

Henry T. Hoffmann, MD, *Section Editor*

CERVICAL NODAL METASTASES IN SQUAMOUS CELL CARCINOMA OF THE HEAD AND NECK: WHAT TO EXPECT

Suresh K. Mukherji, MD,^{1,2} Diane Armao, MD,² Varsha M. Joshi, DNB²

¹ Division of Neuroradiology, and Department of Otolaryngology, Head & Neck Surgery, University of Michigan Health System, 1500 E. Medical Center Drive, Ann Arbor, Michigan 48109-0030. E-mail: suresh@med.umich.edu

² Department of Radiology, University of North Carolina School of Medicine, Chapel Hill, North Carolina 27599-7510

Accepted 29 March 2001

Abstract: The treatment and management of malignancies of the head and neck is directly altered by the presence of metastatic cervical adenopathy. The treatment of nodal metastases in squamous cell carcinoma of the head and neck (HNSCCA) is determined by the lymphatic drainage of the upper aerodigestive tract. The lymphatic drainage is site-specific and occurs in a predictable manner. The purpose of this text is to provide an overview of the normal routes of lymphatic drainage in the head and neck and correlate this with the current nodal classification system. The specific aims of this manuscript are to 1) illustrate the expected lymphatic drainage patterns of HNSCCA arising in the different subsites (nasopharynx, oropharynx, oral cavity, larynx,

and hypopharynx) and 2) review the expected frequency of metastases within nodal groups for HNSCCA that arise in these locations. An understanding of the topographical distribution and incidence of cervical lymph node metastases plays an integral role in the physical examination and radiological evaluation of patients with HNSCCA. For the neuroradiologist, this information may increase the ability to identify those nodal groups at risk for metastatic involvement. © 2001 John Wiley & Sons, Inc. *Head Neck* 23: 995–1005, 2001.

Keywords: lymph nodes; SCCA; metastases

The treatment of cervical lymph nodes in patients with squamous cell carcinoma of the head and neck (HNSCCA) is based on the lymphatic drainage of the upper aerodigestive tract. The

Correspondence to: S. K. Mukherji

© 2001 John Wiley & Sons, Inc.

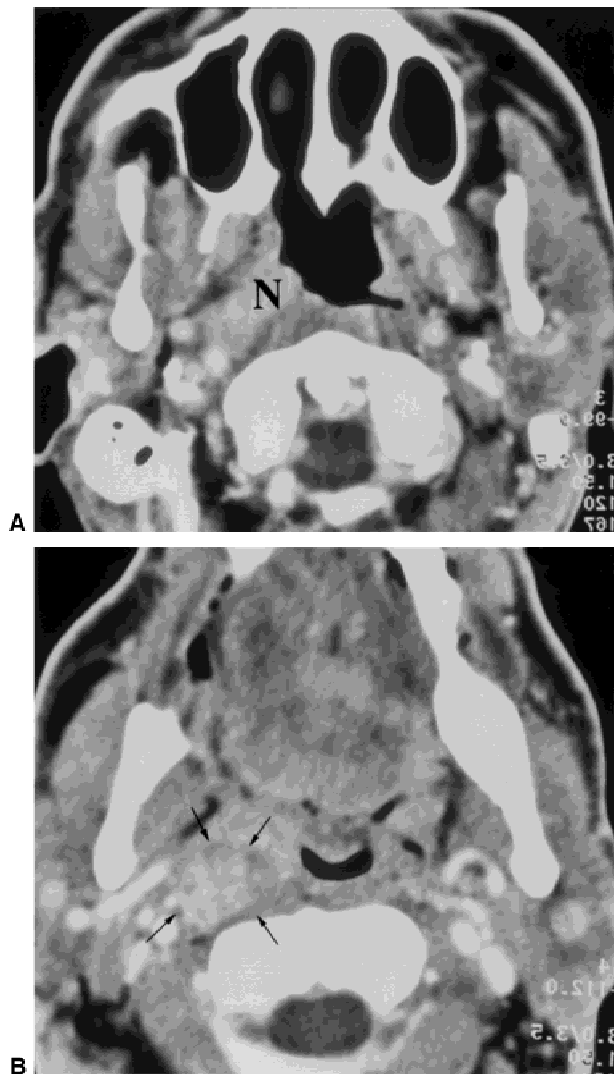

FIGURE 2. Nasopharyngeal Cancer.
A: Axial contrast-enhanced CT scan demonstrates an enhancing mass in the right nasopharynx. (N)
B: Axial contrast-enhanced CT scan in the same patient shows a metastatic right sided retropharyngeal lymph node. (black arrows)
C & D: Schematic illustrations demonstrate the ipsilateral (C) and contralateral (D) nodal groups most likely at risk for developing nodal metastases from nasopharyngeal carcinoma. Note that only the most common nodal groups are highlighted on each side using the following color scheme: **red** $\geq 45\%$, **dark blue** = **15%-45%**, **purple** $\leq 15\%$. This paradigm will be followed for all following subsite illustrations. On the ipsilateral side, groups II (82%) and V (73%) are most likely at risk for developing nodal metastases. The groups at highest risk for metastases on the contralateral side are groups II (36%) and V (41%). Please refer to Table 1 for a listing of specific percentages for each individual nodal group. (The retropharyngeal lymph node involvement as illustrated in the figure 2B is not depicted in this schematic illustration.)

lymphatic drainage varies with the anatomic subsite. However, within a subsite, the drainage occurs in a predictable manner. We review the drainage patterns using the current classification system of the most common subsites of malignancies in the upper aerodigestive tract^{1,2} (Fig. 1). We also review the expected frequency of metastases within nodal groups in these locations to emphasize the importance of evaluating these areas.^{3,4}

ANALYSIS

The percentages of nodal involvement presented in this manuscript are derived from the classic articles by Lindberg and Byers, which reported the distribution of cervical lymph nodes metastases from various sites in the head and neck.^{3,4} Lindberg analyzed patients with “clinical evidence” of cervical node metastases.³ A “clinically positive” neck was defined by Lindberg as a node “usually greater than 1cm, spherical rather than flat ovoid, and harder than the nonmetastatic lymph node”.³ The percent involvement of the nodal subsites used in this manuscript was derived from Lindberg’s data using the following equation for each anatomic subsite:

$$\frac{\text{\# of patients with clinically positive nodes within each nodal group}}{\text{total \# of patients with clinically positive necks for each anatomic subsite}}$$

Lindberg did not report the distribution of cervical lymph nodes metastases from true vocal cord carcinoma. Byers et al reported the relative percentage of node involvement by nodal subsite in the N0 neck following elective node dissection for true vocal cord carcinoma. Thus, the information regarding the relative percentages of lymph node involvement from true vocal cord carcinoma presented in this manuscript was directly obtained by Byers et. al.⁴ Only the ipsilateral neck was evaluated since this was the only side reported.⁴

Table 1. Frequency of cervical nodal metastases in nasopharyngeal carcinoma

Nodal group	Ipsilateral (%)	Contralateral (%)
I	7	1
II	82	36
III	31	17
IV	16	6
V	73	41
Supraclavicular	11	7

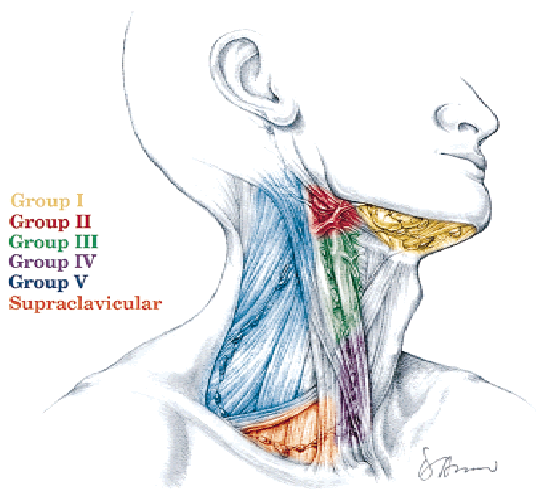
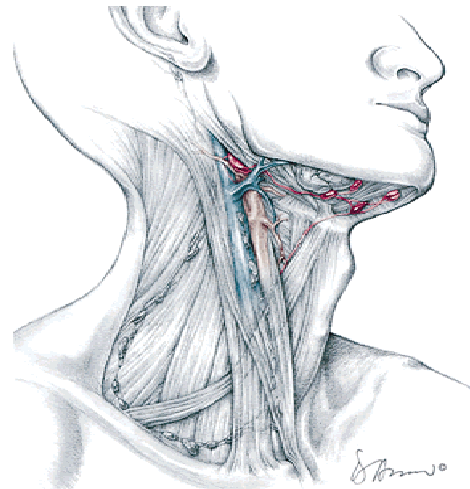
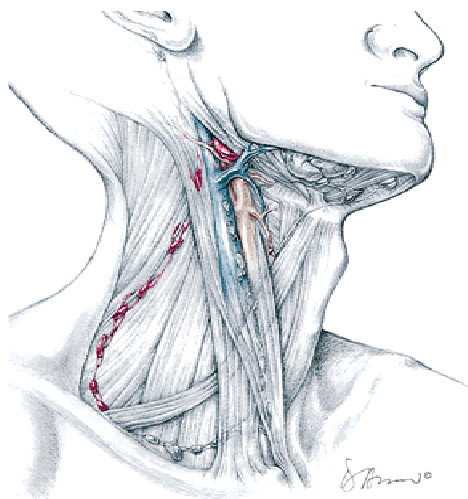


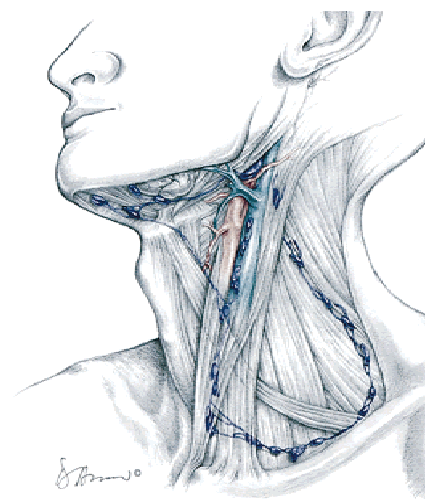
FIGURE 1. Schematic illustration of the head and neck showing the current nodal classification.



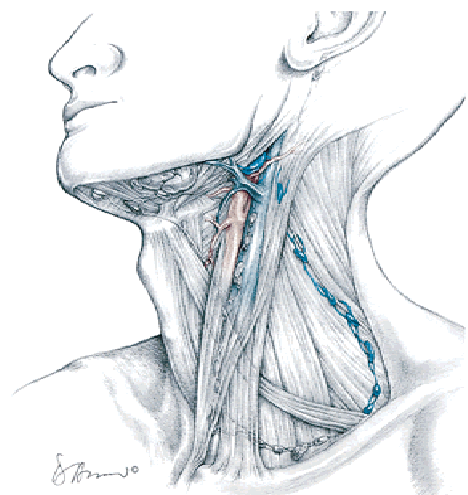
B
FIGURE 3B. Floor of Mouth Cancer. See Figure 3 on page 1000 for legend.



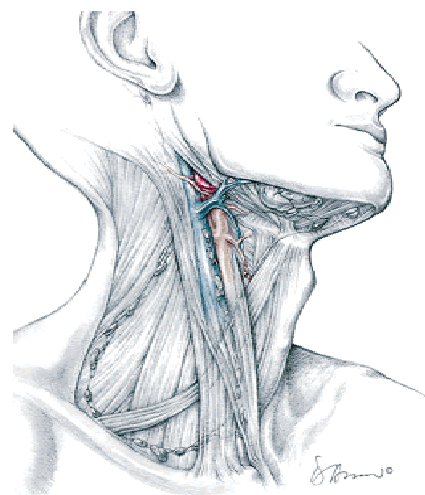
C
FIGURE 2C. Nasopharyngeal Cancer. See Figure 2 on page 996 for legend.



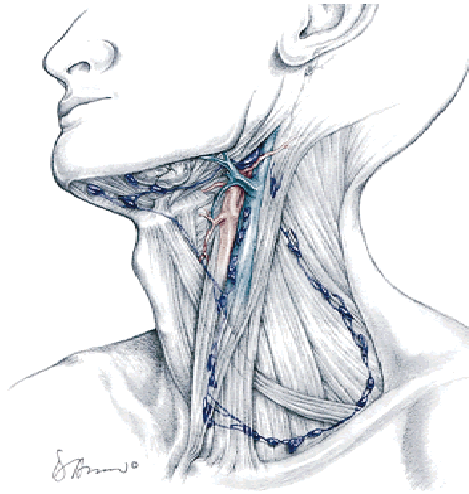
C
FIGURE 3C. Floor of Mouth Cancer. See Figure 3 on page 1000 for legend.



D
FIGURE 2D. Nasopharyngeal Cancer. See Figure 2 on page 996 for legend.

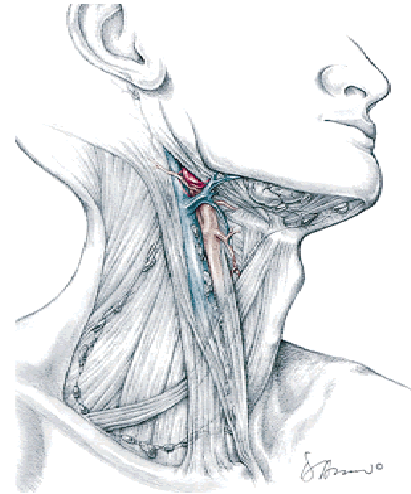


B
FIGURE 4B. Oral Tongue Cancer. See Figure 4 on page 1000 for legend.



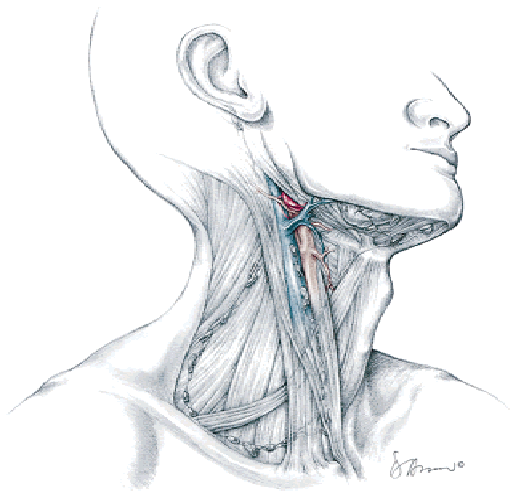
C

FIGURE 4C. Oral Tongue Cancer. See Figure 4 on page 1000 for legend.



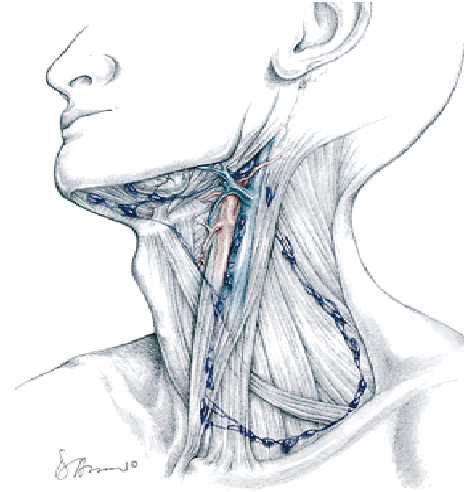
C

FIGURE 6C. Tonsil Cancer. See Figure 6 on page 1001 for legend.



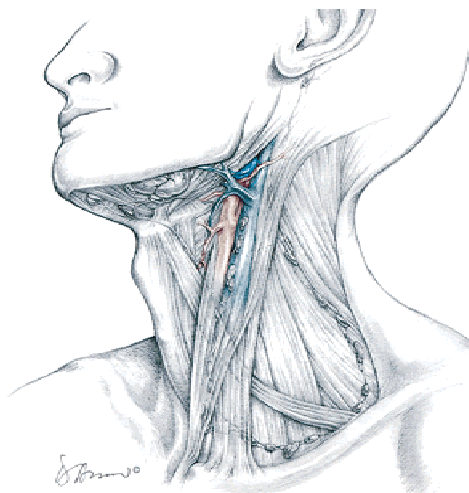
B

FIGURE 5B. Tongue Base Cancer. See Figure 5 on page 1001 for legend.



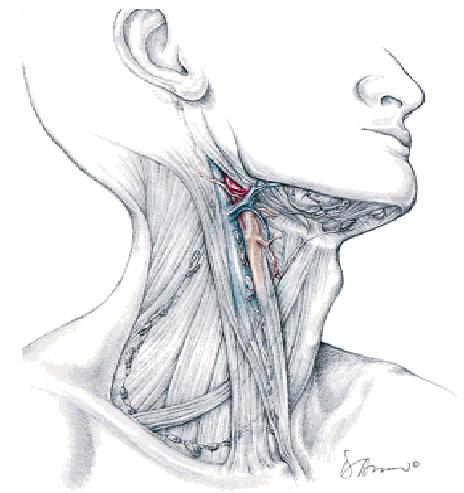
D

FIGURE 6D. Tonsil Cancer. See Figure 6 on page 1001 for legend.



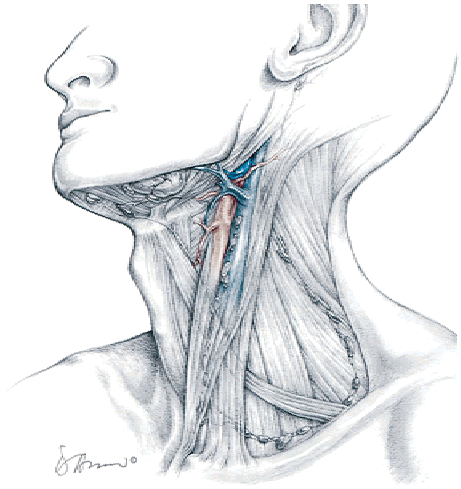
C

FIGURE 5C. Tongue Base Cancer. See Figure 5 on page 1001 for legend.



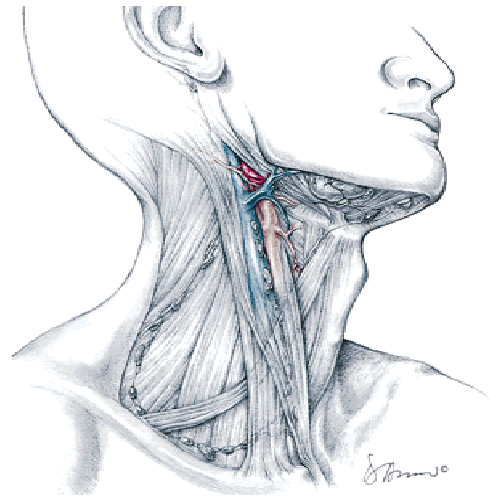
C

FIGURE 7C. Soft Palate Cancer. See Figure 7 on page 1002 for legend.



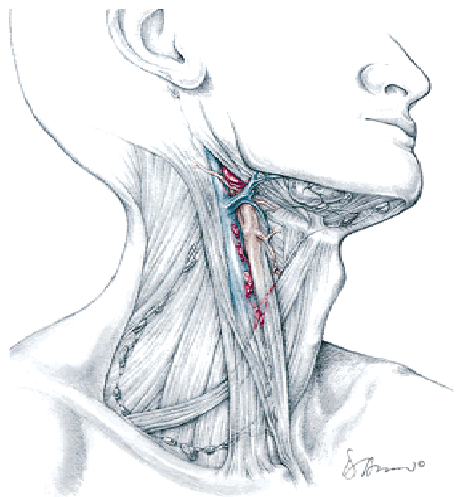
D

FIGURE 7D. Soft Palate Cancer. See Figure 7 on page 1002 for legend.



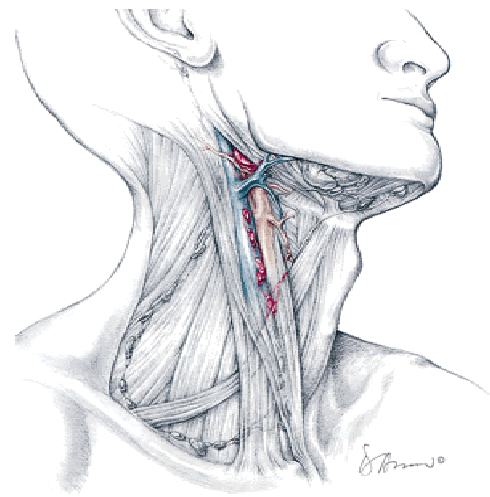
B

FIGURE 9B. Glottic Cancer. See Figure 9 on page 1003 for legend.



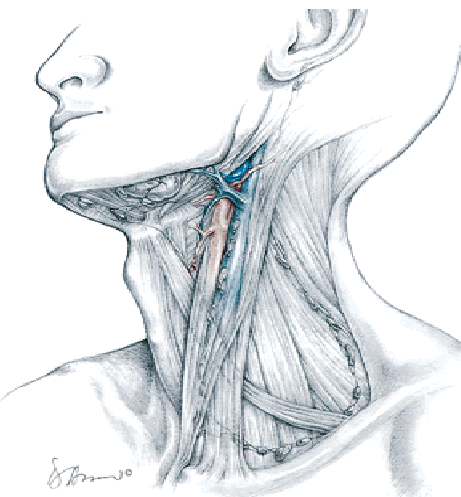
B

FIGURE 8B. Supraglottic Cancer. See Figure 8 on page 1003 for legend.



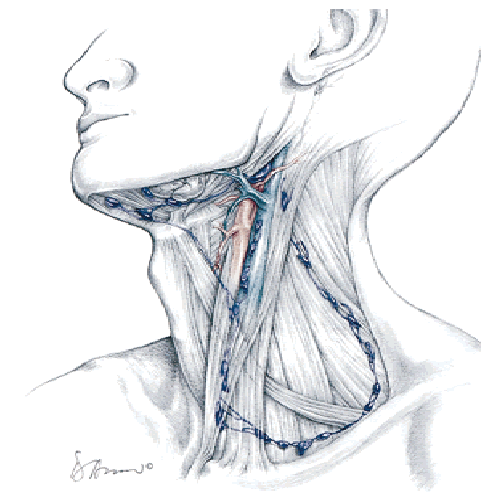
C

FIGURE 10C. Pyriform Sinus Cancer. See Figure 10 on page 1004 for legend.



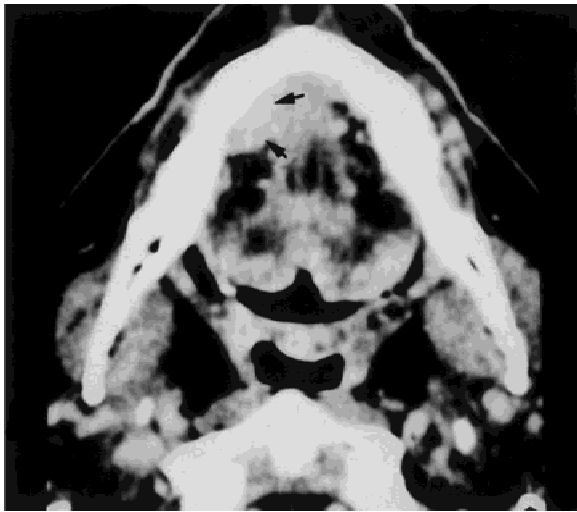
C

FIGURE 8C. Supraglottic Cancer. See Figure 8 on page 1003 for legend.



D

FIGURE 10D. Pyriform Sinus Cancer. See Figure 10 on page 1004 for legend.

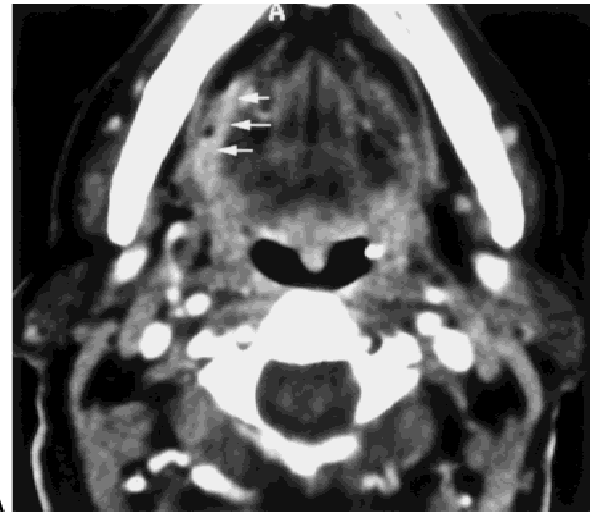

A

FIGURE 3. Floor of Mouth Cancer.

A: Axial contrast-enhanced CT image shows an enhancing mass in the anterior floor of mouth on the right. (black arrows)

B & C: Schematic illustrations demonstrate the ipsilateral (B) and contralateral (C) nodal groups most likely at risk for developing nodal metastases from a floor of mouth carcinoma. On the ipsilateral side, groups I (70%) and II (54%) are most likely at risk for developing nodal metastases. There is less than a 15% likelihood of metastases for contralateral nodal groups I - V. Please refer to Table 2 for a listing of specific percentages for each individual nodal group.



A

FIGURE 4. Oral Tongue Cancer.

A: Axial contrast-enhanced CT image shows an enhancing mass along the right lateral aspect of the oral tongue. (white arrows)

B & C: Schematic illustrations demonstrate the ipsilateral (B) and contralateral (C) nodal groups most likely at risk for developing nodal metastases from oral tongue carcinoma. On the ipsilateral side, group II (85%) is most likely at risk for developing nodal metastases. There is less than a 15% likelihood of metastases for contralateral nodal groups I - V. Please refer to Table 3 for a listing of specific percentages for each individual nodal group.

SUBSITES

Nasopharynx. The lymphatic vessels drain in two general directions, lateral and medial.^{1,3} The primary drainage is the lateral pathway. These lymphatic channels pierce the superior constrictor muscle and drain into the lateral retropharyngeal, high group II and high group V lymph nodes. Inconsistent channels have been described that can drain directly to group II lymph nodes.¹ Rarely, the intraparotid lymph nodes can be involved due to invasion of the eustachian tube, tympanic membrane or external auditory canal that drain to this unusual nodal group. The medial drainage pathway drains the roof and poste-

rior wall of the nasopharynx.¹ These vessels penetrate the visceral fascia at the skull base and drain into the median retropharyngeal lymph nodes. Lymphatic drainage is often bilateral so both sides of the neck are at risk for cervical nodal metastases (Fig. 2) (Table 1).

Oral Cavity.

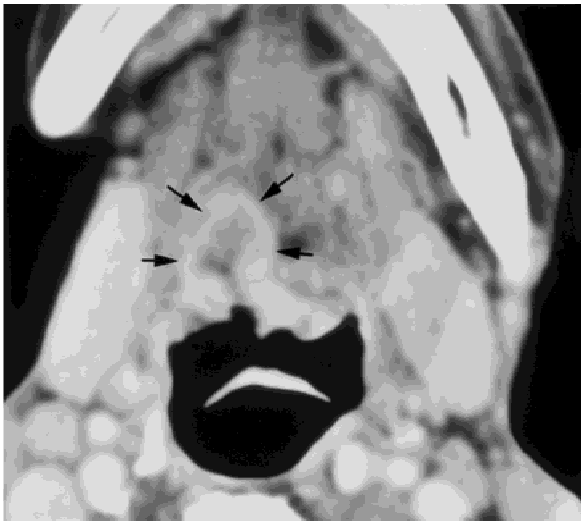Floor of mouth (FOM). The lymphatic drainage of the FOM is supplied by an anterior and posterior complex.^{1,3} The anterior complex drains the anterior half of the FOM and anterior portion of the sublingual gland. These lymphatic vessels terminate in the Group I nodes. The posterior group drains the posterior two-thirds of the FOM. The primary drainage is to the ipsilateral Group II

Table 2. Frequency of cervical nodal metastases in floor of mouth carcinoma

Nodal group	Ipsilateral (%)	Contralateral (%)
I	70	5
II	54	6
III	14	0
IV	6	1
V	3	0
Supraclavicular	1	0

Table 3. Frequency of cervical nodal metastases in oral tongue carcinoma

Nodal group	Ipsilateral (%)	Contralateral (%)
I	37	6
II	85	9
III	15	4
IV	4	1
V	1	0
Supraclavicular	0	0



A

FIGURE 5. Tongue Base Cancer.

A: Axial contrast-enhanced CT image shows an aggressive mass involving the right tongue base. (black arrows)

B & C: Schematic illustrations demonstrate the ipsilateral (B) and contralateral (C) nodal groups most likely at risk for developing nodal metastases from base of tongue carcinoma. On the ipsilateral side, group II (88%) is at greatest risk for developing nodal metastases. The group at highest risk for nodal metastases on the contralateral side is group II (31%). Please refer to Table 4 for a listing of specific percentages for each individual nodal group.

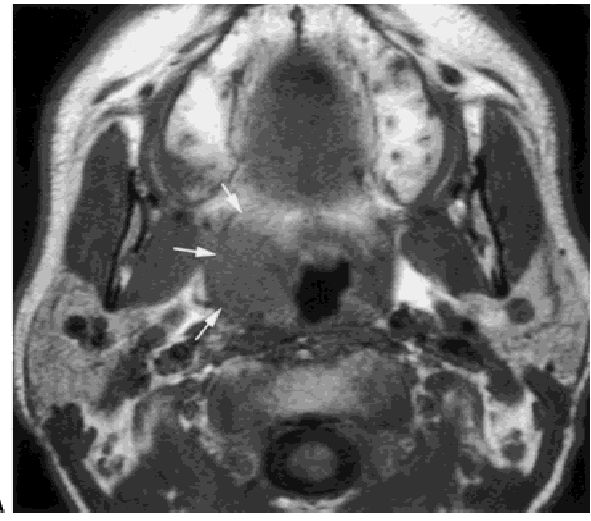
lymph nodes. However, there is occasionally a direct lymphatic drainage to the Group III nodes that bypasses the Group II nodes.¹

Anatomic studies have shown significant cross-over of the lymphatic drainage of superficial lymphatic capillaries. As a result, both sides of the neck are at risk for metastases arising from FOM malignancies (Fig. 3) (Table 2).

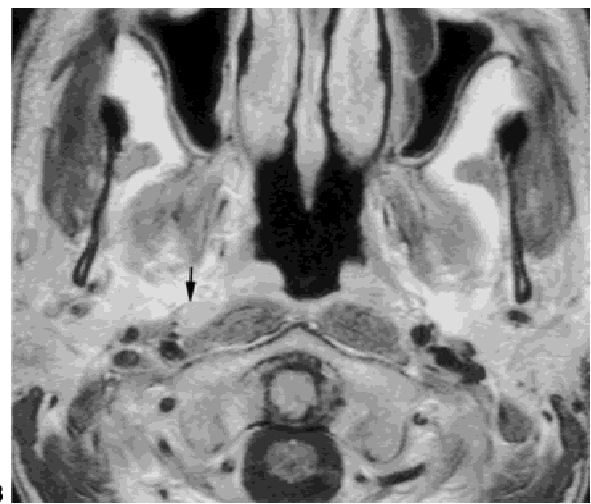
Oral tongue. A superficial and deep lymphatic network drains the oral tongue.^{1,3} The superficial network extends from the tip of the tongue to the circumvalate papillae and drains into the muscular network. There are three main components of the deep muscular lymphatic drainage pathways

Table 4. Frequency of cervical nodal metastases in tongue base carcinoma

Nodal group	Ipsilateral (%)	Contralateral (%)
I	8	1
II	88	31
III	40	7
IV	9	3
V	12	2
Supraclavicular	4	1



A



B

FIGURE 6. Tonsil Cancer.

A: Non-contrast T1W axial image shows a mass involving the right tonsil. (white arrows)

B: Contrast-enhanced T1W axial image shows an enlarged ipsilateral metastatic retropharyngeal lymph node. (black arrow)

C & D: Schematic illustrations demonstrate the ipsilateral (C) and contralateral (D) nodal groups most likely at risk for developing nodal metastases from tonsillar carcinoma. On the ipsilateral side, group II (97%) is at risk for developing nodal metastases. There is less than a 15% likelihood of metastases for contralateral nodal groups I - V. Please refer to Table 5 for a listing of specific percentages for each individual nodal group. (The retropharyngeal lymph node involvement as illustrated in the figure 6B is not depicted in this schematic illustration.)

for the oral tongue.¹ The anterior (apical) pathway drains the tip of the oral tongue and primarily drains to Group III or less likely to Group I. The lateral (marginal) group drains the lateral one-third of the dorsum of the tongue from the tip to the circumvallate papillae.¹ These lymphatic channels drain to either Groups I, II, or III. The central pathway drains the central two-thirds of

Table 5. Frequency of cervical nodal metastases in tonsillar carcinoma

Nodal group	Ipsilateral (%)	Contralateral (%)
I	16	3
II	97	13
III	24	3
IV	13	2
V	23	7
Supraclavicular	0	0

the tongue. These vessels drain to the Group I nodes or course through a sublingual node and terminate in group III nodes. Investigators have also identified direct metastases to Group IV without involvement of groups I-III (“skip metastases”).⁴ Cross-drainage in the oral tongue by is common, thereby placing both sides of the neck at risk for nodal metastases (Fig. 4) (Table 3).

Oropharynx.

Tongue base. The lymphatic drainage of the tongue base consists of a superficial and deep muscular lymphatic network.^{1,3} The superficial network is continuous with the superficial plexus that covers the oral tongue. The primary drainage is to Groups II and III. The deep lymphatic drainage may drain ipsilaterally or have direct branches that drain to the contralateral neck (Fig. 5) (Table 4).

Palatine tonsil. The lymphatic drainage of the tonsil is to the ipsilateral Group II and retropharyngeal lymph nodes.^{1,3} A less common route of drainage is to the Group III nodes. Rouviere did not describe cross-lymphatic drainage for this area (Fig. 6) (Table 5).

Soft palate. Rouviere described three separate drainage pathways for the soft palate, anterior, middle, and posterior.^{1,3} Of these three, the middle is the most constant pathway. The lymphatic vessels of the middle path extend from the soft palate to the inner margin of the posterior belly of the digastric muscle and primarily drain into Group II nodes.¹ The middle pathway normally has crossed lymphatic drainage. The lymphatics that comprise the posterior pathways are present in 60% of cases.^{1,3} These vessels penetrate the superior constrictor muscle into the retropharyngeal space and normally drain into the lateral retropharyngeal lymph nodes. Crossed drainage of the posterior pathways has been shown to be present in 50% of individuals. The

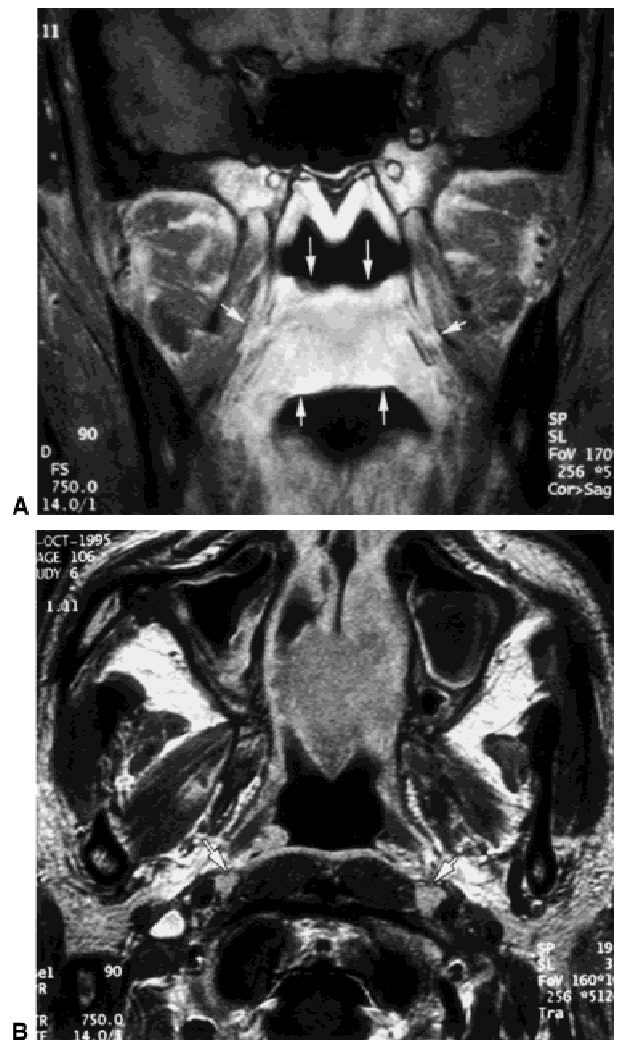


FIGURE 7. Soft Palate Cancer.

A: Contrast-enhanced T1W coronal image shows an enhancing mass involving the soft palate. (white arrows)

B: Contrast-enhanced T1W axial image shows bilateral enlarged retropharyngeal lymph nodes. (white arrows)

C & D: Schematic illustrations demonstrate the ipsilateral (C) and contralateral (D) nodal groups most likely at risk for developing nodal metastases from lateralized soft palate carcinoma. On the ipsilateral side, group II (86%) is at greatest risk for developing nodal metastases. The group at highest risk for nodal metastases on the contralateral side is group II (29%). Please refer to Table 6 for a listing of specific percentages for each individual nodal group. (The retropharyngeal lymph node involvement as illustrated in the figure 7B is not depicted in this schematic illustration.)

anterior pathway is present in half of individuals and drains into the Group I lymph nodes. This region has crossed lymphatics in 50% of cases. Although both the anterior and posterior pathways are potential drainage pathways for the soft palate, the posterior pathway is the more common pathway for the soft palate lesions while the an-

Table 6. Frequency of cervical nodal metastases in soft palate carcinoma

Nodal group	Ipsilateral (%)	Contralateral (%)
I	9	6
II	86	29
III	26	6
IV	6	0
V	0	3
Supraclavicular	0	0

terior pathway is more common for hard palate tumors (Fig. 7) (Table 6).

Larynx.

Supraglottic larynx. The lymphatic drainage is separated into two components, a superficial mucosal component that drains into a deeper system of collecting ducts.^{1,3} The deep system forms a draining pedicle near the anterior aspect of the aryepiglottic fold. This unites with the lymphatic drainage of the inferior pharynx. The draining vessels exit the larynx through the natural defect in the thyrohyoid membrane that permits passage of the superior laryngeal neurovascular

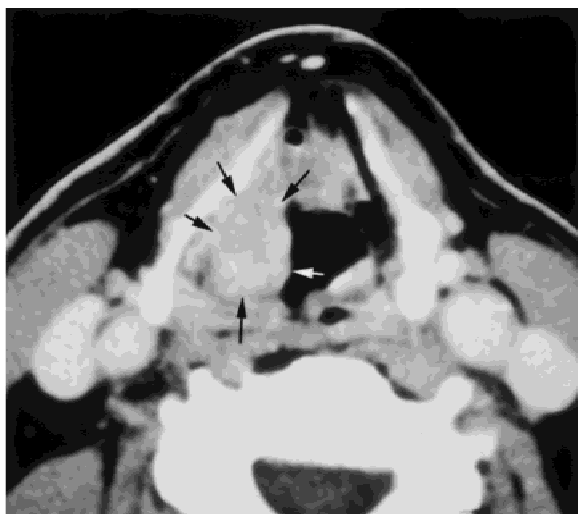

FIGURE 8. Supraglottic Cancer.
A: Contrast-enhanced axial CT image shows an enhancing mass involving the right aryepiglottic fold. (arrows)
B & C: Schematic illustrations demonstrate the ipsilateral (B) and contralateral (C) nodal groups most likely at risk for developing nodal metastases from supraglottic carcinoma. On the ipsilateral side, groups II (67%) and III (48%) are most likely at risk for developing nodal metastases. The group at highest risk for metastases on the contralateral side is group II (21%). Please refer to Table 7 for a listing of specific percentages for each individual group.

Table 7. Frequency of cervical nodal metastases in supraglottic carcinoma

Nodal group	Ipsilateral (%)	Contralateral (%)
I	2	0
II	67	21
III	48	10
IV	15	5
V	9	4
Supraclavicular	3	

bundle. At this point, one component of the lymphatic drainage extends superiorly and terminates in the ipsilateral Group II nodes. Another component extends transversely and drains into nodes located at the junction of Groups II and III. There is occasionally a third component that drains into the nodes located in Group III nodes. Tumors involving the supraglottic larynx are at risk for crossed lymphatic drainage. However, the mechanism by which this occurs is debatable. There appears to be cross-drainage of the superficial mucosal lymphatics.^{1,3} However, no consistent direct cross-drainage of the deep collecting duct has been described (Fig. 8) (Table 7).

Glottic larynx. There is a paucity of lymphatics draining the true vocal cords (TVC). The superfi-

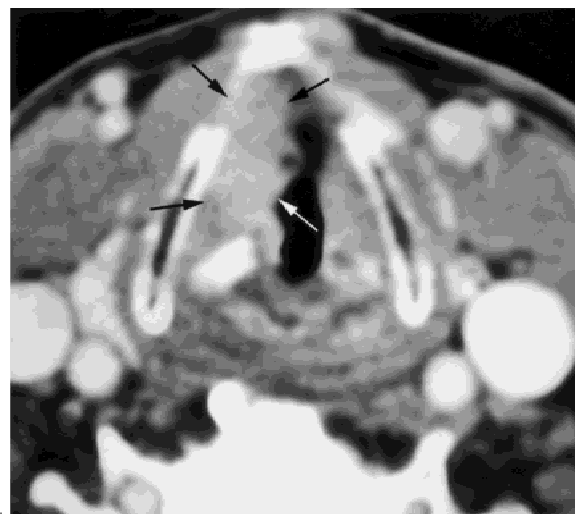

FIGURE 9. Glottic Cancer.
A: Contrast-enhanced axial CT image shows an irregular enhancing mass involving the right true vocal cord. (arrows)
B: Schematic illustration demonstrates the ipsilateral nodal group most likely at risk for developing nodal metastases from glottic carcinoma is group II (55%). Please refer to Table 8 for a listing of specific percentages for each individual nodal group.

Table 8. Frequency of cervical nodal metastases in glottic carcinoma

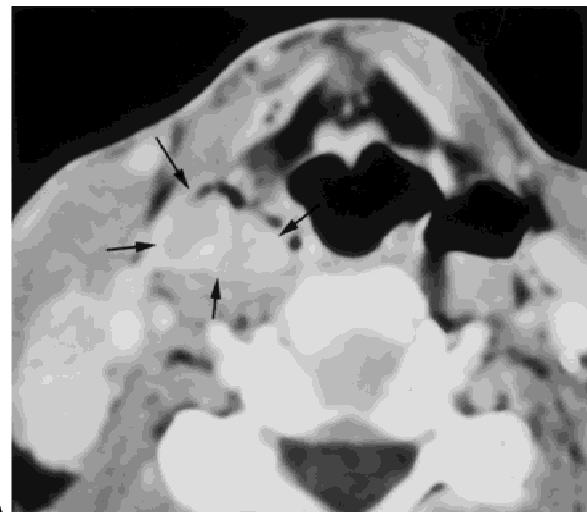Nodal group	Ipsilateral (%)
I	0
II	55
III	27
IV	0
V	0
Paratracheal	18

cial mucosal lymphatics form a continuous layer along the posterior aspect of the larynx. However, the lymphatics draining the TVC are sparse and form a natural barrier between the supraglottic and infraglottic larynx. The predominant lymphatic drainage of the advanced TVC occurs by acquiring the lymphatic drainage that occurs by extension into the supraglottic or subglottic larynx^{1,4} (Fig. 9) (Table 8).

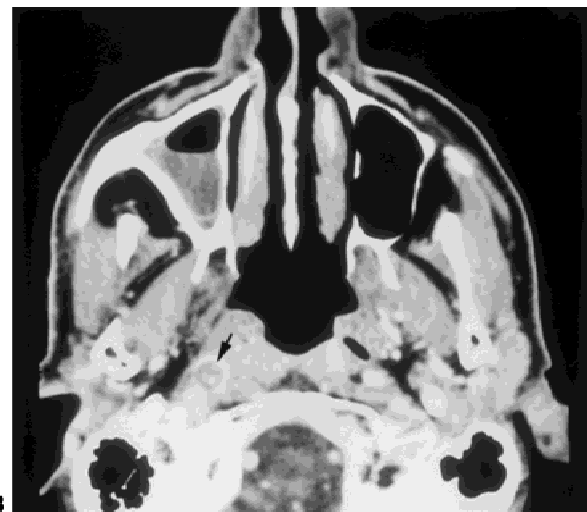
Pyiform Sinus. The lymphatic drainage is divided into anterior and posterior groups.^{1,3} The anterior collecting system exits along with the lymphatics of the supraglottic larynx through the thyrohyoid membrane. These vessels course through pre-laryngeal lymph nodes and primarily drain into the Groups II, III. The posterior group drains the inferior hypopharynx. These vessels penetrate the superior constrictor muscle and drains into the paratracheal lymph nodes, lateral retropharyngeal lymph nodes and the internal jugular chain.⁸ Cross-lymphatic drainage occurs from the superficial lymphatics along the midline of the posterior pharyngeal wall. Advanced disease may involve Groups IV and V (Fig. 10) (Table 9).

CONCLUSION

We have reviewed the expected lymphatic drainage of various subsites of the upper aerodigestive tract and correlated this with the current nodal classification system.^{1,2} The surgical results of Lindberg and Byers et al correlate with the anatomic dissections of Rouviere and suggest that there are predictable pathways of lymphatic drainage within the subsites of the upper aerodigestive tract.^{3,4} These results form the basis of modified and selective neck dissections and radiation treatment planning.⁴⁻⁷ This information may also be useful when attempting to define the lymphatic drainage to sentinel lymph nodes. It



A



B

FIGURE 10. Pyriform Sinus Cancer.

A: Contrast-enhanced axial CT image shows an irregular large mass involving the right pyriform sinus. (black arrows)

B: Contrast-enhanced axial CT image shows an ipsilateral metastatic retropharyngeal lymph node. (black arrow)

C & D: Schematic illustrations demonstrate the ipsilateral (C) and contralateral (D) nodal groups most likely at risk for developing nodal metastases from pyriform sinus carcinoma. On the ipsilateral side, groups II (72%) and III (55%) are most likely at risk for developing nodal metastases. There is less than a 15% likelihood of metastases for contralateral nodal groups. Please refer to Table 9 for a listing of specific percentages for each individual group. (The retropharyngeal lymph node involvement as illustrated in the figure 10B and paratracheal involvement is not depicted in this schematic illustration.)

should be emphasized that tumors attain the lymphatic drainage associated with their primary location. Tumors that cross the midline to the contralateral side or spread to adjacent subsites will acquire the lymphatic drainage associated within these areas.

Table 9. Frequency of cervical nodal metastases in pyriform sinus carcinoma

Nodal group	Ipsilateral (%)	Contralateral (%)
I	1	0
II	72	9
III	55	3
IV	21	2
V	15	2
Supraclavicular	3	1
Paratracheal	8.3	

REFERENCES

1. Rouvierre H Lymphatic systems of the head and neck. Tobias MJ, trans. Ann Arbor, Mich: Edwards Brothers: 1938
2. Som PM, Curtin HD, Mancuso AA. An imaging-based classification for the cervical nodes designed as an adjunct

to recent clinically-based nodal classifications. Arch Otolaryngol Head Neck Surg 1999;125:388-396

3. Lindberg R. Distribution of cervical lymph node metastases from squamous cell carcinoma of the upper respiratory and digestive tracts. Cancer 1972;29:1446-1449
4. Byers RM, Wolf PF, Ballantyne AJ. Rationale for elective modified neck dissection. Head & Neck Surgery 1988;10:160-167
5. Lindberg R, Jesse RH. Treatment of cervical lymph node metastases from primary lesions of the oropharynx, supraglottic larynx, and hypopharynx. Am J Roentgen Rad Ther Nucl Med 1968;102:132-137
6. Shah J. Patterns of cervical lymph node metastases from squamous cell carcinomas of the upper aerodigestive tract. Am J Surg 1990;160:405-409
7. Shah J, Andersen PE. Impact of patterns of nodal metastases on modifications of neck dissection. Ann Surg Oncol 1994;1:521-532.
8. Weber RS, Marvel J, Smith P, Hankins P, Wolf P, Goepfert H. Paratracheal lymph node dissection for carcinoma of the larynx, hypopharynx, and cervical esophagus Otolaryngol Head Neck Surg 1993;108:11-17