

Mandibular Growth in the Rhesus Monkey (*Macaca mulatta*)¹

JAMES A. McNAMARA, JR.² AND LEE W. GRABER³
Center for Human Growth and Development and Department of Anatomy,
The University of Michigan, Ann Arbor, Michigan 48104, and Department
of Orthodontics, Northwestern University, Chicago, Illinois 60611

KEY WORDS Growth · Mandible · *Macaca mulatta* · Cephalometrics · Implants · Bone markers.

ABSTRACT Mandibular growth of 42 rhesus monkeys (*Macaca mulatta*) was analyzed quantitatively and qualitatively. Four groups of animals were defined according to dentitional age (i.e., infant, juvenile, adolescent, young adult). At each age growth was observed for a 24 week period. Since some animals were observed at more than one stage of development, 57 periods of growth were studied. The growth incremental data were collected by superimposing serial cephalograms on mandibular implants.

Growth and remodeling of both the skeletal and dento-alveolar components of the rhesus mandible were greatest in the infant monkeys and were less in successive age groups. Posterior relocation of the ramus was noted in all age groups while bone deposition on the anterior and inferior borders of the mandibular body was greatest in the younger animals. The most pronounced dental changes also occurred in the younger animals while the dentitions of the adolescent and adult animals were generally more stable.

This study demonstrates that the rate and direction of normal mandibular growth varies with the age of the animal. Furthermore, mandibular growth is quantified at four defined maturational levels to provide a set of values illustrating normal mandibular growth. These values can also be used as control data for experimental studies.

The continuing use of the rhesus monkey (*Macaca mulatta*) in experimental studies of craniofacial growth and adaptation necessitates further definition of the parameters of normal craniofacial development of this species. There have been several histologic studies of craniofacial growth in *Macaca mulatta*, e.g., Enlow ('63), Turpin ('68), Duterloo and Enlow ('70), Zimmerman ('72). However, few serial cephalometric-implant studies of normal growth in *Macaca mulatta* have been reported. Gans and Sarnat ('51) studied sutural growth in the upper face of four infant and four juvenile rhesus monkeys for seven to ten months. Erickson ('58) described facial changes in three juvenile animals for a six month period and Pihl ('59) followed two of these animals for an additional 18 months. Elgoyhen et al. ('72) described and quantified maxillary and mandibular changes in 13 juvenile mon-

keys for a five month period. However, comparative data from rhesus monkeys of different maturational levels, especially adolescent and adult animals, are not presently available.

The purpose of this report is to provide quantitative and qualitative documentation of the growth of the mandible of the rhesus monkey. Four maturational levels are considered and the various rates (increments) and directions of mandibular growth and remodeling compared. All of this information is necessary for an understanding of normal mandibular growth of the rhesus monkey and is of critical im-

¹ This study was supported in part by United States Public Health Service Grants HD-02272 and DE-03610.

² Center for Human Growth and Development and Department of Anatomy, The University of Michigan, Ann Arbor, Michigan 48104.

³ Department of Orthodontics, Northwestern University, Chicago, Illinois 60611, and Center for Human Growth and Development, The University of Michigan, Ann Arbor, Michigan 48104.

portance in the analysis and interpretation of experimental craniofacial growth data.

MATERIALS AND METHODS

Mandibular growth and remodeling were studied during four periods of postnatal morphogenesis. Four groupings of animals were established on the basis of dentitional development. An animal was considered to be in a particular group when the animal attained a specific stage of tooth eruption. The *infant* animals (Group I studied dur-

ing Period I) were characterized by the presence of a complete deciduous dentition at the onset of the study. The birth dates of these animals were known and ranged from five and one-half to seven months of age at the time of the first cephalogram (table 1). The *juvenile* animals (Group II studied during Period II) had a complete deciduous dentition and the first permanent molars were fully in occlusion. The exact dates of birth of most animals in Groups II, III and IV were not available. According to the tooth eruption

TABLE 1

Distribution of animals by periods studied

Animal		Age or approximate age when study started (months)	Study periods				Total periods
ID	Sex		I	II	III	IV	
1	F	5½ ¹	X				1
2	F	5½ ¹	X	X			2
3	M	6 ¹	X				1
4	M	6 ¹	X	X			2
5	F	6 ¹	X				1
6	M	6½ ¹	X				1
7	M	7 ¹	X	X			2
8	M	7 ¹	X	X			2
9	F	7 ¹	X				1
10	M	19 ¹		X			1
11	M	20 ¹		X			1
12	M	22½ ¹		X			1
13	M	18-24		X	X	X	3
14	M	18-24		X			1
15	M	18-24		X			1
16	M	18-24		X	X		2
17	M	18-24		X			1
18	M	18-24		X			1
19	M	18-24		X	X	X	3
20	M	18-24		X			1
21	M	18-24		X	X	X	3
22	M	18-24		X			1
23	M	18-24		X			1
24	M	18-24		X	X		2
25	M	18-24		X			1
26	M	18-24		X	X		2
27	M	18-24		X			1
28	M	18-24		X			1
29	F	18-24		X			1
30	F	18-24		X			1
31	M	18-24		X			1
32	M	18-24		X			1
33	M	45-54			X	X	2
34	M	45-54			X		1
35	M	45-54			X	X	2
36	M	72+				X	1
37	M	72+				X	1
38	F	72+				X	1
39	F	72+				X	1
40	F	72+				X	1
41	F	72+				X	1
42	F	72+				X	1
			9	27	9	12	57

¹ Birth date known.

scales of Hurme and Van Wagenen ('53, '61) and Schultz ('69), the animals in Group II were approximately 18–24 months of age. The animals in the *adolescent* group (Group III studied during Period III) possessed a full permanent dentition except for unerupted third molars and partially erupted cuspids. These animals were approximately four to four and one-half years old. The *young adult* monkeys (Group IV studied during Period IV) were at least six to seven years of age and had complete permanent dentitions including fully erupted third molars.

Forty-two *Macaca mulatta* from the primate colony of the Center for Human Growth and Development, The University of Michigan, were used in this study. Each period of postnatal mandibular growth observed was 24 weeks in duration. Since 12 of these animals had been followed

longitudinally for two to five years, cephalograms of these animals could be placed in more than one group (table 1). Nine of these animals were studied during two periods of mandibular growth and three during three periods. The average time interval between the two initial radiographs of the animals observed during both Period I and Period II was 14 months. The average interval between the two initial radiographs of the animals observed in both Periods II and III and of the animals in both Periods III and IV was 24 months and 22 months, respectively.

Twenty-nine tantalum implants (Björk, '55, '68; McNamara, '72) were placed in each animal. Four pins were placed extra-orally in the right side of the mandible, including one pin in the symphysis and one near the posterior border of the ramus (fig. 1). The additional implants were

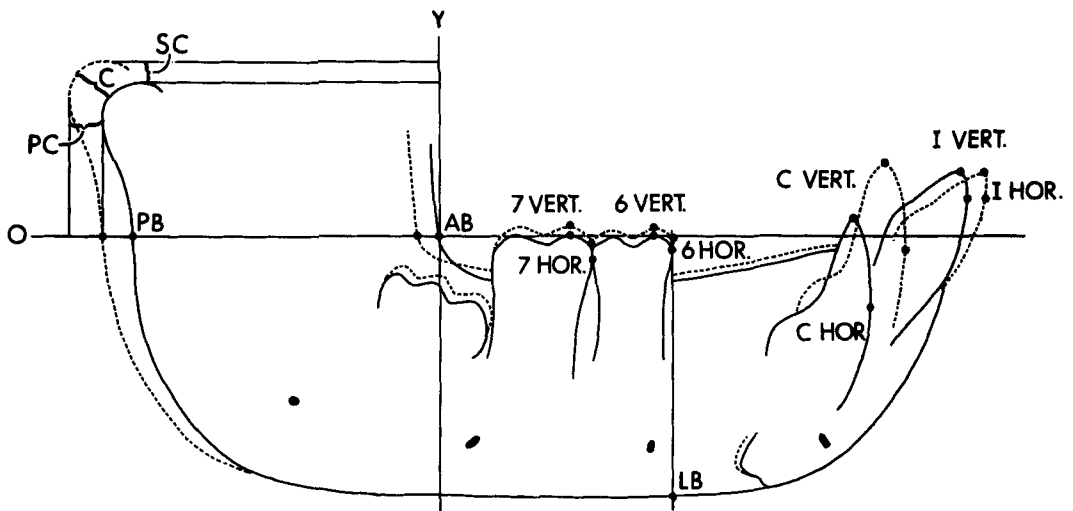


Fig. 1 Points and lines to be used in measuring mandibular dimensions. Note also the position of the tantalum implants within the mandible. SC: Uppermost portion of the condylar outline determined by the tangent perpendicular to "Y." PC: Most posterior point of the condylar outline determined by the tangent perpendicular to the occlusal reference line ("O"). C: Condylion, the most posterior and superior point on the condyle. PB: Intersection of the occlusal reference line with the posterior border of the ramus. AB: Intersection of the occlusal reference line with the anterior border of the ramus. LB: Intersection of a perpendicular to the occlusal reference line, drawn through the most mesial point of the first permanent molar, with the lower border of the mandible. I Hor: Most anterior point on incisor. I Vert: Most occlusal point on incisal edge. C Hor: Most mesial point on cuspid. C Vert: Most occlusal point on cuspid. 6 Hor: Most medial point on first permanent molar. 6 Vert: Most occlusal point on mesial cusp of first permanent molar. 7 Hor: Most mesial point on second permanent molar. 7 Vert: Most occlusal point on mesial cusp of second permanent molar.

Other dental measurements taken in certain age groups, but not shown in the above figure, included: DM Hor: Most mesial point on second deciduous molar. DM Vert: Most occlusal point on mesial cusp of second deciduous molar. 8 Hor: Most mesial point on third permanent molar. 8 Vert: Most occlusal point on mesial cusp of third permanent molar.

inserted into the maxillary region, cranium and cranial base, but were not used in this study.

Each animal was radiographed at the beginning and at the end of the 24 week period using a cephalostat especially designed for primates (Elgoyhen et al., '72). The fine grain of the Kodak type M industrial film used in this procedure allowed for precise definition of structures. Two lateral views were taken on each occasion, one with the teeth in occlusion, and one with the mouth held open to allow for increased visualization of the temporomandibular joint structures. Each radiograph was then enlarged three times the original size when copied on translite film. This enlargement procedure allowed for tracing and direct quantification of very small changes in mandibular dimensions which normally might be masked by tracing errors.

Growth changes were measured by placing a piece of 0.003" acetate tracing paper on the initial cephalogram and tracing the outlines of the mandibular implants (McNamara, '72, '73). An occlusal reference line "O" was drawn along the functional occlusal plane (fig. 1). A perpendicular line "Y" was also constructed at the point of intersection of the occlusal reference line with the outline of the anterior border of the ramus. This "template" provided a means of quantifying skeletal and dental changes relative to the position of the mandibular implants in successive cephalograms. Tracings of the mandibular out-

line were only used for descriptive purposes while distance and angular measurements were made directly on the cephalograms themselves.

FINDINGS

Regional growth and remodeling patterns

Through the use of the template system based on implant superimposition, growth changes were measured at specific locations on the mandible (including the dentoalveolar area) and then analyzed by region, and within each region by maturational level.

The condylar region. Growth at the head of the mandibular condyle was greatest during Period I and successively less during the other periods studied. Each month approximately 1 mm of bone was deposited along the posterior-superior border (condyion) of the infant condyle (i.e., 5.92 mm per 24 weeks; table 2). The mean values of the three condylar measurements (condyion, superior condyion, and posterior condyion) of the monkeys in Group II were respectively 76% (e.g., 4.47 mm versus 5.92 mm), 70%, and 84% that of the same values in the infant animals, while the increments for Group III were 51%, 47%, and 57% of Group I and for Group IV were 18%, 21%, and 18% of Group I, respectively (fig. 2, table 2). Because of the distribution of males and females in Groups I, II, and IV, sexual dimorphism in increments of condylar growth could be examined at these matu-

TABLE 2
Mandibular skeletal growth during 24 weeks

Measurements	Groups							
	I-Infant (N = 9)		II-Juvenile (N = 27)		III-Adolescent (N = 9)		IV-Young adult (N = 12)	
	Avg. mm	S.D. mm	Avg. mm	S.D. mm	Avg. mm	S.D. mm	Avg. mm	S.D. mm
Condylar region								
Condyion	5.92	0.99	4.47	0.96	3.00	1.32	1.07	1.10
Sup. condyion	4.50	0.76	3.13	0.73	2.11	1.17	0.95	1.26
Post. condyion	4.11	1.04	3.44	0.92	1.93	0.75	0.75	0.67
Mandibular ramus								
Anterior border	-0.93	0.39	-1.60	0.60	-1.21	0.54	-0.26	0.22
Posterior border	4.05	0.46	3.37	0.87	2.17	1.07	0.90	0.99
Mandibular corpus								
Lower border	1.05	0.44	0.42	0.32	0.09	0.11	0.04	0.14
Ramus-corpus relationship								
CRO angle	-6.2°	1.0°	-2.4°	1.8°	-1.7°	1.9°	-0.2°	0.9°

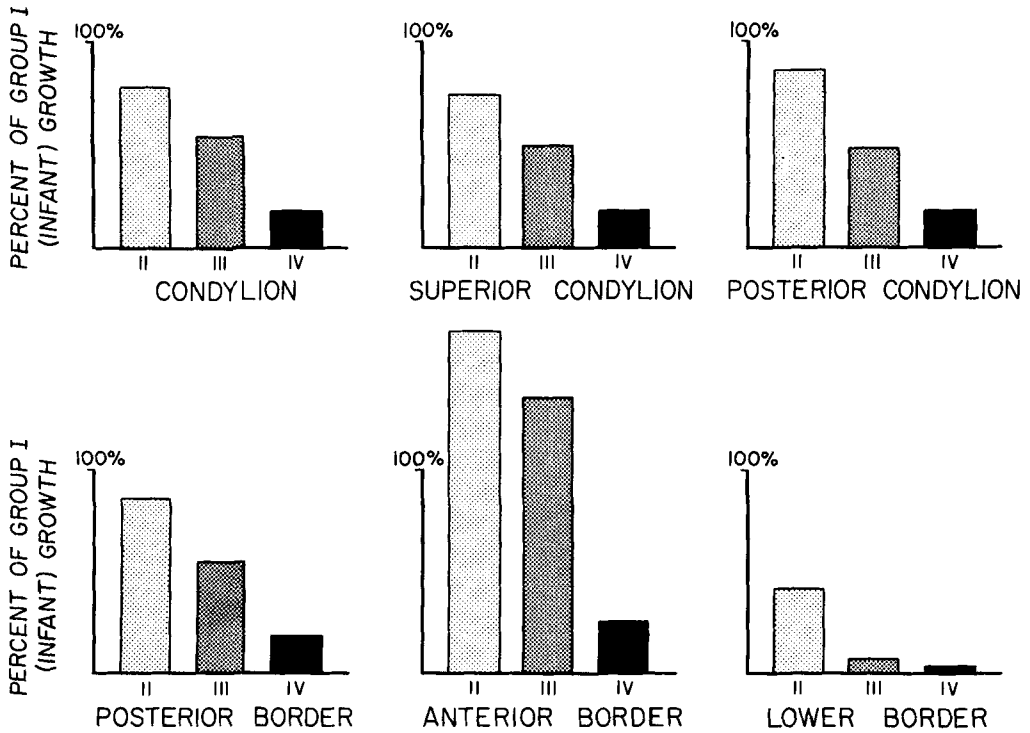


Fig. 2 Mandibular growth of Groups II, III, and IV represented as a percentage of the growth of Group I. The regional growth increment is less in successive age groups, except for the anterior border of the ramus. The anterior border is the only measurement in this figure which is associated with the eruption of the dentition.

rational levels. Each variable was studied marginally by performing a two sample t-test. There was no statistically significant difference in the magnitude of the three condylar measurements between male and female monkeys in Groups I and II (table 3). However, in Group IV the results were closer to being statistically significant at the 0.05 level and the male monkeys exhibited greater growth for each variable. It is possible that a larger sample size would show significant differences. From another point of view the mean values of the three condylar growth increments in the adult males were 27%, 37% and 25%, compared to those of the infant males while the same increments of condylar growth of the female adults were 6%, 3% and 9% that of the female infant animals (table 3). Since all of the monkeys in Group III were male, no analysis of sexual dimorphism was possible in this group.

The relative contributions of posterior

and superior growth to the shape and growth direction of the condyle differed among animals in the same age group. The infant monkeys in general demonstrated slight vertical growth of the head of the condyle, while the animals in Group II demonstrated slight anteroposterior vector of growth (table 2).

The mandibular ramus. All animals demonstrated deposition of bone along the posterior border and resorption at the anterior border of the ramus, but the differential amounts varied with the age of the animal. Group I had the greatest increase in ramus width; approximately four times as much bone deposition took place along the posterior border as was removed along the anterior border (fig. 3, table 2). An increase in resorption, related to further tooth eruption, and a decrease in deposition reduced the ratio from 4:1 in Group I to 2:1 in Group II (figs. 2, 4). The Group III monkeys maintained a resorptive pattern similar to Group II, but a decrease in pos-

TABLE 3
Mandibular skeletal growth by age and sex

Measurements (fig. 1)	Groups																		
	I-Infant Male (N = 5)			I-Infant Female (N = 4)			II-Juvenile Male (N = 22)			II-Juvenile Female (N = 5)			III-Adolescent — Males only IV-Young adult Male (N = 7)			III-Adolescent — Males only IV-Young adult Female (N = 5)			
	Avg. mm	S.D. mm	t	Avg. mm	S.D. mm	t	Avg. mm	S.D. mm	t	Avg. mm	S.D. mm	t	Avg. mm	S.D. mm	t	Avg. mm	S.D. mm	t	sig.
Condylar region	5.64	0.63	0.94	6.27	1.33	0.94	4.53	0.93	4.25	1.17	0.56	1.56	1.22	0.38	2.05	0.07			
Condyllion	4.13	0.56	1.84	4.96	0.78	1.84	3.25	0.64	2.60	0.84	1.95	1.52	1.40	0.15	2.15	0.06			
Sup. condyilion	4.07	0.95	0.12	4.17	1.27	0.12	3.49	0.94	3.26	0.98	0.49	1.00	0.77	0.40	1.62				
Mandibular ramus	-1.10	0.37	1.55	-0.73	0.33	1.55	-1.68	0.61	-1.25	0.46	1.54	-0.27	0.20	-0.23	0.31	0.08			
Anterior border	3.92	0.37	0.97	4.22	0.54	0.97	3.39	0.88	3.27	0.95	0.97	1.31	1.11	0.31	1.90				
Posterior border	0.98	0.40	0.42	1.11	0.54	0.42	0.45	0.34	0.31	0.18	0.41	0.10	0.17	0.03	1.58				
Mandibular corpus																			
Ramus-corpus relationship																			
CRO angle	-5.6°	0.8°	2.15	-6.9°	0.9°	2.15	-2.3°	1.8°	-3.0°	2.1°	2.15	-0.7°	0.8°	0.5°	2.95	0.4°	0.4°	2.95	0.01

terior deposition of bone dropped the ratio to 1.7:1 (fig. 5). Only slight anterior and posterior border remodeling was observed in Group IV (fig. 6). Sexual differences in the growth increments at the borders of the mandibular ramus were not statistically significant at the 0.05 level in any age group (table 3).

The mandibular corpus. The labial surface of the symphysis was appositional in infant, juvenile and some of the adolescent animals as was the base of its lingual surface (figs. 3, 4, 5). The area of the symphysis was relatively stable in the adult animals except in the alveolar area adjacent to the incisors. The lower border of the mandible was also appositional in the younger animals with the amount of apposition decreasing posteriorly. Marked remodeling was observed in the gonial region of all but the adult monkeys (figs. 1, 3, 4, 5).

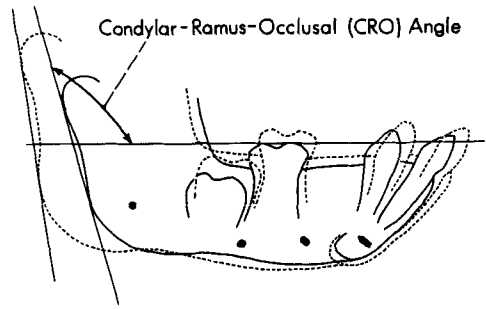


Fig. 3 Typical growth pattern of the infant mandible during 24 weeks. The solid lines represent the initial tracing and the dashed lines represent the final tracing. This figure also demonstrates the construction of the condylar-ramus-occlusal (CRO) angle at the intersection of the posterior ramus planes with the occlusal reference plane. Note the closure of the condylar-ramus-occlusal angle during growth and the forward and upward movement of the dentition.

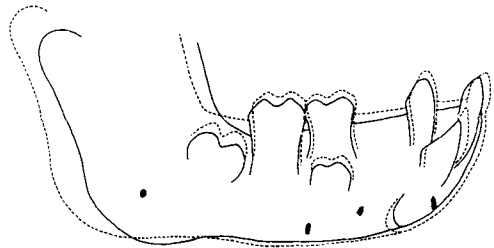


Fig. 4 Typical growth pattern of the juvenile mandible. Note the remodeling in the gonial region and the vertical drifting of the second deciduous molar and of the first permanent molar. The amount of mesial migration of the posterior dentition is variable in this age group. The central incisor, the second premolar and the second permanent molar are developing.

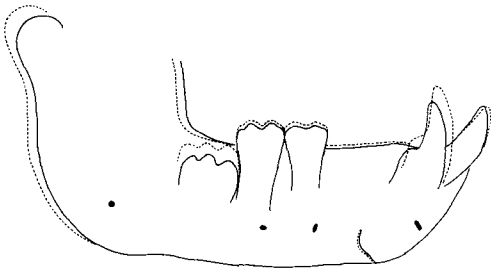


Fig. 5 Typical growth pattern of the adolescent mandible. Note the remodeling in the gonial region, the eruption of the cuspid and the slight vertical migration of the buccal segments. The third molar is developing.

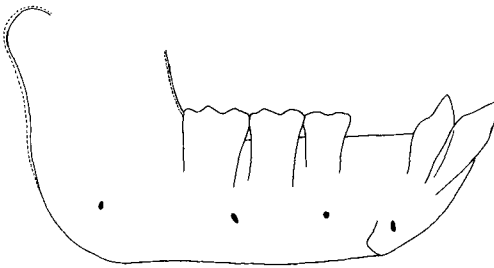


Fig. 6 Typical growth pattern of the mandible of a female adult monkey. Slight remodeling occurs along the anterior and posterior borders of the ramus. The dento-alveolar region is stable.

The ramus-corporis relationship. The relationship of both the condyle and ramus to the body of the mandible was determined by the angle of intersection of the occlusal reference line (fig. 3) with a line drawn from the posterior border of the condyle through the most posterior point on the ramus. This angle was termed the Condylar-Ramus-Occlusal (CRO) angle.

The mandibular plane could not be used for reference because of generalized apposition along the lower border of the mandibular corpus in the two younger age groups and the irregular remodeling pattern at the gonial angle (figs. 3, 4, 5). Also, the increasing curvature of the inferior border of the mandible in many of the older animals prevented consistent localization of a mandibular plane on successive tracings (fig. 1).

A progressive closure of the CRO angle occurred with maturation so that the ramus assumed a more vertical orientation with respect to the mandibular corpus. This angle decreased by an average of six degrees in the infant monkeys during the 24 week period (table 2). Lesser angular decreases were evident in the juvenile

and adolescent groups. Though not statistically significant, the closure of the CRO angle was greater in the infant and juvenile female animals (table 3). In the adult animals, neither sex showed significant change. There was, however, a statistical difference between the sexes. The biological interpretation of this last result is unclear.

The mandibular dentition. In describing the changes in tooth position, specific terms are used. *Eruption* refers to the movements of the tooth toward occlusion. *Migration* is used to describe movement of the tooth either vertically or antero-posteriorly after the tooth has occluded with its dental antagonist. As the tooth changes position, the exposed crown length of the tooth remains relatively stable in relation to its supporting alveolar bone (Enlow, '65; Enlow and McNamara, '73). *Movement* refers to any change in tooth position.

The most pronounced dental changes occurred in the two younger groups and were greatest in the infant animals. In the infant and juvenile monkeys, the mandibular incisors and canines migrated in a forward and upward orientation (figs. 3, 4; table 4). Vertical migration was observed in the posterior segments of both groups, but mesial migration in this region

TABLE 4
Mandibular dentoalveolar changes during 24 weeks

Measurements (fig. 1)	Groups			
	I-Infant (N=9)		II-Juvenile (N=27)	
	Avg. mm	S.D. mm	Avg. mm	S.D. mm
I Horiz.	1.21	0.38	1.00	0.45
I Vert.	0.90	0.30	0.57	0.49
C Horiz.	1.11	0.51	0.44	0.31
C Vert.	0.95	0.29	0.66	0.40
DM Horiz.	0.97	0.46	0.32	0.26
DM Vert.	1.13	0.33	0.88	0.27
6 Horiz.			0.34	0.28
6 Vert.			1.02	0.52
	III-Adolescent (N=9)		IV-Young adult (N=12)	
I Horiz.	0.96	0.42	0.07	0.18
I Vert.	0.01	0.10	0.05	0.24
C Horiz.	1.98	1.29	0.25	0.33
C Vert.	3.06	1.56	0.03	0.22
6 Horiz.	0.09	0.11	0.07	0.14
6 Vert.	0.42	0.25	0.13	0.16
7 Horiz.	0.13	0.14	0.09	0.14
7 Vert.	0.37	0.31	0.13	0.17
8 Horiz.			0.12	0.15
8 Vert.			0.19	0.22

was more evident in the infant animals. It is noted that mesial migration of the mandibular molars did occur in certain juvenile animals.

The dentitions of the adolescent and adult animals were generally more stable. The incisors and canines of the adult animals were stable (table 4). The lower canines of the adolescent animals erupted 3 to 4 mm vertically during the 24 week period of the study. The buccal segments

of the older animals were generally stable, although slight vertical migration was evident in the adolescent group (figs. 5, 6). No statistically significant sexual differences in dentitional movement were evident in any age group.

Long-term serial changes

An analysis of the composite tracings of those animals which were followed for longer periods of time (two to five years)

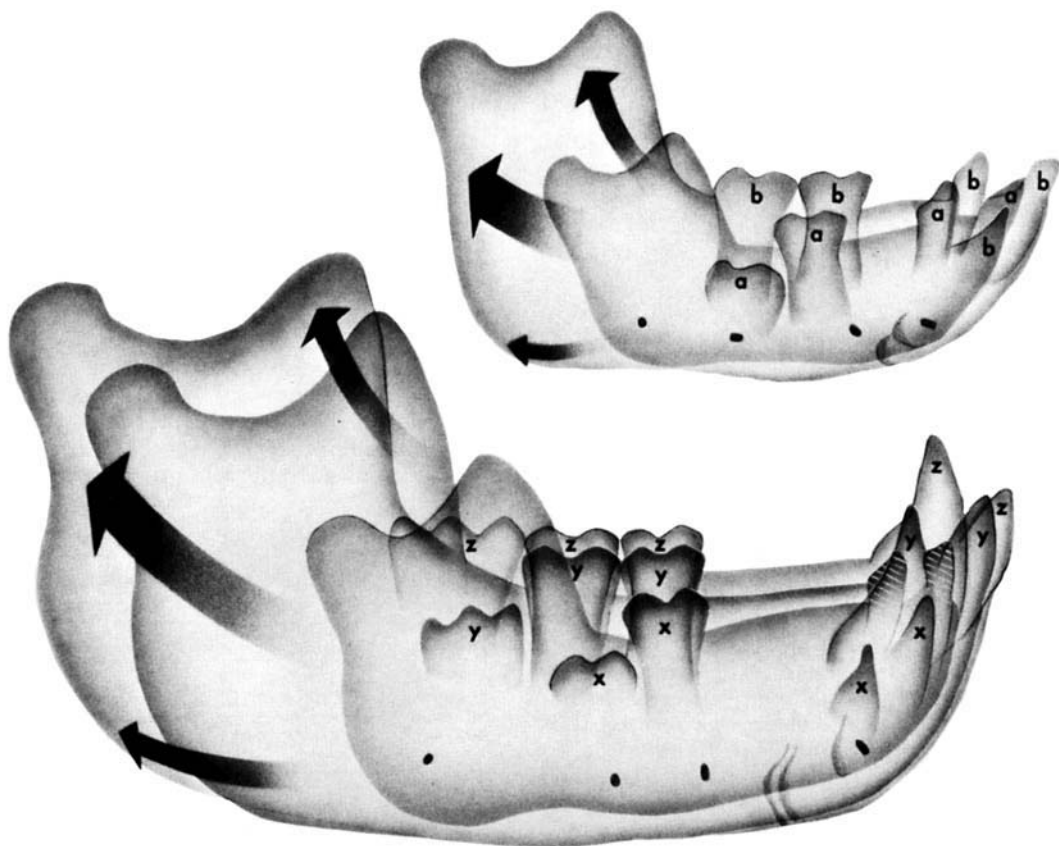


Fig. 7 Composite tracings of the growth of the mandible in a rhesus monkey from infancy to adulthood. Upper: Growth of the mandible of a young rhesus monkey of known age (6 months). Note the generalized bone deposition, the posterior relocation of the ramus, and the upward and forward movement of the dento-alveolar region which occurred during the 14 month interval between the first and second tracings. (a) position of teeth at beginning of period I; (b) position of teeth at beginning of period II. The position of the permanent central incisor is indicated only at the beginning of period II. Lower: Further growth of the rhesus mandible. The three superimposed tracings represent growth of the mandible from the juvenile to the adult stage. The time interval between the juvenile and adolescent tracings is 21 months and the interval between the adolescent and adult tracings is 22 months. The exact age of this animal is unknown, but estimated to be 18 to 24 months at the time of the first cephalogram. (x) position of teeth at beginning of period II; (y) position of teeth at beginning of period III; (z) position of teeth at beginning of period IV. The position of the third molar is represented only at the beginning of periods III and IV.

revealed the tremendous increase in size and the extensive growth and remodeling processes taking place in the rhesus mandible from infancy to adulthood (fig. 7). The most rapid period of growth occurred during the earliest growth periods studied.

Generalized bone deposition was observed in the growth of the mandible from the infant through the juvenile periods. Bone resorption was centered primarily along the anterior border of the ramus and of the coronoid process. The upward and forward movement of the dentition with an accompanying increase in height of alveolar bone was also observed.

There was a gradual decrease in the rate of growth of the mandible as the animal matured. In the development of the juvenile mandible to the adolescent stage, significant bone deposition occurred along the anterior and inferior portions of the mandibular body. Selective bone deposition and resorption in the posterior portion of the mandible accounted for the posterior relocation of the ramus and the further development of the dento-alveolar region. Dental migration continued to occur during this time with an upward and forward migration of the anterior teeth and with an upward migration of the posterior dentition.

The primary characteristics observed during the growth of the rhesus mandible from the adolescent to the young adult stage were the further posterior relocation of the ramus and the continued development of the dentition and its accompanying alveolar bone (fig. 7). Selective bone remodeling occurred along the anterior and inferior border of the mandible with increased bone deposition along the posterior border of the ramus and bone resorption occurring along the anterior border of the ramus. The overall rate of bone growth and remodeling decreased considerably during this last interval studied.

DISCUSSION

The findings of this study correlate well with previous cephalometric implant studies in the macaque (wherever corresponding data are available). The qualitative and quantitative findings in our juvenile sample correspond closely to those reported by Elgoyhen et al. ('72). Similar

cephalometric descriptions of mandibular growth in the juvenile mandible are reported by Erickson ('58), Pihl ('59) and Turpin ('68). The patterns of bone deposition and resorption during mandibular growth reported in the current study confirm those implied by the histological investigations of Enlow ('63) and Turpin ('68) in the monkey. For example, the posterior relocation of the ramus of the mandible, illustrating the phenomenon of "area relocation" described by Enlow ('63), is easily demonstrated in all age groups of this study.

In contrast to previous studies, the present investigation provides a long-term perspective regarding the growth of the rhesus mandible and allows for a comparison of mandibular growth increments and directions at specific maturational levels. Enlow ('63) and Turpin ('68) have histologically described bone deposition along the lower border of the rhesus mandible and extensive bone remodeling in the gonial region. The present study indicates that the rate and extent of growth and remodeling (as with other areas of the mandible) is related to the age level of the animal. The lower border shows continued bone deposition until adolescence, at which time there is a sharp decrease in the rate of growth along this border. The posterior border of the mandible on the other hand shows significant bone deposition throughout all growth periods studied. In general, the highest rates of growth and remodeling of both skeletal and dento-alveolar components of the rhesus mandible were noted in the youngest animals with successively lower rates in subsequent age groups.

It is important to note that growth and remodeling continued to occur in the oldest age groups studied. Those animals primarily were young adults and they demonstrated selective growth changes which can be compared to similar growth increments in man during late adolescent and adult periods (Garn and Wagner, '69; Israel, '73). Israel ('73) has reported a 4% increase in the overall length of the human mandible during two decades of adult life. In the adult rhesus mandible, an average of about 1 mm of bone was deposited at the condyle and along the posterior border of the ramus during a

six month period. The highest growth rates in the adult animals were seen in the male animals, while the rates of mandibular growth in the female animals studied were greatly reduced.

Thus, analysis of mandibular growth increments demonstrates that age, level of maturation, and sex are important when considering the parameters of normal growth of the rhesus mandible. The present study has demonstrated that the rate and direction of normal mandibular growth in the rhesus monkey varies with the age of the animal. Furthermore, mandibular growth has been quantified at four defined maturational levels to provide a set of values illustrating normal mandibular growth. These values can also be used as control data for experimental studies.

ACKNOWLEDGMENTS

The authors acknowledge the technical assistance of M. Christine McBride and Marian Johnson and the statistical advice of Kenneth E. Guire. Illustrations by William L. Brudon. Editorial assistance by Ruth Bigio and Barbara Nesbitt.

LITERATURE CITED

- Björk, A. 1955 Facial growth in man, studied with the aid of metallic implants. *Acta odont. Scand.*, 13: 9-34.
- 1968 The use of metallic implants in the study of facial growth in children: method and application. *Amer. J. Phys. Anthrop.*, 29: 243-254.
- Duterloo, H. S., and D. H. Enlow 1970 A comparative study of cranial growth in *Homo* and *Macaca*. *Am. J. Anat.*, 127: 357-368.
- Elgoyhen, J. C., M. L. Riolo, L. W. Graber, R. E. Moyers and J. A. McNamara, Jr. 1972 Craniofacial growth in juvenile *Macaca mulatta*: a cephalometric study. *Am. J. Phys. Anthrop.*, 36: 369-376.
- Enlow, D. H. 1963 *Principles of Bone Remodeling*. Charles C Thomas, Publishers, Springfield, Illinois.
- 1965 Mesial drift as a function of growth. *Symp. on Growth, Univ. West Indies, West Indian Med. J.*, 14: 124.
- Enlow, D. H., and J. A. McNamara, Jr. 1973 Varieties of *in vivo* tooth movements. *Angle Orthodont.*, 43: 216-217.
- Erickson, L. C. 1958 Facial growth in the Macaque monkey: a longitudinal cephalometric roentgenographic study using metallic implants. M. S. Thesis, University of Washington, Seattle, Washington.
- Gans, B. J., and B. G. Sarnat 1951 Sutural facial growth of the *Macaca rhesus* monkey: a gross and serial roentgenographic study by means of metallic implants. *Amer. J. Orthod.*, 37: 827-841.
- Garn, S. M., and B. Wagner 1969 The adolescent growth of the skeletal mass and its implications to mineral requirements. In: *Adolescent Nutrition and Growth*. F. P. Heald, ed. Appleton-Century-Crofts, New York, Publishers, Educational Division, Meredith Corporation. Chapter 11, pp. 139-161.
- Hurme, V., and G. Van Wagenen 1953 Basic data on the emergence of permanent teeth in the rhesus monkey (*Macaca mulatta*). *Proc. Amer. Philo. Soc.*, 97: 291-315.
- 1961 Basic data on the emergence of permanent teeth in the rhesus monkey (*Macaca mulatta*). *Proc. Amer. Philo. Soc.*, 105: 105-140.
- Israel, H. 1973 Age factor and the pattern of change in craniofacial structures. *Am. J. Phys. Anthrop.*, 39: 111-128.
- McNamara, J. A., Jr. 1972 Neuromuscular and skeletal adaptations to altered orofacial function. Monograph No. 1, Craniofacial Growth Series, Center for Human Growth and Development, The University of Michigan, Ann Arbor, Michigan.
- 1973 Neuromuscular and skeletal adaptations to altered function in the orofacial region. *Amer. J. Orthodont.*, 64: 578-606.
- Pihl, E. B. 1959 A serial study of the growth of various cranial and facial bones in the macaque monkey. M. S. Thesis, University of Washington, Seattle, Washington.
- Schultz, A. H. 1969 Growth and development. In: *The Anatomy of the Rhesus Monkey*. C. G. Hartman and W. L. Straus, Jr., eds. Hafner Publishing Company, New York, pp. 10-27.
- Turpin, D. L. 1968 Growth and remodeling of the mandible in the *Macaca mulatta* monkey. *Amer. J. Orthodont.*, 54: 251-271.
- Zimmermann, H. I. 1971 The normal growth and remodeling of the temporomandibular joint of *Macaca mulatta*. M. S. Thesis, University of Washington, Seattle, Washington.