

Rheumatoid Pleuritis

By GEORGE S. SCHOOLS AND WILLIAM M. MIKKELSEN

Three patients are described in whom pleural effusion appeared to be a manifestation of rheumatoid arthritis. In each, needle biopsy demonstrated granulomatous pleural lesions resembling the subcutaneous rheumatoid nodule while extensive studies failed to reveal any evidence of infection or neoplasm. The presence of extremely low fluid sugar concentration is regarded as strongly suggestive of rheumatoid pleuritis.

Es describe tres pacientes in qui effusion pleural pareva esser un manifestation de arthritis rheumatoide. In omnes, biopsias a agulia demonstrava granulomatose lesiones pleural resimilante le subcutanee nodulos rheumatoide, durante que extense studios revelava nulle indication de infection o de neoplasma. Le presentia de un extremamente basse concentration de sucro in le liquido es regardate como un forte supporto pro le suspicion de pleuritis rheumatoide.

THE OCCURRENCE of unexplained pleurisy, often with pleural effusion, in patients with rheumatoid arthritis has been noted by numerous investigators.^{1,13,15} Nonspecific pleural adhesions or fibrosis were described in 22 of 30 subjects with rheumatoid arthritis examined at necropsy.² In a second autopsy study, similar changes were present in 72 of 90 rheumatoid arthritics as compared to 35 of 90 control subjects.¹⁵ In a few cases the pleural lesions have been shown to have the pathologic characteristics of the rheumatoid nodule.^{2,6,10-14} In an earlier study, one of the authors (G. S. S.) demonstrated granulomatous lesions resembling the subcutaneous rheumatoid nodule in pleural tissue obtained by needle biopsy in three of 100 consecutive cases of idiopathic pleural effusion.¹⁴ Because of increasing interest in the pleural and pulmonary manifestations of rheumatoid arthritis, these three cases are reported in greater detail.

CASE REPORTS

Case #1, U.M.H. registration number 872215, F. P., a 35 year old white male, was first seen at the University of Michigan Hospital in May 1957. Fifteen months earlier he had developed a skin rash which was described as urticarial and occasionally "like blisters." The skin lesions had cleared but recurred periodically, involving the palms and soles primarily. Shortly thereafter, moderate discomfort was noted in the right shoulder and both wrists became swollen, red, warm, stiff and painful. At approximately the same time, complaints of burning on urination led to urologic studies which demonstrated a urethral stricture without evidence of infection. An episode of unexplained gross hematuria had occurred at age 8, but there was no other history of genitourinary abnormality.

From the Rackham Arthritis Research Unit and the Department of Internal Medicine, The University of Michigan, Ann Arbor, Mich.

The Rackham Arthritis Research Unit is supported by a grant from the Horace H. Rackham School of Graduate Studies.

Intermittent migratory joint pains continued, involving most of the joints of the upper extremities. Persistent pain and swelling had been present in small finger joints for several months before admission. Generalized morning stiffness of one and one-half hours duration was described and mild malaise, ease of fatigue and anorexia had been noted. In the week before admission, a mild nonproductive cough and pleuritic right chest pain had occurred.

The past and family medical histories were essentially negative except for a fracture of the left fibula at age 21, and a sister with a history of childhood pulmonary tuberculosis.

On physical examination the patient appeared mildly chronically ill. A loud pleural rub was heard over the right lower chest anterolaterally, and dullness to percussion and diminished breath sounds were present at the right base posteriorly. Moderate swelling and tenderness were present in the proximal and metacarpophalangeal finger joints and there was tenderness on compression of the metatarsophalangeal joints. There was a moderate decrease in range of motion in both shoulders and tenderness over the right temporomandibular joint. The palms and soles were red and moist and several 2 to 3 mm. vesicles were present on the left sole. Small, discrete, non-tender lymph nodes were palpable in the right posterior cervical, submandibular, axillary, epitrochlear and inguinal areas. The remaining physical findings were within normal limits.

Laboratory examination disclosed a hemoglobin of 14.1 Gm. per cent and a hematocrit of 47 vol. per cent. The white blood cell count was 12,150 per cu. mm. with 62 per cent polymorphonuclear leukocytes, 21 per cent lymphocytes, 7 per cent monocytes and 10 per cent eosinophils; a subsequent differential count revealed 9 per cent eosinophils. Stools were negative for occult blood, ova and parasites. The sedimentation rate was 32 mm. per hour (Wintrobe method) and a 3+ precipitation reaction for C-reactive protein was obtained. The total serum protein was 7.8 Gm. per cent with an electrophoretic pattern showing 39 per cent albumin, 6 per cent α_1 -, 15 per cent α_2 -, 16 per cent β - and 24 per cent γ -globulin. The sensitized sheep cell agglutination test (Ziff) was positive in a dilution greater than 1:56. Several L.E. cell preparations, the serum Kahn test, urine examination, fasting blood sugar, nonprotein nitrogen and bromsulphalein retention were normal or negative.

Chest x-ray examination disclosed a pleural effusion at the right base. Radiographic examination of the hands and feet was negative except for minimal soft tissue swelling of the proximal interphalangeal finger joints.

The old tuberculin skin test was positive. Cultures of three gastric aspirates and of the pleural fluid were negative for acid-fast bacilli. Cultures of pleural fluid for fungi and pyogenic organisms were negative. The pleural fluid appeared milky and slightly yellow and on stained film contained moderate numbers of polymorphonuclear leukocytes and serosal cells but no microorganisms. Cytologic examination for malignant cells was negative. The total protein content was 7.5 Gm. per cent and the sugar content 3 mg. per cent. Microscopic examination of the needle pleural biopsy tissue showed an area of necrosis surrounded by epithelioid cells arranged in a palisade fashion compatible with a rheumatoid nodule (fig. 1).

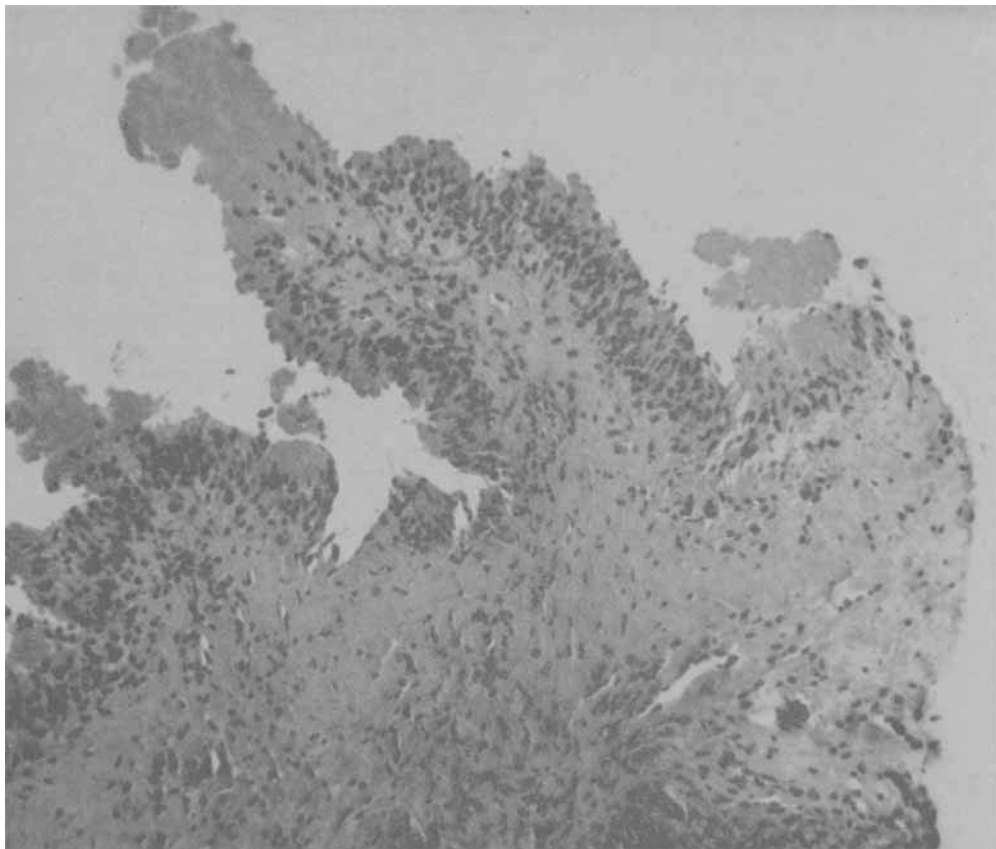


Fig. 1.—Case 1, University of Michigan, Department of Pathology, pathological number 9130-BI; needle biopsy specimen of right pleura. The areas of necrosis surrounded by epithelial cells arranged in a palisade fashion were regarded as compatible with a rheumatoid nodule.

The patient was discharged on completion of the above studies on a conservative program of salicylate and physical therapy. He was not seen again until March 1961 when he reported that joint pains had continued in the hands, wrists, feet and temporomandibular joints. Characteristically, only a few joints were involved at a time, with difficulty persisting for four to five days in a given joint. Minimal swelling had been observed in the finger joints and wrists. During the preceding year this pattern had changed in that joint pain occurred less frequently and was of only four to eight hours' duration. No further skin manifestations had occurred but urinary symptoms had recurred, usually following dilatation of the urethral stricture. The general physical examination at this time was normal except for slight residual swelling, capsular thickening and minimal effusion of the right third metacarpophalangeal joint. A complete blood count and urine examination were normal. The sedimentation rate was 10 mm. per hour (Westergren). The latex fixation test (Singer-Platz) for rheumatoid factor was positive in a dilution of 1:5120. Chest x-ray examination demonstrated chronic pleural scarring at the right

base without evidence of active inflammatory disease. Radiographic studies of the hands revealed definite loss of joint space of the right third metacarpophalangeal joint with erosive and cystic changes in the adjacent base.

Case #2, U.M.H. registration number 434994, C. B., a 66 year old white male, was admitted to the University of Michigan Hospital on May 1, 1957 with the complaint of pain and swelling behind the right knee of four months' duration. Involvement of the right knee had been followed shortly by swelling and stiffness of the left knee, wrists and finger joints. Generalized morning stiffness, malaise, ease of fatigue, anorexia and weight loss were prominent symptoms. No respiratory symptoms had been noted. The patient had been hospitalized elsewhere in February 1957 following an episode of gross hematuria and evidence was found of a left renal calculus and urinary tract infection. The past and family medical histories were otherwise not pertinent.

On physical examination the patient appeared as a well developed but pale, emaciated and chronically ill elderly white male. He was afebrile and the blood pressure was 130/70 in the right arm recumbent position. Flatness to percussion and decreased breath sounds were present at both lung bases. There was evidence of active synovitis involving the knees, elbows, wrists, metacarpophalangeal joints and the proximal interphalangeal joints of the right and left 2nd, 3rd, 4th and 5th fingers. A cystic swelling was present in the right popliteal space. Subcutaneous nodules were not present and the remainder of the physical examination was normal.

Laboratory examination revealed a hemoglobin of 10.5 Gm. per cent with a hematocrit of 34 vol. per cent. The white blood cell count was 9,850 per cu. mm. with 62 per cent polymorphonuclear cells, 36 per cent lymphocytes and 2 per cent monocytes. The sedimentation rate was 58 mm. per hour observed, 32 mm. per hour corrected (Wintrobe). Urine examination revealed a specific gravity of 1.020, 2+ reaction for albumin, negative reaction for sugar and numerous red blood cells but no white blood cells or bacteria on microscopic examination of the sediment. The serum Kahn reaction was negative. Two L.E. cell preparations were negative. Bromsulphalein retention was 1.8 per cent at 45 minutes. Serum creatinine was 1.02 mg. per cent. The sensitized sheep cell agglutination test (Ziff modification) was negative. Synovial fluid aspirated from the right knee showed changes compatible with rheumatoid arthritis, with a white cell count of 4,950 per cu. mm. with 90 per cent polymorphonuclear cells, formation of a poor mucin clot and reduction of relative viscosity to 3.7 units.

X-ray examination of the knees disclosed no abnormality while examination of the hands revealed soft tissue swelling and juxta-articular osteoporosis. Radiologic examination of the chest showed bilateral pleural effusion and flattening of the diaphragms without evidence of parenchymal involvement.

On admission the patient was considered to have definite rheumatoid arthritis but, because of the extensive weight loss and constitutional symptoms, an accompanying neoplasm was strongly suspected. Radiologic examination of the upper gastrointestinal tract, gallbladder and colon was normal. Intra-venous pyelograms confirmed the presence of a radiopaque calculus in the left renal pelvis but were otherwise normal. Repeated cytologic examinations of

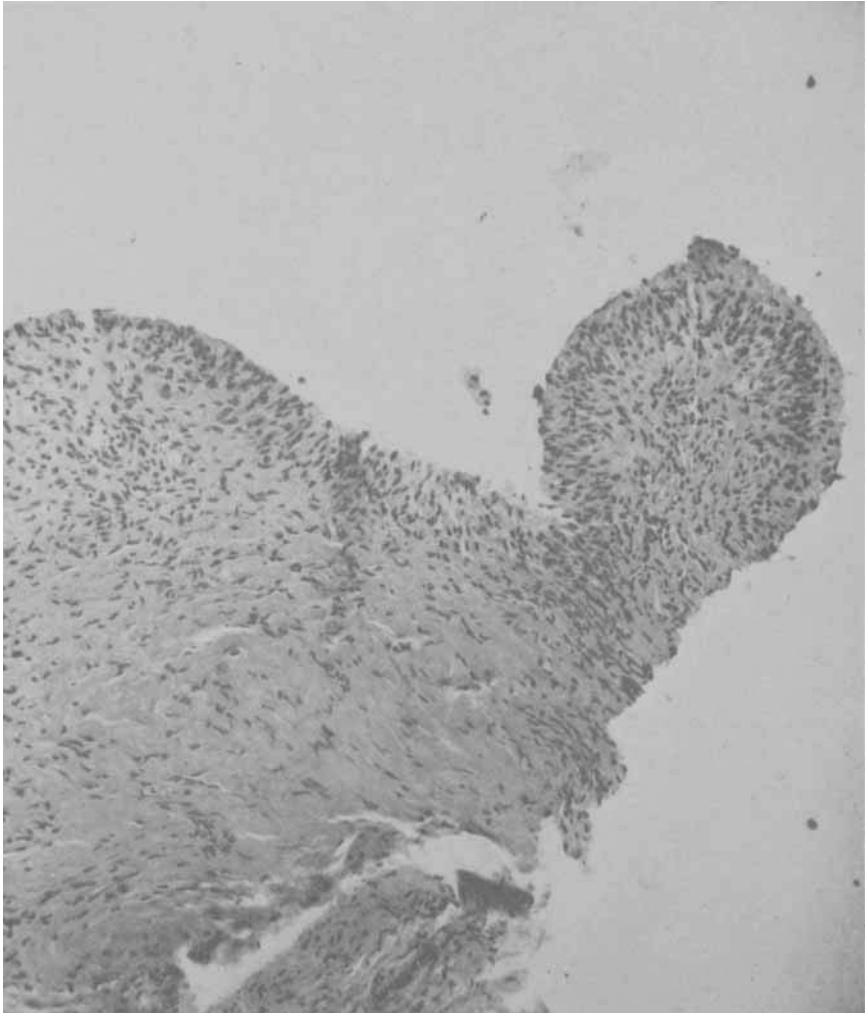


Fig. 2.—Case 2, University of Michigan, Department of Pathology, pathological number 8948-BI; needle biopsy of the pleura showing an area of early necrosis surrounded by spindled epithelioid cells and considered characteristic of a rheumatoid nodule.

sputum and pleural fluid were negative for malignant cells. The pleural fluid appeared milky yellow and on smear contained moderate numbers of polymorphonuclear and serosal cells but no microorganisms; the protein concentration was 4.5 Gm. per 100 ml. and glucose concentration 0. Repeated cultures of pleural fluid and sputum for acid-fast bacilli and pyogens were negative. Cultures of synovial fluid from the cyst in the right popliteal space were negative for pyogens, acid-fast bacilli and fungi. Pleural biopsy revealed an area of necrosis, surrounded by spindled epithelioid cells, which was considered compatible with a rheumatoid nodule (fig. 2).

The patient was discharged on a conservative regimen. The right popliteal cyst was excised elsewhere on July 25, 1957. The synovium showed nonspecific

inflammatory changes compatible with rheumatoid arthritis. A left pyelolithotomy was performed elsewhere on February 26, 1958. When seen on April 1, 1958, the patient denied joint pain but described morning stiffness of about one hour's duration. Moderate malaise and ease of fatigue had persisted but there had been an improvement in appetite and weight. The patient remained pale and chronically ill in appearance and there was continued evidence of polyarthritis involving the left knee, ankles, elbows, wrists, and the metacarpal and proximal interphalangeal finger joints. Diaphragmatic excursion was diminished and there were decreased breath sounds and dullness at the right base posteriorly. Subcutaneous nodules were not present. The sedimentation rate was elevated to 55 mm. per hour (Westergren) and the sensitized sheep cell agglutination test was again negative. Chest roentgenograms showed bilateral pleural changes with persistence of signs of effusion at the left base. A conservative program of therapy was continued.

Case #3, U.M.H. registration number 893007, H. R., a 41 year old white housewife, was admitted to the University of Michigan Hospital on June 15, 1958. In early 1956 she had experienced transient pain and limitation of motion in the shoulders. This had been followed shortly by migratory pains involving the knees, ankles, elbows, wrists and finger joints. Swelling had been observed in the ankles and in the metacarpophalangeal and proximal interphalangeal joints. Morning stiffness was described in the ankles and hands. In early 1958 a "trigger finger" phenomenon involved the flexor tendon apparatus of both fourth fingers and a subcutaneous nodule appeared near the left elbow. Biopsy had revealed this to have the classic histopathologic appearance of a rheumatoid nodule. The patient was referred for evaluation of multiple pulmonary nodules and slight bilateral pleural effusion noted on routine radiologic examination of the chest in October 1957. There were no respiratory complaints.

Physical examination was within normal limits except for slight pain and limitation of motion in both shoulders, questionable swelling of the proximal interphalangeal finger joints and atrophy of the interosseous muscles, several small nodules in the right olecranon bursa and a bilateral hallux valgus deformity. No abnormality was noted on examination of the chest.

Laboratory studies included a hemoglobin of 14.2 Gm. per cent and a hematocrit of 45 vol. per cent. The white blood cell count was 13,500 per cu. mm. with 67 per cent polymorphonuclear cells, 19 per cent lymphocytes, 6 per cent monocytes and 8 per cent eosinophils. Subsequent white blood cell counts ranged from 12,000 to 29,000 per cu. mm. with an eosinophilia ranging from 7 to 32 per cent. The sedimentation rate was 21 mm. per hour, corrected (Wintrobe method). The sensitized sheep cell agglutination test (Ziff) was negative. The total serum protein was 8.0 Gm. per 100 ml. with 42.7 per cent albumin, 4.4 per cent α_1 -globulin, 13.3 per cent α_2 -globulin, 15 per cent β -globulin and 24.6 per cent γ -globulin.

Radiologic examination of the chest confirmed the presence of bilateral pleural effusion and multiple nodular densities. Roentgenograms of the shoulders were normal while those of the hands showed moderate demineralization and slight decrease in the left fifth proximal interphalangeal joint space.

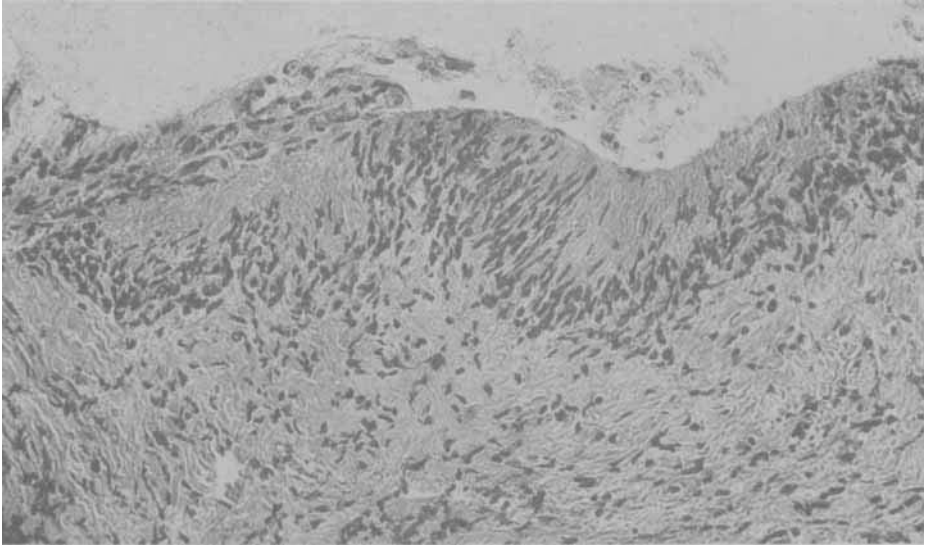


Fig. 3.—Case 3, University of Michigan, Department of Pathology, pathological number 9924-BJ; needle biopsy of the pleura showing several small areas of fibrinoid necrosis with a surrounding margin of spindle-shaped cells.

Several specimens of pleural fluid were negative on smear and culture for pyogens, acid-fast bacilli and fungi. On cytologic examination of the pleural fluid and sputum, no malignant cells were observed. The glucose concentration of the pleural fluid was 0. A needle biopsy of the pleura was performed on the right on July 17 and on the left on June 19, 1958. The first specimen showed nonspecific changes of chronic inflammation while the second was regarded as suggestive of a rheumatoid nodule (fig. 3).

DISCUSSION

The three patients described satisfy the American Rheumatism Association criteria for "definite" or "classical" rheumatoid arthritis. In each, the articular manifestations, although of brief duration, preceded pleural involvement. In two of the three patients the joint disease has thus far pursued a notably benign course without evidence of progressive destructive changes. Although needle biopsy of the parietal pleura demonstrated granulomatous lesions resembling the rheumatoid nodule in each case, subcutaneous nodules were present in only one. Tests for the presence of "rheumatoid factor," generally positive in the presence of rheumatoid nodules,¹⁶ were negative in two of the three patients.

There was nothing distinctive about the gross appearance of the pleural fluid, which in each instance was yellow or straw colored, somewhat cloudy and nonbloody. The fluid had a protein concentration of 7.5 and 4.5 Gm. per 100 ml. in the two patients in whom determinations were made. In all three cases careful cytologic examination failed to reveal the presence of malignant cells. Culture of pleural fluid for pyogens and tubercle bacilli was negative in the three patients and culture for fungi was negative in the two in which it was carried out. The most distinctive finding on examination of the pleural

fluid was the extremely low glucose concentration—0 in two instances and 3 mg. per 100 ml. in the third. This unique finding has also been noted by other investigators^{4,5} in 10 of 11 patients studied.

In previous reports of pleural effusion associated with rheumatoid arthritis, there has been little to distinguish the articular disease from uncomplicated rheumatoid arthritis. In several series, males have predominated^{5,9,10} although the underlying disease is usually stated to be two to three times more frequent in females. Although the majority of reports have described patients of middle or advanced age,^{5,12} it is probable that pleural complications, like rheumatoid arthritis itself, can occur at any age. Pleural effusion has generally occurred in patients with well established polyarthritis but occasionally it has been present very early in the course of joint disease and in rare instances it has actually antedated articular manifestations.¹¹ Radiologic examination has usually failed to reveal associated pulmonary parenchymal abnormalities, although in a few instances nodular lesions^{8,11} or diffuse fibrosis¹¹ have been described. Appropriate studies are necessary to rule out infectious or neoplastic disorders. The diagnosis may be confirmed by needle biopsy of the parietal pleura, although it should be borne in mind that a negative or nonspecific biopsy does not rule out rheumatoid pleuritis and should be repeated. The pleural effusion is usually minimal or moderate in degree and well tolerated by the patient even when persistent over a period of months or years. In some cases periodic thoracentesis has been considered necessary. Resolution of effusion has been observed coincident with oral steroid¹¹ and antimalarial¹² therapy, but has also been observed to occur spontaneously.⁹

SUMMARY

Three patients are described in whom pleural effusion appeared to be a manifestation of rheumatoid arthritis. In each, needle biopsy demonstrated granulomatous pleural lesions resembling the subcutaneous rheumatoid nodule while extensive studies failed to reveal any evidence of infection or neoplasm. The course of the rheumatoid arthritis has been remarkably benign in two of these patients.

Review of the previously reported cases suggests that this manifestation of rheumatoid arthritis may be particularly prone to occur in males of middle age, that it may occur very early in the course of the disease and that it is generally well tolerated by the patient. Appropriate skin tests and bacteriologic and cytologic studies of the pleural fluid and sputum are necessary to exclude infection and neoplasm. Needle biopsy of the parietal pleura should be regarded as a valuable diagnostic aid although a negative or nonspecific biopsy does not rule out the possibility of rheumatoid pleuritis or of other specific pleural lesions. It is suggested that the presence of extremely low pleural fluid sugar content may be characteristic of rheumatoid pleuritis.

ACKNOWLEDGMENT

We are indebted to Dr. William A. Gracie, Jr., for permission to include Case #3.

REFERENCES

1. Aronoff, A., Bywaters, E. G. L., and Fearnley, G. R.: Lung lesions in rheumatoid arthritis. *Brit. M. J.* 2: 228, 1955.
2. Baggenstoss, A. H., and Rosenberg, E. F.: Visceral lesions associated with

- chronic infectious (rheumatoid) arthritis. *Arch. Path.* 35:503, 1943.
3. Bevans, M., Nadell, J., Demartini, F. E., and Ragan, C.: The systemic lesions of malignant rheumatoid arthritis. *Am. J. Med.* 16:197, 1954.
 4. Carr, D. T., and Powers, M. H.: Pleural fluid glucose with special reference to its concentration in rheumatoid pleurisy with effusion. *Dis. Chest* 37: 321, 1960.
 5. Carr, D. T., and Mayne, J. G.: Pleurisy with effusion in rheumatoid arthritis. *American Rheumatism Assn. Annual Meeting, 1961. Arth. & Rheumat. (abst.)* 4:410, 1961.
 6. Christie, G. S.: Pulmonary lesions in rheumatoid pleuritis. *Australasian Ann. Med.* 3:49, 1954.
 7. Douglas, B. E., Carr, D. T., and Bernatz, P. E.: Diagnostic thoracotomy in the study of idiopathic pleural effusions. *Amer. Rev. Tuberc.* 74:954, 1956.
 8. Edge, J. R., and Rickards, A. G.: Rheumatoid arthritis with lung lesions. *Thorax* 12:352, 1957.
 9. Emerson, P. A.: Pleural effusion complicating rheumatoid arthritis. *Brit. M. J.* 1:421, 1956.
 10. Heller, P., Kellow, W. F., and Chomet, B.: Needle biopsy of the parietal pleura. *New England J. Med* 255: 684, 1956.
 11. Horler, A. R., and Thompson, M.: The pleural and pulmonary complications of rheumatoid arthritis. *Ann. Int. Med.* 51:1179, 1959.
 12. Lee, P. R., Sox, H. C., North, F. S., and Wood, G. A.: Pleurisy with effusion in rheumatoid arthritis. *Arch. Int. Med.* 104:634, 1956.
 13. Raven, R. W., Weber, F. P., and Price, L. W.: The necrobiotic nodules of rheumatoid arthritis. *Ann. Rheumat. Dis.* 7:63, 1948.
 14. Schools, G. S., and Davey, W. N.: Needle biopsy of the parietal pleura. *Univ. Michigan M. Bull.* 26:1, 1960.
 15. Sinclair, R. J. G., and Cruickshank, B.: A clinical and pathological study of 16 cases of rheumatoid arthritis with extensive visceral involvement. *Quart. J. Med.* 49:313, 1956.
 16. Ziff, M.: The agglutination reaction as a diagnostic aid in rheumatoid arthritis. *Bull. Rheumat. Dis. (Diagnostic Suppl.)* 75:13, 1956.

George S. Schools, M.D., The Rackham Arthritis Research Unit, and Department of Internal Medicine, University of Michigan, Ann Arbor, Mich. Present Address: Department of Internal Medicine, University of Texas Southwestern Medical School, Dallas, Texas.

William M. Mikkelsen, M.D., The Rackham Arthritis Research Unit, and Department of Internal Medicine, University of Michigan, Ann Arbor, Mich.