
CASE REPORT**UNUSUAL ELECTROMYOGRAPHIC FINDINGS IN A PATIENT WITH POLYMYALGIA RHEUMATICA**

MILTON D. GROSS, MARK H. BORKIN, and STEPHEN RUPP

A case of polymyalgia rheumatica (PMR) with biopsy-proven giant cell arteritis (GCA) is described in which there were marked abnormalities noted on electromyography (EMG). Spike potentials, positive waves, and fibrillation potentials were seen in the proximal musculature of the upper and lower extremities as well as in the erector spinae muscles. Investigation failed to reveal abnormalities in either creatinine phosphokinase (CPK), aldolase, or muscle obtained at biopsy. The presence of these EMG findings in the PMR-GCA syndrome is unusual. Response to therapy with systemic corticosteroids and normalization of the EMG are documented.

Polymyalgia rheumatica is a clinical syndrome of pain in the muscles of the neck, shoulders, buttocks, and thighs noted over the course of weeks to months and associated with normal physical findings (1,2). Anemia, elevation of the sedimentation rate and alpha₂ globulin with normal muscle enzymes and muscle

biopsy are characteristic of the syndrome (1,2). It has also been noted that rheumatoid factors, antinuclear antibodies, and other serologic phenomena are absent. Approximately 50% of cases are associated with giant-cell arteritis (1,2). Typically this affects the temporal arteries resulting in unilateral blindness and accounts for the major morbidity in the syndrome. In the absence of the arteritis, phenylbutazone, indomethacin, or corticosteroids have been utilized as treatment, but corticosteroids are the agents of choice for the complication of temporal arteritis (1).

Electromyography has not been useful in the diagnosis of the syndrome and has been described as normal or nonspecific (1-3). This report describes a case of polymyalgia rheumatica and temporal arteritis with electromyographic findings of partial denervation in the erector spinae muscles and the proximal musculature of the upper and lower extremities. After the patient was treated with prednisone, the electromyogram findings and sedimentation rate returned to normal.

CASE REPORT

A 62-year-old white female was admitted to the University of Michigan Medical Center with a 3-month history of progressive weakness in her shoulders and hips. This weakness had continued until at admission she was unable to raise her arms above her head. She also complained of low grade fevers and nocturnal, deep, aching pains in her arms and legs. Mild band-like headaches without visual disturbances were noted. The patient denied any history of arthritis. She had no trauma or chemical toxin exposure.

From the Department of Internal Medicine, University of Michigan Medical Center, Ann Arbor, Michigan.

Milton D. Gross, MD: House Officer III; Mark H. Borkin, MD: House Officer I; Stephen Rupp, BS.

Address reprint requests to Milton Gross, MD, Department of Internal Medicine, University of Michigan Medical Center, Ann Arbor, Michigan 48109.

Submitted for publication May 24, 1977; accepted in revised form November 8, 1978.

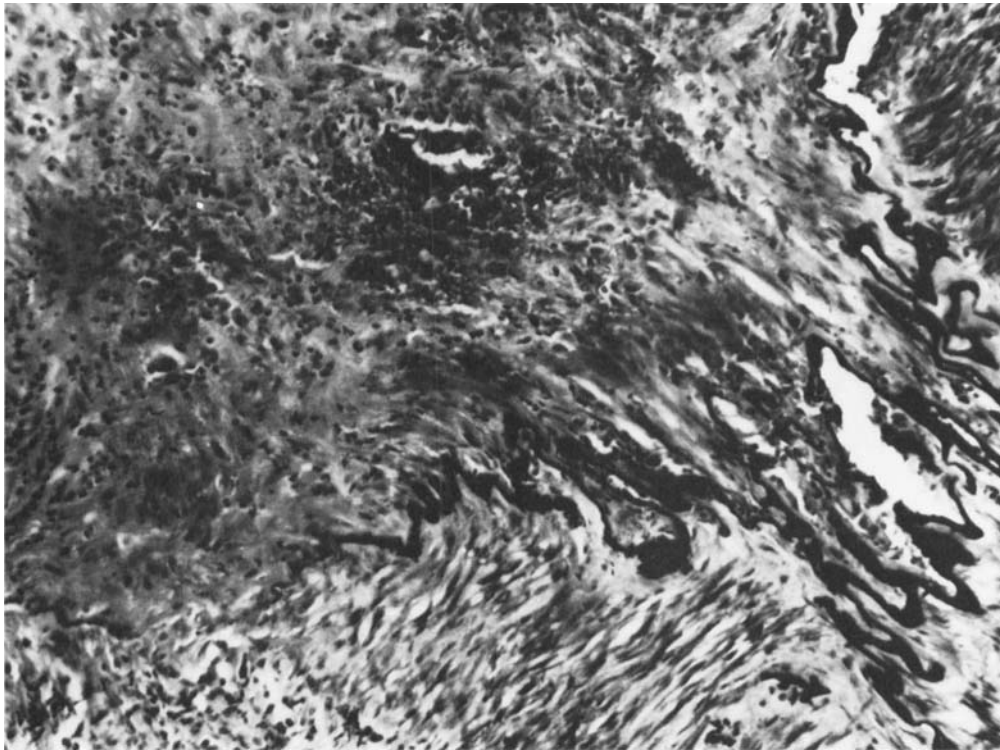


Figure 1. Temporal artery biopsy specimen demonstrating intimal destruction with granuloma formation (Movat trichrome; $\times 160$).

On physical examination her vital signs were normal. Temporal arterial pulsations were diminished, but there was no tenderness. Fundoscopic examination revealed no abnormalities. Chest, abdominal, and genitourinary examinations showed normal results. Examination of extremities revealed full pulses without arterial bruits. There was full range of motion without joint findings. No adenopathy was noted. Neurologic examination revealed intact cranial nerves. Motor strength was greatly decreased in the proximal muscles of the shoulder and hip girdles. A positive Gowers' sign was noted. Distal strength was intact. Sensation was normal. Reflexes were equal and bilateral throughout. Plantar responses were flexor. Laboratory examination revealed a hematocrit of 33%, a hemoglobin of 10.3 gm, a WBC of 7,000 with a normal differential count, and a Westergren sedimentation rate of 125 mm/hour. Serum creatine phosphokinase was 14 units (0-111 IU/ml) and aldolase 3 units (3-10 units/ml). Liver, renal, and thyroid functions were normal. Latex fixation, antinuclear antibody, LE preps, VDRL, serum immunodiffusion, and urine for kappa and lambda chains were negative. Serum protein electrophoresis revealed an elevated α_2 globulin fraction. Chest x-rays, urinalysis, and electrocardiograms were normal. An electromyogram revealed positive waves, spike potentials, and fibrillation potentials in the proximal muscles of the upper and lower extremities as well as in the erector spinae muscles. No myopathic units were noted and nerve conduction velocities were normal.

Temporal artery biopsy revealed granulomatous inflammation of the arterial wall with intimal destruction and multinucleated giant cells (Figures 1 and 2). A deltoid muscle biopsy was normal (Figure 3).

The patient began taking oral prednisone, 60 mg a day, and experienced a remarkable improvement in her symptoms. Her strength increased and her pain abated. At the end of 6 days of corticosteroid therapy, her sedimentation rate had decreased to 84 mm/hour and her hematocrit had increased to 38%. A repeat electromyogram 6 weeks after the initiation of therapy was interpreted as normal. At that time the sedimentation rate was 4 mm/hour and her strength had returned to normal.

DISCUSSION

Numerous studies have demonstrated patients with polymyalgia rheumatica to have normal electromyograms; however this is not a universal finding (4,5). In studies that reported electromyographic abnormalities, the findings are usually a myopathy (5). Denervation without evidence of myopathy has been seen in one previous study in a patient with polymyalgia rheumatica and biopsy proven giant-cell arteritis (6). Improvement was noted in all clinical parameters after

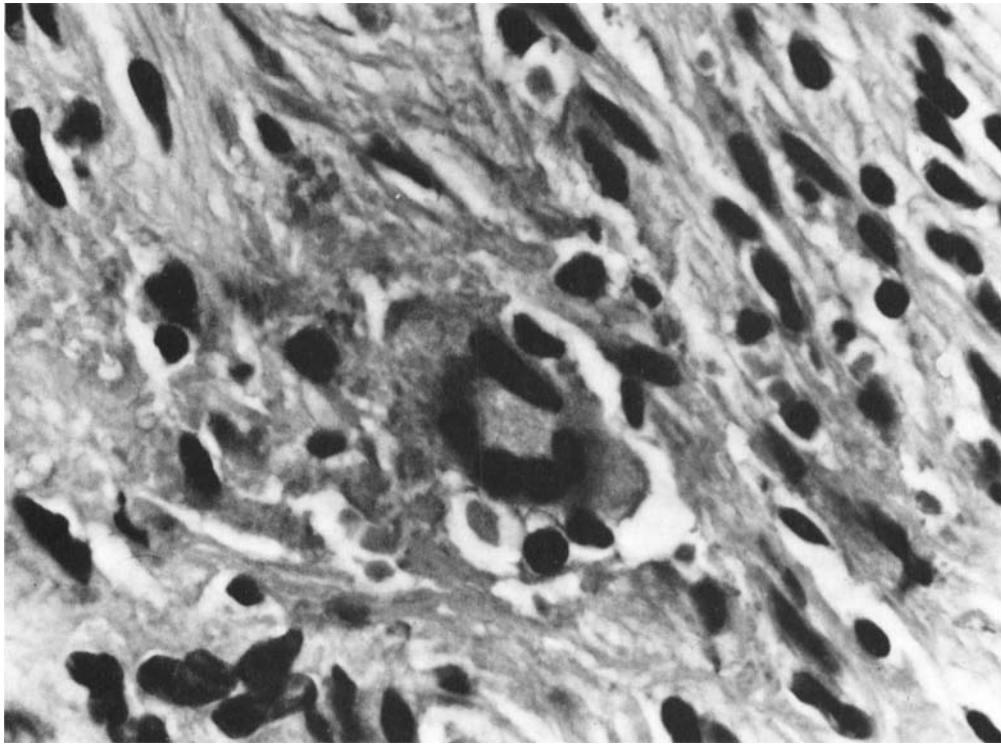


Figure 2. Multinucleate giant cell from temporal artery granuloma (hematoxylin-eosin; $\times 700$).

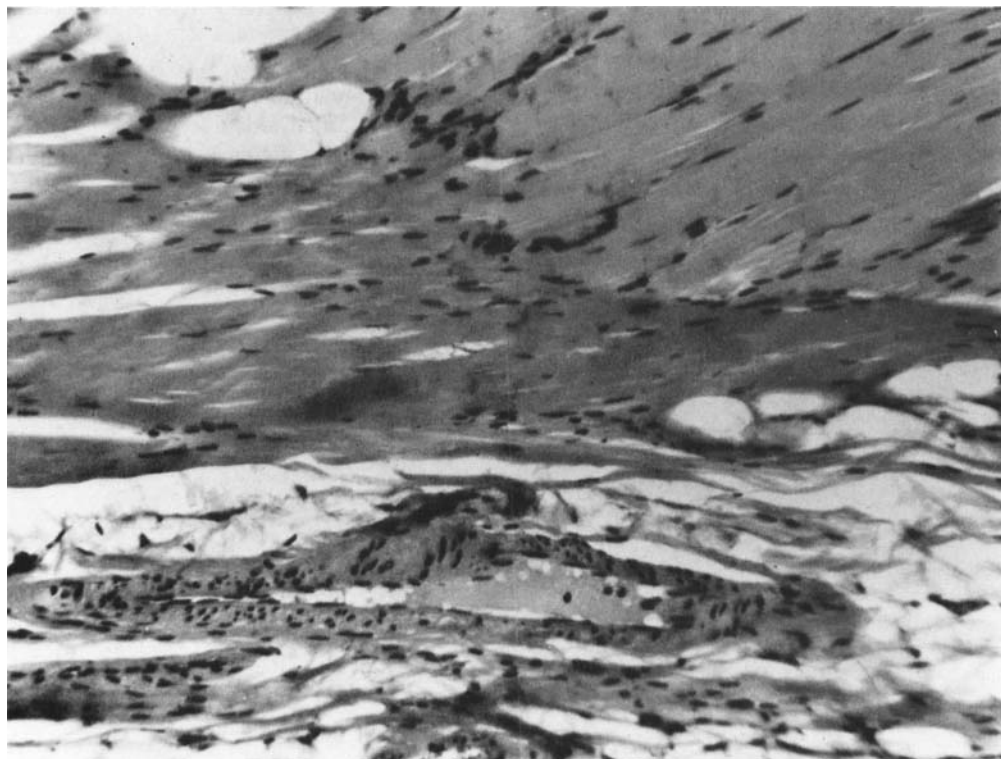

Figure 3. Deltoid muscle biopsy demonstrating normal muscle fibers and arterioles (hematoxylin-eosin; $\times 160$).

institution of corticosteroids, but no mention was made of repeat electromyography.

The consideration of polymyositis was raised in this patient. Of criteria previously set forth for the establishment of the diagnosis of polymyositis, this patient demonstrated proximal muscle weakness and EMG findings consistent with proximal denervation without changes in nerve conduction velocities. These findings have been reported in cases of polymyositis and dermatomyositis (7). The absence of elevated muscle enzymes and a normal muscle biopsy from an affected site do not totally exclude the diagnosis of polymyositis (8-10). They do, however, make the diagnosis less tenable. There are numerous other conditions associated with polymyositis and, in one instance, temporal arteritis was associated with a polymyositis-like syndrome (10). This prompted a thorough search for other causes of polymyositis in this case, with negative results.

This case illustrates the variability of the polymyalgia rheumatica-giant cell arteritis syndrome. The presence of elevated α_2 globulins, an elevated sedimentation rate, and temporal arteritis with a normal muscle biopsy and muscle enzymes is most consistent with a diagnosis of polymyalgia rheumatica. It is unique that weakness was the prominent clinical manifestation of the disease in this patient and that partial proximal denervation was found on the EMG. It appears as though a myositis can be included in the symptom complex of this patient. Treatment with systemic corticosteroids had a predictable effect upon the patient's symp-

tomology and various laboratory studies. Coincident with the clinical improvement was normalization of the electromyogram. This has not been reported in polymyalgia rheumatica.

ACKNOWLEDGMENT

The authors would like to acknowledge Sara Walker, M.D. for her assistance in the preparation of this manuscript.

REFERENCES

1. Fernandex-Herlihy L: Polymyalgia rheumatica. *Semin Arthritis Rheum* 1:236-245, 1971
2. Hunder GG, Disney TF, Ward LE: Polymyalgia rheumatica. *Mayo Clin Proc* 55:849-875, 1969
3. Boyle AC, Beatty DC: Polymyalgia rheumatica. *Proc Royal Soc Med* 54:681-684, 1961
4. Davison S, Spiera H, Plotz CM: Polymyalgia rheumatica. *Arthritis Rheum* 9:19-23, 1966
5. Buchthal F: Electrophysiological abnormalities in metabolic myopathies and neuropathies. *Acta Neurol Scand (suppl)* 43:129-176, 1969
6. Warrell DA, Godfrey S, Olsen E: Giant cell arteritis with peripheral neuropathy. *Lancet* 1:1010-1013, 1968
7. Bender LF: Diagnostic electromyography. *JAMA* 199:721-731, 1967
8. Bohan A, Peter JB: Polymyositis and dermatomyositis. *N Engl J Med* 292:344-347, 1975
9. Devere R, Bradley WG: Polymyositis. Its presentation, morbidity and mortality. *Brain* 98:637-666, 1975
10. Roland LP, Clark C, Olarte M: Therapy for dermatomyositis and polymyositis. *Adv Neurol* 17:63-97, 1977