

---

## BRIEF REPORT

# ACUTE CALCIFIC TENDINITIS OF THE HAND: AN INFREQUENTLY RECOGNIZED AND FREQUENTLY MISDIAGNOSED FORM OF PERIARTHRITIS

CHARLES L. SELBY

Paraarticular calcifications are frequently seen around the shoulders and greater trochanters of the hips. However, calcific deposits in other sites are infrequently recognized or described. Calcific periartthritis of the hand, an unusual site of involvement, is often overlooked and underdiagnosed. In 1938 Sandstrom (1) reported that of 329 sites of calcareous deposit, only 8 involved the hand (wrist plus fingers), an incidence of 2.4%. A case of acute calcific tendinitis of the hand is reported and the syndrome reviewed.

**Case report.** A 57-year-old woman, previously in good health, was admitted for acute pain and swelling around the right first interphalangeal (IP) joint. Four days prior to admission, she noted soreness of her thumb. She had been gardening the day before and in retrospect, thought perhaps she had been bitten by an insect. Her thumb progressively became more swollen and tender, and she became unable to flex the joint. She denied having fever, chills, vaginal discharge, dysuria, rash, myalgias, or other present or past joint complaints. She had been sexually inactive for years. There was no history of gout or trauma. She was receiving no medication.

Physical examination revealed a temperature of 99.5°F orally. There was massive swelling and tenderness around the right first IP joint with associated soft tissue swelling, and inability to flex. The examination otherwise showed no abnormalities.

Laboratory studies revealed the following values: hematocrit was 42.8%, white blood cell count (WBC) 11,200  $\mu$ l (57% neutrophils, 38% lymphocytes), alkaline phosphatase 112 units/liter (normal 30–96), calcium 10.0 mg/dl, phosphorus 3.4 mg/dl, uric acid 5.0 mg/dl, Westergen erythrocyte sedimentation rate 30 mm/hour. Prior to admission, arthrocentesis produced 2 drops of fluid. One drop was sent for culture. Analysis on the other revealed no crystals, a negative Gram stain, 23,000 WBC (insufficient quantity for differential), and red blood cell count of 59,000. Radiographs of the right thumb (Figure 1) revealed a discrete calcific density around the flexor side of IP joint associated with a sesamoid bone and degenerative changes.

She was admitted for a presumptive diagnosis of septic arthritis and began receiving antibiotics intravenously. Blood cultures and cultures from the thumb were negative at 48 hours. She remained afebrile, but the thumb did not improve. A repeat radiograph 2 days after admission revealed the calcific deposit had broken into multiple smaller, ill-defined masses (Figure 2). A diagnosis of acute calcific tendinitis of the hand was made. Her antibiotics were discontinued, and an injection of a triamcinolone-novocaine mixture was infiltrated around the most tender area. Twelve hours later, her swelling was significantly reduced, her pain entirely gone, and she could bend her thumb. She was discharged on a regimen of naproxen. Followup at 1

---

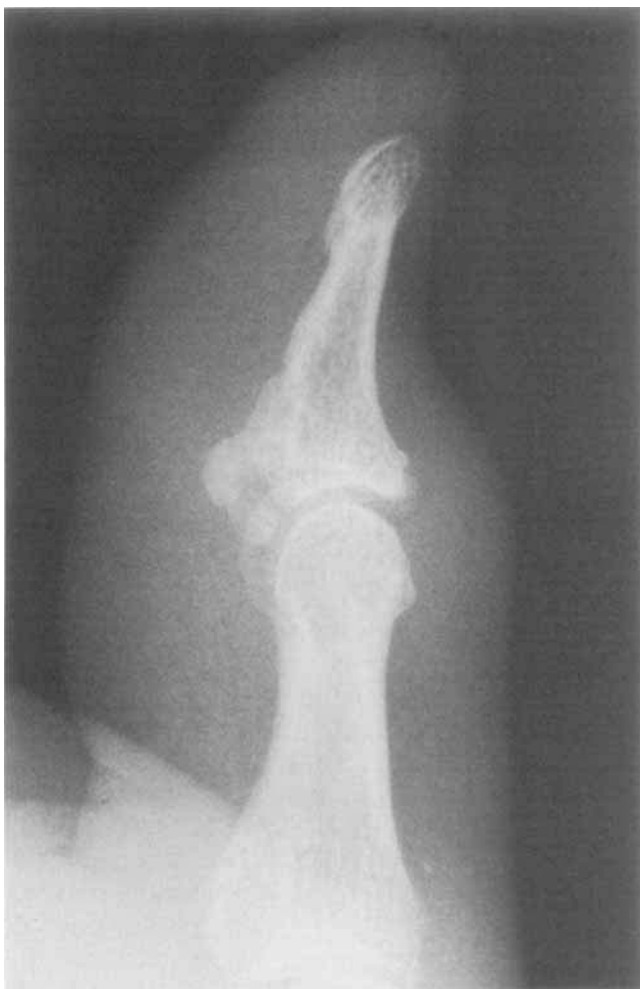From the Rackham Arthritis Research Unit, University of Michigan, Ann Arbor.

Supported in part by a grant from the Michigan Chapter of the Arthritis Foundation.

Charles L. Selby, MD: Rheumatology Fellow, Rackham Arthritis Research Unit, University of Michigan, Ann Arbor, MI.

Address reprint requests to Charles L. Selby, MD, Germantown Hospital and Medical Center, Two Penn Blvd., Suite 211, Philadelphia, PA 19144.

Submitted for publication June 13, 1983; accepted in revised form September 30, 1983.



**Figure 1.** Radiograph at admission, demonstrating dense calcific deposit around interphalangeal joint with associated sesamoid bone.

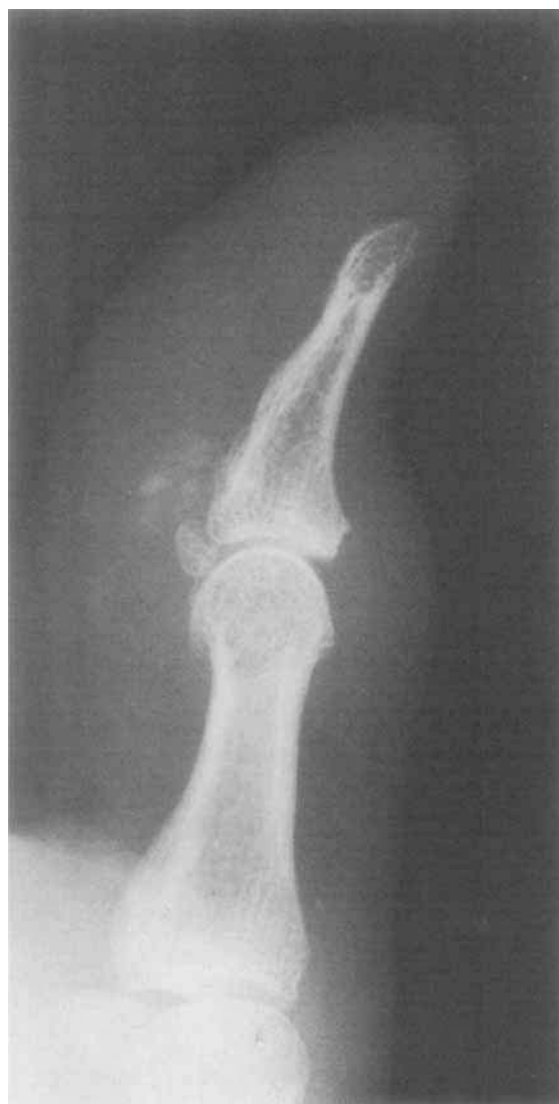week revealed total resolution of swelling and pain. A radiograph 6 months later (Figure 3) showed that the calcific deposits had completely disappeared. She remained asymptomatic during the followup period.

This patient had what initially appeared to be an acute monoarticular arthritis of the right first IP joint of the hand without signs of systemic toxicity. The first impression was that of septic arthritis. Attempted arthrocentesis yielded minimal inflammatory fluid. Radiographic studies demonstrated a calcific deposit around the joint. All cultures remained negative. Forty-eight hours after admission the correct diagnosis of acute calcific tendinitis of the hand was made. She responded dramatically to a local injection of a mixture of a corticosteroid and local anesthetic. A follow-

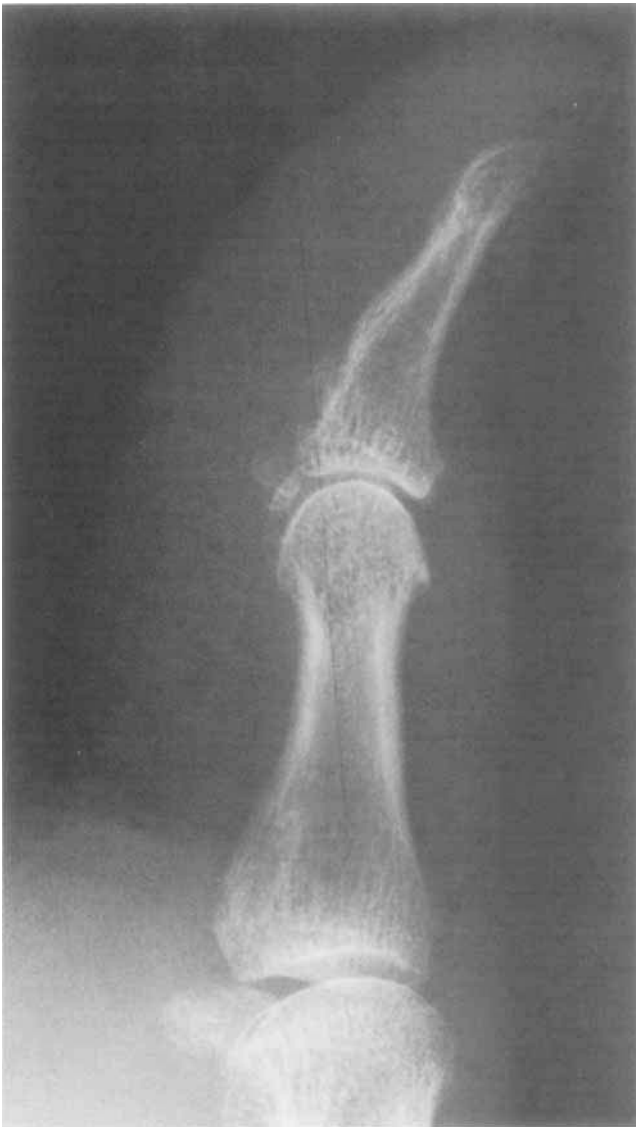
up radiograph demonstrated resolution of the calcareous deposit.

**Discussion.** Acute calcific tendinitis can involve sites other than those commonly seen such as the shoulder or hip, including: elbows, ankles, knees, feet, wrists, and hands (1-4). Repeated attacks of calcific periartthritis involving multiple sites over a number of years have been noted (1,3-5) suggesting a generalized disorder, rather than a localized process, in some patients. Crystalline analysis has demonstrated that the deposits are hydroxyapatite (3,6).

Cohen in 1924 (7) described the first case of acute calcific tendinitis in the hand in a 28-year-old



**Figure 2.** Repeat radiograph 2 days after admission and prior to treatment, demonstrating breakdown of deposit into multiple small, ill-defined masses.



**Figure 3.** Followup film 6 months after admission shows complete resolution of calcific mass.

woman with wrist involvement and calcification over the pisiform. Subsequent reports (1,2,5,6,8-13) have documented multiple paraarticular sites of involvement in the fingers and wrist. The 2 largest series, by Yelton and Dickey (109 cases) (5) and Carroll et al (100 cases) (8), suggest that this syndrome is much more common than realized. The wrist is more frequently involved than the hand itself (5,8). In Yelton's series, 74 cases involved the wrist, while 35 involved the fingers (metacarpophalangeal joints—19, proximal interphalangeal or distal interphalangeal joints—16). The most common site in the wrist is the distal end of the tendon of flexor carpi ulnaris at the pisiform (8,13).

There is no sexual predilection (5,8), and onset occurs most commonly from 30 to 60 years of age, although no age group is excluded (1,8). Although calcific tendinitis of the shoulder frequently is asymptomatic, only rarely has this been observed with calcareous deposits in the hand (5,8). Only 2 of Yelton's 109 patients had asymptomatic calcium deposition, while all 100 of Carroll's patients were symptomatic.

Clinically, the patient presents with symptoms of acute onset of pain, swelling, erythema, and limitation of motion around the involved joint, all of which mimic an acute monarticular arthritis. The calcific deposit may be localized by the point of maximal tenderness (8,9,12). Anatomically, sites of calcification have been found to localize to tendons, peritendinous tissue, joint capsule, or collateral ligaments (1,5). A history of trauma may be obtained in up to one-third of patients (8). The patient may be afebrile or run a low-grade temperature (5,9,11). The white blood cell count is usually normal (11). The sedimentation rate is usually normal, although it can be elevated (3,5,8,9,11). Serum calcium, phosphorus, alkaline phosphatase, and uric acid levels are normal (5,9,11).

The pathognomonic finding of radiographic examination is soft tissue calcification at the affected site. Although deposits are usually readily seen, special views and soft tissue films may, on occasion, be necessary to demonstrate them (5). The size of calcification is entirely variable and does not correlate with symptoms (12). This material has been successfully aspirated and grossly appears like toothpaste (8). With the onset of an attack, the calcium is seen as a homogeneous distinct mass. Over a period of time, this deposit may become less well-defined or mottled in appearance, and may fragment. It disappears entirely over a course of weeks to months (1,8). It is possible that cases occur without visible calcification radiographically (5), although the frequency of this is not known. A sesamoid bone may be distinguished from dystrophic calcification by the presence of bony trabeculation in the former (12).

Calcification, per se, is not the inciting agent; occasionally by chance it may be seen before the development of an attack (1,4,5). Rather, it appears that symptoms occur with the onset of dissolution of calcium (4,14); it is postulated that the inciting incident is rupture of the calcific deposit. Hydroxyapatite crystals are spilled into the surrounding soft tissue space or bursa (13), thus setting off an acute inflammatory response. The mechanism by which dystrophic calcification occurs within a tendon is unknown. The "de-

generative" theory (5,8,9) proposes that trauma or stress associated with poor local blood supply leads to tendinous tears and resultant calcification. More recently, Uthoff et al (14) have expanded this hypothesis based on histologic observations from surgically treated patients. They suggest hypoxia of a tendinous area, caused by poor blood flow induced by mechanical, metabolic, or other factors, results in transformation of this region into fibrocartilage. Following this, calcification occurs, mediated by chondrocytes. This is associated with vascular proliferation and subsequent resorption of the calcific focus by macrophages.

The natural history of acute calcific tendinitis is that of a self-limited condition. Carroll et al (8) found that in untreated patients, symptoms lasted up to 3 weeks. Immobilization by splinting decreased the symptomatic period to 9 days. Radiation therapy (1,2,12) and surgical evacuation (13) have been advocated in the past, but are not frequently recommended treatments now. Other remedies include aspiration (9,10), injection with local anesthetic and/or corticosteroids (3,5,8,10), and nonsteroidal antiinflammatory drugs (3,6,10). Colchicine has also been used successfully (6). There is no general consensus on therapy.

The differential diagnosis of calcific tendinitis of the hand includes, most importantly, infection. Many of the cases reported in the literature were initially misdiagnosed as septic arthritis (1,8,9). Crystalline disease such as gout or pseudogout (1,6,9) may appear clinically similar. Calcific tendinitis may also be misdiagnosed as simply a traumatic injury (7,8). Metabolic abnormalities can be associated with metastatic soft tissue calcification in hypervitaminosis D, hyperparathyroidism, and chronic renal failure.

## REFERENCES

1. Sandstrom C: Peritendinitis calcarea: a common disease of middle life: its diagnosis, pathology, and treatments. *AJR* 40:1-21, 1938
2. Hauptman HA: Acute tendinitis calcarea. *NY State J Med* 70:955-961, 1970
3. McCarty DJ Jr, Gatter RA: Recurrent acute inflammation associated with focal apatite crystal deposition. *Arthritis Rheum* 9:804-819, 1966
4. Pinals RS, Short CL: Calcific periartthritis involving multiple sites. *Arthritis Rheum* 9:566-573, 1966
5. Yelton CL, Dickey LE: Calcification around the hand and wrist. *South Med J* 51:489-495, 1958
6. Thompson GR, Ting YM, Riggs GA, Fenn ME, Denning RM: Calcific tendinitis and soft tissue calcification resembling gout. *JAMA* 203:464-472, 1968
7. Cohen I: Calcareous deposit at the insertion of flexor carpi ulnaris tendon following trauma. *Am J Surg* 38:172-173, 1924
8. Carroll RE, Sinton W, Garcia A: Acute calcium deposits in the hand. *JAMA* 157:422-426, 1955
9. Cooper W: Calcareous tendinitis in the metacarpophalangeal region. *J Bone Joint Surg* 24:114-122, 1942
10. Greene TL, Louis DS: Calcifying tendinitis in the hand. *Ann Emerg Med* 9:438-440, 1980
11. Pollen AG: Calcareous deposits around the metacarpophalangeal joints. *J Bone Joint Surg* 43B:250-255, 1961
12. Cowan II, Stone JR: Painful periarticular calcifications at wrist and elbow: diagnosis and treatment. *JAMA* 149:530-533, 1952
13. Strandell G: Peritendinitis calcarea in the hand. *Acta Chir Scand* 125:42-51, 1963
14. Uthoff HK, Kiriti S, Maynard JA: Calcific tendinitis: a new concept of its pathogenesis. *Clin Orthop* 118:164-168, 1976