

Antenatal Sonographic Findings of Fetal Adrenal Hemorrhage

P.J. Strouse, MD, R.A. Bowerman, MD, and A.E. Schlesinger, MD

In spite of the widespread use of obstetrical sonography, the prenatal detection of presumed adrenal hemorrhage remains extremely unusual.¹⁻⁴ Pathologic proof is rare.^{2,4} Several authors have noted adrenal calcifications at birth and have speculated that they represent the sequelae of prenatal adrenal hemorrhage. However, without pathologic proof, differentiation from spontaneously resolved neuroblastoma is not possible.⁵⁻⁷

We present a case of adrenal hemorrhage initially detected as a predominantly cystic mass with prenatal sonography at 28 weeks. The mass persisted on sequential prenatal sonograms with an increase in size and a change in internal architecture, from primarily cystic to complex with cystic and solid elements. Postnatal sonography and computed tomography (CT) on the first day of life confirmed a complex cystic and solid mass. Persistence of a suprarenal mass without significant decrease in size, in combination with a complex sonographic appearance, led to a presurgical diagnosis of cystic neuroblastoma; however, adrenal hemorrhage was found at surgery.

CASE REPORT

A 28-year-old woman (gravida 5, para 1, spontaneous abortion 3) had unremarkable sonograms at 6 weeks and 14 weeks, menstrual age (MA). At 28 weeks, MA, a 5.3 cm × 3.3 cm cystic mass was detected in the fetal left upper quadrant (Figure 1). On follow-up examinations at 32 weeks and 34 weeks, MA, the mass was complex with significant solid components intermixed with cystic spaces (Figure 2A) and had increased in size, now measuring 5.5 cm × 6.8 cm × 4.5 cm. The left

kidney was inferiorly displaced by the mass (Figure 2B). The fetal survey was otherwise normal, as was the amniotic fluid volume.

A 3,500 g baby boy was born at 37 weeks, MA, by an uneventful elective cesarean section. The physical examination of the neonate was unremarkable. No calcifications or masses were detected on abdominal radiographs. Sonography on the first day of life confirmed a complex cystic and solid mass in the left upper quadrant, inferior to the spleen and displacing the left kidney inferiorly (Figure 3). CT, also performed on the first day of life, showed a primarily cystic mass with a discernible rim and faint internal septations (Figure 4). On both postnatal sonogram and CT the mass was spherical, measuring approximately 4.7 cm in diameter. The findings were thought to most likely represent a cystic neuroblastoma, with adrenal hemorrhage being considered unlikely given the lack of significant decrease in size over 9 weeks and the complex sonographic appearance. On the third day of life, the infant underwent surgical excision of a cystic mass arising from the left adrenal gland. Pathology revealed a hemorrhagic cyst, with no evidence of neoplasm on careful examination. The patient recovered uneventfully.

DISCUSSION

Neonatal adrenal hemorrhage is commonly encountered in large obstetrical/neonatal centers. It occurs on the order of 1.7 times per 1,000 births.⁸ The chief differential consideration is non-metastatic neonatal neuroblastoma, which is usually solid. Differentiation of the two lesions is generally accomplished by close follow-up with serial sonography. As opposed to neuroblastoma, adrenal hemorrhage will demonstrate increasing sonolucency and decreasing size in follow-up sonograms.⁹ Correlation with urinary homovanillic acid (HVA) and vanillylmandelic acid (VMA)

From the University of Michigan Medical Center, Ann Arbor, Michigan. For reprint requests contact P.J. Strouse, MD, Section of Pediatric Radiology, C.S. Mott Children's Hospital, University of Michigan Medical Center, Ann Arbor, Michigan 48109-0252.

PRENATAL ADRENAL HEMORRHAGE

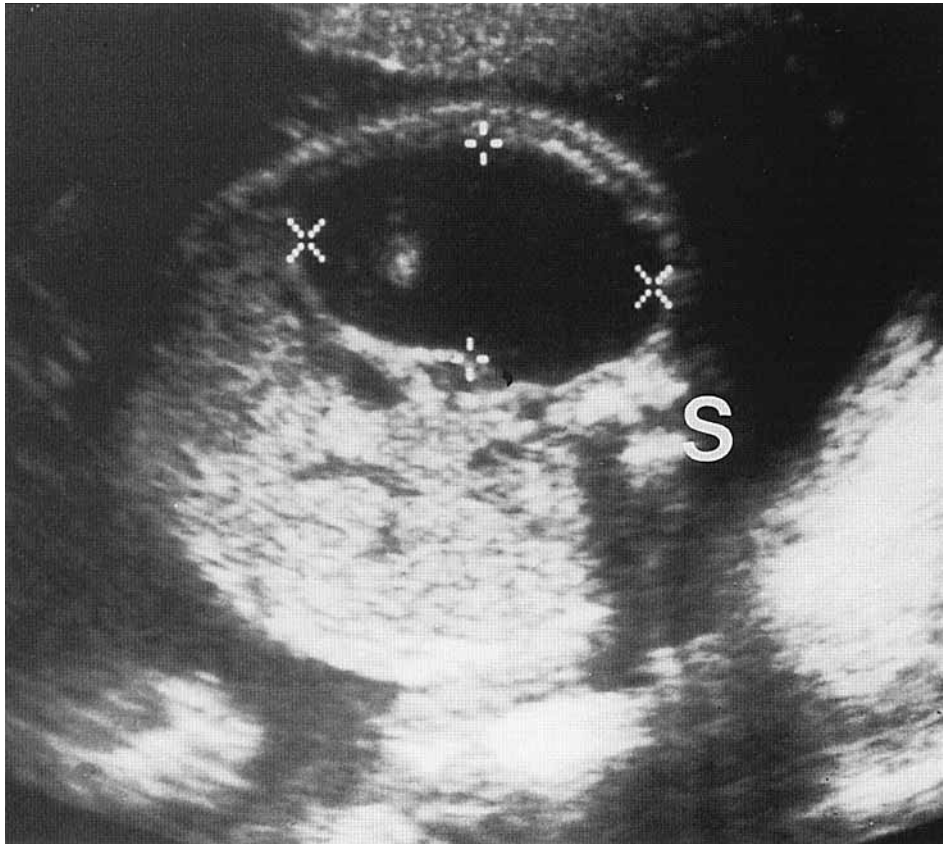


FIGURE 1. Transverse sonogram of the fetal abdomen at 28 weeks, MA. A cystic lesion is present within the left upper quadrant (calipers) (S: spine). (Images courtesy of Atis K. Freimanis, MD, and Teresa Kelley, MD, Department of Radiology, Michigan State University, East Lansing, Michigan.)

is also valuable in excluding the presence of neuroblastoma.¹⁰

There have been four prior reported cases of adrenal hemorrhage detected with prenatal sonography between 23 weeks and 36 weeks, MA.¹⁻⁴ Two of these cases had pathologic proof; the other two were presumed based on follow-up studies. Gotoh et al reported a 3.6 cm cystic mass detected with prenatal sonography at 36 weeks, MA.¹ A presumed diagnosis of adrenal hemorrhage based on a decrease in size by sonography 3 weeks postnatally, absence of metastases, normal urinary homovanillic acid (HVA) and vanillylmandelic acid (VMA) levels, and eventual calcification by 5 months. Marino et al reported a 5 cm × 3 cm cystic mass at 24 weeks, MA, which was pathologically proven to be an adrenal hemorrhage following postnatal surgery.² Lee et al reported a 3.6 cm × 3.2 cm "hypoechoic" mass identified with prenatal sonography at 32 weeks, MA.³ A presumed diagnosis of adrenal hemorrhage was based on decrease in size and eventual resolution on serial postnatal sonography.³ Noe and Angel reported a 2.5 cm suprarenal mass, echogenic on both prenatal (23 weeks, MA) and

postnatal sonography, and surgically confirmed to be an adrenal hemorrhage.⁴ Three authors have postulated that adrenal calcifications detected at birth represent the sequelae of prenatal adrenal hemorrhage,⁵⁻⁷ but none of these cases were proven pathologically.

Prior non-pathologically proven cases of presumed adrenal hemorrhage are controversial because of the natural history of neuroblastoma in the neonatal age group and the overlap of the sonographic and radiographic characteristics of the two lesions. It has been widely published that neuroblastoma in the neonate or child of younger than 2 years of age carries a better prognosis than neuroblastoma in the older child.¹¹ Spontaneous resolution can occur, especially with stage IV disease.¹² Incidental or "in situ" neuroblastoma is a proven phenomenon.¹³ Eklof et al reported 11 cases of "concomitant" neonatal adrenal hemorrhage and neuroblastoma.¹⁴ It is not clear whether the hemorrhages were truly concomitant or actually secondary to neuroblastoma. One would expect these lesions to behave, at least in part, like adrenal hemorrhage when examined sonographically. Neonatal neuroblastoma can also be

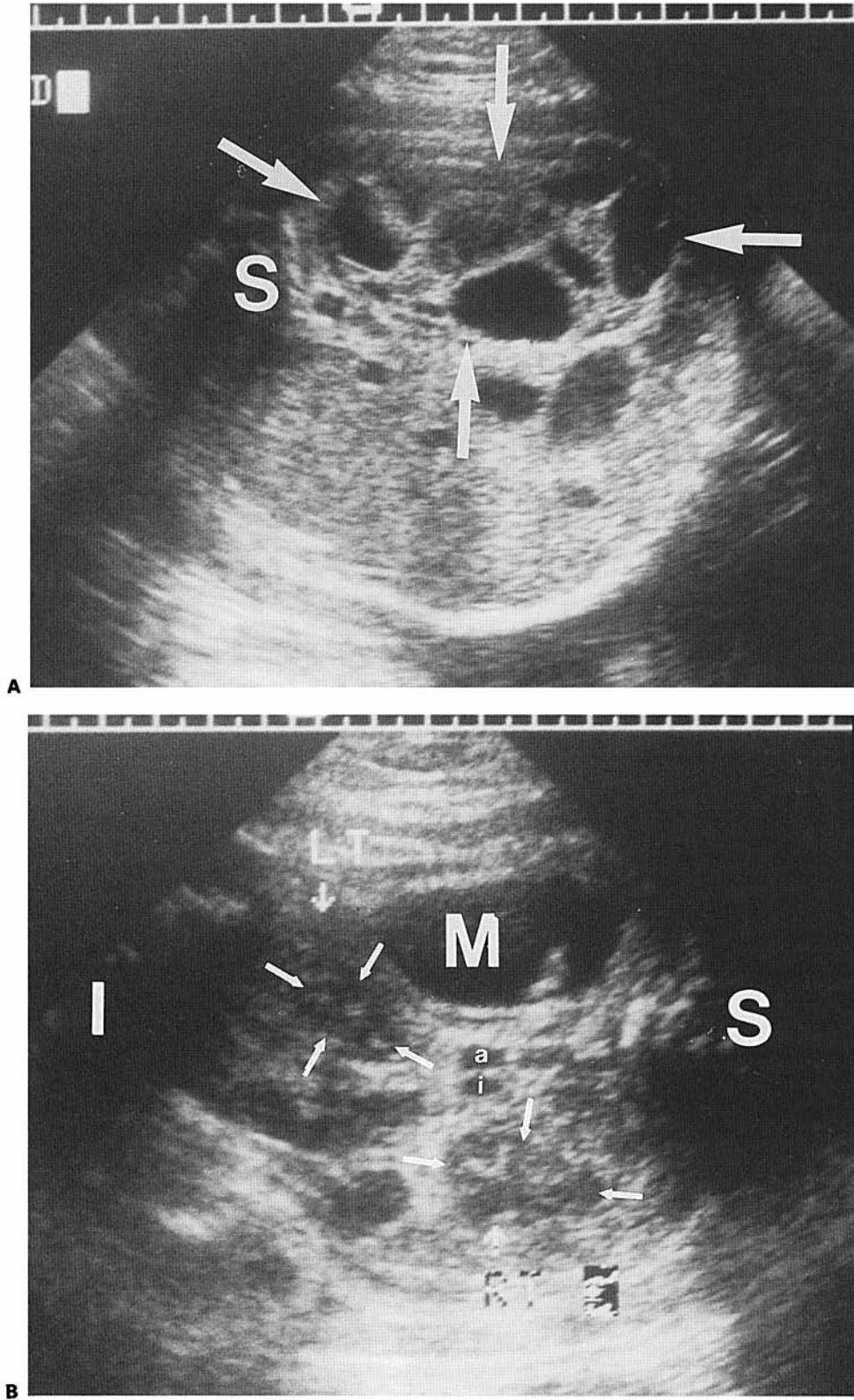


FIGURE 2. (A) Transverse sonogram of the fetal abdomen at 34 weeks, MA. The fetal left upper quadrant mass (arrows) is now complex with cystic and solid components, and was larger than 4 weeks previously (S: spine). **(B)** Coronal sonogram of the fetal abdomen at 34 weeks, MA. This plane is through a cystic component of the mass (M). The left kidney (LT, arrows) is inferiorly displaced by the mass (RT, arrows: right kidney; S: superior in fetus; I: inferior in fetus; a: aorta; i: inferior vena cava).

PRENATAL ADRENAL HEMORRHAGE

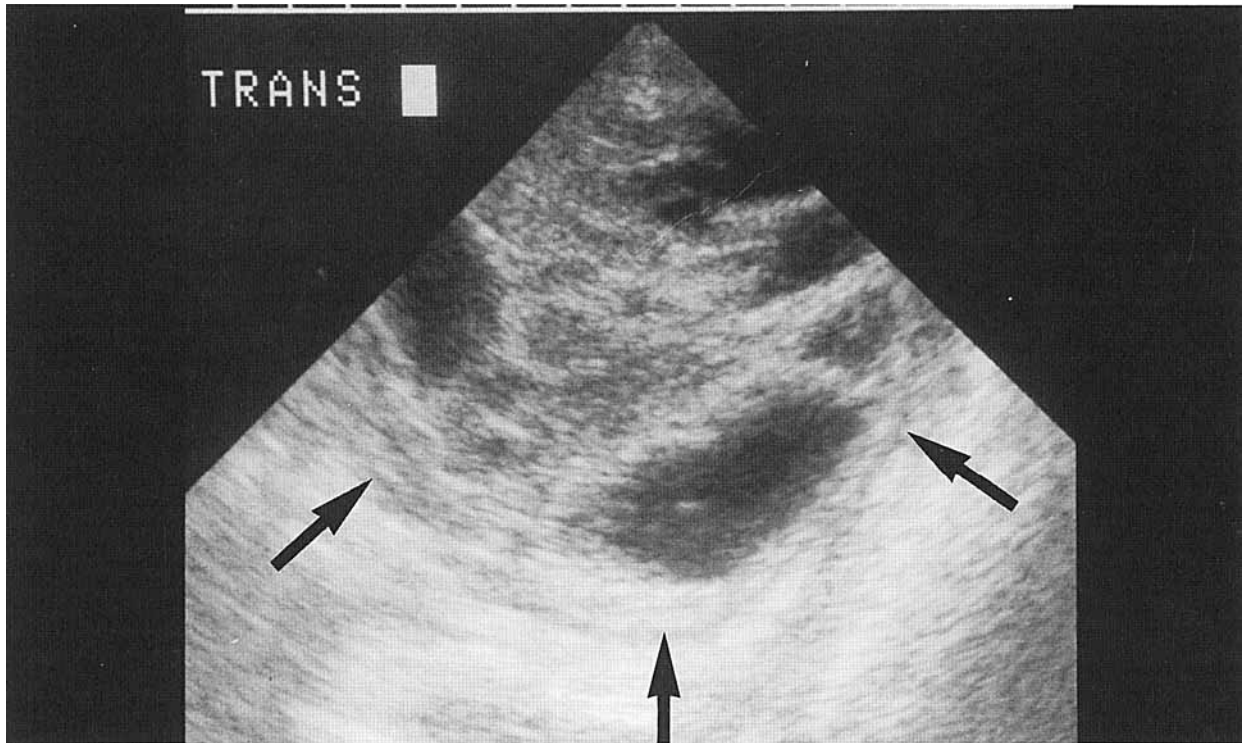


FIGURE 3. Postnatal transverse sonogram through the left upper quadrant. A complex cystic and solid mass (arrows) similar to the prenatal appearance is seen.

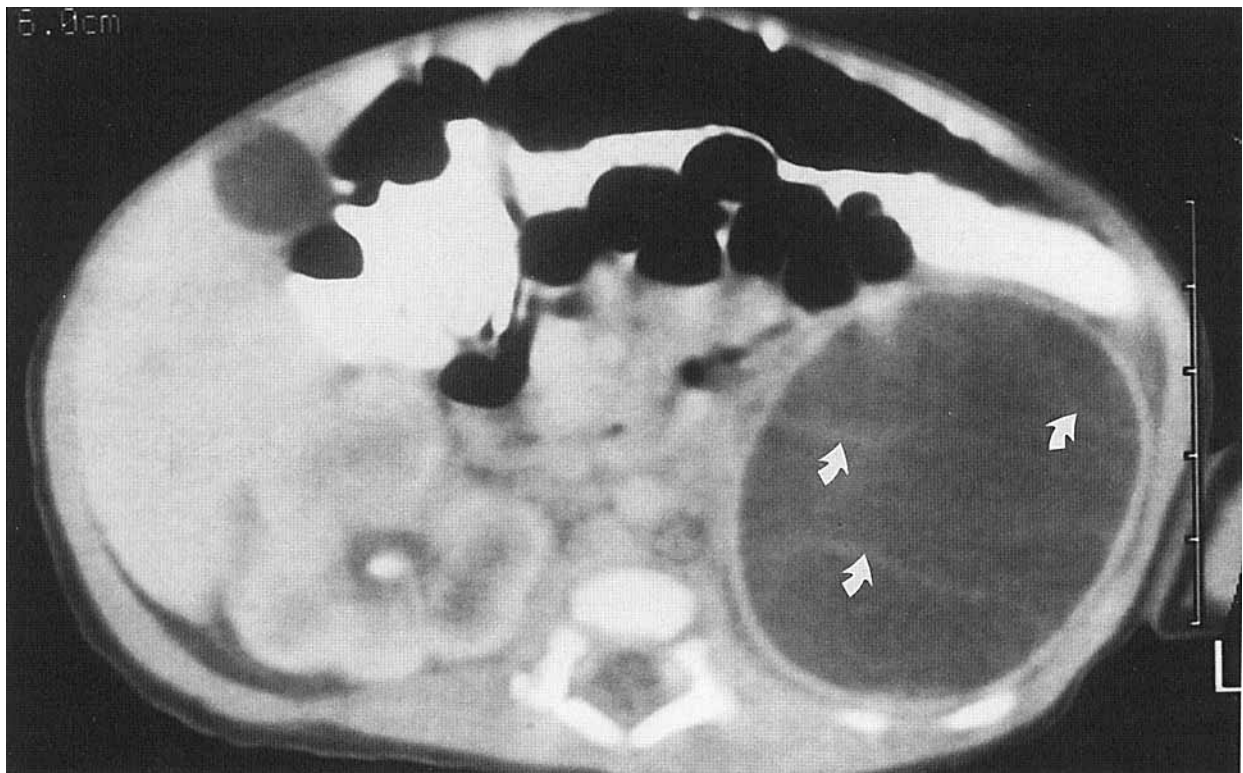


FIGURE 4. Postnatal CT. A predominantly cystic mass is seen in the left upper abdomen. A discernible wall and faint internal septations (arrows) are noted.

cystic, simulating an evolving adrenal hemorrhage.¹⁵ Reinberg reported a solid appearing neuroblastoma which decreased in size on subsequent sonograms, a finding usually considered reliable evidence of adrenal hemorrhage.¹⁶ The sonographic diagnosis of neonatal adrenal hemorrhage thus remains an assumptive one, based on the typical sonographic course. Follow-up to sonographic resolution and correlation with urinary catecholamines should suffice to exclude clinically significant neuroblastoma.

Diagnosing prenatal adrenal hemorrhage on the basis of adrenal calcifications detected at birth is also controversial. Fifty to seventy-five percent of neuroblastomas contain calcification. Neuroblastoma in the neonate, and presumably in the fetus, can spontaneously resolve or exist in situ.^{12,13} Therefore, it is possible that calcifications presumed to represent the sequelae of prenatal adrenal hemorrhage actually represent the residua of spontaneously resolved neuroblastoma or neuroblastoma in situ.

As there is unequivocal proof that prenatal adrenal hemorrhages do occur, suprarenal masses detected in utero can be followed postnatally in a similar fashion to those detected postnatally, assuming the infant's urinary HVA and VMA levels are normal. A solid or complex suprarenal mass which subsequently becomes sonolucent and shrinks on follow-up sonograms, *prenatally* and *postnatally*, is most consistent with adrenal hemorrhage. Should the mass grow, fail to resolve, or have other characteristics suspicious for neuroblastoma, even with normal urinary HVA and VMA levels (10% of patients with neuroblastoma have normal HVA, 27.5% have normal VMA¹⁰), then additional imaging and possible surgical intervention should be considered.

Our case is only the third report of pathologically proven prenatal adrenal hemorrhage. The sonographic appearance in this case differs from prior reported cases. Although initially detected at 28 weeks, MA, as a primarily cystic lesion, by 32 weeks it had evolved to a complex cystic and solid sonographic appearance. Although a lesion that changes on serial sonograms from cystic to semisolid is frequently adrenal hemorrhage, this can also be seen with neuroblastoma, particularly with associated hemorrhage. Due to the complex appearance and a lack of significant decrease in size in postnatal examinations, a cystic neuroblastoma was suspected and surgery was performed in the reported case. Even with the knowledge that prenatal adrenal hemorrhages do occur, it is unlikely that surgery could have been averted because the lesion did not follow the typ-

ical sonographic course of adrenal hemorrhage. This may represent a different physiology of adrenal hemorrhage occurring in utero, or recurrent hemorrhages contributing to a confusing sonographic appearance.

In conclusion, prenatal adrenal hemorrhage does occur. Prenatal adrenal hemorrhage has a variable sonographic appearance. Prenatally detected suprarenal masses may be investigated and followed clinically and radiographically similar to postnatally detected suprarenal masses.

REFERENCES

1. Gotoh T, Adachi Y, Nounaka O, et al: Adrenal hemorrhage in the newborn with evidence of bleeding in utero. *J Urol* 141:1145, 1989.
2. Marino J, Martinez-Urrutia MJ, Hawkins F, et al: Adrenal hemorrhage: prenatal diagnosis. *Acta Paediatr Scand* 79:230, 1990.
3. Lee W, Comstock CH, Jurcak-Zaleski S: Prenatal diagnosis of adrenal hemorrhage by ultrasonography. *J Ultrasound Med* 11:369, 1992.
4. Noe HN, Angel CRE: Adrenal hemorrhage in the newborn with evidence of bleeding in utero (letter). *J Urol* 147:1627, 1992.
5. Newman SL, Papciak MR, Gay BB Jr: Adrenal calcification present at birth. *Southern Med J* 72:372, 1979.
6. Pinck RL, Constantacopulos CG, Felice A, et al: Adrenal hemorrhage in the newborn with evidence of bleeding while in utero. *J Urol* 122:813, 1979.
7. Naidech HJ, Chawla HS: Bilateral adrenal calcifications at birth in a neonate. *AJR* 140:105, 1983.
8. DeSa DJ, Nicholls S: Haemorrhagic necrosis of the adrenal gland in perinatal infants: a clinicopathological study. *J Pathol* 106:133, 1972.
9. Bergami G, Malena S, Di Mario M, et al: L'ecografia nel follow-up dell'emorragia surrenalica in età neonatale: presentazione di 14 casi. *Radiol Med* 79:474, 1990.
10. Tuchman M, Ramnaraine MLR, Woods WG, et al: Three years of experience with random urinary homovanillic and vanillylmandelic acid levels in the diagnosis of neuroblastoma. *Pediatrics* 79:203, 1987.
11. Jereb B, Bretsky SS, Vogel R, et al: Age and prognosis in neuroblastoma. *Am J Ped Hem Onc* 6:233, 1984.
12. Evans AE, Chatton J, D'Angio GJ, et al: A review of 17 IV-S neuroblastoma patients at Children's Hospital of Philadelphia. *Cancer* 45:833, 1980.
13. Beckwith JB, Perrin EV: In situ neuroblastoma: a contribution to the natural history of neural crest tumors. *Am J Pathol* 43:1089, 1963.
14. Eklof O, Mortensson W, Sandstedt B: Suprarenal haematoma versus neuroblastoma complicated by haemorrhage. *Acta Radiologica Diagnosis* 27:3, 1986.
15. Hendry GMA: Cystic neuroblastoma of the adrenal gland—a potential source of error in ultrasonic diagnosis. *Pediatr Radiol* 12:204, 1982.
16. Reinberg YRE: adrenal hemorrhage in the newborn with evidence of bleeding in utero (letter). *J Urol* 144:1244, 1990.