

THE NORMAL HISTOLOGY OF THE HUMAN HEMOLYMPH GLANDS.

BY

ALDRED SCOTT WARTHIN, PH. D., M. D.,

Assistant Professor of Pathology, Pathological Laboratory, University of Michigan.

In the prevertebral fat of the bullock and sheep there are found in large numbers glands varying in size from a pin-point to a large cherry and of a deep-red or chocolate color. Because of their number and striking color these glands stand out with much greater prominence than the pale lymph glands of these animals, but despite this fact they have been strangely overlooked and their histology and function investigated by but few observers. The earliest mention made of them that I have been able to find is by Leydig (*Lehrbuch der Histologie der Menschen und der Thiere*, 1857, pages 424, 429). This writer speaks of glands occurring along the thoracic aorta in many mammals, particularly in the hog, which from their color might be mistaken for accessory spleens in case they were found in the immediate neighborhood of the spleen. The cut surface of many of these glands he describes as perfectly resembling that of the spleen, presenting a dark-red pulp in which lie white masses of cells corresponding to the Malpighian follicles. Leydig noticed further that transition-forms exist between these glands and ordinary lymph-glands, but his observations were confined entirely to the gross appearances, and the histological structure of these glands was not investigated by him.

In 1884 H. Gibbes noticed the presence near the renal vessels of the human body of glands differing from ordinary lymph-glands in that they possessed sinuses containing blood in place of lymph. This important discovery was not carried further and the observation was lost sight of, the next mention of these organs being made by Robertson (*Lancet*, Nov. 29, 1890) who, apparently unaware of Gibbes' discovery, made the first histological study of these structures and gave them the name of hemolymph glands (suggested by Dr. Russell under whom Robertson was working). He found these glands to be present in the sheep, bullock and human body, but his histological descriptions are based chiefly upon their structure as found in the sheep. His work

upon the human body was unsatisfactory because of the unfavorable conditions under which his autopsies were made. He was able, however, to determine the presence of these glands in man, and states that their structure in the human body is very similar to that in the sheep and bullock.

In 1891 Clarkson reported observations on "certain hitherto undescribed glands" found in the neighborhood of the renal vessels in the horse, sheep and goat. To these he gave the name of "hemal glands," and considered them to be a different variety from the hemolymph glands described by Robertson though probably possessing the same function.

Gibbes in 1893 made a second report in which he states that Robertson's description of these organs accords with the glands discovered by himself in 1884, and accepts the designation of hemolymph glands as an appropriate name for them. Finding his discovery thus confirmed he had made further investigations in the human subject, and found these glands to be constantly present near the renal vessels. He added nothing, however, concerning their histology or function.

In Clarkson's "Text-Book of Histology," 1896, several pages are devoted to the histology of the "hemal glands." Clarkson states that these organs have been found in the pig, horse, ox and sheep, but have not yet been observed in man. His descriptions are similar to those of Gibbes and Robertson, and the hemal glands must be regarded as hemolymph glands.

Vincent and Harrison, in 1897, gave a detailed histological description of the hemolymph glands of the ox, sheep and rat. They noted also the occurrence of similar glands in the horse, dog, common fowl and turkey, and pointed out the histological resemblance existing between hemolymph glands and the head-kidney of certain teleostean fishes. In several human cadavers examined they found no hemolymph glands, but Vincent in a later examination found them in the mesentery of a young boy.

In 1900 Drummond made a more thorough study of the histology of the hemolymph glands of the sheep, ox, rat and dog; and gave a very clear description of their structure. He confirmed the work of Robertson and Vincent and Harrison; and added many important points concerning the distribution and structure of these glands in the lower animals.

In so far as I have been able to discover these are the only observations that have been made of the occurrence and structure of the hemolymph glands, and as seen above the chief part of these have been

of these glands as occurring in the lower vertebrates. Gibbes' discovery of their presence in the human subject, confirmed by Robertson, the second report of the former and the solitary observation of Vincent represent the sum total of the published work upon the human hemolymph glands up to the publication of my article, "A Contribution to the Normal Histology and Pathology of the Hemolymph Glands" (Journal of the Bost. Soc. of Med. Sciences, April, 1901). In this paper I made a preliminary report of a study of the human hemolymph glands which has been carried on by me in this laboratory for several years. My attention was first drawn to these glands by certain cases in which some of the retroperitoneal lymph glands appeared to play a part independent of that of the other lymph glands of the body. In its earlier stages the study was confined to the retroperitoneal region, but later systematic investigation was also carried out of the cervical, thoracic and mediastinal glands. The material for this work has been obtained from my autopsy cases of the last five years, 94 in all. It was early evident to me that there were two distinct varieties of lymph glands, one containing blood sinuses and apparently possessing distinct hemal functions. At that time the observations of Gibbes, Robertson and Vincent were unknown to me so that the essential nature of the glands was also independently discovered by me.

Since the publication of my article in April of this year there has appeared in the *Archiv f. Mikr. Anatomie* (July) a paper by Weidenreich on the "Gefässsystem der Menschlichen Milz," in which he treats theoretically of the hemolymph glands, basing his conclusions upon the work of the English observers. The more important of his theoretical deductions are confirmed by my previously-reported observations.

The present paper will be devoted to a consideration of the normal histology of human hemolymph glands to a much fuller extent than in my preliminary report. With the exception of a few accident cases none of my autopsy subjects can be said to have been normal. The majority were chronic cases, many of which showed various stages of anemia and cachexia. In so far as I am able to divide the appearances observed by me into histological and pathological such classification is based upon the fact that only in cases showing extensive changes in the blood were conditions found in the hemolymph glands that could be regarded as being essentially pathological. In all other cases the structure of the glands was assumed to be histological because of their identity of structure with the glands found in normal individuals killed by accident, the general similarity of structure in all cases except certain blood cases, and finally their resemblance to the hemolymph glands of

normal animals. As a result of this study the following conclusions regarding the normal histology of the human hemolymph glands have been reached.

Technique.—The thymus, anterior mediastinal and renal regions are examined in the usual order of the autopsy; the prevertebral tissues at the close of the autopsy. The neck-organs, thoracic and abdominal vessels, root of the mesentery, and other structures attached are stripped from the spinal column from above downwards and removed from the body for minute examination. When there is much prevertebral fat present or when the tissues are very opaque the search for hemolymph glands may be made much more successful by first fixing the tissues in mass in 4 per cent formalin. The color of the blood-sinuses is in this way brought out much more sharply, and the glands may be recognized when the search in the fresh tissue would have been negative. When it is desired to study the exact position and relations of these glands the prevertebral tissues should be dissected in place and not stripped from the spine. Since the sinuses of the human hemolymph glands partly collapse after death the recognition by color alone is not easy and at times impossible. It therefore becomes necessary to remove all glands found in a region for microscopical diagnosis and in many cases it is only in this way that the character of a gland can be definitely determined. In the search for these glands in the human body their proximity to large vessels should be borne in mind; they occur very frequently in the connective tissue between artery and vein.

OCCURRENCE.—Taking the presence of a sinus containing blood in place of lymph as the essential feature of a hemolymph gland, such glands are found constantly present in the human body. They are apparently more numerous, at least are more easily recognized, in early adult and middle life than in infancy or old age. In new-born children they are discovered with difficulty, and usually can be found only after microscopical examination. In late life they become atrophic, the blood-sinuses being obliterated for the greater part by connective-tissue increase. No difference in their occurrence has been observed in the sexes. With the individual they apparently differ very much as regards their location, number and size, seldom being found under exactly similar conditions; but owing to the difficulty of recognizing them with the naked eye it is probable that these variations may be only apparent, resulting from imperfect technique.

They are found in greatest numbers in the prevertebral retroperitoneal and cervical regions, in the neighborhood of the adrenal and renal vessels, along the brim of the pelvis, in the root of the mesen-

tery but rarely extending far out into it, still more rarely in the omentum and epiploica. In normal individuals they are rarely found in the mediastinal tissues or along the thoracic vertebrae, but in cases of anemia in which the hemolymph glands throughout the entire body are enlarged they may be found in large numbers in these regions making it appear probable that under normal conditions they are of such small size as to escape notice. In the cervical region they are usually found below and behind the lobes of the thyroid in association with the parathyroids.

GROSS APPEARANCES.—The human hemolymph glands are not nearly so easily recognized by the naked eye as are those of the steer and sheep, because of the fact that their blood-sinuses are frequently collapsed and partly emptied after death. They usually lie deeply embedded in fat or connective tissue, and as a rule near the wall of some large vessel. As a rule only a few show distended sinuses, these glands are deep-red or bluish in color and may be easily mistaken for hemorrhages, blood-clots, or deeply-congested lymph glands. The resemblance to spleen-tissue is often very close. In the transition forms which are partly hemolymph glands and partly ordinary lymphatic glands the blood-sinuses appear as red points or streaks. It is often difficult or impossible to distinguish these from congested lymph glands. The smallest hemolymph glands may often be found by stretching the tissue against the light, the blood-sinuses then appearing as red points or lines. Fixation of the tissues in formalin is of great advantage as the blood-content of the sinuses of these glands is brought out in sharp contrast to the lighter color of lymphoid tissue. When the blood-sinuses are small or few in number the gland cannot be distinguished on naked-eye inspection from an ordinary lymph gland. It is, therefore, safest in studying the occurrence of hemolymph glands to remove all apparent glandular structures and examine them microscopically.

On cross-section the blood-sinuses resemble spleen-pulp and contrast according to their blood-content more or less sharply with the whitish areas of lymphoid tissue. Small round masses of whitish lymphoid tissue often project into the pulp-like peripheral sinus suggesting splenic follicles. Partly collapsed and emptied sinuses appear as points and streaks of red. The presence of a peripheral red streak just beneath the capsule of the gland with red lines radiating toward the center of the gland is a very important point in the naked-eye diagnosis of these organs. Occasionally the capsular surface of a hemolymph gland is studded with small beaded elevations, giving it a raspberry appear-

ance; on section these are found to be small round masses of lymphoid tissue projecting into the peripheral sinus.

The size of the human hemolymph glands varies from that of a pinpoint to a large cherry or almond. The latter size is, however, uncommon, the usual size being that of a yellow mustard seed or pea. In the majority of cases their shape is round or oval, some are flattened, others elongated, while not infrequently glands of an almond shape are found, the larger end being somewhat recurved upon itself. They usually possess a distinct hilum into which vessels enter. Their consistency is somewhat softer than that of ordinary lymph glands depending upon the amount of blood in the sinuses. If these are large and dilated the capsule of the gland may be so stretched that it is easily ruptured and the gland pulp have the appearance and consistency of a fresh blood-clot; and these glands are undoubtedly many times mistaken for such.

Attached to the gland there is usually a relatively large plexus of vessels, the veins in particular being large and prominent. Occasionally these remain dilated and filled with blood, and under such conditions are of great aid in making the naked-eye diagnosis. No lymph vessels can be demonstrated in the case of those glands, even the largest, which contain blood-sinuses throughout, but in the glands of mixed type, partly hemolymph and partly lymphatic, lymph vessels can be made out.

The number of hemolymph glands in the human body is exceedingly difficult of estimation. Since the ultimate diagnosis depends upon the microscopical examination it would be necessary in making an exact estimation to examine every lymphatic gland in the body. Moreover, since many of the hemolymph glands are very small and lie deeply embedded in fat and connective tissue, it is necessary to remove all the tissues in the regions where the glands are found and make serial sections of the entire tissue. The difficulty of this is evident. The number of lymph glands visible to the naked eye in the retroperitoneal region varies from 200-500, and the prevertebral tissues contain also numerous nodes of lymphoid tissue too small to be seen on naked-eye inspection. In a number of cases the entire retroperitoneal tissue has been examined, both in the fresh state and microscopically, but the results are so much at variance that no definite statements regarding the number of hemolymph glands can be made. Ordinarily the relative proportion to lymphatic glands is 1-20 to 1-50, but this statement is based upon very incomplete observations. It is very probable that the number of hemolymph glands is much greater than that expressed by these ratios, since in one case of pernicious anemia over sixty of the glands were removed

from the cervical, thoracic and retroperitoneal regions alone; in another case of pernicious anemia, over thirty from the retroperitoneal region alone; and forty from the same region in a case of leukemia. Vincent's finding of hemolymph glands, about fifty in number, in the mesentery and gastro-colic omentum may also be remembered. In the human body many of these glands appear to be in a resting state, and are not easily distinguished from ordinary lymph glands, but in certain conditions, particularly blood diseases, they become enlarged and prominent. A new-formation of these glands in compensation for spleen or bone-marrow is also possible and undoubtedly takes place under certain pathological conditions. The use of formalin in fixing the tissues and rendering more prominent the blood-content of hemolymph glands may be mentioned again in this place as being of great service in the estimation of their number.

MICROSCOPICAL EXAMINATION.

Technique.—Alcohol fixation does not give the best results in the study of these glands except for the use of the tri-acid stain. It produces too much contraction of the reticulum and changes the red cells so that they do not stain well. Mercuric chloride, formalin and Zenker's fluid are the best fixing agents in the order named. With all of these there is less shrinkage, and the red cells are better preserved, staining well with eosin, etc., so that the course of the blood-sinuses is well outlined by the blood yet remaining in the meshes of the reticulum. Mercuric chloride fixation is especially recommended in the study of their finer structure, since all stains, including the tri-acid, give good results after this fixation, the cell-division figures and the red-blood cells are well preserved, and there is little shrinking. Hematoxylin and eosin, the tri-acid stain, etc., are used according to the object sought. Mallory's reticulum stain is essential for the study of the reticulum of the blood-sinuses, and is particularly valuable in tracing the course of these. Kresylechtviolett is also very valuable in the study of mast-cells, etc.

For the study of the cells of these glands it is also advisable to make cover-glass smears from the freshly-cut surface. This should be done as soon as possible after death. The smears are made in the usual manner, fixed by heat or alcohol and ether, and stained as desired. In this connection kresylechtviolett is also recommended as of value in the study of cell-granulation.

Microscopical Appearances.—The lymph glands of the human body may be divided broadly into two groups: those containing only lymph-sinuses, ordinary lymphatic glands, and those possessing blood-sinuses, hemolymph glands. Between these two groups intermediate forms exist—a gland may contain both blood and lymph-sinuses—the pres-

ence of a blood-sinus, however small, is sufficient warrant for the classification of a gland as a hemolymph gland.

The microscopical study of the lymphoid nodes containing blood-sinuses reveals a most striking variety of structure in so far as the relative size, number and arrangement of the blood-sinuses, lymphoid tissue, etc., are concerned. It is possible, however, to divide the different forms into two distinct types, to which I have given the names *splenolymph* and *marrowlymph* gland as indicating their structure and probable functions. Between these two there is every possible transition-form, just as there is also between the spleen, hemolymph glands and ordinary lymphatic glands. It is not by any means intended to replace the designation, hemolymph gland, by these names, as the latter should still be used as a collective term.

SPLENOLYMPH GLANDS.

The great majority of hemolymph glands correspond to this type. They are found chiefly along the abdominal aorta, vena cava, adrenal and renal vessels, in the neighborhood of the solar plexus, cervical region, occasionally in the omentum, mesentery, epiploica, mediastinal and thoracic prevertebral regions. These glands are usually round, but also frequently almond-shaped, varying in size from a pin-point to a large cherry. As a rule they possess a distinct hilum into which numerous vessels of large size enter. These are also found penetrating the capsule at many points. Very often the gland appears to be surrounded by a plexus of vessels, sometimes arterial, at other times venous. Their gross appearances correspond with those given above for hemolymph glands in general. Their resemblance to the spleen is sometimes so great that they may be mistaken for accessory spleens, and undoubtedly many of the so-called accessory spleens belong to this type of hemolymph gland. This fact was dimly recognized by Haberer in his recent article "Lien Succenturiatus und Lien Accessorius" (Arch. f. Anat. u. Phys., March, 1901). Apparently unaware of the existence of hemolymph glands this observer concluded that many glands regarded as accessory spleens were in reality peculiar types of lymph glands representing intermediate forms between spleen and lymph glands.

Capsule.—The splenolymph glands possess a capsule of connective tissue which may be very thick in proportion to the size of the organ or very thin and delicate. It contains a varying amount of unstriped muscle, and very little yellow elastic tissue. Adipose tissue surrounds the capsule. The latter is frequently pierced by many obliquely-pene-

trating blood-vessels. Occasionally the blood-spaces and vessels in the capsule are so numerous as to give it the cavernous structure so frequently seen in the capsule of these glands in the steer; but on the whole the splenolymph glands of man are distinguished from those of the lower animals by the less vascular structure of the capsule. From the external capsule trabeculæ of similar tissues run into the gland dividing it into irregular lobules. Accompanying the trabeculæ are the communicating blood-sinuses and between them lies the lymphoid tissue.

Blood-sinuses.—Immediately beneath the external capsule there is a blood-sinus which sometimes extends entirely around the periphery of the gland, but more frequently only for portions of the way, being frequently interrupted by masses of lymphoid tissue which reach to the external capsule. In the great majority of cases this sinus is much smaller and less prominent than in the hemolymph glands of the steer and sheep. Glands are, however, occasionally seen in man with the peripheral sinus dilated and containing as much blood as in any gland from these animals. From the peripheral sinus branches pass in with the trabeculæ toward the centre of the gland or toward its hilum, increasing in size and becoming confluent towards these points until they are often very large and prominent. These radiating sinuses frequently communicate with each other, and so divide the lymphoid tissue into irregularly-shaped islands apparently surrounded on all sides by a blood-sinus. Serial sections, however, show that these islands are not entirely cut off from each other in the majority of cases, but at some point or other are connected by an isthmus of lymphoid tissue of varying size. The number and size of the blood-sinuses as well as their general arrangement vary greatly, so that scarcely any two glands exactly resemble each other in these respects.

The lumen of the peripheral as well as of the communicating and central sinuses is traversed by a coarse reticulum through the meshes of which the blood circulates. The amount of this reticulum and the size of its meshes vary in different glands; frequently the central sinuses are open, possessing but a scanty reticulum or none at all. The reticulum of the sinuses is probably lined throughout with flattened endothelium, but it is sometimes difficult or impossible to make this out, so that the blood appears to be in direct contact with fibres of the reticulum. A wide sinus is often abruptly narrowed by a constriction of coarser reticulum suggesting a valve-like arrangement, but this point is yet to be worked out. The course of the sinuses is clearly shown in sections by the lighter staining nuclei of the reticulum in contrast

to the more deeply-stained lymphoid tissue and the red cells lying in the reticular meshes.

The central sinuses frequently form the most striking feature of the splenolymph glands. Though usually partly or even wholly emptied of blood they often remain dilated. Scanty reticulum may extend either across or only for a short distance into the lumen of the larger sinuses. At other times the central sinuses may contain as much reticulum as either the peripheral or communicating ones. Red-blood cells and large phagocytes containing red cells and blood pigment are found in the reticular meshes along the sides of these sinuses. In some glands the central and communicating sinuses take up the greater part of the central portion of the gland, so that microscopical sections resemble a much-congested spleen-pulp.

Lymphoid Tissue.—The lymphoid tissue lying between the sinuses resembles very much that of an ordinary lymph gland. It varies very much in amount, sometimes forming a mere network between the sinuses, while in other cases it may form the chief part of the gland. Usually the greater mass of lymphoid tissue is toward the periphery, forming the inner border of the peripheral sinus, but it also frequently extends to the capsule interrupting the peripheral sinus. The arrangement of the lymphoid tissue also varies much in different glands. It is usually cut up into irregular areas or lobules which are for the greater part surrounded by the blood-sinuses. Small round collections of lymphoid cells are often seen, resembling splenic follicles. These occur more frequently at the periphery, where they may be partly or wholly surrounded by the blood-sinus, but they may also be found toward the central portion of the gland. Serial sections show that they are almost perfectly round. In the majority of cases they possess no arterial relations as in the case of the splenic follicles, but occasionally a small capillary is found in them which under certain pathological conditions may become gradually converted into a small arteriole with thick walls. The resemblance in this case to the splenic follicle is complete.

The cells of the lymphoid tissue are for the greater part small lymphocytes. These vary greatly with respect to the relative size and staining power of the nucleus and relative amount of protoplasm. Next to the small lymphocyte the large mononuclear cell is the most common form present. These also vary much in size, form and staining power. Transitional and polymorphonuclear leukocytes are also present. A small number of basophile and mononuclear eosinophiles is usually present, mast-cells are rare in the majority of cases, but occasionally a

gland is found, as in the steer and sheep, in which the majority of the cells of the central portion of the gland are mast-cells.

Red-blood cells lie free in the meshes of the reticulum. The small blood-vessels and capillaries of the lymphoid tissue are usually filled with red cells and leukocytes, the large mononuclear form appearing to predominate. Throughout the reticulum there is usually present a varying amount of blood pigment, partly free and partly contained within large mononuclear phagocytes. Red cells in various stages of disintegration are also found in these cells. Scattered areas of a hyaline substance which stain pink with eosin, red with fuchsin, and blue with Mallory's reticulum stain are often found throughout the lymphoid tissue, but are most numerous toward the periphery of the gland. Small hyaline, highly refractile spherules of varying size, usually about the diameter of a red-blood cell, are frequently seen in small groups lying free in the reticular meshes and are also found in the mononuclear phagocytes. They stain intensely with eosin and fuchsin, retaining the latter with Mallory's reticulum stain. These hyaline bodies are evidently the products of the destruction of red-blood cells, as all stages of their formation can be found. They may contain iron, especially those found in the phagocytes, the reaction being absent from many of the free bodies. In some cases these spherules can be seen partly extruded from the phagocyte.

Reticulum.—The reticulum of the lymphoid areas resembles that of ordinary lymphatic glands. That of the blood-sinuses is much more abundant and of a coarser mesh-like structure than that of the lymph-sinuses of lymph glands. It differs from the reticulum of the spleen-pulp in the same respects. It stains blue with Mallory's reticulum stain, and consists of branching fibres and stellate or spindle-shaped cells arranged in a coarse mesh-work, the surfaces of which are covered with flattened endothelial cells. Small fibrillæ of yellow elastic tissue and occasional unstriped muscle-cells may be scattered through it. In its meshes there are found constantly large mononuclear phagocytes containing disintegrating red cells. These cells are always more abundant in the reticulum of the sinuses than in the lymphoid tissue. Under certain conditions they are so greatly increased in number as to almost entirely fill the spaces of the sinus. Normally their number in individual glands varies greatly, suggesting a possible cyclical function of hemolysis. Glands containing many of these cells may be found side by side with others whose reticular spaces contain but few. The same appearances are found in the hemolymph glands of the lower animals, particularly in those of the dog and rat. Multinuclear giant-

cells, eosinophile, basophile and mast-cells may at times be found also in the reticular meshes. The origin of the phagocytes has not yet been definitely determined; they may arise either from leukocytes or from the endothelial cells lining the reticulum.

Vascular System.—The exact manner of circulation in these glands has not yet been worked out, but it seems probable that the arteries entering the hilum quickly divide into small branches which, passing toward the periphery, empty into the blood-sinuses from which the blood is again gathered into veins which pass out at the hilum or obliquely through the capsule. As in the lower animals, there are great individual differences in the number and mode of branching of the blood-vessels. Occasionally the entering arteries pass along the trabeculæ and do not divide until near the periphery. In well-stained sections the course of the blood-sinuses and vessels is well shown by the blood contained in them which serves the purpose of an injection. The exact manner of communication between arterial and venous systems cannot, however, be made out by this means. Injections have not yet been attempted in the human subject, but in the lower animals they have been unsatisfactory. The circulation in the sinuses is of the type known as sinusoidal, only the endothelium separating the blood from the cells contained in the reticular meshes. The current in these spaces must be extremely slow and a long period of time must be required for the complete circulation through the intricate meshes of the reticulum crossing the sinuses.

In the splenolymph glands containing blood-sinuses throughout, afferent and efferent lymph vessels are not found, small lymphatics alone being present in the capsule. In glands of mixed type containing lymph-sinuses lymphatic vessels are also found. Whether there is any communication between the lymphatic and blood-systems in these glands remains yet to be shown. In the round masses of cells lymph-spaces or capillaries are probably present as in the splenic follicles, since under certain pathological conditions these may become edematous, the cells being separated by an accumulation of fluid in the intercellular spaces. These lymph spaces probably empty directly into the blood-sinuses and convey leukocytes into the circulation.

Varieties.—As already mentioned transition forms exist between the splenolymph glands and the spleen on one hand and ordinary lymphatic glands on the other. The significance of these intermediate forms is not yet apparent.

Development.—No work has yet been done on the development of these glands. They are present as fully-developed organs in the new-

born child, and have been found at an early period in the fetal calf. They are without doubt individual organs whose early stages of development are probably parallel with those of the lymph glands. Under certain pathological conditions it is possible that they may be developed from ordinary lymphatic glands or even in adipose tissue in compensation for the spleen or bone-marrow.

Function.—A discussion of the probable functions of these glands is beyond the limits of this paper. Briefly stated, it is probable that their function is chiefly one of hematolysis. The great variation in appearances in different glands suggests a cyclical function. They are also leukocyte-forming organs. Under normal conditions no evidences of red-blood cell formation have been discovered in them. It may also be possible that in the glands containing both blood and lymph-sinuses there is communication between the two systems and these glands may serve as the means of the return of lymph into the bloodstream. This supposition must, however, be regarded as purely hypothetical.

Differential Diagnosis.—To the inexperienced observer the hemolymph glands may at first be taken for deeply-congested or hemorrhagic lymph glands, even on microscopical examination. This mistake has probably occurred many times. The essential features of these glands as given above are, however, easily seen and, when once known, a glance at a section is sufficient for their recognition. The differences in reticulum, lymphoid tissue, sinuses, etc., together present a picture entirely distinct and characteristic from that of a congested or hemorrhagic lymph gland. Care in the treatment of the autopsy material, perfect fixation and good staining are points of technique which are of great service in the recognition of these organs.

MARROWLYMPH GLANDS.

The second form of hemolymph gland to which I have applied the designation of marrowlymph gland is of very much less frequent occurrence. They are much more prominent in certain pathological conditions than they are in the normal body, suggesting the possibility of resting glands or of new formations. In many cadavers I have been unable to find them, but this may have been due to a lack of time for a thorough examination. They have been found only in the retroperitoneal region, along the spine and brim of pelvis, always in close proximity to the large vessels, vena cava, abdominal aorta, adrenal and renal vessels and common iliacs. They are present most frequently

along the vertebræ behind the aorta or between it and the vena cava. These glands are flattened and long in proportion to their breadth, their greatest dimension lying parallel to the axis of the neighboring vessel. They may have a distinct hilum, but the number of vessels entering is not so great as in the case of the splenolymph glands. Lymph vessels may also be found in connection with these glands. The latter vary greatly in size, but are sometimes found as slender cylinders several centimeters long embedded in adipose tissue. They are white or pinkish in color with fine red lines corresponding to the blood-sinuses. Their consistence is very soft and on section they present an almost homogeneous surface.

They possess a thin capsule which contains but little unstriped muscle and yellow elastic tissue. Delicate trabeculæ run from this toward the centre of the gland. Beneath the capsule there is a blood-sinus of small size which usually runs entirely around the periphery and from this there are narrow branching sinuses accompanying the trabeculæ toward the centre of the gland. All of the sinuses are filled with a coarse reticulum through the meshes of which the blood circulates. Dilated sinuses like those of the splenolymph glands are not present. The course of the sinuses is shown by the lighter staining nuclei of the reticulum and by the presence of red-cells. Lymph sinuses are also present in some of these glands. Between the sinuses lies the lymphoid tissue arranged in irregular islands or lobules and is in much greater amount than in the splenolymph glands. Collections of cells resembling follicles are not found in the pure type of this gland. Throughout their central portions large numbers of fat cells are usually present.

The reticulum of the lymphoid tissue is more delicate and contains but little elastic tissue. The lymphoid areas are richer in cells and these present a much greater variety than in the splenolymph glands. Mononuclear eosinophiles and mast-cells are more numerous, and multinuclear as well as large mononuclear forms with deeply-stained knobbed nuclei also occur. Giant-cells resembling those of the bone-marrow are also occasionally found, and in certain pathological states of the blood may be very numerous. No nucleated red cells have been found in normal conditions. The lymphocytes and large mononuclears show a much greater diversity of form and staining power, and there is also a great variety of cells in the reticulum of the sinuses. Phagocytes containing red-cells pigment, fuchsinophile hyaline bodies and leukocytes occur to a much less extent than in the splenolymph glands. Red-

blood cells are found scattered throughout the reticulum of the lymphoid tissue.

Transition-forms between spleno- and marrowlymph glands are found and also between the latter and ordinary lymphatic glands. The function of the marrowlymph glands is not clear. They are evidently leukocyte-forming organs, and the presence of giant-cells and many mononuclear eosinophiles suggests the bone-marrow and the formation of red-cells. In certain forms of anemia and leukemia these glands are greatly enlarged and come to resemble the lymphoid marrow, containing nucleated red cells, neutrophile and eosinophile mononuclears, and many giant-cells exactly similar to those of the marrow. It can hardly be doubted that in these cases these glands are centres of red-cell formation perhaps compensatory for the marrow. Under normal conditions they may be in a resting state in so far as their function is concerned. Their part in hemolysis is much less marked than that of the splenolymph glands. In old age they become atrophic, their sinuses obliterated, large deposits of hyalin occur in them, and finally they cannot be distinguished from atrophic lymphatic glands. The study of these glands from the pathological side promises much more than from the normal.

SUMMARY.

Our conceptions of lymphoid tissue are greatly broadened by the study of the hemolymph glands. The intimate relations existing between the different organs of this class, the transition-forms, the possibility of compensation of function, etc., throw new and important light upon both histological and pathological problems. The various lymphoid organs might be compared as follows:

1. LYMPHOID MARROW :

- Hemal gland.
- Blood-forming function.
- Sinusoidal organ.
- Afferent and efferent blood-vessels.
- No afferent lymph-vessels.

2. HEMOLYMPH GLANDS :

- Hemolymph gland.
- Hemolytic function.
- Sinusoidal organ.
- Afferent and efferent blood-vessels.
- No afferent lymph-vessels.
- Efferent lymph-capillaries.

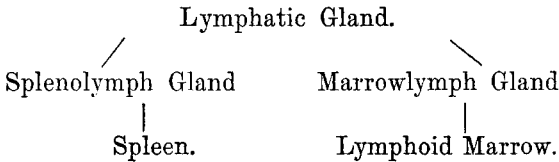
3. SPLEEN :

- Hemolymph gland.
- Hemolytic function.
- Sinusoidal organ.
- Afferent and efferent blood-vessels.
- No afferent lymph-vessels.
- Efferent lymph-capillaries.

4. LYMPHATIC GLAND :

- Lymph gland.
- Lymphatic function.
- Lymph-sinuses.
- No blood-sinuses.
- Lymph and blood-systems separate.

With respect to the relations between blood and lymphatic systems the red marrow might be considered the most primitive type of lymphoid structure, and the ordinary lymphatic gland the most highly developed, the hemolymph glands and spleen occupying intermediate positions. If viewed from a broader standpoint regarding both general structure and functions the relations of the organs might be theoretically represented in the following manner:



In conclusion, the field of the human hemolymph glands has barely been entered and its most important problems remain unsolved. Much is to be hoped from experimental work upon the lower animals in whom these glands are larger and more numerous than in man. Work along this line has already been begun in this laboratory.

NOTE.—The limits of this article have prevented me including in the brief review of the literature given above references to observations made on *lymph-glands with blood-containing sinuses* by a number of writers who apparently unaware of the existence of hemolymph glands interpreted their findings as hyperemic or hemorrhagic lymph-glands. Rindfleisch, Weigert, Neumann and Orth are among those who have made such observations. Especial attention is, however called to the article by Saltykow (*Ueber bluthältige Lymphdrüsen beim Menschen*, Zeitschr. f. Heilkunde, 1900). In an examination of 60 cadavers this

observer found blood-containing lymph-glands in 91.66% of the cases. Saltykow considered these glands to be only ordinary lymphatic glands in which there had been hemorrhage or a backward flow of blood into the lymph-vessels. Referring to the hemolymph glands as described by Gibbes, Robertson and Clarkson he concludes that these writers were in error in their assumption that these were glands *sui generis*. I have already pointed out the close resemblance between hemorrhagic lymph glands and hemolymph glands and some of the more important differential points between these structures. I regard Saltykow as being wholly in error in so far as his conclusions regarding the nature of these glands are concerned.

BIBLIOGRAPHY.

- CLARKSON.—*British Med. Jour.*, July 25, 1891.
——— *Text-book of Histology*, 1896.
DRUMMOND.—*Jour. of Anat. and Phys.*, 1900.
GIBBES.—*Microscopical Journal*, Vol. XXIV, 1884.
——— *Amer. Jour. of Med. Sciences*, 1893.
HABERER.—*Arch. f. Anat. u. Phys.*, March, 1901.
LEYDIG.—*Lehrbuch der Histologie d. Menschen u. d. Thiere*, 1857.
ROBERTSON.—*Lancet*, 1890.
VINCENT AND HARRISON.—*Jour. of Anat. and Phys.*, 1897.
WARTHIN.—*Jour. of the Bost. Soc. of Med. Sciences*, April, 1901.
——— *Jour. of Med. Research*, July, 1901.
WEIDENREICH.—*Arch. f. Mikr. Anatomie*, July, 1901.