

THE HISTOLOGY OF THE GASTRO-INTESTINAL
MUCOSA (RAT) AFTER ADRENALECTOMY
OR ADMINISTRATION OF ADRENO-
CORTICAL HORMONES ¹

BURTON L. BAKER AND RITA M. BRIDGMAN

Department of Anatomy, University of Michigan Medical School, Ann Arbor

THIRTY-EIGHT FIGURES

The capacity of hormones to carry out their functions is conditioned by many factors, one of the most important being the nutritional status of the animal. In well-planned endocrine experiments, care is exercised to ensure that the same amount of food is consumed by experimental and control animals. This is accomplished either by feeding measured quantities of food with a stomach tube or by determining the amount of food eaten by the experimental animal and presenting a like quantity to its control. It is unfortunate, however, that after food is introduced into the gastro-intestinal tract, little attention is given to the capacity of the mucosa to support digestion and absorption under conditions of hormonal deficiency or excess.

Certain studies have demonstrated that the adrenal cortex modifies the secretory activity of the stomach and the absorptive capacity of the intestine, but little is known of the manner in which these effects are reflected in the histology of the gastro-intestinal mucosa. Their importance is suggested by the pathology which may arise under extreme conditions of adrenocortical activity. Gastric ulcers are common

¹This investigation was supported (in part) by research grants from The National Institutes of Health, Public Health Service (A-131), and from The Upjohn Company.

in patients with Addison's disease who have severe gastrointestinal symptoms (Soffer, '48). Creation of a state of hyperadrenocorticalism by administration of corticotropin to human subjects may activate quiescent peptic ulcers (Smyth, '51) and cause duodenal ulcers to perforate (Habif et al., '50). No reports are available of the effect of adrenalectomy on the histology of the stomach. With respect to the intestine,

TABLE 1

Summary of experiments on adrenalectomy and complete starvation

EXP. NO.	SEX	NO. RATS	MANNER OF FEEDING	DRINKING FLUID	DURATION	MEAN BODY WEIGHT	
						Initial	Final
					<i>days</i>	<i>gm</i>	<i>gm</i>
I	E	2 ¹	Ad. lib. ¹	1% NaCl	33
	C	2 ¹	Ad. lib. ¹	H ₂ O	
II	E	11 ¹	Ad. lib. ¹	1% NaCl	19-23	255 ± 56 ²	290 ± 38
	C	11 ¹	Pr.-fed ¹	H ₂ O		260 ± 52	288 ± 38
III	E	3 ¹	Ad. lib. ¹	1% NaCl	43	305 ± 16	326 ± 25
	C	3 ¹	Pr.-fed ¹	H ₂ O		301 ± 14	325 ± 19
IV	E	9	Ad. lib.	H ₂ O	2-10	199 ± 12	197 ± 11
	C	9	Pr.-fed	H ₂ O		198 ± 14	192 ± 13
V	E	3	None	H ₂ O	3-6	193 ± 2	151 ± 12
	C	1	Ad. lib.	H ₂ O		192	205

E = adrenalectomized or starved rats. C = control rats. Ad. lib. = ad libitum. Pr.-fed = pair-fed.

¹ Rats were given no food for the 24 hours preceding autopsy.

² Standard deviation.

Tissières ('48) observed adrenalectomy to be without effect on alkaline phosphatase in the epithelium of the villi. According to Verne and Hébert ('49) this enzyme can no longer be detected by histochemical procedures after combined adrenalectomy and gonadectomy; it is restored by administration of sex steroids. Stenram ('51) emphasized that the apparent modification of alkaline phosphatase activity after adrenalectomy is dependent on the substrate and the pH maintained during incubation of the sections.

The purpose of this report is to describe the histology of the mucosa of the stomach, duodenum, and colon as modified by adrenalectomy or by the administration of large doses of cortisone or hydrocortisone to non-adrenalectomized rats.

MATERIALS AND METHODS

The number, sex and initial and final body weights of the animals used in each experiment are given in tables 1 and 2. The rats were adults of the Long-Evans or Sprague-Dawley strains. They were kept in individual cages and fed a diet consisting of Purina Laboratory Chow supplemented twice weekly with oranges, lettuce and a vitamin concentrate. Those used in experiments II to IV (table 1) and in the hormone administration experiments (table 2) were pair-fed, i.e., the amount of food consumed daily by each experimental rat was measured and a like quantity fed to its control on the succeeding day. In some instances, food was removed from the cage 24 hours before autopsy in order to reduce the amount of material in the lumen of the gastro-intestinal tract. Since food consumption is reduced by adrenalectomy, or by over-dosage with adrenocortical hormones, the histological changes induced were compared with those occurring in rats which were supplied with water only for three to 6 days (experiment V, table 1). Thus, the influence of variations in food intake on gastro-intestinal histology was controlled by pair-feeding in most experiments and, also, by comparison with the observations made in the starvation experiment.

Adrenalectomized rats excrete an excessive amount of sodium and accumulate potassium in the body fluids. Their survival is prolonged if 1% sodium chloride is given in the drinking fluid. Animals receiving salt remain in rather good physical condition, often showing an almost normal gain in body weight. In order to secure a more exact picture of the digestive tract as it exists when the body is subjected to all of the effects of adrenal insufficiency, some adrenalectomized rats (experiment IV) were given water without salt, care being taken to secure the tissues before death had occurred.

Several vehicles were used for the administration of cortisone and hydrocortisone (table 2) because Schneebeli, Dougherty and Loewe ('51) have shown that the suspending agents contained in Merck vehicle No. 1 affect the cells of fibro-elastic connective tissue. Certain aspects of their observations have been confirmed in this laboratory.

TABLE 2

Summary of experiments on administration of cortisone acetate or hydrocortisone

EXP. NO.	SEX	NO. RATS	SUBSTANCE INJECTED	DOSE DAILY	DURATION	MEAN BODY WEIGHT		
						Initial	Final	
VI	E	♂	8	Cort. acet. ¹	3	10	274 ± 30 ²	260 ± 18
	C	♂	8					
VII	E	♂	3	Cort. acet.	5	10	389 ± 22	371 ± 8
	C	♂	3					
VIII	E	♂	3	Cort. acet.	5	12	223 ± 14	199 ± 13
	C	♂	3					
IX	E	♂	6	Cort. acet.	5	21	269 ± 5	227 ± 2
	C	♂	6					
X	E	♂	4 ⁴	Hydrocortisone	5	10	298 ± 12	248 ± 6
	C	♂	4 ⁴					
XI	E	♂	4 ⁴	Hydrocortisone	4	10	323 ± 5	256 ± 20
	C	♂	4 ⁴					

E = hormone-injected rats. C = vehicle-injected controls.

¹ Cortisone acetate.

² Standard deviation.

³ Aqueous vehicle No. 1 of the Merck Company which contains sodium carboxymethylcellulose, sodium chloride, benzyl alcohol and Tween 80.

⁴ These rats were given no food for the 24 hours preceding autopsy.

Autopsy was performed either while the rats were under ether anesthesia or after they had been killed by a blow on the head. The stomach was incised along its greater curvature and freed of food material by rinsing in physiological saline. Strips of the wall, measuring about 15 mm × 4 mm, were cut parallel to the long axis. These pieces included small portions of the fore-stomach, fundus, and the transi-

tional region between the fundus and antrum (fig. 1). The antrum was cut into smaller longitudinal pieces. All samples were flattened out on cardboard and immersed in fixing fluids. Pieces of upper duodenum and lowermost part of the colon were placed directly into the fixative.

Zenker-formol and a fluid containing formalin, glacial acetic acid and 80% alcohol (FAA) in the proportions 1:1:18, respectively, were used routinely for fixation of a sample of each of the organs studied. The pieces preserved in Zenker-formol were sectioned at 3 to 5 μ , stained with the Altmann acid fuchsin-Masson procedure as modified by Severinghaus and Thompson ('39) for the hypophysis, and used primarily for the study of mitochondria. The samples fixed in FAA were stained with the Bodian ('37) protargol method for argentophile cells or the Hotchkiss ('48) periodic acid-leucofuchsin (PAS) procedure for polysaccharides. Some of these slides were counterstained with Harris' hematoxylin or methylene blue (pH 5.8, citric acid-disodium phosphate buffer) for observation of basophilia. Following the interpretation of Dawson ('48) the term "argentophile" will be applied to the silver-staining cells of the body of the stomach; "argyrophilic" will be applied to all other silver-staining cells described in the gastro-intestinal tract in the realization that they may be "argentaffin" cells.

Other specimens of each organ were fixed in chilled 80% alcohol and stained for alkaline phosphatase (Gomori, '39) with incubation ranging from 15 minutes to 24 hours. Samples fixed in formaldehyde-calcium were stained for phospholipids by the method of Baker ('46).

The effect of adrenocortical secretions on cellular proliferation was studied in the duodenum. Adult, female, Long-Evans rats were divided into groups of three, one of which was adrenalectomized; one, injected with 5 mg cortisone acetate² (1 cm³) daily; and the third, which served as a control, was injected with 1 cm³ of Merck's vehicle No. 1. The latter

² We wish to thank Dr. Elmer Alpert of Merck and Co. for the cortisone acetate, hydrocortisone and suspending vehicle.

material served as a suspending medium for the cortisone acetate. In each group, food intake was restricted to that of the rat consuming the least each day. On the 6th day each rat received an intraperitoneal injection of 0.2 mg colchicine in 1 cm³ of distilled water at 9:00 A.M. with autopsy being performed at 5: P.M. The samples of duodenum were fixed in Bouin's fluid and stained with iron hematoxylin and Masson. The percentage of cells in mitosis was determined from counting the number of mitotic figures and nuclei of epithelial cells lining the crypts of Lieberkühn in every 5th section until a minimum of 1,000 cells per rat was obtained. Counts were made only in crypts which were sectioned sagittally and showed a lumen extending from the base to or near the opening of the gland. Since no change in size of the epithelial cells was observed after adrenalectomy or administration of adrenocortical hormones, it was unnecessary to correct for error resulting from variation in the number of nuclei contained in a section due to alteration in cellular size.

OBSERVATIONS

The stomach

Normal anatomy. The gross anatomy of the stomach of the rat has been described by Berg ('42). It is subdivided into two major portions, the fore-stomach and the glandular stomach (fig. 1). A cardiac region characterized by a glandular mucosa is not present in the immediate area of the esophageal opening. The fundus composes the major part of the glandular stomach and its mucosa presents a ruddy color in the freshly opened organ. The antrum extends farther cephalically on the lesser than on the greater curvature of the stomach. In the living state, its mucosa is pale in color.

The mucosa of the esophagus is continuous with and histologically similar to that of the fore-stomach. The latter region is lined with stratified squamous epithelium and its lamina propria is thin except at the junction with the glandular stomach where it is thickened to form a prominent transverse

ridge (fig. 2). The fibro-elastic connective tissue in this location stains intensely with periodic acid-leucofuchsin (PAS) and alkaline phosphatase is present in the walls of the abundant capillaries which are located just beneath the epithelium. With the substrate and incubation times used, this is the only site in the stomach where alkaline phosphatase was found.

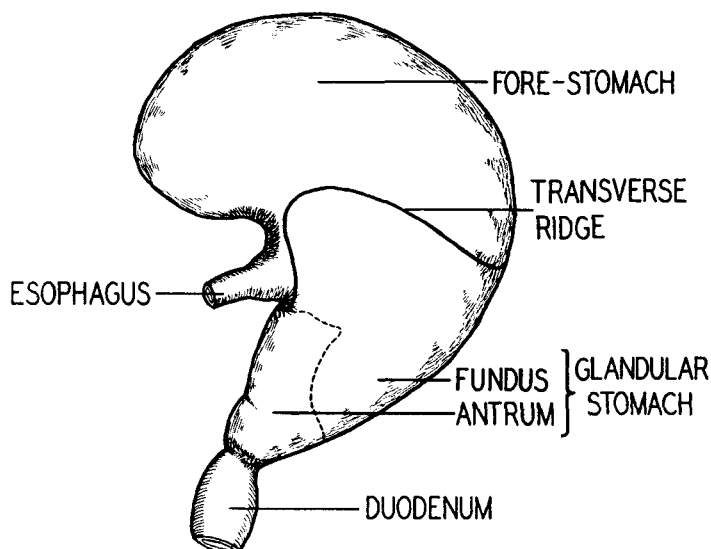


Fig. 1 Anatomy of the stomach of the rat

On the caudal side of the ridge, the stratified squamous epithelium becomes thinner and changes abruptly to the simple columnar epithelium of the glandular stomach.

Simple columnar mucus-producing cells line the glandular stomach and gastric pits. Some aspects of their cytology have been described by Stevens and Leblond ('53) who report that these cells arise by mitotic proliferation in the isthmus of the glands and move along the walls of the pits toward the free surface. They further describe the accumulation of mucus within the cells during this shift in position. After staining with PAS and methylene blue, the early stages in the formation of mucus are particularly clear in our material,

especially in the cells at the bottom of the pits and in the isthmus of the glands. Mucus first appears close to the nucleus, either on the apical or lateral sides (fig. 25). It may be in the form of a network which probably coincides in outline with the Golgi apparatus. Apical to this region are particles of mucus which become densely packed just beneath the free surface of the cell. The amount of intra-cellular mucus increases toward the openings of the pits into the gastric lumen. The cytoplasm of the mucus-producing cells is faintly basophilic. Mitochondria are distributed throughout the cytoplasm, collecting into dense aggregations just beneath the apical mass of mucus and frequently being scattered throughout the mucus itself.

Cardiac glands are present at the junction of fore-stomach and glandular stomach in all samples removed from the greater curvature or the dorsal and ventral surfaces, indicating that a narrow band of them is always present on the caudal side of the transverse ridge (fig. 2). These are the only cardiac glands present and do not extend over a considerable area near the opening of the esophagus into the fore-stomach as outlined by Blank ('50) for the cotton rat.

The gastric pits, into which the cardiac glands open, extend about half-way to the muscularis mucosae. The glands are tubular and coiled (fig. 2). Their cells contain mucus which accumulates at the apical surface and has a foamy appearance after staining of FAA-fixed material with periodic acid-leucofuchsin. Some cells are vacuolated extensively after fixation in aqueous fluids such as Zenker-formol; they are poor in mitochondria and cytoplasmic basophilia. Argyrophilic cells are found rarely in the cardiac glands.

The transition from the cardiac to the fundic glands of the fundus of the stomach is rather abrupt (fig. 2). The varied histological procedures used in our study make it possible to supplement the cytological description of fundic glands by Stevens and Leblond ('53) which was based only on staining with PAS and hematoxylin. Throughout most of the body of the stomach, *mucous neck cells* are scattered among parietal

cells in the neck of the fundic gland. They are compressed laterally by the adjacent parietal cells with the secretion-filled apical portion bulging into the glandular lumen. When stained with PAS the intra-cellular secretion is disposed in a foamy pattern. The mucoid material produced by mucous neck cells appears to be chemically different from that contained in the columnar cells of the foveolae and mucosal surface. In the neck cells it is not demonstrated by fixation in Zenker-formol and staining with the Masson procedure, the cytoplasm appearing vacuolated; in contrast, the mucus of the epithelium lining the foveolae is preserved and stained blue. The cytoplasm of the neck cells is faintly basophilic and contains a few coarse rod-like mitochondria.

The large *parietal cells* are most numerous in the neck but scattered ones may be found in the isthmus and base of the fundic glands. An occasional cell appears in the lining of the deeper portion of the gastric pits where it is usually degenerating and being extruded into the lumen. Although devoid of PAS-staining material and cytoplasmic basophilia, parietal cells contain a large number of bodies which resemble mitochondria in staining with acid fuchsin after chromation (fig. 16). They differ greatly from the mitochondria of most animal cells in their large size and spheroidal shape. Scattered among these granules are rod-like and filamentous mitochondria. The mitochondria may be straight or curved. Black bodies which appear to be identical to the fuchsinophilic granules and mitochondria are revealed by the Baker technique for phospholipids. Canaliculi and the negative image of the Golgi apparatus are delineated clearly.

The *chief* or *zymogenic* cells are the predominant cell type in the base of the gland and extend also into the neck. Pepsinogen granules were not stained clearly by any of our procedures. In the bases of the glands their number and position is indicated by vacuolation of the cytoplasm (fig. 6). After subjecting Zenker-formol-fixed specimens to the Altman-Masson procedure, the vacuoles in the cells of the neck region contain faintly stained granules. On this basis, chief

cells are differentiated sharply from mucous neck cells whose cytoplasmic vacuoles are empty. The quantity of granules and size of the chief cells are greatest in the deepest part of the gland and decline progressively at more superficial levels of the mucosa. Their cytoplasm is generally basophilic. This reaction is especially marked in the subnuclear region due to the presence of large amounts of ribonucleic acid in the cytoplasm (Dempsey and Wislocki, '46). The mitochondria are coarse rods and are found throughout the cytoplasm. Many are arranged along the cellular membrane, especially in those cells which are filled with zymogen granules.

In preparations stained with protargol, *argentophile* cells are most numerous in the basal region of the fundic glands but extend in decreasing numbers into the neck (fig. 12). This observation agrees with that of Dawson ('48). On the basis of number and distribution they are remarkably similar to distinctive cells which appear in preparations fixed in Zenker-formol and stained with the Altmann-Masson procedure. These cells are located next to the basement membrane of the gland and are irregularly ovoid in shape (fig. 11, insert). Their cytoplasm is sparse, negative to PAS and frequently consists of only a few indistinct strands in the region of the cyto-centrum. Mitochondria are granular, few in number, and located chiefly in the perinuclear area.

The gastric pits associated with pyloric glands of the antrum are as deep as those into which the cardiac glands open. The cytology of their epithelium is similar to that described for the foveolae of the body of the stomach. The pyloric glands are short, tubular, straight and lined by simple columnar epithelium (fig. 21). At the base of the gland the cytoplasm of the epithelial cells shows little basophilia, whereas at the body and isthmus it stains more intensely with methylene blue (fig. 28). Rapid mitotic proliferation occurs in the latter region. As demonstrated by staining with PAS, the apical cytoplasm contains mucoid material which is disposed in a foamy pattern. Only a few mitochondria are present.

Argyrophilic cells are sparse as compared with the number found in the fundus of the stomach.

The longitudinal sections of the stomach which extend from fore-stomach to antrum make possible a study of the relationships of the cells which secrete mucoid substances. After staining with PAS, the mucous neck cells form a distinctive band through the mucosa which, in the region of fundic glands, is relatively near the surface (fig. 2). Toward the junction with the fore-stomach, this band is located relatively deeper in the mucosa (fig. 2) and becomes directly continuous with the cells of the cardiac glands. In the transitional region between the fundus and antrum, the band of mucous neck cells also gradually becomes situated closer to the muscularis mucosae, coincident with the dropping out of parietal and zymogenic cells (fig. 4). Ultimately, the band of mucous neck cells becomes continuous with the epithelial cells of the pyloric glands. The mucous neck cells and cells of the pyloric and cardiac glands are similar as to the disposition of the mucus within the cell. In each site, the mucoid material in the apical portion of the cell possesses a foamy pattern when studied with PAS staining. The epithelium of the cardiac and pyloric glands possesses very little basophilia and few mitochondria. The mucous neck cells are slightly more basophilic and contain more prominent mitochondria.

The effects of adrenalectomy. Significant changes were not observed in the epithelium or lamina propria of the fore-stomach excepting at the transverse ridge. Here a reduction in alkaline phosphatase was observed in adrenalectomized rats maintained on salt. Alkaline phosphatase was not studied in this region in the other groups. The staining of the connective tissue with PAS was not modified significantly (fig. 3).

Adrenalectomy reduced only slightly the size of the epithelial cells on the surface and in the pits. However, less mucus was present in the lumen of the pits and, also, within the epithelial cells (figs. 2-5). The degree of change was variable but occurred in both the adrenalectomized rats which were maintained on salt solution and in those which were not.

Even though these observations suggest that the secretion of mucus was suppressed, its continued elaboration was indicated by the presence of some mucus in both the apical portion of the cell and in the region of the Golgi apparatus (fig. 24). There were no consistent changes in the mitochondria. These observations apply particularly to the pits associated with fundic and pyloric glands and were not ascertained in our material for those into which the cardiac glands open. The only change which occurred in the cardiac glands was a reduction in the amount of mucoid material contained in the epithelium of rats maintained on saline or water as a drinking fluid (fig. 3).

The fundic glands were modified more significantly by adrenalectomy. When the operated animals were maintained on salt, the mucous neck cells were either unchanged or possessed less mucus. However, without addition of salt to the drinking fluid, there occurred a marked reduction in size of the cells and in their mucus content (fig. 5). Otherwise, the neck cells were histologically normal.

The zymogenic cells were affected more by adrenalectomy than any other type of cell studied in the gastric mucosa. They were reduced markedly in size and granular content and contained much less basophilic material, especially in the subnuclear region (figs. 6, 7). Usually, fewer mitochondria were present. These modifications seemed to be somewhat more intense if the adrenalectomized rats were not given salt water. Parietal cells showed little change (figs. 16, 17) except for a slight reduction in size and increased concentration of the fuchsinophilic bodies in some cells. No effect was observed after staining with the Baker's acid hematein, but this could have been obscured by the erratic staining which characterizes this procedure. Adrenalectomy usually did not change argentophile cells (fig. 13) but in some cases their granulation was reduced, especially if the rats were not given salt (fig. 14). No changes were observed in them after fixation in Zenker-formol and staining with the Altmann-Masson procedure.

The epithelium of the pyloric glands frequently contained less mucoid material, but the degree of change varied considerably in different animals (fig. 21). Cytoplasmic basophilia, the frequency of mitotic figures and the incidence of argyrophilic cells were not altered.

The effects of hormone administration. No histological modifications were observed in the stratified squamous epithelium of the fore-stomach or in the lamina propria at the horizontal ridge. Similarly, cardiac glands remained unchanged.

Following the injection of cortisone or hydrocortisone the amount of mucus was reduced on the surface of the mucosa, within the lumina of the gastric pits, and in the epithelium of these regions (fig. 9). The constituent cells were smaller but their mitochondria continued to be numerous and brilliantly stained. The magnitude of the effect varied and was greatest in those animals which received cortisone acetate for 21 days. However, the continued synthesis of mucus was indicated by the presence of material staining with PAS in the apical cytoplasm and Golgi region of the epithelial cells lining the foveolae. Similarly the amount of secretion in the mucous neck cells was reduced greatly (figs 8, 9). With the exception of this effect and a concurrent reduction in size, mucous neck cells were normal.

Several observations indicated that the relative number of zymogenic cells was increased by injection of the hormones. They frequently extended proportionately higher into the mucosa than in the control animals (figs. 8, 9). Also, in the bases of the fundic glands, the ratio of zymogenic cells to parietal cells was higher after treatment with the hormones. The effect on size was irregular, in most cases the cells being smaller and containing fewer apical granules. Basophilia was increased especially in the basal portion of the cell. This observation was supported by staining of Zenker-formol-fixed material with the Altmann-Masson procedure, which revealed the comparable "basal ergastoplasm" to be more prominent (figs. 10, 11). In general, the nuclei were larger, contained

larger nucleoli and occupied a higher position in the cell. Mitochondria were not modified. These changes were present after hormonal treatment for 10 or 21 days.

Parietal cells frequently appeared to be reduced in number and many were smaller after injection of adrenocortical hormones. However, the small parietal cells were well-filled with fuchsinophilic granules even though the number of granules per cell was less (figs. 18, 19). The granules which remained were, on the average, larger than those in the larger parietal cells of the same section or those in the control rats. This change was more striking after 21 days of treatment than after 10 days. Mitochondria were found in most cells and alteration in frequency of their occurrence could not be ascertained. Argentophile cells remained unaltered.

Under the conditions of these experiments, adrenocortical hormones failed to modify the parenchyma of the mucosa in the antrum. Unchanged were the size of the epithelial cells lining the pits and glands, cytoplasmic basophilia, number of argyrophilic cells (fig. 15) and apparent frequency of mitotic figures. In general, the amount of mucoid substance contained within epithelial cells remained about the same although in a few instances it was reduced (fig. 23).

The duodenum

The effects of adrenalectomy. Adrenalectomy, with and without maintenance on salt, modified only slightly the topography of the duodenum. Villi, which in the controls were high and narrow, became low and broad. The epithelium covering their apices more commonly showed post-fixation distortion. In some areas the width of the glandular portion of the mucosa was reduced moderately after adrenalectomy with the glands being somewhat more shallow. Their total size was not different from that of the controls.

The columnar absorbing cells of the villous epithelium retained approximately the same size as those of the controls and their cytoplasmic basophilia was unchanged. In the con-

trols, mitochondria were aggregated into dense subnuclear masses. In the apical cytoplasm they were long, thick filaments and arranged parallel to the long axis of the cell. Adrenalectomy induced an inconsistent reduction in number of mitochondria. The striated border stained less intensely with PAS. Alkaline phosphatase activity was usually reduced, especially in the long-term adrenalectomized rats maintained on salt (figs. 33, 34) and after survival for 6 to 10 days in those given water only. Goblet cells in the villous epithelium were smaller and contained less mucus as shown by staining with the Masson procedure after Zenker-formol fixation and by the periodic acid-leucofuchsin procedure. The population of plasma cells, eosinophiles, globular leucocytes and lymphoid cells in the connective tissue core did not vary significantly.

There was no consistent change in size of the epithelial cells lining the crypts or in their basophilia. If the mucous content of the goblet cells on the villi was reduced by adrenalectomy, those in the crypts also shared in this depletion. Paneth cells were changed more by adrenalectomy than any other type of cell observed in the intestine. In the controls they were pyramidal, narrow and, after fixation in Zenker-formol, contained very few serous granules (fig. 27). The supranuclear cytoplasm stained faintly with PAS and usually contained one or more large vacuoles (fig. 29). Following adrenalectomy, Paneth cells were enlarged several times and filled with large spherical granules which stained with either aniline blue or acid fuchsin (fig. 26). Staining with PAS was intensified and sparse small deep purple granules of glycogen appeared in the cytoplasm (fig. 30). These changes were striking in the adrenalectomized rats maintained on salt for 21 days and were clearly present 6 days after the operation without maintenance on salt. Argrophilic cells were exceedingly scarce in the duodenum of the controls and no variation in their structure or number was detected after adrenalectomy.

The effects of hormone administration. The injection of cortisone induced no significant changes in the topography

of the duodenum, or in the size and form of the villi and crypts of Lieberkühn. In the epithelium covering the villi, the size of the columnar absorbing cells, their basophilia, number of mitochondria and alkaline phosphatase were unchanged. However, the number of cells in the connective tissue of the villi was reduced by both hormones after all periods of treatment. This reduction involved chiefly the globular leucocytes (Kent, Baker and Ingle, unpublished) and lymphocytes although the number of the latter cells which had invaded the simple columnar epithelium of the surface was

TABLE 3

The effect of adrenalectomy or administration of cortisone on mitotic activity in the duodenum

TREATMENT	NO. RATS	PER CENT MITOTIC FIGURES	P ¹
Adrenalectomy	9	15.97 ± 2.7 ²	> .05
Cortisone acetate	11	15.84 ± 3.7	> .05
Control	11	20.68 ± 7.0	

¹ Difference between the means, comparing each experimental group with the control group. Behrens-Fisher test.

² Standard deviation.

about the same as in the controls. Plasma cells remained numerous after treatment.

In the epithelium lining the crypts of Lieberkühn, basophilia was usually unchanged. The Paneth cells were enlarged and contained more granules after administration of cortisone acetate for 21 days but not after treatment with this compound or hydrocortisone for 10 to 12 days. The degree of this effect was much less than that induced by adrenalectomy.

Considering the total mucosa, the amount of mucus contained in the goblet cells was reduced moderately after all periods of treatment (figs. 31, 32). No changes were present in the sparsely scattered argyrophilic cells.

Mitotic activity. Adrenalectomy and treatment with cortisone acetate reduced the number of mitotic figures seen in

the crypts of Lieberkühn (table 3). This change was not statistically significant.

The colon

Effects of adrenalectomy and hormone administration. Adrenalectomy or administration of adrenocortical hormones failed to induce major changes in the histology of the colon. Size of epithelial cells and of glands, the concentration of argyrophilic cells, the intensity of basophilia and quantity of mitochondria in epithelia were not altered. The quantity of mucus contained in the goblet cells was usually comparable with that in the controls (figs. 35-38) but in some cases was reduced. This change was limited frequently to only certain crypts in individual cross-sections. The number of cells in the mucosal connective tissue was reduced slightly by hormonal treatment. The leucocytes were the only component which exhibited significant alkaline phosphatase activity and fewer of them were seen in the connective tissue after injection of hormones.

Comparison with the effects of complete starvation

Comparison of the major histological changes which occurred in experimental hypo- and hyperadrenocorticalism with those resulting from complete starvation is desirable in order to further exclude reduced food intake as being a modifying factor. Three previous observations merit consideration in this connection: (a) involution of the zymogenic cells of the stomach after adrenalectomy and their stimulation by administration of adrenocortical hormones, (b) enlargement and increased granulation of the Paneth cells after adrenalectomy, and (c) the tendency for both adrenalectomy and hormone administration to reduce the mucus content of cells which produce it.

Complete starvation affected the zymogenic cells of the stomach in a different manner from adrenocortical deficiency or excess. The cells were of about the same size as in the

controls and were engorged with pepsinogen granules. After three days of starvation, the basophilia, which is due to the presence of ribonucleic acid in the cytoplasm, was reduced slightly. After 6 days it was diminished markedly. Thus, there was loss of cytoplasmic ribonucleic acid without general cellular involution, in both respects being different from the effects induced by adrenocortical hormone administration. Only in the loss of basophilia is there similarity to the changes which occurred after adrenalectomy.

Complete starvation caused an increase in size of the Paneth cells and in their serous granulation, in one case after 6 days this change being comparable to that seen after adrenalectomy.

Complete starvation exerted variable effects on mucus-producing cells. Mucous neck cells of the stomach were unaltered and in two of three cases there was no reduction in the amount of mucus present in the epithelial cells lining the stomach and gastric pits. The goblet cells of the duodenum and colon showed variable change, in some cases the mucus being reduced to a moderate degree comparable with that in the adrenocortical experiments.

In summary, it appears that reduction in food intake may have been a factor in inducing the changes observed in the Paneth cells and in some of the mucus producing cells in the experiments dealing with the adrenal cortex. However, the zymogenic cells of the stomach reacted in a unique manner which suggests that adrenocortical secretions play a specific role in maintaining their normal secretory state.

DISCUSSION

The cytological changes observed in the zymogenic cells of the stomach indicate that their secretory activity is suppressed by adrenalectomy and accelerated by administration of cortisone or hydrocortisone. In addition to loss of cellular and nuclear size and of apical granulation after adrenalectomy, the depletion of cytoplasmic ribonucleic acid is of particular

importance. This substance plays an important role in the synthesis of protein (Mirsky, '43; Greenstein, '44) and reduction in the amount present, as revealed by basophilic staining, might be expected to accompany an impaired capacity to secrete pepsin. Likewise, injection of adrenocortical hormones enlarged the nuclei and nucleoli of zymogenic cells and increased the amount of ribonucleic acid. Nucleolar enlargement is a frequent accompaniment of accelerated secretory activity in glandular cells. Because nucleoli are rich in ribonucleic acid, they are thought by some to be synthetic centers for this material. The reduced size of the zymogenic cells following hormone administration resulted primarily from their degranulation. This probably accompanied the liberation of secretion.

These cytological observations agree with available biochemical data. Tuerkischer and Wertheimer ('45) found that the gastric juice secreted in adrenalectomized rats under the influence of the cholinergic drug, carbamylcholine chloride (Doryl), was low in pepsin activity. Abrams and Baker (unpublished) have confirmed this observation in the adrenalectomized, pylorus-ligated rat using an improved method for the determination of pepsin activity. Concurrently a profound reduction in total volume of the gastric juice occurs (Madden and Ramsburg, '51).

Administration of adrenocortical hormones increases the secretory activity of the zymogenic cells. In the experiments of Tuerkischer and Wertheimer ('45) adrenocortical extract restored their secretory activity to normal in adrenalectomized rats but administration of NaCl or desoxycorticosterone* acetate failed to do so. In man, the secretory rate of the zymogenic cells may be evaluated by determining the amount of uropepsin excreted. This substance appears to be the form in which pepsinogen is excreted after it has been secreted into the blood stream by the zymogenic cells. The excretion of uropepsin is high in Cushing's disease and after administration of corticotropin or cortisone (Gray et al., '51) and is

low in Addison's disease (Gray et al., '52). The peptic activity of gastric juice is increased also by corticotropin.

Retardation in the rate of body growth is a well-recognized sequel to adrenalectomy in experimental animals (Hartman and Thorn, '30). Depression of appetite and generalized metabolic disturbances are usually held accountable for this effect. The demonstration that adrenocortical secretions are essential to normal production of pepsin or pepsinogen by zymogenic cells of the stomach suggests that defective digestion of protein in the hypoadrenocortical state is probably of some importance also.

The relationship of the adrenal cortex to secretion of hydrochloric acid by the parietal cells is less clear. Depletion of fuchsinophilic granules is said not to accompany accelerated secretion (Plenk, '32). In our study, they were not altered greatly by either adrenalectomy or hormone administration. Biochemical data published by others are in disagreement with respect to the action of adrenocortical hormones on secretion of hydrochloric acid. According to Tuerkischer and Wertheimer ('45) the acidity of gastric juice produced in adrenalectomized rats under the influence of Doryl is reduced. Madden and Ramsburg ('51) observed no change in the pylorus-ligated, adrenalectomized rat. The marked achlorhydria of Addison's disease is well-known. Administration of corticotropin to experimental animals (Zubiran, Kark and Dragstedt, '52) and to man (Gray, Benson, Reifenstein and Spiro, '51; Porter, Longmire and French, '53) increases gastric acidity. However, direct application of desoxycorticosterone or cortisone to the mucosa of mouse stomach *in vitro* fails to stimulate secretion (Davenport and Chavré, '50). It appears probable that any effects exerted on parietal cells by the adrenocortical hormones may be secondary to alterations in electrolyte and water metabolism.

With the exceptions cited, and with considerable variation in degree, both adrenalectomy and over-dosage with adrenocortical hormones reduced the amount of mucoid substances found within the various types of cells which produce it in the

stomach, duodenum and colon. This observation probably indicates that the rate of mucus secretion is suppressed. Several factors, therefore, appear to be involved in the etiology of ulceration which frequently follows administration of corticotropin or adrenocortical steroids. These hormones appear capable of stimulating an increased output of gastric juice which is rich in pepsin and hydrochloric acid at a time when the protection afforded the mucosa by the mechanical and neutralizing action of mucus is reduced. In addition, the well-known inhibitory action of over-dosage with adrenocortical steroids on proliferation of fibro-elastic connective tissue in the healing of wounds is probably operative in retarding the repair of any small ulcers which may develop.

Adrenalectomy interferes with the absorption of glucose (Soulaïrac, '46), fat (Bavetta, Hallman, Deuel and Greeley, '41) and chloride (Clark, '39). Concurrent administration of NaCl to adrenalectomized rats restores the rate of intestinal absorption of glucose (Althausen, Anderson and Stockholm, '39). Although the mild reduction in alkaline phosphatase in the epithelium covering villi which occurs after adrenalectomy may be a factor, no other histological changes were observed which might account for defective absorption by the intestine.

The failure of administration of adrenocortical hormones to suppress mitotic proliferation and reduce the size of epithelial cells in the duodenum marks the intestine as being comparatively resistant to the catabolic of these hormones on protein. Administration of excessive amounts of corticotropin or cortisone suppresses proliferation of many other tissues including the hair bulbs, epidermis (Baker, '51; Baker and Whitaker, '48), cartilage and bone (Becks, Simpson, Li and Evans, '44; Baker and Ingle, '48), fibro-elastic connective tissue in the healing of wounds (Baker and Whitaker, '50; Alrich, Carter and Lehman, '51), and lymphoid organs (Baker, Ingle and Li, '51). When nitrogen is lost from the carcass due to over-dosage with cortisone, it is increased in the gastro-intestinal tract (Silber and Porter, '53). Similarly, incorporation of cystine-S³⁵ into the protein of heart, liver,

kidney and spleen is diminished by adrenalectomy and restored by cortisone but in the intestine is not affected by either form of treatment (Lee and Williams, '52).

SUMMARY

Following adrenalectomy, the zymogenic cells of the stomach were smaller, degranulated and possessed less cytoplasmic basophilia. With the injection of cortisone or hydrocortisone to non-adrenalectomized rats, their nuclei and nucleoli were enlarged, cytoplasmic basophilia was increased and the number of pepsinogen granules reduced. These observations agree with biochemical data which show that adrenocortical hormones may stimulate the secretion of pepsin by zymogenic cells. Parietal cells showed less structural change. The amount of mucus contained within the mucous neck cells was reduced by injection of adrenocortical hormones and by adrenalectomy if the animals were not maintained on NaCl drinking solution.

The size and granulation of duodenal Paneth cells was increased greatly by adrenalectomy and to a lesser extent by adrenocortical hormone administration. A small but statistically insignificant reduction in mitotic activity in the crypts of Lieberkühn occurred after adrenalectomy or injection of cortisone acetate. Alkaline phosphatase was reduced slightly by adrenalectomy. The colon showed only minor changes after adrenalectomy or hormone injection. Considering all organs studied and both types of experimental procedure, argyrophilic cells showed little change and intracellular mucoid substances tended to be reduced in amount.

LITERATURE CITED

- ALRICH, E. M., J. P. CARTER AND E. P. LEHMAN 1951 The effect of ACTH and cortisone on wound healing. An experimental study. *Ann. Surg.*, 133: 783-789.
- ALTHAUSEN, T. L., E. M. ANDERSON AND M. STOCKHOLM 1939 Effect of adrenalectomy and of NaCl on intestinal absorption of dextrose. *Proc. Soc. Exp. Biol. and Med.*, 40: 342-344.

- BAKER, B. L. 1950 Modification of body structure by adrenocortical secretions with special reference to the regulation of growth. Pituitary-Adrenal Function, A.A.A.S., Washington.
- 1951 The relationship of the adrenal, thyroid and pituitary glands to the growth of hair. *Ann. N. Y. Acad. Sci.*, 53: 690-707.
- BAKER, B. L., AND D. J. INGLE 1948 Growth inhibition in bone and bone marrow following treatment with adrenocorticotropin (ACTH). *Endocrinology*, 43: 422-429.
- BAKER, B. L., D. J. INGLE AND C. H. LI 1951 The histology of the lymphoid organs of rats treated with adrenocorticotropin. *Am. J. Anat.*, 88: 313-349.
- BAKER, B. L., AND W. L. WHITAKER 1948 Growth inhibition in the skin following direct application of adrenal cortical preparations. *Anat. Rec.*, 102: 333-347.
- 1950 Interference with wound healing by the local action of adrenocortical steroids. *Endocrinology*, 46: 544-551.
- BAKER, J. R. 1946 The histochemical recognition of lipine. *Quart. J. Micr. Sci.*, 87: 441-471.
- BAVETTA, L., L. HALLMAN, H. J. DEUEL AND P. O. GREELEY 1941 The effect of adrenalectomy on fat absorption. *Am. J. Physiol.*, 134: 619-622.
- BECKS, H., M. E. SIMPSON, C. H. LI AND H. M. EVANS 1944 Effects of adrenocorticotropic hormone (ACTH) on the osseous system in normal rats. *Endocrinology*, 34: 305-310.
- BERG, B. N. 1942 Pathological changes in nutritional gastritis in rats. *Am. J. Path.*, 18: 49-61.
- BLANK, O. E. 1950 A histological study of the alimentary canal of the cotton rat, *Sigmodon hispidus*. *Anat. Rec.*, 108: 421-440.
- BODIAN, D. 1937 The staining of paraffin sections of nervous tissues with activated protargol. Role of fixatives. *Anat. Rec.*, 69: 153-162.
- CLARK, W. G. 1939 Effect of adrenalectomy upon intestinal absorption of sodium chloride. *Proc. Soc. Exp. Biol. and Med.*, 40: 468-470.
- DAVENPORT, H. W., AND V. J. CHAVRÉ 1950 The lack of effect of the adrenal hormones upon gastric acid secretion. *Endocrinology*, 47: 193-197.
- DAWSON, A. B. 1948 Argentophile and argentaffin cells in the gastric mucosa of the rat. *Anat. Rec.*, 100: 319-329.
- DEMPSEY, E. W., AND G. B. WISLOCKI 1946 Histochemical contributions to physiology. *Physiol. Rev.*, 26: 1-27.
- GOMORI, G. 1939 Microtechnical demonstration of phosphatase in tissue sections. *Proc. Soc. Exp. Biol. and Med.*, 42: 23-26.
- GRAY, S. J., J. A. BENSON, JR., R. W. REIFENSTEIN AND C. M. RAMSEY 1952 The stomach as an endocrine-like organ. Factors influencing urinary uropepsin excretion. *J. Clin. Invest.*, 31: 633-634.
- GRAY, S. J., J. A. BENSON, JR., R. W. REIFENSTEIN AND H. M. SPIRO 1951 Chronic stress and peptic ulcer. I. Effect of corticotropin (ACTH) and cortisone on gastric secretion. *J. Am. Med. Assn.*, 147: 1529-1537.
- GREENSTEIN, J. P. 1944 Nucleoproteins. *Advances in Protein Chemistry*, 1: 209-287.

- HABIF, D. V., C. C. HARE AND G. H. GLASER 1950 Perforated duodenal ulcer associated with pituitary adrenocorticotrophic hormone (ACTH) therapy. *J. Am. Med. Assn.*, *144*: 996.
- HARTMAN, F. A., AND G. W. THORN 1930 A biological method for the assay of cortin. *Proc. Soc. Exp. Biol. and Med.*, *28*: 94-95.
- HOTCHKISS, R. D. 1948 A microchemical reaction resulting in the staining of polysaccharide structures in fixed tissue preparations. *Arch. Biochem.*, *16*: 131-141.
- LEE, N. D., AND R. H. WILLIAMS 1952 The role of the pituitary-adrenal system in cystine-S³⁵ incorporation into protein. *Endocrinology*, *51*: 451-456.
- MADDEN, R. J., AND H. H. RAMSBURG 1951 Adrenalectomy in the Shay rat. *Gastroenter.*, *18*: 128-134.
- MIRSKY, A. E. 1943 Chromosomes and nucleoproteins. *Advances in Enzymology*, *3*: 1-34.
- PLENK, H. 1932 *Der Magen*. *Handb. der Mikr. Anat. des Menschen*. Ed. by W. von Möllendorf. Springer, Berlin. V/2, Part II.
- PORTER, R. W., R. L. LONGMIRE AND J. D. FRENCH 1953 Neurohumoral influence on gastric hydrochloric acid secretion. *Fed. Proc.*, *12*: 110.
- SCHNEEBELL, G. L., T. F. DOUGHERTY AND S. LOEWE 1951 Production of cytoplasmic azurophilic inclusions in connective tissue cells by suspending agents. *Proc. Soc. Exp. Biol. and Med.*, *77*: 407-411.
- SEVERINGHAUS, A. E., AND K. W. THOMPSON 1939 Cytological changes induced in the hypophysis by the prolonged administration of pituitary extract. *Am. J. Path.*, *15*: 391-412.
- SILBER, R. H., AND C. C. PORTER 1953 Nitrogen balance, liver protein repletion and body composition of cortisone-treated rats. *Endocrinology*, *52*: 518-525.
- SMYTH, G. A. 1951 Activation of peptic ulcer during pituitary adrenocorticotrophic hormone therapy. Report of three cases. *J. Am. Med. Assn.*, *145*: 474-477.
- SOFFER, L. J. 1948 *Diseases of the Adrenals*. 2nd edition. Lea & Febiger, Philadelphia.
- SOULAIRAC, A. 1946 Action de la surrénale sur l'absorption intestinale du glucose. *Compt. rend. Soc. de Biol.*, *140*: 253-254.
- STENRAM, U. 1951 The effect of adrenalectomy on the histochemically determined phosphatases of the small intestine of the rat. *Acta Anat.*, *12*: 316-333.
- STEVENS, C. E., AND C. P. LEBLOND 1953 Renewal of the mucous cells in the gastric mucosa of the rat. *Anat. Rec.*, *115*: 231-245.
- TISSIÈRES, A. 1948 L'activité des phosphomonoestérases et des pyrophosphatases dans le rein et l'intestin du rat surrénaléctomisé et l'action du désoxycorticostérone. *Acta Anat.*, *5*: 224-234.
- TUERKISCHER, E., AND E. WERTHEIMER 1945 Adrenalectomy and gastric secretion. *J. Endocrinol.*, *4*: 143-151.

- VERNE, J., AND S. HÉBERT 1949 La réactivation de la phosphatase alcaline de l'intestin après surrénalectomie et castration chez le rat male. *Ann. d'Endocrinol.*, *10*: 460-463.
- ZUBIRAN, J. M., A. E. KARK AND L. R. DRAGSTEDT 1952 The effect of ACTH on gastric secretion in experimental animals. *Gastroenter.*, *21*: 276-279.

PLATE 1

EXPLANATION OF FIGURES

The sections of the gastric mucosa illustrated on this plate were fixed in formalin-acetic acid-alcohol and stained with periodic acid-leucofuchsin and Harris' hematoxylin.

2 Control for figure 3. A longitudinal section of the junction of fore-stomach and glandular stomach is shown with the transverse ridge (TR) on the upper side. The deeper portion of the submucosa at the transverse ridge is stained deeply with fuchsin. At the junction are cardiac glands (C) whose epithelium contains much mucus (black in the photomicrograph). The cardiac glands are directly continuous with the mucous neck cells of fundic glands (MNC). Large quantities of mucus are present in the epithelium lining the pits (P) and covering the surface. $\times 70$.

3 Four days after adrenalectomy with water for drinking fluid. Staining of the mucosa with PAS is unchanged but the amount of mucus is reduced in the mucous neck cells, and epithelium of the cardiac glands, pits and on the surface. $\times 70$.

4 Transitional region between the fundus and antrum from the slide used for figure 2. As compared with figure 2, the band of mucous neck cells is wider and approaches the muscularis mucosae. $\times 120$.

5 Transitional region between the fundus and antrum from the slide used for figure 3. The amount of mucus is reduced in mucous neck cells, pits and on the surface.

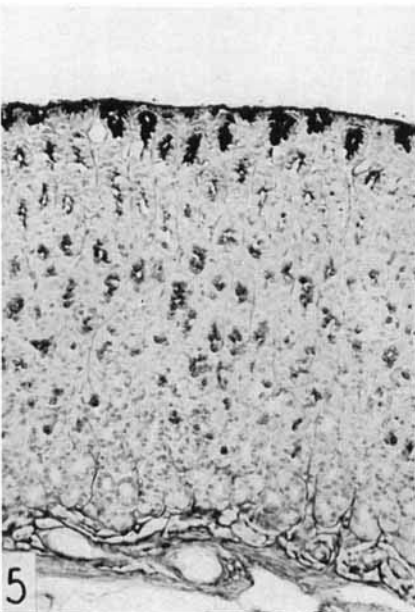
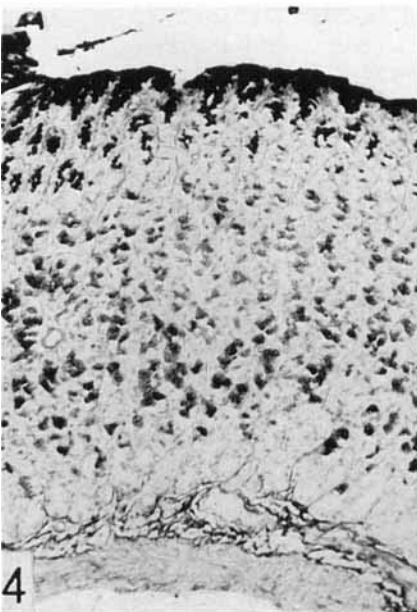
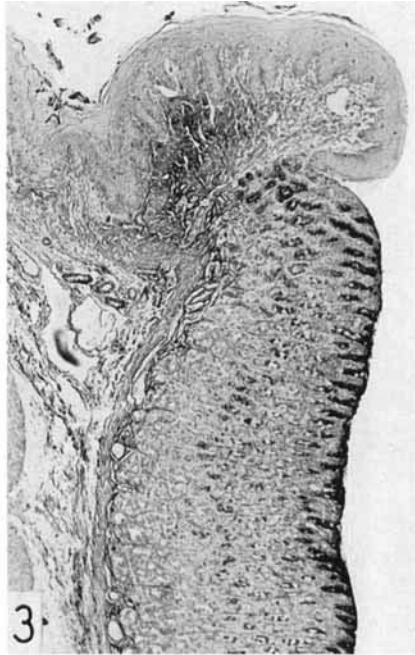
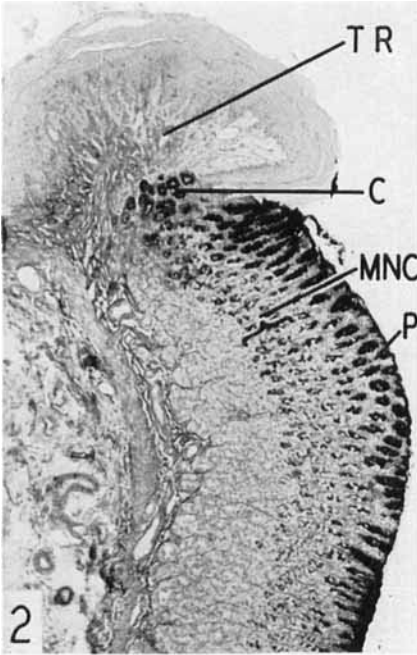


PLATE 2

EXPLANATION OF FIGURES

All photographs are of the gastric mucosa

6 Control for figure 7. Zymogenic cells are large, deeply basophilic in the perinuclear region, and the apical cytoplasm is vacuolated due to defective preservation of pepsinogen granules. FAA, Giemsa. $\times 400$.

7 Twenty-three days after adrenalectomy with maintenance on 1% NaCl. The zymogenic cells are small and depleted of their cytoplasmic basophilia and pepsinogen granules. FAA, Giemsa. $\times 400$.

8 Control for figure 9. Mucus appears black in the pits, on the surface and in the band of mucous neck cells (M). Gray zymogenic cells are present basally. FAA, PAS and methylene blue. $\times 150$.

9 Five milligrams cortisone acetate daily for 21 days. Mucus is reduced in the pits, mucous neck cells and on the surface. The number of zymogenic cells appears to be increased, although individually they are not larger than those shown in figure 8. Technique as for figure 8.

10 Control for figure 11. Zymogenic cells are large, filled with vacuoles (pepsinogen granules) and have a minimal amount of basal ergastoplasm (ribonucleic acid). Zenker-formol, Altmann-Masson. $\times 1350$.

11 Five milligrams hydrocortisone daily for 10 days. Basal ergastoplasm is increased and pepsinogen granules decreased. The nuclei are enlarged and contain a more prominent nucleolus. A clear cell is shown in the insert. Technique as for figure 10.

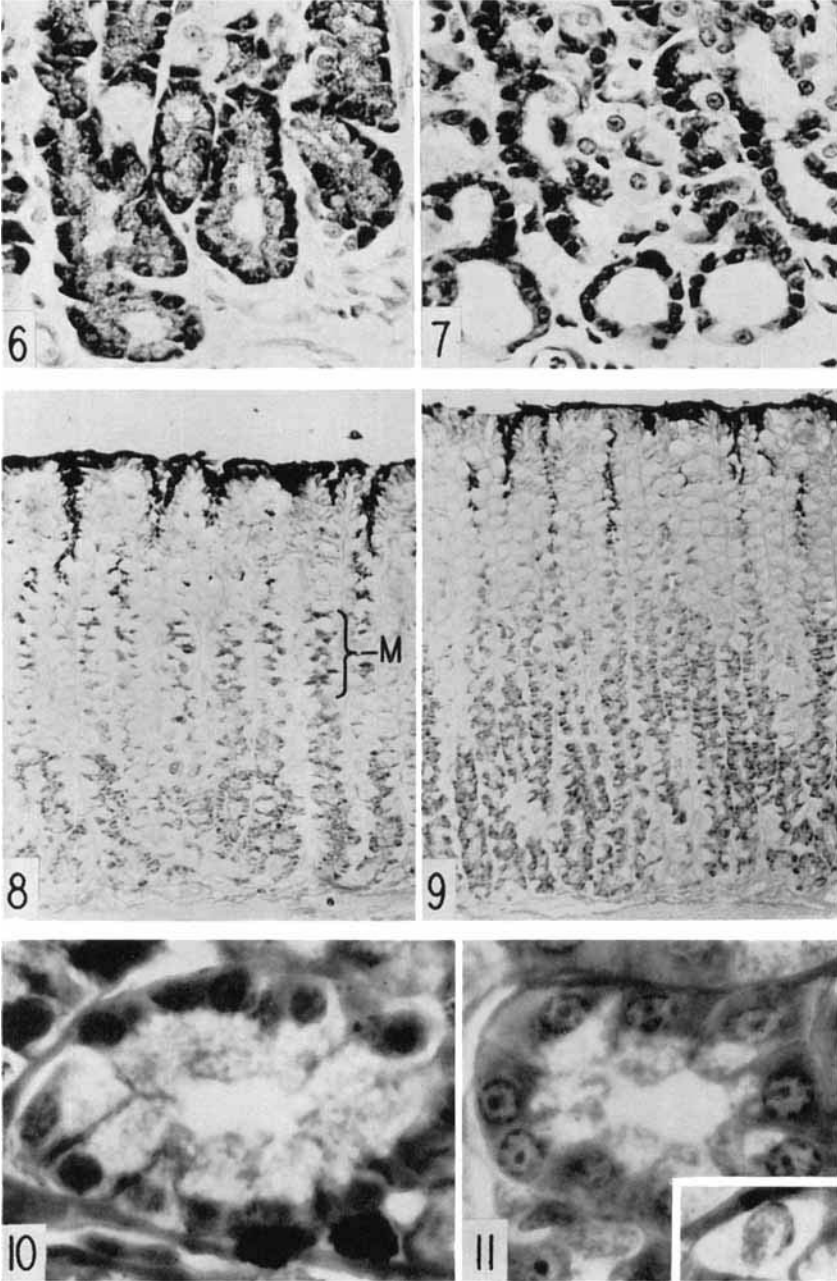


PLATE 3

EXPLANATION OF FIGURES

All figures are of the gastric mucosa. Figures 12-15: fixation in FAA, staining with the Bodian protargol method, $\times 130$; figures 16-19: fixation in Zenker-formol, staining with the Altmann-Masson procedure, $\times 1350$.

12 Adrenalectomized for 22 days and maintained on 1% NaCl. Black argentophile cells in the basal region of the mucosa are not significantly different from those of the control (fig. 13).

13 Control for figure 13.

14 Adrenalectomized for 4 days and given water to drink. Its control was similar to that shown in figure 13. Some reduction in size of argentophile cells is indicated.

15 Five milligrams cortisone acetate daily for 21 days. Argentophile cells remain unchanged.

16 Control for figure 17. Three large parietal cells are present on the lower side of the gland. They are densely packed with large fuchsinophilic granules and smaller rod-shaped mitochondria.

17 Adrenalectomized for 6 days and given water to drink. Several parietal cells are shown which are well-filled with granules and mitochondria.

18 Control for figure 19. Four parietal cells are illustrated.

19 Five milligrams of hydrocortisone daily for 10 days. The partial degranulation of several parietal cells is shown. The cell at the upper middle contains many mitochondria but only a few granules.

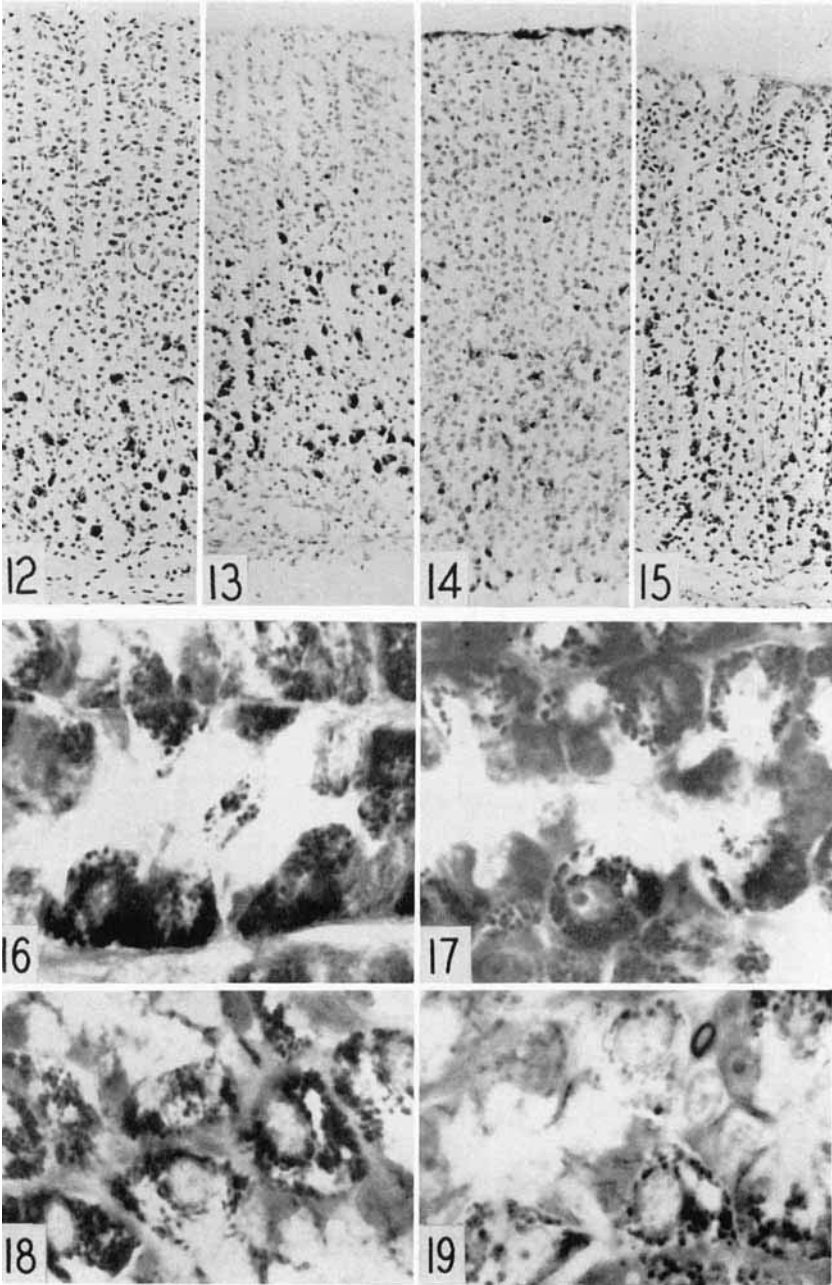


PLATE 4

EXPLANATION OF FIGURES

The gastric mucosa shown in figures 20-25 was fixed in FAA and stained with PAS and methylene blue.

20 Antrum, control for figure 21. The pits are deep and their epithelium contains much mucus. The glands are adjacent to the muscularis mucosae. The apical cytoplasm of the cells lining them stains with PAS. $\times 110$.

21 Antrum, adrenalectomized for 22 days and maintained on 1% NaCl. There is no reduction in the amount of mucus present in the pits or glands. $\times 110$.

22 Antrum, control for figure 23. $\times 110$.

23 Antrum, 3 mg cortisone acetate daily for 10 days. The mucus in the epithelium of pits and glands is reduced. $\times 110$.

24 Pit of the antrum, the rat having been adrenalectomized 22 days previously and maintained on 1% NaCl. Mucus is present in the Golgi region above the nucleus and is concentrated at the apical end of the cell. There is less mucus than in figure 25. $\times 1100$.

25 Pit of antrum, control for figure 25. $\times 1100$.

26 Duodenal crypt of Lieberkühn, the rat having been adrenalectomized 22 days previously and maintained on 1% NaCl. Three Paneth cells at the bottom are enlarged greatly and contain many serous granules. Zenker-formol, Altmann-Masson. $\times 760$.

27 Crypt of Lieberkühn, control for figure 26. The Paneth cells at the bottom contain large vacuoles and few granules. Technique as for figure 26.

28 Mucosa of gastric antrum fixed in FAA and stained with methylene blue. The most intense cytoplasmic basophilia occurs in the isthmus and neck of the glands, less in the epithelium of the pits and surface and none in the deep portion of the glands. $\times 220$.

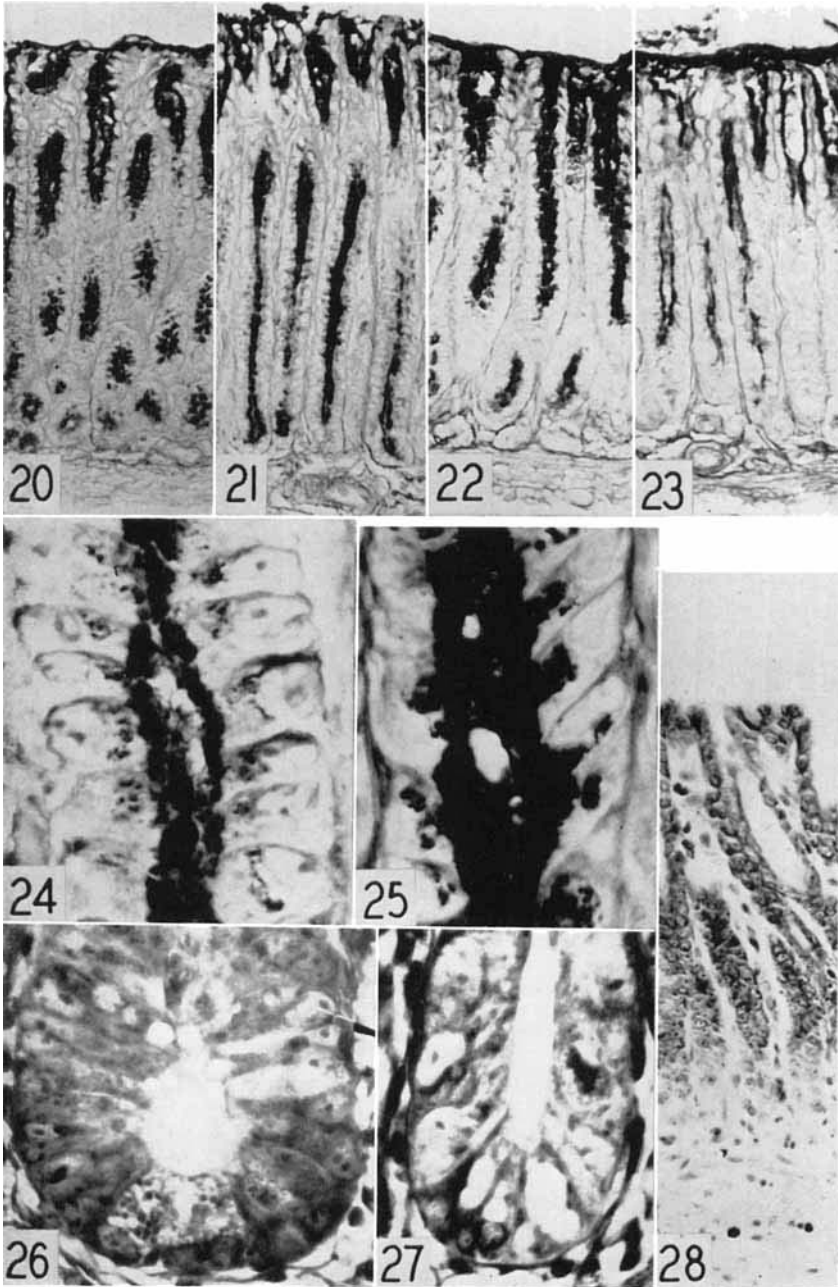


PLATE 5

EXPLANATION OF FIGURES

29 Duodenal crypt of Lieberkühn, control for figure 30. Two Paneth cells at the bottom are vacuolated and stain lightly with PAS. FAA, PAS and methylene blue. $\times 670$.

30 Duodenal crypt of Lieberkühn, 22 days after adrenalectomy and maintenance on 1% NaCl. At the bottom are two Paneth cells whose cytoplasm stains more intensely with PAS than that shown in figure 29. The right hand cell contains granules of glycogen. Technique as for figure 29.

31 Duodenal mucosa, control for figure 32. Goblet cells and the striated border are stained with PAS. FAA, PAS and Harris' hematoxylin. $\times 66$.

32 Duodenal mucosa, 5 mg of cortisone acetate daily for 22 days. The amount of mucus contained by the goblet cells and the intensity of staining of the cuticular border are reduced somewhat. Technique as for figure 31.

33 Duodenal mucosa, control for figure 34. Gomori's alkaline phosphatase technique. Incubation for 15 minutes. $\times 66$.

34 Duodenal mucosa, 10 days after adrenalectomy with water for drinking fluid. Alkaline phosphatase is reduced slightly. Technique as for figure 33.

35 Mucosa of colon, control for figure 36. FAA, PAS and Harris' hematoxylin. $\times 166$.

36 Mucosa of colon, 5 mg of cortisone acetate daily for 22 days. Little change has occurred. Technique as for figure 35.

37 Mucosa of colon, control for figure 38. FAA, PAS. $\times 160$.

38 Mucosa of colon, 22 days after adrenalectomy and maintenance on 1% NaCl. The amount of mucus is unchanged. FAA, PAS. $\times 160$.

