

# The Role of the Convolute Segment of the Proximal Tubule in the Disposal of $^{131}\text{I}$ -Insulin in the Rat Kidney

VIKROM SOTTIURAI

*Department of Anatomy, University of Michigan, Medical School, Ann Arbor, Michigan 48104*

**ABSTRACT** It is generally accepted that in the kidney insulin is metabolized in the proximal tubule, but whether in the convolute segment, the straight segment, or both has not been established. By means of autoradiography counting of radioactivity, and interrupted flow techniques, the following observations have been made.  $^{131}\text{I}$ -labelled porcine insulin is metabolized exclusively in the convolute segment of the proximal tubule. Although the glomerular filtrate is the major source of insulin supply to the renal epithelia, the peritubular capillary plexuses provide as much as 30% or more of the total insulin delivered to the renal epithelia. The epithelium of the convolute segment is capable of sequestering  $^{131}\text{I}$ -insulin from the peritubular capillary plexuses, a phenomenon which has not been established previously.

Numerous investigators have studied the role of mammalian kidneys in the disposal of insulin. Several studies (Elgee, Williams and Lee, '54; Elgee and Williams, '55; Narahara, Everett, Simmons and Williams, '58; Rubenstein and Spitz, '68; Allgood, '61) demonstrated that insulin is metabolized by the renal proximal tubule after being filtered through the glomerulus and reabsorbed by the tubular cells like other proteins (Ericson, '64, '65; Eliasch, Sellers, Sheldon, Mamorston and Rosenfeld, '55; Goodman and Baxter, '56; Mendel, '59; Miller, '60; Miller and Palade, '64; Oliver, '54; Spector, '54; Straus, '64a,b,c). Despite increased knowledge about insulin metabolism in the kidney no reports have suggested whether insulin is metabolized in the convolute, straight, or both segments of the renal proximal tubule. This study attempts to determine the specific site of the renal proximal tubule which engages in the disposal of  $^{131}\text{I}$ -insulin and whether renal epithelium can sequester  $^{131}\text{I}$ -insulin from the peritubular capillary plexuses.

## MATERIALS AND METHODS

Young adult, male Sprague-Dawley rats, weighing 250–300 gm were anesthetized with an intraperitoneal injection of sodium

pentobarbital (60 mg/kg body weight). Approximately 6 ml of mannitol solution (20 gm/100 ml) was infused via the femoral vein at the rate of 0.5 ml/min until osmotic diuresis was produced. When the diuresis reached a steady state, a laparotomy was performed and one ureter was ligated. An additional 3 ml of mannitol solution 20 gm/100 ml was then given at the same rate as before. This caused an increase in the intratubular pressure and reduced the glomerular filtration to a negligible amount in the kidneys with the ligated ureter. Six minutes after ureteral ligation 20  $\mu\text{C}$  of  $^{131}\text{I}$ -insulin was injected intravenously via the femoral vein into each of the 14 animals. The animals were sacrificed in pairs at different circulation times (2, 5, 11, 16, 22, 24, 41 min) to obtain the relationship between time and radioactivity present in the blood, urine, cortex and outer stripe. In these experiments samples were collected in heparinized capillary tubes at two minute intervals throughout the experiment from a polyethylene tube implanted in the abdominal aorta of the animals (a solution of sodium heparin 1 gm/100 ml was used as anticoagulant in the polyethylene tube by keeping the latter filled with the heparin solution between each sample collection).

Urine samples obtained by catheterizing the nonligated ureter with a polyethylene tube, were also collected in heparinized capillary tubes at two minute intervals throughout the experiment. At the conclusion of fluid collection for each group, the kidneys were removed and frozen on dry ice. Paramedian frontal sections, 20  $\mu$  and 5  $\mu$  thick, were obtained from each kidney for gross and microscopic radioautographic studies, respectively. For gross radioautography a piece of Kodak No-Screen X-ray film was placed adjacent to the thawed and air-dried kidney section. The film was held in place by another clean slide with a rubber band wrapped around both. For microscopic autoradiography, Bouin-fixed 5  $\mu$  thick sections were dehydrated through ethanol and ether and then air-dried for two hours. The slides were dipped in Kodak NTB-2 emulsion, exposed for three weeks in light proof boxes, developed in Kodak D-11, and stained with hematoxylin-eosin. The cortex and the outer stripe of the outer zone of the medulla were separately dissected free from the remaining approximately 1 mm thick median frontal kidney slice. The dry weights of these tissue samples were obtained and their radioactivity were assayed with a well-type scintillation counter.

### RESULTS

Gross autoradiographs of fresh-frozen kidney sections demonstrated that radioactivity of  $^{131}\text{I}$ -insulin was far more striking the cortex (locus of convoluted segment) than in any other part of the kidney with both the noninterrupted and the interrupted flow conditions (figs. 1, 2). Accumulation of radioactivity in the cortex appeared greater in the noninterrupted flow kidneys than in those with interrupted flow.

In the microscopic autoradiographs of the noninterrupted flow kidney,  $^{131}\text{I}$  induced silver grains were present at very high concentration in the glomeruli, at the glomerulotubular junction in the peritubular space, (fig. 4); in the lumen, and within the tubular epithelia of the convoluted segmented (figs. 6, 8).

In the interrupted-flow kidney equal numbers of silver grains were observed in the glomeruli, and the peritubular spaces

(figs. 3, 5, 7). Fewer silver grains were found in the epithelia, and only a few were encountered in the lumen (figs. 5, 7). Silver grains at the glomerulotubular junction terminated abruptly. They were numerous on the glomerular side with only a few appearing on the tubular side (fig. 3). This observation is contrary to the uniform and uninterrupted grain distribution observed in the noninterrupted flow kidney (fig. 4).

The quantities of radioactivity in the cortex and the outer stripe, as measured by counting, directly correlate with the radioautographs (figs. 1, 2). Quantitatively, in noninterrupted flow and interrupted flow alike, radioactivity was localized exclusively in the cortex, and the cortex/outer stripe ratio in the noninterrupted flow kidney was approximately 10:1 ( $p < 0.1$ ), (fig. 9). This ratio was maintained regardless of circulation time. The greatest accumulation of radioactivity occurred 11 minutes after injection.

Radioactivity in plasma fell rapidly during the first five minutes after injection of insulin, and declined slowly during the remainder of the experiment.

Radioactivity in the urine rose rapidly during the first five minutes after insulin injection, which was followed by a more gradual rise up to 25 minutes and then a decline which paralleled that in the plasma after 25 minutes (fig. 10).

### DISCUSSION

Although insulin is filtered, reabsorbed and metabolized in the renal proximal tubule (Elgee et al., '54, '55; Narahara et al., '58; Rubenstein et al., '68; Allgood, '61), whether this process takes place in a particular segment of the tubule has not previously been considered. The accumulation of radioactivity in the cortices (loci of the convoluted segments) of the interrupted and the noninterrupted flow kidneys, demonstrated by quantitative data and autoradiographs indicates that the cortically located convoluted segment is the major portion of the nephron which engages in disposal of  $^{131}\text{I}$ -insulin and its by-products. The distribution of silver grains in the liquid emulsion autoradiographs with respect to the lumen, within the renal epithelia and the peritubular space, con-

firmly the aforementioned hypothesis and makes possible more accurate determination of how insulin is delivered to the renal epithelia of the convoluted segment.

There are two sources from which the renal epithelia can obtain  $^{131}\text{I}$ -insulin; the glomerular filtrate and the peritubular capillary plexus. The former source of  $^{131}\text{I}$ -insulin delivery to the renal epithelia has been recognized and accepted (Narahara et al., '58). The latter source, however, has not previously been demonstrated. By means of ureteral ligation to interrupt urine flow and arrest glomerular filtration, this study showed that the tubular epithelia of the convoluted segment can sequester  $^{131}\text{I}$ -insulin from the peritubular capillary plexuses.

Although controversial, whether or not ureteral ligation of an animal made diuretic with mannitol completely stops glomerular filtration, it is generally agreed that the continuing glomerular filtration is negligible. Taylor and Ullman ('61) reported that with a 20% mannitol solution as the diuretic agent, ureteral ligation for six minutes stops 94% of the glomerular filtration.

The lack of silver grains in the tubular lumen of the interrupted flow kidney coupled with only a moderate accumulation in the epithelium of the convoluted segment of the proximal tubule support the concept of a great reduction in glomerular filtration in the interrupted flow kidney. The abundance of silver grains in the peritubular spaces and the glomerulus, which are comparable to that of the noninterrupted-flow kidney, further supports a negligible glomerular filtration in the interrupted-flow kidney. Consequently, the glomerular filtrate can no longer be the major source of radioactivity for the renal epithelia. The observation of an abrupt termination of silver grains at the glomerulotubular junction of the interrupted-flow kidney perhaps reflects the interruption of urine flow and confirms the assumption that prevailing filtration is insignificant.

The radioactivity found in the cortex of the interrupted-flow kidney is 33% of the noninterrupted-flow kidney, which is not explained by the prevailing glomerular filtration (6% according to Taylor and Ull-

man, '61) or the distribution of silver grains. The moderate accumulation of silver grains in the epithelium therefore must be derived from the peritubular capillary plexuses.

The manner of sequestration of  $^{131}\text{I}$ -insulin by the epithelium of the convoluted segment and the precise amount of radioactivity delivered to the epithelium by the glomerular filtrate and the peritubular capillary plexuses are beyond the scope of this study. However, this study indicated that (1)  $^{131}\text{I}$ -insulin is filtered, reabsorbed and metabolized exclusively in the epithelium of the convoluted segment of the proximal tubule, (2) although the glomerular filtrate provides the major source of  $^{131}\text{I}$ -insulin supply to this renal epithelium, the peritubular capillary plexuses can deliver as much as 30% of the total  $^{131}\text{I}$ -insulin uptake of these epithelia, (3) the renal epithelium of the convoluted segment is capable of sequestering  $^{131}\text{I}$ -insulin from the peritubular capillary plexuses.

Questions concerning the nature of the substance that carries the radioactivity recovered in the renal tissues and that which induced silver grains in autoradiographs have been asked, since it can be attributed to  $^{131}\text{I}$ ,  $^{131}\text{I}$ -insulin,  $^{131}\text{I}$ -monoiodotyrosine, or  $^{131}\text{I}$ -diiodotyrosine (Mortimore, Tietze and Stetten, '59). Determination of the intact  $^{131}\text{I}$ -insulin in the injection fluid and in the renal epithelia with an immunoassay study was found to be 86% and 52%, respectively (Sottiurai, unpublished).

The possibility of a decrease in renal blood flow after ureteral ligation which could result in a decrease of glomerular filtration has also been considered. However, Gilmore ('65) and Yoshitoshi, Honda, Marikawa, Aizawa and Seki ('67) in separate studies both concluded that renal blood flow was not decreased but maintained normally by occlusion of the ureter during mannitol diuresis.

#### ACKNOWLEDGMENTS

This investigation was supported by Federal Fund 005170, Kidney Foundation of Michigan, 34029 and Faculty Research 360127.

#### LITERATURE CITED

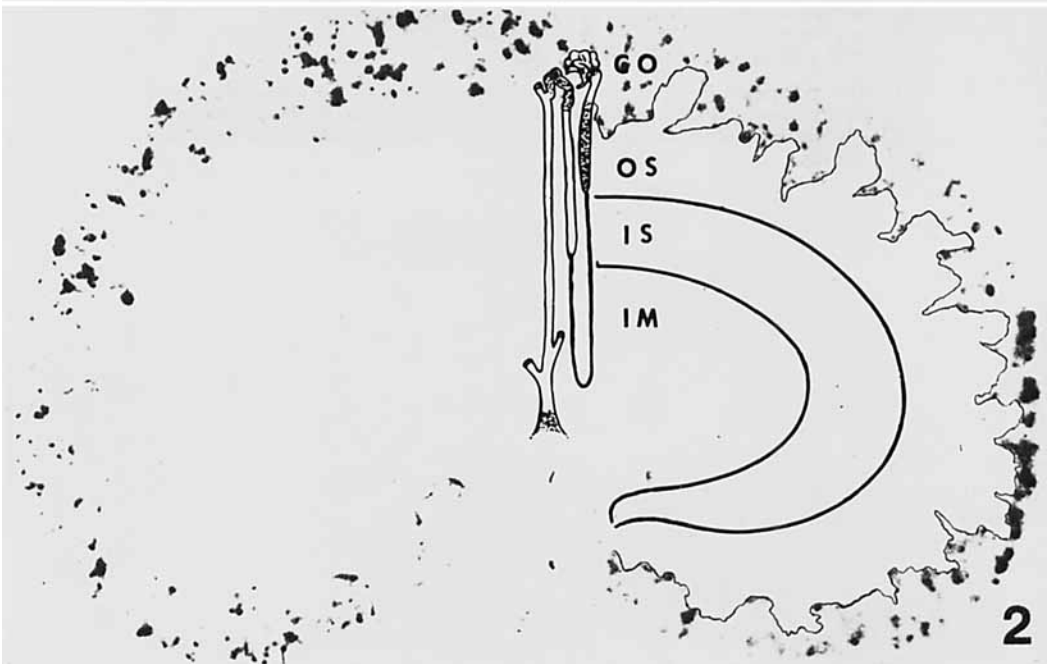
Allgood, J. M. 1961 The renal clearance of  $\text{I}^{131}$

- during the infusion of  $\text{NaI}^{131}$  and insulin- $\text{I}^{131}$ . *Diabetes*, 10: 7-11.
- Elgee, N. J., and R. H. Williams 1955 Specificity of insulin degradation reaction. *Diabetes*, 4: 87-90.
- Elgee, N. J., R. H. Williams and N. D. Lee 1954 Distribution and degradation studies with insulin- $\text{I}^{131}$ . *J. Clin. Invest.*, 33: 1252-1260.
- Eliasch, H., A. L. Sellers, R. D. Sheldon, J. Marmorston and D. V. M. Rosenfeld 1955 Protein metabolism in the mammalian kidney. *J. Exp. Med.*, 101: 129-134.
- Ericsson, J. L. 1964 Absorption and decomposition of hemoglobin in renal proximal tubular cells: A light and electron microscopic study. *Acta Path. Microbiol. Scand.*, 168: 1-120.
- 1965 Transport and digestion of hemoglobin in the proximal tubule. I. Light microscopy and cytochemistry of acid phosphatase. *Lab. Invest.*, 14: 1-15.
- Gillmore, J. P. 1965 Influence of tissue pressure on renal blood flow autoregulation. *Am. J. Physiol.*, 106: 707-713.
- Goodman, H. C., and J. H. Baxter 1956 Tubular reabsorption of protein in experimentally produced proteinuria in rats. *Proc. Soc. Exp. Biol. Med.*, 93: 136-140.
- Mendel, D. 1959 Tubular reabsorption of protein in the rat. *J. Physiol.*, 148: 1-13.
- Miller, F. 1960 Hemoglobin absorption by the cells of the proximal convoluted tubule in mouse kidney. *J. Biophys. Biochem. Cytol.*, 8: 689-718.
- Miller, F., and C. Palade 1964 Lytic activities in renal protein absorption droplets. *J. Cell Biol.*, 23: 519-552.
- Mortimore, G. E., F. Tietze and K. W. Stetten, Jr. 1959 Metabolism of insulin- $\text{I}^{131}$ , studies in isolated, perfused rat liver and hind limb preparations. *Diabetes*, 8: 307-314.
- Narahara, H. T., N. B. Everett, B. S. Simmons and R. H. Williams 1958 Metabolism of insulin- $\text{I}^{131}$  and glucagon- $\text{I}^{131}$  in the kidney of the rat. *Am. J. Physiol.*, 192: 227-231.
- Oliver, J. 1954 Cellular mechanism of protein metabolism in the nephron. II. The biochemical characteristics of protein absorption droplets. *J. Exp. Med.*, 99: 589-604.
- Rubenstein, A. H., and I. Spitz 1968 Role of the kidney in insulin metabolism and excretion. *Diabetes*, 17: 161-169.
- Spector, W. C. 1954 The reabsorption of labelled protein by the normal and nephrotic rat kidney. *J. Path. Bact.*, 68: 187-196.
- Straus, W. 1964a Factors affecting the cytochemical reaction of peroxidase with benzidine and stability of the blue reaction product. *J. Histochem. Cytochem.*, 12: 462-469.
- 1964b Factors affecting the state of injected horseradish peroxidase in animal tissue and procedures for the study of phagosomes and phago-lysosomes. *J. Histochem. Cytochem.*, 12: 470-480.
- 1964c Occurrence of phagosomes and phago-lysosomes in different segments of the nephron in relationship to the reabsorption, transport, digestion and extrusion of intravenously injected horseradish peroxidase. *J. Cell Biol.*, 21: 295-308.
- Taylor, M. G., and E. J. Ullman 1961 Glomerular filtration after obstruction of the ureter. *J. Physiol.*, 157: 38.
- Yoshitoshi, Y., N. Honda, A. Marikawa, C. Aizawa and K. Seki 1967 Alteration in intrarenal hemodynamics following changes in ureteral pressure in rabbit kidney. *Jap. Heart J.*, 8: 32-41.

## PLATE 1

## EXPLANATION OF FIGURES

- 1 Autoradiograph showing  $^{131}\text{I}$ -insulin accumulation in the cortex of the rat kidney after 11 minutes of circulation under noninterrupted urine flow conditions. (Radioactive areas in this and the following autoradiograph are black.)  $\times 6.3$ .
- 2 Autoradiograph showing decreased  $^{131}\text{I}$ -insulin accumulation in the cortex of the rat kidney after 11 minutes of circulation under interrupted urine flow conditions. CO, cortex; OS, outer stripe; IS, inner stripe; IM, inner medulla.  $\times 6.3$ .



The magnification of the photomicrographs for figures 3-8 is  $\times 450$ . Arrows point to silver grain; G, glomerulus; LU, lumen; BS, Bowman's space; GT, glomerulotubular junction; PT, peritubular space.

#### PLATE 2

##### EXPLANATION OF FIGURES

- 3 Photomicrograph of glomerulotubular junction of the interrupted flow kidney, demonstrating abrupt termination of silver grains at the glomerulotubular junction. They were numerous on the glomerular side with only a few on the tubular side.
- 4 Photomicrograph of glomerulotubular junction of the noninterrupted flow kidney, demonstrating silver grains distribution in the glomerulus, glomerulotubular junction and the lumen of the convoluted proximal tubule.

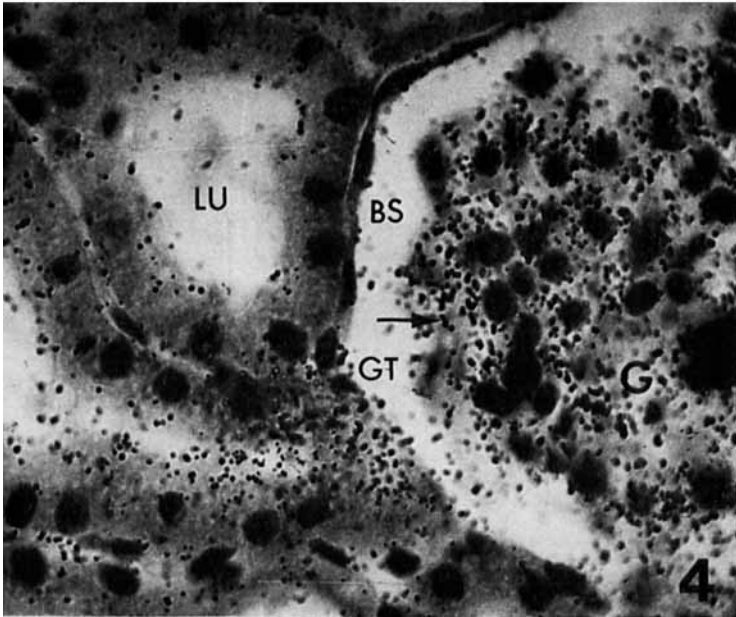
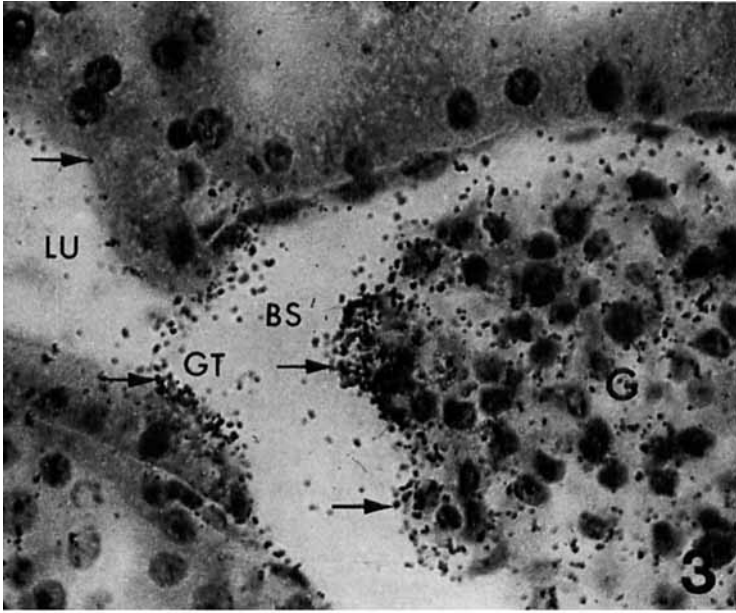
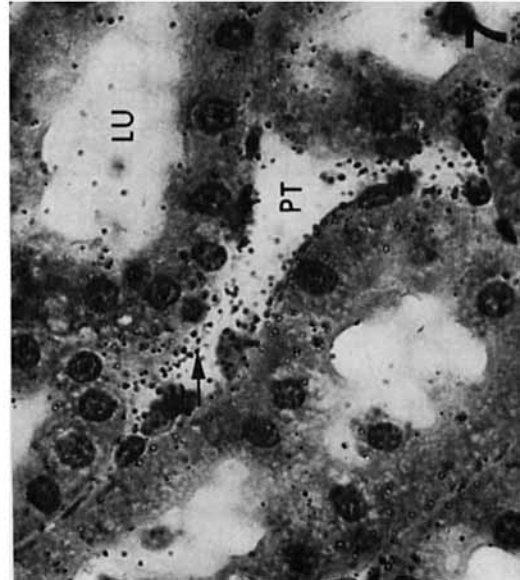
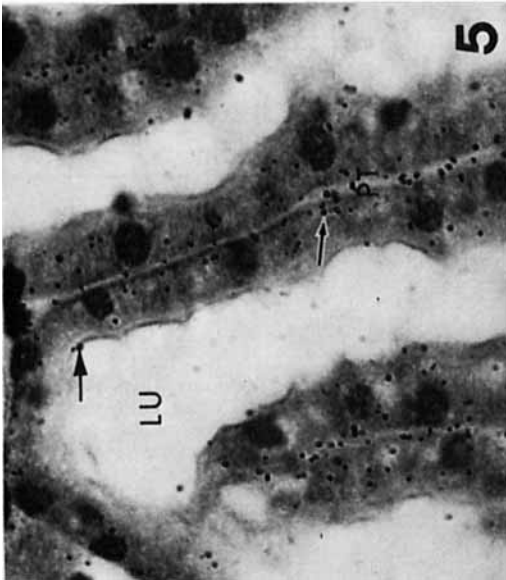
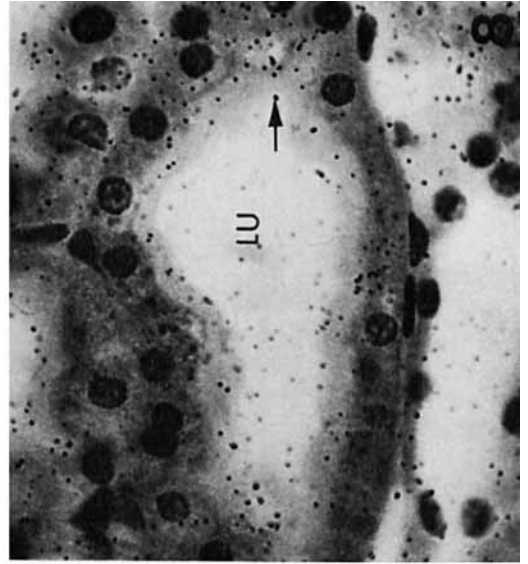
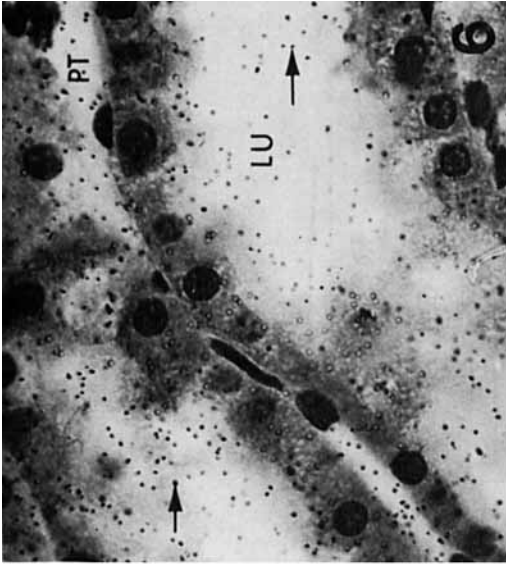


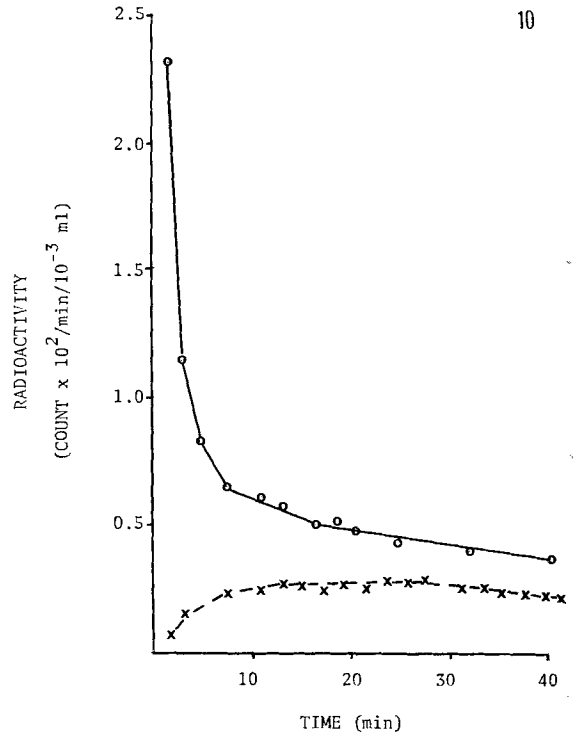
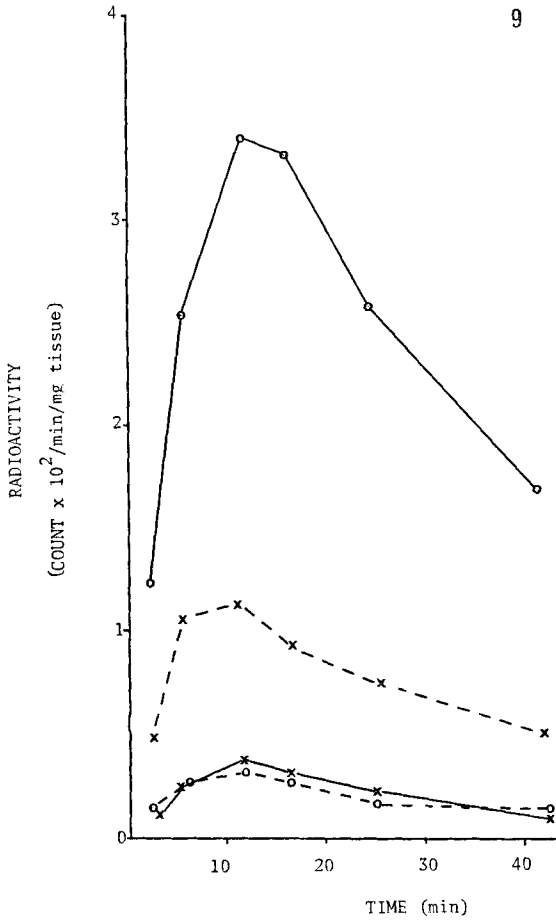
PLATE 3

EXPLANATION OF FIGURES

- 5 Photomicrograph of longitudinally sectioned convoluted segment of the interrupted flow kidney depicting a few silver grains in the renal epithelia, the peritubular spaces and the lumen.
- 6 Photomicrograph of longitudinally sectioned convoluted segment of the noninterrupted flow kidney, depicting numerous silver grains in the renal epithelia, peritubular spaces and the lumen.
- 7 Photomicrograph of the transversely and obliquely sectioned convoluted segment of the interrupted flow kidney, depicting a few silver grains in the renal epithelia, the peritubular spaces and the lumen.
- 8 Photomicrograph of the transversely and obliquely sectioned convoluted segment of the interrupted flow kidney, depicting numerous silver grains in the renal epithelia, the peritubular spaces and the lumen.







EXPLANATION OF FIGURES

- 9 Radioactivity ( $^{131}\text{I}$ -insulin) in the cortex and outer stripe after different times of circulation under interrupted flow and noninterrupted flow conditions. Cortex from the non-interrupted flow kidney (-O-); cortex from interrupted flow kidney (-X-); outer stripe from noninterrupted flow kidney (--O--); outer stripe from interrupted flow kidney (--X--).
- 10 Radioactivity ( $^{131}\text{I}$ -insulin) in plasma and urine versus time. Plasma (-o-); urine (-x-).