

# Identification of the Corticotropin Cell in Rat Hypophyses with Peroxidase-labeled Antibody<sup>1</sup>

BURTON L. BAKER, SUMER PEK, A. REES MIDGLEY, JR.  
AND BRIAN E. GERSTEN

*Departments of Anatomy, Internal Medicine and Pathology,  
The University of Michigan Medical School,  
Ann Arbor, Michigan 48104*

**ABSTRACT** Utilization of peroxidase-labeled antibody to porcine corticotropin permitted the delineation of a distinctive cell in the hypophyseal pars distalis of the rat that appears to be the source of corticotropin. Corticotropin cells were stellate and possessed processes that ended on the walls of sinusoids. Corticotropin cells composed a small percentage of the total cell population, and were distributed throughout the gland except that they were less common posteriorly, superiorly, and immediately alongside the pars intermedia. Alteration in size of corticotropin cells was related directly to change in corticotropin content of the gland as effected by differing physiological conditions. Thus, they were larger in the female than in the male and were enlarged after adrenalectomy of the male; they became much smaller following treatment of the female with cortisol. Some corticotropin cells stained with aldehyde fuchsin and the periodic acid-Schiff (PAS) reaction. These reactions were more intense if hormone antibody and the gamma-globulin conjugate had been applied previously. However, the capacity of some corticotropin cells to stain weakly with PAS without prior application of antibody suggests that they may contain mucoprotein.

The cellular origin of corticotropin remains undetermined, its secretion having been attributed to each of the major cell classes found in the hypophyseal pars distalis. Finerty and Briseno-Castrejon ('49) drew attention to acidophils as a possible source of corticotropin by observing an increase in their relative number after subsection of hemi-adrenalectomized rats to stress. This conclusion was later supported by Herlant and Klastersky ('63) who reported an increase in the number of pituitary acidophils containing small granules (about 100–150 m $\mu$  in diameter) in hypophyses made hyperactive by administration of a chemical inhibitor of corticosteroidogenesis. Utilizing fluorescein-labeled antibody to synthetic  $\beta^{1-24}$ -corticotropin, Kracht et al. ('65) also localized corticotropin in acidophils of the rat. On the other hand, Siperstein ('63) combined radioautography with chemical staining after administration of labeled glycine to identify a hyperactive cell in adrenalectomized rats which she believed to be a chromophobe and the source of corticotropin.

Basophils are implicated as being the source of corticotropin by several lines of evidence. They exhibit characteristic structural alteration in Cushing's syndrome. Also, many investigators by diverse experimental approaches have found a direct correlation between accelerated corticotropin secretion and cytological evidence of basophil activation (reviewed by Siperstein, '63). By means of immunofluorescent techniques corticotropin has been localized in basophils of man (Leznoff et al., '62; Pearce and van Noorden, '63; Hachmeister and Kracht, '65), rat (Hess et al., '68), rabbit, dog and cat (Hachmeister and Kracht, '65).

The objectives of this investigation were (a) to ascertain the cellular origin of corticotropin in the rat hypophysis by means of immunohistochemical staining with peroxidase-labeled antibody to corticotropin, (b)

Received June 30, '69. Accepted Oct. 28, '69.

<sup>1</sup> Supported in part by USPHS research grants HD 03159-01A1 and HD 02193, and a grant from the University of Michigan Horace H. Rackham School of Graduate Studies.

<sup>2</sup> Appreciation is extended to Dr. William D. Odell, University of California, Los Angeles, for providing antisera to human thyrotropin, and to Mrs. Ya-Yen Yu for her skillful technical assistance.

to seek verification of the accuracy of this identification by observing if experimental alteration in corticotropin content of the gland is reflected by a predictable structural change in the corticotropin cell, and (c) to correlate the cell revealed immunohistochemically with the cell types observed after chemical staining.

#### MATERIALS AND METHODS

The observations to be presented were made on hypophyses of young adult Sprague-Dawley rats grouped as follows: 16 intact females; 6 females killed 35 days after ovariectomy; 4 females killed 3 days after adrenalectomy; 10 females treated with 1 mg of dexamethasone daily for 7 days; 5 females treated with 5 mg of cortisol acetate daily for 19 days; 6 intact males; and 5 males killed 7 days after adrenalectomy. The adrenalectomized rats were given 1% NaCl solution as drinking fluid. The dexamethasone and cortisol acetate were prepared as suspensions in Upjohn vehicle 98 (carboxymethylcellulose, polysorbate, and propylparaben) diluted 1:2 with 0.9% NaCl solution.

The hypophyses were fixed in Bouin's fluid, embedded in paraffin and sectioned at  $3\ \mu$  on a frontal plane. One slide was prepared for chemical staining with ten sections taken from three equally spaced zones throughout the gland. Single sections obtained from each of the zones were placed on slides for immunohistochemical staining by the Nakane-Pierce ('67) procedure. This is an indirect method involving, first, application to the section of rabbit antiserum to the hormone; second, application of sheep antirabbit gamma-globulin conjugated with peroxidase; and, third, histochemical staining for peroxidase. 3,3'-Diaminobenzidine (DAB) and  $\alpha$ -naphthol served as substrates for the peroxidase reaction. The sections incubated in  $\alpha$ -naphthol were subsequently stained with pyronin.

Antiserum to porcine corticotropin (anti-PC) was prepared by administering 20 injections of porcine corticotropin, emulsified with Freund's adjuvant, to rabbits at intervals of 2 to 3 weeks. This antiserum has a low antibody titer. However, in a radioimmunoassay system using hydrodynamic flow chromatography-electrophoresis

this antiserum can be used for the specific quantification of as little as five picograms of porcine or human corticotropin preparations (S.P.).

Since the staining method involves several steps, numerous control procedures were carried out. No staining of corticotropin cells was obtained under the following conditions: incubation of sections in the peroxidase substrate without prior treatment with antiserum to hormone and the gamma-globulin-peroxidase conjugate; substitution in the Nakane-Pierce procedure of normal rabbit serum or rabbit antiserum to egg albumen for anti-PC; and by blockade of immunoreactive sites on the hormone antibody when attached to the corticotropin cell by application of unconjugated anti-rabbit gamma-globulin prior to treatment with conjugated anti-rabbit gamma-globulin.

Specificity of the staining procedure was indicated by the following observations. No staining of corticotropin cells occurred if the anti-PC was previously absorbed with the 3,500-10,000 M.W. fraction (presumably containing corticotropin) of female rat hypophyses obtained by gel filtration through a  $2.5 \times 89.5$  cm column of Sephadex G-100 which was equilibrated and eluted with 0.05 M ammonium bicarbonate, pH 8.0, and calibrated with a series of reference proteins of known M.W. as described by Reichert et al. (in press). The fraction was lyophilized and redissolved in buffered physiological saline to increase the concentration prior to absorption. Absorption with fractions which should have contained only buffer did not interfere with staining. Similarly, no staining of corticotropin cells was obtained if the anti-PC was previously absorbed with U.S.P. corticotropin Reference Standard. On the other hand, absorption of anti-PC at identical concentrations with bovine plasma albumen, thyrotropin (NIH-TSH-S-1 ovine), luteinizing hormone (NIH-LH-B-1, bovine, Lot 7231), or follicle-stimulating hormone (NIH-FSH-S-1, ovine) did not neutralize the effectiveness of anti-PC in the staining procedure, indicating that the antiserum was not significantly contaminated with antibodies capable of cross reacting with these hormones. The anti-PC tended to produce

more background staining when followed by incubation in DAB and treatment with osmic acid than was true of all other hormone antisera used in this laboratory. This difficulty was not alleviated by prior absorption of the antiserum with rat liver powder and activated charcoal. On the other hand, background was negligible if the osmic acid step was omitted and when  $\alpha$ -naphthol was used as the substrate for peroxidase.

To provide additional evidence for specificity of the immunochemical staining reaction for corticotropin cells, double-staining (Nakane, '68) was carried out in which the corticotropin cell was demonstrated alongside the growth hormone cell or prolactin cell in the same section. For this purpose antisera to human growth hormone (anti-HGH) and to rat prolactin (anti-RP) were used as previously described (Baker et al., '69). Preliminary observations were similarly made on the relation of the corticotropin cell to the thyrotropin cell by using an antiserum to human thyrotropin (anti-HTSH).<sup>3</sup> For these preparations different substrates were employed for peroxidase so that the two cell types were revealed in contrasting colors in a single section.

In order to correlate the corticotropin cell with the cell types revealed by chemical staining, several procedures were followed. First, after the peroxidase reaction, selected cells were photographed, destained, and then restained by one of the following chemical procedures: aldehyde fuchsin and the Masson procedure; periodic acid-Schiff (PAS) with and without hematoxylin; and Alcian blue (pH 2). Control sections were incubated in a medium containing  $\alpha$ -amylase before chemical staining. Second, sections were stained immunochemically, destained, antibody removed by dissociation in HCl (Nakane, '68), and then restained by a chemical method. Third, adjacent sections were compared after one had been stained immunochemically and the others with aldehyde fuchsin or PAS.

#### OBSERVATIONS

The cell type revealed immunochemically with anti-PC, and which will be designated the corticotropin cell, consti-

tuted about 4% of the parenchymal cells in the female hypophysis. It was stellate (fig. 6) with the cell body usually being located centrally in a cell cord and thus removed from the sinusoids. Long processes commonly extended from the cell body to end on a sinusoidal wall; occasionally the processes of one cell formed a bridge between two sinusoids. With fixation in Bouin's fluid the cytoplasm in these processes occasionally contracted toward the central axis (fig. 2). Corticotropin cells were distributed rather diffusely throughout the pars distalis, but were somewhat less numerous near the posterior border, alongside the pars intermedia where growth hormone cells and prolactin cells abound, and in the superior medial region where basophils are abundant. The pars nervosa showed practically no staining while the pars intermedia (fig. 7) stained with an intensity which was usually above the background of the pars distalis. However, the depth of color in the pars intermedia rarely approached that of corticotropin cells.

Double immunochemical staining of single sections showed that the corticotropin cell is distinct from growth hormone, prolactin, and thyrotropin cells (fig. 5), these cell types not exhibiting any reactivity to anti-PC. However, additional study is necessary to prove the specificity of the anti-HTSH used.

Several chemical staining reactions indicated that the corticotropin cell might be classified as a basophil although the evidence is weaker than that for other subgroups of the basophil category. Light green stained the cytoplasm of corticotropin cells with varying degrees of intensity. All corticotropin cells reacted strongly to aldehyde fuchsin in sections which had been previously stained immunochemically and subsequently destained (figs. 8, 9). However, aldehyde fuchsin also colored other cells that did not fix antibodies to corticotropin; some of these were thyrotropin cells (fig. 9). In sections not previously subjected to the immunochemical procedure, and in sections previously stained immunochemically, but from which the antibody was subsequently dissociated in HCl, certain

corticotropin cells failed to stain with aldehyde fuchsin.

With PAS under all conditions used for comparison of the response of corticotropin cells to immunochemical and chemical staining some cells gave a weak positive reaction (figs. 10, 11) while others were negative; the intensity of the reaction was always less than that of some other basophils (fig. 13) and was not eliminated by amylase digestion. Prior immunochemical staining seemed to make possible a more intense PAS reaction in corticotropin cells (fig. 12). Staining of corticotropin cells was never obtained with Alcian blue in loci where other basophils took up the dye. On the basis of these observations it is concluded that the corticotropin cell at times contains sufficient mucoprotein to permit histochemical detection.

Corticotropin cells varied in size under different physiological conditions. They tended to be somewhat larger and more intensely stained in the hypophysis of the female (fig. 1) as compared with the male (fig. 2). Ovariectomy elicited minor and variable alteration in the corticotropin cell; most commonly the size and staining capacity of the cytoplasm were mildly reduced. Seven days after adrenalectomy of the female, some corticotropin cells were enlarged; after a three-day postoperative period little alteration was observed. However, in the male corticotropin cells were strikingly hypertrophied seven days after adrenalectomy (fig. 3) although they sometimes stained somewhat less intensely than in the intact rat. Treatment of female rats with dexamethasone for seven days induced a variable reduction in size of corticotropin cells. However, therapy with cortisol acetate for a longer period elicited such a profound reduction in size and staining capacity that identification of corticotropin cells became difficult (fig. 4).

#### DISCUSSION

*Nature of the corticotropin cell.* The inability of earlier workers to demonstrate the corticotropin cell by means of chemical staining is understandable. After Bouin fixation, the cytoplasm stains with light green, as is true of many other basophils, but not in a distinctive manner. The

larger corticotropin cells can be identified with reasonable certainty on the basis of their shape, position, and occasional tendency of the cytoplasm to pull away from the plasmalemma. However, the smaller corticotropin cells are indistinguishable from small chromophobes.

The capacity of the corticotropin cell to stain with aldehyde fuchsin and with the PAS procedure indicates that it sometimes contains muco- or glycoprotein and, therefore, might be classed as a basophil. Such a conclusion would agree with the opinion of other workers previously cited who employed immunofluorescent procedures. However, the irregularity of the staining reaction with PAS suggests that under normal circumstances mucoprotein does not accumulate within the cell to a significant degree. Since immunoglobulins are glycoproteins, their prior application may have enhanced the responsiveness of the cell to aldehyde fuchsin and PAS. However, removal of antibody by acid dissociation did not reduce greatly the capacity of corticotropin cells to take up these dyes. Likewise, neither growth hormone cells nor prolactin cells became PAS-positive after application of antisera to human growth hormone or rat prolactin, respectively, followed by the gamma-globulin-peroxidase conjugate. The corticotropin cell should not be considered an acidophil because its granules were not fuchsinophilic. Probably the cell identified as the corticotropin cell in this study would have been classified as a chromophobe by most earlier workers who used chemical staining procedures.

It seems reasonably certain that the "adrenalectomy cell" described by Siperstein ('63) corresponds to the larger corticotropin cells as defined herein. This conclusion is based on the following characteristics which she attributed to the adrenalectomy cell: low relative number in the gland, general distribution, and irregular shape with cytoplasmic processes that extend between and partially surround neighboring cells. Siperstein and Allison ('65) showed that few cytoplasmic granules accumulate in the adrenalectomy cell which may account for the difficulty she and the present authors have experienced in staining the corticotropin cell

distinctively with chemical procedures, and explain why she concluded that the adrenalectomy cell is a chromophobe. Her subsequent demonstration with electron microscopy that granules are present in the cytoplasm suggests that the adrenalectomy cell should not be considered a chromophobe in a strict sense.

*Correlation of corticotropin cells with physiological status.* In general, the size of the corticotropin cell varied directly with the glandular corticotropin content when altered by experimental means. Thus, the smaller size of the cell in the male hypophysis as compared with the female is correlated with a probable lower hormone content as indicated by several lines of evidence. Using implants of hypophyses as a bioassay procedure Emery and Winter ('34) found less corticotropin in the male gland. This difference is to be expected since testosterone seems to exert a depressing effect on content of corticotropin in the male rat. For example, testosterone therapy prevents the rise in pituitary corticotropin that occurs after castration (Kitay, '63). In contrast, estrogen treatment elevates the pituitary corticotropin content in ovariectomized rats (Kitay, '63). Thus, it can be expected that corticotropin cells would be more active in the female and would, therefore, be larger as observed in this study. Ovariectomy does not alter the amount of corticotropin in the gland (Kitay, '63) which correlates well with the irregular changes observed in the corticotropin cells.

Most studies dealing with the effect of adrenalectomy on pituitary corticotropin have been performed on male rats. All of these investigations (Gemzell et al., '51; Sydnor and Sayers, '54; Fortier, '59a; Kitay, '63) reveal that a significant rise occurs by the seventh postoperative day. Hence, the marked enlargement of corticotropin cells observed in male rats after adrenal ablation is to be expected. Similarly, Hess et al., ('68) observed cellular enlargement and reduced reaction with fluorescein-labeled antibody to  $\beta^{1-24}$  corticotropin cells after adrenalectomy.

Data pertaining to the effect of adrenalectomy on pituitary corticotropin content in female rats is less extensive. Kitay ('63)

reported a rise with wide variation from rat to rat but did not give the duration of the postoperative period. In the present study, at seven days after adrenalectomy a modest hypertrophy was of lesser consistency and magnitude than that observed in the male rat.

The profound reduction in size and stainability of corticotropin cells after treatment of intact female rats with cortisol acetate for 19 days correlates well with the reduced corticotropin content in the hypophysis that follows such therapy (Fortier, '59b). The less impressive structural changes elicited by dexamethasone can probably be related to the shorter treatment period (7 days).

*Specificity of the immunochemical procedure.* The results of all control experiments carried out indicate that the immunochemical staining method is specific for the demonstration of corticotropin. Particularly significant is the fact that absorption of anti-PC with corticotropin standard, or with rat pituitary fractions presumed to contain corticotropin, negated its effectiveness while absorption with non-hormonal protein or any of the other glycoprotein pituitary hormones failed to do so.

Particularly troublesome is the possible cross-reaction with melanocyte-stimulating hormone (MSH) because MSH and corticotropin possess a common core with an identical amino acid sequence. Information concerning the distribution of MSH in the rat pars distalis was not found; presumably it occurs in the pars intermedia. Cross-reaction between the two hormones is indicated by the fact that the pars intermedia stained more intensely than the pars nervosa and the general parenchyma of the pars distalis. Hess et al. ('68) also reported significant staining of the pars intermedia with antiserum to  $\beta^{1-24}$ -corticotropin. Additional study of the immunological interrelationship of MSH and corticotropin is needed.

The close relationship of corticotropin and thyrotropin, as well as of the cells producing these hormones, is indicated by extensive experimental data. First, evidence obtained from experimental endocrine alteration in rats indicates that both thyrotropin and corticotropin are produced

by basophils and that the latter hormone may be secreted by an aldehyde fuchsin-positive cell type (Halmi, '50). Dhom ('63) concluded that thyrotropin and corticotropin are produced by the same "system" of basophils. Second, as viewed with the electron microscope the ultrastructure of thyrotropin and corticotropin cells is somewhat similar, especially with respect to size of cytoplasmic granules, making their differentiation hazardous with this instrument (Herlant and Klastersky, '63; Siperstein and Allison, '65; Kurosumi and Kobayashi, '66). Third, as determined by assay of pituitary fractions, thyrotropin is associated with cytoplasmic granules about 140 m $\mu$  in diameter; corticotropin is associated with granules no larger than 140 m $\mu$  or with smaller particulates (Hymer and McShan, '63). The successful delineation of corticotropin and thyrotropin cells stained side by side with the Nakane-Pierce procedure lends strong support to the concept that corticotropin and thyrotropin are produced by separate cells. However, it remains uncertain whether the anti-HTSH used revealed other basophilic cell types in addition to the thyrotropin cell.

In conclusion, the evidence presented herein, in addition to the immunofluorescent, electron microscopic and fractionation studies of other workers, indicates that the corticotropin cell of the rat possesses a unique morphology, is more prominent in the female than in the male, and responds predictably to alteration in the level of pituitary corticotropin. Although the cell stains with aldehyde fuchsin, its weak and irregular reaction to the PAS procedure suggests that additional study is needed before the corticotropin cell can be included among the basophil cells as they have been identified previously with chemical staining procedures.

#### LITERATURE CITED

- Baker, B. L., A. R. Midgley, Jr., B. E. Gersten and Y.-Y. Yu 1969 Differentiation of growth hormone- and prolactin-containing acidophils with peroxidase-labeled antibody. *Anat. Rec.*, 164: 163-171.
- Dhom, G. 1963 Fortschritte der Histophysiologie des Hypophysenvorderlappens. *Klin. Wschr.*, 41: 1117-1125.
- Emery, F. E., and C. A. Winter 1934 The adrenotropic substance of the hypophysis as influenced by age, castration, sex and thyroparathyroidectomy. *Anat. Rec.*, 60: 381-390.
- Finerty, J. C., and B. Briseno-Castrejon 1949 Quantitative studies of cell types in the rat hypophysis following unilateral adrenalectomy. *Endocrinology*, 44: 293-300.
- Fortier, C. 1959a Pituitary ACTH and plasma free corticosteroids following bilateral adrenalectomy in the rat. *Proc. Soc. Exp. Biol. Med.*, 100: 13-16.
- 1959b Effect of hydrocortisone on pituitary ACTH and adrenal weight in the rat. *Proc. Soc. Exp. Biol. Med.*, 100: 16-19.
- Gemzell, C. A., D. C. Van Dyke, C. A. Tobias and H. M. Evans 1951 Increase in the formation and secretion of ACTH following adrenalectomy. *Endocrinology*, 49: 325-336.
- Hachmeister, U., and J. Kracht 1965 Antigene Eigenschaften von  $\beta^{1-24}$ -Corticotropin. *Virch. Arch. path. Anat.*, 339: 254-261.
- Halmi, N. S. 1950 Two types of basophils in the anterior pituitary of the rat and their respective cytophysiological significance. *Endocrinology*, 47: 289-299.
- Herlant, M. 1964 The cells of the adenohypophysis and their functional significance. *Int. Rev. Cytol.*, 17: 299-382.
- Herlant, M., and J. Klastersky 1963 Étude au microscope électronique des cellules corticotropes de l'hypophyse. *C. R. Acad. Sci. (Paris)*, 256: 2709-2711.
- Hess, R., D. Barratt and J. Gelzer 1968 Immunofluorescent localization of  $\beta$ -corticotropin in the rat pituitary. *Experientia*, 24: 584-585.
- Hymer, W. C., and W. H. McShan 1963 Isolation of rat pituitary granules and the study of their biochemical properties and hormonal activities. *J. Cell Biol.*, 17: 67-86.
- Kitay, J. I. 1963 Pituitary-adrenal function in the rat after gonadectomy and gonadal hormone replacement. *Endocrinology*, 73: 253-260.
- Kracht, J., H.-J. Breustedt and U. Hachmeister 1965 Immunohistologische Befunde mit Anti- $\beta^{1-24}$ -Corticotropin am Hypophysenvorderlappen der Ratte. *Naturwissenschaften*, 52: 432.
- Kurosumi, K., and Y. Kobayashi 1966 Corticotrophs in the anterior pituitary glands of normal and adrenalectomized rats as revealed by electron microscopy. *Endocrinology*, 78: 745-758.
- Leznoff, A., J. Fishman, M. Talbot, E. E. McGarry, J. C. Beck and B. Rose 1962 The cytological localization of ACTH in the human pituitary. *J. Clin. Invest.*, 41: 1720-1724.
- Marshall, J. M. 1951 Localization of adrenocorticotrophic hormone by histochemical and immunochemical methods. *J. Exp. Med.*, 94: 21-30.
- Nakane, P. K. 1968 Simultaneous localization of multiple tissue antigens using the peroxidase-labeled antibody method: a study on pituitary glands of the rat. *J. Histochem. Cytochem.*, 16: 557-560.
- Nakane, P. K., and G. B. Pierce, Jr. 1967 Enzyme-labeled antibodies for the light and electron microscopic localization of tissue antigens. *J. Cell Biol.*, 33: 307-318.

- Pearse, A. G. E., and S. van Noorden 1963 The functional cytology of the human adenohypophysis. *Canad. Med. Assoc. J.*, 88: 462-471.
- Reichert, L. E., Jr., M. Arnott, D. N. Ward, G. D. Niswender and A. R. Midgley, Jr. 1969 Isolation and properties of subunits of bovine pituitary luteinizing hormone. *J. Biol. Chem.*, 244: 5110-5117.
- Siperstein, E. R. 1963 Identification of the adrenalcorticotrophin-producing cells in the rat hypophysis by autoradiography. *J. Cell Biol.*, 17: 521-546.
- Siperstein, E. R., and V. F. Allison 1965 Fine structure of the cells responsible for secretion of adrenocorticotrophin in the adrenalectomized rat. *Endocrinology*, 76: 70-79.
- Sydnor, K. L., and G. Sayers 1954 Blood and pituitary ACTH in intact and adrenalectomized rats after stress. *Endocrinology*, 55: 621-636.

All photographs were taken with Kodak no. 15 and 58 filters. C, corticotropin cell; S, sinusoid; T, thyrotropin cell; B, basophil; G, growth hormone cell.

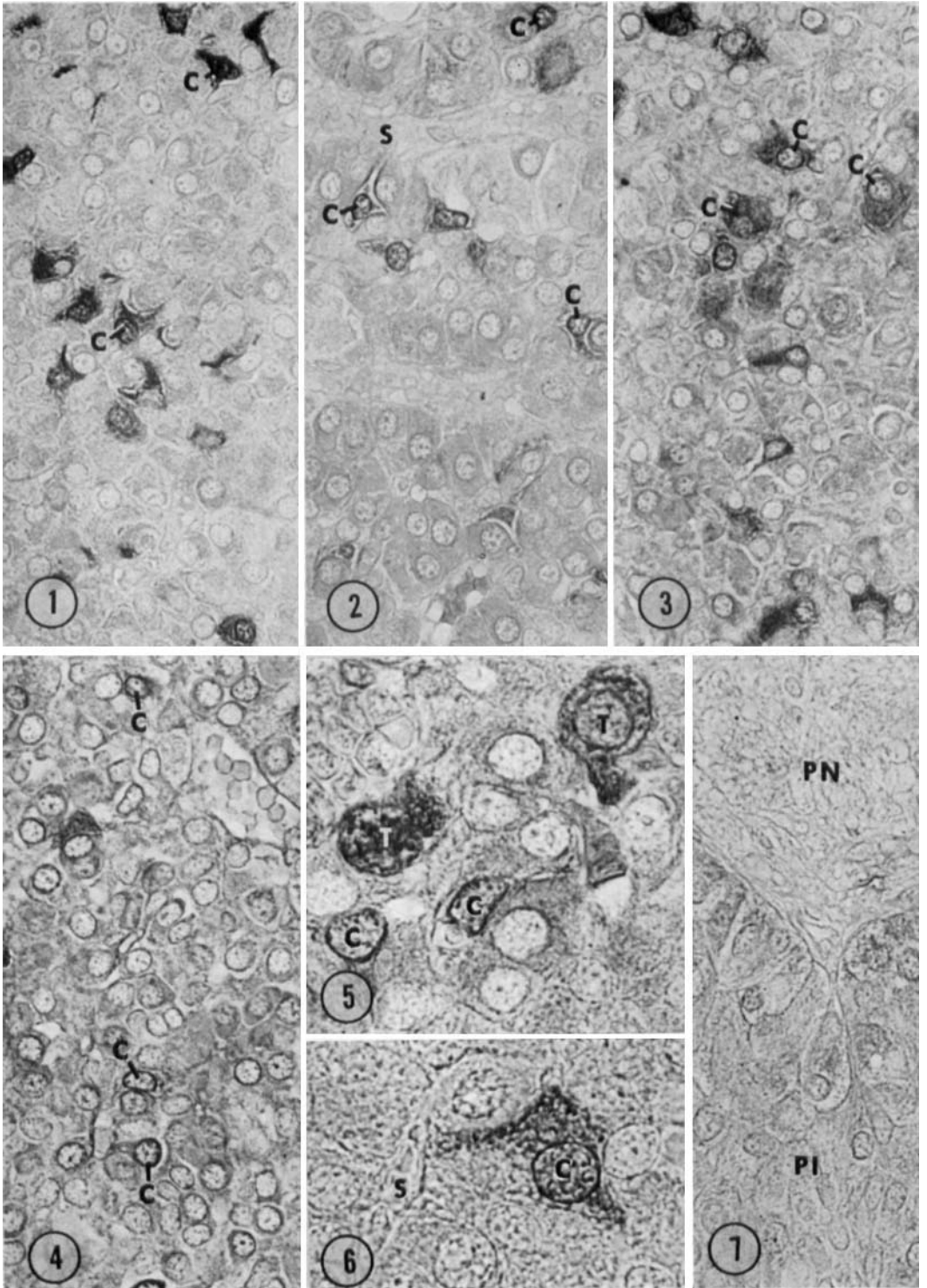
## PLATE 1

### EXPLANATION OF FIGURES

The areas illustrated in figures 1-4 were located somewhat anterior to the central region of the lateral lobe of the hypophyseal pars distalis. These sections were treated with anti-PC and DAB was used as the substrate to reveal the location of peroxidase-labeled antibody. They were treated subsequently with  $\text{OsO}_4$  which accounts for much of the background staining.  $\times 480$ .

- 1 Female. Corticotropin cells are intensely stained, of irregular shape and sometimes cup around neighboring cells.
- 2 Male. Corticotropin cells are smaller and less intensely stained than in the female (fig. 1). Cytoplasmic processes are often visible extending from cell bodies toward a sinusoid. Note contraction of cytoplasm in some cells.
- 3 Male hypophysis seven days after adrenalectomy. As compared with the normal male (fig. 2), corticotropin cells are greatly enlarged and have denser cytoplasm.
- 4 Female hypophysis after treatment with cortisol acetate for 19 days. Corticotropin cells (arrows) are so reduced in size that they are barely identifiable.
- 5 Female. Corticotropin cells (golden) were stained immunochemically with DAB serving as the peroxidase substrate. Thyrotropin cells (rose) were stained immunochemically, anti-HSTH being used with  $\alpha$ -naphthol serving as the peroxidase substrate.  $\times 1000$ .
- 6 Female. Corticotropin cell showing a cytoplasmic process ending on a sinusoidal wall. Although the general cytoplasm is stained, darker granules are grouped at the periphery of the cell. Immunochemically stained with  $\alpha$ -naphthol-pyronin.  $\times 1200$ .
- 7 Female. Magnification and preparation as for figures 1-4. The pars intermedia is stained somewhat darker than the background of figure 1.





## PLATE 2

### EXPLANATION OF FIGURES

- 8 Female. Corticotropin cells were stained immunochemically with  $\alpha$ -naphthol-pyronin being used.  $\times 1000$ .
- 9 The section illustrated in figure 8 was destained and then restained with aldehyde fuchsin and Masson. All corticotropin cells are stained with aldehyde fuchsin in addition to a larger cell (T) which was unstained in figure 8.
- 10 Female. Corticotropin cells were stained immunochemically with  $\alpha$ -naphthol-pyronin being used.  $\times 1000$ .
- 11 A section adjacent to that illustrated in figure 10 was stained with PAS and hematoxylin. The two corticotropin cells ( $C_1$ ,  $C_2$ ) shown in figure 10 are here lightly PAS-positive and contain fine cytoplasmic granules.  $\times 1000$ .
- 12 Female. After corticotropin cells were stained immunochemically, the slide was decolorized and then restained with PAS. Illustrated is a more intense reaction of the corticotropin cells to PAS than that shown in figure 11.
- 13 Female. The typically more intense reaction to PAS of certain basophils other than corticotropin cells is illustrated.  $\times 1000$ .

