

OLFACTORY CONNECTIONS IN THE ALBINO RAT, WITH SPECIAL REFERENCE TO THE STRIA MEDULLARIS AND THE ANTERIOR COMMISSURE

ELISHA S. GURDJIAN

Department of Anatomy, University of Michigan

EIGHTEEN FIGURES

CONTENTS

Introduction	128
Olfactory bulb	129
Accessory olfactory bulb	129
Lateral olfactory stria	132
Medial olfactory stria	134
Commissura anterior	135
Interbulbar component	136
Intertemporal component	136
Summary of the interbulbar and the intertemporal components of the anterior commissure	138
Fibers between the bed nuclei of the anterior commissure.....	140
Stria terminalis component of the anterior commissure.....	140
Nucleus olfactorius anterior	142
Tuberculum olfactorium	143
Basal olfactory areas of the medial wall of the hemisphere.....	144
Medial forebrain bundle	146
Stria medullaris	148
Medial cortico-habenular tract	150
Septo-habenular tract	151
Connections with the stria terminalis	151
Connections with the bed nuclei of the stria terminalis and the anterior commissure	152
Lateral olfacto-habenular tract	152
Medial olfacto-habenular tract	152
Lateral cortico-habenular tract	154
Summary of the components of the stria medullaris	154
Course of the stria medullaris	155
Habenula	155
Medial habenular nucleus	156
Lateral habenular nucleus	156
Bed nucleus of the habenular commissure	157
Habenulo-peduncular tract	157

Stria terminalis	157
Supracommissural portion	157
Commissural portion	158
Preoptic component	158
Fibers to the bed nucleus of the stria terminalis	159
Fibers to the bed nucleus of the anterior commissure	159
Fibers to the stria medullaris	159
Bed nucleus of the stria terminalis	160
Conclusions	161
Literature cited	162

INTRODUCTION

Our goal is a study of the mammalian thalamus. In preparation for such a study it was necessary to become familiar with the olfactory connections in forms to be studied. In the present paper we have described several of these olfactory fiber connections in the albino rat brain, since these tracts seemed to present certain interesting features. We have laid special emphasis on the consideration of the stria medullaris and the anterior commissure. This paper treats primarily of fiber connections. The nuclear structure has been considered in so far as it is necessary for an understanding of the fiber tracts described.

The material so far prepared consists of the following series: 1) Three series of albino rat's brain prepared according to Huber's modification of the Ranson pyridine-silver method (Huber and Guild, '13). These series are cut in three planes: transverse, sagittal, and horizontal. 2) A transverse series of the brain of the albino rat, prepared according to a modification of Cajal's silver method. 3) A transverse series of the albino rat's brain fixed in alcohol and stained in toluidin blue.

I am indebted to Professor Huber and Dr. Elizabeth Crosby for encouragement and material aid rendered throughout this study, which was submitted as partial fulfillment of the requirement for the degree of Master of Science, Graduate School, University of Michigan.

OLFACTORY BULB

In the rat the olfactory bulb is separated on its dorsal aspect from the rest of the brain by the rhinic fissure. The olfactory bundles surround the bulb on all sides except dorsally, in which region they are much more scanty (fig. 1). Next to the fiber layer is found the layer of glomeruli (fig. 1). This layer fades quite rapidly on the lateral aspect of the bulb, while ventrally and medially one can follow it caudad to the plane of the accessory olfactory bulb. The next layer is that of the mitral cells, which, as in the case of the glomerular layer, ceases first on the lateral side of the bulb and later on the ventral and the medial aspects. The granular layer (figs. 1, 2) is the next layer in succession and follows closely the others described. It also disappears first on the lateral aspect of the bulb, while dorso-medially it extends caudad to the region behind the accessory olfactory bulb.

From the foregoing account it will be seen that the structure of the olfactory bulb of the rat agrees in all essentials with that customarily described for vertebrates. The details of the finer structure and relations have received much attention from many observers (Golgi, '75; Cajal, '90, '02, and others). The literature on the subject is so generally reviewed in the larger texts on nervous anatomy (Dejerine, '01; Cajal, '11, for example) that it will not be considered in this paper.

ACCESSORY OLFACTORY BULB

The accessory olfactory bulb (fig. 2) is found on the dorsal aspect of the main bulb. It extends more medially than laterally and is surrounded by glomeruli on its dorsal aspect; a great many more being present dorsomedially than dorso-laterally. Bundles (vomeronasal nerves) reach this area mainly from the region between the two bulbs. Ventrally and laterally one does not see a glomerular zone. The accessory bulb causes an indentation on the olfactory bulb as also into the hemisphere with which it comes into relation ventrally and dorsally, respectively. In the region of this indentation

into the bulb, especially rostrally, the granular layer of the main bulb shows an infolding into which the accessory bulb projects (fig. 2). A zone of cells very much like the mitrals of the main bulb surrounds the accessory bulb rostrally and ventrally. Rostrally this layer forms a wall of cells oval in outline, while a little caudad to this plane these same cells become continuous with a layer of cells crescentic in outline with the concavity of the crescent directed toward the accessory bulb. This zone of cells has the form of a trough, with the long axis parallel to the horizontal plane.

The accessory bulb has certain analogies with the main bulb. From the description given above, it can be seen that, like the main bulb, it has a zone of olfactory nerve bundles, which, however, do not surround the entire accessory bulb as they do the main bulb, but are found dorsally, dorso-medially, and dorsolaterally. It has a glomerular zone which in general follows the olfactory nerve zone. Thus no glomeruli are seen ventrally, ventromedially, and ventrolaterally. It presents next a zone of cells which appear very much like the mitral cells and are homologous structures. The accessory bulb does not present a granular zone internal to the mitral cells as does the olfactory bulb proper. The accessory olfactory bulb is approximately oval in outline, with its long axis placed in the long axis of the brain. The rostral extreme is in a plane with the rostral extreme of the secondary lateral olfactory area of the bulb. Caudad it extends as far as a plane just behind the granular zone on the dorsomedial aspect of the main bulb.

The accessory olfactory bulb has been identified in a number of mammalia. Cajal ('02, '11) both described and figured it in the mouse, rabbit, and guinea-pig. He studied its cellular structure in Golgi material and states that it receives a special bundle of nerve fibers. McCotter ('17) demonstrated that the accessory bulb in the frog and turtle is concerned with the vomeronasal apparatus and Herrick ('21) pointed out that, in the frog, this accessory bulb is connected with the nucleus amygdalae by a special tract.

Our material is not favorable for determining the peripheral distribution of the distinct bundle of fibers which reaches the accessory bulb in the rat. McCotter ('14), how-

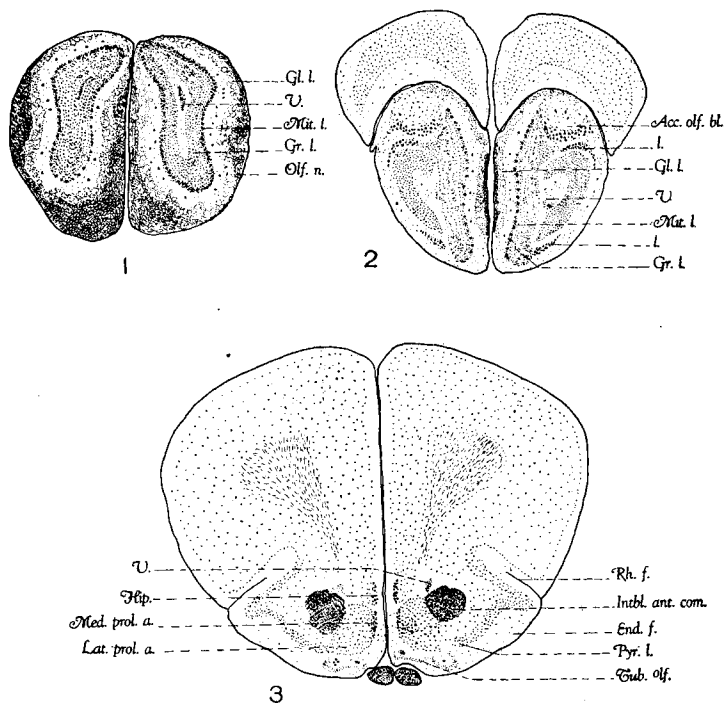


Fig. 1 Toluidine-blue preparation. Cross-section through the middle of the olfactory bulb. *Gl.l.*, glomerular layer; *Gr.l.*, granular layer; *Mit.l.*, mitral cell layer; *Olf.n.*, olfactory nerve; *V.*, ventricle.

Fig. 2 Toluidine-blue preparation. Cross-section through the middle third of the accessory bulb. *Acc.olf.bl.*, accessory olfactory bulb; *Gl.l.*, glomerular layer; *Gr.l.*, granular layer; *V.*, ventricle. Note the lateral aspect of the main bulb showing the continuation forward of the pyriform lobe area (the rostral extreme of the anterior olfactory nucleus according to Herrick, '24). Just lateral to this area note the layer of cells labeled 'l.' (In position this layer corresponds to what has been described in the opossum by Herrick, '24) and named 'nucleus olfactorius anterior pars externa.')

Fig. 3 Toluidine-blue preparation. Cross-section passing through the rostral third of the tuberculum olfactorium. *End.f.*, endorhinal fissure; *Hip.*, hippocampus; *Intbl.ant.com.*, interbulbar component of the anterior commissure; *Lat.prol.a.*, lateral parolfactory area, Johnston (nucleus accumbens, Kappers, Hines, and others); *Med.prol.a.*, medial parolfactory area (Johnston); *Pyr.l.*, pyriform lobe; *Rh.f.*, rhinic fissure; *Tub.olf.*, tuberculum olfactorium; *V.*, ventricle. Note the characteristic figure-three portion of the tuberculum olfactorium.

ever, demonstrated that the vomeronasal nerves in the rat go to the accessory bulb. Its caudad connections, so far as our preparations show them, are mainly with the lateral stria, which in turn terminates in part in the amygdaloid region. This suggests, of course, by analogy that in the rat, as in the frog, the accessory bulb is related with the vomeronasal apparatus and the amygdaloid complex.

LATERAL OLFACTORY STRIA

The lateral olfactory stria is first evident on the lateral aspect of the olfactory bulb in its middle third (fig. 2). In the more rostral portion the tract extends over the whole lateral boundary of the bulb in a plane outside of the glomerular zone. The fibers that make up this tract come from the main bulb, especially its dorsomedial portion, and from the accessory bulb, most of the fibers of which contribute to the formation of this tract. A little more caudad the tract is more compact and somewhat oval in outline and now comes in relation with the rostral continuation of the pyriform lobe region (fig. 2), the bulbar secondary lateral olfactory area. The bulbar portion of this rostral continuation of the pyriform lobe is the most anterior prolongation of the secondary olfactory areas of the hemisphere.¹ It appears in the same plane as the rostral border of the accessory olfactory bulb. It constitutes about one-third the thickness of the bulb, and as it passes out of the bulb into the hemisphere proper, it becomes flattened, and as the lateral olfactory stria becomes larger and larger due to the continuous addition of fibers, the gray mass undergoes an invagination into which the lateral stria penetrates. From here caudad the lateral olfactory stria lies in intimate relation with the pyriform lobe area which soon takes on the characteristic cortex structure of the pyriform lobe. (This whole bulbar secondary lateral olfactory area may be considered as a relatively less differentiated rostral continua-

¹ See foot note page 142.

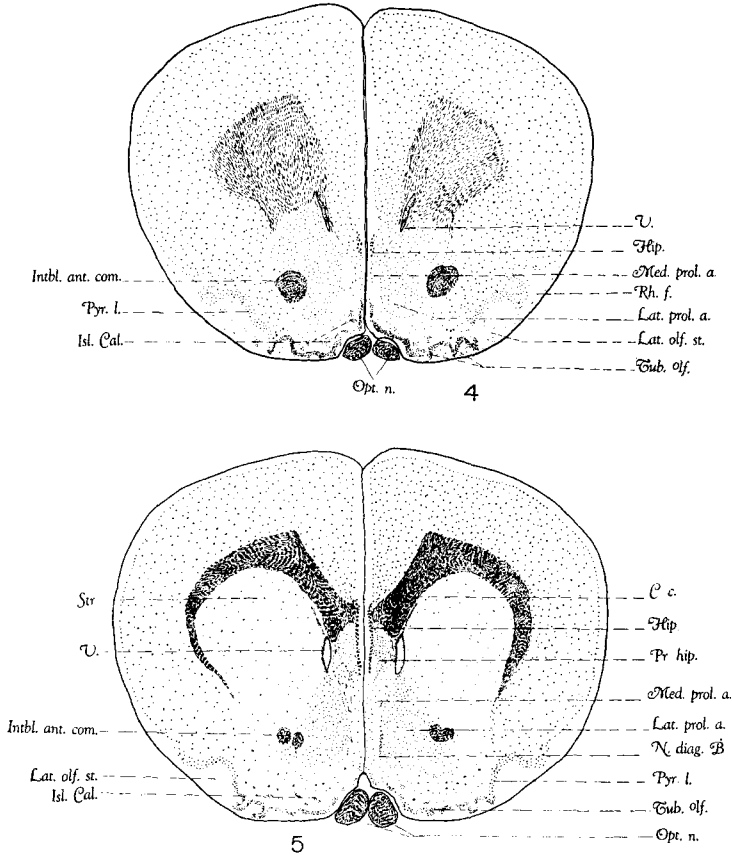


Fig. 4 Toluidine-blue preparation. Cross-section passing through the middle third of the tuberculum olfactorium. *Hip.*, hippocampus; *Intbl.ant.com.*, interbulbar component of the anterior commissure; *Isl.Cal.*, islands of Calleja; *Lat.olf.st.*, lateral olfactory stria; *Lat.prol.a.*, lateral parolfactory area; *Med.prol.a.*, medial parolfactory area; *Opt.n.*, optic nerve; *Pyr.l.*, pyriform lobe area; *Rh.f.*, rhinc fissure; *Tub.olf.*, tuberculum olfactorium; *V.*, ventricle. Note the crumpled appearance of the tuberculum olfactorium.

Fig. 5 Toluidine-blue preparation. Cross-section passing through the caudal third of the tuberculum olfactorium. *C.c.*, corpus callosum; *Hip.*, hippocampus; *Intbl.ant.com.*, interbulbar component of the anterior commissure; *Isl.Cal.*, islands of Calleja; *Lat.prol.a.*, lateral parolfactory area; *Med.prol.a.*, medial parolfactory area; *N.diag.B.*, nucleus of the diagonal band; *Opt.n.*, optic nerve; *Pr.hip.*, primordium hippocampi; *Tub.olf.*, tuberculum olfactorium; *V.*, ventricle.

tion of the pyriform lobe.) The relations are shown in figures 2 to 5 and 7 to 10.

That many fibers of the tract end in the pyriform lobe region is brought out by the fact that the bundle grows progressively smaller as one passes caudad. Behind the plane of the anterior commissure this tract comes into relation with a nuclear mass on the ventromedial aspect of the hemisphere, probably the nucleus of the lateral olfactory tract. Many of the fibers of the stria are directed toward this nuclear mass, and undoubtedly make connections here. After the disappearance of this nuclear mass the stria is greatly reduced in size and somewhat scattered. A little more caudad it sends a tract medially which courses next to the periphery of the hemisphere and then turns dorsally on the lateral aspect of the optic tract. The further course of these fibers is not definitely determined; they probably go to the amygdaloid complex. In this plane the lateral stria is greatly reduced in size. However, it passes caudad for a considerable distance and, in our preparations, disappears in the plane of the middle third of the amygdaloid complex.

MEDIAL OLFACTORY STRIA

The medial olfactory stria, so far as it is impregnated in our preparations, does not form a compact bundle, but consists of small groups of fibers which appear to supply the medial wall of the hemisphere, including the medial aspect of the tuberculum olfactorium, the parolfactory area of Johnston (precommissural portion of the septum, according to Kappers, Hines, and others), the septum proper, and the anterior continuation of the hippocampus, at least. The description of the stria given here for rat corresponds with that generally accepted for vertebrates. It has been described in more or less detail for many types (Dejerine, '01; Herrick, '10; Cajal, '11; Edinger, '11, and others).

COMMISSURA ANTERIOR

A complete review of the literature dealing with the anterior commissure is beyond the scope of the present paper. Such a review is found in the larger texts on nervous anatomy (Dejerine, '01; Cajal, '11, and others). We here quote Cajal ('02) for his extensive description of the olfactory and the temporal components of the anterior commissure in the mouse. In the bulb he found that the olfactory component was divisible into inner, middle, and outer portions, the

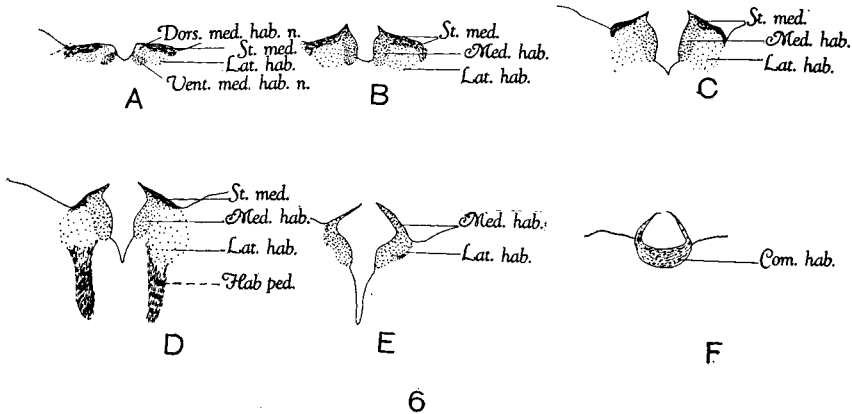


Fig. 6 Toluidine-blue preparation. Cross-sections through six different planes of the habenula. They are labeled alphabetically from above downward. *Dors.med.hab.n.*, dorsomedial portion of the medial habenular nucleus; *Hab.com.*, habenular commissure and its bed nucleus; *Hab.ped.*, habenulo-peduncular tract (Meynert's); *Lat.hab.*, lateral habenular nucleus; *Med.hab.*, medial habenular nucleus; *St.med.*, stria medullaris; *Vent.med.hab.n.*, ventromedial portion of the medial habenular nucleus.

middle one being by far the largest. The fibers from these different sources ran horizontally caudad, anterior to the intertemporal component, and swept back into the opposite bulb. The stria terminalis component of the anterior commissure was also seen and described by Cajal. Of the precise origin and termination of the intertemporal component he confesses his ignorance.

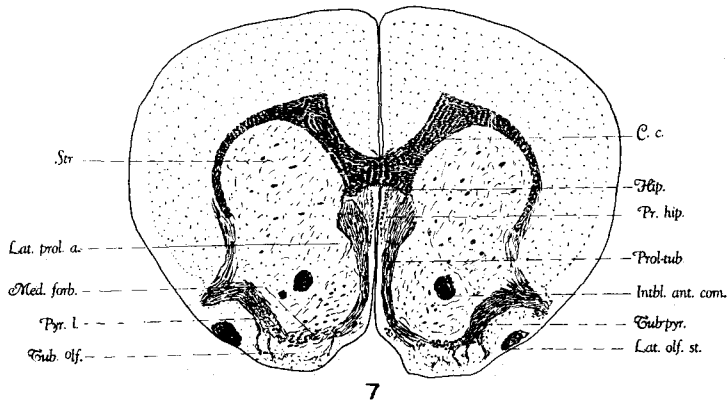
The most interesting account of the components of the anterior commissure so far as it relates to our own findings is

that illustrated and briefly described in the Edinger text (1911 edition, pp. 388-9). The figure is a horizontal section of the brain of *Didelphys marsupialis*, and it shows particularly a component of the anterior commissure which reaches the region of the hippocampal gyrus. The following quotation ('11, p. 399) suggests his idea of the function of this component: "Beide gyri hippocampi sind untereinander verbunden durch das kaudale Bündel der Commissura anterior, beide Cornua Ammonis durch das Psalterium." An account of the components of the anterior commissure, as we have been able to observe them in the adult rat, follows:

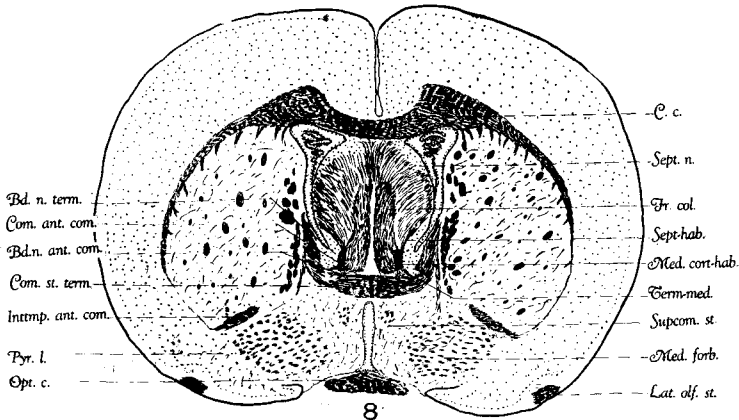
Interbulbar component. The strictly interbulbar portion of the anterior commissure has in the rat the characteristic horseshoe appearance described for it in various mammals (fig. 14). That this portion carries only commissural fibers between the bulbs the experimental findings of other observers appear to indicate (Cajal, '11). The course of certain fiber bundles as seen in our rat material gives reason for doubt as to the purely commissural nature of this component. However, further experimental observations will be necessary to enable one to reach definite conclusion on this matter. Associated with this purely interbulbar component there is a narrow band of fibers placed on its lateral aspect (fig. 14) which interconnects the lateral olfactory areas of the hemisphere just lateral to the bulb.

Intertemporal component (figs. 8 to 10, 14, and 18). In considering the intertemporal component of the anterior commissure it is of interest to note that in our sagittal series this component has different staining properties than has the interbulbar portion. In our series it presents a lighter, golden-yellow color, while the other component is much darker. Figure 18 illustrates the relative size of the different components of the anterior commissure.

The intertemporal component is most easily traced in a series of horizontal sections. Beginning at the point of junction of the two hemispheres, it can be seen coursing horizontally lateralward (figs. 14 to 16). At the rostral angle formed



7



8

Fig. 7 Modified Cajal preparation. Cross-section through the middle third of the tuberculum olfactorium. *C.c.*, corpus callosum; *Hip.*, hippocampus; *Intbl.ant.com.*, interbulbar component of the anterior commissure; *Lat.olf.st.*, lateral olfactory stria; *Lat.prol.a.*, lateral parolfactory area; *Med.forb.*, medial forebrain bundle; *Pr.hip.*, primordium hippocampi; *Prol-tub.*, parolfacto-tubercular tract; *Pyr.l.*, pyriform lobe area; *Str.*, striatum; *Tub-pyr.*, tuberculo-pyriformic tract.

Fig. 8 Modified Cajal preparation. Cross-section through the caudal third of the anterior commissure. *Bd.n.ant.com.*, bed nucleus of the anterior commissure; *Bd.n.term.*, bed nucleus of the stria terminalis; *C.c.*, corpus callosum; *Com.ant.com.*, commissural fibers between the bed nuclei of the anterior commissure; *Com.st.term.*, commissural portion of the stria terminalis; *Fr.col.*, fornix column; *Inttmp.ant.com.*, intertemporal component of the anterior commissure; *Lat.olf.st.*, lateral olfactory stria; *Med.cort.hab.*, medial cortico-habenular tract; *Med.forb.*, medial forebrain bundle; *Opt.c.*, optic commissure; *Pyr.l.*, pyriform lobe area; *Sept.hab.*, septo-habenular tract; *Sept.n.*, septal nucleus (lateral); *Supcom.st.*, supra-commissural portion of the stria terminalis.

by it and the interbulbar component a fair-sized bundle is given off (figs. 14 and 15) which runs rostrolaterally with the concavity medially, reaches the region of the pyriform lobe a little lateral to the interbulbar component. In our series this bundle is well impregnated on both sides. The main bundle then presents a rostral concavity and courses laterally through the striatum. In its course through this region it sends out three branches which run laterally and rostrally and reach the pyriform lobe region from before backward at different levels (fig. 16). The main more caudal bundle can be traced to the medial boundary of the temporal cortex (fig. 16), where it becomes surrounded and infiltrated with a nuclear mass which is probably a part of the amygdaloid complex. At this point the majority of the fibers turn caudad, very few fibers curving rostrally, while some of them run ventrally and others dorsally, and supply the surrounding area. The fibers which run caudad are found at the medial border of the temporal cortex and can be followed back in this position to the lateral border of the hippocampus (fig. 16). This is the same component as that described by Edinger for marsupials and to which reference was made in the account of the literature. The fact that the bundle grows progressively smaller as one follows it caudad makes it evident that it supplies the whole area of the pyriform lobe. We have been unable to trace definitely any fibers into the hippocampus proper, and our observations tend to support Edinger's ('11) conclusion that this component is associated with the gyrus hippocampi rather than hippocampus proper.

Summary of the interbulbar and the intertemporal components of the anterior commissure. From the above description of the interbulbar and the intertemporal components of the anterior commissure it is clear that in the rat their rôle must be a very important one. It can be seen that by means of these components the lateral olfactory areas of the bulb and the hemisphere on the two sides are interrelated throughout their entire extent by commissural and probably

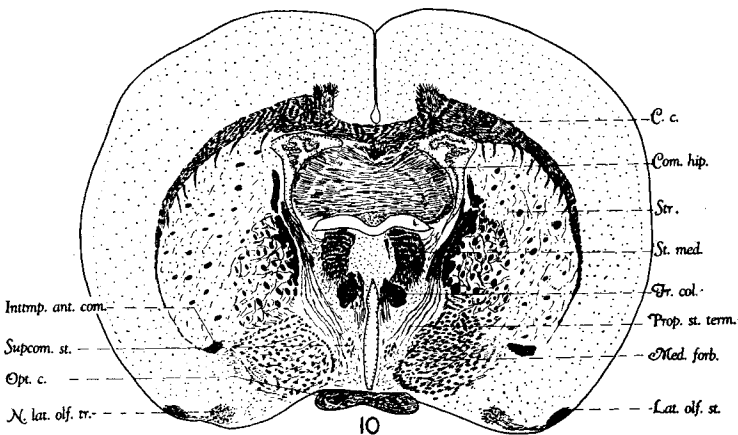
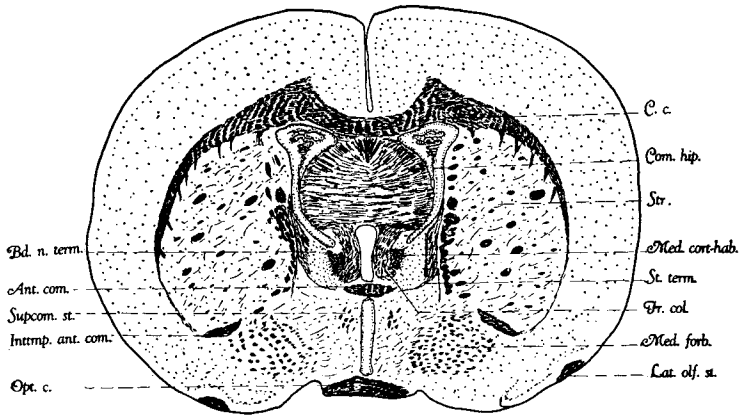


Fig. 9 Modified Cajal preparation. Cross-section passing through the caudal aspect of the anterior commissure. *Ant.com.*, anterior commissure; *Bd.n.term.*, bed nucleus of the stria terminalis; *C.c.*, corpus callosum; *Com.hip.*, commissura hippocampi; *Fr.col.*, fornix column; *Inttmp.ant.com.*, intertemporal component of the anterior commissure; *Lat.olf.st.*, lateral olfactory stria; *Med.cort-hab.*, medial cortico-habenular tract; *Med.forb.*, medial forebrain bundle; *Opt.c.*, optic commissure; *Str.*, striatum; *St.term.*, stria terminalis; *Supcom.st.*, supra-commissural portion of the stria terminalis.

Fig. 10 Modified Cajal preparation. Cross-section passing through the extreme rostral end of the diencephalon. *C.c.*, corpus callosum; *Com.hip.*, commissura hippocampi; *Fr.col.*, fornix column; *Inttmp.ant.com.*, intertemporal component of the anterior commissure; *Lat.olf.st.*, lateral olfactory stria; *Med.forb.*, medial forebrain bundle; *N.lat.olf.tr.*, nucleus of the lateral olfactory tract; *Opt.c.*, optic commissure; *Prop.st.term.*, preoptic component of the stria terminalis; *St.med.*, stria medullaris; *Str.*, striatum; *Supcom.st.*, supra-commissural portion of the stria terminalis.

decussating fibers as well, from the region of the olfactory bulbs to the posterior pole of the hemisphere.

Fibers between the bed nuclei of the anterior commissure. The interstitial or the bed nuclei of the anterior commissure are two in number, one on each side. Each consists (fig. 8) of a group of small nerve cells compactly placed and of circular outline. Laterally it is in relation with the bed nucleus of the stria terminalis, while dorsally it becomes continuous with the septal nuclei. The cells of the nuclei are smaller than those of strial bed. Fibers interrelating the two bed nuclei of the anterior commissure are found on the dorsal aspect of this commissure and form a part of the same. Among these there are also fibers that are not commissural in nature. The bed nuclei act as substations between the areas supplied by the various components of the anterior commissure, including the stria terminalis to be next described. They also may relate the centers supplied by these components with the habenula and the hippocampus through the synaptic relations of the medial cortico-habenular tract with these bed nuclei (see account of the stria medullaris).

Stria terminalis component of the anterior commissure. In our series the commissural portion of the stria terminalis presents a portion which is placed caudoventrally in relation to the other components of the anterior commissure (fig. 8). The caudoventral portion is undoubtedly that commissural portion of the stria terminalis which Johnston has described for various Mammalia and particularly for the opossum. Johnston ('23) regards this as representing a commissural connection between the bed nuclei of the lateral olfactory tracts. Our preparations are not favorable for determining this point in the rat.

In addition to this caudoventral portion of the stria terminalis component of the anterior commissure, our rat series presents a more dorsally placed bundle. This carries not only fibers between the bed nuclei of the anterior commissure, but also decussating fibers of the stria terminalis (fig. 8). This bundle is recognizable because of its lighter staining characteristics in our preparations.

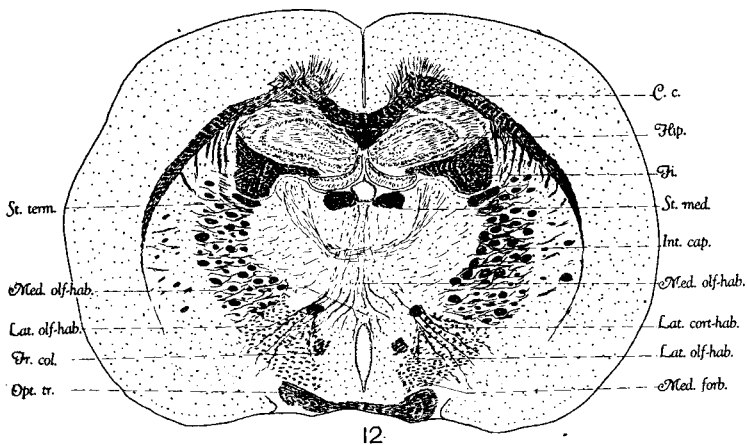
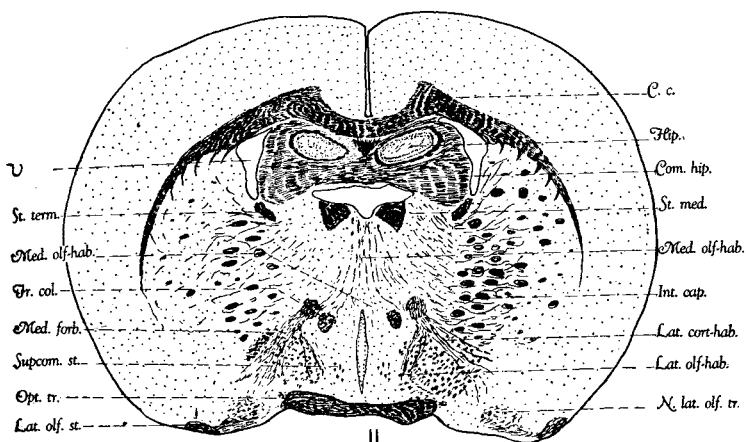


Fig. 11 Modified Cajal preparation. Cross-section passing through the rostral end of thalamus. *C.c.*, corpus callosum; *Com.hip.*, commissura hippocampi; *Fr.col.*, fornix column; *Hip.*, hippocampus; *Int.cap.*, internal capsule; *Lat.cort-hab.*, lateral cortico-habenular tract; *Lat.olf-hab.*, lateral olfacto-habenular tract; *Lat.olf.st.*, lateral olfactory stria; *Med.forb.*, medial forebrain bundle; *Med.olf-hab.*, medial olfacto-habenular tract; *N.lat.olf.tr.*, nucleus of the lateral olfactory tract; *Opt.tr.*, optic tract; *St.med.*, stria medullaris; *St.term.*, stria terminalis; *Supcom.st.*, supracommissural portion of the stria terminalis; *V.*, ventricle.

Fig. 12 Modified Cajal preparation. Cross-section passing through the extreme rostral end of the habenula. *C.c.*, corpus callosum; *Fi.*, fimbria; *Fr.col.*, fornix column; *Hip.*, hippocampus; *Int.cap.*, internal capsule; *Lat.cort-hab.*, lateral cortico-habenular tract; *Lat.olf-hab.*, lateral olfacto-habenular tract; *Med.forb.*, medial forebrain bundle; *Med.olf-hab.*, medial olfacto-habenular tract; *Opt.tr.*, optic tract; *St.med.*, stria medullaris; *St.term.*, stria terminalis.

NUCLEUS OLFACTORIUS ANTERIOR²

The anterior end of the basal olfactory area in the hemisphere is occupied by the nucleus olfactorius anterior. In the rat it has essentially the relations described for it in various other mammals by Johnston ('23). Consequently, the following account is a very brief one. In the rat it is found on the ventromedial border of the olfactory bulb between the junction of the secondary lateral and medial olfactory areas of that region. Dorsally it blends with both of them, but to a greater extent with the medial than the lateral. Most rostrally it is made up of a solid cord of cells of essentially the same type as those of the olfactory areas. Farther caudad this solid cord is hollowed out and the cells are more scattered so that we here deal with a conical structure, the apex of which is rostrally placed, while the base is caudad. The long axis of the cone is parallel to the long axis of the brain. The base of the cone is not circular, but assumes the character of a figure three (3) with the concavity dorsally. Caudad the area diminishes markedly in size in a plane with

²According to Herrick ('24), the nucleus olfactorius anterior in the opossum (*Didelphys virginiana*) extends as far forward as the "transverse plane of the rostral border of the accessory olfactory bulb." Farther caudad it encircles the ventricle at and about the crus. "Behind the olfactory crus the anterior nucleus spreads into the ventral part of the hemisphere. There is a considerable accumulation of cells above the rostral end of the tuberculum olfactorium around the rostro-ventral border of the head of the caudate nucleus. Farther spinalward the cells of this sheet become dispersed in the extensive area between the ventral border of the head of the caudate and the underlying tuberculum olfactorium."

It can thus be seen that the anterior olfactory nucleus as described by us constitutes a very small portion of the nucleus of the same name as defined by Herrick. Accordingly, his nucleus would include the anterior olfactory nucleus, the rostral prolongation of the pyriform lobe area and a portion of the undifferentiated gray matter extending through the crus into the olfactory bulb on the medial aspect of the latter structures of our description.

We were very fortunate in having access to a part of Doctor Obenchain's paper ('24, in press) on *Caenolestes*, through Professor Herrick's courtesy. This part deals with the anterior olfactory nucleus, pars externa (Herrick terminology). She has also described the same nucleus in the white rat. She concludes that the layer of cells just outside of the rostral prolongation of the anterior olfactory nucleus (Herrick terminology) is the pars externa of that same nucleus. Our figure 2 shows this layer of cells (labeled 'l').

the rostral end of the tuberculum olfactorium, with the deeper layer of which it is apparently continuous. It seems to us that in the rat the nucleus olfactorius anterior is differentiable from the caudate—a point in which the rat differs from the Mammalia described by Johnston.

TUBERCULUM OLFACTORIUM

The rostral end of the tuberculum olfactorium begins near the caudal end of the anterior olfactory nucleus and extends caudad to a region in the same transverse plane as the middle third of the anterior commissure. Between these two levels the tuberculum presents some variation in cell arrangement. At the two extremes the tuberculum has a relatively smooth gray surface, while in the intermediate area it appears as a greatly crumpled, plicated, or corrugated mass (figs. 3 to 5). Thus in the caudal aspect of the rostral third it presents at least two evaginations which give the appearance of a figure 3 with the convexity of the figure ventrally and with the long axis of the figure from side to side (fig. 3). Some of these outfoldings contain large multipolar nerve cells. Somewhat farther caudad the tuberculum is very much more crumpled and in three different regions its evaginations practically reach the ventral periphery of the brain (figs. 4 and 5). In this same region also are seen certain cell masses which are known as the islands of Calleja ('93). These islands of small nerve cells show central depressions and in our silver preparations nerve fibers can be seen emerging from the concavities (fig. 16). We have been able to distinguish clearly at least twelve of these islands in the rat. It is of interest to note that the largest and the most medially placed of these islands on either side (the island which is located next to the midline in the middle third of the tuberculum) presents on its medial aspect a concavity which surrounds a group of nerve cells somewhat larger than the average cells of the islands proper.

The tuberculum olfactorium presents a certain stratification (figs. 3 to 5) so that one can see a plexiform layer next to the periphery, next a layer of cells compactly placed, this

being three or four cells thick, and a third layer of loosely arranged nerve cells, among which are some relatively large multipolar cells. It is in this latter layer that the islands of Calleja are found. Miss Obenchain ('24) has described a structurally highly developed tuberculum in her interesting account of the brain of *Caenolestes*.

The tuberculum olfactorium receives terminal fibers of both the lateral and the medial striae. It is intimately interrelated with the pyriform lobe by a tuberculo-pyriformic tract (fig. 7) (which may also carry impulses in the opposite direction). Tuberculo-septal and probably septo-tubercular fibers relate it with the septal regions proper of the medial wall and the precommissural regions which are considered by some as septal and by others as parolfactory (see discussion of this area which follows). Some of the fibers interconnecting the septal and the tuberculum regions are probably accompanied by fibers to the latter area from the hippocampus. These constitute in all probability the tractus parolfacto-ammonicus of Edinger's description. The tuberculum also contributes fibers to the medial forebrain bundle (fig. 7).

BASAL OLFACTORY AREAS OF THE MEDIAL WALL OF THE HEMISPHERE

The relation of the basal olfactory areas on the medial wall of the hemisphere have been fully described by Johnston for a number of Mammalia. Among other drawings he has included six figures of the rat brain. As far as nuclear arrangement is concerned, the results obtained agree with those which he has figured. A detailed account of the cell masses in this region is therefore considered unnecessary for an understanding of the fiber masses we wish to describe and consequently aside from the purpose of this brief paper. Certain points, however, must be considered as regards nomenclature. Herrick ('10), Hines ('22), and Kappers ('21) consider the septal region in vertebrates and lower mammals and in embryonic human material to extend forward

and downward well toward the olfactory bulb. Kappers ('21) calls this the precommissural portion of the septum. It includes the lateral and medial septal nuclei of their description together with nucleus accumbens septi. Johnston regards these areas as in front of the human septum pellucidum and has applied the name area parolfactoria to them, using the terms lateral and medial parolfactory nuclei, the former of

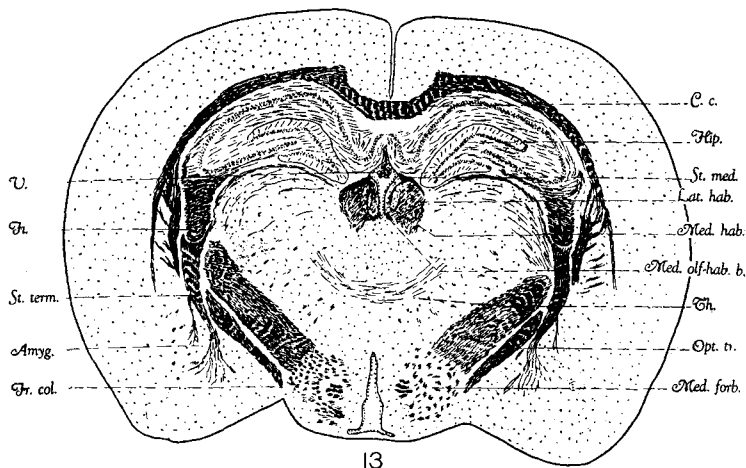


Fig. 13 Modified Cajal preparation. Cross-section passing through the middle third of the habenula. *Amyg.*, amygdaloid complex; *C.c.*, corpus callosum; *Fi.*, fimbria; *Fr.col.*, fornix column; *Hip.*, hippocampus; *Lat.hab.*, lateral habenular nucleus; *Med.forb.*, medial forebrain bundle; *Med.hab.*, medial habenular nucleus; *Med.olf-hab.b.*, the bundle of the medial olfacto-habenular tract; *Opt.tr.*, optic tract; *St.med.*, stria medullaris; *St.term.*, stria terminalis; *Th.*, thalamus.

which is the nucleus accumbens in part at least of the other terminology. In our material the nucleus parolfactorius medialis (this nucleus is not clearly differentiable from the nucleus of the diagonal band which is shown in the figure, but not discussed in the present paper) of Johnston's terminology (figs. 3 to 5) certainly extends far in front of the region designated as septum pellucidum in the human. Nevertheless, it may be that from its developmental relations to other structures of the medial wall the term septal may

still be applied to the area. We are not prepared to discuss the question as to which nomenclature is the better, nor does it seem to us that such a discussion is of vital importance in the description involved in this paper. In the more posterior region between the fornix and the hippocampal commissure and the corpus callosum, which every one concedes is septal, the two nuclei which Johnston has described and figured in the rat stand out clearly (Johnston, '11, p. 462, fig. 64). These nuclei are continuous with each other in front of the fornix columns. The small-celled medial one which forms a bed nucleus for the hippocampal commissure appears to be directly continuous with the primordium hippocampi in front. Johnston regards them as a differentiation of the primordial hippocampal tissue. It is from these undoubted septal nuclei that our tractus septo-habenularis arises (see account of the stria medullaris).

MEDIAL FOREBRAIN BUNDLE

The medial forebrain bundle in the rat may be identified as a relatively compact mass of fibers as far forward as the region of the tuberculum olfactorium (fig. 7), the fibers emerging from that nucleus and probably those entering it as well making up a considerable part of the bundle. The medial forebrain bundle also receives fibers from the par-olfactory area of Johnston and septal regions farther posterior. As it is followed caudad in the preoptic region it increases in size and probably is in synaptic relation with that region also. The position of the medial forebrain bundle as it passes caudad from the region of the tuberculum olfactorium is, at first, ventral to the anterior commissure and lateral to the ventricle (fig. 8). Then it enters the preoptic area and in the caudal part of this area approaches the lateral forebrain bundle or internal capsule (figs. 9 and 10). The fibers that leave the stria terminalis and descend ventromedially to reach the preoptic area are found medial to this bundle (fig. 10). A little farther caudad the lateral cortico-habenular fibers pass through this bundle and reach their

destination (fig. 11). The optic tract lies in close relation with this bundle in the ventromedial portion of its course (figs. 11 to 13). Farther caudad the descending fornix bundle is medial to and overlapped by the medial forebrain bundle (figs. 12 and 13). •This bundle can be followed as far caudad as the posterior end of the hypothalamic region,

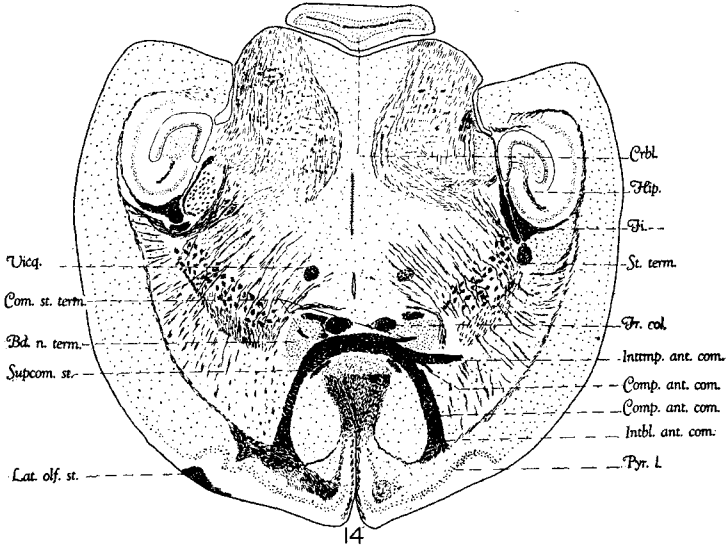


Fig. 14 Decalcified pyridine-silver preparation. Horizontal section passing through the plane of the middle third of the anterior commissure *Bd.n.term.*, bed nucleus of the stria terminalis; *Com.st.term.*, commissural portion of the stria terminalis; *Comp.ant.com.*, Component of the anterior commissure connecting lateral olfactory areas, note that there are two of these in this particular drawing; *Crbl.*, cerebellum; *Fi.*, fimbria; *Fr.col.*, fornix column; *Hip.*, hippocampus; *Intbl.ant.com.*, interbulbar component of the anterior commissure; *Inttmp.ant.com.*, intertemporal component of the anterior commissure; *Lat.olf.st.*, lateral olfactory stria; *St.term.*, stria terminalis; *Supcom.st.*, supra-commissural portion of the stria terminalis.

gradually diminishing in size as it passes caudad. We have not been able to follow definitely any of it into the mesencephalon as de Lange described for lower forms. The medial forebrain bundle has been described for various lower vertebrates (de Lange, '11; Herrick, '10; Crosby, '17; Hines, '23, and others). Johnston ('23) has figured but not described it in his late paper on the opossum.

STRIA MEDULLARIS

There has been considerable controversy over the relations and the components of the stria medullaris. Its position on the dorsomedial wall of the diencephalon has long been recognized, the tract going by various names, such as *linea alba* (Haller), the *Sehstreifen* (Burdach, 1819--26), and the *taenia thalami* (of many observers). Although its connection with the habenula was soon recognized, its relations with other centers were in dispute. Mendel ('89), after iridectomy in several mammals, described a partial atrophy of the habenular ganglion. Honegger ('90) also believed that there were pupillary fibers to the habenula by way of stria medullaris. Darkschewitch (according to Dejerine, '01) agreed with Mendel regarding the supposed connection of the habenula with the optic apparatus, but said that the fibers did not constitute a part of the stria medullaris. Dejerine ('01) stated that in his laboratory, working with rabbits and dogs, he had been unable to confirm the work of Honegger and his supporters. (Cajal ('94, '11) enucleated the whole eye of a mouse and demonstrated clearly that such an operation was not followed by a degeneration of the habenular ganglion. Many earlier observers (Lotheissen, '94, for example) believed that the stria medullaris carried fibers to the pineal body. Dejerine gave a relatively full account of the literature dealing with the stria and the habenula up to that time, and says in conclusion: "Le taenia thalami constitut en effet un faisceau fort complexe, dont les origines sont loin d'être complètement élucidées.")

Regarding the origin of the fibers of the stria medullaris, there still exists a considerable difference of opinion. Ganser ('81), by operative procedure in which he destroyed the tuber cinereum region in the cat, showed that fibers arising from the cortex with the fornix bundles separated from these in the region of the anterior commissure and ran caudad into the stria medullaris. Honegger ('90) confirmed this statement, and it is now generally accepted (Lotheissen, '94; Dejerine, '01; Edinger, '11, and others) for Mammalia as

well as for lower forms (Herrick, '10; Crosby, '17; Hines, '23, and others). Cajal ('11), however, was not able to follow this connection in his material. It is the tractus cortico-habenularis medialis of the present description. In ungulates, Honegger ('90) described a second tract from the fornix to the stria medullaris which ran internal to the

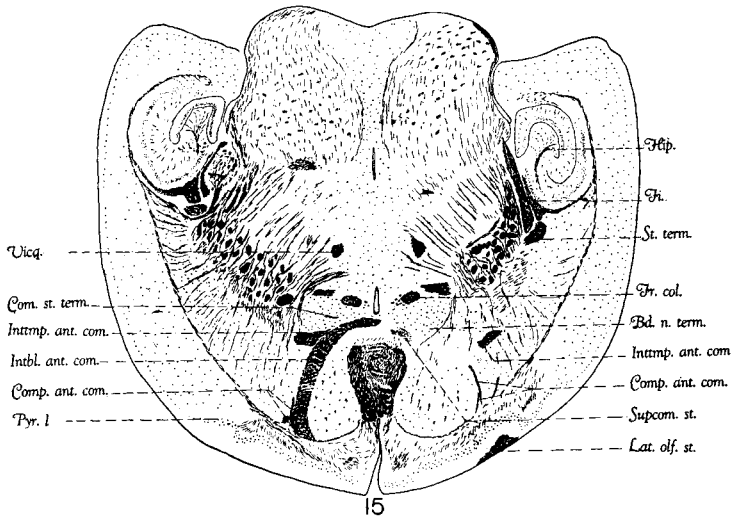


Fig. 15 Decalcified pyridine silver preparation. Horizontal section passing through the ventral third of the anterior commissure. *Bd.n.term.*, bed nucleus of the stria terminalis; *Comp.ant.com.*, component of the anterior commissure connecting lateral olfactory areas, note that there are four different ones of these in this particular section; *Fi.*, fimbria; *Fr.col.*, fornix column; *Hip.*, hippocampus; *Intbl.ant.com.*, interbulbar component of the anterior commissure; *Inttmp.ant.com.*, intertemporal component of the anterior commissure; *Lat.olf.st.*, lateral olfactory stria; *Pyr.l.*, pyriform lobe area; *St.term.*, stria terminalis; *Vicq.*, Vicq d'Azyr bundle.

anterior nucleus of the thalamus and entered the stria. Such a tract has never been confirmed so far as we know.

The ventral olfactory areas of the hemisphere have been designated in Mammalia and other vertebrate types under various names, such as the tuberculum olfactorium of many writers, 'das Kern des basalen Langsbundel' of Lotheissen, and the 'Lobus parolfactorius' of Edinger. This region is in general included in the higher mammals under the name

of the anterior perforated space, although the various names cannot be considered synonymous. Most observers are agreed that from this anterior perforated space there are fibers which enter the stria medullaris. Cajal ('11) believed that these arose as far forward as the peduncle of the olfactory bulb and termed the bundle 'the frontal olfactory projection tract.' Lotheissen ('94) and Dejerine ('01) described fibers from the septal regions to the stria—a connection which was questioned by Cajal ('11). Lotheissen further described connections with the tuber cinereum, explaining that fibers from this region enter the stria by both a medial and a lateral path. This description suggests in part at least the olfacto-habenular tracts of the present account. Since these tracts are not labeled in his drawings and are apparently not illustrated in his one section of the rat, we are not very certain of the homology. An account of the fiber connections of the stria medullaris now follows:

Medial cortico-habenular tract (figs. 8, 9). In all probability, the cells of origin for the medial cortico-habenular tract lie in the hippocampus. The fibers descend with the fornix columns in the region of the caudal one-third of the anterior commissure (fig. 8). They lie on the lateral aspect of the fornix, from which they are easily differentiated in silver preparations by their dark color. As the medial cortico-habenular tract separates from the fornix it is at first triangular in outline and is bounded on its lateral aspect by the bed nucleus of the stria terminalis, dorsally by the ventricle, and medially and ventromedially by the fornix columns. From this position it runs dorsomedially until it reaches the dorsomedial surface of the diencephalon and becomes the most dorsomedial constituent of the stria medullaris. From its dorsomedial position it may be safely assumed that it is particularly related to the medial habenular nucleus of the same side. This medial cortico-habenular tract is the one demonstrated by Ganser ('89) and generally accepted by observers since, with the exception of Cajal ('11).

Septo-habenular tract (fig. 8). In its course through the septal regions with the fornix fibers the medial cortico-habenular tract is bounded laterally and caudally by the large-celled septal nucleus previously mentioned under the description of the basal olfactory areas of the medial wall. A considerable bundle of fibers is added to the tract from this region. This is probably the septo-habenular tract of

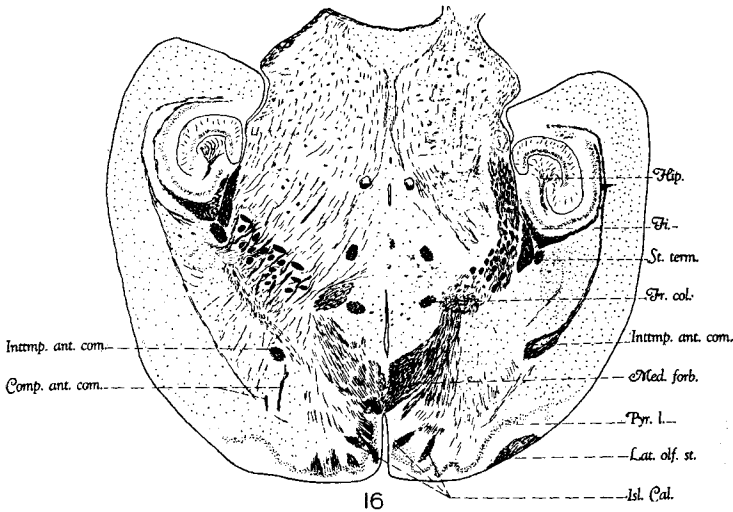


Fig. 16 Decalcified pyridine-silver preparation. Horizontal section passing through the region just ventral to the anterior commissure. *Comp.ant.com.*, component of the anterior commissure connecting lateral olfactory areas; *Fi.*, fimbria; *Fr.col.*, fornix column; *Hip.*, hippocampus; *Inttmp.ant.com.*, intertemporal component of the anterior commissure; *Isl.Cal.*, islands of Calleja; *Lat.olf.st.* lateral olfactory stria; *Med.forb.*, medial forebrain bundle; *Pyr.l.*, pyriform lobe area; *St.term.*, stria terminalis.

Dejerine ('01) which Cajal was not able to determine. We do not know the direction of conduction along this path.

Connections with the stria terminalis (figs. 8 and 9). Honegger ('90) and certain earlier workers described a connection of the stria terminalis and the stria medullaris. Kölliker and Lotheissen ('94) were skeptical of this relation. Johnston, in his recent paper ('23), has described such a connection in the opossum and we have seen it in our rat material.

There are fibers that leave the stria terminalis and pass through the bed nucleus of the same and join the medial cortico-habenular component of the stria medullaris. This occurs at the level of the decussation of the stria terminalis in the anterior commissure (see previous account). In the rat the tract is not a very compact one and is apparently smaller than that described for the opossum by Johnston ('23). This last author suggests that it probably represents an amygdalo-habenular connection.

Connections with the bed nuclei of the stria terminalis and the anterior commissure (figs. 8 and 9). The above-described components of the stria medullaris are in intimate synaptic relations with the bed nuclei of the stria terminalis and the anterior commissure. Fibers from these nuclei join the other components to enter the stria medullaris. The synaptic relations of the medial cortico-habenular tract with the bed nuclei of the anterior commissure have been demonstrated for lower forms (Crosby, '17).

Lateral olfacto-habenular tract (fig. 11). The fibers that make up the lateral olfacto-habenular tract come from the caudal aspect of the tuberculum olfactorium and the rostral one-third of the preoptic area. Many of the fibers course through the medial forebrain bundle, and just lateral and somewhat dorsal to the fornix columns join the lateral cortico-habenular fibers, together with which they run into the stria medullaris (see account of the lateral cortico-habenular tract).

Medial olfacto-habenular tract (figs. 11 and 12). This system of fibers consists of a number of small bundles grouped for convenience under the one name. The fibers arise from the medial portions of the preoptic area and the hypothalamic regions throughout a considerable part of their extent. The bundles course dorsally and somewhat medially, lying on the medial side of the medial forebrain bundle. The more rostral ones, that is, those from the preoptic area, turn dorsocaudad and join the stria on its ventromedial surface near its entrance to the habenula. The olfacto-habenular fibers from

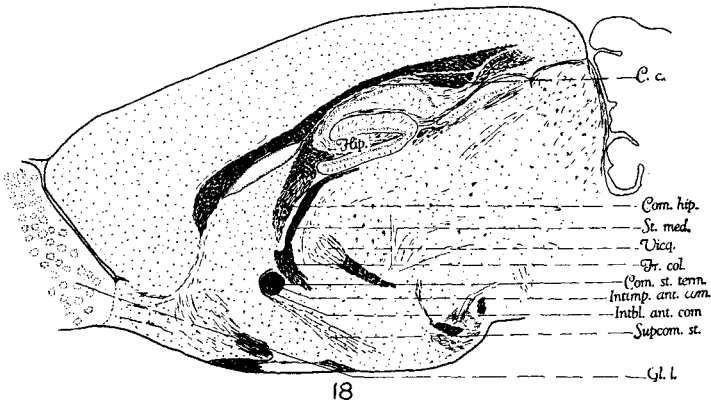
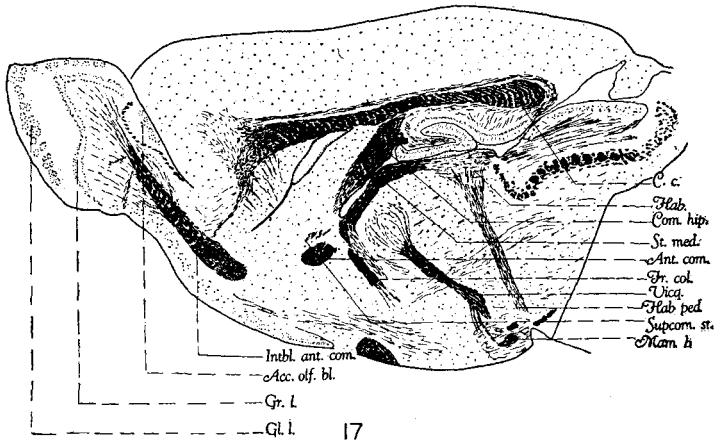


Fig. 17 Decalcified pyridine-silver preparation. Sagittal section passing through the interbulbar component of the anterior commissure. *Acc.olf.bl.*, accessory olfactory bulb; *Ant.com.*, anterior commissure; *C.c.*, corpus callosum; *Com.hip.*, commissura hippocampi; *Fr.col.*, fornix column; *Gl.l.*, glomerular layer; *Gr.l.*, granular layer; *Hab.*, habenula; *Hab-ped.*, habenulo-peduncular tract (Meynert's); *Intbl.ant.com.*, interbulbar component of the anterior commissure; *St.med.*, stria medullaris; *Supcom.st.*, supracommissural portion of the stria terminalis; *Vicq.*, Vieq d'Azyr bundle.

Fig. 18 Decalcified pyridine-silver preparation. Sagittal section passing through a plane just lateral to the midline. *C.c.*, corpus callosum; *Com.hip.*, commissura hippocampi; *Com.st.term.*, commissural portion of the stria terminalis; *Fr.col.*, fornix column; *Gl.l.*, glomerular layer; *Hip.*, hippocampus; *Intbl.ant.com.*, interbulbar component of the anterior commissure; *Inttmp.ant.com.*, intertemporal component of the anterior commissure; *St.med.*, stria medullaris; *Supcom.st.*, ~~supra-commissural~~ supra-commissural portion of the stria terminalis; *Vicq.*, Vieq d'Azyr bundle.

the hypothalamic areas pass almost directly dorsalward and reach the ventromedial border of the stria medullaris. The medial olfacto-habenular fibers, particularly those from the hypothalamic regions, are finer and darker than the fibers of other components of the stria, and form a relatively distinct bundle which can be traced to the habenula as such (fig. 13). Both the lateral and the medial olfacto-habenular tracts have been described for forms below mammals (Herrick, '10; Crosby, '17; Hines, '23).

Lateral cortico-habenular tract (figs. 11, 12). The lateral cortico-habenular tract is connected with the ventromedial portion of the hemisphere, the pyriform lobe, and the nucleus of the lateral olfactory tract. The bundles run dorsally and mesially, enter the diencephalon and join the lateral olfacto-habenular fibers somewhat dorsolateral to the anterior columns of the fornix. In this union of the two components a characteristic V-shaped figure is formed (fig. 11). After coming together the two tracts run as a common bundle, coursing forward and dorsalward, until, near the rostral boundary of the diencephalon, they join the other components from the medial wall of the hemisphere and so build the stria medullaris.

Johnston ('23) has described a connection of the stria medullaris with the lateral olfactory nucleus and his nucleus medialis. It is apparently not homologous with the above-mentioned tract so far as we have been able to determine from his description. Possibly the tract which he has described is not impregnated in our material.

Summary of the components of the stria medullaris. It will be seen from the foregoing account that the stria medullaris is a relatively complex system of fibers. Through its septo-habenular and medial cortico-habenular components, the dorsomedial olfactory areas of the hemisphere (the hippocampus and the septal areas) are put into relation with the habenula; through its lateral cortico-habenular component and its connection with the stria terminalis the is brought into relation with the lateral olfactory are

hemisphere, particularly with the amygdaloid region. The medial basal wall of the hemisphere, the preoptic area, and the hypothalamus are connected with the habenula through the lateral and medial olfacto-habenular components of the stria medullaris.

Course of the stria medullaris (figs. 6 to 13, 17, and 18). The union of the lateral cortico-habenular and the lateral olfacto-habenular tracts, on the one hand, with the septo-habenular, the stria terminalis connection, and the medial cortico-habenular tract, on the other hand, may be considered as marking the cephalad beginning of the stria medullaris. This union occurs in the rat near the anterior end of the diencephalon (fig. 10). The bundle thus formed is at first triangular in shape (fig. 11). It passes along the extreme dorsomedial surface of the diencephalon toward the habenula. In its more caudad relations it is more circular in shape (fig. 12). In their course through the stria the various components of the same maintain certain relationships to each other. Thus those from the dorsomedial wall of the hemisphere (the medial cortico-habenular and the septo-habenular) occupy the dorsal half of the stria medullaris. The tracts from the lateral wall of the hemisphere and the ventral olfactory centers of the medial part of the hemisphere and diencephalon (lateral cortico-habenular and the olfacto-habenular tracts) take a more ventral position, and somewhat medially inclined. The medial olfacto-habenular tract has the most ventral position of any of the components. The stria medullaris fibers end for the most part in the habenular nuclei of the same side. A few may cross in the habenular commissure which is very small in the rat.

HABENULA

In connection with the foregoing account of the stria medullaris, it may be of interest to give a brief description of the structure of the habenula (fig. 6). Nissl (according to Cajal), Cajal, ('11); Dejerine ('01), and others have recog-

nized in the habenula a medial (internal) nucleus and a lateral (external) nucleus. They are both present in our material, and the medial in particular manifests certain interesting configurations.

Medial habenular nucleus (fig. 6). The medial habenular nucleus can be divided rostrally into two portions: a ventromedial and a dorsomedial part.

The ventromedial portion of the medial nucleus (fig. 6, A) is found in close relation to the ventricular cavity, and is in the rostral third of the habenular complex. Its cells are compactly placed in the form of an irregular triangular mass. This becomes larger caudally and eventually joins the dorsomedial portion of the medial nucleus to form the medial nucleus of classical description.

The dorsomedial portion of the medial habenular nucleus (fig. 6, A) consists of a group of cells loosely placed, the group being dorsal and somewhat lateral to the ventromedial portion. It joins the other to form the medial nucleus. In general, it is found in the same region as the ventromedial portion.

With the union of these two components there is produced an oval nucleus, the classical medial nucleus of the habenula (fig. 6, B, C, D, E). Medially it is adjacent to the ependymal lining of the ventricle, and laterally it is bounded by the lateral habenular nucleus and a portion of the stria medullaris. Above it is in relation with the stria medullaris. The nucleus is oval and its long axis placed from before backward. It bulges more medially than laterally, and thus causes a certain convexity in lateral habenular nucleus. It appears to be more tapering in the caudal than in the ventral direction.

Lateral habenular nucleus. The lateral habenular nucleus is on the lateral aspect of the medial habenular nucleus (fig. 6). In its rostral relations it is pushed ventrally, due to the large number of bundles of the stria medullaris, which after their entrance into the habenula permit the lateral habenular nucleus to reach a more dorsal position. The cells

here are smaller than those in the medial nucleus and are much more scattered.

Bed nucleus of the habenular commissure (fig. 6, F). The bed nucleus of the habenular commissure is continuous with the medial nucleus in its rostral relations. It is associated with the habenular commissure and is not very highly developed.

Habenulo-peduncular tract (fig. 17). The habenulo-peduncular tract has been thoroughly demonstrated for Mammalia and other vertebrates. It is also identified in the rat and is shown in the figure (fig. 17).

STRIA TERMINALIS

A detailed account of the stria terminalis connections has been given by Johnston in his 1923 paper. This account has been based primarily on the opossum, and certain of the connections have been checked on rabbit and human foetal material. In general, our findings in the rat correspond with those described by the above-quoted author for the opossum. Consequently, a detailed account of the connections in the rat appears unnecessary. A summary of the components follows together with a description of such minor differences as appear in the animal studied.

Supracommissural portion (figs. 8 to 11 and 18). The supracommissural portion is the most cephalad of all the components, and is a distinct bundle which loops around the anterior commissure, and then takes a caudad course, ventrally inclined. It is clearly seen in the accompanying figure made from a sagittal series (fig. 18). As it courses more caudad the bundle becomes separated into smaller components, and diminishes in size, indicating that it supplies all that region on the lateral aspect of the ventricle, the preoptic and the hypothalamic areas. Johnston ('23), in the opossum, says of this bundle that its fibers "join the medial forebrain bundle (fibers from the parolfactory nuclei) and run on toward the hypothalamus." In the rat the supracommissural portion of the stria terminalis, while accom-

panying the medial forebrain bundle, on the latter's medial aspect, can be followed as a distinct bundle into the preoptic and the hypothalamic regions where it ends. However, the connection forward into the parolfactory area is not demonstrable in our preparations.

Commissural portion. The commissural portion is the next group of fibers given off from the stria. Its relations, while a part of the anterior commissure, have been considered under that heading (see account under anterior commissure and fig. 18). This component is traced to the inferolateral aspect of the lateral ventricle, where it unites with the rest of the stria.

Preoptic component. Just caudad to the plane of the anterior commissure and to the components just described, the preoptic component is given off from the stria terminalis. This bundle runs toward the preoptic nucleus. In its course downward and medialward it curves over the medial aspect of the medial forebrain bundle, lying in close relationship with that bundle, but readily distinguishable from it (fig. 10). As it reaches the preoptic area it breaks up into smaller bundles of fibers which supply that region. It has not been possible to demonstrate that any of them reach the hypothalamus. In the opossum, Johnston ('23) has described a hypothalamic bundle which in some respects resembles this preoptic connection. He considers this tract to be the projection tract of Cajal, and says of it that "the diffuse fibers turn downward without approaching very near the anterior commissure and then backward, in the medial forebrain bundle presumably to go to the hypothalamus." It may be that, in the rat, certain fibers accompanying this preoptic connection as it passes over the medial forebrain bundle join that bundle and accompany it to hypothalamus (a connection comparable to the hypothalamic bundle of Johnston). It has been impossible to demonstrate such a connection in the material at hand. It is certain that the bundle, so far as we have been able to follow it, is mainly for preoptic connections.

Fibers to the bed nucleus of the stria terminalis (figs. 8 and 9). A great many of the fibers seem to end or begin in the bed nucleus of the stria.

Fibers to the bed nucleus of the anterior commissure (figs. 8 and 9). Some fibers do end in this bed nucleus of the anterior commissure. This would make possible synapse with fibers carrying impulses from the hippocampal cortex, since the medial cortico-habenular fibers synapse in this bed nucleus of the anterior commissure also.

Fibers to the stria medullaris (fig. 8). In the caudal third of the anterior commissure there is seen a communication between the stria terminalis and the medial cortico-habenular component of the stria medullaris, thus establishing a possible connection with the habenula. Further mention of this tract is made under the account of stria medullaris (see that account).

All of these different components of the stria terminalis converge caudad, with the consequent formation of a bundle which courses toward the inferolateral aspect of the lateral ventricle and then turns horizontally caudad. As we trace this tract backward we observe that it is found ventral to the lateral boundary of the fornix and overlapped by the same. In this region the stria terminalis appears to be made up of two rather indistinct portions, which become more evident as the stria is traced more caudad. Its relations in a plane passing through the cephalic third of the hippocampus are as follows (fig. 12): Dorsally the fornix; laterally the internal capsule; ventrally the internal capsule and particularly its cortico-thalamic component; medially the thalamus and the lateral geniculate body. The stria then courses farther caudad and, in the plane of the middle third of the habenula, it runs ventrally and ends in the amygdaloid complex, passing caudoventrally to the internal capsule (fig. 13). Johnston ('23) has been able in the opossum to trace back from the plane of the anterior commissure the various components of the stria to the different nuclei of the amygdaloid complex. In our rat material it has not been possible for us to do this.

While in some smaller details our findings in the rat differ from those obtained for certain lower vertebrates by various observers (Johnston, '15, '23; Crosby, '17; Herrick, '21; Hines, '23, and others) and for the opossum by Johnston ('23), in all their main features the results are in agreement with those described by previous workers. They are particularly in accordance with the careful analysis that Johnston has presented in the opossum, as the discussion in the preceding paragraphs show.

In general, one may say that the stria terminalis is concerned in relating the lateral olfactory areas, particularly the amygdaloid complex and the nucleus of the lateral olfactory tract, with: *a*) the medial basal olfactory areas of the hemisphere of the same and opposite sides; *b*) the preoptic region and the hypothalamus; *c*) the habenula, either by direct fiber contributions to the stria medullaris or indirectly by synapse in the bed nuclei of the stria terminalis and the anterior commissure. It should be remembered that these latter regions give rise to certain fibers of the stria medullaris.

Bed nucleus of the stria terminalis (figs. 8, 9). Johnston ('23) has described this for the rat. He draws attention to the fact that it is found in the plane of the anterior commissure and becomes continuous with the head of the caudate and the nucleus accumbens rostrally, while caudally it follows the fornix columns to the hypothalamus. He thinks that this bed nucleus accompanies the stria all the way through its course from the amygdaloid complex. However, we want to stress this one point: that the stria terminalis in its course on the ventrolateral aspect of the fornix is accompanied by very few nerve cells. Thus, we have not been able to see a nerve cell in as many as fifteen to twenty sections in the serial order, in the preparations at hand. It is also noted that a close relation exists between this and the bed nucleus of the anterior commissure.

CONCLUSIONS

Throughout the paper brief summaries have been given in various sections in order to stress certain observations. A brief résumé of the more important results follows.

The foregoing account shows that the structure of the olfactory bulb in the rat is essentially the same as that described for other mammals. Its connection with the secondary centers farther caudad through the medial and the lateral olfactory striae has been considered. The connection of the accessory olfactory bulb with the lateral stria has been stressed, due to its significance as a center for impulses from the vomeronasal organ to the amygdaloid complex.

There has been no attempt to describe fully the secondary and tertiary basal and cortical olfactory centers, except in so far as it was necessary to identify and describe them in order to make clear the relations of certain fiber tracts. Incidentally, some rather interesting details were obtained concerning the tuberculum olfactorium. The islands of Calleja were seen as masses of cells, which were infiltrated in their central portions by fine fibers which pass out together at one side as a distinct bundle. These could be traced particularly to the medial forebrain bundle and the tuberculo-pyriformic tract. They may also contribute fibers to the tracts which relate the tuberculum with the medial basal wall of the hemisphere (parolfactory area of Johnston, '10, pre-commissural portion of the septal area of Kappers, '22, and Hines, '23) and with the preoptic area and the hypothalamus.

The anterior commissure has been shown to consist not only of the classical interbulbar and the intertemporal components, but of practically an unbroken extent of fibers, interrelating the bulbar and lateral secondary and tertiary olfactory areas (largely pyriform lobe) from the region of the olfactory bulb to practically the caudal end of the hemisphere. The stria terminalis component of the anterior commissure and the fibers between its bed nuclei have been demonstrated.

The rôle of the stria medullaris in the rat appears to be an important one and the number of components we have been

able to demonstrate is relatively large. In general, we have found it to connect the habenula, *a*) with the hippocampus and septum (dorsomedial areas of the hemisphere); *b*) with the pyriform lobe, the nucleus of the lateral olfactory tract and a part at least of the amygdaloid complex (lateral olfactory areas of the hemisphere); *c*) with the preoptic nucleus and the hypothalamus (diencephalic olfactory centers).

The habenular nuclei in the rat are large and apparently well differentiated, although the habenular commissure is small. Edinger's idea that the size of the habenula is directly proportional to the number of incoming olfactory nerve fibers was denied by Lotheissen ('94), but supported by Cajal ('11). We have no opinion to offer as to the truth of Edinger's statement at the present time, but certainly in the rat the number of incoming olfactory fibers is large and the habenula is large and well differentiated.

Our observations on stria terminalis agree in all main points with those described for mammals (particularly the opossum) by Johnston ('23). We wish to emphasize the large preoptic component in the rat and the relation of the stria terminalis not only with its own bed nucleus, but also with that of the anterior commissure as well.

LITERATURE CITED

- CAJAL, S. R. 1890 Origen y terminacion de la fibras nerviosas olfactorias. Gac. Sanitaria de Barcelona.
 1894 Estructura del ganglio di la habenula de los mamiferos. Anat. de la Sociad Esp. d. Hist. natural., T. 32.
 1902 La corteza olfactivo. Trab. d. Lab. d. investig. biol., T. 1.
 1902 Textura del lobulo olfactivo accessorio. Rev. trim. micrografica., T. 6.
 1911 Histologie du système nerveux, T. 2. Paris.
- CROSBY, ELIZABETH C. 1917 The forebrain of Alligator mississippiensis. Jour. Comp. Neur., vol. 27.
- DEJERINE, J. 1901 Anatomie des centres nerveux, T. 2. Paris.
- EDINGER, LUDWIG 1893 Vorlesunger über den Bau der nervösen Centralorgane des Menschen und der Tiere. 4te Auflage. Leipzig.
 1911 Idem. 8te Auflage. Leipzig.

- GANSER, S. 1879 Ueber die vordern Hirnkommissur der Säugethiere. Arch. für Psych., Bd. 9.
1889 Vergleichende anatomischen Studien über das Gehirn des Maulwurfs. Morph. Jahrbuch, Bd. 7.
- GOLGI 1875 Sulla fina anatomia dei bulbi olfaktorii. Reggio-Emilia.
- HERRICK, C. JUDSON 1910 The morphology of the forebrain in Amphibia and Reptilia. Jour. Comp. Neur., vol. 20.
1921 The connections of the vomeronasal nerve, the accessory olfactory bulb and the amygdala in Amphibia. Jour. Comp. Neur., vol. 33.
1924 The nucleus olfactorius anterior of the opossum. Jour. Comp. Neur., vol. 37.
- HINES, MARION 1922 Studies in the growth and differentiation of the telencephalon in man, the fissura hippocampi. Jour. Comp. Neur., vol. 34.
1923 The development of the telencephalon in *Sphenodon punctatum*. Jour. Comp. Neur., vol. 35.
- HONEGGER, J. 1890 Vergleichende anatomischen Untersuchungen über den Fornix. Recueil zool. suisse, Bd. 5.
- HUBER, G. CARL, AND GUILD, STACY R. 1913 Observations on the peripheral distribution of the nervus terminalis in Mammalia. Anat. Rec., vol. 7.
- JOHNSTON, J. B. 1913 The morphology of the septum, hippocampus and pallial commissures in reptiles and mammals. Jour. Comp. Neur., vol. 23.
1923 Further contributions to the study of the evolution of the forebrain. Jour. Comp. Neur., vol. 35.
- KAPPERS, C. U. ARIËNS 1914 Phenomena of neurobiotaxis in the central nervous system. 17th Intern. Congress of Med., London.
1920 Vergleichende Anatomie des Nervensystems, vol. 2, Haarlem.
- DELANGE, S. J. 1911 Das Vorderhirn der Reptilien. Folia Neurobiologica, Bd. 5.
- LOTHEISSEN, GEORG 1894 Ueber die Stria medullaris Thalami optici. Anat. Hefte, Bd. 4.
- MCCOTTER, ROLLO E. 1912 The connection of the vomeronasal nerves with the accessory olfactory bulb in the opossum and other mammals. Anat. Rec., vol. 6.
1917 The vomeronasal apparatus in *Chrysemys punctata* and *Rana catesbiana*. Anat. Rec., vol. 13.
- MENDEL 1889 Ueber reflectorische Pupillenstarre. Sitzungsbericht d. Berliner Medic. Gesellschaft, Berl. klin. Wochenschrift, No. 47.
- OBENCHAIN, JEANETTE B. 1923 The brain of *Coenolestes obscurus*. Trans. Illinois State Academy of Science, vol. 16.
1924 The brains of the South American marsupials *Caenolestes* and *Orolestes*. Field Mus. of Nat. History, Zool. Series, vol. 14 (in press).
- VAN GEHUCHTEN ET MARTIN 1891 Le bulbe olfactif chez quelques mammifères. La Cellule, T. 7.
- VAN GEHUCHTEN, A. 1897 Anatomie du système nerveux. Louvain.
1902 Contribution a l'étude des voies olfactives. Le Nevraxe, T. 6.