

# THE NUCLEAR PATTERN OF THE NON-TECTAL PORTIONS OF THE MIDBRAIN AND ISTHMUS IN THE DOG AND CAT

JAMES O. BROWN<sup>1</sup>

*Department of Anatomy, University of Michigan*

TWELVE PLATES (EIGHTEEN FIGURES)

## INTRODUCTION

Few of the investigations on midbrain areas have been based on carnivore material, and only the Winkler and Potter atlas ('14) on the cat brain and Tamthai's ('43) paper on the mink present a picture of the nuclear structure of the whole region. The present account deals with the nuclear areas of the midbrain tegmentum in the dog with direct comparisons with the homologous areas in the cat, in an attempt to establish the pattern common to the region in these forms which are so frequently used experimentally.

The preparations employed in this study are a part of the Huber Neurological Collection of the Laboratory of Comparative Neurology at the University of Michigan. One transverse and one sagittal series of the dog's brain and similar material of the cat's brain were available for study. This material had been hardened in alcohol-mercuric chloride-trichloroacetic acid fixative and stained in toluidin blue. Through the employment of suitable filters, photomicrographs were found to give satisfactory cytoarchitectonic pictures of the various brain stem levels, and so were chosen for illustrating the paper.

<sup>1</sup> A dissertation submitted in partial fulfillment of the requirements for the degree of doctor of philosophy.

For the generous grant which made possible this research the writer wishes to express grateful acknowledgment to the Horace H. Rackham School of Graduate Studies of the University of Michigan. Special thanks are due Prof. Elizabeth C. Crosby for her interest in this paper and for the criticism and cooperation proffered throughout its preparation.

The major part of the pertinent literature will receive consideration in connection with the detailed description of the material. Only a few contributions of more general bearing or those which have been used particularly for the present paper need be mentioned here.

The works of Ramón y Cajal ('09-'11), Winkler and Potter ('14) and Ariëns Kappers, Huber and Crosby ('36) have been very helpful for general orientation and in providing an approach to the literature. Nuclear groups of the posterior commissure have been reported by von Kölliker (1896), Panegrossi ('04), Rioch ('29 a), Ingram and Ranson ('35) and others. Darkschewitsch (1885 and 1889), von Kölliker (1896), Ziehen ('20) and Castaldi ('23) and Ingram and Ranson ('35) have studied particularly the nuclear groups associated with the medial longitudinal fasciculus. Dealing with the cranial nerve nuclei in carnivores or related forms are the papers of Perlia (1889), Panegrossi ('04), Tsuchida ('06), Johnston ('09), van Valkenburg ('10 and '12), Bronwer ('18), Le Gros Clark ('26) and Weinberg ('28). Among those who have studied the midtegmental nuclear groups are von Gudden (1889), Hatschek ('03 and '07) von Monakow ('10), Castaldi ('23), Tsai ('25), Davenport and Ranson ('30) and Papez ('32). Henle (1871), Forel (1877), von Gudden (1881), Ramón y Cajal ('09-'11), Ziehen ('20), Castaldi ('23) and Rioch ('29 a and '29 b) have presented pertinent material concerned with the midline nuclear groups, and Ramón y Cajal ('09-'11) has described the nuclear gray associated with the lateral lemniscus.

Dominating in importance all the contributions on the mid-brain are the exceedingly detailed studies by Castaldi ('23, '24 and '26) on this region in the guinea pig.

## THE PERIVENTRICULAR GROUPS

*General areas of periventricular gray*

The mesencephalic periventricular gray is formed by the neurons which immediately surround the aqueduct throughout the midbrain (figs. 2 to 15). It may be divided secondarily into dorsal, lateral and ventral portions. The dorsal part extends from the posterior commissure levels to planes through the inferior colliculus where it becomes continuous with the chief nucleus of the latter area. It forms the periventricular layer of the optic tectum and need not receive further consideration here.

The lateral part of the periventricular gray extends from the diencephalic-mesencephalic boundary to the region of the anterior medullary velum. Within this lateral part of the central gray only one nuclear mass, the medial part of the dorsal nucleus of the posterior commissure, develops.

Pars ventralis begins as a caudal continuation of the diencephalic gray medial to zona incerta and continues through the mesencephalon to pass without sharp demarcation into the central gray of the pons. Within the ventral part of the central gray practically all the nuclear differentiation characteristic of the periventricular portion of the mesencephalon occurs. Among such nuclei are the eye-muscle nuclei, the nucleus of Darkschewitsch, the dorsal nucleus of the raphé, the laterodorsal tegmental nucleus, and the dorsal tegmental nucleus, together with certain smaller cell masses. These areas are surrounded by less differentiated central gray.

*Nuclear groups associated with posterior commissure*

Differentiable magnocellular, intracommissural and precommissural portions of the gray related to the posterior commissure at or near its crossing have been selected for special consideration. Still further subdivisions of this general gray might be made.

Associated with fibers of the posterior commissure as they fan out laterally in the dog and the cat is a gray mass which constitutes the nucleus of the commissure (figs. 2 to 4, 15). This is composed of small, rounded, multipolar cells characterized by a rather indistinct nucleus containing a prominent nucleolus. Fine Nissl granules are found throughout their cytoplasm. The lateral boundaries of the nucleus are indistinct, the cells intermingling with those of the subtectal gray. Here are certain larger neurons of tegmented type intermingled with the smaller rounded cells which constitute an area comparable to the pars magnocellularis described for various forms. The nucleus of the posterior commissure extends from about midlevels

of the chief oculomotor nucleus to a plane through the frontal border of the posterior commissure, at which latter level it curves medially rostral to the commissural fibers forming a precommissural part to blend with the diffuse pretectal gray. The nucleus of the posterior commissure as here described corresponds in general to the nucleus of the posterior commissure of Rioch ('29 a) and probably falls within the caudal end of the posterior nucleus described by Papez ('32) for the armadillo. It is comparable to the dorsal nucleus of the posterior commissure of Castaldi ('24).

The cells that make up the intracommissural portion of the nucleus of the posterior commissure are identical in type with the smaller cells of the so-called magnocellular part of the nucleus of this commissure. Morphologically the outstanding difference between these two nuclei is largely that of position. Spreading medialward from the laterally placed magnocellular portion are the neurons of the intracommissural nucleus, intercalated among the commissural fibers. Such a position produces very inconstant small clusters of cells of various sizes.

In the dog, the intracommissural portion is found for only a very limited distance close to the magnocellular part of the commissure (fig. 3). The neurons do not reach so far as the midline, as is also the case in the mink (Tamthai, '43), nor do they approach it closely until the more caudal regions of the nucleus. At these levels, scattered cells extend quite close to the midline, and in some places even blend with those of the opposite side. Throughout the greater part of the posterior commissure this intracommissural nucleus is lacking.

The rostral half of the intracommissural portion in the cat differs little from that gray mass in the dog. Caudally it is increased, for scattered neurons of the nucleus are readily observed extending all the way across the midline above the dorsal part of the periventricular gray (fig. 4).

#### *Nucleus of Darkschewitsch*

In the cat and the dog, the nucleus of Darkschewitsch lies dorsomedial to and close to the interstitial nucleus of the medial longitudinal fasciculus (figs. 2 to 5), but possesses a much shorter extent. It parallels this interstitial nucleus except at its rostral end, which shows a slight dorsal tilt. It is distinguished from the latter by the slightly smaller size and more intensive staining of its multipolar cells. The neurons of this portion are somewhat scattered.

The nucleus here recognized as the nucleus of Darkschewitsch corresponds to nucleus accessorius medialis of Darkschewitsch, to der Nebenkern of von Kölliker (1896), and to the nucleus of Darkschewitsch according to Ramón y Cajal ('09-'11). Panegrossi ('04) described a medial accessory nucleus of Darkschewitsch in the cat, but denied its presence in the dog.

*Eye-muscle nuclei*

*Oculomotor complex.* The oculomotor complex involves two groups of nuclei, each of which forms a functional unit. These are the chief oculomotor nucleus and the Edinger-Westphal nucleus.

The chief oculomotor nucleus extends from a plane through the caudal portion of the superior colliculus to the level of the posterior commissure. It is rather sharply defined caudally in the dog and occupies a position dorsomedial to the medial longitudinal fasciculus and lateral to the midline (fig. 7). As it is traced caudorostrally (figs. 7, 6), it gradually enlarges and wedges itself ventrally between the medial longitudinal fasciculus and the midline. Some of its more peripheral cells penetrate between the fibers of the fasciculus. It also enlarges dorsally so that it overrides slightly the dorsal margin of the medial longitudinal fasciculus. Throughout the midportion of its extent the nucleus curves slightly ventromedialward and shows some tendency to fuse across the midline with its fellow of the opposite side (fig. 6, P). Rostrally the oculomotor nucleus diminishes, beginning with its dorsolateral part, and disappears in planes through the posterior commissure (fig. 3).

The chief oculomotor nucleus may secondarily be divided into two major portions, a dorsolateral and a ventromedial nucleus (figs. 5, 6). Of these, the ventromedial part is the longer, extending to the rostral tip and also to the caudal pole of the chief oculomotor nucleus, at which pole it is continuous with the trochlear nucleus in the cat but not in the dog and also not in the mink (Tamthai, '43). The dorsolateral portion begins slightly behind the frontal border of the oculomotor nucleus and, unlike its homologue in many forms, is separated from the trochlear nucleus lying caudal to it. These two regions had been noted by Perlia (1889) for man. Tsuchida ('06) described them in a series of animals including carnivores, although his work was based primarily on macaque.

The ventromedial nuclei of the two sides are fused into a single nuclear mass across the midline for a short distance in the midportions of the nucleus (fig. 6, P) but are distinct from each other, caudal and rostral to the level of fusion. This is in agreement with the observations of Brouwer ('18), who noted the fusion of these nuclei for some distance in carnivores. This region of fusion is suggestive of the central nucleus of Perlia (Perlia, 1889), a midline cell mass toward the anterior region of the oculomotor nucleus, which is "surmounted by lateral large cells" appearing to "merge into a single nucleus" with the midline group lying directly ventral to it. The overlying large cells (referred to by Perlia) constitute the so-called paramedian group of Le Gros Clark ('26). Opinions have differed as to whether or not this fusion of the ventromedial nuclei in the dog and the cat represents the forerunner of a paramedian nucleus or a central

nucleus. The present observer is inclined toward the latter opinion. He believes from personal observations that definite ocular convergence is demonstrable in adult dogs and cats and regards the gray mass in question as a homologue of the human central nucleus of Perlia, which, Brouwer suggested, is the center for convergence. No nuclear group corresponding to the caudal central nucleus of primates (Tsuchida, '06; Le Gros Clark, '26) was found in the carnivores studied.

The chief oculomotor nucleus in both the dog and the cat is composed of fairly large multipolar neurons. Tsuchida ('06) was able to recognize more than a single type in the dog but Brouwer ('18) found the cells to be the same throughout in the cat. The relations of the oculomotor nuclei are essentially alike in the dog and the cat except that, in the latter carnivore only, a connection with the trochlear nucleus is made by a small isthmus of gray.

The Edinger-Westphal complex (figs. 3 to 6, 13) has been studied comparatively by Le Gros Clark ('26) and others. This nucleus lies in close relationship with the medial face of the rostral half of the chief oculomotor nucleus. In primates it is a paired structure close to the midline, but in subprimate mammals it is usually a median, unpaired nucleus. In the dog, there is a midline fusion for a part of the cell mass (compare with conditions in the mink, Tamthai, '43), so that there might be some question in the adult as to whether it should be regarded as a paired nucleus showing partial fusion or an unpaired nucleus displaying partial separation.

Frontally, at the caudal edge of the mammillary body, slightly more rostral than the chief oculomotor nuclei, are two little masses of small cells, each of which lies very near the midline. These are about half way between the floor of the aqueduct and the interpeduncular fossa. Cells from each group extend toward the midline so that there is slight fusion of the right and left cell masses. This portion of the Edinger-Westphal nucleus has been termed nucleus medianus anterior in the cat by Panegrossi ('04), who believed it to be a separate nucleus. In the dog and the cat, no such separate group can be distinguished, since morphologically the neurons are identical with those of the Edinger-Westphal nucleus (as Brouwer, '18, and Le Gros Clark, '26, also found), the two masses being continuous. This frontal extension may be considered a rostral Edinger-Westphal nucleus.

Behind this rostral tip the remainder (or caudal part) of the Edinger-Westphal nucleus enlarges and, in planes through the front end of the chief oculomotor nucleus (figs. 3, 13), shifts dorsocaudalward commensurate with the curvature produced by the rapidly enlarging frontal end of the latter gray. At approximately its mid-longitudinal extent, as it lies in relation to the dorsolateral oculomotor

nucleus laterally and the midline medially, the Edinger-Westphal nucleus abandons its dorsal course and extends directly caudalward (fig. 13). At about the same level, the median fissure, which appears slightly more rostrally, suggests a midline cleavage separating the Edinger-Westphal gray into definite right and left parts (figs. 5, 6). These continue distally as two caudally projecting lateral extensions of an unpaired nucleus. They gradually fade away in the raphé region, at the level of the posterior third of the chief oculomotor nucleus. In the cat the median fissure also occurs but without cleavage of the nucleus. The Edinger-Westphal nucleus of the dog is intermediate in differentiation between the definitely median (unpaired) nucleus of rodents and the paired nucleus of primates. This interpretation is not in entire agreement with all the accounts in the literature, for Panegrossi ('04) and Brouwer ('18) thought that a paired Edinger-Westphal nucleus is found only in the monkey (*Macacus*) and in man, and Tsuchida ('06) stated that the differentiation of a bilateral Edinger-Westphal nucleus is characteristic only of man. The description of Tamthai ('43) based on mink material documents that observed in the dog.

The somewhat scattered cells of the Edinger-Westphal nucleus are uniformly of multipolar type and about half as large as those of the chief oculomotor nucleus. They show fewer processes and have finer Nissl granules.

*Trochlear gray.* The trochlear nucleus (figs. 14, 15), lying at the level of the inferior colliculus in approximately the same relative position in both the dog and the cat, is slightly behind and slightly lateral to the ventromedial portion of the chief oculomotor nucleus. Differentiated from the ventral part of the periventricular gray, it is in close relationship to the medial longitudinal fasciculus, among the fascicles of which its cells are embedded, and just lateral to the midline. The carnivore trochlear nucleus (see also Tamthai, '43) has a position intermediate to that described for the rabbit, in which van Valkenburg ('12) and Gillilan ('43 a) found its cells dorsolateral to the medial longitudinal fasciculus, and to that seen in the horse, in which Tsuchida ('06), Vermeulen ('14) and Gillilan ('43 b) found them lying ventral to the fasciculus.

The trochlear nucleus is much smaller and has a somewhat more rounded outline than does the chief oculomotor nucleus. Both nuclear groups contain large, deeply stained, multipolar cells. In the material studied, the trochlear nucleus is sharply separable from the oculomotor in the dog, although in the cat a narrow isthmus of cells connects these two nuclei. On the contrary, van Valkenburg ('12) found in his series a definite separation between the trochlear and oculomotor nuclei in the cat, but direct continuity between them in the dog.

The cells of the trochlear nucleus resemble in general appearance those of the chief oculomotor nucleus. They are large, multipolar, and obviously efferent neurons.

Obersteiner (1887) confirmed the findings of Westphal (1887) that a group of very small cells lies dorsal to the medial longitudinal fasciculus and close to the midline at the level of the trochlear decussation. He called this group of neurons Westphal's nucleus or the posterior nucleus of the trochlear nerve because he believed it contributed fibers to this nerve. Our material indicates that neither the nuclear mass described by these authors nor the unlabelled cell group shown by Obersteiner (1887, fig. 132) is actually a posterior trochlear nucleus. The nucleus described by these authors appears to be the lateral part of the dorsal nucleus of the raphé.

However, another cell group, caudal to the main trochlear nucleus, was identified by van Valkenburg ('12) as a posterior trochlear nucleus in the rabbit but this author denied its existence in the dog or the cat. The material available for study shows the presence of this cell group in both of these carnivores, the present account being the first description of the posterior trochlear nucleus in these forms. In the dog this nucleus (fig. 13) lies about 1.5 mm. caudal to the rostral trochlear nucleus, close to the midline. It overlies the medial longitudinal fasciculus and borders the ventromedial edge of the rostral tip of the dorsal tegmental nucleus. Thus it is in a wedge-like chink at the ventromedial border of the central gray matter. In the cat the posterior part of the trochlear nucleus (fig. 9) is immediately caudal to the rostral portion of the complex. It is embedded among the fibers of the medial longitudinal fasciculus, lying somewhat more lateral than its homologue in the dog, and is slightly smaller. The neurons constituting the posterior trochlear nucleus in both carnivores are of the same type as those which compose the chief or rostral trochlear nucleus. They are not numerous but rather widely scattered, three neurons constituting the average number found in the posterior trochlear nucleus. In the dog there are 57 on the left side although on the right side a total of only 27 cells was found. In the cat, the nuclei of the two sides are more nearly equal in size with but a slight predominance in favor of the right side (16 cells on the left, 19 cells on the right). No posterior trochlear nucleus was found by Tamthai ('43) in the mink. It has been said (van Valkenburg, '12) that in mammals in general a posterior trochlear nucleus is more usual on the left than on the right side, although it may be demonstrable on neither side.

The reasons underlying the doubling of the trochlear nucleus are not very clearly understood. The explanation advanced by van Valkenburg ('10) is a logical and possibly a correct one. This author believed that the separation of the trochlear nucleus into two parts



may have resulted from a common "functional stimulation received by it and the abducens nucleus." This arrested the forward migration of a small group of the trochlear cells. The bulk of the trochlear neurons under the influence of the stimulation "which simultaneously affected the oculomotor nucleus" migrated forward. The separation into a caudal cell cluster and a rostral nuclear group resulted then from differences in functional factors during their development.

#### *Dorsal nucleus of raphé*

The dorsal nucleus of the raphé (figs. 8 to 10) consists of two major portions, a central and a lateral part. The central part of this nucleus, composed of spindle-shaped, multipolar neurons, larger and more deeply stained than those of the surrounding central gray, extends rostralward into the mesencephalon from the pons.

Between the central part of the dorsal nucleus of the raphé and the laterodorsal tegmental nucleus are masses of cells which constitute the lateral part of the raphé gray (figs. 8, 9, 14, 15). This part appears caudally in planes in front of the rostral pole of the dorsal tegmental nucleus and extends forward to levels cutting the caudal pole of the trochlear nucleus. In this region the dorsal nucleus of the raphé is continued, as a frontal undifferentiated portion of this nuclear mass, by a cluster of smaller, more scattered neurons (fig. 7, Q), which pass over without demarcation into the central gray in planes through the caudal end of the oculomotor nucleus. The lateral part of this dorsal nucleus, then, is not sharply delimitable either caudally or frontally from surrounding gray. It is composed of neurons similar to those constituting the central part of the nucleus but it is paired, a column of cells forming a pars lateralis lying on either side of the central part of the dorsal nucleus of the raphé. Caudally, these cell columns are perpendicular but as they are traced forward they take an oblique position, like the spread-out leaves of an opened book, and reach their greatest extent in planes through the caudal pole of the trochlear nucleus. Within this pars lateralis fall nucleus lateralis anuli aquaeductus of Ziehen ('20) and nucleo ventrale del grigio centrale, parte laterale of Castaldi ('23).

#### *Laterodorsal tegmental nucleus*

At planes through the inferior collicular levels of the midbrain, in the lateral part of the central gray, a nucleus laterodorsalis tegmenti appears (fig. 8). This gray mass, which corresponds in general to a similarly designated cell group in the guinea pig (Castaldi, '26), extends caudalward through the isthmus region and to the level of

entering trigeminal roots, maintaining throughout its lateral position. At first it lies lateral to the dorsal nucleus of the raphé and the surrounding undifferentiated ventral nucleus of the central gray (fig. 14). Farther caudalward the dorsal tegmental nucleus appears on its medial border (fig. 10), fitting into a depression in the laterodorsal tegmental nucleus. At the level of the dorsal tegmental nucleus, the laterodorsal tegmental nucleus extends into the underlying tegmentum and, as it is followed through the isthmus region, is in very close relationship with the nucleus of the mesencephalic root of V and the associated cells which constitute the homologue of the human nucleus loci coerulei (fig. 10). It disappears in planes through the rostral end of the motor nucleus of the trigeminal nerve. The area may be secondarily subdivided into a dorsomedial or medial portion, which lies in particularly close relation to nucleus dorsalis tegmenti, and a ventrolateral or lateral part, especially related to the nucleus of locus coeruleus, with which at some levels it is so intermingled as to make differentiation between the two exceedingly difficult (fig. 10). The relations suggest that nucleus loci coerulei is differentiated from the ventrolateral or lateral part of the laterodorsal tegmental nucleus, particularly its more caudal portion. The neurons of the latter nucleus are intermingled medium-sized and smaller elements, the medium-sized being the less numerous but the more conspicuous cells of the cell mass. The laterodorsal tegmental nucleus has received various designations. A list of synonyms may be found in the 1926 paper of Castaldi.

There is very considerable difference of opinion with regard to nucleus loci coerulei of various mammals, particularly in respect to its relations with the nucleus of the mesencephalic root of V and nucleus laterodorsalis tegmenti. Nucleus loci coerulei is pigmented in man (Meynert, 1872; Forel, 1877; and others). Forel (1877) believed that in subprimates the comparable region is unpigmented, so that its cells are scarcely distinguishable from the neurons of the central gray. Thelander ('24) described pigment in the cells of locus coeruleus in the cat, but Castaldi ('26) denied its existence in the guinea pig, confirmed Forel's findings, and placed the gray of the region with nucleus laterodorsalis tegmenti. Just as it is difficult on the one hand to distinguish in subprimates between nucleus loci coerulei and nucleus laterodorsalis tegmenti, so, on the other hand, it is not possible to draw a sharp line, except on the basis of cell character, between the former nucleus and the nucleus of the mesencephalic root of V. Allen ('19), agreeing with Henle (1871, quoted from Duval, 1879) and Kohnstamm and Quensel ('08), regarded nucleus loci coerulei as composed of vesicular cells intermingled with those of the nucleus of the mesencephalic root of V. Held (1893)

thought that part of the motor root of V arose from nucleus loci coerulei and Johnston ('09; mole, cat, man) was of the opinion that this nucleus supplied sensory fibers to the mesencephalic root of V, which he interpreted as joining the sensory root of the trigeminal nerve. Sterzi ('15, quoted from Castaldi, '26) differentiated between the vesicular cells of the mesencephalic root of V and the neurons forming nucleus loci coerulei and stated that the rostral tip of locus coeruleus sometimes extended into the mesencephalon. Sheinin ('30) also was able to differentiate between the cells of nucleus loci coerulei and those of the mesencephalic root of V but extended the frontal limit of the former nucleus only as far as the aqueduct.

In the carnivore material available, nucleus loci coerulei lies along the ventrolateral angle of the fourth ventricle in the lateral margin of the periventricular gray (fig. 10), from a plane through the rostral half of the motor nucleus of V to a plane through the rostral pole of the dorsal tegmental nucleus. It has similar relations and cytoarchitecture in both of the carnivores studied, but in the cat it is composed of a greater number of neurons than in the dog. Its neurons are not sharply clustered but are scattered in the central gray and even shallowly into the underlying reticular area. Frequently its cells lie among the vesicular elements of the nucleus of the mesencephalic root of V which bound them laterally. The slightly smaller size, the definite multipolarity and the coarser Nissl substance of the neurons of nucleus loci coerulei make them readily distinguishable from the larger, round or oval, unipolar cells with finely granular Nissl substance which constitute the nucleus of the mesencephalic root of V.

#### *Dorsal tegmental nucleus*

In the same paper in which von Gudden (1889; pl. XXX, fig. 5, d.G.) described the ventral tegmental nucleus, he indicated another distinct nuclear mass which he termed the dorsal ganglion. Since that time, various names have been used for this nuclear complex, among which is that of dorsal tegmental nucleus.

In the dog and the cat, the dorsal tegmental nucleus is located on either side of the raphé within the central gray matter of the isthmus, at the level of the decussating trochlear nerve and dorsal to the medial longitudinal fasciculus (fig. 10). Bordering the frontal regions of this nucleus dorsolaterally are the still larger but scattered cells of nucleus laterodorsalis tegmenti (fig. 14). Throughout its rostral half, the dorsal tegmental nucleus lies close to the dorsal border of the medial longitudinal fasciculus, separated from it only by a thin stratum of the central gray, and lying medial and in part ventromedial to the laterodorsal tegmental nucleus. In cross section

the nucleus under consideration is rounded in outline and is constituted of numerous, closely packed, small cells. Sagittally it has the form of a relatively short, thick column, more conspicuous in the cat than in the dog. In the dog, the dorsal margin of this nucleus is slightly curved, with its very shallow concavity directed dorso-frontally (fig. 14). At the level of the midfrontocaudal extent of the dorsal tegmental nucleus, the somewhat scattered and larger neurons of the pontine part of the annular nucleus appear along the rather dorsally situated ventral and ventromedial border of the dorsal tegmental nucleus, between it and the medial longitudinal fasciculus (fig. 14).

The caudal half of the dorsal tegmental nucleus increases in size dorsally in the cat. In consequence, a short, more ovoid dorsal tegmental nucleus, devoid of any dorsal curvature, is found in this carnivore in comparison with the more uniformly columnar nucleus of the dog. The dorsal tegmental nucleus of both carnivores is composed of small neurons, distinguishable by their slightly larger size and closer arrangement from the cells of the surrounding central gray matter.

#### *Nucleus of mesencephalic root of V*

This nucleus, first correctly described by Meynert (1872) as "small collections of bladder-shaped cells which lie in a curved line around the outer edge of the thick wall of gray substance which surrounds the aqueduct," was earlier considered by Stilling (1846), Stieda (1870) and Henle (1871) as a part of the trochlear nucleus. Since Meynert's classical treatise, Henle (1879), Johnston ('09), Willems ('11), Castaldi ('26), Weinberg ('28), Schneider ('28) and others have regarded this cell mass as being distinct from the trochlear nucleus.

In the dog and the cat the nucleus of the mesencephalic root of V extends from the level of the posterior commissure to that of the motor nucleus of V, attaining a length of about 11.7 mm. (figs. 4, 7, 8, 10, 11). It forms a narrow, curved band of cells bordering the periventricular gray and conforming to all of the contiguous angles and curves of the latter throughout its adjacent course. The more rostral portion of the nucleus of the mesencephalic root of V lies along the dorsolateral edge of the periventricular gray. However, the nuclei of the two sides are not continuous, even though occasionally neurons lie near the midline above the aqueduct. From its rostral to its caudal end, this nucleus gradually slants ventralward so that it extends rostrocaudally from a position where it adjoins the dorsolateral edge of the periventricular gray to the lateral and, farther back, to the ventrolateral edge of this gray.

Along the extent of the nucleus, three major enlargements have been recognized. The first cell aggregation, the largest in the dog and cat material available, constitutes the superior collicular group lying along the lateral and dorsolateral border of the central gray matter at the level of the oculomotor nucleus (fig. 7).

A second marked accumulation of cells of the nucleus of the mesencephalic root of V, although somewhat smaller than the first in our material, lies along the lateral edge of the gray substance in the isthmus region at the level of the trochlear decussation, and may be designated as the isthmus group. Johnston ('09) believed that the largest collection of neurons of this nucleus occurs in mammals, in the region of locus coeruleus. According to him the cells of locus coeruleus not only supply fibers of the same type as those found in the mesencephalic root, but also are the main source of the nuclear mass and, frontal and caudal to it, the nucleus of the mesencephalic root of V is diminished. As has been seen, many observers do not accept this interpretation. In the region of the anterior medullary velum, just rostral to the crossing of the trochlear nerves, the cells of the mesencephalic root of V lie medial to the trochlear fibers. In planes in which these fibers curve medially to decussate within the velum, some of the cells of the nucleus lie also at the lateral edge of the velum (fig. 10). Thus the first and second groups are connected by a thinner line of cells.

The most caudal nuclear enlargement associated with the mesencephalic root of V extends down as far as the ventrolateral corner of the gray substance, in the region just anterior to the motor nucleus of V. This mass is considerably smaller and less distinct than either of the preceding groups, although connected with the isthmus group by small clusters of neurons. On the whole, the nucleus of the mesencephalic root of V displays a continual diminution in size from its rostral to its caudal end in the carnivores considered. Sometimes one or two cells can be observed slightly lateral or medial to the more or less regular band-like nuclear formation, a situation apparently of no special significance.

In the cat and dog material studied, the cells of the nucleus of the mesencephalic root of V are either small or large, round or oval neurons. A few multipolar cells are present in the vicinity of the nucleus, most of them lying either lateral or medial to it. However, only rarely is such a cell found in the nucleus proper. For the most part, the smaller cells, which stain less intensively than the larger neurons, predominate in the dorsal part of the nucleus, the larger, more deeply stained cells being more numerous in the ventral portions.

Such a cellular differentiation is in conformity with the findings of Schneider ('28), Weinberg ('28) and Sheinin ('30) for various mammals.

The larger cells of the nucleus of the mesencephalic root of V, particularly because of their flask shape and unipolarity, bear a close resemblance in size and general appearance to spinal ganglion cells, except that the single process of the former is not coiled about its cell body like that of the latter (Allen, '19) nor is there as yet a demonstrable pericellular capsule (Forel, 1877). Histologically, the cells do not appear to be motor in type since they have exceedingly minute Nissl granules scattered uniformly throughout their cytoplasm. Some of the less large cells found in the nucleus are of the unipolar type also; certain of the smaller cells are bipolar in form. The general morphologic similarity of these neurons to those of the spinal ganglion suggests that cells of the nucleus of the mesencephalic root of V have a sensory function. Held (1893), von Kölliker (1896), Kohnstamm and Quensel ('08), Terni ('12) and Castaldi ('26) have held, however, that these cells are wholly or in part multipolar in form and so of motor function. Obersteiner (1887), Johnston ('09) and Willems ('11) believed they may be bipolar. Meynert (1872), Johnston ('09), Willems ('11), Schneider ('28), Weinberg ('28) and Sheinin ('30) found unipolar cells predominating in the nucleus, a statement which this study of the dog and the cat documents. Johnston ('09), May and Horsley ('10), Willems ('11), and Weinberg ('28) regarded the nucleus as concerned with proprioceptive impulses from the extrinsic muscles of the eyeball and the muscles of mastication. The suggestion of Lewy, Droff and Grant ('38) that the nucleus of the mesencephalic root of V contains cells of origin for parasympathetic fibers distributing through the trigeminal nerve requires substantiation and has not been documented by the results of Corbin and Harrison ('40) and Corbin ('40). These latter observers found that when the masticator muscles of the cat were stretched by opening its jaw, action potentials, such as were obtained from proprioceptive impulses elsewhere, were demonstrable from all parts of the mesencephalic root of the trigeminal.

The evidence at present available indicates strongly that the nucleus of the mesencephalic root of V is a sensory ganglion spread out within the brain wall, with peripheral distribution through trigeminal and probably through oculomotor and trochlear nerves.

In his comprehensive report on the nucleus of the mesencephalic root of V, Weinberg ('28) gave an excellent account of its presence in the cat and Tamthai ('43) has described it in the present series of papers for the mink. It seems, therefore, unnecessary to consider the nucleus further in the present report.

## MIDTEGMENTAL NUCLEAR GROUPS

*Red nucleus*

At superior collicular levels of the midbrain tegmentum the red nucleus (figs. 3 to 6, 15 to 17) is present as a conspicuous, ovoid group of cells. Its sharply circumscribed caudal pole is rostral to a transverse plane passing in front of the decussation of the brachium conjunctivum. The red nucleus continues forward through the reticular formation to end rostrally, in front of the oculomotor nerve roots, in a plane passing through the posterior commissure dorsally and the caudal end of the mammillary body ventrally. Its frontal pole is not sharply delimitable from the surrounding gray.

As the fibers of the brachium conjunctivum ascend after their decussation, they penetrate the red nucleus breaking up its gray into small cell clusters. Some of the fascicles pass around the periphery of the nuclear mass forming a more or less complete capsule for it (figs. 3, 5, 16, 17). The presence of such a fibrous capsule in the dog was denied by Hatschek ('07); however, von Monakow ('10) and Rioch ('29 b) recognized it in carnivores. This capsule delimits the red nucleus from the surrounding areas. The nucleus lies dorsal and dorsomedial to substantia nigra, dorsolateral to the interpeduncular nucleus, ventrolateral to the medial longitudinal fasciculus and ventromedial to pars dorsalis of nucleus lateralis profundus mesencephali. At the level of the oculomotor nerve roots, fibers passing from their nucleus of origin toward their emergence on the ventral surface of the midbrain follow a curved path and penetrate the medial region of the red nucleus, resulting in a secondary subdivision of its cells into what Davenport and Ranson ('30) have called adventitious groups.

The red nucleus is composed primarily of large and small multipolar neurons, although various intergrades between these types may be found. The regional distribution of cell types within the red nucleus of carnivores has been noted by various observers (Hatschek, '07; von Monakow, '10 and others) and the present study is largely confirmatory of their conclusions, for, as they found, the large cells are most conspicuously present at the caudal pole and the smaller cells are most numerous toward the middle and rostral parts of the red nucleus.

Magnocellular and parvocellular portions of the nucleus then can be demonstrated in the dog and the cat. The large celled portion (figs. 3, 5, 6, 15 to 17) forms the caudal pole of the nucleus and tapers off as it is followed rostrally. Ultimately it is represented by only occasional scattered neurons. The small celled portion (figs. 3, 5, 6, 16, 17), on the contrary, is largest frontally and decreases in size at

levels at which an overlap of the magnocellular and parvocellular portions occurs. Hatschek ('07, dog) found that the rostral end of the large celled part, disappears first dorsally. In the material available for the present study the large celled portion diminishes in size and disappears first ventrally and ventrolaterally (figs. 16, 17). The small celled part replaces the large celled portion throughout the midregions of the nucleus and in front of it. At levels at which both portions are represented, the large cells are fairly distinctly separated from the more numerous smaller cells by thick band-like fiber fascicles, said to be longitudinally coursing bundles of the brachium conjunctivum (figs. 3, 5, 6, 16 17). This constitutes the lacerated portion described by von Monakow ('10, dog). Even at the frontal tip a few large cells are intermingled with the parvocellular portion of the nucleus. The separation into large and small-celled portions is more distinct in the dog than in the cat (compare figs. 3 and 5). This statement is in agreement with the account of Davenport and Ranson ('30). The red nucleus has approximately the same rostro-caudal extent in both carnivores.

In the cat but not in the dog material a small compact group of tiny cells, termed nucleus minimus by Mahaim (1894), von Monakow ('10) and Davenport and Ranson ('30), lies near the lateral margin in midregions of the red nucleus. Preisig ('04) was unable to find nucleus minimus in rodents and Forel (1877, dog) Hatschek ('07, carnivores and primates), Ramón y Cajal ('09-'11, cat) and Rioch ('29 b, cat) did not mention it in their accounts of the red nucleus. However, Tamthai ('43) identified it in the mink. Since nucleus minimus has been identified only rarely, it is not possible to state whether it is constantly present in a given species. It may appear occasionally yet inconstantly, or possibly it represents some form of individual variation.

#### *Deep mesencephalic gray (nucleus mesencephalicus profundus)*

The reticular area of the midbrain tegmentum, long known as formatio reticularis, lies dorsal to substantia nigra, ventral to the periventricular gray and lateral to the midline. Occupying much of this region at the level of the superior colliculus is the very conspicuous red nucleus which has developed phylogenetically from the reticular area (Hatschek, '07; Ariëns Kappers, Huber and Crosby, '36).

Much of this formatio reticularis consists of intermingled larger and smaller elements without specific grouping. The former are deeply stained and the latter are smaller, less intensively stained, multipolar neurons. There are many fibers of passage through the area.



Rostrally, this *formatio reticularis* replaces the diencephalic gray and caudally it passes over without sharp demarcation into the pontine tegmentum. The magnocellular portion of the red nucleus represents a differentiation from the large celled elements of the reticular formation. To collections of large cells of a similar type in the region around the red nucleus, the term *nucleus mesencephalicus profundus* has been given (see also Castaldi, '23, p. 144, for a list of synonyms).

Clusters of cells dorsal to the red nucleus constitute a *pars dorsalis* of *nucleus mesencephalicus profundus*. Laterally and without sharp boundaries, this accumulation blends with another cluster of similar neurons lateral to the red nucleus. This latter group is *pars lateralis* of *nucleus mesencephalicus profundus* (figs. 3 to 5).

Caudal to the emerging oculomotor nerve fibers and medial and ventral to the red nucleus, the smaller tegmental cells tend to be arranged in areas of slight concentration. These tegmental areas, for which no previous descriptions have been found, are devoid of the larger elements of *nucleus mesencephalicus profundus*. They have extended forward from the pontine tegmentum in company with the larger cells and together with the latter surround the caudal half of the red nucleus at superior collicular levels. Rostral to the oculomotor fibers, the areas medial and ventral to the red nucleus are filled only by cells that are diffusely scattered without grouping.

#### *Nuclear groups associated with medial longitudinal fasciculus*

Two midbrain nuclear groups are directly associated with the medial longitudinal fasciculus. These are the interstitial nucleus of the medial longitudinal fasciculus and the annular nucleus.

In planes through the frontal regions of the mesencephalon there is a rather scattered group of medium- to large-sized, not intensively stained, multipolar cells—the interstitial nucleus of the medial longitudinal fasciculus. In position, they are closely related to this fasciculus, between the fibers of which the neurons are interspersed (figs. 2 to 5). This nucleus is ventrolateral to the nucleus of Darkschewitsch as termed by Ramón y Cajal ('09-'11), lateral to the ventrolateral part of the central gray matter, dorsomedial to the rostral end of the red nucleus (figs. 3, 4) and dorsolateral to the oculomotor nucleus (fig. 5). The rostral end of the interstitial nucleus of the medial longitudinal fasciculus contains more cellular elements than does its more caudal portion. Near its frontal pole, it is pierced by the habenulo-peduncular tract, at which level a considerable diminution in the size of the nucleus is observed. Its rostral pole, which extends forward into the diencephalon, consists only of scattered cells.

The interstitial nucleus of the medial longitudinal fasciculus corresponds to the upper oculomotor nucleus described by Darkschewitsch (1885 and 1889), to nucleus commissurae posterioris of von Kölliker (1896), and to the nucleus of Darkschewitsch according to Zeri (1895; quoted from Ingram and Ranson, '35). The Castaldi ('24) nomenclature terms this nucleus the interstitial nucleus of the medial longitudinal fasciculus, but the older, and widely used Ramón y Cajal terminology, has confused this nucleus (interstitial nucleus of Ramón y Cajal, '11) with the nucleus of Darkschewitsch (of Ramón y Cajal, '11).

Castaldi ('23) has given an excellent description of a group of neurons in the guinea pig which he termed *nucleo anulare del fasciculi longitudinalis posterioris*. This cell mass is comparable to *der Ringkern des hinteren Längsbündel* as designated by Ziehen ('20) in man. The present study reveals the presence of an annular nucleus of the medial longitudinal fasciculus in the carnivores, similar in many respects to that described for the guinea pig.

In both the dog and the cat, the cells of the annular nucleus (figs. 10, 14, 15) make their frontal appearance either at the level of the rostral pole of the trochlear nucleus or in front of that pole. In fact, widely scattered cells connect the annular nucleus with the interstitial nucleus of the medial longitudinal fasciculus. The neurons of the annular nucleus are irregularly scattered along the ventromedial and ventrolateral borders of the medial longitudinal fasciculus, as well as interspersed among its fascicles. Frequently they become loosely grouped into small and irregular masses (figs. 14, 15).

At the level of the trochlear nucleus, neurons of the annular nucleus are lacking in the dog, although in the cat a small group of cells is present, the conditions in the latter animal more nearly agreeing with those described in the guinea pig (Castaldi, '23) and man (Ziehen, '20). Although maintaining neither regularity in size nor continuity between cell clusters, caudal to the trochlear nucleus the annular nucleus displays its characteristic position in relation to the medial longitudinal fasciculus. In the guinea pig, the annular nucleus forms a horseshoe-shaped mass ventral and ventromedial to the medial longitudinal fasciculus but in this position the gray was poorly represented in the carnivores studied, the greater part of the annular nucleus lying distinctly more lateral than in rodents.

At the level of the frontal pole of the dorsal tegmental nucleus, the neurons of the annular nucleus become more numerous and spread dorsalward, through the more lateral regions of the medial longitudinal fasciculus, so that, at the level of the middle of the dorsal tegmental nucleus, the cells of the annular nucleus intervene between it and the

dorsal border of the medial longitudinal fasciculus. Caudalward these dorsally lying cells of the annular nucleus increase still more until a conspicuous mass is found along the dorsal edge of the fasciculus (fig. 15). The dorsal tegmental nucleus, tapering toward its caudal pole, overrides dorsally the unusually increased mass of cells of the annular nucleus. Such an accumulation is greater in carnivores than Castaldi ('23) found to be the case in rodents, but in both animals it marks the caudal extent of the annular nucleus of the medial longitudinal fasciculus, and the level at which the sparsely scattered, medially placed cells blend with the neurons of the raphé.

*Nucleus medialis profundus*

Nucleus medialis profundus (Castaldi, '23) has been described under various names such as Gudden's ganglion (so termed by its discoverer von Gudden, 1889), ganglion tegmenti profundum of von Gudden (Hatschek, '03) and, rather generally, nucleus ventralis tegmenti (Ramón y Cajal, '09-'11). For a more complete list of synonyms reference may be made to the paper by Castaldi quoted above. This nucleus lies in the dorsomedial tegmental portion of the isthmus region, at the level of the decussating trochlear nerve, lateral to the raphé and ventral to the medial longitudinal fasciculus, its position being the same in both the dog and the cat. In cross section it is a round, all gray mass (fig. 10), but sagittally it shows a columnar form (figs. 14, 15) comparable to that of the corresponding gray figured originally by von Gudden for the rabbit (1889, pl. XXX, figs. 4 and 5, G.G.). The comparative studies of Hatschek ('03) showed this nucleus to be relatively larger in lower than in higher mammals, a difference which is documented if the large nuclear mass of the rabbit is compared with the corresponding but smaller nucleus of the dog. The ventral slant toward the rostral end is less marked in the carnivore nucleus medialis profundus than Hatschek ('03) found to be the case with its homologue in the guinea pig. This latter author believed that the tilting of the nucleus permitted its merging with nucleus centralis superior medialis, but in the carnivores studied both its frontal and caudal ends terminate without union with any other nuclear mass.

Larger and smaller neurons are present in nucleus medialis profundus. The larger are triangular or elongated in outline and laterally placed; the smaller are more medially situated. Ramón y Cajal ('09-'11) figured these cells in silver impregnation preparations and showed that the former had longer, little branched dendrites and the latter shorter dendrites.

A fibrous capsule has been described around the nucleus medialis profundus of some forms (Hatschek, '03). In the dog and cat, a few fiber bundles skirt the margins of the nucleus but are not sufficiently numerous to be considered as encapsulating it.

*Nuclear gray associated with lateral lemniscus*

At the level of the decussating trochlear nerves, the lateral lemniscus lies along the lateral side of the tegmentum in the isthmus region, passing lateral to brachium conjunctivum, between it and the outer margin of the brain stem (fig. 10). Intercalated among the lemniscal fibers are cells which have spread forward and dorsally from the caudal ventral nucleus of the lateral lemniscus (figs. 10, 18; inferior nucleus of the lateral lemniscus, Ramón y Cajal, '09-'11; lower or caudal nucleus of the lateral lemniscus, Ariëns Kappers, Huber and Crosby, '36) found in the upper pons region. Part of these cells maintain their ventral position frontally within the isthmus and appear as scattered, large, deeply stained, multipolar neurons along the ventromedial border of the lateral lemniscus.

At planes through the dorsal tegmental nucleus and dorsally placed among the fibers of the lateral lemniscus is a well circumscribed group of medium-sized polygonal neurons, the caudodorsal portion of the dorsal nucleus of the lateral lemniscus (figs. 10, 18; superior nucleus of the lateral lemniscus, Ramón y Cajal, '09-'11; upper or dorsal nucleus of the lateral lemniscus, Ariëns Kappers, Huber and Crosby, '36), which lies dorsolateral to brachium conjunctivum. Between this lemniscal gray mass and the more caudoventral nucleus of the lateral lemniscus are scattered interstitial cells which connect these two nuclear regions. The forward extension of this nucleus, represented by a not sharply differentiated cell mass beneath the inferior colliculus, represents the rostradorsal part of the dorsal nucleus of the lateral lemniscus.

Extending forward toward the medial geniculate nucleus, from planes through the caudal pole of the trochlear nucleus, is another gray mass related to the lateral lemniscus. Such a group of neurons is located in the dorsolateral part of the midbrain, along the rostro-lateral margin of the lemniscal fibers just ventral to the brachium of the inferior colliculus. Distinctly in the cat, less so in the dog, this nuclear accumulation produces a swelling on the lateral wall of the brain stem. It is termed here the rostral ventral nucleus of the lateral lemniscus (figs. 7 to 9). This nucleus is composed of small, rounded, multipolar neurons that are closely packed throughout the cell mass. Caudally and rostrally the cells are less numerous, tapering into scattered neurons intercalated among the lemniscal fibers (figs. 8, 9).

*Nucleus ventralis tegmenti*

In the ventromedial part of the midtegmental gray, between the oculomotor nerve roots and the mammillary body, and in planes passing slightly caudal to the rostral end of the red nucleus, there is a cellular area in the dog and the cat which corresponds in position to that termed nucleus tegmenti ventralis by Tsai ('25) in the opossum and nucleus ventralis tegmenti by Rioch ('29 a) in the dog, and includes the nucleus of the mammillary peduncle of Papez ('32, in the nine-banded armadillo). Neither Tsai nor Rioch described this nuclear mass, merely indicating its position on their figures, but the limits set for it in our material agree in general with those established for the homologous area by Papez.

No sharply defined boundaries circumscribe nucleus ventralis tegmenti (figs. 3 to 5, 15 to 17) but it lies ventromedial to the red nucleus, medial to the nucleus of the basal optic root (nucleus tractus peduncularis transversi) and substantia nigra, the cells of which are larger than those of the nucleus ventralis tegmenti, ventrolateral to the interstitial nucleus of the commissure of Forel, the cells of which are smaller, and lateral to the interpeduncular nucleus. Planes which cut through the habenulo-peduncular tract, lying lateral to the interstitial nucleus of the commissure of Forel, show nucleus ventralis tegmenti to be lateral to the tract (figs. 3, 4). Kosaka and Hiraiwa ('15) and Castaldi ('23) have interpreted this cell group as a part of substantia nigra, but from the material available, a distinct cell mass, unlike that of substantia nigra in cell structure or orientation, is present in the carnivores. Caudal to the oculomotor nerve roots, scattered tegmental cells, having little tendency toward grouping, continue caudalward, as far as a plane through the caudal regions of substantia nigra, in company with the accessory bundle of the mammillary peduncle (figs. 15 to 17).

Fewer discretely grouped cells are evident for nucleus ventralis tegmenti in the cat than in the dog. This is apparently the only difference between the nuclear mass in these carnivores. Triangular, fusiform and polygonal, large and small neurons filled with coarsely granular and even rod-shaped Nissl substance, possessing a distinct nucleus in which is a prominent nucleolus, make up this nucleus. Apparently those cells immediately adjacent to the mammillary peduncle are in synaptic relation with this system (see also Fox, '41). To these specifically the name of interstitial nucleus of the mammillary peduncle has been applied in the present series of papers.

## MIDLINE NUCLEAR GROUPS

*Linear nuclear gray*

Caudal to the decussation of the superior cerebellar peduncle between it and the raphé, a few elongated or spindle-shaped neurons, characterized by rather coarsely granular Nissl substance and a distinct nucleus containing a large, prominent nucleolus, lie in the midline region between the two medial longitudinal fasciculi (this region is termed *angustia* by Ziehen, '20). This linear gray lies directly between the two nuclei *mediales profundi*. Caudalward these linear cells blend into the dorsal region of the pontine raphé without sharp separation. Rostralward, at planes through the frontal end of nucleus *medialis profundus*, the linear gray extends obliquely rostroventralward (figs. 12, 13) with a tendency to form a row of more rounded and even angular neurons (*una bottoniera*, Castaldi, '23) symmetrically placed close to each side of the midline (fig. 10). These rows are more distinctly separated at some levels than at others. Still more frontally, a separation appears between the linear gray in the midline region and the oblique nuclear extension which, continuing rostroventrally, proceeds toward the caudal pole of the interpeduncular nucleus.

A few scattered cells of the dorsal linear gray spread ventrally into the caudodorsal part of the decussation of the superior cerebellar peduncle; however, the remainder of the decussation is cell-free except for neuroglial elements. The caudally lying, obliquely placed cellular extension is the caudal linear nucleus and corresponds to the nucleus of the same name of Castaldi ('23) and to the linear nucleus of Ramón y Cajal ('09-'11).

Rostral to the crossing of the superior cerebellar peduncle and between it and the caudal pole of the red nucleus, the dorsal linear gray continues forward, bearing the same relations to the medial longitudinal fasciculus as does the more caudal linear group. At planes through the caudal pole of the trochlear nucleus, it begins to expand rostroventralward, increasing in length *pari passu* as the frontal end of the decussation of the brachium conjunctivum is approached. This obliquely directed portion of the linear gray — the central or intermediate linear nucleus (caudal part of the central tegmental nucleus of Rioch, '29 a) — extends toward the interpeduncular nucleus, the dorsal border of which is capped by a few slightly larger and more deeply stained neurons (*foyer pediculaire* di Cajal, according to Castaldi, '23, fig. 47). These cells separate the interpeduncular nucleus from the linear nuclear gray (figs. 12, 13). Such a cell cap over the interpeduncular nucleus is better developed in the cat than in the dog.

The forward extension of the dorsal linear gray terminates in planes through the caudal third of the red nucleus. Ventrally, adjacent to the medial longitudinal fasciculus at this level, lies the dorsal tegmental decussation between which and the interpeduncular nucleus is the ventral tegmental decussation. No midline cells are present through these fiber crossings, except neuroglial elements.

The neurons of the rostral linear nucleus (figs. 3 to 5, 13) are few in number and widely separated, showing little change in amount throughout the nuclear extent. They appear abruptly, as the caudal end of the diencephalon passes over into the midbrain, and extend for only a short distance. They are not continuous with the intermediate part of the linear nucleus.

In the cat, the linear nuclei have the same relations except for the rostral linear nucleus. Neurons of this rostral linear gray spread rostroventrally toward the frontal end of the ventral tegmental decussation, at the same time producing two ventrally extending rows closely adjoining the midline (see Rioch, '29 a, fig. 2, n.cent.teg.); but this nucleus in the cat does not extend so far frontalward as its homologue in the dog, terminating in planes through the frontal regions of the red nucleus. However, like its counterpart in the dog, the rostral linear nucleus exists as a separate portion which is not continuous caudally with the central or intermediate linear nucleus.

#### *Interstitial nucleus of the commissure of Forel*

Scattered medium to small-sized polygonal cells, intercalated among the fibers of the commissure of Forel throughout its rostrocaudal extent, and continuing even slightly rostral and caudal to the decussating fibers, form the interstitial nucleus of the commissure of Forel (figs. 1, 3, 4, 13, 15, 16, 17; interstitial nucleus of the supramammillary decussation, Rioch, '29 a). Rostrally, this nucleus blends into the posterior gray of the hypothalamus without specific boundaries and caudally it disappears indistinctly by fading into the general tegmental and linear gray. The interstitial nucleus of the commissure of Forel is an unpaired midline nucleus, but, when followed rostrocaudally, two wings, one on either side, lead away from the nucleus and become more and more apparent (figs. 3, 4). In the dog, the dorsal border of these lateral extensions of the nucleus flares dorsolaterally toward nucleus lateralis profundus rostrally, and the red nucleus more caudally, producing a shallow curve, the convexity of which is directed dorsomedially (fig. 3). From the ventrolateral part of the lateral wings of the interstitial nucleus of the commissure of Forel strands of neurons extend toward the medial margin of substantia nigra and the nucleus of the basal optic root.

Through caudal levels, the habenulo-peduncular tract, as it passes laterally, lies in the shallow depression of the flared wings. Dorsal to the median portion of the interstitial nucleus, in the midline between the two laterally flared nuclear extensions, is the rostral linear nucleus. In the cat, the nuclear wings spread somewhat more directly lateralward than in the dog, frontal to the ventral half of the habenulo-peduncular tract, in order to approach the red nucleus, the rostral pole of which lies lateral to the interstitial nucleus of the commissure of Forel rather than dorsolateral as does its homologue in the dog. The rostral linear nucleus lies dorsal to the midline portion of the interstitial nucleus of the commissure of Forel, but since wings of the latter nucleus extend more directly lateralward in the cat than in the dog, no intimate relationship is established between them and the linear gray as in the former animal.

#### *Interpeduncular nucleus*

In the dog and the cat, the interpeduncular nucleus (figs. 1, 3, 4, 5, 7, 8, 9, 12, 13) is a long gray mass between the rostral pons region caudally and the caudal end of the mammillary nuclei frontally. Throughout its entire extent it is an unpaired structure located in the ventral midline (interpeduncular) region, underlying the ventral margin of the mesencephalic raphé (figs. 12, 13). Throughout the greater part of its extent, the interpeduncular nucleus is fairly well defined (fig. 7), but toward its frontal pole there is less and less differentiation of the nucleus from the surrounding gray (figs. 1, 3, 4, 5).

Followed rostrocaudally the interpeduncular nucleus gradually becomes more clearly differentiated from the cells of the ventral tegmental gray. Its small and medium-sized neurons are intermingled caudally (fig. 8), but soon differentiate into two areas which are more obvious in the cat (fig. 9) than in the dog. The small neurons (which are of very small size and more abundant than the larger cells) become better aggregated rostralward in the central part of the nucleus, although still intermingled to some extent with the large cells. The relatively larger but less numerous neurons spread toward the periphery of the nucleus (cf. the two zones of Ramón y Cajal, '09-'11). This separation is not clear-cut throughout the extent of the nuclear complex, for the outer zone does not appear to be a continuous cell mass but consists of elongated cell clusters separated by relatively cell free zones. The larger neurons are multipolar, with several widely directed processes. Their cytoplasm is relatively abundant and their Nissl granules are distinctly rod-shaped.



The smaller neurons, which have a relatively large nucleus and a prominent eccentrically placed nucleolus, are rounded in outline and multipolar, with fine Nissl granules.

Cellular differentiation within the interpeduncular nucleus has been observed by many investigators (Henle, 1871; Forel, 1877; von Gudden, 1881; Ramón y Cajal, '11, Castaldi, '23, and many others).

#### BASAL MIDBRAIN GRAY

##### *Substantia nigra*

In the midbrain section of a fresh specimen of a fully adult dog brain, a slightly pigmented area is observed overriding the fibrous mass of the cerebral peduncle. This is substantia nigra in relationships similar to those found for other higher mammals. The presence of pigment in this region in the dog is of particular interest since Obersteiner (1887) stated that substantia nigra is pigmented only in man and not in other animals, and Forel (1877) declared an unpigmented substantia nigra existed in animals below apes. However, pigmentation has been found in the series of studies of which this paper is a part, in ungulates (Gillilan, '43 b), and in monkeys (Crosby and Woodburne, '43 c).

Substantia nigra, extending from a level through the rostral edge of the pons to a plane adjacent to the caudal end of the mammillary body, exhibits a total length of about 6.6 mm. in the dog. Within this extent, the nuclear gray may be divided into three regions, each of which will be described separately.

Zona compacta is a part of the substantia nigra which has the greatest length of any of the three portions and is present practically throughout the entire extent of the midbrain. It corresponds to substantia nigra as used in the more restricted sense by Malone ('13). Since the cells of this part of the nucleus are grouped fairly closely together to form a thick, slightly curved band, the wide concavity of which is directed ventrolaterally, the name zona compacta, employed by Rioch ('29 b) and others is a useful descriptive term. This part of substantia nigra caps the underlying cellular and fibrous portions of basis pedunculi. It lies ventral to the midbrain tegmentum and sharply delimited from it by the closer arrangement and characteristic appearance of its constituent neurons (figs. 1, 3, 4, 5, 7, 16, 17). Definite grouping of the cells appears neither possible nor significant. The individual neurons are intensively stained, either triangular, polygonal or fusiform in shape, and medium to small in size. The nucleus of the basal optic root (fig. 1) lies along the medial margin of substantia nigra in planes through the rostral end of the mesencephalon, just in front of the emerging oculomotor fascicles.

The smallest part of substantia nigra is pars lateralis, which is located in the more frontal regions of the nuclear mass (fig. 3). As the name suggests, this portion lies distinctly lateral to the other subdivisions of the nuclear complex, along the outer part of the cerebral peduncle and just dorsolateral to the lateral extremity of zona compacta. Pars lateralis extends from a plane through the posterior border of the mammillary body to one passing through the caudal border of the root fibers of the oculomotor nerve. At this latter level, the lateral part of substantia nigra blends with the dorsolateral margin of zona compacta through a definite cellular fusion. The cells of pars lateralis, slightly larger than those of zona compacta, are chiefly triangular and fusiform in shape, but a few rounded neurons are found among them.

The third nuclear portion of substantia nigra is zona reticulata (figs. 1, 3, 5, 7), which corresponds to Ramón y Cajal's inferior zone and to Malone's nucleus intrapeduncularis. It lies ventral and ventrolateral to zona compacta, from which it is separated by a practically acellular fibrous layer known as stratum intermedium (Quain's Anatomy, 1882). In such a position, the cells of zona reticulata are intercalated among the more dorsal peduncular fibers so that the nuclear margins cannot be sharply delimited. Rostrally, zona reticulata extends to the frontal plane of the midbrain, but caudally it is found only as far as the level of the middle third of the interpeduncular nucleus.

In the dog and the cat, the cells of zona reticulata are slightly smaller and less intensively stained than those of zona compacta and show less tendency toward arrangement (Ramón y Cajal, '09-'11; Rioch, '29 b). Malone objected to the inferred significance implied by the term *zona reticulata*. For him, it denoted the presence of "cells of diverse histological character" and such cells, he said, did not occur. It is true that in *zona reticulata* the cells are histologically of the same type throughout but there are other interpretations than this author's of the significance of the term *zona reticulata*. Apparently Rioch intended to indicate that the cells were scattered forming a reticulum or lattice framework for the fibers. It is evident that such is the structure of the nucleus.

#### *Nucleus of basal optic root*

The nucleus of the basal optic root (*nucleus tractus peduncularis transversi*) with its connections and the pertinent literature (including such well known accounts as those of Marburg, '03; Wallenburg, '04 a; Bochenek, '08; and Castaldi, '23) have been considered recently for various mammals by Gillilan ('41). Since her account for carnivores was based on the same series used for this study, no further description of the cell group need be given here.

## SUMMARY

Nuclear differentiations characteristic of the mesencephalic periventricular gray are found chiefly within its ventral portion. They include, not only the eye-muscle nuclei, but the central and lateral parts of the dorsal nucleus of the raphé, the laterodorsal tegmental nucleus with the intimately associated nucleus of locus coeruleus, the components of which can be clearly distinguished from the near-lying neurons of the nucleus of the mesencephalic root of V. The dorsal tegmental nucleus, shorter and more ovoid in the cat than its columnar homologue in the dog, is likewise a ventral central gray modification. The nuclear gray associated with the posterior commissure is in part derived from the central gray.

The eye-muscle nuclei fall within the periventricular region. The oculomotor nuclei include the chief oculomotor nucleus, divisible into dorsolateral and ventromedial portions, and the Edinger-Westphal nucleus, the caudal half of which is paired in the dog but unpaired in the cat. The trochlear nucleus consists of a main portion continuous with the chief oculomotor nucleus in the cat, but separated from it in the dog, and a smaller caudal part. The posterior trochlear nuclei of the two sides are not bilaterally equal in size in either carnivore studied. The nucleus of the mesencephalic root of V is composed of unipolar neurons morphologically suggestive of a sensory function. Of its three major cell concentrations, all of which lie along the edge of the central gray matter, the superior collicular group is the largest.

The outstanding constituent of the midtegmental region is the red nucleus, the large and small cells of which predominate in the caudal and rostral regions respectively. The fibers of the superior cerebellar peduncle which form in the cat and dog more clearly than in the mink (Tamthai, '43) a more or less complete encapsulation for this nucleus, also penetrate the cell mass separating a dorsomedial magnocellular portion from a ventrolateral parvocellular part. Nucleus minimus is present in the cat, as it is in the mink (Tamthai, '43), but absent in the dog. At superior collicular levels, large, deeply stained multipolar cells of the reticular formation are grouped

The interstitial nucleus of the medial longitudinal fasciculus is a mass of neurons intercalated among the fibers at the frontal end of the fasciculus. It corresponds to the interstitial nucleus of Ramón y Cajal. The widely scattered elements of the annular nucleus, also intercalated among the fibers of the medial longitudinal fasciculus, but at more caudal levels than the interstitial nucleus of the latter, are more laterally placed than its homologue in certain rodents (Castaldi, '23). A distinct accumulation of cells occurs at the caudal end of the annular nucleus. Nucleus medialis profundus lies within the dorsomedial part of the isthmus and consequently behind the midbrain. It is composed of two types of neurons, and terminates rostrally and caudally without union with any other cell cluster. A fibrous encapsulation for this nucleus does not exist in the dog or the cat. The gray masses associated with the lateral lemniscus are well and typically developed.

Ventral to the mesencephalic central gray, in the midline region, are neurons constituting the linear complex. Three distinct parts — a caudal, an intermediate and a rostral linear nucleus — are recognized in this region. The rostral portion is discontinuous with the intermediate group. The interpeduncular nucleus, a midline cell group ventral to the linear gray, contains numerous small, centrally placed neurons and fewer large, more laterally displaced cells. The interstitial nucleus of the commissure of Forel, with its cellular elements intercalated among the corresponding commissural fibers, lies between the rostral linear nucleus, dorsally and the interpeduncular nucleus, ventrally. Lateral wings, which are strands of neurons fraying out toward the homolateral red nucleus and substantia nigra, extend from the central part of this cell mass.

A fresh, gross specimen of a fully adult dog brain shows, in the peduncular region of the midbrain, a slightly pigmented area in the region of substantia nigra. In the carnivores considered this area exhibits in the toluidin blue preparations the usual subdivision — zona compacta, pars lateralis and zona reticulata. In both the cat and dog, the nucleus of the basal optic root lies along the medial margin of substantia nigra, in

## PLATES 1 TO 12

## EXPLANATION OF FIGURES

1 Photomicrograph of a transverse section through the left peduncular region of the dog. Note the relationship of the nucleus of the basal optic root to substantia nigra. Toluidin blue preparation.  $\times 20$ .

2 Photomicrograph of a transverse section through the rostral end of the midbrain. Note the relative positions of the nucleus of Darkschewitsch and the interstitial nucleus of the medial longitudinal fasciculus. Dog. Toluidin blue preparation.  $\times 20$ .

3 Photomicrograph of a transverse section through rostral planes of the mesencephalon, passing through the frontal pole of the oculomotor nucleus. Attention is called to the large-celled and the small-celled portions of the red nucleus. Dog. Toluidin blue preparation.  $\times 8$ .

4 Photomicrograph of a transverse section through the midbrain of the cat at the rostral pole of the red nucleus. Toluidin blue preparation.  $\times 10$ .

5 Photomicrograph of a transverse section through the middle third of the oculomotor nucleus. Note the position of the median fissure in relation to the unpaired Edinger-Westphal nucleus, and also the tendency of the rostral linear nucleus to form two cellular areas. Cat. Toluidin blue preparation.  $\times 20$ .

6 Photomicrograph of a transverse section through the midregions of the oculomotor nucleus. Note the midline fusion (P) of the ventral tips of the ventromedial oculomotor nuclei. Dog. Toluidin blue preparation.  $\times 17$ .

7 Photomicrograph of a transverse section through the caudal region of the oculomotor gray. Dog. Toluidin blue preparation.  $\times 8$ .

8 Photomicrograph of a transverse section through the inferior colliculus slightly caudal to the trochlear nucleus. Dog. Toluidin blue preparation.  $\times 8$ .

9 Photomicrograph of a transverse section through the region between the caudal pole of the trochlear nucleus and the rostral pole of the dorsal tegmental nucleus. Cat. Toluidin blue preparation.  $\times 13$ .

10 Photomicrograph of a transverse section through the rostral isthmus region at the level of the trochlear decussation. Note the position of the cells of the annular nucleus of the medial longitudinal fasciculus. Dog. Toluidin blue preparation.  $\times 8$ .

11 Photomicrograph of a transverse section of the upper pons in a plane intersecting the rostral pole of the motor nucleus of the trigeminal nerve. Note the small and somewhat larger neurons of nucleus laterodorsalis tegmenti and also the caudal tip of the dorsal nucleus of the raphé. Dog. Toluidin blue preparation.  $\times 17$ .

12 Photomicrograph of a midsagittal section of the isthmus region. Attention is called to relationships of the linear gray at this level. Dog. Toluidin blue preparation.  $\times 13$ .

13 Photomicrograph of a sagittal section cut close to the midline. Note particularly the Edinger-Westphal nucleus. Dog. Toluidin blue preparation.  $\times 13$ .

14 Photomicrograph of a sagittal section through the midbrain of the dog. Note particularly nucleus dorsalis tegmenti and nucleus medialis profundus. Toluidin blue preparation.  $\times 18$ .

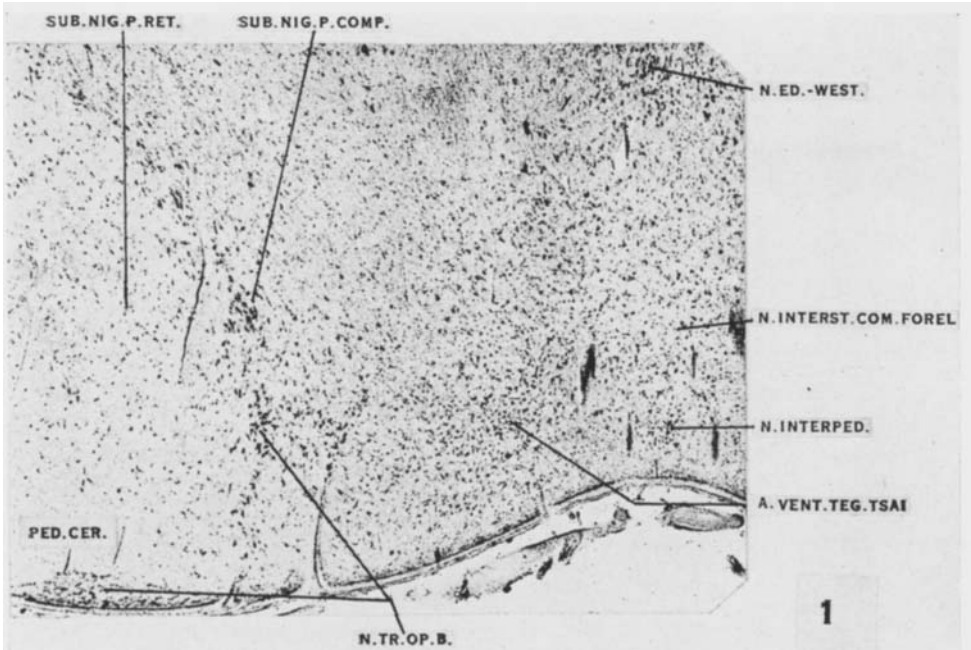
15 Photomicrograph of a sagittal section through the midbrain of the cat. The section has a slightly oblique tilt dorsoventrally. Toluidin blue preparation.  $\times 13$ .

16 Photomicrograph of a sagittal section through the red nucleus of the dog. The rostral diminution of the magnocellular part of the red nucleus along its ventral margin and its replacement by smaller cells is shown. Toluidin blue preparation.  $\times 13$ .

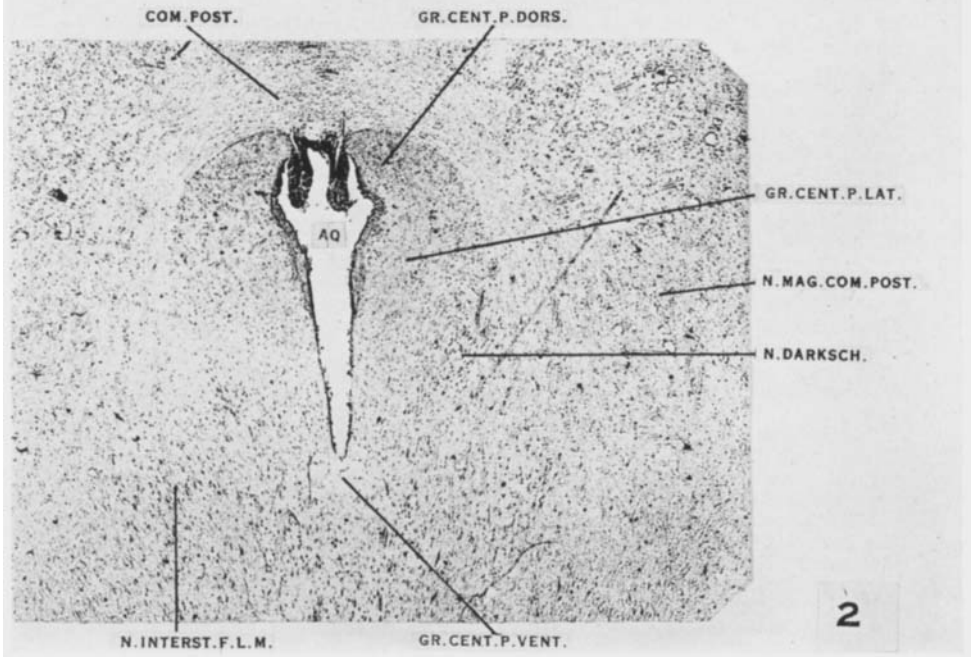
17 Photomicrograph of a sagittal section through the red nucleus in the cat. Compare this figure with figure 16, illustrating the red nucleus in the dog. Toluidin blue preparation.  $\times 13$ .

18 Photomicrograph of a sagittal section through the lateral part of the inferior colliculus and the isthmus region. Attention is drawn to the dorsal and ventral nuclei of the lateral lemniscus. Cat. Toluidin blue.  $\times 15$ .

PLATE 1



1



2

PLATE 2

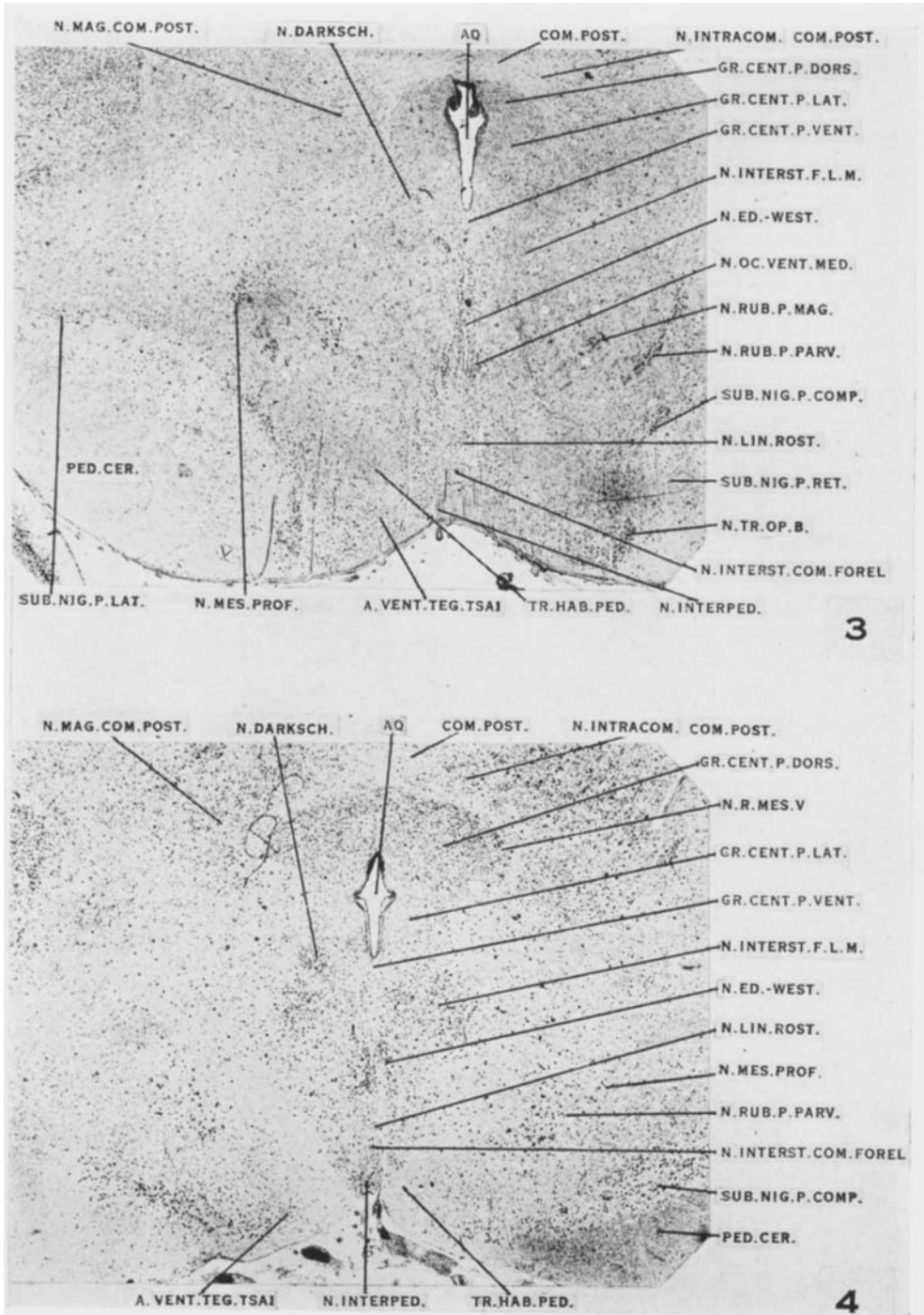


PLATE 3

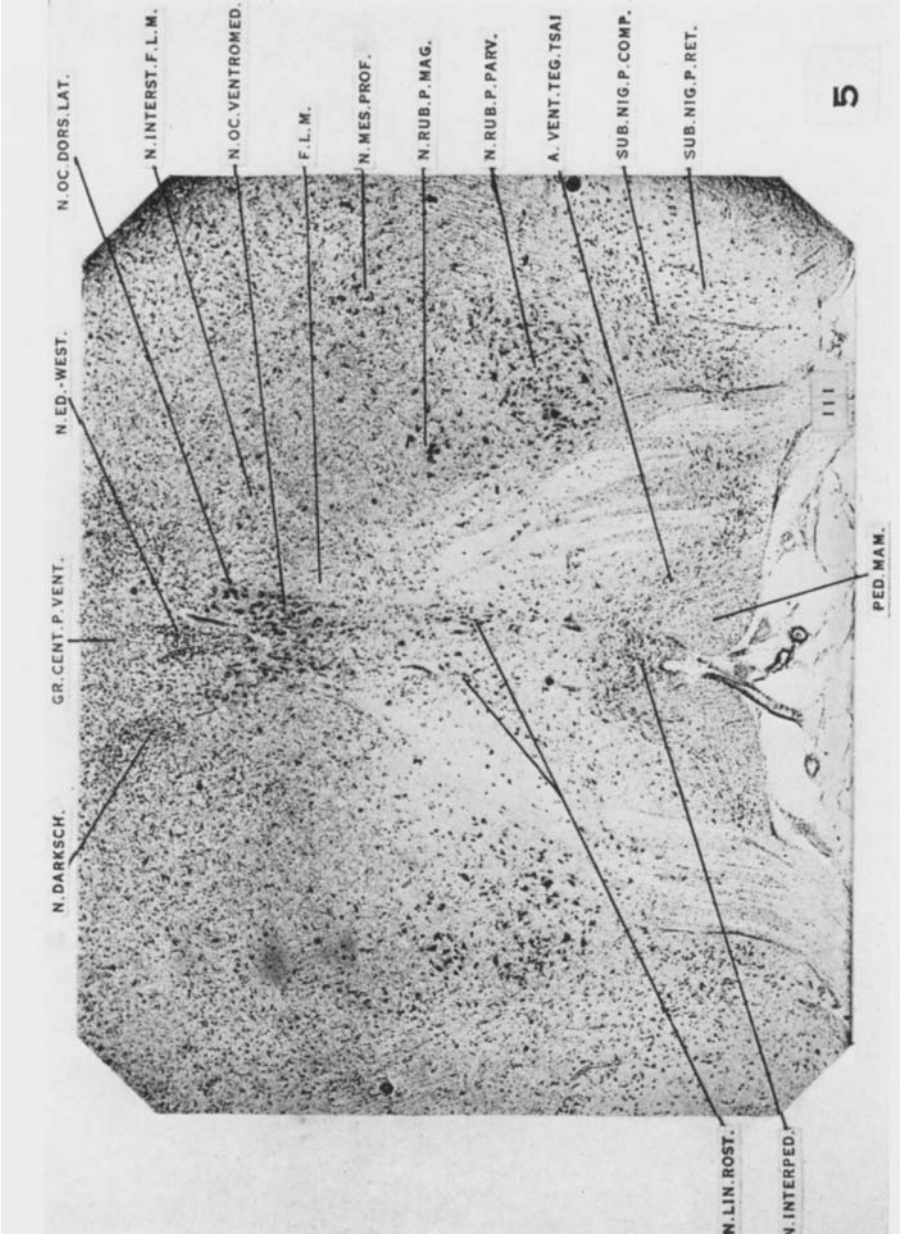




PLATE 4

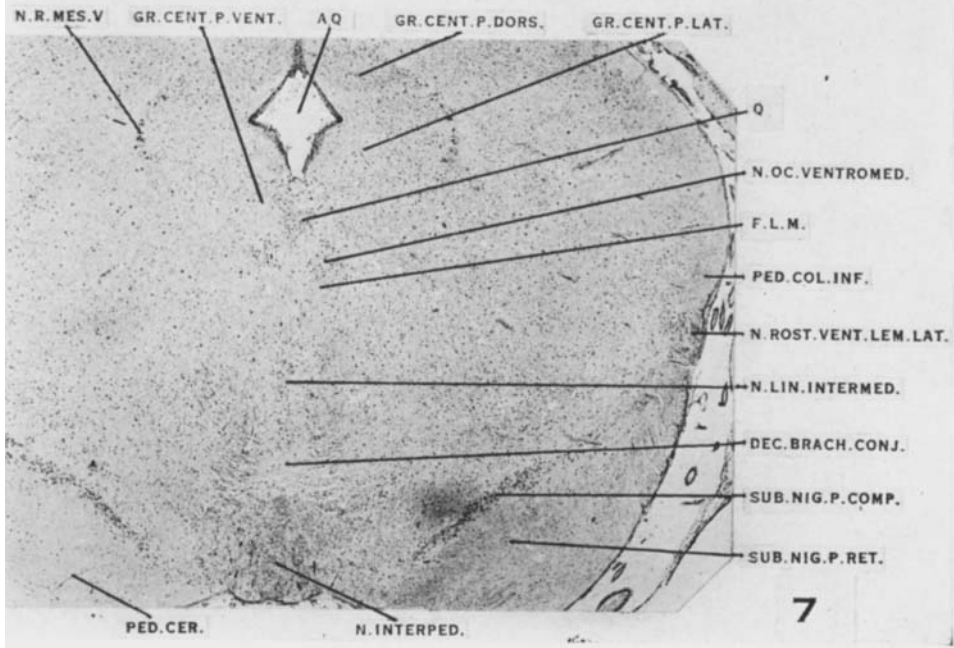
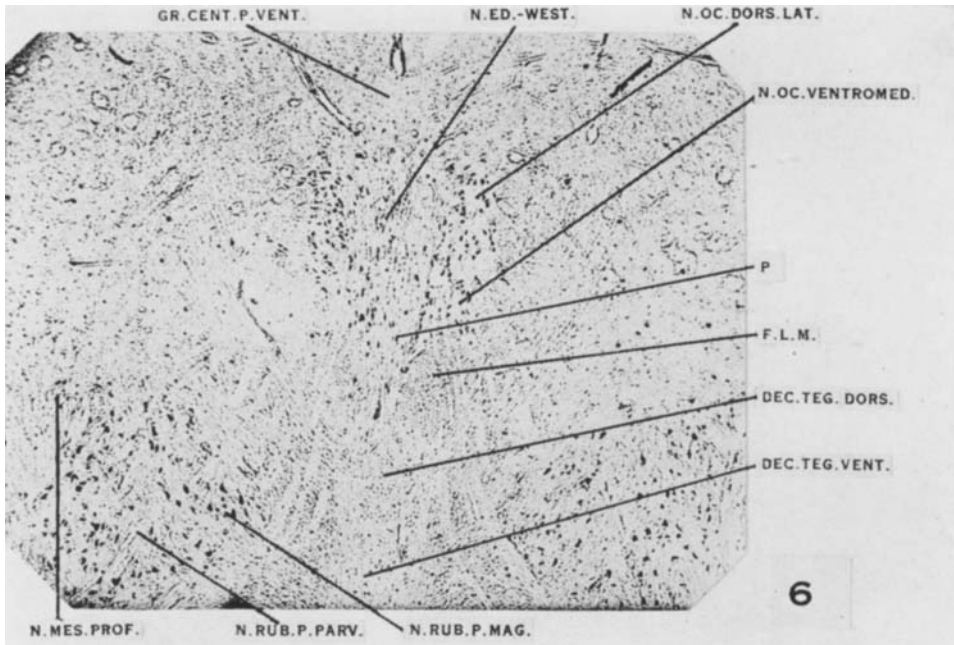


PLATE 5

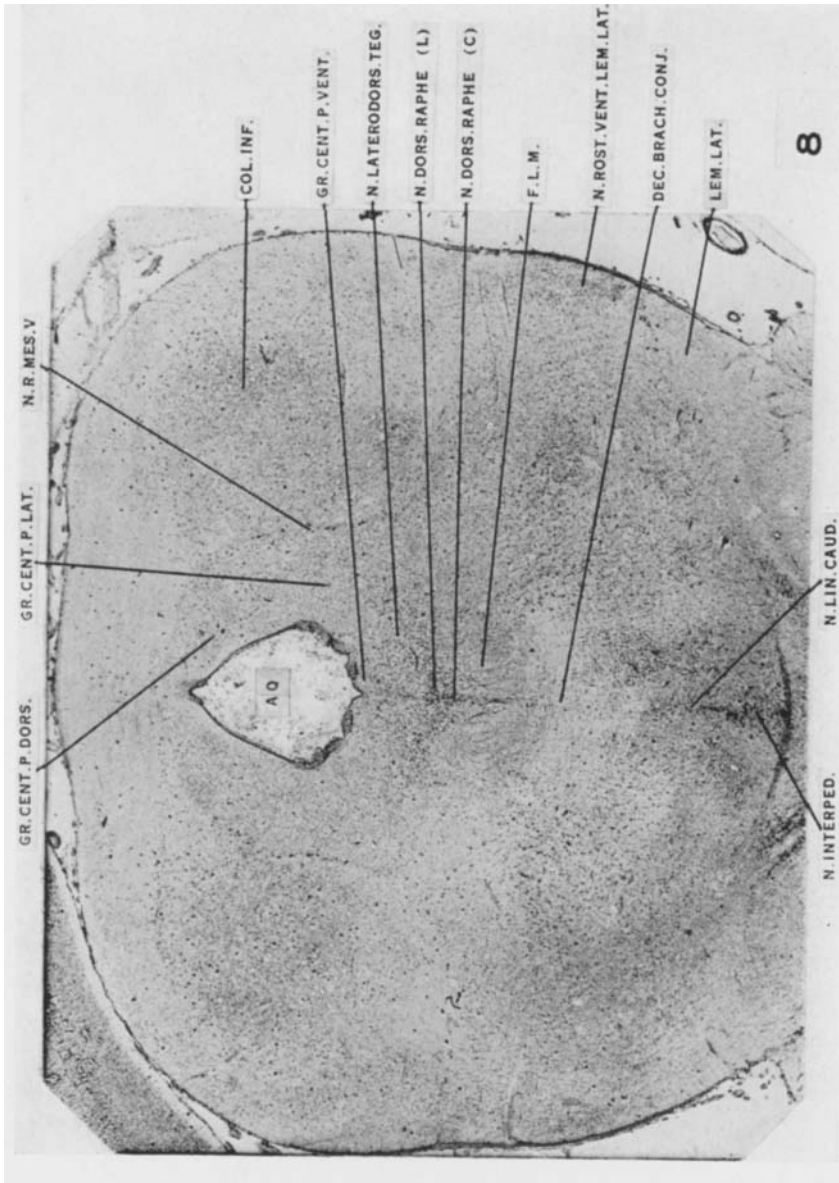
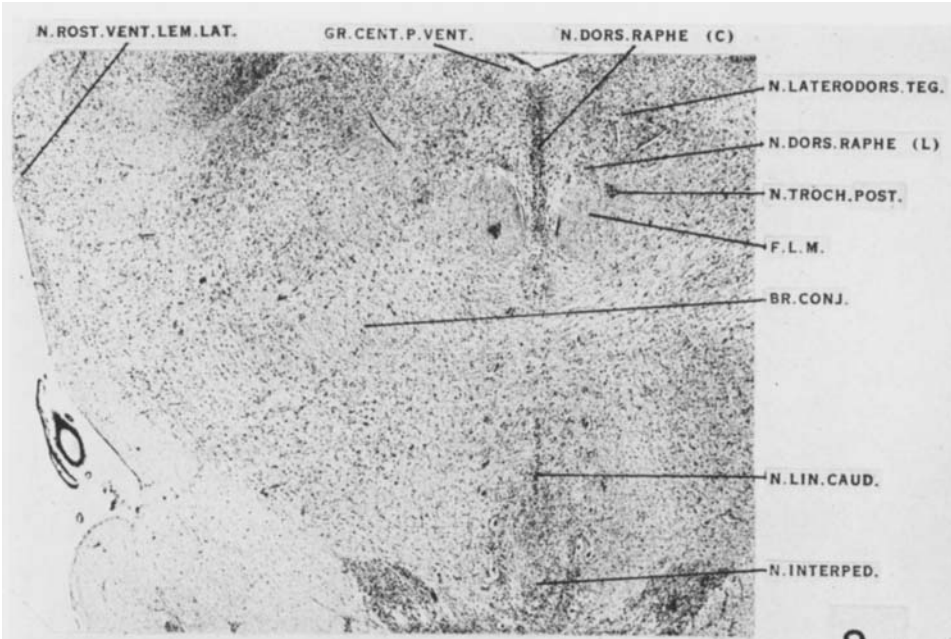
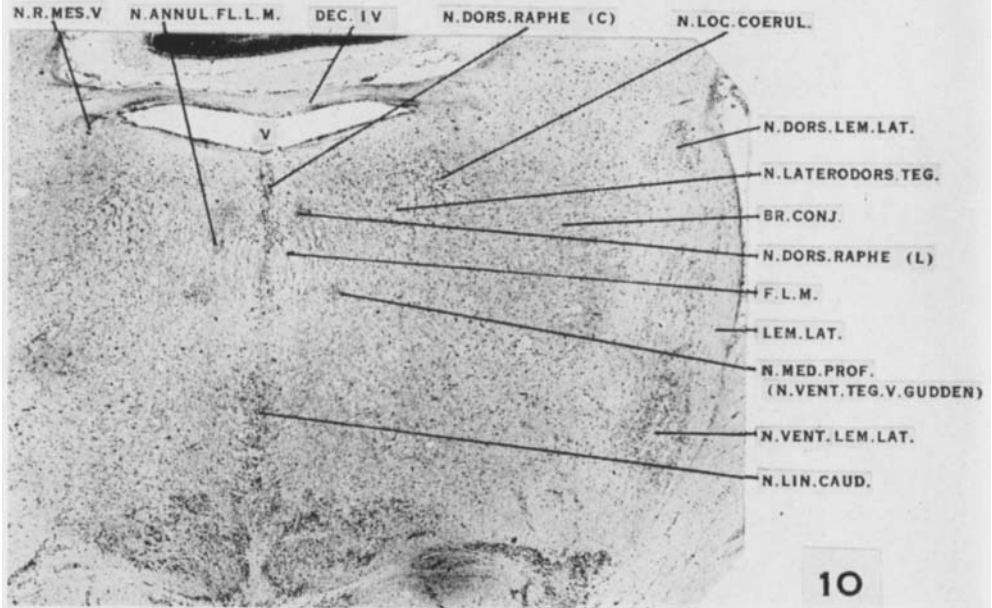


PLATE 6

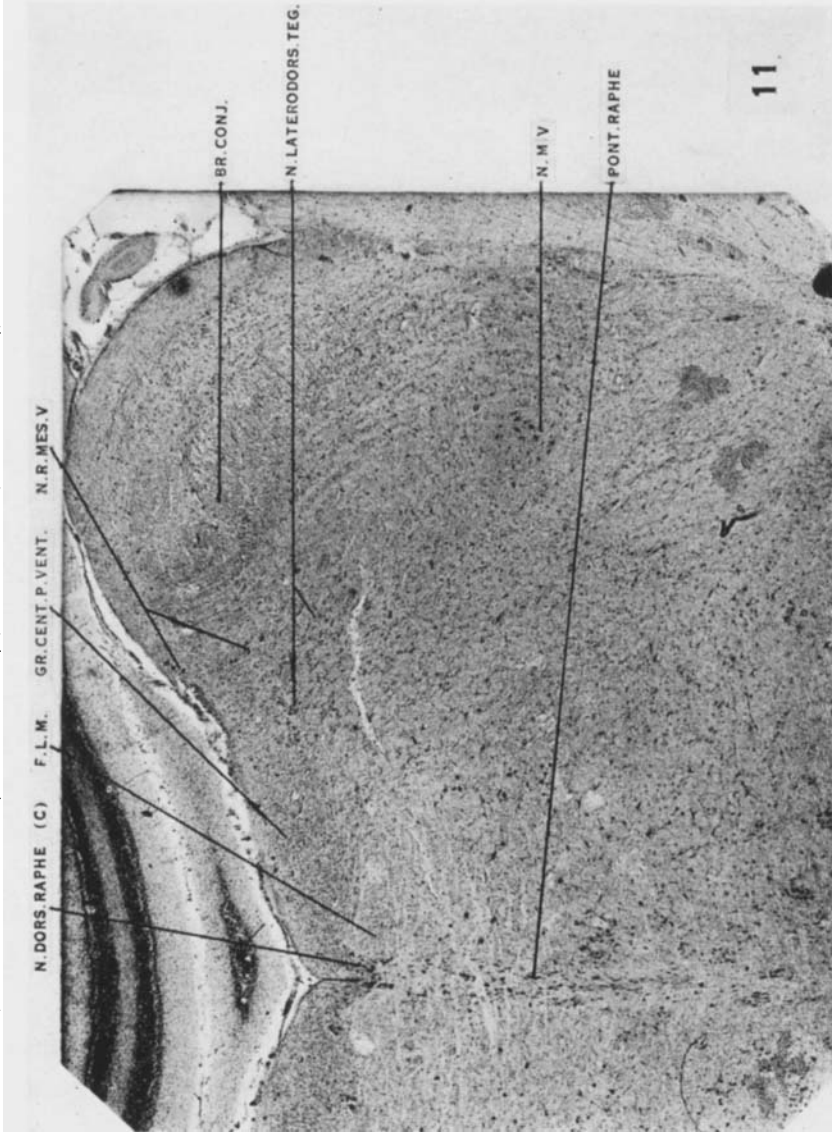


9



10

PLATE 7



11

PLATE 8

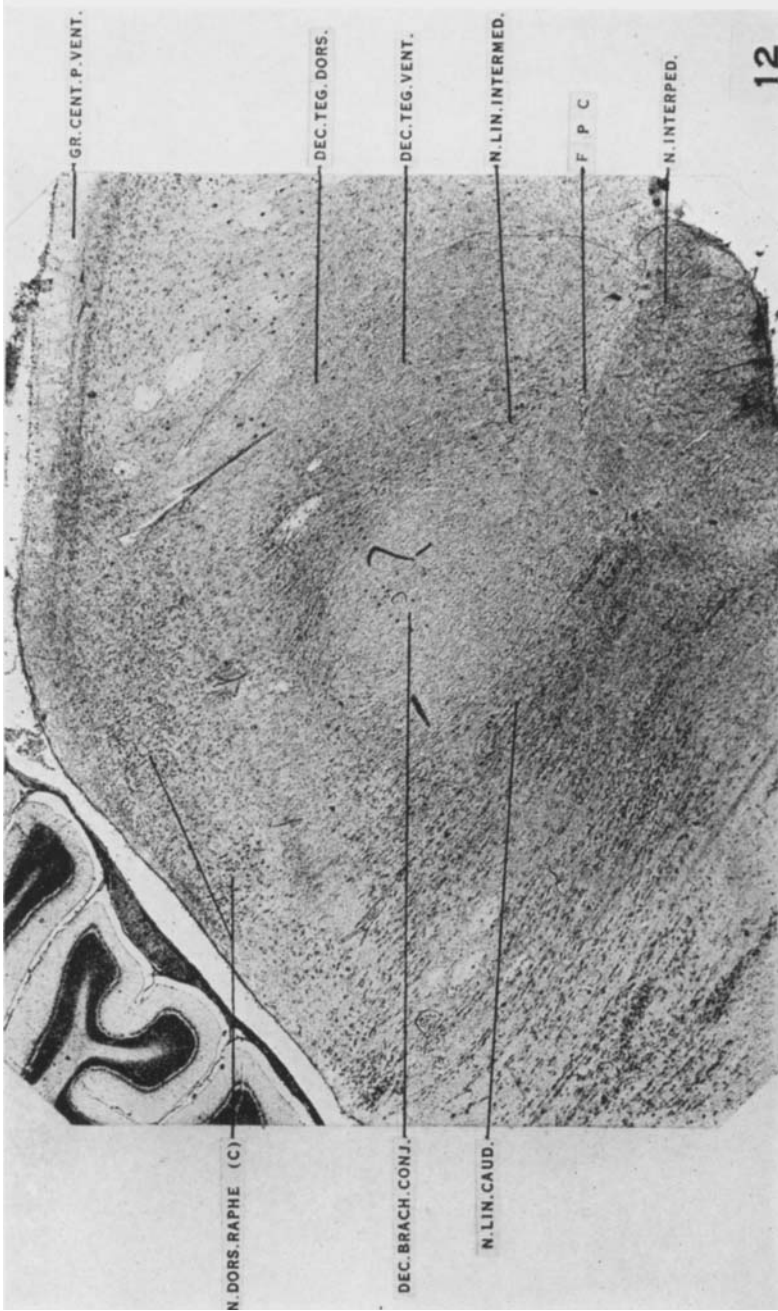


PLATE 9

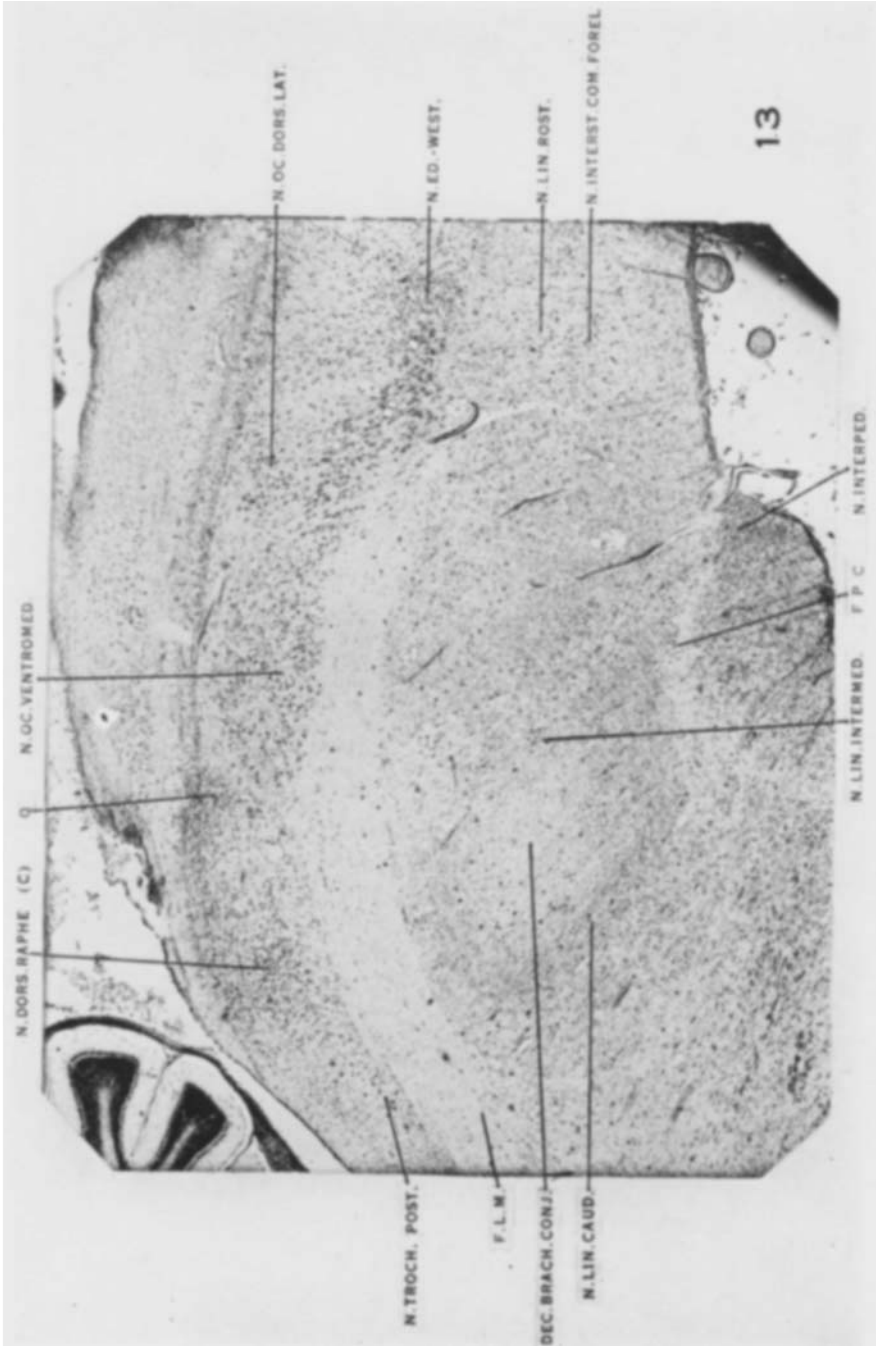


PLATE 10

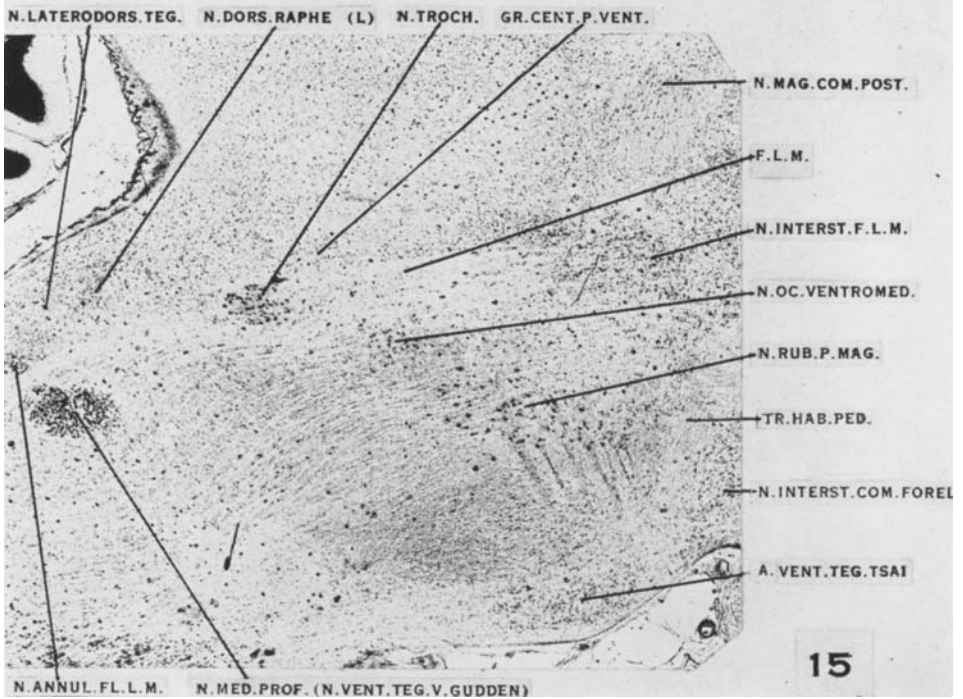
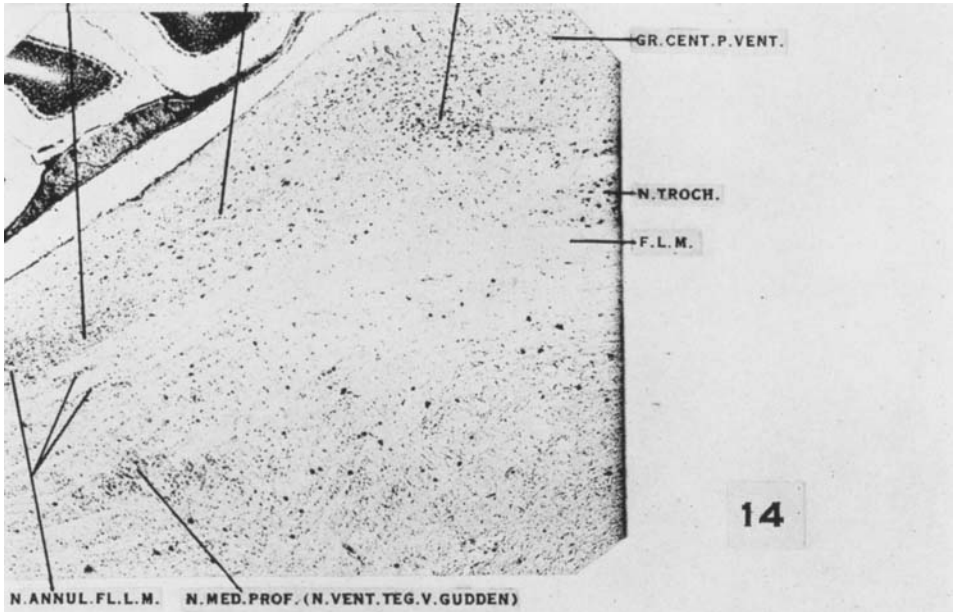




PLATE 11

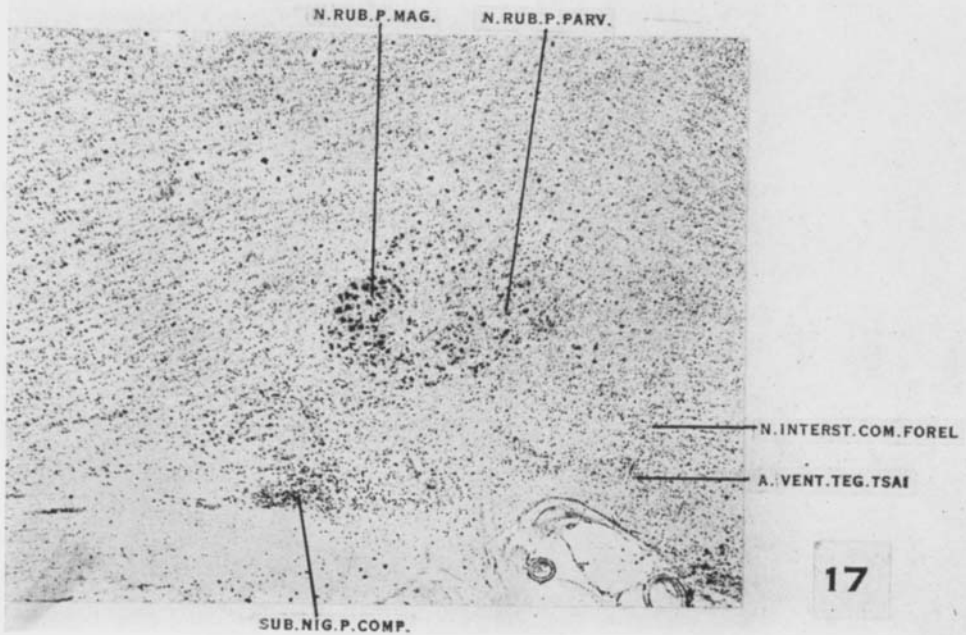
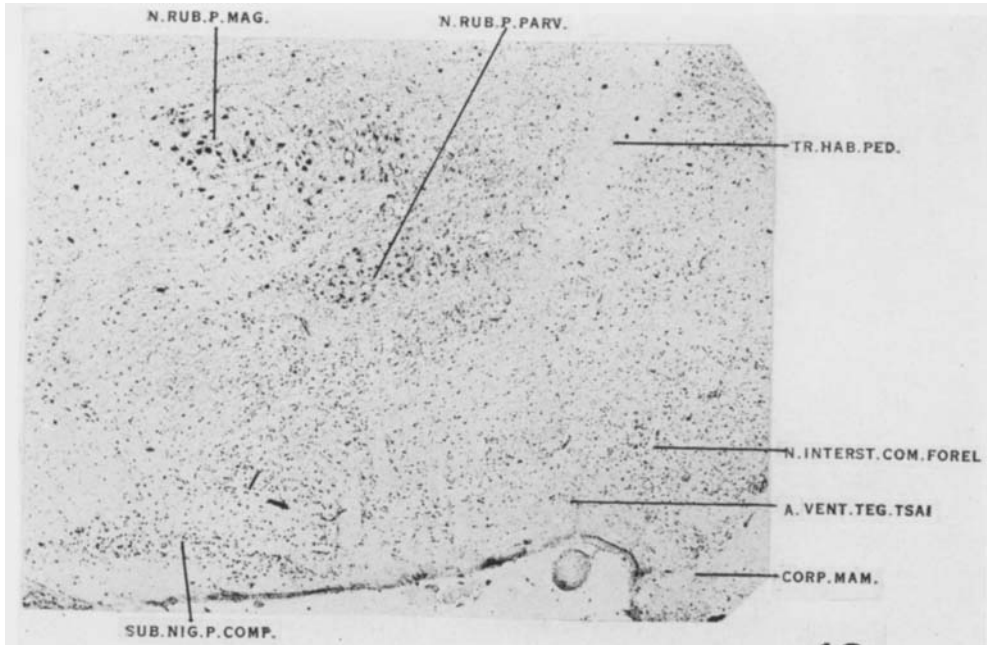




PLATE 12

