

# THE MAMMALIAN MIDBRAIN AND ISTHMUS REGIONS

## PART II

### THE FIBER CONNECTIONS

#### A. THE RELATIONS OF THE TEGMENTUM OF THE MIDBRAIN WITH THE BASAL GANGLIA IN *MACACA MULATTA*

RUSSELL T. WOODBURN, ELIZABETH CAROLINE CROSBY AND  
ROLLO E. McCOTTER

*The Laboratory of Comparative Neurology, Department of Anatomy,  
University of Michigan,<sup>1</sup> Ann Arbor*

SEVENTEEN FIGURES

### INTRODUCTION

The study of the nuclear pattern of the mammalian midbrain and isthmus regions (Huber et al.) reported in 1943 is being followed by an investigation of the fiber connections of this area based on both normal and experimental material. The present paper, the first of this series of studies on the connections, reports on the interrelations existing between the tegmentum of the midbrain and the basal ganglia of the hemispheres. Since many of the descending paths from the basal ganglia undergo synapse in the subthalamus and the tegmental region of the midbrain, subthalamo-tegmental and certain descending paths from the tegmentum to lower centers are also discussed. The material used for this consideration of fiber connections consists of transversely and sagittally cut serial sections of the brain of *Macaca mulatta* stained by the Weigert technique, and supplemented by some Marchi preparations.

<sup>1</sup> The authors wish to take this opportunity of thanking the Horace H. Rackham School of Graduate Studies of the University of Michigan for the generous grants which have made possible the preparation of material used in this paper and available for other midbrain studies.

Since the time of Forel (1877) investigators have been placing lesions in the basal ganglia or in regions through which their discharge paths run. These lesions have sometimes involved only parts of the basal ganglia and at other times have included fiber tracts and areas not concerned with the discharge from this region. As a result the connections most strongly advocated by one group of observers have been denied by others and the fiber interrelations of the basal ganglia are poorly understood in spite of the multiplicity of papers that have appeared on the subject. It has seemed, then, desirable to the present authors to make a fresh start and to obtain as a foundation for the understanding of the reported experimental results a thorough knowledge of the normal morphological relations of the nuclear masses and the fiber paths involved. Examination of the material available for study showed clearly that sections cut in the sagittal plane are particularly favorable for this purpose.

#### DESCRIPTION OF MATERIAL

In order to confine the discussion to the problem in hand no consideration is given in this report to the cortical connections of the basal ganglia which have received much attention from various recent observers, such as Kodama ('26), Dusser de Barenne, Garol and McCulloch ('42), Mettler ('42), Kennard and Fulton ('42), Garol and McCulloch ('44) and others. Likewise, the internuclear connections, which have been discussed by most workers on the basal ganglia (for example, Wilson, '14, and Kodama, '29) will not be described.

#### *H<sub>2</sub> bundle of Forel<sup>2</sup>*

The H<sub>2</sub> bundle (fasciculus lenticularis or dorsal division of ansa lenticularis) arises in the dorsomedial portion of

<sup>2</sup>The term H<sub>2</sub> bundle of Forel as used in this paper includes more than the original fiber tract designated by Forel. He traced it from the field of Forel above the subthalamic nucleus and through the internal capsule into the hemisphere. Fascicles were followed into the hypothalamus which correspond to the modern pallido-hypothalamic tract. He apparently considered the H<sub>2</sub> bundle to be continuous with ansa lenticularis and termed the whole fiber complex ansa lenticularis after they merged.

globus pallidus from fibers which have accumulated (figs. 8 and 9) in the internal medullary lamina. These bundles are supplemented from each portion of globus pallidus. The accumulated fascicles turn directly medialward, interdigitating with the bundles of the internal capsule, and so reach the diencephalon dorsal to nucleus subthalamicus. They proceed medialward to the inner border of zona incerta (fig. 13) giving off fascicles in course (see also Kodama, '29) and so come into relation with the nucleus of the field of Forel (Wilson, '14; Foix and Nicolesco, '25; Morgan, '27; Papez, '42). In this position, a distinct although a quite small bundle of fibers (fig. 1) swings ventromedialward, medial to nucleus subthalamus, to enter the hypothalamus, where it terminates in the ventromedial hypothalamic nucleus. These fascicles constitute a pallido-hypothalamic tract (Jakob, '23; Morgan, '27; Kodama, '29; Ranson and Ranson, '42; Papez, '42; Mettler, '45). In the field of Forel many of the fibers terminate in relation with secondary neurons, but the authors believe that fascicles (figs. 2 and 3) also pass through this area without synapse. Both primary and secondary fibers continue caudalward until near the rostral border of the mesencephalon (the prerubral field of Papez, '42) where the uppermost fascicles (figs. 1 and 2) swing slightly dorsalward to end in relationship with the interstitial nucleus of the medial longitudinal fasciculus and the nucleus of Darkschewitsch as Vogt and Vogt ('19), Jakob ('23), Foix and Nicolesco ('25) and Morgan ('27) have found. The smaller ventral portion of this bundle terminates in part immediately dorsal to the red nucleus among the scattered cells of pars dorsalis of nucleus mesencephalicus profundus (figs. 1, 2 and 3). The remaining fibers of this most ventral portion of  $H_2$  ( $H_2V$ , figs. 1 and 4) enter the capsule of the red nucleus (fig. 1) where they occupy a dorsomedial position. Through the rostral end of the red nucleus, this portion of the bundle does not vary much in size, but gradually disappears, in relation to the magnocellular portion of the red nucleus. Fascicles of the  $H_2V$  bundle also reach the more dorsomedial and rostral portion of nucleus

mesencephalicus profundus pars lateralis (fig. 4), especially those fibers which sweep over or past the red nucleus. For the connections with the interstitial nucleus and the nucleus of Darkschewitsch, Kodama's ('29) material provided no evidence.

Various observers have described connections from the basal ganglia to the dorsal thalamus. Such fibers have been seen by C. Vogt ('09), Ranson and Ranson ('42), Kodama ('29) and many others. They are also clearly apparent in one of the experimental series studied, but are not illustrated here since the previous workers have shown them adequately. From globus pallidus they swing through the internal capsule and medialward, above the main bundle of the lenticular fasciculus and the dorsally adjacent pallido-incertal tract, to a position near the ventricular wall of the diencephalon. Here they make a sharp U-shaped turn, as C. Vogt ('09) and Ranson and Ranson ('42) have described, in order to enter the dorsal thalamus where they distribute to the lateral part of the ventral nucleus. This bundle may be considered as a dorsal part of the  $H_2$  bundle or as the rostral portion of the thalamic fasciculus. The degeneration material studied indicates that it is efferent with respect to the basal ganglia.

#### *Ansa lenticularis*

As far as the available material indicates, ansa lenticularis, or the so-called ventral division of ansa lenticularis of various terminologies, arises (figs. 8, 9, 11, 12 and 13) from putamen, from both segments of globus pallidus and from substantia innominata with which it is intermingled in its course beneath the lenticular nucleus. It collects at the ventromedial angle of the inner segment of globus pallidus. Dorsomedially it lies adjacent to the  $H_2$  bundle at the level at which a part of this latter bundle is infiltrating the internal capsule. Thus, in this position the two systems form a single arciform fiber mass (figs. 8 and 9), which gradually passes into the diencephalon with the  $H_2$  portion intermingled with the internal capsule and ansa lenticularis passing beneath it. Throughout,

the two portions maintain continuity with each other. In the diencephalon the two parts of the complex form a continuous mass in the shape of a boomerang (fig. 7) with the dorsal horizontal limb representing the  $H_2$  bundle and the ventral vertical limb, ansa lenticularis. This characteristic form can be seen only in sagittal sections. Ansa lenticularis turns directly caudalward in a position just ventral to the  $H_2$  bundle and in relation to the field of Forel (figs. 4, 12 and 13) where some of its fibers synapse (Jakob, '23; Papez, '42; Ranson and Ranson, '42). Here secondary fibers join the ansa. Fascicles of ansa lenticularis (*TR. HYPOTHAL.*, figs. 2 and 3) can be traced to the periventricular hypothalamic gray (Jakob, '23, and others) and, near the caudal end of the diencephalon (figs. 4, 14 and 15), come into relation with the red nucleus. Through superior collicular levels of the mesencephalon the ansa proceeds caudally along the capsule of the red nucleus (figs. 2, 14 and 15). Behind the red nucleus it continues through the tegmental gray lateral to the decussation of brachium conjunctivum (see Kodama, '29) to its termination in the caudal part of nucleus mesencephalicus profundus pars lateralis (figs. 2 and 3). The most ventral fibers of ansa lenticularis break up in nucleus mesencephalicus profundus pars ventralis (figs. 4, 5 and 6) which lies ventral to the red nucleus.

Kodama ('29) found that lesions made by sectioning just in front of the decussation of brachium conjunctivum resulted in bilateral secondary degeneration of globus pallidus on the two sides. The farther forward in the tegmentum the cut was made, the greater the degeneration. The material studied for this paper shows no evidence of the crossing of ansa lenticularis or the  $H_2$  bundle.

#### *Fasciculus subthalamicus*

The subthalamic fasciculus (Wilson, '14; Vogt and Vogt, '19; Jakob, '23; Foix and Nicolesco, '25; Morgan, '27; Kodama, '29; Papez, '42; Ranson and Ranson, '42) arises in the external and the internal segments of globus pallidus

and in small part, from the putamen. The fibers making up this fasciculus appear to be slightly less heavily medullated than those of the other divisions and much less numerous. They accumulate in the inner segment of globus pallidus in a position intermediate between the  $H_2$  bundle and ansa lenticularis (figs. 8 and 9) before these divisions have combined. They interdigitate with the internal capsule ventral to the crossing of the  $H_2$  bundle (fig. 9) and most of them enter immediately the lateral pole of nucleus subthalamicus (figs. 8 and 14) where they terminate. Some of them encapsulate this nucleus dorsally and ventrally. A very small fascicle associated with fasciculus subthalamicus does not enter nucleus subthalamicus but swings caudalward along the ventrolateral border of the nucleus to reach the lateral part of substantia nigra (*TR.PALL.NIG.*, fig. 14, and see also Kodama, '29). Fine fascicles running between the subthalamic nucleus and substantia nigra join this small pallido-nigral tract ventrally to enter substantia nigra. Such a connection has been described by Jakob ('23), Kodama ('29) and Rioch ('29). The direction of conduction is uncertain. For purposes of labelling it has been termed tractus subthalamo-nigralis (*TR.SUBTHAL.NIG.*, figs. 14 and 15).

#### *Subthalamo-tegmental tract*

The subthalamo-tegmental tract (Kodama, '29; Papez, '42, '46) arises from the whole rostrocaudal extent of the subthalamic nucleus. The fascicles accumulate into a rather discrete bundle at the caudal pole of this nucleus (fig. 9) and then proceed almost directly caudalward. Through the mesencephalon they form a slight ventral loop. Lateral to the red nucleus they infiltrate the capsular fibers of this nucleus and, behind it, terminate in the lateral part of nucleus mesencephalicus profundus (fig. 8) which lies in a plane caudal to the red nucleus and rostral to the decussation of brachium conjunctivum. A few of the fibers which can be traced through this peduncle, as it extends ventrally toward its crossing in the midbrain,

reach nucleus mesencephalicus profundus pars lateralis at levels where the nucleus intermingles with the marginal nucleus of brachium conjunctivum.

*Rubro-spinal and tegmento-spinal system*

The rubro-spinal tract, as is generally recognized, has origin in nucleus ruber pars magnocellularis. It appears as a discrete bundle on the ventromedial margin of this nucleus. After undergoing an immediate crossing in the ventral tegmental decussation (fig. 15), the rubro-spinal tract runs lateralward and slightly caudalward for a short distance under the caudal end of nucleus ruber (figs. 7, 8 and 16), then caudolateralward in relation to the ventral aspect of the decussation of brachium conjunctivum (fig. 17), and finally more nearly lateralward until the surface of the brain is approached. Here it lies immediately ventral to the lateral border of brachium conjunctivum as this comes down toward its crossing. The rubro-spinal tract then runs directly caudalward through the brainstem to the spinal cord. In its course it is joined, on its dorsal border, by fascicles which arise from those portions of nucleus mesencephalicus profundus pars lateralis which lie in front of brachium conjunctivum and caudal to the plane of the red nucleus (*TR.TEG.SP.*, figs. 7 and 8). These fascicles infiltrate the peduncle in their course. Fibers from the most caudal portion of nucleus mesencephalicus profundus pars lateralis which lies behind the decussation of brachium conjunctivum also join this descending system on its dorsal side (*TR.TEG.SP.CAUD.*, fig. 17). The generally accepted rubro-spinal tract is, then, a combined rubro-spinal and tegmento-spinal system. Various other descending connections of the tegmentum have been identified but are reserved for a later discussion.

*Pallido-incerto-tegmento-olivary system*  
(*thalamo-olivary tract*)

From globus pallidus, fibers adjacent dorsally to the H<sub>2</sub> bundle pass with it through the internal capsule to reach

zona incerta. They run medialward through zona incerta, stem fibers and collaterals terminating in that area. In the medial region of zona incerta, dorsal to the  $H_2$  bundle (fig. 14), some of these pallido-incertal fibers synapse and others continue caudalward, supplemented largely from fibers arising in zona incerta. Then the pallido-incerto-tegmento-olivary tract (figs. 4, 7, 14 and 15) rapidly becomes a discrete bundle of rather coarsely medullated fibers which arches gently dorso-caudalward, occupying a position close to the periventricular gray (fig. 15). It continues in this position to planes behind the red nucleus (figs. 16 and 17) where the tract, which represents the tegmento-olivary tract of Papez ('42), is joined ventrally by rubro-olivary fibers (fig. 4; see the rubro-olivary tract of Papez, '42). The combined bundle swings gently caudoventralward, infiltrating brachium conjunctivum where this latter system swings down toward its decussation. The pallido-incerto-tegmento-olivary tract passes through the pons in a position dorsal to the medial lemniscus and then enters the rostral pole and the lateral side of the inferior olivary nucleus at upper medullar levels. This system corresponds in part to the central tegmental tract described by Foix and Nicolesco ('25) and in part to the annulo-olivary tract of Mettler ('44). The system has also been seen by Ogawa ('39).

Part of the component of ansa lenticularis which reaches nucleus mesencephalicus profundus pars ventralis passes through this nuclear gray without synapse, but is augmented by fibers which arise there. The fascicles accumulate into a small but distinct bundle (*Z*, fig. 4), which proceeds directly caudalward to join the pallido-incerto-tegmento-olivary tract at lower pons levels.

#### *Nigro-pallidal connections*

The nigropallidal fibers accumulate throughout the extent of the reticular and the compact portions of substantia nigra into a bundle of considerable size. This bundle extends forward from the rostral tip of substantia nigra (figs. 8 and 14) beneath nucleus subthalamicus. These large fascicles pass



through the internal capsule constituting the "comb-system" of various authors, and enter the medial tip of the internal segment of globus pallidus to distribute to its internal and external portions and possibly to putamen. The experimental results of various workers (Ferraro, '28; Kimmel, '42; Ranson and Ranson, '42; Rosegay, '44 and Fox and Schmidt, '44) indicate that this bundle is afferent with respect to the basal ganglia.

#### SUMMARY

The basal ganglia and the hypothalamic regions are connected with each other by both ansa lenticularis and the H<sub>2</sub> bundle. Likewise, the dorsal thalamus is connected with the basal ganglia by a path running with the H<sub>2</sub> bundle and by the inferior thalamic peduncle which emerges ventrally from the basal ganglia and then arches dorsally to enter the dorsal thalamus.

The foregoing account indicates, however, that the tegmentum of the midbrain is a very important internode in the discharge of the basal ganglia to the brainstem and spinal cord. To a considerable extent the pertinent pathways are either direct connections from the centers in the hemisphere to the midbrain tegmentum, or indirect connections after synapse in the nucleus of the field of Forel. Examples of such connections are the H<sub>2</sub> bundle and ansa lenticularis. The H<sub>2</sub> bundle distributes chiefly to the interstitial nucleus of the medial longitudinal fasciculus, the nucleus of Darkschewitsch, the red nucleus and the tegmentum dorsal and lateral to the rostral end of the red nucleus (nucleus mesencephalicus profundus, pars dorsalis and pars lateralis). Ansa lenticularis passes to nucleus mesencephalicus profundus pars ventralis, to the more caudal part of nucleus mesencephalicus profundus pars lateralis and to nucleus mesencephalicus profundus pars lateralis caudalis. Thus, the large-celled tegmental elements of the midbrain, whether encapsulated as is the red nucleus, or present as scattered groups, are under the direct influence of and a part of the discharge pattern of the basal ganglia.

In addition to these two direct systems from the basal ganglia there is an indirect path of considerable proportions by way of the subthalamic fasciculus to nucleus subthalamicus which relays the impulses to the tegmentum of the midbrain and pons through the subthalamo-tegmental bundle. The fact that the discharge of the basal ganglia to lower centers may be largely interrupted above the midbrain level is documented by the demonstration in other contributions (Papez, '42) and in this paper of a large pallido-incerto-tegmento-olivary system.

The caudal discharge to the tegmentum is by way of a series of tegmento-bulbar and spinal paths of which the rubro-spinal tract is only a specialized portion. It is clear that the generally recognized rubro-spinal system is supplemented by numerous tegmento-bulbar and spinal bundles arising from the various parts of nucleus mesencephalicus profundus from levels rostral to brachium conjunctivum to levels caudal to it. A direct discharge to the efferent centers of the brainstem by way of the specialized interstitial nucleus of the medial longitudinal fasciculus and the nucleus of Darkschewitsch is provided through the medial longitudinal fasciculus. It should be remembered in this connection that all of these centers, with the possible exception of the interstitial nucleus and the nucleus of Darkschewitsch, are in the direct line of discharge from the cerebellum by way of brachium conjunctivum and that they are under cortical regulation, in part at least, through cortico-rubral and cortico-tegmental paths.

The fiber connections of the tegmentum of the midbrain, as far as they have been studied, suggest strongly that this region is a very important efferent correlation center in which there is an interplay of cerebellar and striatal functioning with a conditioning cortical component modifying the resulting activity.

#### LITERATURE CITED

- DUSSER DE BARENNE, J. G., H. W. GAROL AND W. S. McCULLOCH 1942 Physiologiéal neuronography of the cortico-striatal connections. Res. Pub., Assoc. Res. Nerv. Ment. Dis., vol. 21, pp. 246-266.

- FERRARO, A. 1928 The connections of the pars suboculomotoria of the substantia nigra. *Arch. Neurol. Psychiat.*, vol. 19, pp. 177-180.
- FOIX, C., AND J. NICOLESCO 1925 *Anatomie cerebrale Noyaux gris centraux et région mésencéphalo-sous-optique*. Masson et Cie, Paris.
- FOREL, A. 1877 Untersuchungen über die Haubenregion und ihre oberen Verknüpfungen im Gehirne des Menschen und einiger Säugethiere, mit Beiträgen zu den Methoden der Gehirnuntersuchung. *Arch. f. Phychiat. u. Nervenkr.*, vol. 7, pp. 393-495.
- FOX, C., AND J. T. SCHMITZ 1944 The substantia nigra and the entopeduncular nucleus in the cat. *J. Comp. Neur.*, vol. 80, pp. 323-334.
- GAROL, H. W., AND W. S. McCULLOCH 1944 Physiological neuronography of some cortico-subcortical connections in the chimpanzee. *J. Neurophysiol.*, vol. 7, pp. 199-204.
- HUBER, G. C., E. C. CROSBY, R. T. WOODBURN, L. A. GILLILAN, J. O. BROWN AND B. TAMTHAI 1943 The mammalian midbrain and isthmus regions. I. The nuclear pattern. *J. Comp. Neur.*, vol. 78, pp. 129-534.
- JAKOB, A. 1923 Die extrapyramidalen Erkrankungen mit besonderer Berücksichtigung der pathologischen Anatomie und Histologie und der Pathophysiologie der Bewegungsstörungen. *Gesamtgebiete d. Neurol. u. Psychiat.* no. 37, pp. 1-416.
- KENNARD, M., AND J. L. FULTON 1942 Corticostriatal interrelations in monkey and chimpanzee. *Res. Pub., Assoc. Res. Nerv. Ment. Dis.*, vol. 21, pp. 228-266.
- KIMMEL, D. 1942 Nigrostriatal fibers in the cat. *Anat. Rec.*, vol. 82, p. 425.
- KODAMA, S. 1926 2. Über die sogenannten Basalganglien. (Morphogenetische und pathologisch-anatomische Untersuchungen.) II. Pathologisch-anatomische Untersuchungen mit Bezug auf die sogenannten Basalganglien und ihre Adnexe. *Schweiz. Arch. f. Neurol u. Psychiat.*, vol. 20, pp. 209-261.
- 1929 2. Über die sogenannten Basalganglien. (Morphogenetische und pathologisch-anatomische Untersuchungen.) II. Pathologisch-anatomische Untersuchungen mit Bezug auf die sogenannten Basalganglien und ihre Adnexe. B. Über die Faserverbindungen zwischen den Basalganglien und ihren Adnexen, sowie den übrigen subkortikalen Kerngebieten beim Menschen, nebst einigen experimentellen Mitteilungen. *Ibid.*, vol. 23, pp. 38-100, pp. 179-265.
- METTLER, F. A. 1942 Relation between pyramidal and extrapyramidal function. *Res. Pub., Assoc. Res. Nerv. Ment. Dis.*, vol. 21, pp. 150-227.
- 1945 Fiber connections of the corpus striatum of the monkey and baboon. *J. Comp. Neur.*, vol. 82, pp. 169-204.
- MORGAN, L. O. 1927 The corpus striatum. A study of secondary degeneration following lesions in man and symptoms and acute degenerations following experimental lesions in cats. *Arch. Neurol. Psychiat.*, vol. 18, pp. 495-549.
- OGAWA, T. 1939 The tractus tegmenti medialis and its connection with the inferior olive in the cat. *J. Comp. Neur.*, vol. 70, pp. 181-190.

- PAPEZ, J. W. 1942 A summary of fiber connections of the basal ganglia with each other and with other portions of the brain. Res. Pub., Assoc. Res. Nerv. Ment. Dis., vol. 21, pp. 21-68.
- 1946 Subthalamo-tegmental tract. Anat. Rec., vol. 94, p. 80.
- RANSON, S. W., AND S. W. RANSON, JR. 1942 Efferent fibers of the corpus striatum. Res. Pub., Assoc. Nerv. Ment. Dis., vol. 21, pp. 69-76.
- RIOCH, D. 1929 Studies on the diencephalon of Carnivora. II. Certain nuclear configurations and fiber connections of the subthalamus and midbrain of the dog and cat. J. Comp. Neur., vol. 49, pp. 121-153.
- ROSEGAY, H. 1944 An experimental investigation of the connections between the corpus striatum and substantia nigra in the cat. J. Comp. Neur., vol. 80, pp. 293-321.
- VOGT, C. 1909 La myéloarchitecture du thalamus du cœreopithèque. J. f. Psychol. u. Neurol., vol. 12, pp. 285-324.
- VOGT, C., AND O. VOGT 1919 Zur Kenntnis der pathologischen Veränderungen des Striatum und des Pallidum und zur Pathophysiologie der dabei auftretenden Krankheitserscheinungen. Sitzungb. d. Heidelberger Akad. d. Wissensch. Math.-naturwiss. Kl. Abteil. B. Biol. Wissensch. Abhandl. 14, pp. 3-56.
- WILSON, S. A. K. 1914 An experimental research into the anatomy and physiology of the corpus striatum. Brain, vol. 36, pp. 427-492.

## ABBREVIATIONS

ANSA LENT., ansa lenticularis	GL.PALEXT., globus pallidus, external part
BR.CONJ., brachium conjunctivum	GL.PALINT., globus pallidus, internal part
CAP.INT., internal capsule	H <sub>2</sub> , H <sub>2</sub> bundle
CAP.N.RUB., capsule of red nucleus	H <sub>2</sub> V., ventral part of H <sub>2</sub> bundle
CAUD., caudate nucleus	HAB., habenula
CEREBELL., cerebellum	HYPOTHAL., hypothalamus
CH.OP., optic chiasm	LEM.MED., medial lemniscus
COM.ANT., anterior commissure	L.MED.EXT., external medullary lamina
COM.POST., posterior commissure	L.MED.INT., internal medullary lamina
COL.INF., inferior colliculus	MAM., mammillary body
COL.SUP., superior colliculus	N.III, oculomotor nucleus
DEC.BR.CONJ., decussation of brachium conjunctivum	N.DARK., nucleus of Darkschewitsch
DEC.SUPRAOP., supraoptic decussation	N.GEN.LAT., lateral geniculate nucleus
DEC.TEG.DORS., dorsal tegmental decussation	N.GEN.MED., medial geniculate nucleus
F., fornix	N.INTERPED., interpeduncular nucleus
F.L.M., medial longitudinal fasciculus	N.INTERST.F.L.M., interstitial nucleus of the medial longitudinal fasciculus
F.SUBTHAL., subthalamic fasciculus	
F.THAL. (FOREL), thalamic fasciculus (Forel) or H <sub>1</sub>	
GL.PAL., globus pallidus	

N.MARG., marginal nucleus	TR.HYPOTHAL.TEG., hypothalamo- tegmental tract
N.MES.PROF.P.DORS., nucleus mesen- cephalicus profundus pars dorsalis	TR.MAM.PED., mammillo-peduncular tract
N.MES.PROF.P.LAT., nucleus mesen- cephalicus profundus pars lateralis	TR.MAM.TEG., mammillo-tegmental tract
N.MES.PROF.P.LAT.CAUD., nucleus mesencephalicus profundus pars lat- eralis caudalis	TR.MAM.THAL., mammillo-thalamic tract
N.MES.PROF.P.VENT., nucleus mesen- cephalicus profundus pars ventralis	TR.NIG.TECT., nigro-tectal tract
N.RUB., red nucleus	TR.OP., optic tract
N.SUBTHAL., subthalamic nucleus	TR.PALL.HYPOTH., pallido-hypothla- mic tract
NN.III, oculomotor nerve	TR.PALL.INC.OL., pallido-incerto-teg- mento-olivary tract
NN.IV, trochlear nerve	TR.PALL.NIG., pallido-nigral tract
NN.VII, facial nerve	TR.RUB.OL., rubro-olivary tract
OL.INF., inferior olivary nucleus	TR.RUB.SP., rubro-spinal tract
PED.CER., cerebral peduncle	TR.SUBTHAL.NIG., subthalamo-nig- ral tract
PED.COL.INF., peduncle of the infer- ior colliculus	TR.SUBTHAL.TEG., subthalamo-teg- mental tract
PED.THAL.INF., inferior thalamic peduncle	TR.TECT.NIG., tecto-nigral tract
PUT., putamen	TR.TEG.SP., tegmento-spinal tract
S.INOM., substantia innominata	TR.TEG.SP.CAUD., caudal component of tegmento-spinal tract
ST.MED., stria medullaris	Z., component of ansa lenticularis to nucleus mesencephalicus profundus pars ventralis
SUB.NIGRA, substantia nigra	Z., descending fascicles from nucleus mesencephalicus profundus pars ven- tralis joining pallido-incerto-teg- mento-olivary tract
THAL., thalamus	Z.INC., zona incerta
TR.CORT.HAB.LAT., lateral cortico- habenular tract	
TR.HAB.PED., habenulo-peduncular tract	
TR.HYPOTHAL., hypothalamic fibers of ansa lenticularis	

Figs. 1-9 inclusive. Photomicrographs prepared from a sagittally cut series of the brain of *Macaca mulatta*, the figures being arranged in sequence from medial to lateral. Pal-Weigert technique. Figures 1-7 at a magnification of 12, figures 8 and 9 at a magnification of 13.

Figs. 10-17 inclusive. Photomicrographs prepared from a transversely cut series of the brain of *Macaca mulatta*, the figures arranged in rostrocaudal sequence. Weil technique.  $\times 10$ .

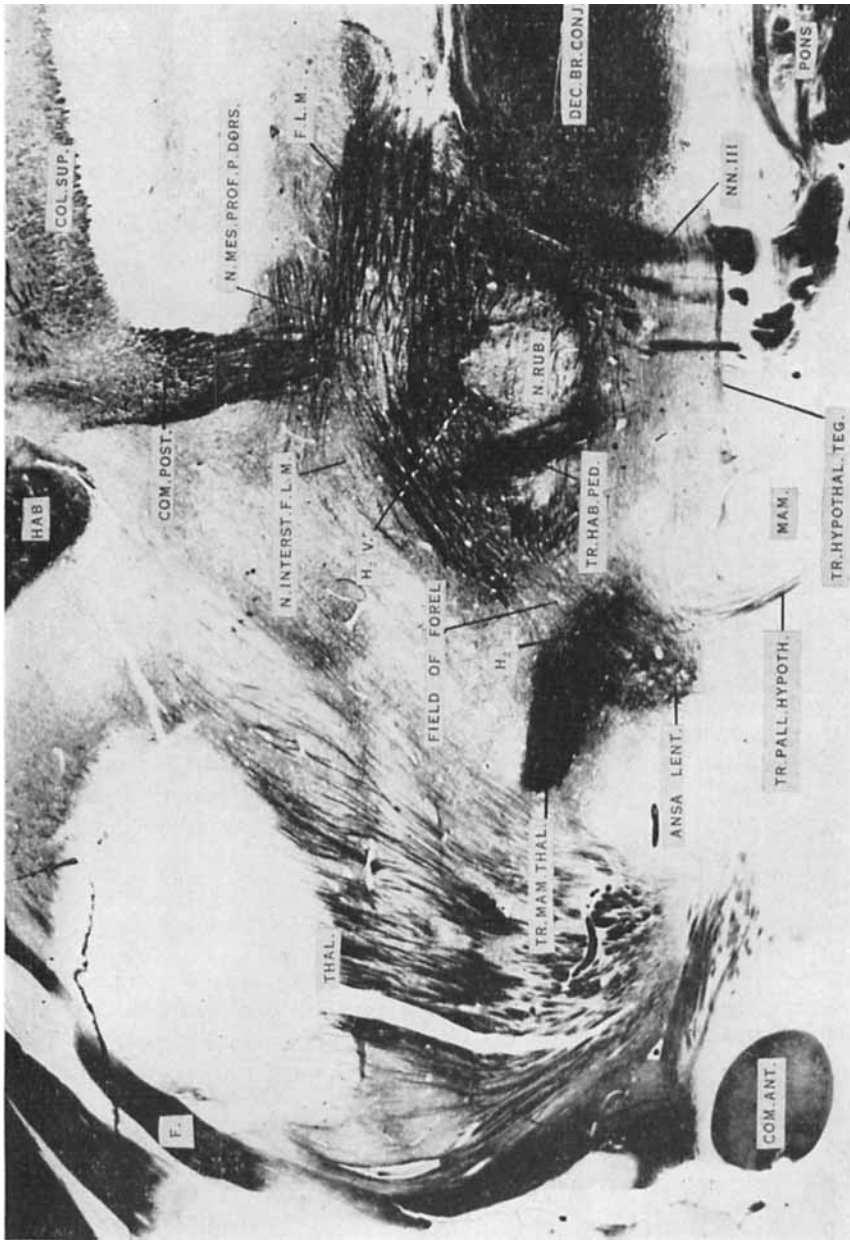

Figure 1




Figure 2

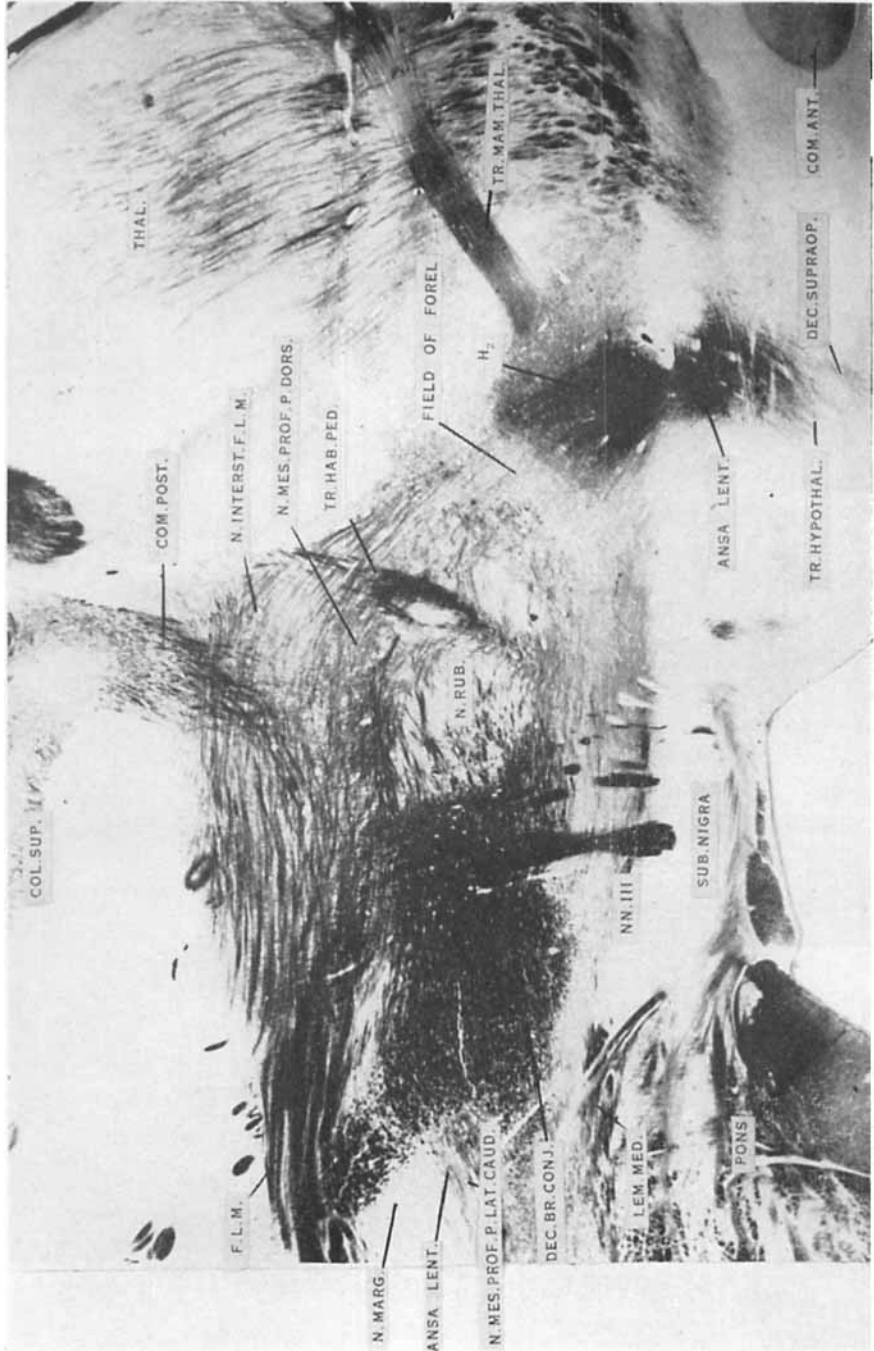


Figure 3





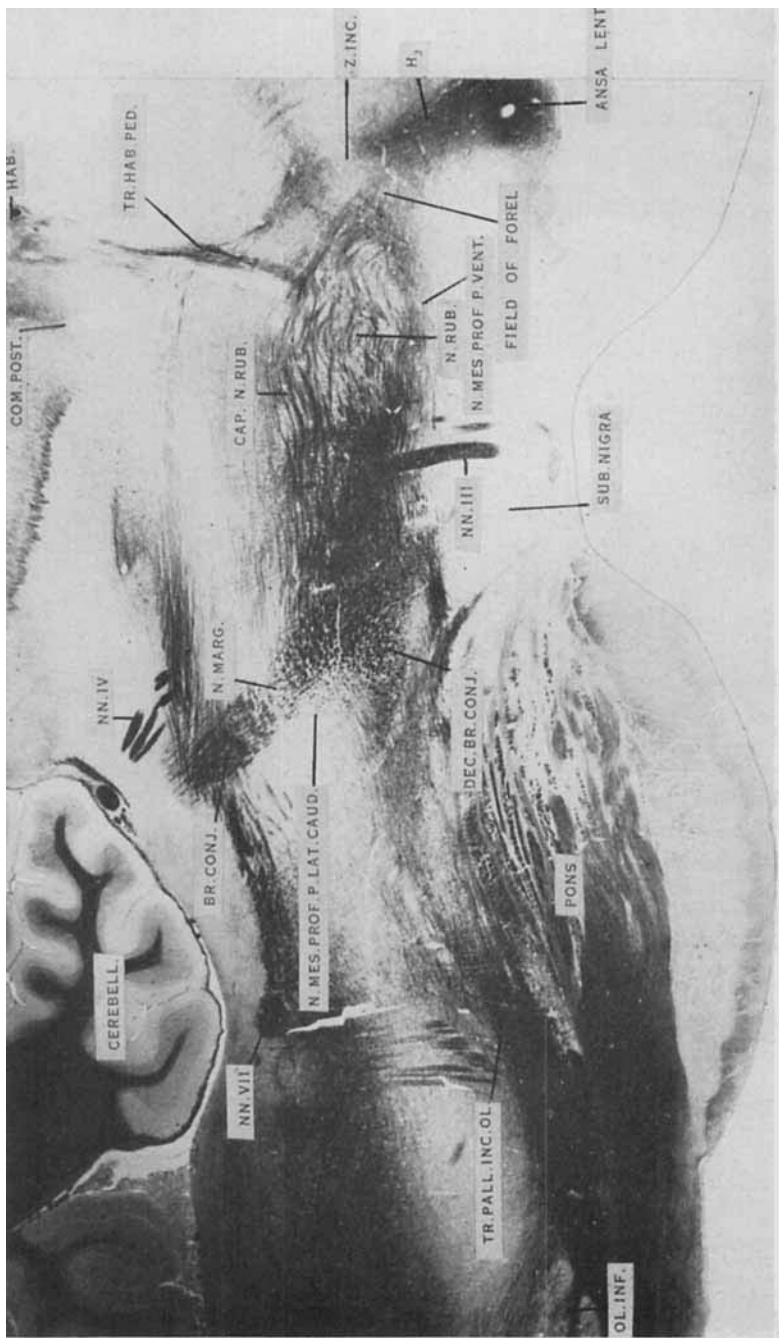


Figure 5

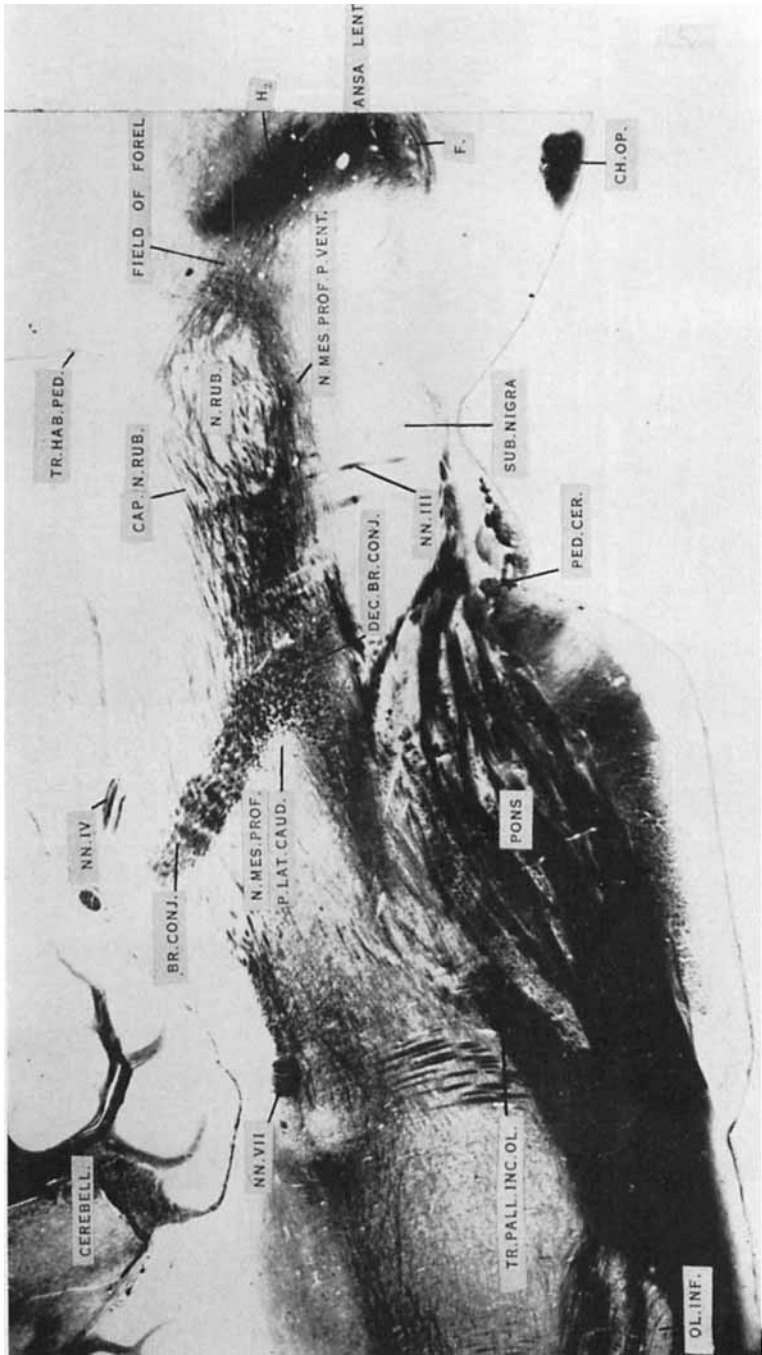


Figure 6

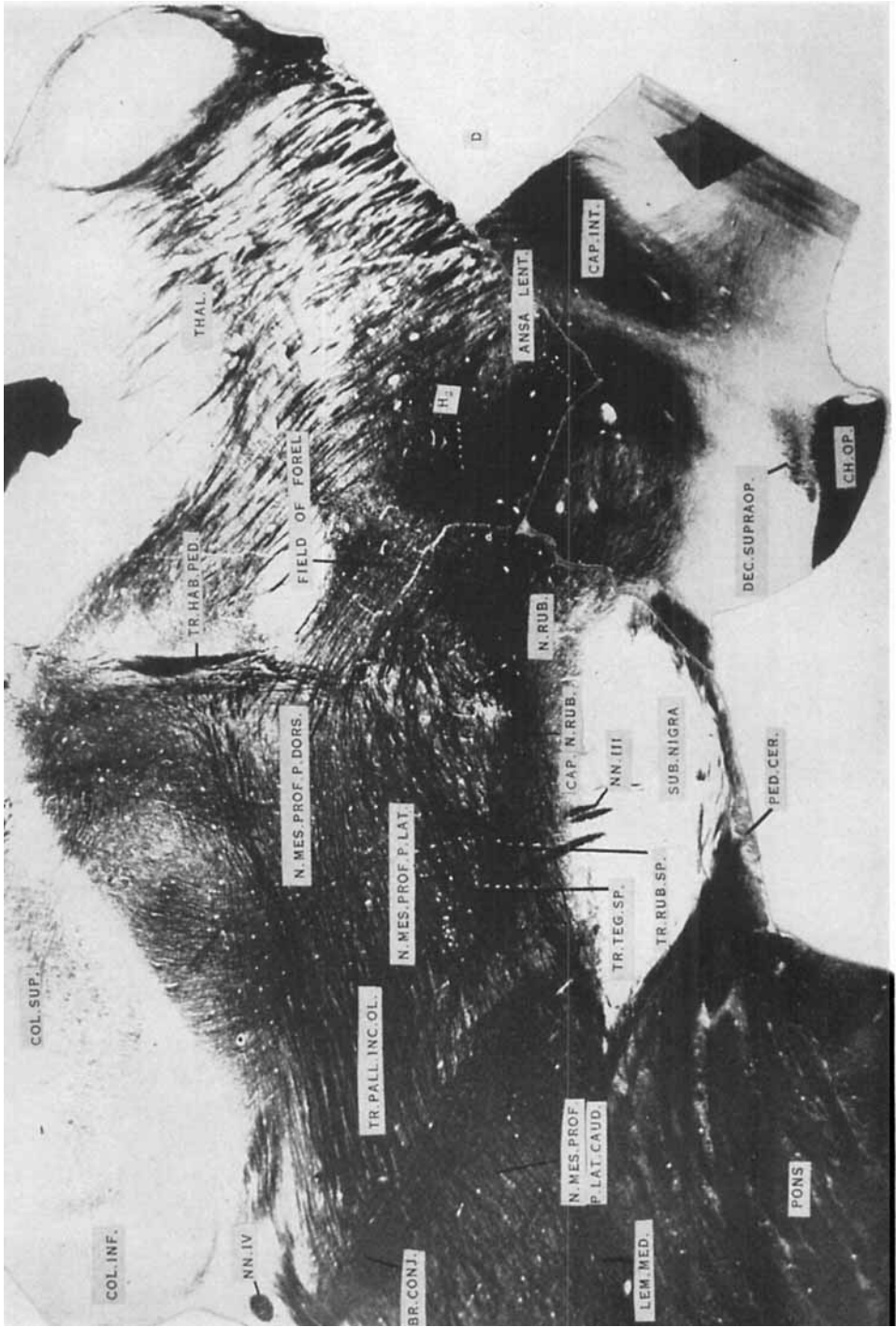


Figure 7



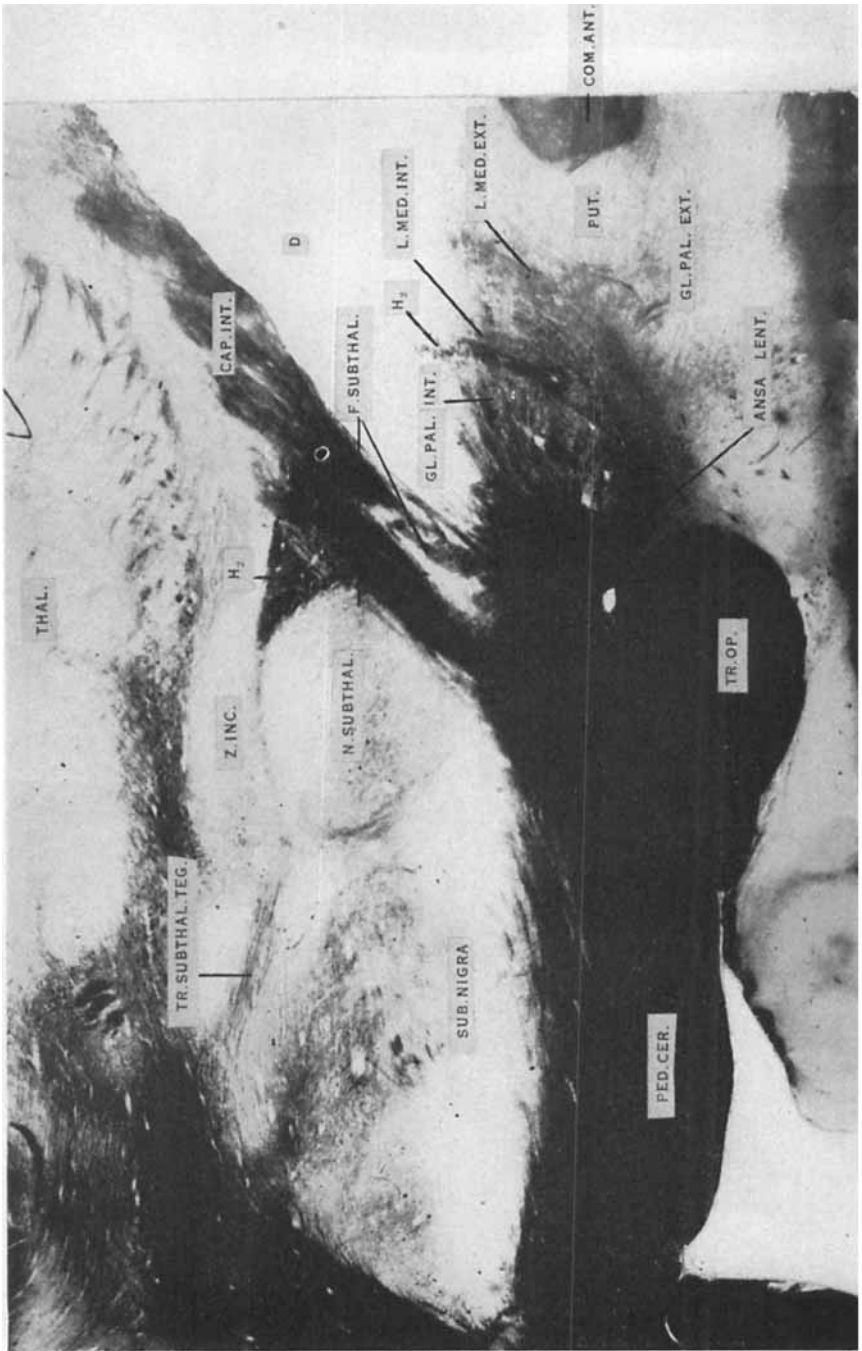
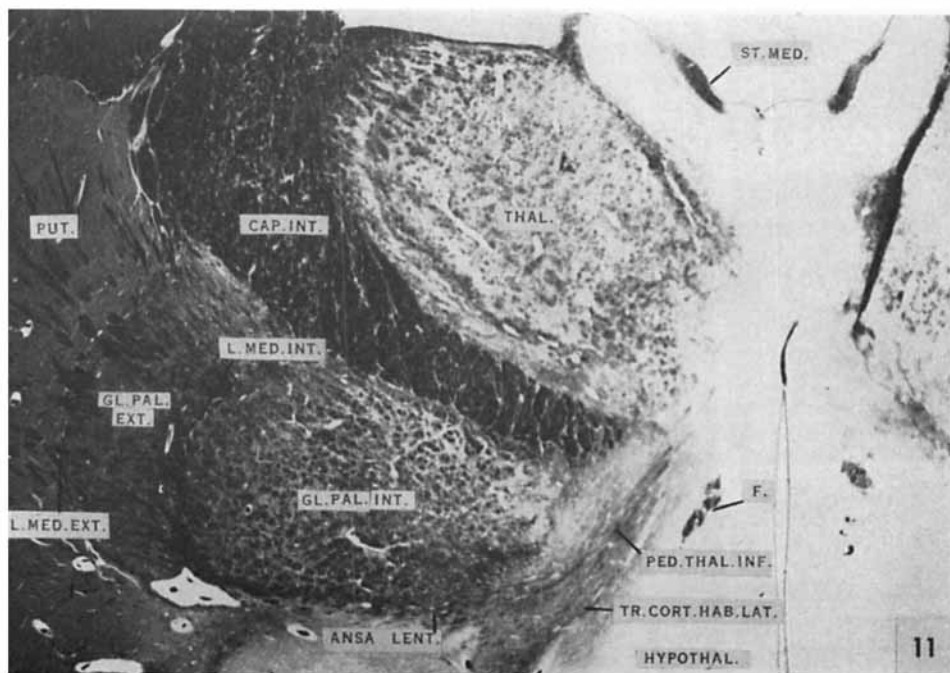
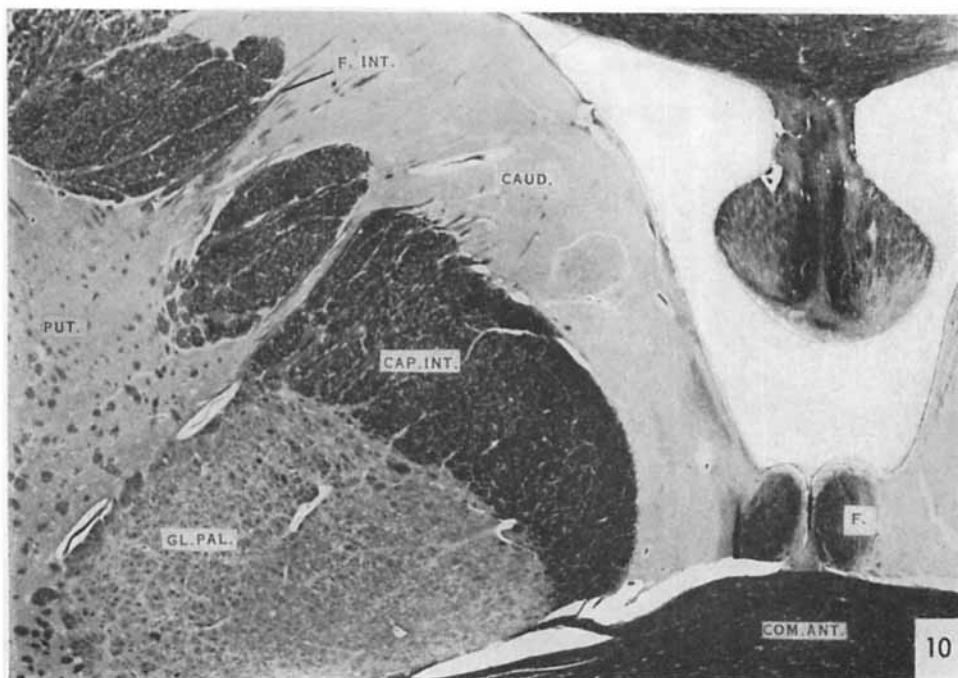
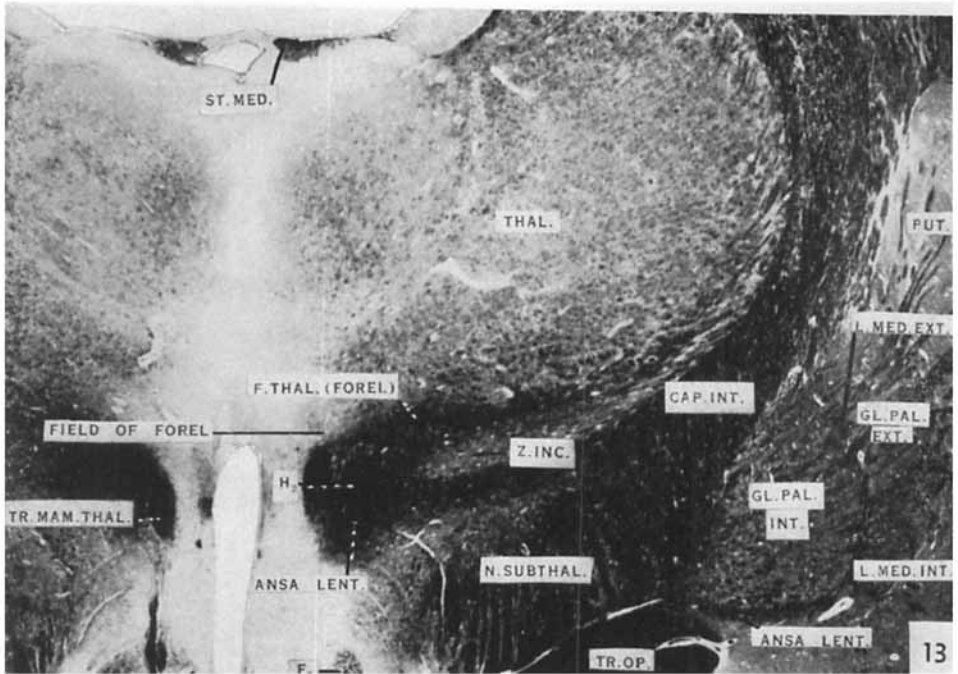
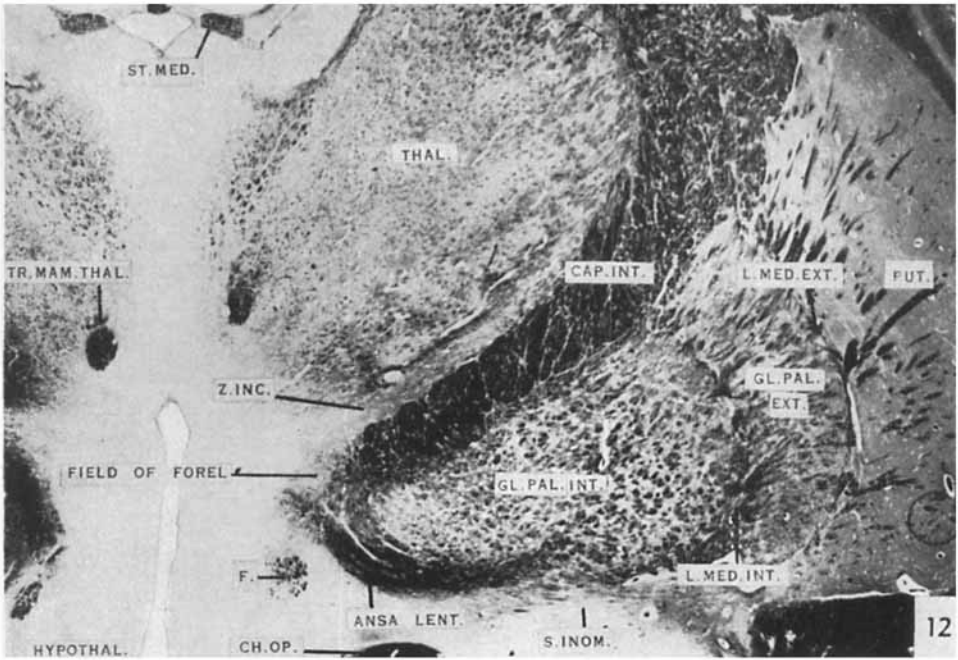


Figure 9

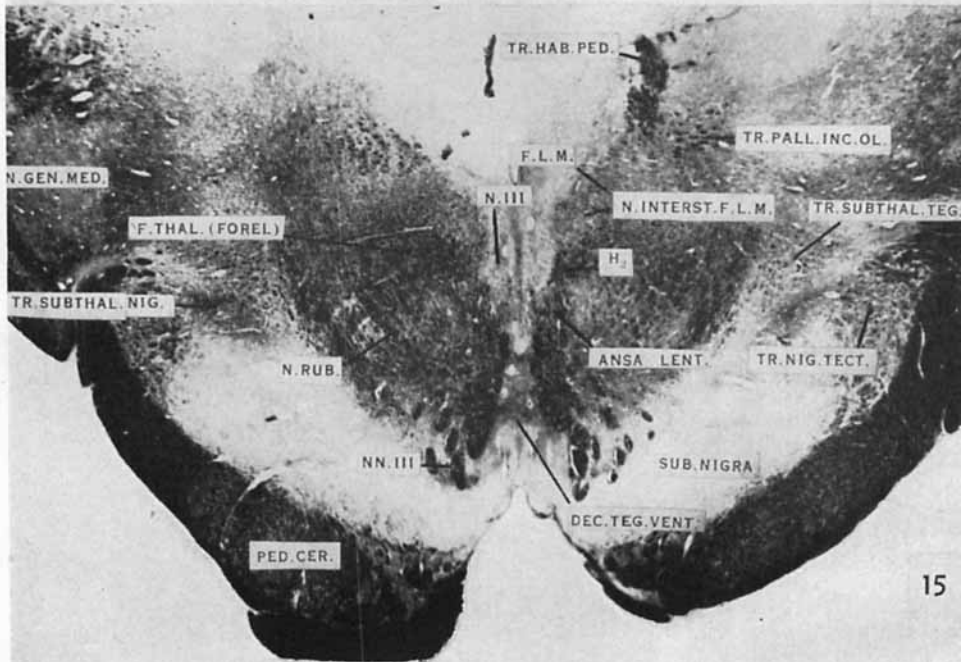
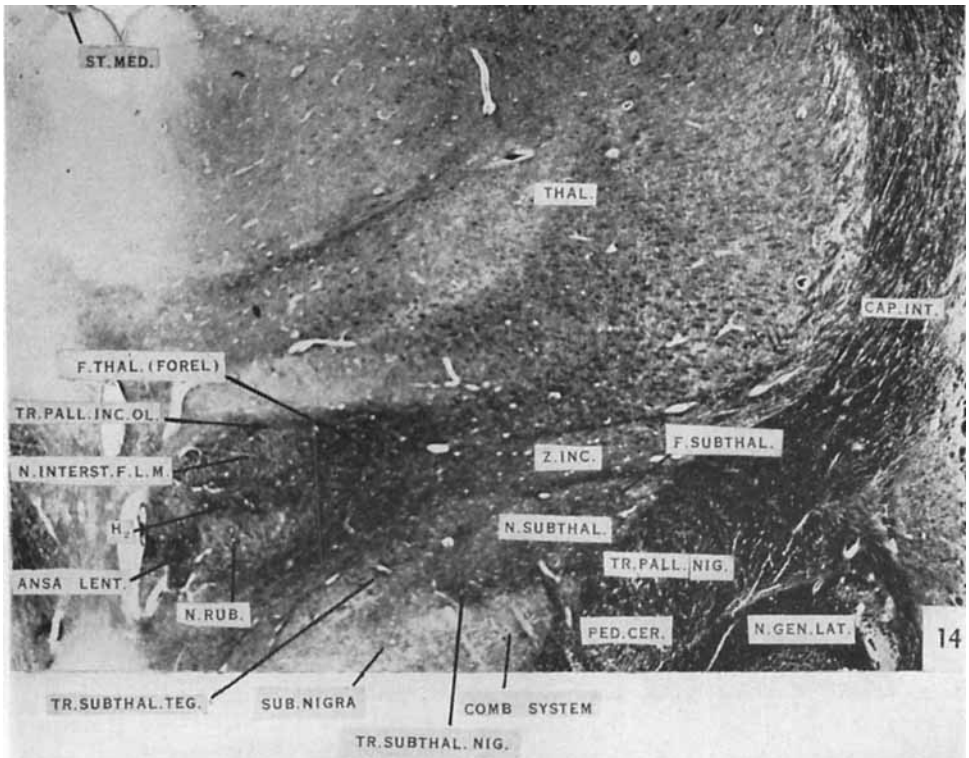


Figures 10 and 11

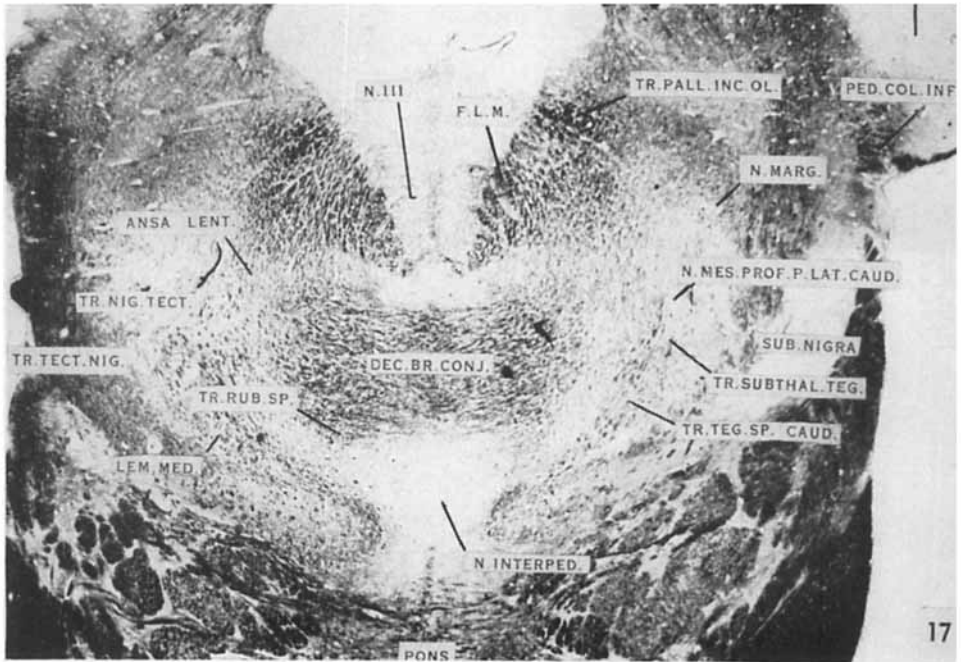
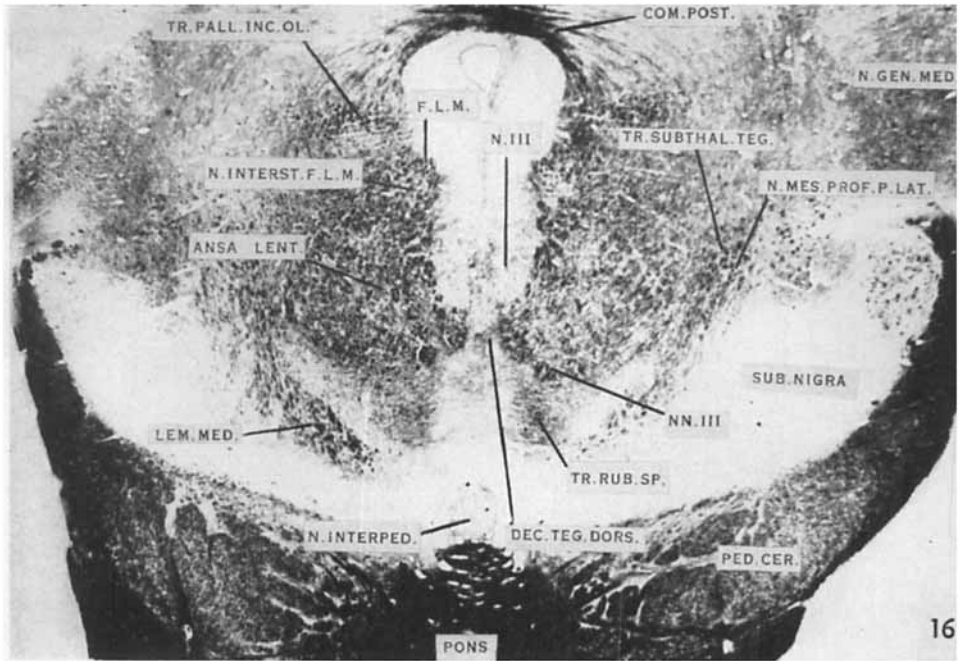


Figures 12 and 13





Figures 14 and 15



Figures 16 and 17