

# Utility of WT-1, p63, MOC31, Mesothelin, and Cytokeratin (K903 and CK5/6) Immunostains in Differentiating Adenocarcinoma, Squamous Cell Carcinoma, and Malignant Mesothelioma in Effusions

Robert T. Pu, M.D., Ph.D.,\* Yijun Pang, M.D., Ph.D., and Claire W. Michael, M.D.

To distinguish carcinoma, either adenocarcinoma (ADC) or squamous cell carcinoma (SCC), and malignant mesothelioma (MM) in effusion can be a diagnostic challenge based on morphology alone. This study evaluates the utility of WT-1, p63, MOC31, mesothelin, and cytokeratin (K903 and CK5/6) immunostains in effusions when ADC and SCC of the lung are in the differential diagnosis with MM. A cohort of 43 effusions consisting of lung ADC (N = 10), SCC (N = 15), and MM (N = 18, mostly (16) pleural based), was subjected to immunostains using the above mentioned antibodies. WT-1 was positive in 100% MM, 0% ADC, and 0% SCC cases while p63 was positive in 0% MM, 30% ADC, and 80% SCC cases. Stain for MOC31 was positive in 100% ADC, 67% SCC, and 35% MM cases. Similarly, mesothelin antibody stained 100% ADC, 60% SCC, and 47% MM cases. Antibodies for K903 and CK5/6 stained 100% SCC cases but fewer ADC cases (40 and 10%, respectively). In conclusion, in this cohort of mostly pleural malignant effusion, MM can be identified with positive staining for WT-1 and negative staining for p63. Conversely, negative staining with WT-1 and positive staining for p63 exclude MM. Used as part of an immunostain panel, cytokeratin markers (CK5/6 and K903) are useful in differentiating SCC from ADC when MM is already excluded, and MOC31 might have limited value in differentiating ADC from MM. A negative stain with MOC31 can exclude lung ADC. Mesothelin, on the other hand, is not useful in the differential diagnosis of ADC, SCC, and MM. *Diagn. Cytopathol.* 2008;36:20–25. © 2007 Wiley-Liss, Inc.

**Key Words:** malignant effusion; adenocarcinoma; squamous cell carcinoma; mesothelioma; WT-1; p63; MOC31; mesothelin; K903; CK5/6

It is difficult to distinguish poorly differentiated carcinoma of lung, either adenocarcinoma (ADC) or squamous cell carcinoma (SCC), from malignant mesothelioma (MM) based on morphology alone in pleural effusion. After a diagnosis of malignancy is initially made in effusions, further classification of ADC, SCC, or MM is needed to help identify the primary tumor and to determine therapy approaches. In daily pathology practice, immunocytochemical stains (ICC) play a vital role in aiding differential diagnoses. The most widely used immunopanel in surgical and cytology specimens includes calretinin, CEA, BerEP4, CD15 (LeuM1), and cytokeratins.<sup>1–4</sup> However, lack of high specificity and sensitivity of these markers prompted an on going search of better markers.

Newer markers including WT-1, p63, MOC31, and mesothelin have been described and some have gained acceptance to be used in practice. Wilms' tumor susceptibility gene (WT-1) expression is mostly restricted to mesenchymally derived tissues.<sup>5,6</sup> Antibody raised against this gene product shows strong nuclear stain in mesothelioma cell lines and in mesothelioma, but not in non-mesothelioma tumors involving the lung, including non-small cell carcinomas examined.<sup>6,7</sup> Others, however, did not find WT-1 as a specific marker for mesothelioma, especially in autopsy specimens.<sup>8</sup> Another antibody that has been described recently is an antibody against p63, a p53-related gene product, which has been shown to be specific for SCC and is con-

Department of Pathology, University of Michigan Medical School, Ann Arbor, Michigan

\*Correspondence to: Robert T. Pu, M.D., Ph.D., Department of Pathology, The University of Michigan Medical School, 1500 E. Medical Center Drive, Room 2G332, Ann Arbor, MI 48109.

E-mail: robertpu@umich.edu

Received 3 March 2007; Accepted 4 May 2007

DOI 10.1002/dc.20747

Published online in Wiley InterScience (www.interscience.wiley.com).

sidered one of the best markers to be used in a panel when the differential diagnosis is between SCC and MM.<sup>9</sup> Similarly, MOC31 and mesothelin have been tested for their utility in the differential diagnosis of MM and shown to be useful in separating lung SCC from MM.<sup>10,11</sup> MOC-31 is a monoclonal antibody that recognizes a transmembrane glycoprotein often expressed in epithelial tumors. Mesothelin is also a glycoprotein that its membrane bound form has been found expressed in mesothelial cells<sup>12</sup> and a commercially available antibody (5B2) has been applied to paraffin embedded clinical samples.<sup>10,11,13</sup> One recent publication showed MOC31's utility in separating ADC from reactive mesothelial cells in pleural effusions (MOC-31 was found to be 95% sensitive and 100% specific for ADC).<sup>14</sup> A more comprehensive analysis of multiple markers in 30 MM and 30 SCC for their utility demonstrated that 100% of the MM were positive for calretinin and mesothelin, 93% each for WT1 and keratin 5/6, 7% each for p63, and MOC-31, and 0% for B72.3, CEA, leu-M1, and TTF-1.<sup>9</sup> In this study, 100% of the SCC was positive for p63 and keratin 5/6, 97% for MOC-31, 77% for CEA, 40% for calretinin, 30% for leu-M1, 27% for mesothelin, and 0% for WT 1 and TTF-1.<sup>9</sup> This study recommended using a combination of two positive mesothelioma markers (WT1 and calretinin or mesothelin) with two negative mesothelioma markers (p63 and MOC-31) to differentiate between epithelioid mesotheliomas and SCC of the lung.<sup>9</sup> In contrast, a recent study found that although anti-mesothelin antibody stained mesothelioma and benign mesothelial cells more frequently than ADC with statistical significance; however, mesothelin was not a good marker for mesothelioma with a sensitivity and specificity of 73% and 55%, respectively, in comparison to calretinin with a sensitivity and specificity of 95% and 86%, respectively.<sup>13</sup> Others further demonstrated that cytokeratins, especially CK5/6, were among the markers showing utility in differentiating MM from other epithelial neoplasms.<sup>15,16</sup> A recent article systematically analyzed published data from 88 papers in order to establish the sensitivity and specificity of 15 commonly used antibodies in distinguishing mesothelioma from lung ADC.<sup>2</sup> This analysis concluded that MOC-31 and BG8 were the most sensitive antibodies for identifying pulmonary ADC (both with 93% sensitivity) while monoclonal CEA and TTF-1 were the most specific (97% and 100% specificity). In their analysis, CK5/6 and HBME-1 were the most sensitive antibodies for epithelioid mesothelioma (83% and 85%) and the most specific antibodies were CK5/6 (85%) and WT-1 (96%).<sup>2</sup> However, it seems not uncommon to have different results from different studies although a few mesothelial markers, carcinoma markers, and other miscellaneous markers were considered most useful in differentiating epithelioid MM from carcinomas.<sup>17</sup>

Those studies were mostly performed on surgical specimens. It is known that different types of specimen prepa-

rations influence immunochemical reaction and consequently the utility of immunostains. In addition, the tumor cells in body effusions may have changed protein expression profile because of the different molecular signaling in the environment.<sup>18-20</sup> Thus, it is necessary to perform a validation study in order to extend the use of tumor markers to cytopathology. Furthermore, to our knowledge, a direct comparison of reactivity for WT-1, p63, mesothelin, and MOC31 antibodies in effusion to differentiate ADC, SCC, and MM has not been performed. Recently, we have explored the role of a panel of 6 antibodies, including antibodies for calretinin, cytokeratins, in distinguishing lung ADC and SCC, and MM in effusions.<sup>21</sup> The purpose of the current study was to extend our previous analysis and to evaluate whether WT-1, p63, MOC31, mesothelin, and cytokeratin (CK5/6 and K903) have a utility in the diagnosis of malignant effusions when ADC, SCC, and MM are in the differential diagnosis.

## Materials and Methods

We identified a cohort of malignant effusions consisting of ADC (10 cases), SCC (15 cases), and MM (18 cases) in our institution with IRB approval. All the carcinoma cases were confirmed by surgical biopsy or resection with lung as the primary site. MM diagnoses were based on morphological criteria, supporting immunohistochemical stains, mostly also with follow up surgical diagnosis, and clinical follow up information and electron microscopy examination in some cases. Paraffin cell blocks of effusions were retrieved from department archives and 4- $\mu$ m thick sections were cut on charged slides and submitted for immunostaining procedures following the manufacturer's suggested condition with optimization for each individual antibody. Immunostains using antibodies for WT-1, p63, mesothelin, and MOC31 were performed on all cases in this cohort, and in addition, all ADC, SCC and a few MM cases were also stained with antibodies against cytokeratin (CK5/6 and CK903). The detailed information of antibodies, antigen retrieval, and conditions for each antibody's detection methods was listed on Table I. The immunocytochemical stains were performed on the DAKO Auto-stainer at room temperature with final DAB chromogen reaction for 5 min. Nuclear stains by WT-1 and p63 antibody were considered positive while membranous/cytoplasm stain with MOC31, mesothelin, and cytokeratin (K903 and CK5/6) were considered positive. The final score on each case was recorded as either negative (<10% of the tumor cells positive) or positive (>10% of the tumor cells positive) staining similar to our previous study.<sup>21</sup> All scores were obtained blindly and independently from all participating cytopathologists and scoring differences were resolved before a consensus score was given to any case.

**Table I.** Antibodies and Detection Conditions

Antibody (clone) names and vendors	1° Ab, dilution and time	2° Ab, time	3° streptavidin label
Wilm's tumor 1 (WT-1), Cell Marque Corporation, Hot Springs, AR	1:50, 30'	30'	n/a
p63 (Ab-1), LabVision, Fremont, CA	1:100, 15'	45'	30'
MOC31(ERA), DAKO, Carpinteria, CA	1:30, 30'	30'	n/a
Mesothelin (5B2), Novocastra Lab. Newcastle Upon Tyne, UK	1:100, 30'	60'	n/a
Cytokeratin-K903, DAKO, Carpinteria, CA	1:100, 30'	30'	30'
Cytokeratin-CK5/6, Chemicon International, Temecula, CA	1:100, 30'	30'	30'

Antigen retrieval: 1. 10 min microwave with citrate buffer, pH 6.0; 2. 10 min cooling; 3. 15 min tap water wash.

**Table II.** Comparison Among Three Tumor Types for Different Antibodies

Tumor	Total	Positive cases (%) for each antibody					
		p63	WT-1	MOC31	Mesothelin	K903	CK5/6
ADC	10	3 (30)	0 (0)	10 (100)	10 (100)	4 (40)	1 (10)
SCC	15	12 (80)	0 (0)	10 (67)	9 (60)	15 (100)	15 (100)
MM	18	0 (0)	18 (100)	6 (35 <sup>a</sup> )	8 (47 <sup>a</sup> )	<sup>b</sup>	<sup>b</sup>
<i>P-values</i>							
ADC vs. SCC		0.0124	n/a	0.013	0.0056	0.0001	<0.00001
ADC vs. MM		0.0047	<0.00001	<0.00001	0.0007	n/a	n/a
SCC vs. MM		<0.00001	<0.00001	0.056	0.46	n/a	n/a

<sup>a</sup>17 MM cases were stained for those two antibodies.

<sup>b</sup>Our previous publication had demonstrated that MM were positive for K903 and CK5/6<sup>21</sup> and a few MM cases stained in current series were also positive.

Statistical analysis was performed using a two-sided  $\chi^2$  test and a *P* value of less than 0.05 was considered significant.

**Results**

A cohort of 43 malignant effusions consisting of ADC (10 cases), SCC (15 cases), and MM (18 cases) were included for the study. The mean ages for the three groups were 72, 72, and 64 years for ADC, SCC, and MM groups, respectively. There was a male predominance among the three groups of patients: ADC (all male, 10), SCC (13 male and 2 female), and MM (13 male and 5 female). All of the ADC (10/10) and SCC (14/15) had lung as the primary site confirmed with biopsy or resection while most of the MM were pleural based (16/18).

The antibody against p63 stained 80% SCC, 30% ADC, but 0% MM cases (Table II). Most of the SCC had intense nuclear stain (Fig. C-1, top row, middle column), while most of the ADC were negative (Fig. C-1, top row, right column) with only a few cases having tumor cells stained with weak to moderate intensity, and no tumor cells in MM stained with this antibody (Fig. C-1, top row, left column). The difference between MM and SCC was very dramatic (0% vs. 80%) while the difference between MM and ADC, or ADC and SCC was also statistically significant (Table II). Antibody against WT-1 reacted to 100% MM with intense nuclear stain but did not stain any of the ADC or SCC, although scattered background reactive/benign mesothelial cells were marked with this antibody (Table II, Fig. C-1, second row).

MOC31 and antibody against mesothelin displayed a similar trend in staining ADC, SCC, and MM cases with a predominant membranous stain pattern (Fig. C-1, third and fourth row). MOC31 stained 100% ADC, 67% SCC, but only 35% MM cases (Table II). The positive reactions to this antibody between the following pairs, ADC versus SCC (100% vs. 67%, *P* = 0.013) and SCC versus MM (67% vs. 35%, *P* = 0.056), although different, had too much overlap for this antibody to be useful for differential diagnosis. There might be a utility of this antibody in differentiating ADC from MM (100% vs. 35%, *P* < 0.00001). Similarly, antibody against mesothelin also stained 100% ADC, but only 60% SCC and 47% MM cases (ADC vs. SCC, *P* = 0.0056, ADC vs. MM, *P* = 0.0007, SCC vs. MM, *P* = 0.46, Table II). As the above tested antibodies did not show much value in discriminating between ADC and SCC, antibodies for cytokeratins (K903 and CK5/6, Fig. C-1, bottom two rows) were included to stain ADC and SCC cases in order to separate the two groups. The results showed that the SCC cases were all positive for CK5/6 (100%) with a cytoplasmic stain pattern (Fig. C-1) and ADC cases were rarely positive (10%), significantly different by statistical analysis (Table II). The stain for K903 was positive in all the SCC (100%) with a cytoplasmic stain pattern, but was also positive in almost half of the ADC (40%) cases (Table II). MM also stained positive for those two cytokeratin stains in the limited number of cases we tested in this cohort (Fig. C-1, first column, last two rows).

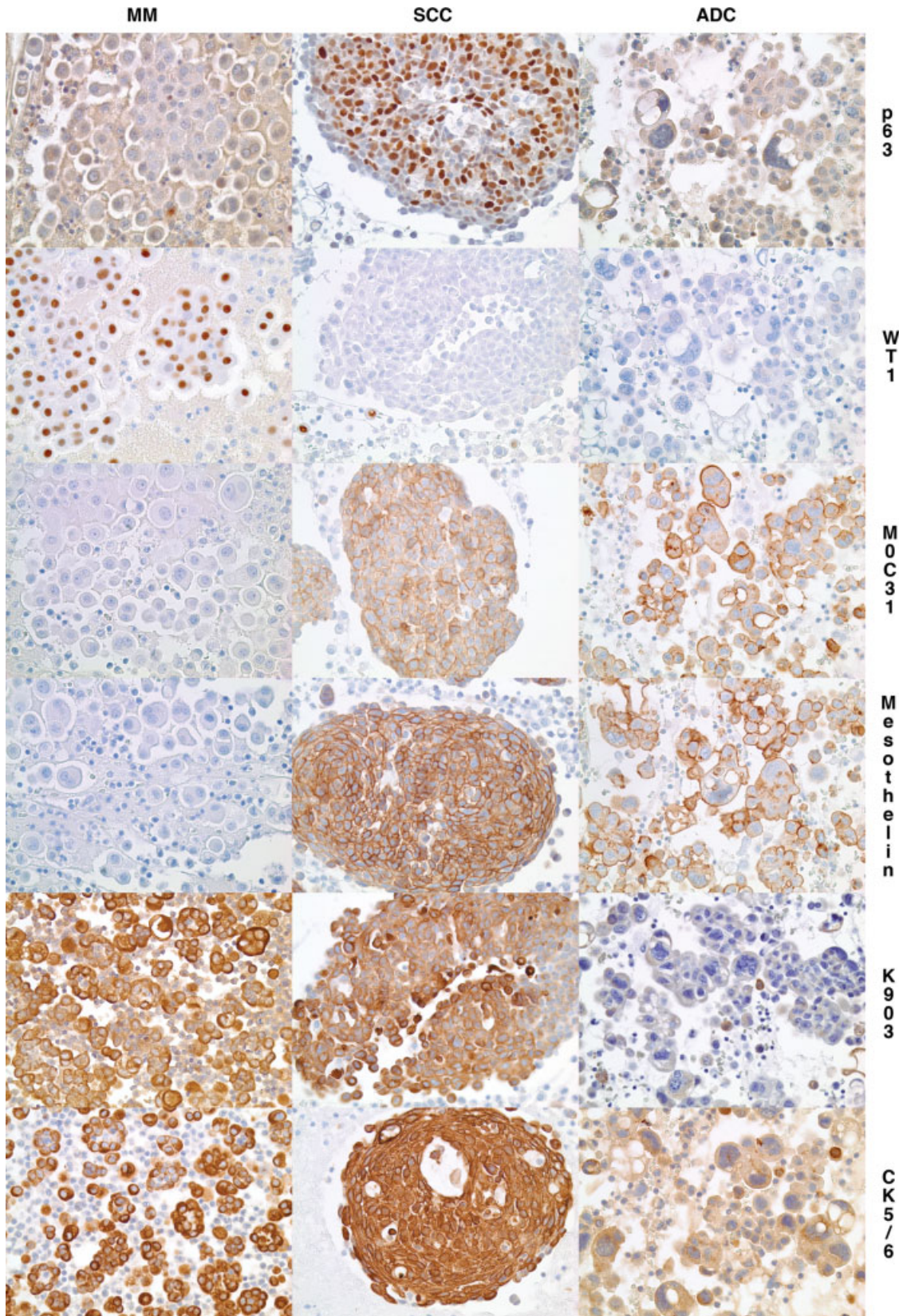


Fig. C-1. Composite of representative images of MM, SCC, and ADC stained with each antibody (all at 40× magnification).

## Discussion

In this report, we tested the utility of a panel of immunostains including WT-1, p63, MOC31, mesothelin, and cytokeratins (K903 and CK5/6) in malignant effusions (mostly pleural) consisting of ADC, SCC, and MM. We showed that WT-1 was most useful in differentiating MM from either SCC or ADC of lung origin. MM cases were 100% positive for WT-1 while none of the ADC or SCC was positive. The sensitivity and specificity were both 100%. We demonstrated that WT-1 has comparable, if not higher, specificity and sensitivity for mesothelial cells in cytological specimens, mainly pleural effusions, to that of the most frequently used positive mesothelial marker, calretinin.<sup>21</sup> Although the number of cases in our cohort was small, our results did confirm WT-1's utility in effusions as a positive mesothelial marker, which had been demonstrated in biopsy specimens.<sup>2,9</sup> Like calretinin, it does not differentiate MM from benign/reactive mesothelial cells, thus has no utility in such a setting. Another cautionary note is that ADC and SCC cases in our cohort are of lung origin from predominantly male patients, thus breast and ovarian carcinoma are not in the differential diagnosis and the conclusion does not apply to them, as it has been shown that WT-1 is positive in serous carcinoma of ovarian surface origin.<sup>22</sup>

Antibody against p63 stained a significant percentage of SCC cases, a much lower percentage of ADC, and none of the MM. Our result supports the utility of p63 in pleural effusions as a marker in distinguishing lung SCC from MM. Using WT-1 and p63 stains, most of the time, we could reliably separate MM (positive for WT-1 and negative for p63) from lung SCC and ADC in malignant pleural effusions. This finding was similar to what others had reported in pleural biopsies of epithelioid MM and lung SCC.<sup>9</sup> although in our cohort the percentage of p63 positive SCC was slightly lower.

On the other hand, our results that MOC31 stained 100% of ADC, 67% of SCC, and 35% of MM made it not a very useful marker, although used as part of a panel of markers it might be helpful in distinguishing ADC from MM. In our study, MOC31 stained small but significant numbers of MM cases, somewhat different from others' findings which showed MOC31 as a positive marker for ADC or SCC (with 95–97% sensitivity and 93–100% specificity) and a negative marker for MM (7% positive).<sup>9,14</sup> By the same token, our anti-mesothelin stain pattern of 100% positive for ADC, 60% for SCC, and 47% for MM was in sharp contrast to some published results which showed positive stain in all MM (100%) and much lower positive stain for lung ADC (40%) and SCC (27%) but slightly higher percentage of non-pulmonary ADC (50%).<sup>9,11,23</sup> However, some of the recent publications demonstrated that mesothelin was not a very specific or sensitive marker for mesothelioma (one study has a sensitivity of 73% and specificity of 55%<sup>13</sup>), although

in those studies mesothelioma was stained with a much higher percentage than ADC.<sup>9,13,24</sup> One Japanese group analysing 90 epithelioid MM and 51 lung ADC showed similar positive stain by mesothelin antibody in MM (77%) and ADC (69%), which further suggest mesothelin might not be a good marker for mesothelioma at all.<sup>24</sup>

Our results suggest that MOC31 and mesothelin stains are not very useful in pleural effusions for our differential diagnosis, even though the differences among the three groups are statistically significant. Explanations for MOC31 and mesothelin stain difference between ours and that of the others could be many, including but not limited to: different specimen fixation conditions of surgical and cytological samples, different antigen retrieval methods, and different primary and secondary antibody or detection conditions. The mesothelin antibody we used is the same as others have used.<sup>13</sup> The pre-treatment for antigen retrieval and dilution of primary antibody were similar, but we used a different detection system (DAKO vs. Ventana).<sup>13</sup> In addition, we had ADC of lung primary while it was more diverse groups of adenocarcinoma in others' cohort.<sup>13</sup> Furthermore, different definitions of a positive, e.g. different percentage of positive tumor cells stained to be scored as positive or in some studies only membrane stain, while in others, as was in our case, either membranous and cytoplasm stain of mesothelin were considered positive, may contribute to inconsistency in positive rates. We don't have a plausible explanation for the discrepancy observed on anti-mesothelin stain, except it strongly suggests that it is prudent to have each antibody validated for its performance in the individual laboratory before universal application.

In our cohort, in order to differentiate ADC from SCC, cytokeratin stains (K903 and CK5/6) were necessary as all of the SCC were positive for those two-antibody stains, while fewer cases of ADC were positive for them. Another stain, TTF1, demonstrated by other's published data and also in our experience, can help separating lung ADC from SCC.<sup>25</sup> It is worth mentioning that MM also stained positive for those two cytokeratin stains in the limited number of cases we tested in this cohort (data not shown) and in our previously published work.<sup>21</sup> Therefore, the utility of K903 and CK5/6 in separating ADC from SCC is valid only when MM has been ruled out.

In conclusion, MM can be separated from either SCC or ADC by its WT-1 positive and p63 negative stains when differential diagnoses of malignant effusions involving lung carcinoma (either ADC or SCC) and MM. p63 is more likely to be positive in SCC than ADC, but cytokeratin, especially CK5/6 is a better marker in separating SCC from ADC when MM has been ruled out. MOC31 might have limited value in differentiating ADC from MM in conjunction with other markers, but it is not useful in differentiating between SCC and ADC or MM and

SCC other than that negative MOC31 stain can exclude lung ADC. Mesothelin, in our cohort, is not a useful marker in the differential diagnosis of ADC, SCC and MM.

## References

1. Yaziji H, Battifora H, Barry TS, et al. Evaluation of 12 antibodies for distinguishing epithelioid mesothelioma from adenocarcinoma: Identification of a three-antibody immunohistochemical panel with maximal sensitivity and specificity. *Mod Pathol* 2006;19:514–523.
2. King JE, Thatcher N, Pickering CA, Hasleton PS. Sensitivity and specificity of immunohistochemical markers used in the diagnosis of epithelioid mesothelioma: A detailed systematic analysis using published data. *Histopathology* 2006;48:223–232.
3. Chhieng DC, Yee H, Schaefer D, et al. Calretinin staining pattern aids in the differentiation of mesothelioma from adenocarcinoma in serous effusions. *Cancer* 2000;90:194–200.
4. De Angelis M, Buley ID, Heryet A, Gray W. Immunocytochemical staining of serous effusions with the monoclonal antibody Ber-EP4. *Cytopathology* 1992;3:111–117.
5. Thorner P, Squire J, Plavsic N, et al. Expression of WT1 in pediatric small cell tumors: Report of two cases with a possible mesothelial origin. *Pediatr Dev Pathol* 1999;2:33–41.
6. Amin KM, Litzky LA, Smythe WR, et al. Wilms' tumor 1 susceptibility (WT1) gene products are selectively expressed in malignant mesothelioma. *Am J Pathol* 1995;146:344–356.
7. Hecht JL, Lee BH, Pinkus JL, Pinkus GS. The value of Wilms tumor susceptibility gene 1 in cytologic preparations as a marker for malignant mesothelioma. *Cancer* 2002;96:105–109.
8. Oates J, Edwards C. HBME-1, MOC-31, WT1 and calretinin: An assessment of recently described markers for mesothelioma and adenocarcinoma. *Histopathology* 2000;36:341–347.
9. Ordonez NG. The diagnostic utility of immunohistochemistry in distinguishing between epithelioid mesotheliomas and squamous carcinomas of the lung: A comparative study. *Mod Pathol* 2006;19:417–428.
10. Ordonez NG. Value of the MOC-31 monoclonal antibody in differentiating epithelial pleural mesothelioma from lung adenocarcinoma. *Hum Pathol* 1998;29:166–169.
11. Ordonez NG. Value of mesothelin immunostaining in the diagnosis of mesothelioma. *Mod Pathol* 2003;16:192–197.
12. Chang K, Pai LH, Pass H, et al. Monoclonal antibody K1 reacts with epithelial mesothelioma but not with lung adenocarcinoma. *Am J Surg Pathol* 1992;16:259–268.
13. Kachali C, Eltoum I, Horton D, Chhieng DC. Use of mesothelin as a marker for mesothelial cells in cytologic specimens. *Semin Diagn Pathol* 2006;23:20–24.
14. Morgan RL, De Young BR, McGaughy VR, Niemann TH. MOC-31 aids in the differentiation between adenocarcinoma and reactive mesothelial cells. *Cancer* 1999;87:390–394.
15. Chu PG, Weiss LM. Expression of cytokeratin 5/6 in epithelial neoplasms: An immunohistochemical study of 509 cases. *Mod Pathol* 2002;15:6–10.
16. Ordonez NG. Value of cytokeratin 5/6 immunostaining in distinguishing epithelial mesothelioma of the pleura from lung adenocarcinoma. *Am J Surg Pathol* 1998;22:1215–1221.
17. Ordonez NG. What are the current best immunohistochemical markers for the diagnosis of epithelioid mesothelioma? A review and update. *Hum Pathol* 2007;38:1–16.
18. Davidson B, Lazarovici P, Ezersky A, et al. Expression levels of the nerve growth factor receptors TrkA and p75 in effusions and solid tumors of serous ovarian carcinoma patients. *Clin Cancer Res* 2001;7:3457–3464.
19. Davidson B, Reich R, Lazarovici P, et al. Altered expression and activation of the nerve growth factor receptors TrkA and p75 provide the first evidence of tumor progression to effusion in breast carcinoma. *Breast Cancer Res Treat* 2004;83:119–128.
20. Yanagisawa Y, Sato Y, Asahi-Ozaki Y, et al. Effusion and solid lymphomas have distinctive gene and protein expression profiles in an animal model of primary effusion lymphoma. *J Pathol* 2006;209:464–473.
21. Li Q, Bavikatty N, Michael CW. The role of immunohistochemistry in distinguishing squamous cell carcinoma from mesothelioma and adenocarcinoma in pleural effusion. *Semin Diagn Pathol* 2006;23:15–19.
22. Hwang H, Quenneville L, Yaziji H, Gown AM. Wilms tumor gene product: Sensitive and contextually specific marker of serous carcinomas of ovarian surface epithelial origin. *Appl Immunohistochem Mol Morphol* 2004;12:122–126.
23. Ordonez NG. The immunohistochemical diagnosis of mesothelioma: A comparative study of epithelioid mesothelioma and lung adenocarcinoma. *Am J Surg Pathol* 2003;27:1031–1051.
24. Kushitani K, Takeshima Y, Amatya VJ, et al. Immunohistochemical marker panels for distinguishing between epithelioid mesothelioma and lung adenocarcinoma. *Pathol Int* 2007;57:190–199.
25. Saad RS, Lindner JL, Lin X, Liu YL, Silverman JF. The diagnostic utility of D2-40 for malignant mesothelioma versus pulmonary carcinoma with pleural involvement. *Diagn Cytopathol* 2006;34:801–806.