

Factors Predicting Additional Disease in the Axilla in Patients With Positive Sentinel Lymph Nodes After Neoadjuvant Chemotherapy

Jacqueline S. Jeruss, MD, PhD¹

Lisa A. Newman, MD, MPH²

Gregory D. Ayers, MS³

Massimo Cristofanilli, MD⁴

Kristine R. Broglio, MS⁵

Funda Meric-Bernstam, MD¹

Min Yi, MD¹

Jennifer F. Waljee, MD²

Merrick I. Ross, MD¹

Kelly K. Hunt, MD¹

¹ Department Surgical Oncology, The University of Texas M. D. Anderson Cancer Center, Houston, Texas.

² Department of Surgery, University of Michigan Medical School, Ann Arbor, Michigan.

³ Department of Biostatistics, Vanderbilt University School of Medicine, Nashville, Tennessee.

⁴ Department of Breast Medical Oncology, The University of Texas M. D. Anderson Cancer Center, Houston, Texas.

⁵ Division of Quantitative Sciences, The University of Texas M. D. Anderson Cancer Center, Houston Texas.

Dr. Jeruss's current address: Department of Surgery, Northwestern University Feinberg School of Medicine, Chicago, Illinois.

Presented in part at the Annual Meeting of the American Society of Clinical Oncology, Atlanta, Georgia, June 2–6, 2006.

We thank Stephanie Deming and Dr. Stacey C. Tobin for their assistance in preparing this article.

Address for reprints: Kelly K. Hunt, MD, Department of Surgical Oncology, The University of Texas M. D. Anderson Cancer Center, 1515 Holcombe Boulevard, Unit 444, Houston, TX 77030; Fax: (713) 792-4689; E-mail: khunt@mdanderson.org

Received October 23, 2007; revision received January 27, 2008; accepted February 4, 2008.

BACKGROUND. The utility of sentinel lymph node (SNL) biopsy (SLNB) as a predictor of axillary lymph node status is similar in patients who receive neoadjuvant chemotherapy and patients who undergo surgery first. The authors of this study hypothesized that patients with positive SLNs after neoadjuvant therapy would have unique clinicopathologic factors that would be predictive of additional positive non-SLNs distinct from patients who underwent surgery first.

METHODS. One hundred four patients were identified who received neoadjuvant chemotherapy, had a positive SLN, and underwent axillary dissection between 1997 and 2005. At the time of presentation, 66 patients had clinically negative lymph nodes by ultrasonography, and 38 patients had positive lymph nodes confirmed by fine-needle aspiration. Eighteen factors were assessed for their ability to predict positive non-SLNs using chi-square and logistic regression analysis with a bootstrapped, backwards elimination procedure. The resulting nomogram was tested by using a patient cohort from another institution.

RESULTS. Patients with clinically negative lymph nodes at presentation were less likely than patients with positive lymph nodes to have positive non-SLNs (47% vs 71%; $P = .017$). On multivariate analysis, lymphovascular invasion, the method for detecting SLN metastasis, multicentricity, positive axillary lymph nodes at presentation, and pathologic tumor size retained grouped significance with a bootstrap-adjusted area under the curve (AUC) of 0.762. The resulting nomogram was validated in the external patient cohort (AUC, 0.78).

CONCLUSIONS. A significant proportion of patients with positive SLNs after neoadjuvant chemotherapy had no positive non-SLNs. The use of a nomogram based on 5 predictive variables that were identified in this study may be useful for predicting the risk of positive non-SLNs in patients who have positive SLNs after chemotherapy. *Cancer* 2008;112:2646–54. © 2008 American Cancer Society.

KEYWORDS: neoadjuvant therapy, nomogram, breast cancer, sentinel lymph node biopsy.

The accuracy of sentinel lymph node (SLN) biopsy (SLNB) for predicting the status of axillary lymph nodes in patients with early-stage breast cancer has been confirmed in several studies, and SLNB rapidly is replacing axillary dissection as the initial surgical approach to the axilla in clinically lymph node-negative patients.^{1–5} For patients who have negative SLNs, no further axillary surgery is performed; however, for patients who have positive SLNs, completion axillary dissection remains the standard practice. Low axillary recurrence rates have been reported for SLN-positive patients who do not undergo completion axillary dissection in the adjuvant

setting; however, only a few larger studies have confirmed initial reports from single institutions with short-term follow-up.⁶⁻¹⁰

Questions have arisen regarding the utility of SLNB for patients who receive neoadjuvant chemotherapy as the use of this technique has become more prevalent in clinical practice. The timing of SLNB in patients who receive neoadjuvant chemotherapy has been debated, although studies have demonstrated that SLNB is accurate both before and after therapy.^{11,12} Some clinicians favor SLNB before neoadjuvant chemotherapy so that lymph node staging information can be used to help choose a specific chemotherapy regimen. Others prefer to perform SLNB after neoadjuvant chemotherapy has been completed, because some initially lymph node-positive patients may have a complete pathologic response in the lymph node basin and, thus, they potentially may avoid a completion axillary lymph node dissection.¹³⁻¹⁵ In general, patients who have positive axillary lymph nodes identified before neoadjuvant chemotherapy, either by ultrasound-guided biopsy or by SLNB, are committed to standard axillary dissection after they complete chemotherapy. However, patients who have negative axillary lymph nodes before neoadjuvant chemotherapy may not need to undergo a standard axillary dissection after they complete chemotherapy.

Currently, a nomogram designed by investigators from Memorial Sloan-Kettering Cancer Center is being used in clinical practice to predict the probability of non-SLN metastases in patients who have a positive SLN.¹⁶ This nomogram, which helps to identify patients with positive SLNs who may be spared additional axillary surgery, has been validated by several institutions, yet it may not be useful for the subset of patients who have received neoadjuvant chemotherapy.¹⁷ We sought to develop a nomogram designed specifically to predict the likelihood of positive non-SLNs in patients with a positive SLN after neoadjuvant chemotherapy. To develop this nomogram, we analyzed multiple clinical and pathologic factors for their ability to predict positive non-SLNs.

MATERIALS AND METHODS

By using a prospective database, we identified 104 patients who had received neoadjuvant chemotherapy, who had a positive SLN on subsequent SLNB, and who underwent a completion axillary lymph node dissection between 1997 and 2005. Individual clinical and tumor characteristics, treatment regimens, and patient outcomes were recorded. An SLN was considered positive if it contained a tumor de-

posit that measured >0.2 mm, in accordance with the sixth edition of the *American Joint Committee on Cancer Staging Manual*.¹⁸ All patient information was reviewed for accuracy by examination of the primary source documents. The study was approved by the Institutional Review Board of The University of Texas M. D. Anderson Cancer Center (M. D. Anderson) with waiver of informed consent.

We evaluated 18 factors for their ability to predict positive non-SLNs in patients with positive SLNs: estrogen receptor status, progesterone receptor status, HER-2 status, lymphovascular invasion (LVI), method of detection of SLN metastasis (immunohistochemical analysis, hematoxylin-and-eosin (H&E) staining, or touch preparation cytology), nuclear grade, multifocality, multicentricity, pathologic tumor size, primary tumor clinical response to neoadjuvant chemotherapy, lymph node clinical response to neoadjuvant chemotherapy, use of taxanes in the neoadjuvant regimen, duration of neoadjuvant chemotherapy (<4 months or ≥ 4 months), number of negative SLNs, number of positive SLNs, presence of positive axillary lymph nodes at initial presentation (determined by axillary sonography and fine-needle aspiration [FNA] biopsy), maximum SLN metastasis size (defined as largest SLN metastasis size), and presence of extranodal extension in the SLN. Univariate assessment of the 18 potential predictors of positive non-SLNs was performed by using chi-square analysis. Then, a multivariate logistic regression model was used to construct a nomogram to predict non-SLN metastases among patients with SLN metastases after neoadjuvant chemotherapy. All 18 variables of interest were entered into a full model, and the final model was selected by using a backwards elimination procedure with Akaike's information criterion to determine whether a factor should be deleted from the model.¹⁹ The nomogram was validated internally with 200 bootstrap samples, and the bootstrap-adjusted area under the receiver operating characteristic curve (AUC) was calculated to quantify the nomogram's ability to rank patients on the basis of risk. According to this evaluation, a nomogram with good discrimination will predict a higher probability of non-SLN metastases for a patient who has non-SLN metastases than for a patient who does not.

The nomogram was validated externally with data from 41 patients with breast cancer who were treated at the University of Michigan. Pretreatment lymph node status for these patients was determined by using sonography and FNA biopsy with or without SLNB. Patients who were identified as lymph node negative by sonography and FNA underwent an SLNB to confirm lymph node status. Patients who

were identified as lymph node positive were treated with neoadjuvant chemotherapy followed by a subsequent SLNB; then, all patients underwent a completion axillary dissection. The M. D. Anderson nomogram (available at <http://www.mdanderson.org/postchemoSLNnomogram>) was used to predict the odds of positive non-SLNs for each patient. Performance of the nomogram in this group of patients was assessed by plotting the receiver operating characteristic curve and calculating the AUC. The 95% confidence interval of the AUC for the validation set was determined by calculating the AUC for 10,000 bootstrap samples and calculating the 2.5% and 97.5% quantiles. Analyses were performed by using R 2.3.1 with the contributed packages Design and ROCR.²⁰⁻²²

RESULTS

Patient Data

Demographics for the 104 patients who were treated at M. D. Anderson whose information was used to develop the nomogram are shown in Table 1. The median age for the study population was 52 years. The median clinical tumor size at presentation was 4 cm, and the median postneoadjuvant chemotherapy pathologic tumor size was 0.7 cm. At the time of initial presentation, 66 patients had clinically negative lymph nodes by sonography, and 38 patients had positive axillary lymph nodes determined by ultrasound-guided FNA biopsy. The majority of tumors were estrogen receptor positive (83%), progesterone receptor positive (67%), HER-2 negative (80%), and negative for LVI (75%). The maximum SLN metastasis size was 0.57 cm, and metastases were detected most commonly by H&E staining (52%). Overall, 58 patients (56%) had positive non-SLNs.

Nomogram

In univariate analyses, the factors that were associated significantly with non-SLN metastases at the $P < .05$ level were positive axillary lymph nodes at presentation, method of SLN metastasis detection, presence of LVI, multicentricity, lymph node response to neoadjuvant chemotherapy, nuclear grade, number of positive SLNs, and maximum SLN metastasis size. Patients with clinically negative axillary lymph nodes at presentation were less likely to have positive non-SLNs than patients with FNA biopsy-positive axillary lymph nodes at presentation (47% vs 71%; $P = .017$). The presence of positive non-SLNs by pathologic tumor classification (T) was as follows: T0, 0% (0 of 2 patients); T1a, 25% (1 of 4 patients); T1b, 58% (7 of 12 patients); T1c, 59% (19 of 32 patients); T2, 50% (20 of 40 patients); and T3, 79% (11 of 14 patients).

TABLE 1
Patient and Tumor Characteristics

Variable	No. of patients (%)
Median age [range], y	52 [27-76]
Median tumor size [range], cm	
Clinical	4 [1-12]
Pathologic	0.7 [0-9]
Tumor classification on final pathology	
T0	2 (2)
T1a	4 (4)
T1b	12 (12)
T1c	32 (31)
T2	40 (38)
T3	14 (13)
Estrogen receptor status	
Positive	86 (83)
Negative	18 (17)
Progesterone receptor status	
Positive	70 (67)
Negative	34 (33)
HER-2 status*	
Positive	20 (20)
Negative	79 (80)
Lymphovascular invasion	
Present	26 (25)
Absent	78 (75)
Nuclear grade	
1	10 (9)
2	61 (59)
3	33 (32)
Maximum metastasis size, cm	0.57
Method of detection	
IHC	23 (22)
H&E	54 (52)
Touch Prep	27 (26)
Focality	
Multicentric	10 (10)
Multifocal	22 (21)

IHC indicates immunohistochemical analysis; H&E, hematoxylin and eosin staining; Touch Prep, touch preparation cytology.

* HER-2 status data were unavailable for 5 patients.

In multivariate analyses, LVI, method of SLN metastasis detection, multicentricity, axillary lymph node status at presentation, and pathologic tumor size retained statistical significance at the $P < .05$ level. The bootstrap-adjusted coefficient estimates for this model are shown in Table 2, and this model was the basis for the nomogram derivation (Fig. 1). The AUC was 0.85, and the bootstrap-corrected AUC was 0.76 for the model. Figure 2A shows the distribution of patients according to total point scores for the study cohort. In the study cohort, applying the nomogram, 6 patients had a predicted probability for additional positive non-SLNs of $<10\%$, and no patients had a probability of $<5\%$. Of these 6 patients, no patient was identified who had LVI, all

TABLE 2
Factors Used to Create the Nomogram for Predicting the Presence of Nonsentinel Lymph Node Metastases in Patients With Positive Sentinel Lymph Nodes After Neoadjuvant Chemotherapy

Variable	Estimate	SE	OR	P
Lymphovascular invasion (present)	1.91	0.65	6.75	.003
Method of detection	1.15	0.38	3.16	.003
Multicentricity	2.50	1.15	12.18	.03
Initial lymph node disease (present)	1.50	0.55	4.48	.007
Pathologic tumor size	0.31	0.13	1.36	.02

SE indicates standard error; OR, odds ratio.

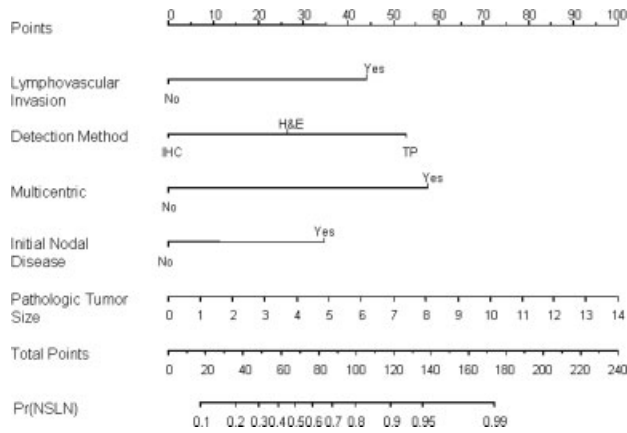


FIGURE 1. Five-variable nomogram. This nomogram was based on 5 variables to predict positive nonsentinel lymph nodes (non-SLNs) after neoadjuvant therapy. To calculate the probability of non-SLN metastasis, Pr (NSLN), for an individual patient, sum the points for each variable (Points), locate that sum on the Total Points line, and draw a line straight downward.

SLN metastasis were detected by immunohistochemistry, the tumors were not multicentric, and no patient had initial positive lymph node disease. Pathologic tumor size for the 6 patients was as follows: 2 patients, 0.5 cm; 1 patient, 1.0 cm; 1 patient, 1.45 cm; 1 patient, 1.50 cm; and 1 patient, 2.0 cm.

External Validation

All patients from the University of Michigan who were used for external validation of the nomogram had positive axillary lymph nodes at initial presentation. The majority of these patients had tumors that were negative for LVI (26 patients; 63%) and negative for multicentricity (40 patients; 98%). The median postneoadjuvant chemotherapy final pathologic tumor size was 1.2 cm. Final tumor size was unknown for 2 patients. In this validation group, 17 patients (41.5%) had non-SLN metastases identified. Metasta-

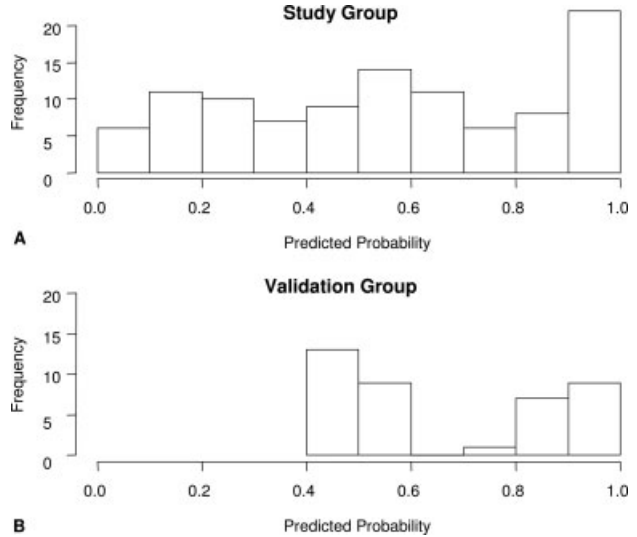


FIGURE 2. Histogram of predicted probabilities for the study group (A) and the validation group (B).

ses were detected by H&E staining. A comparison of characteristics of the University of Michigan patients and the M. D. Anderson patients using the nomogram variables is provided in Table 3. Figure 3 shows the receiver operating characteristic curve based on the University of Michigan validation group. The AUC was 0.78 (95% confidence interval, 0.62–0.92). When applying the nomogram to the validation cohort, no patients had a predicted probability of additional positive non-SLNs of <10%. Figure 2B shows the distribution of patients according to total point scores for the validation cohort.

DISCUSSION

In the current study, we observed that 44% of patients who had a positive SLN after neoadjuvant chemotherapy had no additional axillary lymph node disease. Thus, a significant proportion of the patients in this series were exposed to the potential morbidity of a completion axillary dissection without a significant benefit. With the nomogram derived and validated in this study, we now have a tool to predict the likelihood of positive non-SLNs in patients who have positive SLNs after neoadjuvant chemotherapy. This new nomogram is composed of 5 clinical and pathologic factors: LVI, method of detection of SLN metastasis, multicentricity, initial lymph node status, and pathologic tumor size. The data available from application of the proposed nomogram can be used both intraoperatively and postoperatively, depending on the clinical scenario. Data obtained from this nomo-

TABLE 3
Comparison of Patient Characteristics in Study and Validation Groups
Using Nomogram Variables

Characteristic	Michigan		MDACC	
	No.	%	No.	%
No. of patients	41	100	104	100
LVI				
No	26	63	26	25
Yes	15	37	78	75
Method of detection				
IHC	0	0	3	22
H&E	41	100	54	52
Touch Prep	0	0	27	26
Multicentric				
No	40	98	94	90
Yes	1	2	10	10
Initial lymph node status				
Negative	0	0	66	63
Positive	41	100	38	37
Pathologic tumor size				
Minimum	0	—	0	—
Median	1.2	—	0.7	—
Maximum	11.7	—	9	—
Additional non-SLN metastases				
No	24	59	46	44
Yes	17	41	58	56

Michigan indicates the University of Michigan; MDACC, The University of Texas M. D. Anderson Cancer Center; LVI, lymphovascular invasion; IHC, immunohistochemical analysis; H&E, hematoxylin and eosin staining; Touch Prep, touch preparation cytology; SLN, sentinel lymph node.

gram should be used in conjunction with the clinical context of individual patients to aid in the surgical decision-making process. Physicians can apply the data from this tool when there is a need to risk stratify patients who are treated in the neoadjuvant setting to help determine the potential benefit of a completion axillary dissection.

Over the last several decades, there has been a paradigm shift in the surgical treatment of patients with breast cancer away from maximally invasive procedures to more minimally invasive techniques. Outcomes for these less invasive surgeries largely have been favorable, have produced equal survival, and often have spared patients considerable morbidity. The use of SLNB for staging in patients with clinically lymph node-negative breast cancer is an example of this change in surgical practice. Because many studies have demonstrated that SLNs are the only positive lymph nodes in the majority of patients who undergo surgery first, the need for completion axillary dissection in this patient population has been questioned.

In recent years, neoadjuvant chemotherapy has been used with increasing frequency, and it has been determined that patients who present with biopsy-

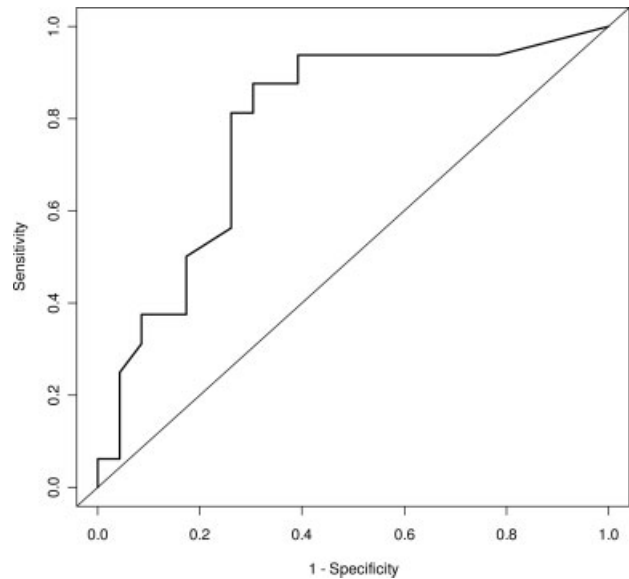


FIGURE 3. Receiver operating characteristic curve for University of Michigan patients. The distribution of study patients is illustrated according to total point scores for both for the training cohort and for the validation cohort.

proven axillary lymph node disease can be converted to a lymph node-negative status with the use of such therapy.^{13,14} Further support for the finding that neoadjuvant chemotherapy can convert patients to lymph node-negative status comes from the National Surgical Adjuvant Breast and Bowel Project B-18 study, in which patients who were assigned randomly to receive neoadjuvant chemotherapy had a lower percentage of positive lymph nodes after treatment than patients who underwent primary surgical therapy.²³ This lymph node conversion facilitated by neoadjuvant treatment is the rationale for attempts to define which patients with a positive SLN after neoadjuvant chemotherapy can forego a completion axillary lymph node dissection.

For patients who undergo surgery first, the incidence of positive non-SLNs in patients with a positive SLN ranges from 34% to 40%.^{24,25} In patients who have documented axillary lymph node involvement at initial evaluation, neoadjuvant chemotherapy results in the eradication of lymph node metastases in 22% to 30% of patients.^{12-14,26} Earlier studies of neoadjuvant chemotherapy that included patients with clinical findings suggestive of axillary lymph node involvement produced a complete axillary lymph node response rate that ranged from 25% to 38%.^{14,27-30} In a previous report by Kuerer et al., 53% of patients who had a negative axilla identified after neoadjuvant chemotherapy by clinical examination and sonography had positive axillary lymph

nodes at pathologic examination.³¹ However, 97% of those patients had only 1 to 3 involved lymph nodes or had small-volume disease (2–5 mm).³¹ These findings suggest that a subset of patients with positive axillary lymph nodes before neoadjuvant chemotherapy will have minimal or no residual axillary disease after they receive neoadjuvant treatment, further supporting investigation of the potential use of SLNB as a definitive procedure in patients who have a complete clinical axillary response.

Lymph node basins are evaluated after chemotherapy, because any residual lymph node disease has been considered a potential source of locoregional and systemic recurrence.³² Several series have demonstrated that, in patients who undergo surgery first and have negative SLNs on SLNB, the axillary failure rate is very low.^{8,33–38} In addition, to date, 5 studies with relatively small patient numbers have demonstrated that patients who undergo surgery first and have a positive SLN on SLNB also have a low recurrence rate after SLNB alone.^{6–10} One additional study subselected patients who had only micrometastases in SLNs and reported that this small patient group was recurrence free after SLNB alone at a median follow-up of 42 months.³⁹ Those studies provide the only information available to date regarding the risk of recurrence in patients with a positive SLN on SLNB who do not undergo completion axillary dissection. It is noteworthy that none of the patients in those studies received neoadjuvant chemotherapy, and most patients had early-stage disease.

Several studies have examined factors that are predictive of lymph node involvement beyond the SLNs in patients who undergo surgery as initial treatment. Factors that have been associated with positive non-SLNs in these patients include SLN metastasis size, primary tumor size, LVI, lack of drainage on lymphoscintigraphy, more than 1 positive SLN, presence of extranodal extension, and number of positive SLNs.^{25,40–53} A meta-analysis performed by Degnim et al. confirmed these findings and demonstrated that macrometastasis, extranodal extension, larger tumor size, more than 1 positive SLN, and LVI were the most important predictors of non-SLN disease in patients who underwent surgery first.⁵⁴ Bedrosian et al. specifically looked at patients with larger primary tumors and observed that the factors predictive of positive non-SLNs included tumor size ≥ 3 cm and macrometastasis, factors similar to those reported for patients with earlier stage disease.⁵⁵ Far fewer studies have examined the likelihood of non-SLN involvement in patients who receive neoadjuvant chemotherapy, because these patients typically have been committed to a completion axillary

dissection regardless of their response to neoadjuvant chemotherapy. Factors predictive of any persistent lymph node involvement in the neoadjuvant setting have included clinical and pathologic response of the primary tumor, tumor grade, estrogen receptor status, size of the primary tumor, and patient age.^{13,14,26,56}

To our knowledge, the current study is the first to define unique clinicopathologic factors for non-SLN involvement in patients who have a positive SLN after neoadjuvant chemotherapy. On the basis of multivariate analysis, the nomogram we developed considers 5 clinicopathologic factors to assess patient risk: LVI, method of SLN metastasis detection, multicentricity, initial lymph node status, and pathologic tumor size. These markers largely are consistent with those reported for patients who undergo surgery first. The method of SLN metastasis detection and initial lymph node status most likely reflect the macrometastatic nature of the SLN tumor burden. The presence of multicentricity and pathologic tumor size likely are reflective of a larger primary tumor. Finally, LVI was a predictor of non-SLN disease in nearly all studies, both in patients who underwent surgery first and in patients who received neoadjuvant chemotherapy, supporting the significance of this biologic marker as a measure of lymph node disease burden.

The Memorial Sloan-Kettering nomogram is being used in clinical practice to facilitate surgical decision making for patients who undergo surgery first and have a positive SLN identified.¹⁶ This nomogram may not be applicable to patients who are treated with neoadjuvant chemotherapy.¹⁶ In fact, a group that is attempting to validate the Memorial Sloan-Kettering nomogram with an external cohort of patients who received neoadjuvant therapy reported an AUC of 0.66, which was not considered sufficient to provide good discrimination for this patient subset.¹⁷ The M. D. Anderson nomogram, in contrast to the Memorial Sloan-Kettering nomogram, was designed specifically to be predictive for patients who receive neoadjuvant chemotherapy. The Memorial Sloan-Kettering nomogram consists of 7 components: nuclear grade, LVI, multifocality, estrogen receptor status, number of positive and negative SLNs, pathologic tumor size, and method of detection of SLN metastasis.¹⁶ Three components from the M. D. Anderson nomogram overlapped with the Memorial Sloan-Kettering nomogram: LVI, pathologic tumor size, and method of detection. In the M. D. Anderson nomogram, multicentricity was a better predictor of additional lymph node involvement than multifocality in both univariate and multivariate analyses. Some of the patients in this study may

have been candidates for surgery first, yet the use of neoadjuvant therapy has increased considerably to include also patients who are striving for improved cosmesis or who prefer to pursue genetic testing during neoadjuvant therapy before making a surgical plan. In light of these more recent changes in patient management, the data obtained from the proposed neoadjuvant nomogram should be contributory, regardless of the primary presenting stage of the patient.

It is interesting to note that initial lymph node status also was a unique component of the M. D. Anderson nomogram. It is standard practice at our institution to perform routine axillary ultrasonography as a component of preoperative staging. Patients are assessed with ultrasonography and FNA biopsy of suspicious axillary lymph nodes during the initial workup and staging of newly diagnosed breast cancer. This procedure, which allows for more definitive clinical staging of patients, is not standard practice at many institutions, which may be an obstacle to widespread use of the proposed neoadjuvant nomogram. However, as the use of neoadjuvant chemotherapy continues to expand, it is likely that more clinicians will implement additional rigorous clinical staging techniques to facilitate the identification of patients who would benefit from neoadjuvant therapy. Therefore, definitive knowledge of initial lymph node status may become more widespread and the proposed nomogram may become more widely applicable in the near future.

The M. D. Anderson nomogram was validated prospectively in a group of patients who received neoadjuvant therapy at the University of Michigan. In this group of patients, the M. D. Anderson model performed well, demonstrating an AUC of 0.78. This finding demonstrates the predictive ability of the M. D. Anderson nomogram for patients who are treated with neoadjuvant therapy in a large academic setting. Most attempts at external validation of the Memorial Sloan-Kettering nomogram have demonstrated good correlation, although not all have been successful.^{17,57-60} These findings underscore the importance of external validation before a proposed nomogram can be applied in general clinical practice. We encourage other groups, both in the community and in academic settings, to test the utility of the M. D. Anderson nomogram further in additional patient populations who are treated with neoadjuvant chemotherapy.

The current study indicates that patients who are treated with neoadjuvant therapy and who have positive SLNs are at high risk for having positive non-SLNs. However, 44% of the patients in the study did

not have non-SLN disease and, thus, underwent an unnecessary completion axillary dissection. Because the morbidity of axillary dissection is often a great concern for patients, the use of this M. D. Anderson nomogram will help to inform both clinicians and patients regarding the potential necessity of axillary dissection in the setting of positive SLNs after neoadjuvant treatment. Although the standard of therapy continues to be a completion axillary dissection in all patients with positive SLNs, the ultimate goal is to individualize therapy such that only patients who will benefit from a treatment will be subjected to the potentially associated morbidity. Clinical trials examining the outcomes of patients with regional lymph node disease who undergo directed surgical resection or observation after neoadjuvant chemotherapy will aid in determining the ultimate utility of SLNB or regional lymphadenectomy as a means for establishing definitive breast cancer prognosis and regional control of disease.

REFERENCES

1. Alex JC, Krag DN. Gamma-probe guided localization of lymph nodes. *Surg Oncol*. 1993;2:137-143.
2. Giuliano AE, Kirgan DM, Guenther JM, Morton DL. Lymphatic mapping and sentinel lymphadenectomy for breast cancer. *Ann Surg*. 1994;220:391-398; discussion 398-401.
3. Krag D, Weaver D, Ashikaga T, et al. The sentinel node in breast cancer—a multicenter validation study. *N Engl J Med*. 1998;339:941-946.
4. Winchester DJ, Sener SF, Winchester DP, et al. Sentinel lymphadenectomy for breast cancer: experience with 180 consecutive patients: efficacy of filtered technetium 99m sulphur colloid with overnight migration time. *J Am Coll Surg*. 1999;188:597-603.
5. Schwartz GF, Giuliano AE, Veronesi U. Proceedings of the consensus conference on the role of sentinel lymph node biopsy in carcinoma of the breast, April 19-22, 2001, Philadelphia, Pennsylvania. *Cancer*. 2002;94:2542-2551.
6. Fant JS, Grant MD, Knox SM, et al. Preliminary outcome analysis in patients with breast cancer and a positive sentinel lymph node who declined axillary dissection. *Ann Surg Oncol*. 2003;10:126-130.
7. Guenther JM, Hansen NM, DiFronzo LA, et al. Axillary dissection is not required for all patients with breast cancer and positive sentinel nodes. *Arch Surg*. 2003;138:52-56.
8. Jeruss JS, Winchester DJ, Sener SF, et al. Axillary recurrence after sentinel node biopsy. *Ann Surg Oncol*. 2005;12:34-40.
9. Naik AM, Fey J, Gemignani M, et al. The risk of axillary relapse after sentinel lymph node biopsy for breast cancer is comparable with that of axillary lymph node dissection: a follow-up study of 4008 procedures. *Ann Surg*. 2004;240:462-468; discussion 468-471.
10. Hwang RF, Gonzalez-Angulo AM, Yi M, et al. Low locoregional failure rates in selected breast cancer patients with tumor-positive sentinel lymph nodes who do not undergo completion axillary dissection. *Cancer*. 2007;110:723-730.

11. Xing Y, Foy M, Cox DD, Kuerer HM, Hunt KK, Cormier JN. Meta-analysis of sentinel lymph node biopsy after preoperative chemotherapy in patients with breast cancer. *Br J Surg*. 2006;93:539–546.
12. Khan A, Sabel MS, Nees A, et al. Comprehensive axillary evaluation in neoadjuvant chemotherapy patients with ultrasonography and sentinel lymph node biopsy. *Ann Surg Oncol*. 2005;12:697–704.
13. Kuerer HM, Sahin AA, Hunt KK, et al. Incidence and impact of documented eradication of breast cancer axillary lymph node metastases before surgery in patients treated with neoadjuvant chemotherapy. *Ann Surg*. 1999;230:72–78.
14. Hennessy BT, Hortobagyi GN, Rouzier R, et al. Outcome after pathologic complete eradication of cytologically proven breast cancer axillary node metastases following primary chemotherapy. *J Clin Oncol*. 2005;23:9304–9311.
15. Hunt KK, Buchholz TA, Hortobagyi GN. Now and later? The sticky question of lymph node management in patients receiving preoperative chemotherapy. *Ann Surg Oncol*. 2005;12:683–685.
16. Van Zee KJ, Manasseh DM, Bevilacqua JL, et al. A nomogram for predicting the likelihood of additional nodal metastases in breast cancer patients with a positive sentinel node biopsy. *Ann Surg Oncol*. 2003;10:1140–1151.
17. Soran A, Evrensel T, Ahrendt G, Kocer B, Johnson R. Use of the breast cancer nomogram to predict non-sentinel nodal positivity in patients having received pre-operative chemotherapy [letter]. *Ann Surg Oncol*. 2007;14:165.
18. Greene FL, Page DL, Fleming ID, et al, editors. *AJCC Cancer Staging Manual*. 6th ed. New York, NY: Springer-Verlag; 2002.
19. Akaike H. A new look at the statistical model identification. *Automatic Control IEEE Trans*. 1974;19:716–723.
20. Team RDC. *R: A Language and Environment for Statistical Computing*. Vienna, Austria: R Foundation for Statistical Computing; 2006.
21. Harrell F. *Design: Design Package*. R Package Version 2.0-12. Nashville, Tenn: Department of Biostatistics, Vanderbilt University; 2005.
22. Sing T, Sander O, Beerenwinkel N, Lengauer T. ROCr: Visualizing classifier performance in R. *Bioinformatics*. 2005;21:3940–3941.
23. Fisher B, Brown A, Mamounas E, et al. Effect of preoperative chemotherapy on local-regional disease in women with operable breast cancer: findings from National Surgical Adjuvant Breast and Bowel Project B-18. *J Clin Oncol*. 1997;15:2483–2493.
24. Voogd AC, Coebergh JW, Repelaer van Driel OJ, et al. The risk of nodal metastases in breast cancer patients with clinically negative lymph nodes: a population-based analysis. *Breast Cancer Res Treat*. 2000;62:63–69.
25. Abdessalam SF, Zervos EE, Prasad M, et al. Predictors of positive axillary lymph nodes after sentinel lymph node biopsy in breast cancer. *Am J Surg*. 2001;182:316–320.
26. Rouzier R, Extra JM, Klijanienko J, et al. Incidence and prognostic significance of complete axillary downstaging after primary chemotherapy in breast cancer patients with T1 to T3 tumors and cytologically proven axillary metastatic lymph nodes. *J Clin Oncol*. 2002;20:1304–1310.
27. McCready DR, Hortobagyi GN, Kau SW, Smith TL, Buzdar AU, Balch CM. The prognostic significance of lymph node metastases after preoperative chemotherapy for locally advanced breast cancer. *Arch Surg*. 1989;124:21–25.
28. Bonadonna G, Veronesi U, Brambilla C, et al. Primary chemotherapy to avoid mastectomy in tumors with diameters of 3 centimeters or more. *J Natl Cancer Inst*. 1990;82:1539–1545.
29. Schwartz GF, Birchansky CA, Komarnicky LT, et al. Induction chemotherapy followed by breast conservation for locally advanced carcinoma of the breast. *Cancer*. 1994;73:362–369.
30. Fisher B, Bryant J, Wolmark N, et al. Effect of preoperative chemotherapy on the outcome of women with operable breast cancer. *J Clin Oncol*. 1998;16:2672–2685.
31. Kuerer HM, Newman LA, Fornage BD, et al. Role of axillary lymph node dissection after tumor downstaging with induction chemotherapy for locally advanced breast cancer. *Ann Surg Oncol*. 1998;5:673–680.
32. Foster RS Jr. The biologic and clinical significance of lymphatic metastases in breast cancer. *Surg Oncol Clin N Am*. 1996;5:79–104.
33. Giuliano AE, Haigh PI, Brennan MB, et al. Prospective observational study of sentinel lymphadenectomy without further axillary dissection in patients with sentinel node-negative breast cancer. *J Clin Oncol*. 2000;18:2553–2559.
34. Chung MA, Steinhoff MM, Cady B. Clinical axillary recurrence in breast cancer patients after a negative sentinel node biopsy. *Am J Surg*. 2002;184:310–314.
35. Janssen CMM, Smidt ML, Bruggink EDM, et al. Axillary recurrences after negative sentinel node biopsy for breast cancer: incidence and clinical significance [abstract]. *Ann Surg Oncol*. 2004;11:S76.
36. Schrenk P, Hatzl-Griesenhofer M, Shamiyeh A, Waynad W. Follow-up of sentinel node negative breast cancer patients without axillary lymph node dissection. *J Surg Oncol*. 2001;77:165–170.
37. Roumen RM, Kuijt GP, Liem IH, van Beek MW. Treatment of 100 patients with sentinel node-negative breast cancer without further axillary dissection. *Br J Surg*. 2001;88:1639–1643.
38. Blanchard DK, Donohue JH, Reynolds C, Grant CS. Relapse and morbidity in patients undergoing sentinel lymph node biopsy alone or with axillary dissection for breast cancer. *Arch Surg*. 2003;138:482–487; discussion 487–488.
39. Langer I, Marti WR, Guller U, et al. Axillary recurrence rate in breast cancer patients with negative sentinel lymph node (SLN) or SLN micrometastases: prospective analysis of 150 patients after SLN biopsy. *Ann Surg*. 2005;241:152–158.
40. Chu KU, Turner RR, Hansen NM, Brennan MB, Bilchik A, Giuliano AE. Do all patients with sentinel node metastasis from breast carcinoma need complete axillary node dissection? *Ann Surg*. 1999;229:536–541.
41. Reynolds C, Mick R, Donohue JH, et al. Sentinel lymph node biopsy with metastasis: can axillary dissection be avoided in some patients with breast cancer? *J Clin Oncol*. 1999;17:1720–1726.
42. Fournier K, Schiller A, Perry RR, Laronga C. Micrometastasis in the sentinel lymph node of breast cancer does not mandate completion axillary dissection. *Ann Surg*. 2004;239:859–863; discussion 863–865.
43. Hwang RE, Krishnamurthy S, Hunt KK, et al. Clinicopathologic factors predicting involvement of nonsentinel axillary nodes in women with breast cancer. *Ann Surg Oncol*. 2003;10:248–254.
44. Shahar KH, Hunt KK, Thames HD, et al. Factors predictive of having 4 or more positive axillary lymph nodes in patients with positive sentinel lymph nodes: implications for selection of radiation fields. *Int J Radiat Oncol Biol Phys*. 2004;59:1074–1079.
45. Rivers AK, Griffith KA, Hunt KK, et al. Clinicopathologic features associated with having 4 or more metastatic axillary nodes in breast cancer patients with a positive sentinel lymph node. *Ann Surg Oncol*. 2006;13:36–44.

46. Goyal A, Douglas-Jones A, Newcombe RG, Mansel RE. Predictors of non-sentinel lymph node metastasis in breast cancer patients. *Eur J Cancer*. 2004;40:1731-1737.
47. Saidi RE, Dudrick PS, Remine SG, Mittal VK. Nonsentinel lymph node status after positive sentinel lymph node biopsy in early breast cancer. *Am Surg*. 2004;70:101-105; discussion 105.
48. Wong SL, Edwards MJ, Chao C, et al. Predicting the status of the nonsentinel axillary nodes: a multicenter study. *Arch Surg*. 2001;136:563-568.
49. Kamath VJ, Giuliano R, Dauway EL, et al. Characteristics of the sentinel lymph node in breast cancer predict further involvement of higher-echelon nodes in the axilla: a study to evaluate the need for complete axillary lymph node dissection. *Arch Surg*. 2001;136:688-692.
50. Weiser MR, Montgomery LL, Susnik B, Tan LK, Borgen PI, Cody HS. Is routine intraoperative frozen-section examination of sentinel lymph nodes in breast cancer worthwhile? *Ann Surg Oncol*. 2000;7:651-655.
51. Katz A, Niemierko A, Gage I, et al. Factors associated with involvement of 4 or more axillary nodes for sentinel lymph node-positive patients. *Int J Radiat Oncol Biol Phys*. 2006;65:40-44.
52. Fan YG, Tan YY, Wu CT, et al. The effect of sentinel node tumor burden on non-sentinel node status and recurrence rates in breast cancer. *Ann Surg Oncol*. 2005;12:705-711.
53. Viale G, Maiorano E, Pruneri G, et al. Predicting the risk for additional axillary metastases in patients with breast carcinoma and positive sentinel lymph node biopsy. *Ann Surg*. 2005;241:319-325.
54. Degnim AC, Griffith KA, Sabel MS, et al. Clinicopathologic features of metastasis in nonsentinel lymph nodes of breast carcinoma patients. *Cancer*. 2003;98:2307-2315.
55. Bedrosian I, Reynolds C, Mick R, et al. Accuracy of sentinel lymph node biopsy in patients with large primary breast tumors. *Cancer*. 2000;88:2540-2545.
56. Lenert JT, Vlastos G, Mirza NQ, et al. Primary tumor response to induction chemotherapy as a predictor of histological status of axillary nodes in operable breast cancer patients. *Ann Surg Oncol*. 1999;6:762-767.
57. Smidt ML, Kuster DM, van der Wilt GJ, Thunnissen FB, Van Zee KJ, Strobbe LJ. Can the Memorial Sloan-Kettering Cancer Center nomogram predict the likelihood of nonsentinel lymph node metastases in breast cancer patients in the Netherlands? *Ann Surg Oncol*. 2005;12:1066-1072.
58. Lambert LA, Ayers GD, Hwang RF, et al. Validation of a breast cancer nomogram for predicting nonsentinel lymph node metastases after a positive sentinel node biopsy. *Ann Surg Oncol*. 2006;13:310-320.
59. Degnim AC, Reynolds C, Pantvaidya G, et al. Nonsentinel node metastasis in breast cancer patients: assessment of an existing and a new predictive nomogram. *Am J Surg*. 2005;190:543-550.
60. Kocsis L, Svebis M, Boross G, et al. Use and limitations of a nomogram predicting the likelihood of non-sentinel node involvement after a positive sentinel node biopsy in breast cancer patients. *Am Surg*. 2004;70:1019-1024.