

Images in Thyroidology*

Section Editor: Yaron Tomer

Metastatic Papillary Thyroid Carcinoma Causing Hand Weakness

Judian Miskulin, Paul G. Gauger, and Norman W. Thompson

A 63-YEAR-OLD-WOMAN had right hand weakness accompanying a right neck mass. Examination revealed a large right thyroid mass, bilateral cervical lymphadenopathy, and weakness of the right intrinsic hand muscles and adductor pollicis. Magnetic resonance imaging (MRI) (Fig. 1) revealed a 6.5-cm thyroid mass (A) and a destructive lesion of C7 and T1 with spinal cord compression (B). Thyroid fine-needle aspiration (FNA) suggested papillary thyroid cancer. Serum

thyroglobulin was 2266 ng/mL. On preoperative angiography, the primary tumor (A) was supplied by the right inferior thyroid artery (Fig. 2) while the spinal metastasis (B) was served by the left supreme intercostal artery which was em-

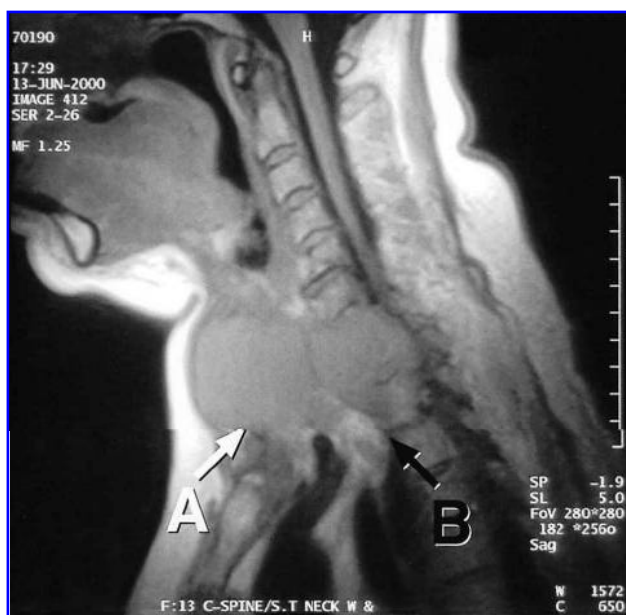


FIG. 1.

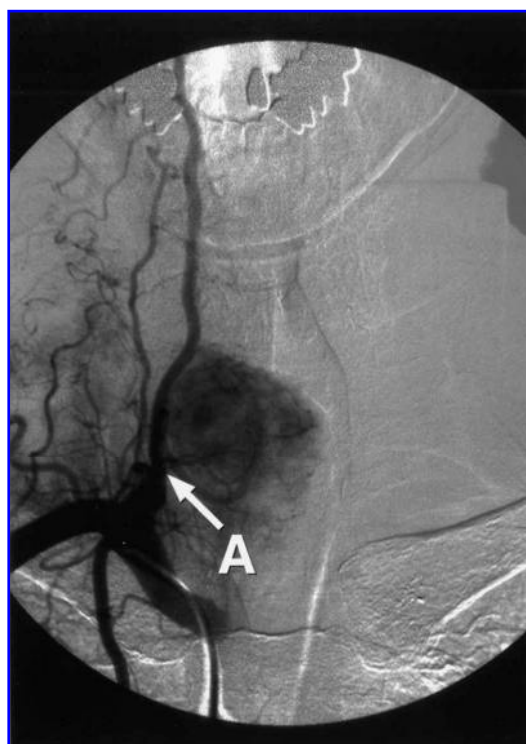


FIG. 2.

*If you would like to submit an image for publication in "Images in Thyroidology" please send two copies of high-quality black-and-white images with a short legend. In special circumstances color figures will be published. Please inquire with the Section Editor for details. All material must be original and neither published nor submitted elsewhere. The legend should give relevant clinical information. The entire legend should be typed double-spaced, and should be no more than 200 words. Send all submissions to Yaron Tomer, M.D., Box 1055, Mount Sinai School of Medicine, One Gustave L. Levy Place, New York, NY 10029; E-mail: Yaron.Tomer@mssm.edu

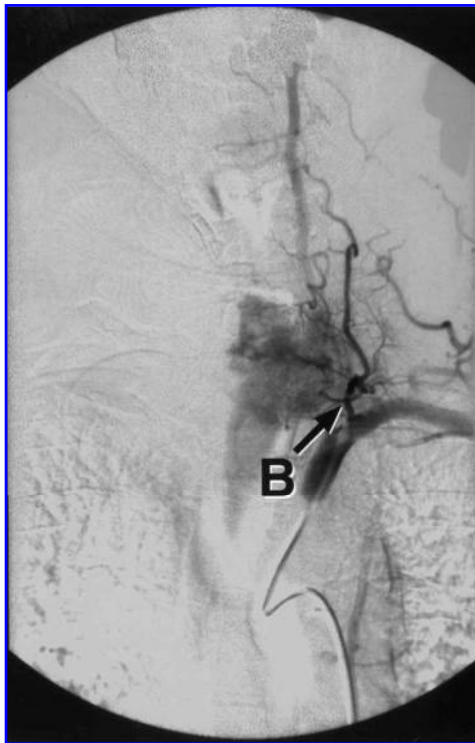


FIG. 3.

bolized to facilitate the operation (Fig. 3). Resection included total thyroidectomy, bilateral lymphadenectomy, limited tracheal resection and C7–T1 corpectomy with anterior cervical spinal fusion. Pathology revealed a papillary cancer with diffuse immunoreactivity for thyroglobulin and occasional insular growth pattern but very low proliferative activity. The spinal metastasis appeared better differentiated than the primary tumor. While hypothyroid, postoperative serum thyroglobulin was 825 ng/mL and a radioiodine scan indicated minimal (2.7% at 24 hours) iodine-avid residual cervical disease. She was treated with 175 mCi of ^{131}I . She has had ongoing improvement in hand function and can now use it effectively for eating and writing.

*Judiann Miskulin, M.D., Paul G. Gauger, M.D.,
Norman W. Thompson, M.D.
Department of Surgery
Division of Endocrine Surgery
University of Michigan
Ann Arbor, MI 48109*

Address correspondence to:
*Paul G. Gauger, M.D.
Division of Endocrine Surgery
University of Michigan
2920H Taubman Center
1500 E. Medical Center Drive
Ann Arbor, MI 48109*

E-mail: pgauger@umich.edu