

---

## CLINICAL REVIEW

David W. Eisele, MD, *Section Editor*

---

# NEUROENDOCRINE NEOPLASMS OF THE LARYNX: AN OVERVIEW

Alfio Ferlito, MD, DLO, DPath, FRCS, FRCSEd, FRCSGlasg, FRCSI, FHKCORL, FDSRCS, FRCPATH, FASCP, IFCAP,<sup>1</sup> Carl E. Silver, MD,<sup>2</sup> Carol R. Bradford, MD,<sup>3</sup> Alessandra Rinaldo, MD, FRCSI<sup>1</sup>

<sup>1</sup>Department of Surgical Sciences, ENT Clinic, University of Udine, Udine, Italy. E-mail: a.ferlito@uniud.it

<sup>2</sup>Departments of Surgery and Otolaryngology–Head and Neck Surgery, Albert Einstein College of Medicine, Montefiore Medical Center, Bronx, New York

<sup>3</sup>Department of Otolaryngology–Head and Neck Surgery, University of Michigan, Ann Arbor, Michigan

*Accepted 24 March 2009*

*Published online 17 June 2009 in Wiley InterScience (www.interscience.wiley.com). DOI: 10.1002/hed.21162*

**Abstract:** Neuroendocrine neoplasms of the larynx are rare but are the most common nonsquamous tumors of this organ. In the past, there has been considerable confusion about the nature and classification of these neoplasms, but the current consensus is that there are 4 different types of laryngeal neuroendocrine tumors composed of paraganglioma, typical carcinoid, atypical carcinoid tumor, and small cell neuroendocrine carcinoma. Carcinoids and small cell neuroendocrine carcinomas are epithelial neoplasms, whereas paragangliomas are of neural origin. Diagnosis is based primarily on light microscopy and confirmed by immunohistochemistry and electron microscopy. Precise diagnosis is essential because the natural history, treatment, and prognosis vary widely for the different neoplastic categories.

Typical carcinoids are very rare and are treated by wide local excision, usually partial laryngectomy, without elective neck dissection. Atypical carcinoid tumors are more common and more aggressive. They are treated by partial or total laryngectomy with elective or therapeutic neck dissection. Adjuvant chemo/radiotherapy may be of benefit in some cases. Small cell neuroendocrine carcinomas are highly aggressive and should be considered disseminated at initial diagnosis. The treatment is by irradiation and chemotherapy as surgery has

proven to be of a little benefit. Paragangliomas are treated by local excision or partial laryngectomy.

It is difficult to determine the valid survival statistics for typical carcinoids because of their rarity and confusion in the literature with their atypical counterparts. They have a greater tendency to metastasize, and thus a worse prognosis than was previously believed. Atypical carcinoid tumors have a 5-year survival rate of approximately 50%, which decreases with time. The prognosis of small cell neuroendocrine carcinoma of the larynx is dismal, with 5-year survival rates of 5%. The biological behavior of laryngeal paraganglioma is generally benign and the prognosis is excellent. © 2009 Wiley Periodicals, Inc. *Head Neck* 31: 1634–1646, 2009

**Keywords:** neuroendocrine neoplasms; larynx; terminology; pathology; treatment; prognosis

### TERMINOLOGY AND CLASSIFICATION

The larynx is the most common site of cancer in the head and neck. However, laryngeal cancer is listed as a “rare disease” by the Office of Rare Diseases of the National Institutes of Health. This means that laryngeal cancer affects fewer to 200,000 people in the United

---

*Correspondence to:* A. Ferlito

© 2009 Wiley Periodicals, Inc.

**Table 1.** Various terms to indicate laryngeal neuroendocrine neoplasms.

Aggressive carcinoid	Moderately differentiated neuroendocrine carcinoma
Anaplastic cell carcinoma	Mucinous carcinoid tumor
Anaplastic small cell carcinoma	Neuroendocrine adenocarcinoma
Apudoma	Neuroendocrine APUD neoplasm
Argentaffinoma	Neuroendocrine carcinoma
Argyrophilic cell carcinoma	Neuroendocrine carcinoma of combined cell type
Atypical carcinoid	Neuroendocrine carcinoma of intermediate-cell type
Atypical carcinoid tumor	Neuroendocrine carcinoma of small-cell type
Atypical endocrine carcinoma	Neuroendocrine carcinoma with exocrine differentiation
Atypical endocrine tumor	Neuroendocrine tumor
Carcinoid	Nonchromaffin paraganglioma
Carcinoid carcinoma	Oat cell carcinoma
Carcinoid tumor	Oncocytic carcinoid
Carcinoma with amine-precursor uptake decarboxylase cell differentiation	Oncocytic carcinoid tumor
Chemodectoma	Oncocytic carcinoma
Combined neuroendocrine carcinoma	Oncocytic neuroendocrine carcinoma
Combined small cell carcinoma, neuroendocrine type	Oncocytoid carcinoid tumor
Composite neuroendocrine carcinoma	Paraganglioma
Composite small cell carcinoma	Pheochromocytoma
Endocrine carcinoma	Poorly differentiated neuroendocrine carcinoma
Endocrinocarcinoma	Reserve cell carcinoma
Endocrinoma	Small cell carcinoma
Glomus tumor	Small cell carcinoma, neuroendocrine type
Grade I neuroendocrine carcinoma	Small cell endocrine carcinoma
Grade II neuroendocrine carcinoma	Small cell neuroendocrine carcinoma
Grade III neuroendocrine carcinoma	Small cell tumor
Kultschitzky cell carcinoma	Small cell undifferentiated carcinoma
Large cell neuroendocrine carcinoma	Spindle-cell carcinoid tumor
Large cell undifferentiated neuroendocrine carcinoma	Typical carcinoid
Malignant carcinoid	Typical carcinoid tumor
Malignant nonchromaffin paraganglioma	Typical endocrine tumor
Malignant paraganglioma	Undifferentiated carcinoma
Mature carcinoid	Undifferentiated small cell carcinoma
Medullary type of neuroendocrine carcinoma	Very well differentiated neuroendocrine carcinoma
Melanotic carcinoid tumor	Well differentiated neuroendocrine carcinoma
Microcytoma	

States.<sup>1</sup> Laryngeal cancer accounts for approximately 2% and 5% of new malignancies worldwide every year, of which 85% to 90% are of the squamous type.<sup>2,3</sup>

Epithelial malignancies with neuroendocrine differentiation can occur in any organ of the body. Laryngeal tumors with neuroendocrine morphology are a distinct, uncommon, heterogeneous group of neoplasms, which share specific morphologic, histochemical, immunohistochemical, and ultrastructural characteristics with prognosis dependent on the tumor type. They have received increasing attention in recent years.<sup>4</sup> The terminology is confusing and controversial and needs standardizing, as a wide variety of names have been used to refer to these neoplasms (Table 1). There is no universal agreement on which terminology should be used for the neuroendocrine neoplasms of the larynx. Table 2 summarizes the most used classifications and the relevant termi-

nology.<sup>5-14</sup> Laryngeal neuroendocrine neoplasms (LNN) are divided into 2 broad categories based on their tissue of origin: epithelial and neural. The epithelial-derived tumors, neuroendocrine carcinomas, are subclassified into 3 subtypes: typical carcinoid (well differentiated neuroendocrine carcinoma, grade I), atypical carcinoid tumor (moderately differentiated neuroendocrine carcinoma, grade II; large cell neuroendocrine carcinoma), and small cell neuroendocrine carcinoma (poorly differentiated neuroendocrine carcinoma, grade III). Small cell neuroendocrine carcinoma includes oat cell, intermediate cell, and combined variants. The oat cell carcinoma is composed of fusiform small cells with sparse cytoplasm, whereas the cells of intermediate type exhibit a more abundant cytoplasm. The combined or composite small cell neuroendocrine carcinoma is a tumor in which there is a definite component of small cell (oat cell or intermediate type)

**Table 2.** Nomenclature for laryngeal neuroendocrine neoplasms.

Classic system	Gould <sup>5</sup>	Woodruff et al <sup>6</sup>	Wenig et al <sup>7</sup>	Ferlito and Friedmann <sup>8</sup>	Shanmugaratnam <sup>9</sup>	Wick <sup>10</sup>	Mills et al <sup>11</sup>	Mills <sup>12</sup>	Barnes <sup>13</sup>	Brandwein-Gensler et al <sup>14</sup>
Carcinoid	Very well differentiated neuroendocrine carcinoma	Typical carcinoid	Well differentiated neuroendocrine carcinoma	Typical carcinoid	Carcinoid tumor (typical carcinoid tumor)	Grade I neuroendocrine carcinoma	Carcinoid	Well differentiated neuroendocrine carcinoma	Typical carcinoid	Well differentiated neuroendocrine carcinoma
Atypical carcinoid	Well differentiated neuroendocrine carcinoma	Large cell neuroendocrine carcinoma	Moderately differentiated neuroendocrine carcinoma	Atypical carcinoid	Atypical carcinoid tumor	Grade II neuroendocrine carcinoma	Moderately differentiated neuroendocrine carcinoma	Moderately differentiated neuroendocrine carcinoma	Atypical carcinoid	Moderately differentiated neuroendocrine carcinoma
Small cell undifferentiated carcinoma	Intermediate/poorly differentiated neuroendocrine carcinoma	Small cell neuroendocrine carcinoma	Poorly differentiated neuroendocrine carcinoma	Small cell neuroendocrine carcinoma	Small cell carcinoma (small cell neuroendocrine carcinoma)	Grade III neuroendocrine carcinoma	Small cell neuroendocrine carcinoma	Poorly differentiated neuroendocrine carcinoma (small cell and large cell subtypes)	Small cell carcinoma, neuroendocrine type	Poorly differentiated neuroendocrine carcinoma
Paraganglioma	Paraganglioma	Paraganglioma	Paraganglioma	Paraganglioma	Paraganglioma	Paraganglioma	Paraganglioma	Paraganglioma	Paraganglioma	Paraganglioma

Reprinted as adapted, with permission from Ferlito et al, *Oral Oncol*, 2006;42:770-778, © Elsevier.

carcinoma together with squamous cell carcinoma and/or adenocarcinoma.<sup>15,16</sup> The term small cell carcinoma, particularly used for lung cancer, is equivocal because not all small cell carcinomas of the larynx show neuroendocrine differentiation.

Some authors consider the large cell neuroendocrine carcinoma of the larynx as a separate entity<sup>14,17,18</sup> using the diagnostic criteria established for pulmonary neuroendocrine tumors.<sup>19</sup> However, in the most recent World Health Organization classification for tumors of the larynx, large cell neuroendocrine carcinoma is classified together with the atypical carcinoid tumor group.<sup>13</sup> In 2008, Wenig<sup>20</sup> includes the large cell neuroendocrine carcinoma in the group of moderately differentiated neuroendocrine carcinoma (or atypical carcinoid tumor). The neural category consists only of paraganglioma.

LNN must be further divided into primary and secondary types, although the latter are extremely rare and only 5 cases of small cell neuroendocrine carcinoma have been reported in the literature.<sup>21</sup> A laryngeal metastasis from a primary small cell neuroendocrine carcinoma of the lung is distinguished from a primary LNN by imaging studies of the lung.<sup>13</sup> However, in rare instances, a primary tumor (with laryngeal metastasis) may be situated in other organs, including the prostate.<sup>22</sup> An aggressive rectal carcinoid metastasizing to the larynx has been reported.<sup>23</sup>

The terms “neuroendocrine neoplasm or neuroendocrine cancer” are suitable for conveying a generic concept but inadequate for diagnosis.<sup>24</sup> Recently, the National Cancer Institute’s Surveillance Epidemiology and End Results database classifies “neuroendocrine tumors”<sup>25</sup> and distinguishes them from “small cell tumors.” This terminology is confusing and inappropriate. The diagnostic term neuroendocrine tumor is too broad to be of practical use. The precise classification of a tumor is not only a subject of academic interest but has important clinical implications for diagnosis, prognosis, and therapy.<sup>26</sup> Table 3 summarizes the spectrum of LNN. They are also subdivided into benign (paraganglioma) and malignant (typical carcinoid, atypical carcinoid tumor, small cell neuroendocrine carcinoma).

LNN have been recognized as the most common nonsquamous types of neoplasms arising in this area. They account for less than 1% of all laryngeal neoplasms. To date, more than 700 cases of LNN have been reported in the litera-

**Table 3.** Spectrum of laryngeal neuroendocrine neoplasms.

Terminology	Synonyms
Typical carcinoid	Well-differentiated neuroendocrine carcinoma, grade I
Atypical carcinoid tumor	Moderately differentiated neuroendocrine carcinoma, grade II; large cell neuroendocrine carcinoma
Small cell neuroendocrine carcinoma	Poorly differentiated neuroendocrine carcinoma, grade III
Combined small cell neuroendocrine carcinoma	Neuroendocrine carcinoma with nonsmall cell component (squamous cell carcinoma, adenocarcinoma, etc.)
Paraganglioma	Nonchromaffin paraganglioma

ture<sup>14,21,25,27</sup> and approximately 500 publications deal with this relatively uncommon yet intriguing family of laryngeal tumors.<sup>25,27–50</sup> The atypical carcinoid tumor is the most frequent of all LNN, followed by the small cell neuroendocrine carcinoma, paraganglioma, and the typical carcinoid.

It is also difficult to determine the exact number of each type of neuroendocrine neoplasm from the publications because of the disparity of diagnostic criteria used. For example, on review, almost all reported cases of malignant paraganglioma were actually cases of atypical carcinoid tumor and many cases of typical carcinoid were also atypical carcinoid tumors.<sup>51–53</sup>

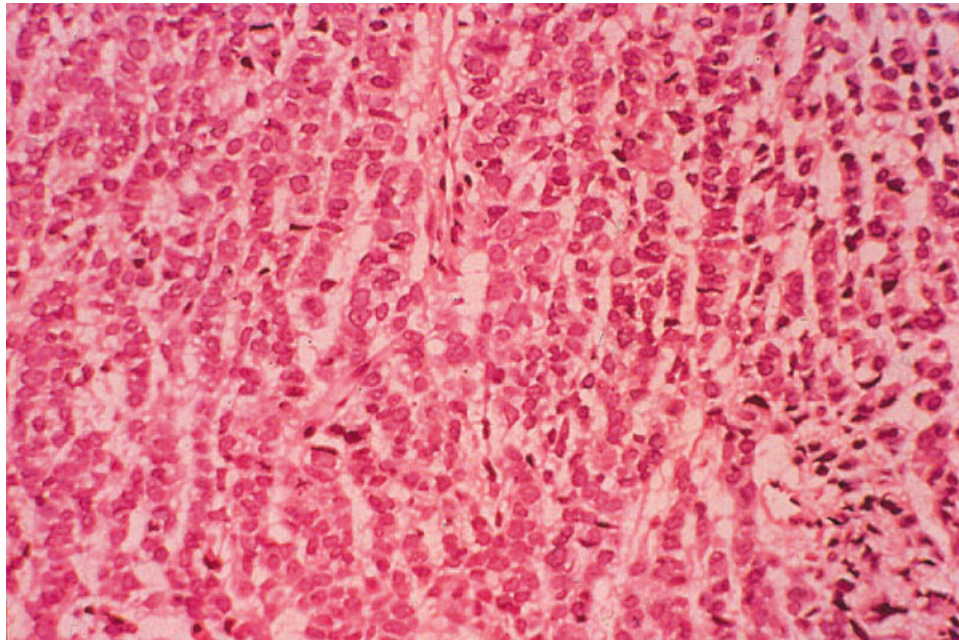
## **PATHOLOGY**

Typical carcinoid (Figure 1), atypical carcinoid tumor (Figure 2), small cell neuroendocrine carcinoma (Figure 3), and paraganglioma (Figure 4) are distinguished from non-neuroendocrine laryngeal neoplasms on light microscopy by their display of neuroendocrine morphology and on immunohistochemistry by reactivity with neuroendocrine markers and ultrastructural evidence of membrane-bound dense-core granules.

### **Typical Carcinoid and Atypical Carcinoid Tumor.**

Grossly, these tumors vary from 0.3 to 4 cm and present as submucosal masses. They may be polypoid, pedunculated, or nodular. Histologically, the tumors display a variety of features. The cells may be arranged in cords, nests, trabeculae, or glandular patterns. The typical carcinoid is composed of uniform and

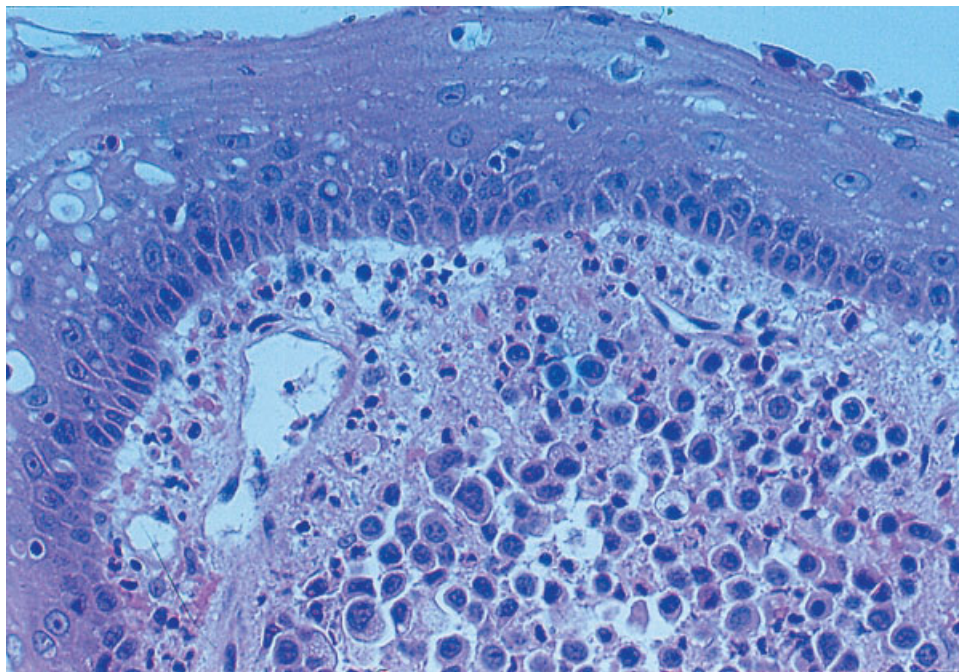




**FIGURE 1.** Typical carcinoid of the larynx of trabecular pattern composed of cuboidal cells with round to ovoid nuclei (hematoxylin-eosin [H&E] stain; original magnification,  $\times 100$ ). [Color figure can be viewed in the online issue, which is available at [www.interscience.wiley.com](http://www.interscience.wiley.com).]

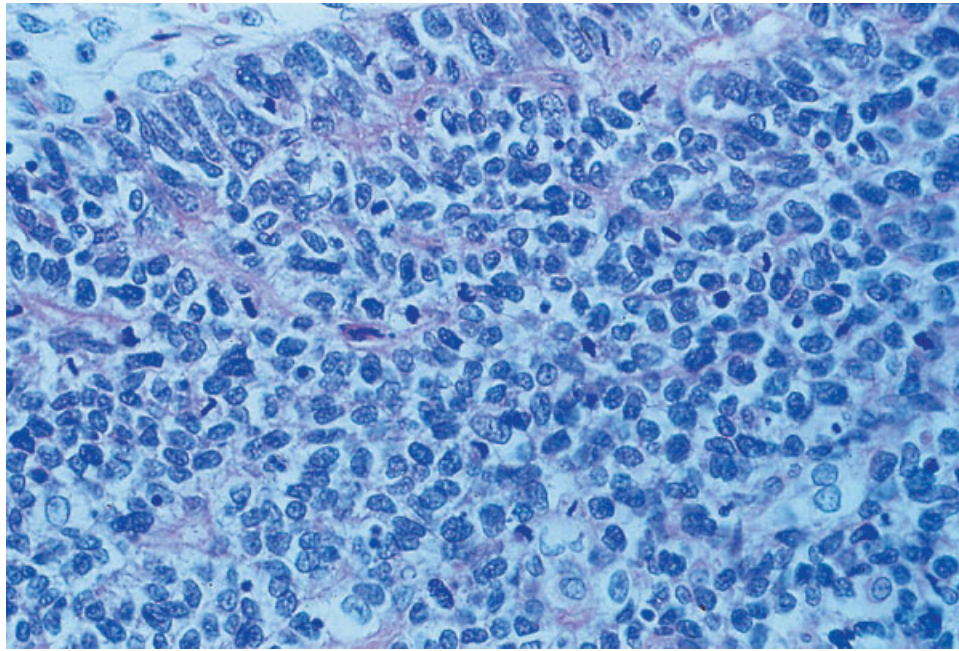
small polygonal cells with regular round or oval centrally placed nuclei and granular eosinophilic cytoplasm. The cells are separated by a fibrovascular or hyalinized stroma. Mitoses, cellular pleomorphism, and necrosis are usually absent in the typical carcinoid. Oncocytic, oncocytoid,

mucinous and amyloid changes, focal “Zellballen,” and rosettes may be seen in typical and atypical carcinoids. In contrast to the typical carcinoid, the neoplastic cells are larger and the nuclei are often vesicular and contain prominent nucleoli in the atypical carcinoid tumor. Typical



**FIGURE 2.** Subepithelial atypical carcinoid tumor of the larynx. This is a characteristic pattern of the lesion (H&E stain, original magnification,  $\times 100$ ). [Color figure can be viewed in the online issue, which is available at [www.interscience.wiley.com](http://www.interscience.wiley.com).]



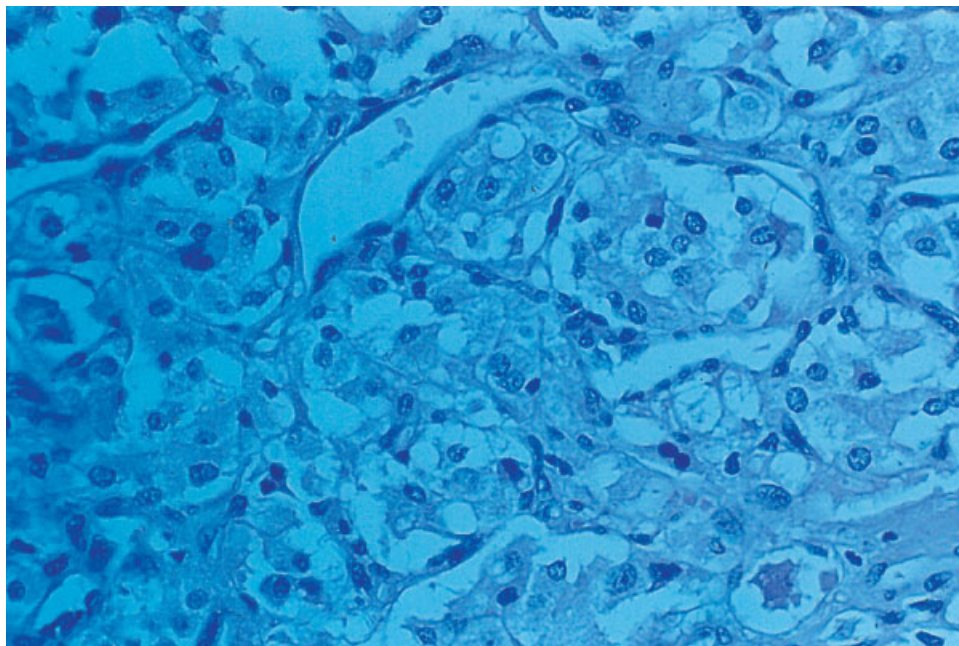


**FIGURE 3.** Small cell neuroendocrine carcinoma of the larynx. The tumor is composed of uniform small cells with hyperchromatic nuclei and scanty cytoplasm (H&E stain, original magnification,  $\times 100$ ). [Color figure can be viewed in the online issue, which is available at [www.interscience.wiley.com](http://www.interscience.wiley.com).]

carcinoid has fewer than 2 mitoses per  $\text{mm}^2$  (10 high-power fields) without necrosis, whereas atypical carcinoid tumor has 2 to 10 mitoses per  $\text{mm}^2$  and/or necrosis.

The tumors are positive for the most sensitive and specific neuroendocrine markers (in

particular for synaptophysin, chromogranin, and CD56), neuropeptide markers (in particular for calcitonin and somatostatin), and almost always for low-molecular-weight cytokeratins as well as other epithelial markers (carcinoembryonic antigen [CEA] and epithelial membrane antigen [EMA]).



**FIGURE 4.** Paraganglioma of the larynx (H&E stain, original magnification,  $\times 100$ ). [Color figure can be viewed in the online issue, which is available at [www.interscience.wiley.com](http://www.interscience.wiley.com).]

**Table 4.** Criteria for the histologic diagnosis of laryngeal neuroendocrine neoplasms.

Typical carcinoid
Subepithelial lesion without ulceration of the mucosa
Trabecular and/or organoid pattern
Glandular and/or squamous differentiation
Oncocytic and oncocytoid changes may be present
Mucinous changes may be present
Stromal amyloid may be present
Squamous nests may be seen
Rosettes may be present
Less than 2 mitoses per 2 mm <sup>2</sup> (10 HPFs)
Sustentacular cells may be present
Focally “Zellballen” pattern may be seen
Fibrovascular or hyalinized connective tissue stroma
Absence of necrosis, mitoses, cytological pleomorphism
Atypical carcinoid tumor
Subepithelial lesion without ulceration of the mucosa
Trabecular and/or organoid pattern
Glandular and/or squamous differentiation
Oncocytic and oncocytoid changes may be present
Mucinous changes may be present
Stromal amyloid may be present
Squamous nests may be present
Rosettes may be present
2 to 10 mitoses per 2 mm <sup>2</sup> (10 HPFs)
Sustentacular cells may be present
Necrosis (often punctuate)
Focally “Zellballen” pattern may be present
Cysts with intracystic papillary like projections of tumor cells may be seen
Large cells with abundant eosinophilic, finely granular cytoplasm with vesicular nuclei and prominent nucleoli
Small cell neuroendocrine carcinoma
Subepithelial lesion with ulceration of the mucosa
Ribbon-like formation
Glandular differentiation rarely seen
Presence of amyloid may be observed
Squamous nests may be present
Rosette pattern
Brisk mitotic activity (11 or greater per 2 mm <sup>2</sup> [10 HPFs])
Azzopardi effect
Prominent crush phenomenon
Small oval to spindle-shaped cells with hyperchromatic granular (or “salt and pepper”) chromatin, scant/absent cytoplasm, absent/inconspicuous nucleoli, nuclear molding, mitoses, apoptosis
Frequent necrosis (often large zones)
Neutropism and angioinvasion is commonly seen
High nuclear to cytoplasmic ratio
In the combined cell type, there is a simultaneous component of squamous cell carcinoma and/or adenocarcinoma.
Paraganglioma
Subepithelial lesion without ulceration of the mucosa
Organoid pattern with aggregation of chief cells in the “Zellballen” pattern characteristic but not pathognomonic of this tumor
Sustentacular cells
Prominent vascular lesion
Mitoses and necrosis are infrequent

**Small Cell Neuroendocrine Carcinoma.** Grossly, the tumors usually arise submucosally and may vary in size from 0.5 cm to a size of 4 to 5 cm. Histologically, the neoplasm can be divided into 3 types. These are oat cell, intermediate, and combined. The oat cell type is composed of sheets of small cell with hyperchromatic nuclei and scant cytoplasm. Occasionally, the cells form interconnecting ribbons. Cell necrosis and mitotic activity are frequent. Rosette formation may be seen. In the intermediate cell type, the growth pattern is similar, but the cells are slightly larger, more polygonal, spindle shaped, or fusiform. The cytoplasm is more prominent than in the oat cell type. In the combined type (the rarest of the 3 types), the tumor is a mixture of small cell neuroendocrine carcinoma with another tumor, usually squamous cell carcinoma or adenocarcinoma.

Small cell neuroendocrine carcinoma may be immunoreactive with cytokeratins, EMA, CEA, and with general neuroendocrine markers, including chromogranin, CD56, CD57, synapthophysin, neuropeptides, including calcitonin, somatostatin, adrenocorticotrophic hormone, bombesin, and serotonin. In addition, small cell neuroendocrine carcinoma may be positive for thyroid transcription factor-1. Table 4 summarizes the criteria for histologic diagnosis of LNN. Table 5 shows the comparison of the immunohistochemical findings of LNN.<sup>7,27</sup>

**Paraganglioma.** Grossly, this tumor has been described as a red or blue submucosal mass of 1 to 6 cm in size. The average tumor is 2 to 3 cm in diameter. On sectioning, it is firm and rubbery with a red or brown cut surface. Areas of hemorrhage may be seen and streaks of fibrous tissue are often identified.

Histologically, the tumor is composed of 2 cell types, chief cells and sustentacular cells. Chief cells are polygonal cells with inconspicuous nuclei and eosinophilic cytoplasm. There is some pleomorphism, but mitoses are not usually seen. These cells are arranged into a characteristic, but not pathognomonic alveolar or “Zellballen” pattern. Around the edge of the “Zellballen” is the second type of cell. These are the slender, spindle-shaped sustentacular cells. This tumor is highly vascular. A dense fibrous capsule can be frequently seen surrounding the tumor. Vascular invasion, perineural involvement, and necrosis are infrequent and do not necessarily indicate aggressive or malignant behavior.<sup>51</sup>

**Table 5.** Comparison of immunocytochemical findings in laryngeal neuroendocrine neoplasms.

Antibody	Typical carcinoid	Atypical carcinoid tumor	Small cell neuroendocrine carcinoma	Paraganglioma
Cytokeratin	+	+	+	–
Epithelial membrane antigen	+	+	+	–
Carcinoembryonic antigen	+	+	+	–
Calcitonin	+	+	+/-	–
Chromogranin	+	+	+	+
Synaptophysin	+	+	+	+
CD57 (Leu 7)	+	+	+	+
CD56	+	+	+	+
Neuron-specific enolase	+	+	+	+
Protein gene product 9.5	+	+	+	+
Galanin	–	–	–	+
Bombesin	+	+	+	–
Somatostatin	+	+	+	+
Serotonin	+	+	+	+
Thyroid transcription factor-1	–	+/-	+/-	–
S-100 protein	–	–*	–	+†
Glial fibrillary acidic protein	–	–	–	+†

Reprinted as adapted, with permission from Ferlito et al, *Oral Oncol*, 2006;42:770–778, © Elsevier.

\*20% positivity in the Wenig et al's series.<sup>7</sup>

†Positivity only in the sustentacular cells.

Immunohistochemically, the chief cells are positive for all the general neuroendocrine markers such as chromogranin, synaptophysin, CD57, and neuropeptide markers, including galanin and somatostatin). They do not stain with epithelial markers (cytokeratin, CEA, EMA) or with calcitonin and bombesin and this supports the diagnosis. Sustentacular cells are stained by antibodies to S-100 protein and glial fibrillary acidic protein. The chief cells are S-100 protein and glial fibrillar acid protein negative.

#### IDENTIFICATION

The first laryngeal neuroendocrine neoplasm of neural type was identified in 1955 by Blanchard and Saunders,<sup>54</sup> whereas only recently laryngeal neuroendocrine carcinomas have been recognized. In particular, the first atypical carcinoid tumor was reported in 1969 by Goldman et al.<sup>55</sup> The identification of LNN is a stepwise process. First, tumors must be recognized as neuroendocrine by the presence of neuroendocrine morphology on conventional light microscopy including organoid nesting, peripheral palisading of tumor nests, trabeculae, glandular differentiation, rosette formation and “crush artifact,” Azzopardi phenomenon, “Zellballen” arrangement, and other histologic features. Once a tumor is considered to be neuroendocrine in consideration of morphologic findings, it

is important to distinguish between typical carcinoid, atypical carcinoid tumor, small cell neuroendocrine carcinoma, and paraganglioma. The diagnosis of neuroendocrine neoplasm requires the presence of both neuroendocrine morphologies by light microscopy and demonstration of neuroendocrine differentiation by immunohistochemistry or electron microscopy. However, the diagnosis of laryngeal small cell neuroendocrine carcinoma is predominately a morphologic diagnosis, as in a limited number of cases this tumor is negative for all neuroendocrine markers. In the lung, the absence of staining for multiple neuroendocrine markers occurs in 10% to 15% of cases.<sup>56</sup> The presence of neurosecretory granules preferentially located in the periphery of the cytoplasm, as observed by electron microscopy, are used to confirm the histologic diagnosis in the absence of a positive immunohistochemical profile for neuroendocrine markers. Distinguishing the type of LNN is largely a morphologic exercise. Immunohistochemistry does not serve as a substitute but as a valid adjuvant in the light evaluation of the morphological criteria of these neoplasms.<sup>57</sup> Tumors of the larynx with neuroendocrine differentiations have widely varying prognosis and response to therapy; thus accurate histologic identification is essential.

LNN can be confused with other neoplasms such as adenocarcinoma not otherwise defined, acinic cell carcinoma, basaloid squamous cell carcinoma, solid type of adenoid cystic carcinoma,



poorly differentiated squamous cell carcinoma, undifferentiated carcinoma, amelanotic malignant melanoma, medullary thyroid carcinoma, lymphoma, hemangiopericytoma, and others.<sup>26</sup>

#### TREATMENT OF NEUROENDOCRINE NEOPLASMS

**Typical Carcinoid.** Surgical excision is the treatment of choice for typical carcinoid of the larynx.<sup>58,59</sup> Conservation surgery, particularly supraglottic subtotal laryngectomy, may be suitable but large tumors require total laryngectomy. Neck dissection is not indicated in view of the usual absence of lymph node metastases.<sup>53</sup> Moreover, irradiation and chemotherapy have been found to be ineffective.<sup>27</sup>

**Atypical Carcinoid Tumor.** The mainstay of treatment for atypical carcinoid tumor of the larynx is surgical excision.<sup>27,58</sup> Partial or total laryngectomy may be performed depending on the site and extent of the primary tumor. As most tumors are supraglottic in location, supraglottic laryngectomy is often the procedure of choice. Endoscopic laser surgery has been employed instead of an external approach for supraglottic atypical carcinoid tumor,<sup>60,61</sup> although 1 tumor, involving the aryepiglottic fold, recurred requiring a second, successful laser resection with wider margins.<sup>61</sup> As perineural extension may exist peripheral to the main tumor mass, wide resection beyond clinically detectable cancer margins is indicated.<sup>62</sup> Neural spread is often discontinuous, and apparently negative margins determined by frozen section may prove positive when permanent sections are obtained.

Elective neck dissection appears to be warranted in view of the high incidence of both early cervical metastasis and subsequent involvement of cervical nodes.<sup>53,63</sup> The dissection of sublevel IIA and level III only is adequate for elective surgical treatment of the neck in supraglottic and glottic tumors.<sup>64</sup> Bilateral selective neck dissection should also be used therapeutically for mobile metastatic disease.

Although earlier literature indicated that radiation and chemotherapy employed preoperatively, postoperatively, or as a primary modality were ineffective in the management of this malignancy,<sup>62,63</sup> Gillenwater et al,<sup>65</sup> in a retrospective review of patients treated at The University of Texas M. D. Anderson Cancer Center, reported that a few patients with atypical carci-

noid tumors responded to these modalities, suggesting that a combined approach may be beneficial, at least for some patients.

**Small Cell Neuroendocrine Carcinoma.** It is generally agreed that surgery alone or in combination with radiation does not improve local tumor control and is not the initial treatment of choice.<sup>58,66,67</sup> Total laryngectomy may control the primary tumor, but the resultant loss of voice is not justifiable in the face of other modalities that may offer primary tumor control.<sup>66</sup> Baugh et al<sup>67</sup> reviewed the various modalities that have been used to treat this cancer. Although radiation alone did not improve survival, it was successful in controlling the tumor at the primary site. Adjuvant chemotherapy appeared to prolong the median survival among patients from 11 to 19 months. The combination of primary radiation therapy and adjuvant chemotherapy resulted in median patient survival of 55 months, representing significantly longer survival than with any other treatment regimen.

The commonly used chemotherapeutic agents are cyclophosphamide, doxorubicin, vincristine, methotrexate, and lomustine. A 9- to 18-month period of treatment is usually suggested.<sup>66,67</sup> Resistance to chemotherapy represents an important indicator of poor prognosis. The recurrence is usually generalized and the results of any therapy are poor. Nevertheless, palliative chemotherapy may be warranted even under these circumstances, as some improvement in the quality and length of life may be achieved.

As the chemotherapeutic agents commonly employed do not penetrate the blood-brain barrier, prophylactic cranial irradiation has been suggested as part of the management of this cancer.<sup>68-70</sup> However, Ferlito and Rinaldo<sup>21</sup> have pointed out that central nervous system metastasis occurs in only 7.7% of patients with laryngeal small cell neuroendocrine carcinoma, and this occurs usually as a preterminal event. Therefore, such elective treatment is not indicated.

The role of surgery in the management of small cell neuroendocrine carcinoma of the larynx is extremely limited. Instances in which partial laryngectomy would likely be adequate to extirpate this aggressive malignancy are extremely uncommon, and most authors feel that such management of even early lesions is best avoided.<sup>21,58</sup>

**Paraganglioma.** Laryngeal paragangliomas are almost invariably benign and should be treated as such. Surgery is preferable to radiation for paragangliomas arising in the larynx as cure can be easily achieved without loss of laryngeal function.<sup>71</sup> Partial laryngectomy remains the mainstay of treatment.<sup>72</sup> Although transoral laser microsurgery has been used successfully in at least 1 reported case,<sup>73</sup> laser surgery is typically not recommended because of the vascular nature of these tumors. Excision of the upper half of the thyroid cartilage is typically employed to expose and achieve complete resection of supraglottic tumors while preserving phonation and deglutition. When possible, an extramucosal excision of tumors arising in the paraglottic and/or supraglottic space is preferred.<sup>58</sup> The generally small size and consistent blood supply of the laryngeal paraganglioma make preoperative angiography and embolization unnecessary. Ligation of the arterial blood supply at the time of surgery will minimize intraoperative blood loss.

A small number of paragangliomas are not supraglottic and may present as transventricular or infraglottic tumors.<sup>42,74-77</sup> These lesions, particularly if large, present a therapeutic challenge, but as they are benign, conservative procedures such as local excision via laryngofissure, with or without cricoid split, are usually performed and often successful.

Most patients require temporary tracheostomy after surgery due to edema and potential for airway compromise. With appropriate clinical suspicion and the use of modern imaging techniques, laryngeal paragangliomas can be routinely diagnosed and treated with the preservation of laryngeal function.<sup>71</sup>

## PROGNOSIS

The clinical course of laryngeal typical carcinoid is not indolent, as was believed in the past, and distant metastases, which involve the liver and cause death, have occurred.<sup>78</sup> Soga et al<sup>79</sup> observed that 33.3% of 42 patients with typical carcinoid of the larynx also developed metastases. Batsakis et al<sup>80</sup> reported distant metastases in 4 of 13 (30.7%) reported cases of typical carcinoid. Wenig and Gnepp<sup>81</sup> reported a case of typical carcinoid of the larynx associated with carcinoid syndrome, which developed subsequently to the appearance of multiple liver me-

tastases. The 5-year survival rate for typical carcinoid of the larynx was 48.7% in a large series as recently reported.<sup>82</sup> The low survival rate is probably due to several cases of atypical carcinoid tumor that had been erroneously classified as typical carcinoid.<sup>27</sup> The clinical behavior of an atypical carcinoid tumor is aggressive and is more aggressive when the metastatic index is high. An unfavorable course is observed when there are lymphatic emboli or when the Ki67 index is higher than 5%.<sup>28</sup> Soga et al<sup>79</sup> described finding metastases in 66.7% of 199 cases of atypical carcinoid tumor of the larynx. Cervical lymph node metastases are often present. Other sites of metastases include bone, skin, subcutaneous tissues, distant lymph nodes, lung, mediastinum, liver, heart, pancreas, diaphragm, peritoneum, gastrointestinal tract, prostate, breast, brain, dura mater, pleura, testicle, and muscle. Death has usually resulted from distant metastases and not from local or regional recurrence. The survival rate is 48% at 5 years and 30% at 10 years.<sup>83</sup> In 2003, Soga<sup>82</sup> reported that the 5-year survival rate for this tumor was 46.7%. In 2007, Ebihara et al<sup>34</sup> collected 33 cases of laryngeal carcinoid (94% atypical carcinoid tumors and 6% typical carcinoids) in Japan. The 3-, 5-, and 10-year survival rates of the patients were 58.5%, 36.5%, and 12.2%, respectively. Thus, the survival rate decreased slowly with the passage of time. Four cases of carcinoid syndrome have been reported in association with atypical carcinoid tumor of the larynx and reportedly all patients died.<sup>84</sup>

The prognosis of small cell neuroendocrine carcinoma of the larynx is very poor,<sup>85</sup> and the clinical course is rapidly fatal. It is the most lethal tumor of the larynx. More than 90% of patients with this tumor develop metastatic disease.<sup>86</sup> The most common sites of metastatic spread of this very aggressive neoplasm are the cervical lymph nodes, liver, lung, bones, and bone marrow. As with small cell lung cancer, small cell neuroendocrine carcinoma of the larynx should be regarded as a systemic disease.<sup>27</sup> In a review by Gnepp et al,<sup>87</sup> 73% of patients with laryngeal small cell neuroendocrine carcinoma died of disease with widespread metastases, with a mean survival time of 9.8 months (range, 1-26 months). The 2- and 5-year survival rates are 16% and 5%, respectively.<sup>86</sup> In 2004, Soga et al<sup>79</sup> reported a 5-year survival rate of 7.7%. These survival rates are similar to

those for small cell lung cancer<sup>85</sup> and did not correlate with the tumor size.<sup>86</sup> This phenomenon has been attributed to the prominent vascular invasion typically present even in small tumors.<sup>87</sup> The prognosis of combined small cell neuroendocrine carcinoma of the larynx is similar to that of a pure small cell neuroendocrine carcinoma.<sup>21</sup> A 2008 publication, using the National Cancer Institute's Surveillance and End Results database, found 5-year survival rates for glottic and supraglottic small cell carcinoma of 15% and 24.1%, respectively.<sup>25</sup> This difference may be due to the diagnostic criteria employed. Different paraneoplastic syndromes, including Schwartz-Bartter, Cushing, and Eaton-Lambert syndromes, have been reported in 5 cases of small cell neuroendocrine carcinoma of the larynx and reportedly all patients died.<sup>84</sup>

The biological behavior of laryngeal paraganglioma is almost exclusively benign. Malignant behavior has been reported in several cases, but critical reviews of the literature have accepted only 1 case of metastatic paraganglioma of the larynx.<sup>51-53,71,88,89</sup> No paraneoplastic syndromes have been reported in association with paraganglioma.<sup>84</sup>

## CONCLUSIONS

LNN constitute a variety of rare neoplasms of the larynx that have had numerous names and classification in the past, but are currently classified as typical carcinoid, atypical carcinoid tumor, small cell neuroendocrine carcinoma, and paraganglioma. It is most important to classify each case correctly as the clinical course, treatment, and prognosis varies greatly according to the diagnosis. Typical carcinoids are more aggressive than previously believed and metastasize in about 1/3 of cases. They are treated by partial or total laryngectomy without neck dissection. Atypical carcinoid tumors metastasize to regional nodes as well as distantly. They are treated surgically by partial or total laryngectomy with elective or therapeutic neck dissection. Small cell neuroendocrine carcinomas are highly aggressive. Treatment is by irradiation and chemotherapy. The survival rates are similar to those for small cell lung cancer. Laryngeal paragangliomas should be treated by local excision or partial laryngectomy. The prognosis is excellent.

## REFERENCES

1. National Institutes of Health. Annual report on the rare diseases and conditions research. Available at: <http://www.rarediseases.info.nih.gov>. Retrieved on March 22, 2007.
2. Ferlito A, Friedmann I. Squamous cell carcinoma. In: Ferlito A, editor. Neoplasms of the larynx. Edinburgh, UK: Churchill Livingstone; 1993. pp 113-133.
3. Ferlito A. Unusual forms of squamous cell carcinoma. In: Ferlito A, editor. Surgical pathology of laryngeal neoplasms. London, UK: Chapman and Hall Medical; 1996. pp 143-171.
4. Ferlito A, Rinaldo A. The spectrum of endocrinocarcinomas of the larynx. *Oral Oncol* 2005;41:878-883.
5. Gould VE. Neuroendocrine tumors in "miscellaneous" primary sites: clinical, pathologic, and histogenetic implications. In: Fenoglio CM, Wolff M, editors. Progress in surgical pathology IV. New York, NY: Masson; 1982. pp 181-198.
6. Woodruff JM, Huvos AG, Erlandson RA, Shah JP, Gerold FP. Neuroendocrine carcinomas of the larynx. A study of two types, one of which mimics thyroid medullary carcinoma. *Am J Surg Pathol* 1985;9:771-790.
7. Wenig BM, Hyams VJ, Heffner DK. Moderately differentiated neuroendocrine carcinomas of the larynx: a clinicopathologic study of 54 cases. *Cancer* 1988;62:2658-2676.
8. Ferlito A, Friedmann I. Review of neuroendocrine carcinomas of the larynx. *Ann Otol Rhinol Laryngol* 1989;98:780-790.
9. Shanmugaratnam K. World Health Organization. International histological classification of tumours. Histological typing of tumours of the upper respiratory tract and ear, 2nd ed. Berlin, Germany: Springer-Verlag; 1991.
10. Wick MR. Immunohistology of neuroendocrine and neuroectodermal tumors. *Semin Diagn Pathol* 2000;17:194-203.
11. Mills SE, Gaffey MJ, Frierson HF Jr. Atlas of tumor pathology: tumors of the upper aerodigestive tract and ear, 3rd series. Washington, DC: Armed Forces Institute of Pathology; 2000.
12. Mills SE. Neuroectodermal neoplasms of the head and neck with emphasis on neuroendocrine carcinomas. *Mod Pathol* 2002;15:264-278.
13. Barnes L. Neuroendocrine tumours. In: Barnes L, Eveson JW, Reichart P, Sidransky D, editors. Pathology and genetics. Head and neck tumours. World Health Organization classification of tumours. Lyon, France: IARC Press; 2005. pp 135-139.
14. Brandwein-Gensler MS, Mahadevia P, Gnepp DR. Laryngeal pathology. In: Fried MP, Ferlito A, editors. The larynx, 3rd ed. San Diego, CA: Plural Publishing; 2009. pp 329-413.
15. Jaiswal VR, Hoang MP. Primary combined squamous and small cell carcinoma of the larynx: a case report and review of the literature. *Arch Pathol Lab Med* 2004;128:1279-1282.
16. Barbeaux A, Duck L, Weynand B, et al. Primary combined small cell carcinoma of the larynx: report of two cases and discussion of treatment modalities. *Eur Arch Otorhinolaryngol* 2006;263:786-790.
17. Serrano MF, El-Mofty SK, Gnepp DR, Lewis JS Jr. Utility of high molecular weight cytokeratins, but not p63, in the differential diagnosis of neuroendocrine and basaloid carcinomas of the head and neck. *Hum Pathol* 2008;39:591-598.
18. Greene L, Brundage W, Cooper K. Large cell neuroendocrine carcinoma of the larynx: a case report and a review of the classification of this neoplasm. *J Clin Pathol* 2005;58:658-661.



19. Travis WD. The concept of pulmonary neuroendocrine tumors. In: Travis WD, Brambilla E, Muller-Hermelink HK, Harris CC, editors. World Health Organization classification of tumours. Pathology and genetics. Tumours of the lung, pleura, thymus and heart. Lyon, France: IARC Press; 2004. pp 19–20.
20. Wenig BM. Neoplasms of the larynx, hypopharynx, and trachea. In: Wenig BM, editor. Atlas of head and neck pathology, 2nd ed. China: Saunders; 2008. pp 439–534.
21. Ferlito A, Rinaldo A. Primary and secondary small cell neuroendocrine carcinoma of the larynx: a review. *Head Neck* 2008;30:518–524.
22. Grignon DJ, Ayala AG, Ro JY, Chong C. Carcinoma of prostate metastasizing to vocal cord. *Urology* 1990;36:85–88.
23. Danikas D, Theodorou SJ, Matthews WE, Rienzo AA. Unusually aggressive rectal carcinoid metastasizing to larynx, pancreas, adrenal glands, and brain. *Am Surg* 2000;66:1179–1180.
24. Ferlito A, Rosai J. Terminology and classification of neuro-endocrine neoplasms of the larynx. *ORL J Otorhinolaryngol Relat Spec* 1991;53:185–187.
25. Lin HW, Bhattacharyya N. Staging and survival analysis for nonsquamous cell carcinoma of the larynx. *Laryngoscope* 2008;118:1003–1013.
26. Milroy CM, Ferlito A. Immunohistochemical markers in the diagnosis of neuroendocrine neoplasms of the head and neck. *Ann Otol Rhinol Laryngol* 1995;104:413–418.
27. Ferlito A, Devaney KO, Rinaldo A. Neuroendocrine neoplasms of the larynx: advances in identification, understanding and management. *Oral Oncol* 2006;42:770–788.
28. Oukabli M, Blechet C, Harket A, Gaillard F, Garand G, Fetissou F. Carcinome atypique de l'aryténoïde: à propos de six observations. *Ann Pathol* 2008;28:2–8.
29. Jumah MD, Fleiner F, Wendt S, Pavel M, Schwabe M, Göktaş O. Poorly differentiated neuroendocrine carcinoma of the larynx: diagnostic features, treatment strategy, and prognosis. *HNO* 2009;57:135–141 (in German).
30. Darantiere S, Romanet P. Carcinomes neuroendocrines du larynx: à propos de 3 cas. *J Fr Otorhinolaryngol* 1999;48:363–367.
31. Soga J. Primary hepatic endocrinomas (carcinoids and variant neoplasms). A statistical evaluation of 126 reported cases. *J Exp Clin Cancer Res* 2002;21:457–468.
32. Capelli M, Bertino G, Morbini P, Villa C, Zorzi S, Benazzo M. Neuroendocrine carcinomas of the upper airways: a small case series with histopathological considerations. *Tumori* 2007;93:499–503.
33. Dhingra M, Agarwal A, Kaushik S, Singh SN. Small-cell neuroendocrine tumor of larynx: a rare presentation. *Indian J Pathol Microbiol* 2008;51:63–64.
34. Ebihara Y, Watanabe K, Fujishiro Y, et al. Carcinoid tumor of the larynx: clinical analysis of 33 cases in Japan. *Acta Otolaryngol Suppl* 2007;559:145–150.
35. Giordano G, Corcione L, Giordano D, D'Adda T, Gnetti L, Ferri T. Primary moderately differentiated neuroendocrine carcinoma (atypical carcinoid) of the larynx: a case report with immunohistochemical and molecular study. *Auris Nasus Larynx* 2009;36:228–231.
36. Lin Z-M, Chang Y-L, Lee C-Y, Wang C-P, Hsiao T-Y. Simultaneous typical carcinoid tumour of the larynx and occult papillary thyroid carcinoma. *J Laryngol Otol* 2008;122:93–96.
37. Lucioni M, Marioni G, Libera DD, et al. Treatment of unusual or rare laryngeal nonsquamous primary malignancies: radical (total/extended total laryngectomy) or conservative surgery? *Am J Otolaryngol* 2008;29:106–112.
38. Papacharalampous GX, Korres S, Tzagaroulakis M, Segas I, Ferekidis E. Paraganglioma of the larynx: a case report. *Med Sci Monit* 2007;13:CS145–CS148.
39. Yamamoto R, Hosokawa S, Yamatodani T, Morita S, Okamura J, Mineta H. Eight cases of neuroendocrine carcinoma of the head and neck Nippon Jibiinkoka Gakkai Kaiho 2008;111:517–522 (in Japanese).
40. Simpson L, Ostlere L, Harland C, Gharaie S. Painful skin metastases from a laryngeal neuroendocrine carcinoma treated with carbon dioxide laser. *Clin Exp Dermatol*, in press.
41. Khalkhali K, Nadimi-Tehrani A, Yazdani N, Azizi A. Tracheal and subglottic paraganglioma, a case report. *Acta Med Iran* 2005;43:377–380.
42. Modlin IM, Shapiro MD, Kidd M. An analysis of rare carcinoid tumors: clarifying these clinical conundrums. *World J Surg* 2005;29:92–101.
43. Seshamani M, Einhorn E, Mirza N. Atypical carcinoid of the larynx and potential complications of the carcinoid syndrome: a case report. *Ear Nose Throat J* 2009;88:E1.
44. Hobson ML, Walker P, Reid C, Braye S. An unusual presentation of laryngeal paraganglioma: the first pediatric case reported in Australia. *Otolaryngol Head Neck Surg* 2008;139:168–169.
45. Garrel R, Raynaud P, Raingard I, et al. An unusual succinate dehydrogenase gene mutation C in a case of laryngeal paraganglioma. *J Laryngol Otol* 2009;123:141–144.
46. Weng CT, Chu PY, Liu MT, Chen MK. Small cell carcinoma of the head and neck: a single institution's experience and review of the literature. *J Otolaryngol Head Neck Surg* 2008;37:788–793.
47. Rubio V, Tamarit JM, Baviera N, et al. Laryngeal paraganglioma: diagnosis and treatment. A propos of a case [in Spanish]. *Acta Otorrinolaringol Esp* 2007;58:333–334.
48. Hatoum GF, Patton B, Takita C, et al. Small cell carcinoma of the head and neck: The University of Miami Experience. *Int J Radiat Oncol Biol Phys* 2009;74:477–481.
49. Chung E-J, Baek S-K, Kwon S-Y, Woo J-S, Jung K-Y. Moderately differentiated neuroendocrine carcinoma of the larynx. *Clin Exp Otorhinolaryngol* 2008;1:217–220.
50. Mani R, Belcadhi M, Chahed H, Ben Abdelkader A, Bouzouita K. Carcinoid tumor of the larynx. *Ann Otolaryngol Chir Cervicofac* 2009;126:71–74 (in French).
51. Barnes L. Paraganglioma of the larynx. A critical review of the literature. *ORL J Otorhinolaryngol Relat Spec* 1991;53:220–234.
52. Ferlito A, Barnes L, Wenig BM. Identification, classification, treatment, and prognosis of laryngeal paraganglioma. Review of the literature and eight new cases. *Ann Otol Rhinol Laryngol* 1994;103:525–536.
53. Ferlito A, Barnes L, Rinaldo A, Gnepp DR, Milroy CM. A review of neuroendocrine neoplasms of the larynx: update on diagnosis and treatment. *J Laryngol Otol* 1998;112:827–834.
54. Blanchard CL, Saunders WH. Chemodectoma of the larynx: case report. *Arch Otolaryngol* 1955;61:472–474.
55. Goldman NC, Hood CI, Singleton GT. Carcinoid of the larynx. *Arch Otolaryngol* 1969;90:91–93.
56. Beasley MB. Immunohistochemistry of pulmonary and pleural neoplasia. *Arch Pathol Lab Med* 2008;132:1062–1072.
57. Ferlito A, Friedmann I. Contribution of immunohistochemistry in the diagnosis of neuroendocrine neoplasms of the larynx. *ORL J Otorhinolaryngol Relat Spec* 1991;53:235–244.
58. Moisa II, Silver CE. Treatment of neuroendocrine neoplasms of the larynx. *ORL J Otorhinolaryngol Relat Spec* 1991;53:259–264.

59. Bapat U, Mackinnon NA, Spencer MG. Carcinoid tumours of the larynx. *Eur Arch Otorhinolaryngol* 2005; 262:194–197.
60. Chang KP, Lee LY, Yeh AR, Dai TS, Hao SP. Endoscopic CO<sub>2</sub> laser surgery for an atypical carcinoid tumor of the epiglottis masquerading as a supraglottic cyst. *Head Neck* 2005;27:1004–1007.
61. Piazza C, Giudice M, Berlucchi M, Peretti G, Antonelli AR. Atypical carcinoid tumour of the larynx treated with CO<sub>2</sub> laser excision: case report. *Acta Otorhinolaryngol Ital* 2003;23:43–46 (in Italian).
62. Mills SE, Johns ME. Atypical carcinoid tumor of the larynx. A light microscopic and ultrastructural study. *Arch Otolaryngol* 1984;110:58–62.
63. Goldman NC, Katibah GM, Medina J. Carcinoid tumors of the larynx. *Ear Nose Throat J* 1985;64:130–134.
64. Ferlito A, Rinaldo A, Silver CE, et al. Neck dissection for laryngeal cancer. *J Am Coll Surg* 2008;207:587–593.
65. Gillenwater A, Lewin J, Roberts D, El-Naggar A. Moderately differentiated neuroendocrine carcinoma (atypical carcinoid) of the larynx: a clinically aggressive tumor. *Laryngoscope* 2005;115:1191–1195.
66. Ferlito A. Diagnosis and treatment of small cell carcinoma of the larynx: a critical review. *Ann Otol Rhinol Laryngol* 1986;95:590–600.
67. Baugh RF, Wolf GT, Beals T, Krause CJ, Forastiere A. Small cell carcinoma of the larynx: results of therapy. *Laryngoscope* 1986;96:1283–1290.
68. Posner MR, Weichselbaum RR, Carrol E, Fabian RL, Miller D, Ervin TJ. Small cell carcinomas of the larynx: results of combined modality treatments. *Laryngoscope* 1983;93:946–948.
69. Vrabec DP, Bartels LJ. Small cell anaplastic carcinoma of the larynx: review of the literature and report of a case. *Laryngoscope* 1980;90:1720–1726.
70. Thompson DH, Kao YH, Klos J, Fay J, Fetter TW. Primary small cell (oat cell) carcinoma of the larynx associated with IgD multiple myeloma. *Laryngoscope* 1982;92: 1239–1244.
71. Myssiorek D, Rinaldo A, Barnes L, Ferlito A. Laryngeal paraganglioma: an updated critical review. *Acta Otolaryngol* 2004;124:995–999.
72. Konowitz PM, Lawson W, Som PM, Urken ML, Breakstone BA, Biller HF. Laryngeal paraganglioma: update on diagnosis and treatment. *Laryngoscope* 1988;98:40–49.
73. Sesterhenn AM, Folz BJ, Lippert BM, Janig U, Werner JA. Laser surgical treatment of laryngeal paraganglioma. *J Laryngol Otol* 2003;117:641–646.
74. Gupta S, Pathak KA, Sanghvi V. Transventricular paraganglioma of the larynx. *Eur Arch Otorhinolaryngol* 2003; 260:358–360.
75. Peterson KL, Fu Y-S, Calcaterra T. Subglottic paraganglioma. *Head Neck* 1997;19:54–56.
76. Sanders KW, Abreo F, Rivera E, Stucker FJ, Nathan C-AO. A diagnostic and therapeutic approach to paragangliomas of the larynx. *Arch Otolaryngol Head Neck Surg* 2001;127:565–569.
77. Maisel R, Schmidt D, Pambuccian S. Subglottic laryngeal paraganglioma. *Laryngoscope* 2003;113:401–405.
78. El-Naggar AK, Batsakis JG. Carcinoid tumor of the larynx. A critical review of the literature. *ORL J Otorhinolaryngol Relat Spec* 1991;53:188–193.
79. Soga J, Ferlito A, Rinaldo A. Endocrinocarcinomas (carcinoids and their variants) of the larynx: a comparative consideration with those of other sites. *Oral Oncol* 2004;40:668–672.
80. Batsakis JG, El-Naggar AK, Luna MA. Neuroendocrine tumors of larynx. *Ann Otol Rhinol Laryngol* 1992;101: 710–714.
81. Wenig BM, Gnepp DR. The spectrum of neuroendocrine carcinoma of the larynx. *Semin Diagn Pathol* 1989;6: 329–350.
82. Soga J. Carcinoids and their variant endocrinomas. An analysis of 11842 reported cases. *J Exp Clin Cancer Res* 2003;22:517–530.
83. Woodruff JM, Senie RT. Atypical carcinoid tumor of the larynx. A critical review of the literature. *ORL J Otorhinolaryngol Relat Spec* 1991;53:194–209.
84. Ferlito A, Rinaldo A. Paraneoplastic syndromes in patients with cancer of the larynx and hypopharynx. *Ann Otol Rhinol Laryngol* 2007;116:502–513.
85. Ferlito A, Rinaldo A. Small cell neuroendocrine carcinoma of the larynx: a preventable and frustrating disease with a highly aggressive lethal behavior. *ORL J Otorhinolaryngol Relat Spec* 2003;65:131–133; Editorial.
86. Gnepp DR. Small cell neuroendocrine carcinoma of the larynx. A critical review of the literature. *ORL J Otorhinolaryngol Relat Spec* 1991;53:210–219.
87. Gnepp DR, Ferlito A, Hyams V. Primary anaplastic small cell (oat cell) carcinoma of the larynx. Review of the literature and report of 18 cases. *Cancer* 1983; 51:1731–1745.
88. Ferlito A, Milroy CM, Wenig BM, Barnes L, Silver CE. Laryngeal paraganglioma versus atypical carcinoid tumor. *Ann Otol Rhinol Laryngol* 1995;104:78–83.
89. Rinaldo A, Ferlito A, Myssiorek D, Devaney KO. Which paragangliomas of the head and neck have a higher rate of malignancy? *Oral Oncol* 2004;40:458–460.