

Unless otherwise noted, the content of this course material is licensed under a Creative Commons Attribution - Non-Commercial - Share Alike 3.0 License.

Copyright 2008, Dr. Jeff Shotwell.

The following information is intended to inform and educate and is not a tool for self-diagnosis or a replacement for medical evaluation, advice, diagnosis or treatment by a healthcare professional. You should speak to your physician or make an appointment to be seen if you have questions or concerns about this information or your medical condition. You assume all responsibility for use and potential liability associated with any use of the material.

Material contains copyrighted content, used in accordance with U.S. law. Copyright holders of content included in this material should contact [open.michigan@umich.edu](mailto:open.michigan@umich.edu) with any questions, corrections, or clarifications regarding the use of content. The Regents of the University of Michigan do not license the use of third party content posted to this site unless such a license is specifically granted in connection with particular content objects. Users of content are responsible for their compliance with applicable law. See <http://www.dent.umich.edu/license/> for more information.

Mention of specific products in this recording solely represents the opinion of the speaker and does not represent an endorsement by the University of Michigan.

Viewer discretion advised: Material may contain medical images that may be disturbing to some viewers.

# Attachments And Their Use In Removable Partial Denture Fabrication

Dr. Jeff Shotwell

## What is an attachment?

An attachment is a connector consisting of two or more components. One component is connected to a tooth, tooth root, or an implant and the other component is connected to a prosthesis.

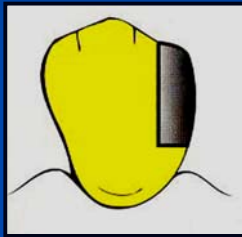
This component of the attachment is typically incorporated in the crown of a tooth. To do this, the tooth needs to be restored with a full or partial coverage crown either all gold or a porcelain fused to metal.



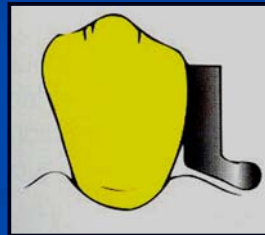
This component is typically incorporated in the prosthesis. For our discussion, this would be a removable partial denture.

Source: Jeff Shotwell, University of Michigan, 2008

## Types of Attachments

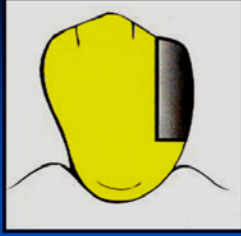

Intracoronal Attachment



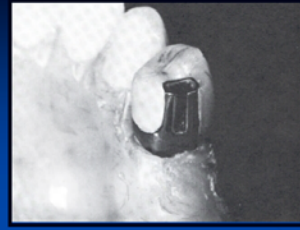Extracoronal Attachment

Source: Peter E. Staubli, MDT, CDT . Attachments & Implants Reference Manual, 6th Ed. Implant Dentistry. 7(4):377, 1998.



Source: Attachments and Implants reference manual 6th edition

## Intracoronary Attachment



Source: Removable Partial Denture Design by Krol et al. Fourth Edition

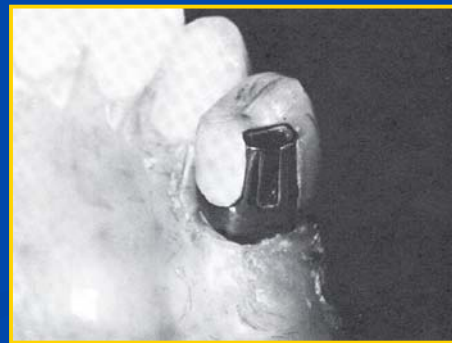Intracoronary attachments are incorporated entirely within the contour of the crown. The advantage of an intracoronary attachment is that the occlusal forces exerted upon the abutment tooth are applied close to the long axis of the tooth. A disadvantage arises when the abutment is overcontoured by placing the "intracoronary attachment" outside the crown contour. This often results from insufficient tooth reduction. If it is not possible to create a box preparation that will totally incorporate the female element, then an extracoronary attachment should be considered. These attachments are non resilient. When limited space exists, a milled lingual surface should be provided on the crown. Most wear occurs on these attachments during placement and placement.

## Intracoronary Attachments

An intracoronary attachment is one which is contained within the normal contours of the crown portion of a natural tooth. The placement of the attachment requires that the abutment tooth be restored with a full or partial coverage (3/4) crown.

---

As seen in the image on the right, the intracoronary attachment has been incorporated on the distal surface of the PFM crown on tooth #28



Source: Removable Partial Denture Design by Krol et al. Fourth Edition

**apm-sterngold**  
PRECISION ATTACHMENT  
MINI G/A  
.085  
W/TF

Intracoronal attachment as supplied with a dime for size comparison. The images at the right show the components of the attachment and an end on view to see the retentive cross section.

Source: Jeff Shotwell, University of Michigan, 2008

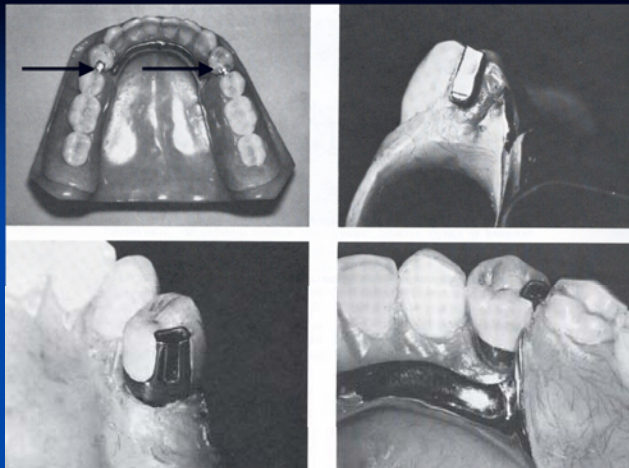
Male portion of the attachment on the partial denture

Female portion of the attachment incorporated in the crown

Partial denture in place with the attachment serving the function of the occlusal rest, and the clasp components

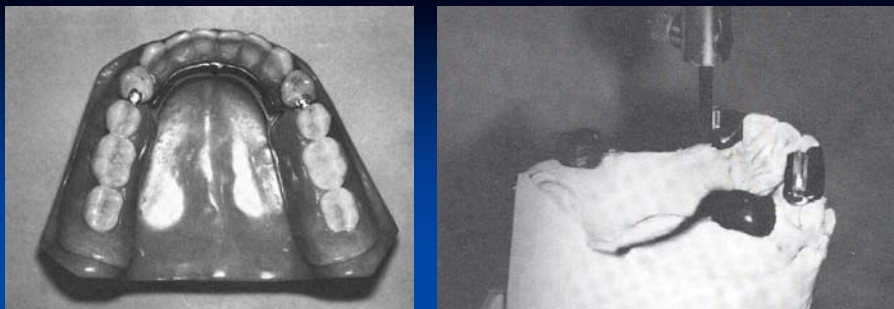
The components can be seen here close up.

Source: Removable Partial Denture Design by Krol et al. Fourth Edition



- Components for intracoronal precision attachment removable partial denture.
- A. Occlusal view of PARPD (note position of attachments)
  - B. Male portion of attachment which is integral with the partial denture.
  - C. The view of the PFM crown with the intracoronal attachment in place.
  - D. Lingual close up of the attachment retained RPD in place.

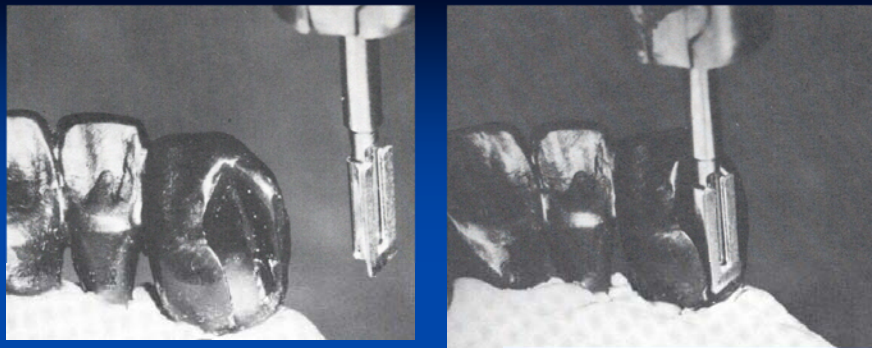
Source: Removable Partial Denture Design by Krol et al Fourth Edition



The attachments obviously have to “draw”, that is they require a common path of insertion. A surveyor is used with a mandrel to place the attachments in the wax patterns of the crowns with a common path of insertion.

Source: Removable Partial Denture Design by Krol et al Fourth Edition





With the crown waxed up for labial contour, occlusion and proximal contact, the working cast is placed on the surveyor table. The surveyor table is adjusted for the path of insertion and the attachment carried to place in the pattern on a mandrel which is specific to the type of attachment being used. Wax is flowed around the attachment in the image on the left securing it in the pattern for casting in the appropriate alloy.

Source: Removable Partial Denture Design by Krol et al. Fourth Edition




Source: Removable Partial Denture Design by Krol et al. Fourth Edition



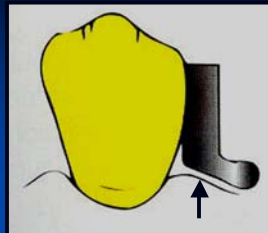
A lug must be fabricated which is cast to the male portion of the attachment. The lug allows the male portion of the attachment to be affixed to the partial denture framework.

Source : Jeff Shotwell, University of Michigan, 2008

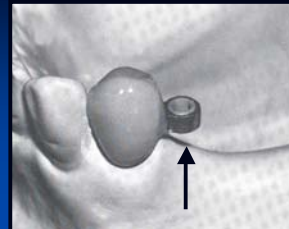


Source: Removable Partial Denture Design by Krol et al. Fourth Edition

The male portion of the attachment is seen in place with the crown on the left and on the right you can see the crown attachment complex related to the partial denture framework. Self cure acrylic will be flowed around the lug securing it to the framework. The area that the acrylic will be placed in indicated within the circle.



### Extracoronal Attachment



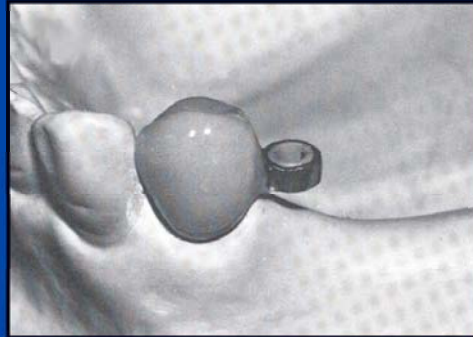
Source : Jeff Shotwell, University of Michigan, 2008

Extracoronal attachments are positioned entirely outside the crown contour of the tooth. The advantages of this type of attachment are that the normal tooth contour can be maintained, minimal tooth reduction is necessary and the possibility of devitalizing the tooth is reduced. Also, the path of insertion is easier for patients with limited dexterity. It is more difficult to maintain hygiene with extracoronal attachments and patients need to be instructed on the use of hygiene accessories such as proxi brushes etc. Keeping the underside of the attachment area clean, greatly improves the tissue response in the area indicated by the arrows.

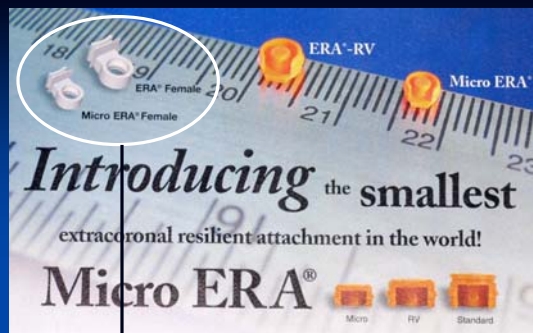## Extracoronary Attachments

An extracoronary attachment extends outside the normal contours of the crown of an abutment tooth. It is still necessary to place a restoration on the abutment tooth.

Here you can see an extracoronary attachment incorporated in the crown on tooth #21.

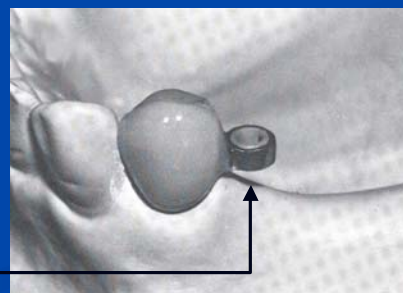


Source: Removable Partial Denture Design by Krol et al Fourth Edition



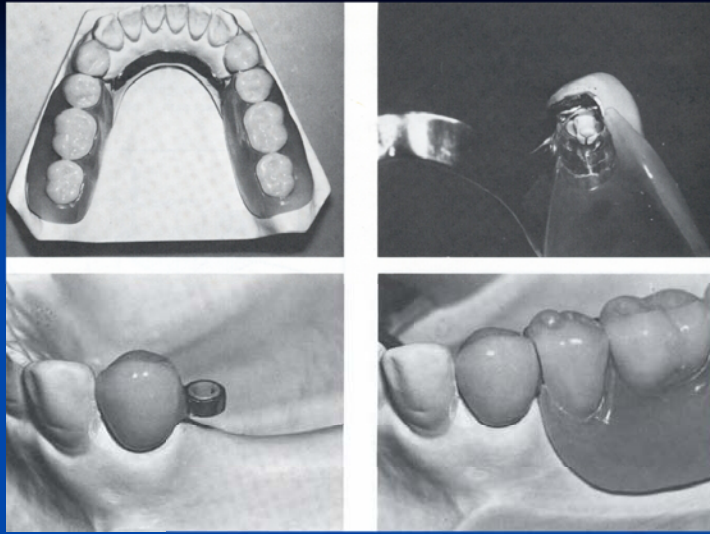
The image on the left is an advertisement from a journal for an extracoronary attachment.

The image below shows the use of the attachment in the fabrication of the abutment crown.



Source: Removable Partial Denture Design by Krol et al Fourth Edition

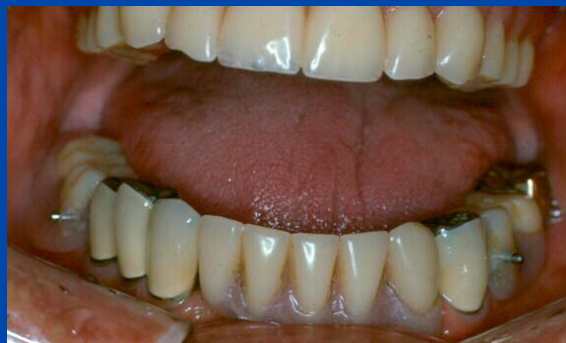
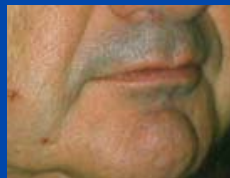


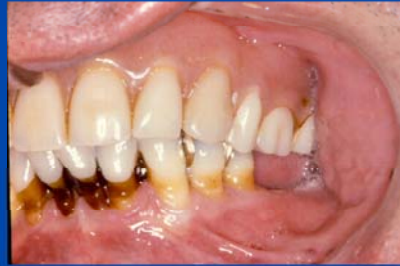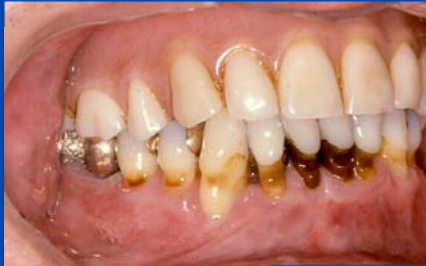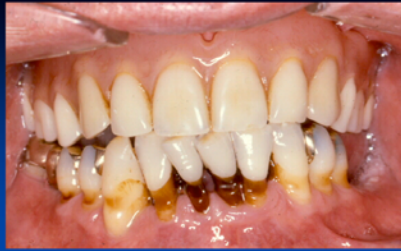This group of images shows the extracoronally attached components and the esthetics of the removable partial denture when viewed from the buccal aspect.

Source: Removable Partial Denture Design by Krol et al. Fourth Edition

## Clinical case for combination case utilizing a maxillary complete denture and a mandibular precision attachment removable partial denture (PARPD)

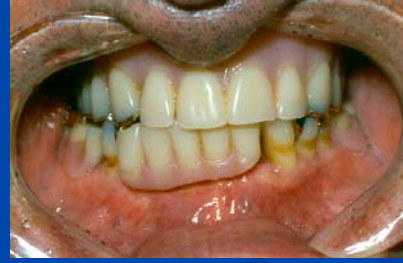
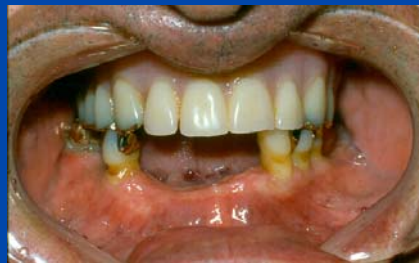
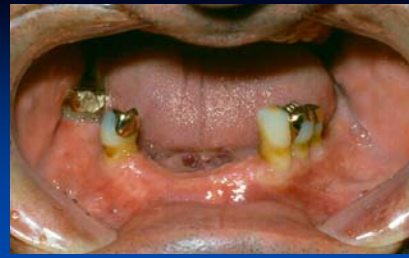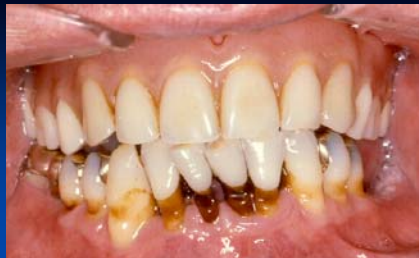Source: Jeff Shotwell, University of Michigan, 2008



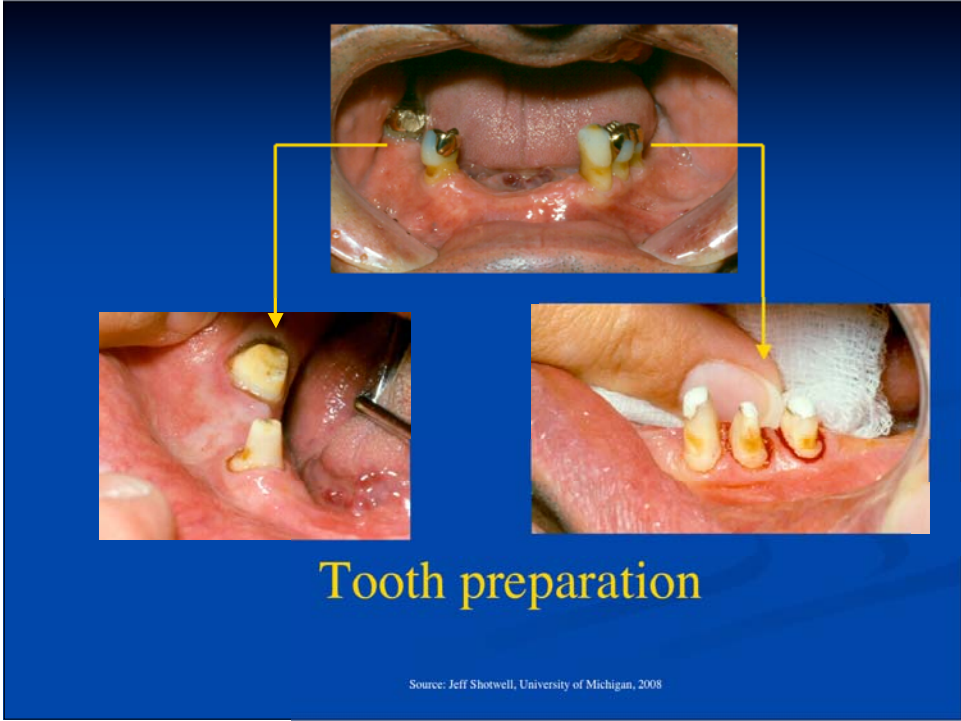Patient's oral condition with the previous complete denture and periodontal involvement of several lower teeth. First step, interim lower removable partial denture.

Source: Jeff Shotwell, University of Michigan, 2008

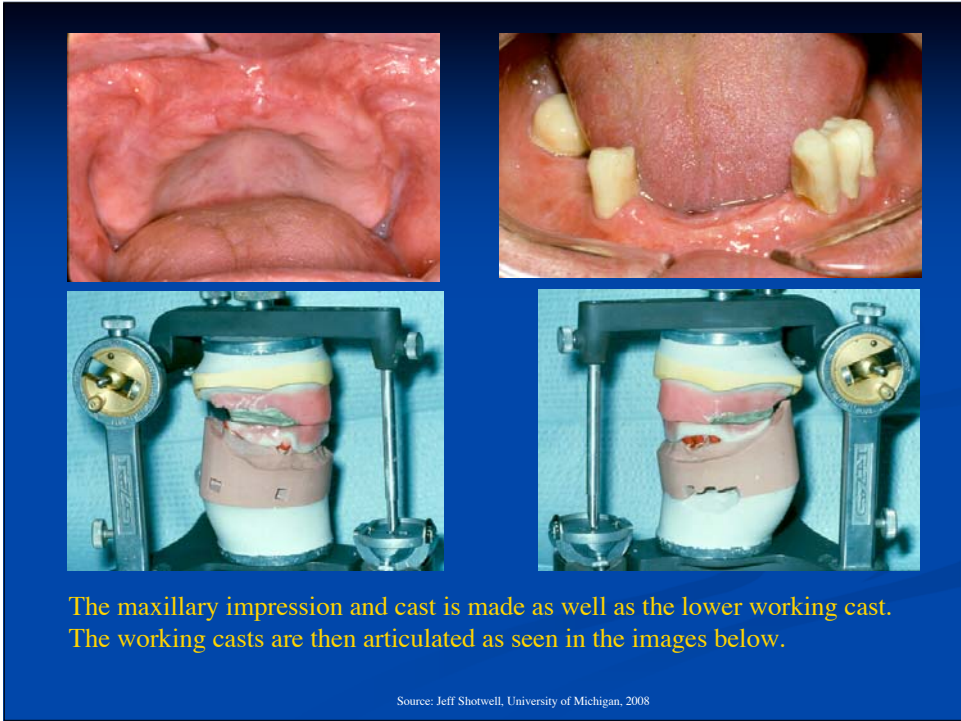


The teeth are extracted, an immediate insertion temporary lower removable appliance placed, and healing allowed. The lack of fit seen on lower right anterior is due to tissue change during healing.

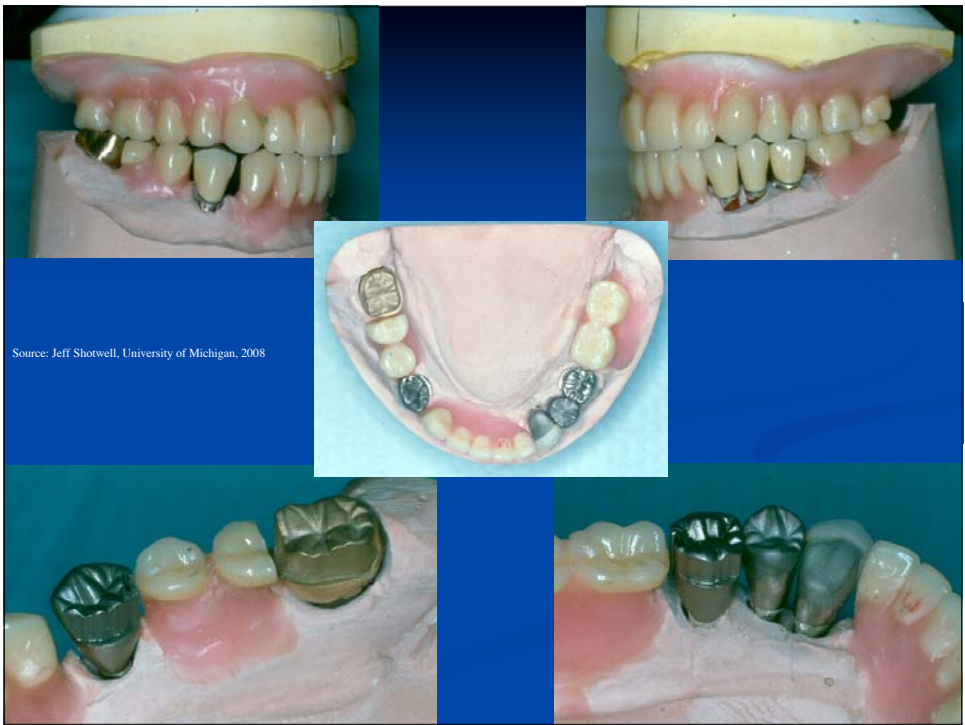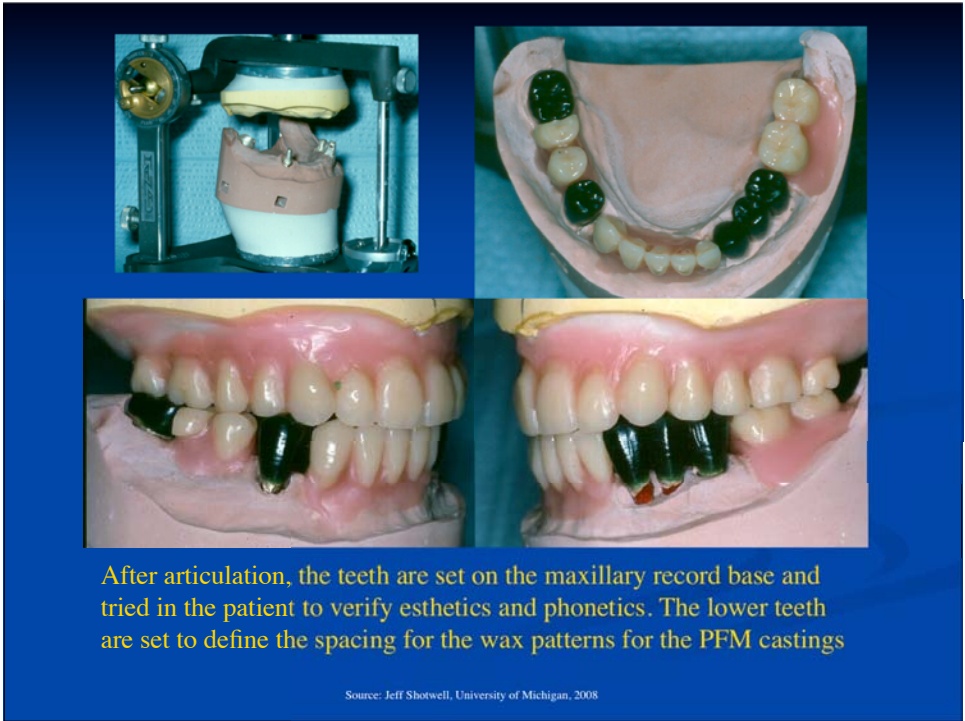
Source: Jeff Shotwell, University of Michigan, 2008

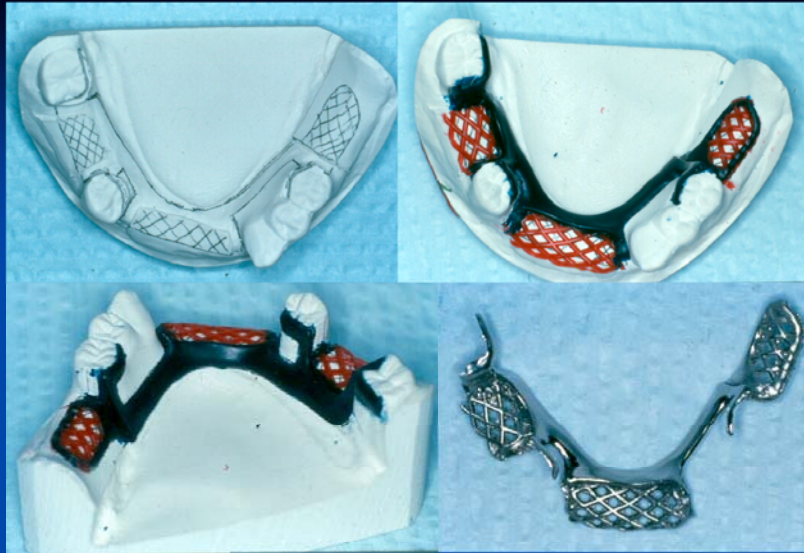


# Tooth preparation



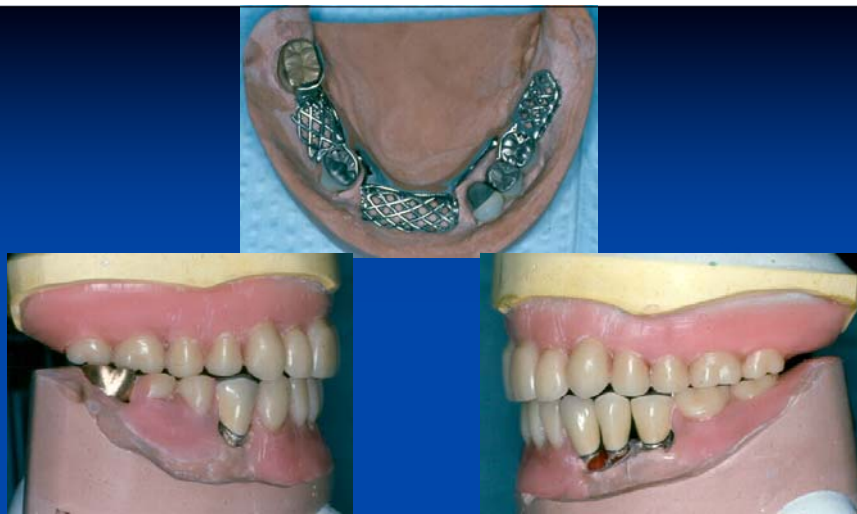





Stages of framework construction from duplicated master cast, through wax pattern, and finally casting in cobalt, chrome alloy. Note lingual reciprocal arms on casting to relate the framework to PFM crown castings

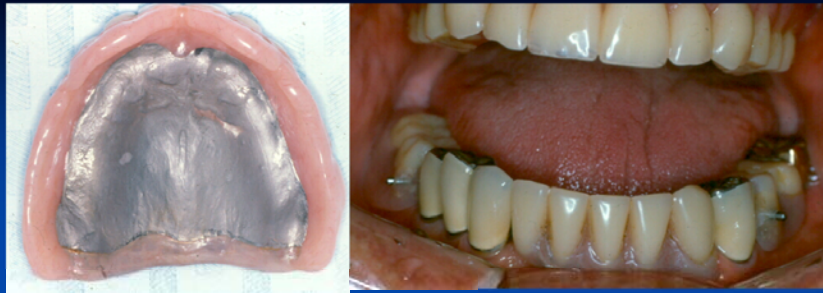
Source: Jeff Shotwell, University of Michigan, 2008



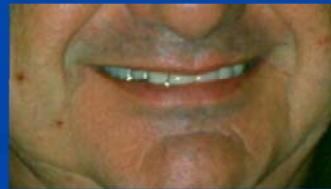Framework related to crowns, attachments can now be related to the framework, teeth set and the teeth set and final wax up for processing.

Source: Jeff Shotwell, University of Michigan, 2008

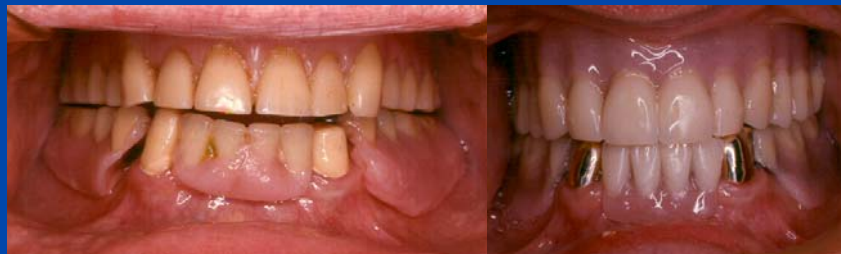
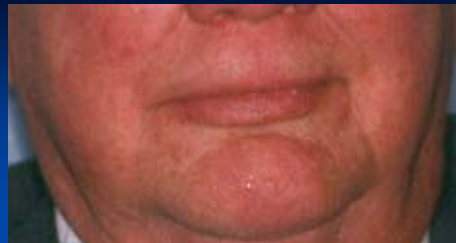


Completed case in place and patient. Note small removal “studs” placed on removable partial denture to aid in the removal of the lower appliance.

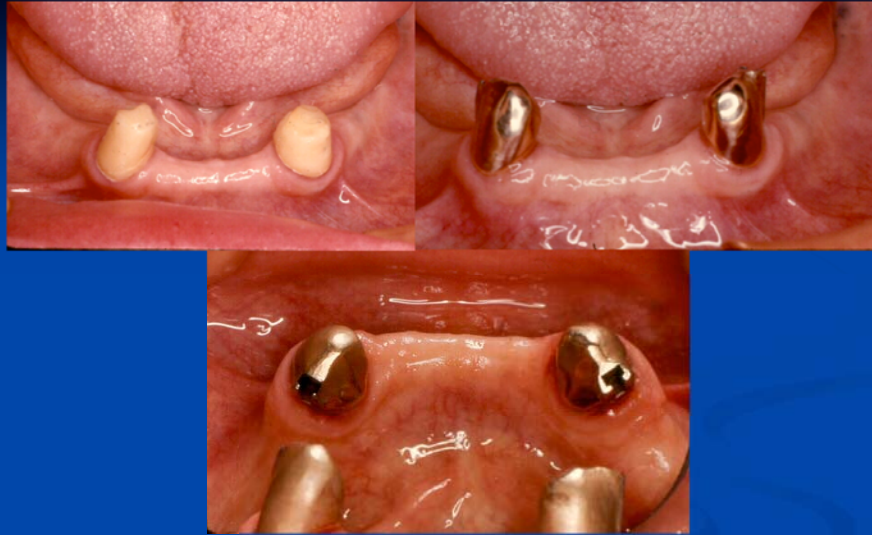


Source: Jeff Shotwell, University of Michigan, 2008



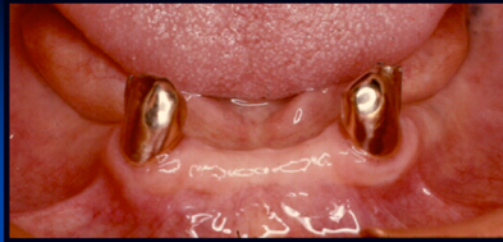Another case using just two lower cuspid teeth for abutments.

Source: Jeff Shotwell, University of Michigan, 2008



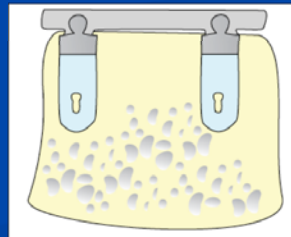
Images showing alignment of female portion of attachments in the all gold crowns on the lower cuspid teeth

Source: Jeff Shotwell, University of Michigan, 2008



Source: Jeff Shotwell, University of Michigan, 2008

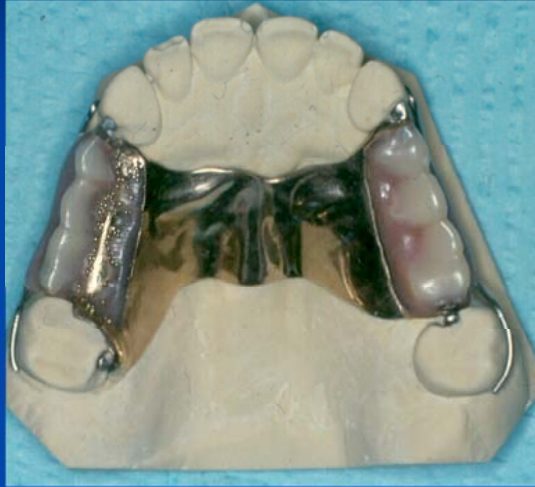With two teeth remaining, the choice may be made to use a bar type attachment rather than the intracoronal attachments seen at the upper right. For the edentulous patient two implants may be placed and a bar fabricated to retain the lower complete denture.



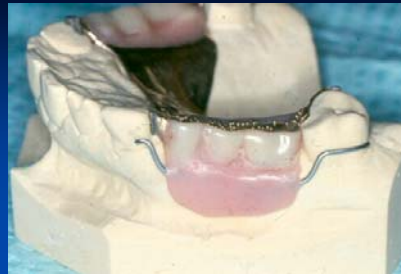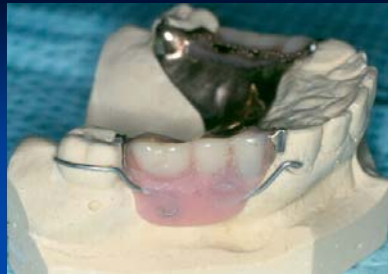Source: University of Michigan School of Dentistry, 2008

## Maintenance Issues for PARPDs

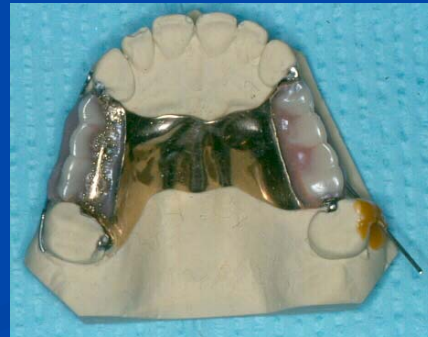Over time, the attachments wear. How to make a worn attachment PARPD again serviceable for the patient. In this case even making the appliance over was a problem as the abutment teeth were very short. The components had worn with time from insertion and removal. The solution used here was the addition of clasps.



Source: Jeff Shotwell, University of Michigan, 2008

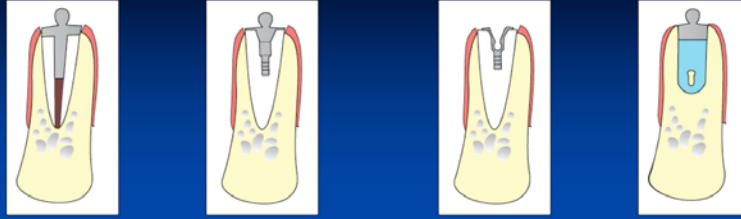


The stainless steel wire is adapted to the buccal surface of the abutment teeth. As seen in the image at the lower right the wire is first embedded in the acrylic flange and then adapted to the teeth. For this patient, this treatment offered the most acceptable solution to the problem of looseness of the maxillary PARPD.



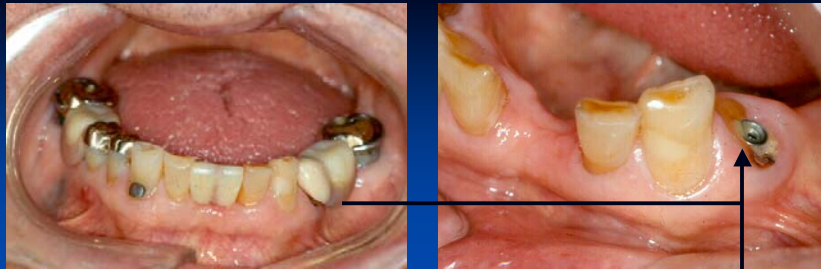
Source: Jeff Shotwell, University of Michigan, 2008

## Radicular and Intraradicular Stud Type Attachments

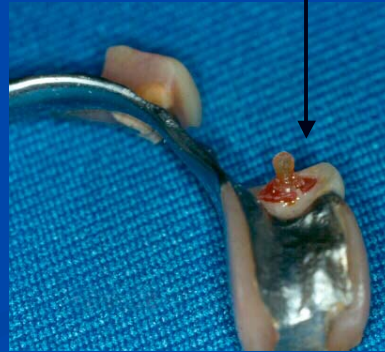


Radicular and intraradicular stud type attachments are connected to a root preparation. The female or male is soldered or cast to a root cap coping as seen in the image top left. Some stud type attachments are directly cemented to the prepared root without requiring a cast coping. Stud type attachments may promote improved or easier oral hygiene and enhance the crown-root ratio due to the low profile. The image at the right shows such an attachment utilized with an implant.

Source: University of Michigan School of Dentistry, 2008



These images demonstrate the use of an intraradicular attachment to repair a lower removable partial denture which still has a usable tooth root from a former abutment. The decision was made not to rebuild a post core and crown to fit the pre-existing lower removable partial denture.



Source: Jeff Shotwell, University of Michigan, 2008



The use of a post and coping as a retainer for a removable RPD

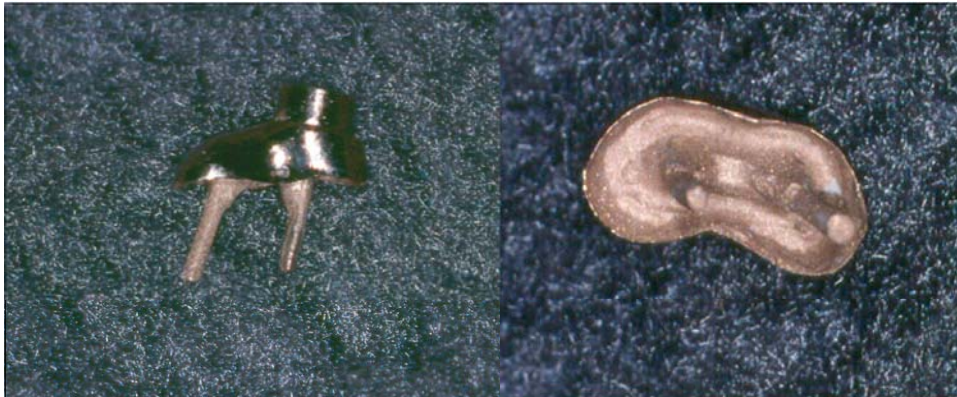Source: Jeff Shotwell, University of Michigan, 2008

Choices for the above tooth since it was treated endodontically.  
 Post and core followed by a crown to fit an existing RPD.  
 Post and coping with a retentive element.

Maxillary bicuspid present challenges with preparation due to the shape of the root of the tooth and the concavities that exist mesially and distally.

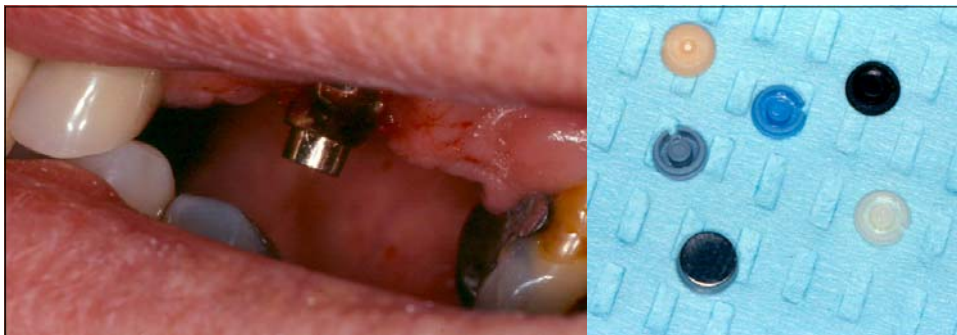Source: Jeff Shotwell, University of Michigan, 2008



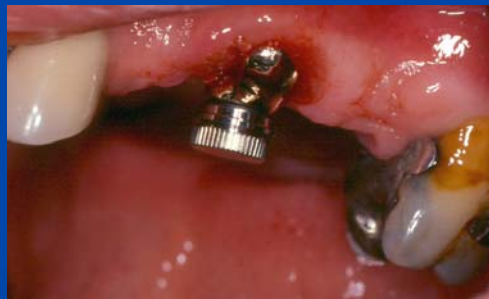

In this case, it was possible to use both canals for posts due to the minimal divergence of the canals. Often times we must choose one canal. Note also that the retentive anchor is kept as low as possible and as lingually placed as possible to allow the setting of a tooth on the RPD later.

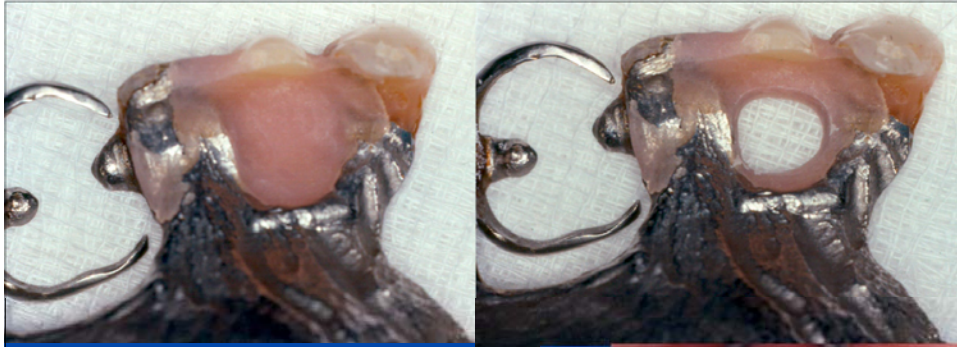Source: Jeff Shotwell, University of Michigan, 2008



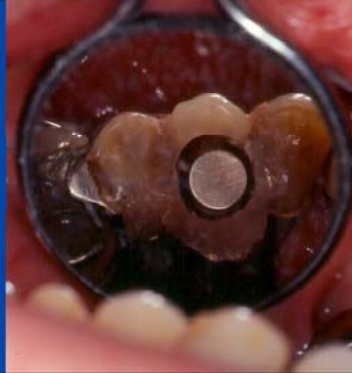The vertical height of the coping and attachment combination is a potential problem if not taken into account. Leave room to set the denture tooth both buccally and occlusally!!



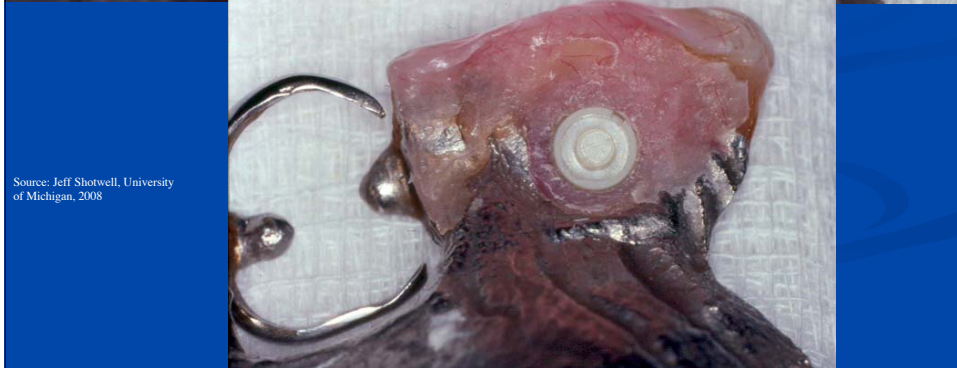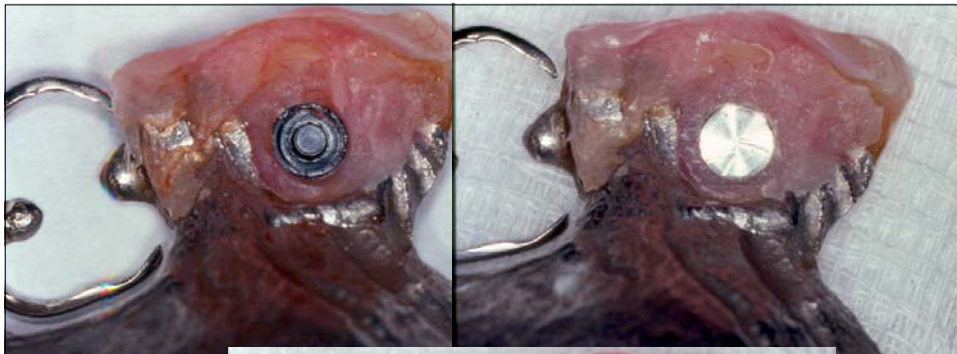
Source: Jeff Shotwell, University of Michigan, 2008



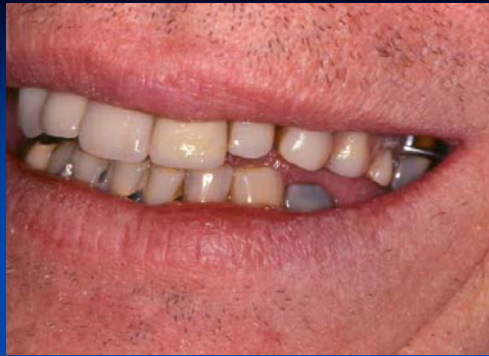A tooth was added to the pre-existing RPD in the place of the natural tooth which is now cut off at the FGM. A recess is cut in the underside of the RPD to fit around the attachment coping. Self cure acrylic will now be painted around the coping making it part of the RPD.



Source: Jeff Shotwell, University of Michigan, 2008



Source: Jeff Shotwell, University of Michigan, 2008



We now have a replacement tooth on the RPD. There is still a natural tooth under the RPD providing support and retention. We have eliminated the need for a clasp in this area as well.

Source: Jeff Shotwell, University of Michigan, 2008