

Unless otherwise noted, the content of this course material is licensed under a Creative Commons Attribution 3.0 License.

Copyright 2008, Jeffrey Shotwell

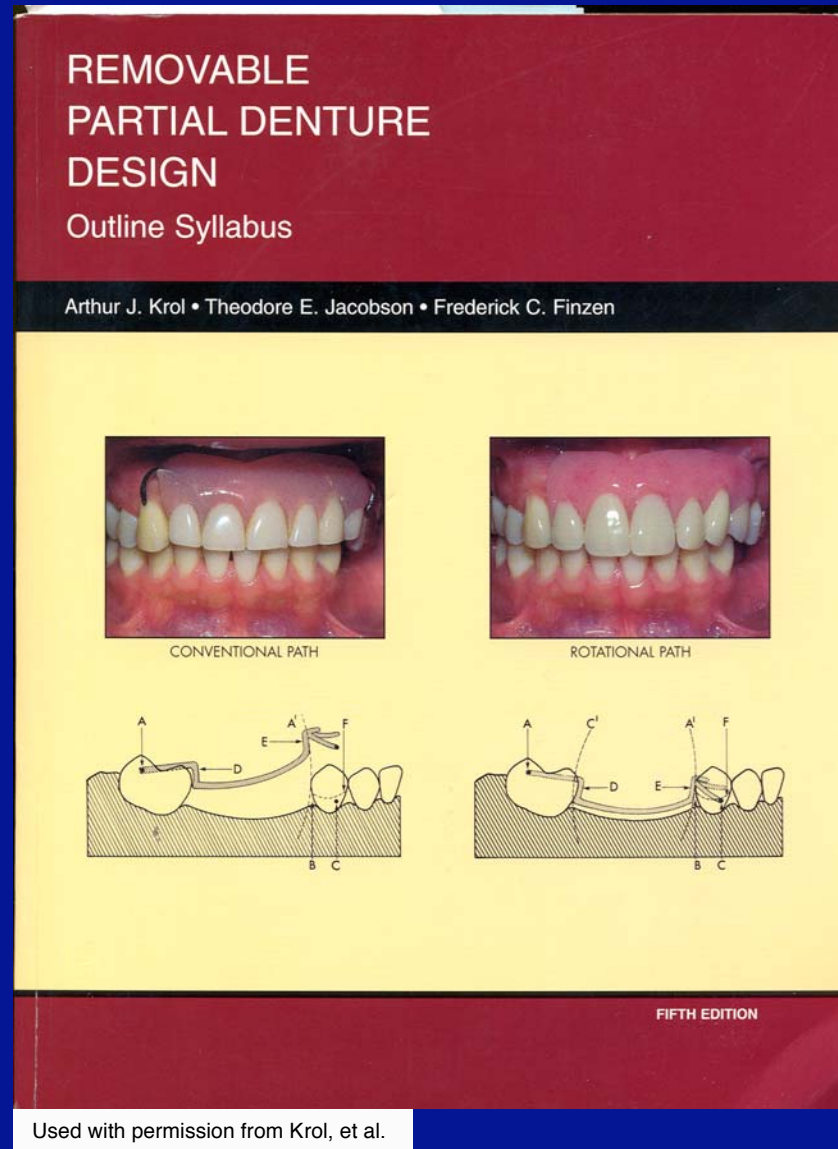


The following information is intended to inform and educate and is not a tool for self-diagnosis or a replacement for medical evaluation, advice, diagnosis or treatment by a healthcare professional. You should speak to your physician or make an appointment to be seen if you have questions or concerns about this information or your medical condition. You assume all responsibility for use and potential liability associated with any use of the material.

Material contains copyrighted content, used in accordance with U.S. law. Copyright holders of content included in this material should contact open.michigan@umich.edu with any questions, corrections, or clarifications regarding the use of content. The Regents of the University of Michigan do not license the use of third party content posted to this site unless such a license is specifically granted in connection with particular content objects. Users of content are responsible for their compliance with applicable law.

Rotational Path Concepts

Images from Krol, A.J.,
Jacobson, T.E., &
Finzen, F.C. (1999).
*Removable Partial
Denture Design:
Outline Syllabus (5th
ed)*. San Rafael, CA :
Indent ; San Francisco,
CA : Bookstore,
University of the
Pacific, School of
Dentistry, [distributor]
and used with
permission of the
authors.



Disclaimer:

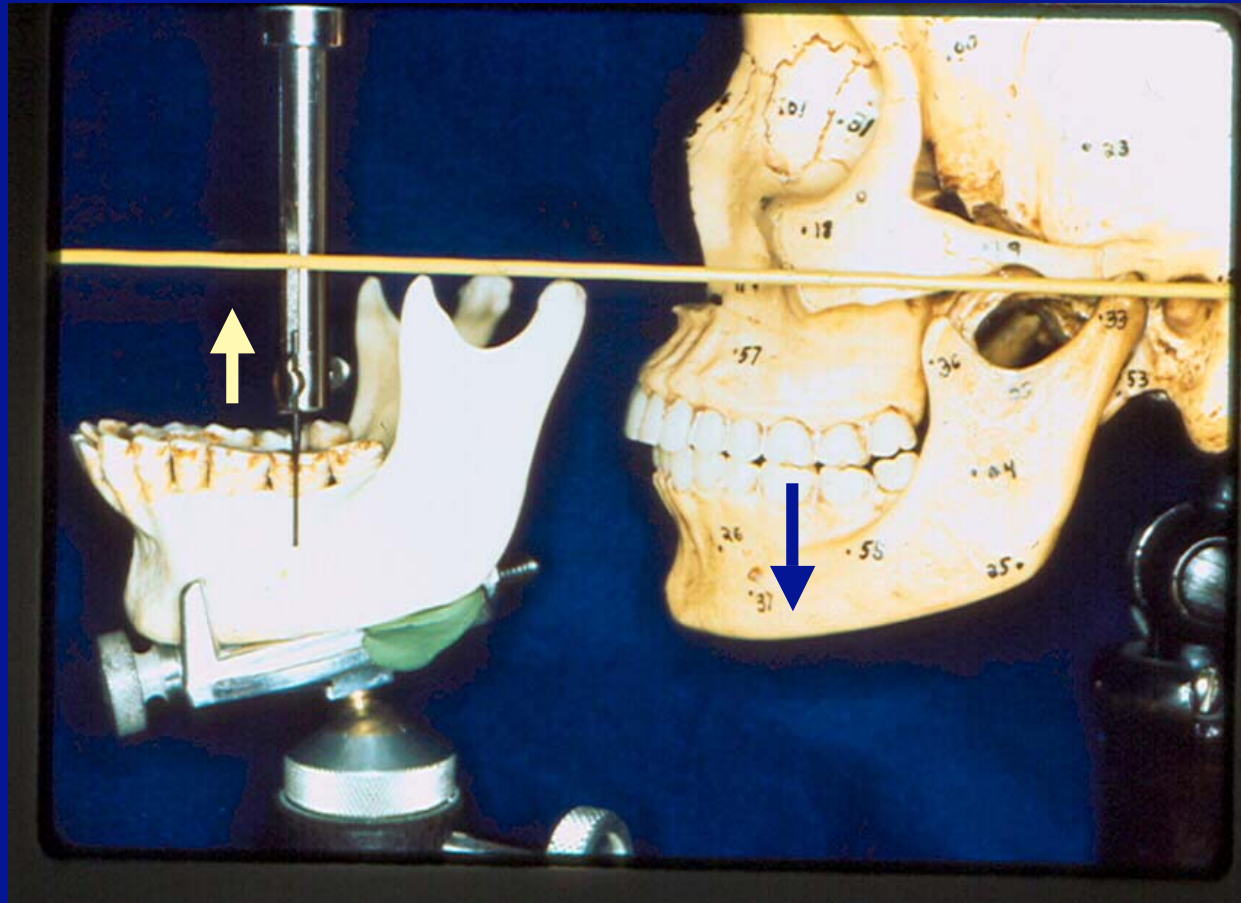
Mentions of specific products in these slides represent the opinion of the speaker only and do not represent endorsement by the University of Michigan.

General Considerations with Rotational Path RPDs

1. All rests do not seat simultaneously.
2. It is not a straight path of placement.
3. Eliminates unesthetic clasps.
4. Clasps replaced by rigid retainers.
5. Rigid retainers engage undercuts.
6. Little tolerance for error.

Krol 5th ed.

Linear Path of Insertion



Undercuts must exist perpendicular
to the plane of occlusion

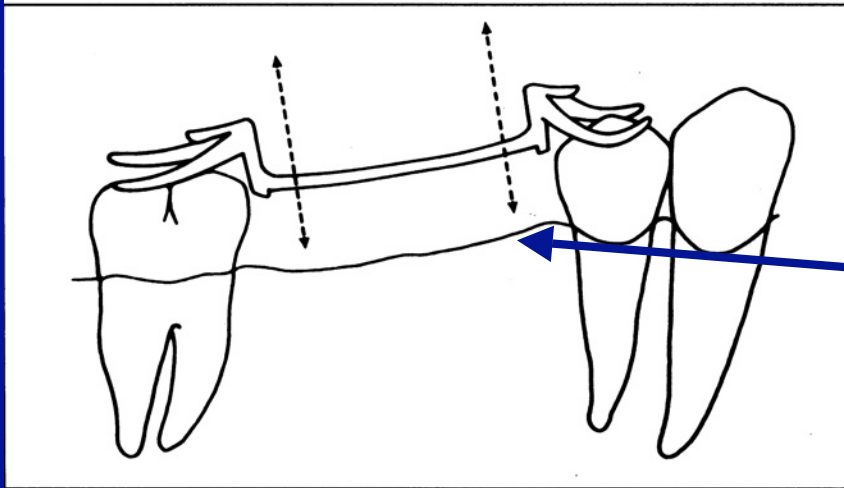


Fig. 9-1A. Straight path of placement. Rests will seat simultaneously.

Used with permission from Krol, et al.

Linear Path of Insertion

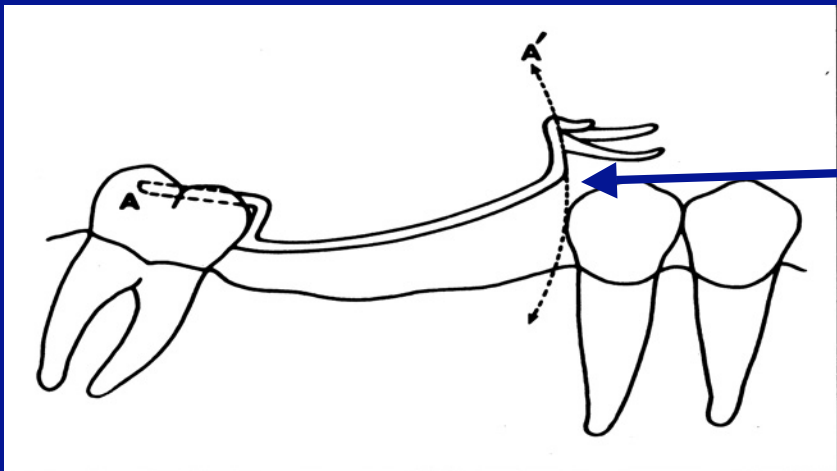


Fig. 9-2A. Rotational path of placement. The terminus of the molar rest (A) is seated first followed by rotation of the pre-molar clasp along arc (A') into its final position.

Used with permission from Krol, et al.

Curvilinear Path of Insertion

Krol 5th ed.

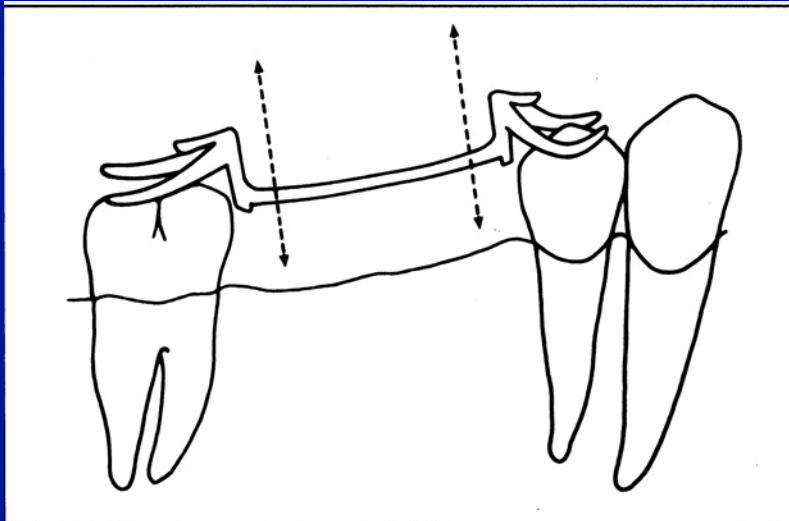


Fig. 9-1A. Straight path of placement. Rests will seat simultaneously.

Used with permission from Krol, et al.

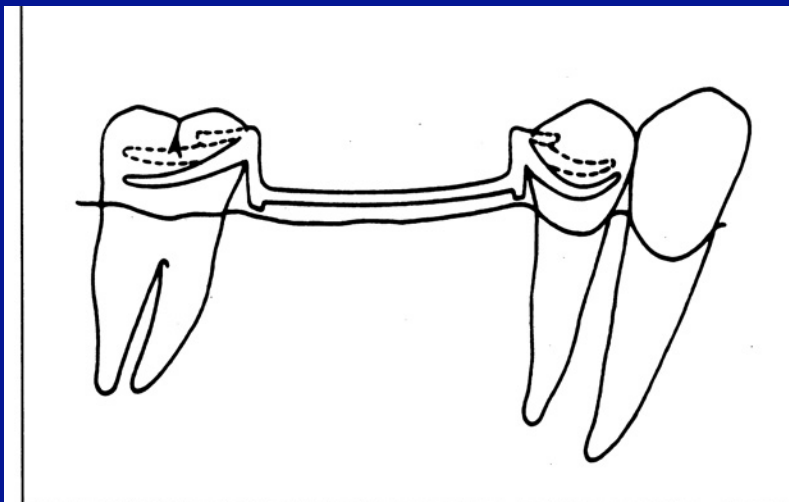


Fig. 9-1B. Partial denture completely seated.

Used with permission from Krol, et al.

In Linear
placement, all rest
seat
simultaneously

Krol 5th ed.

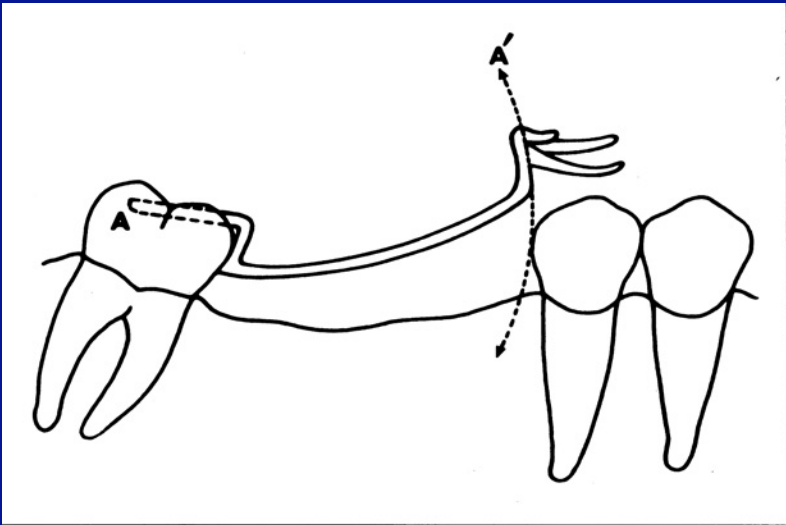


Fig. 9-2A. Rotational path of placement. The terminus of the molar rest (A) is seated first followed by rotation of the pre-molar clasp along arc (A') into its final position.

Used with permission from Krol, et al.

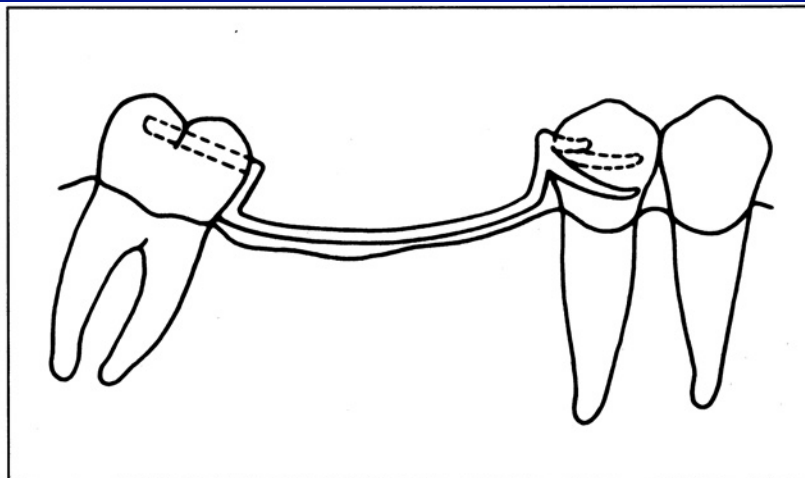


Fig. 9-2B. Rotational path partial denture completely seated.

Used with permission from Krol, et al.

In a curvilinear path, the rests that determine the rotational axis are placed first then the RPD is rotated to final seating.

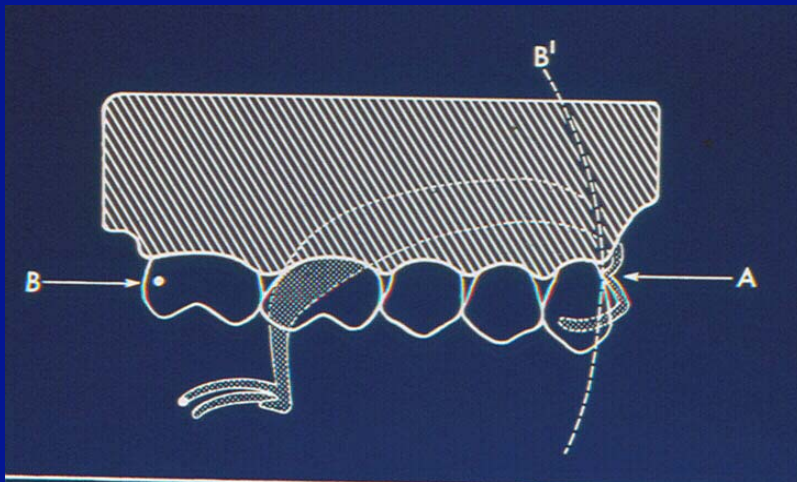
Krol 5th ed.

Types of Rotational Path RPDs

1. Anteroposterior - Front to back
2. Posteroanterior - Back to front
3. Lateral - Sideways

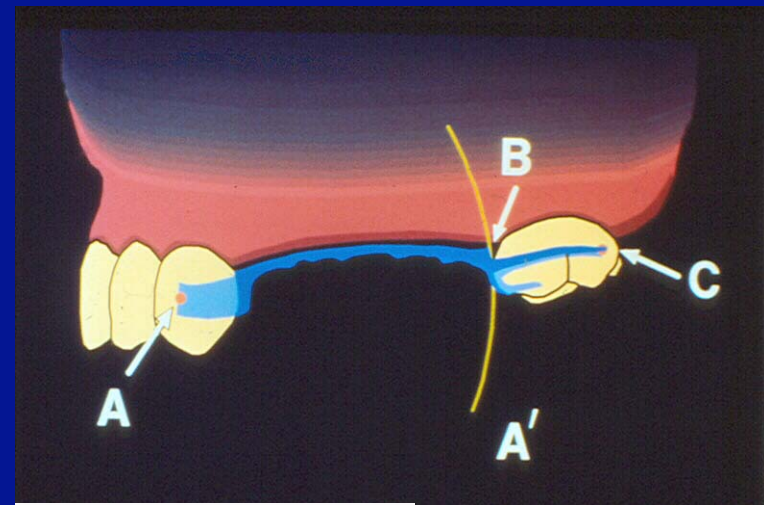
Krol 5th ed.

Anteroposterior



Used with permission from Krol, et al.

Class IV



Used with permission from Krol, et al.

Class III

Krol 5th ed.

Posteroanterior

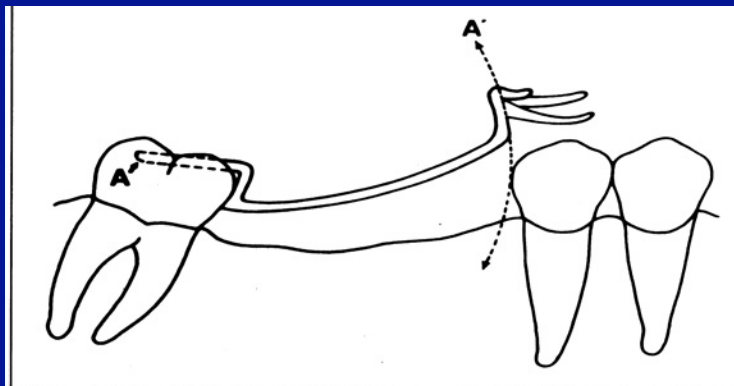


Fig. 9-8. Posteroanterior path of placement. Posterior segment is placed first. (A) is the center of rotation around which the partial denture rotates into position. (A') is the arc that the minor connector on the premolar must follow for final placement.

Used with permission from Krol, et al.

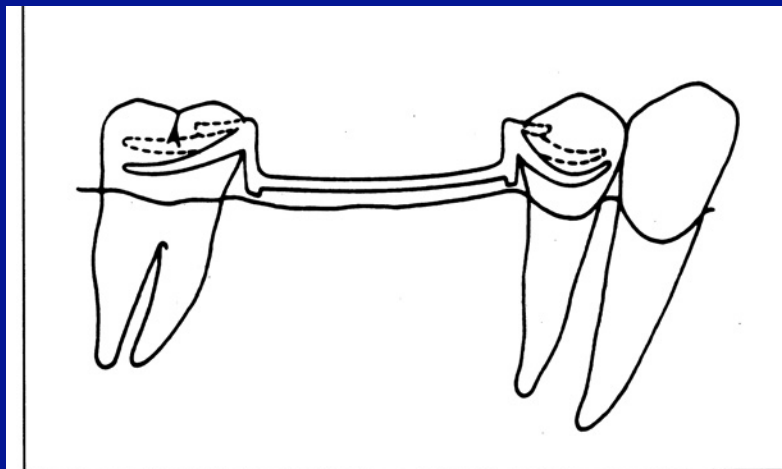


Fig. 9-1B. Partial denture completely seated.

Used with permission from Krol, et al.

Class III

Krol 5th ed.

Lateral

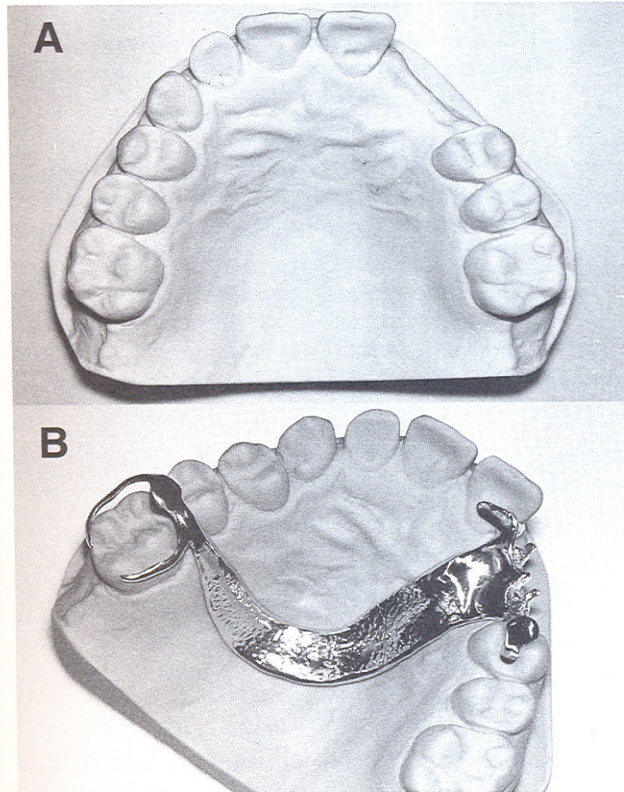


Fig. 9-34A. Master cast of patient with lateral incisor and canine missing.

Fig. 9-34B. Lateral path of placement.

Used with permission from Krol, et al.

Class III

Krol 5th ed.

Categories of Rotational Path RPDs

- Category I - The rotational centers (rests) are seated first then the prosthesis is rotated into place.
- Category II - (Dual Path) The rotational centers are located at the gingival extension of the rigid retainers

Category I

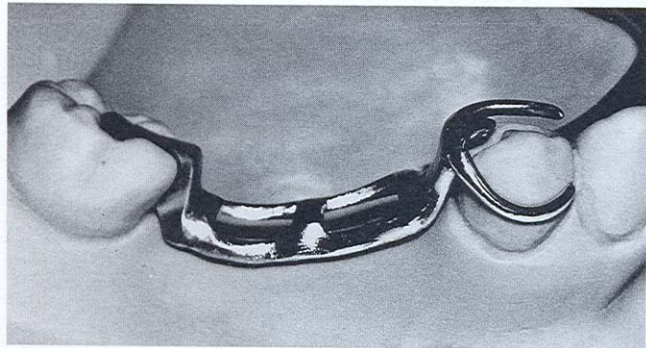


Fig. 9-23C. Partial dentures using a PA path of placement being seated. The minor connector on the molar engages its mesial surface while the clasps on the premolar is being seated.

Used with permission from Krol, et al.



Fig. 9-23D. The partial denture completely seated.

Used with permission from Krol, et al.

Krol 5th ed.

Category II

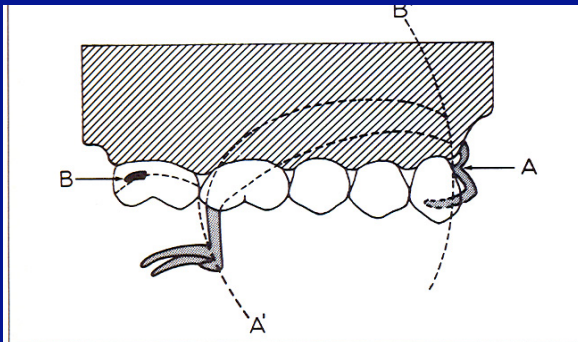


Fig. 9-24A. The anterior rigid retainer is placed first along a straight path to gain access to the rotational center (A) located on the mesial surface of the canine. The clasp on the molar is then completely seated along arc (A').

Used with permission from Krol, et al.

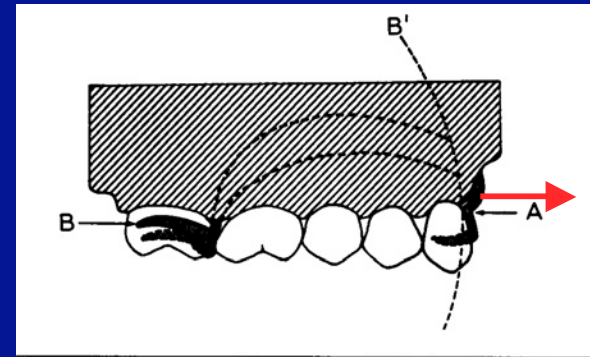


Fig. 9-24B. (B) represents the retentive area for the molar clasp and (B') the arc along which the rigid retainer on the canine would have to move to be displaced.

Used with permission from Krol, et al.

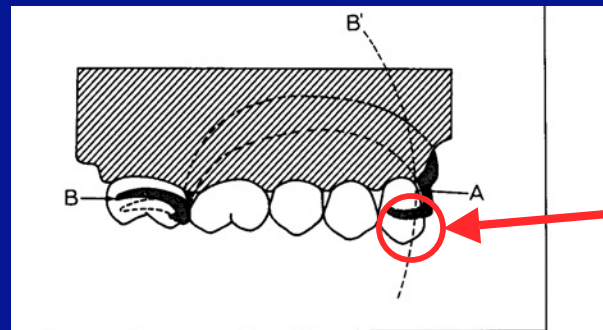


Fig. 9-24C. Arrow (A) indicates a slight space between the minor connector and the mesial surface of the canine which may result from improper waxing, casting, finishing or adjusting of the framework. Such a space reduces the effectiveness of the indirect retainer.

Used with permission from Krol, et al.

Slight space
created

Krol 5th ed.

Cast Analysis

1. Plane of occlusion
2. Length of the edentulous span
3. Rotational axis
4. Shape of the dental arch
5. Depth of undercut

Plane of Occlusion affects the depth of undercut

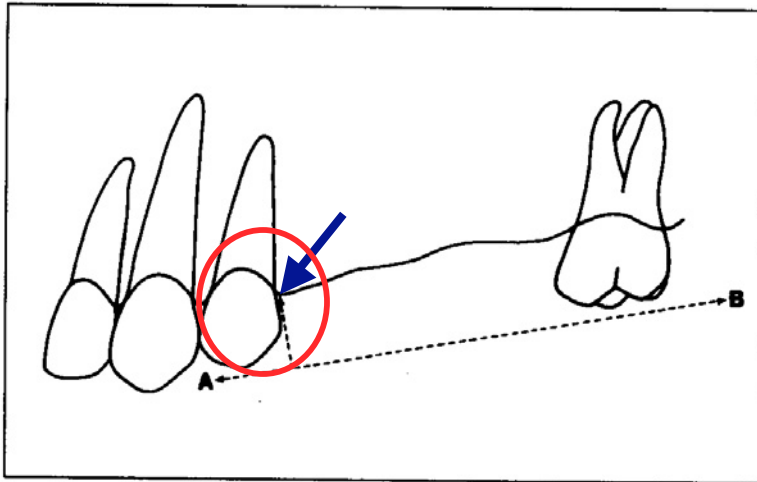


Fig. 9-22A. All abutments are surveyed on a horizontal plane with the analyzing rod perpendicular to the plane. No undercut is present on the distal surface of the first premolar as in Fig. 9-21C.

Used with permission from Krol, et al.

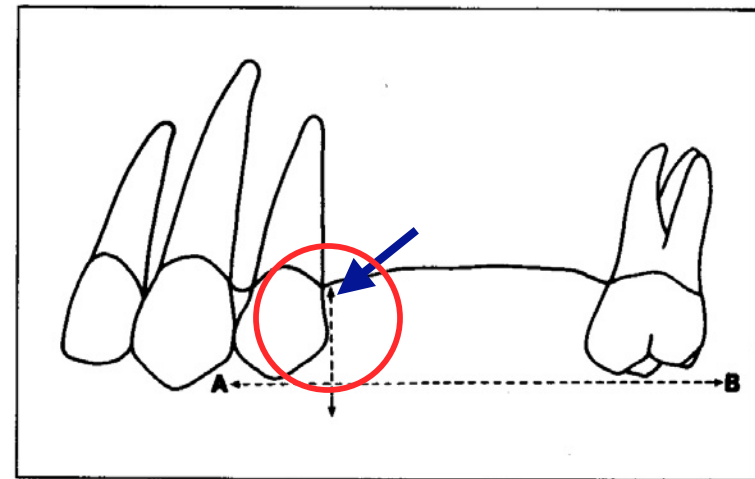


Fig. 9-22B. A slight undercut is present as in Fig. 9-12C. The undercut may be increased to ensure adequate retention.

Used with permission from Krol, et al.

Length of the edentulous span

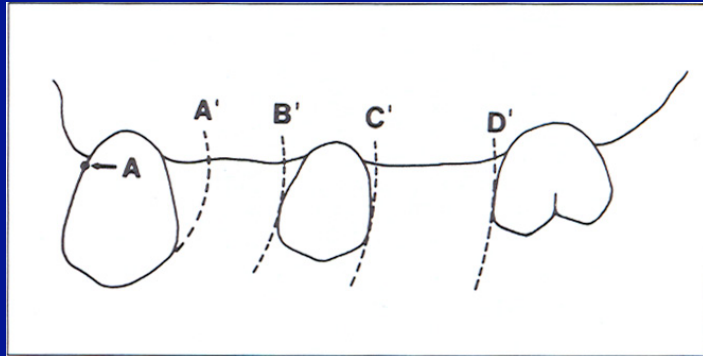


Fig. 9-36. Maxillary arch. The amount of blockout on the distal surface of the canine is much greater than that required on the mesial surface of the molar. This is due to the close proximity of the distal surface of the canine to the rotational center (A).

Used with permission from Krol, et al.

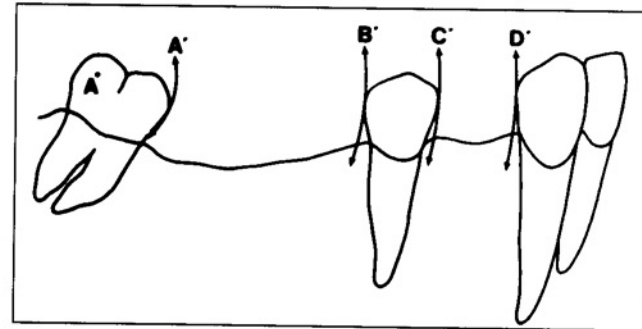


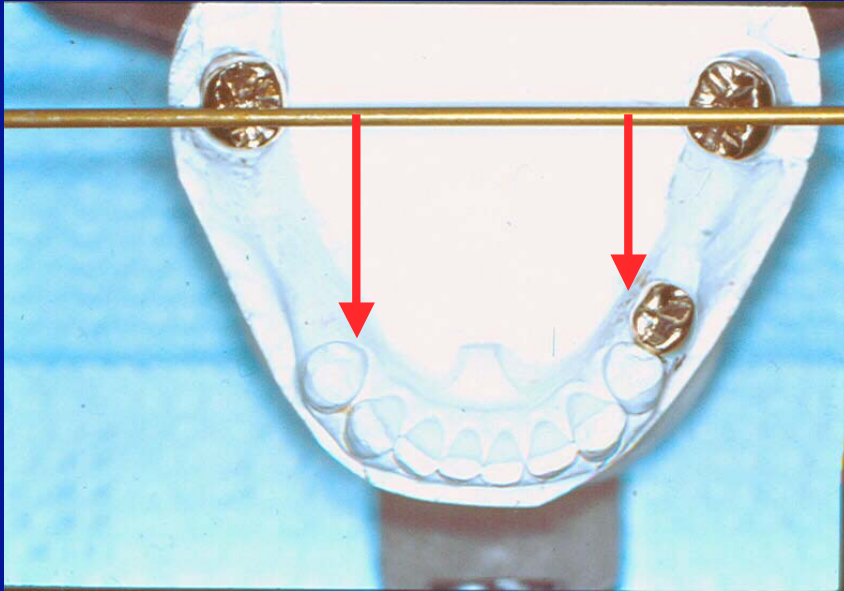
Fig. 9-35. The further the minor connector is from the axis of rotation the straighter the arc that it must follow. The closer the minor connector is from the axis of rotation, the greater the curvature that it must follow requiring more blockout.

Used with permission from Krol, et al.

The closer the edentulous area is to the rotational axis the greater the blockout

Krol 5th ed.

Position of the rotational axis



Will effect the placement of the prosthesis

The shape of the arch

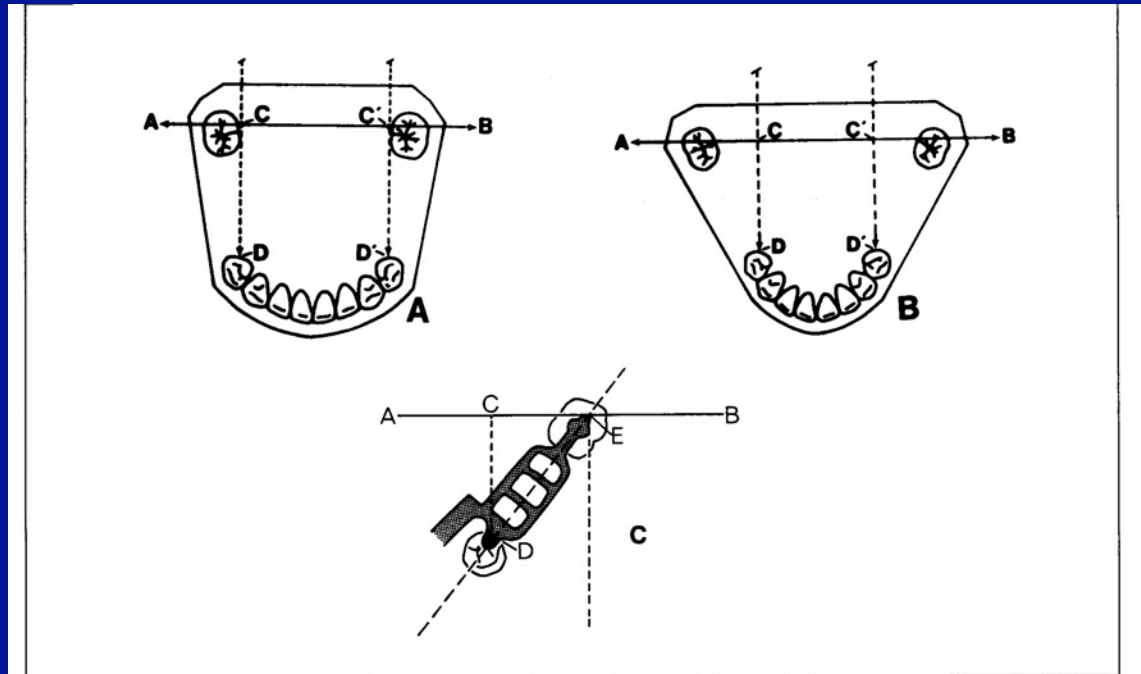


Fig. 9-37A. Category 1 design. Blockout of interferences to framework placement are determined by an arc with a radius formed by extending a line from the blockout areas (D) & (D') perpendicular to the rotational axis. (C D) and (C'D') are the radii. Note that in square arches an arc with a similar radius is obtained by a line connecting the blockout area to the rotational center located at the terminus of the rest.

Fig. 9-37B. The same technique for determining the radius of the arc used to define blockout is used to identify (CD) and (C'D'). Note that these radii are significantly shorter than those that would be obtained using lines extending from the rotational centers.

Fig. 9-37C. Section of a tapering arch with framework in position. Line (CD) is shorter than line (ED). Line (CD) is used to determine the blockout on the distal surface of the premolar. If line (ED) were used insufficient blockout would be provided.

Used with permission from Krol, et al.

Will effect the amount
of blockout

Krol 5th ed.

Depth of undercut

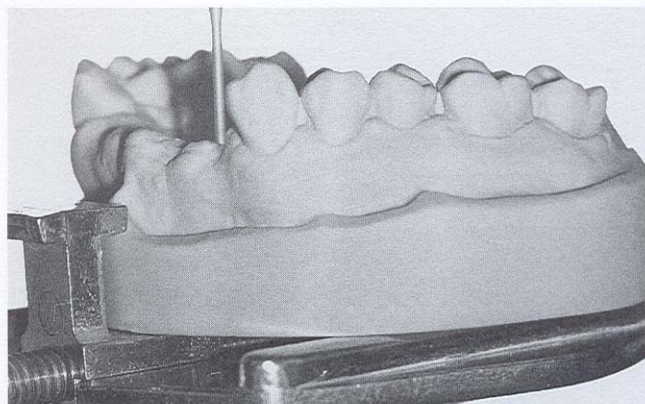


Fig. 9-25. Diagnostic cast being surveyed at a zero degree tilt. Analyzing rod indicates an adequate undercut on the mesial surface of the canine.

Used with permission from Krol, et al.

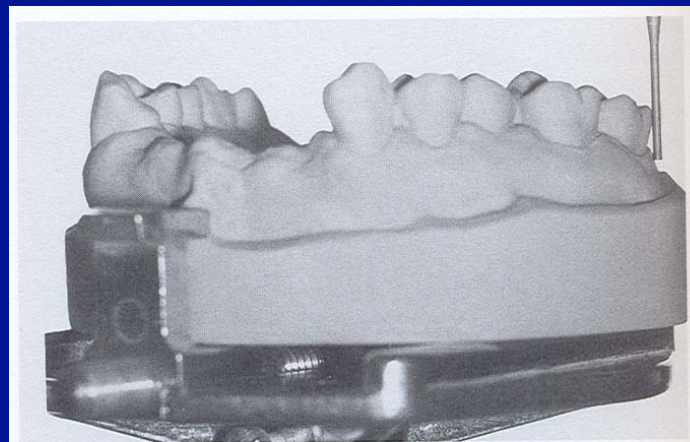
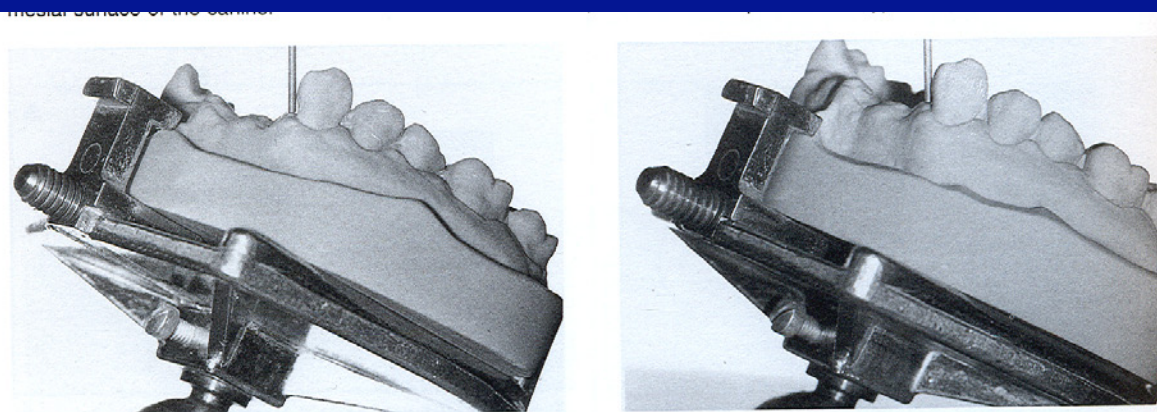


Fig. 9-26. Analyzing rod indicates an acceptable undercut on the distobuccal surface of the molar. The amount of undercut utilized will depend on the type of clasp selected.

Used with permission from Krol, et al.



Figs. 9-27A & B. (A) The cast is tilted upward anteriorly until the undercuts on the mesial surfaces of the anterior abutments are eliminated. This tilt defines the initial straight path of placement. In this photo, a slight space exists between the analyzing rod and the mesial surface of the canine which can best be eliminated by reduction of the tooth. (B) Analyzing rod now indicates absence of undercut.

Used with permission from Krol, et al.

Surveying

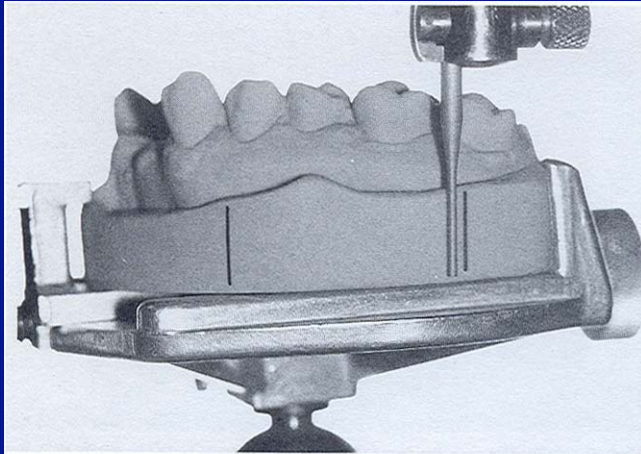


Fig. 9-31A. Cast is tripodized for each position by first placing three widely spaced vertical lines are drawn on the sides of the cast at the zero degree tilt.

Used with permission from Krol, et al.

0 degree tilt




Fig. 9-31B. Three additional lines are drawn on the sides of the cast at the tilt which will permit the initial seating (straight path of placement) without interferences.

Used with permission from Krol, et al.

Anterior tilt

Krol 5th ed.

Rest preparations

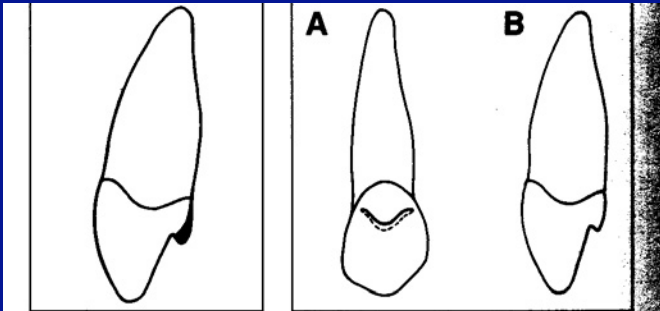


Fig. 9-16. The floor of the cingulum rest seat preparation should be in the enamel if possible. The restoration should serve primarily to prevent migration of the tooth.

Fig. 9-17A. Maxillary cingulum rest seat preparation, when viewed from the lingual should have a "V" or "U" shaped configuration.

Fig. 9-17B. When viewed from the proximal, it should have the shape of an inverted "V" or "U".

Used with permission from Krol, et al.

Anterior

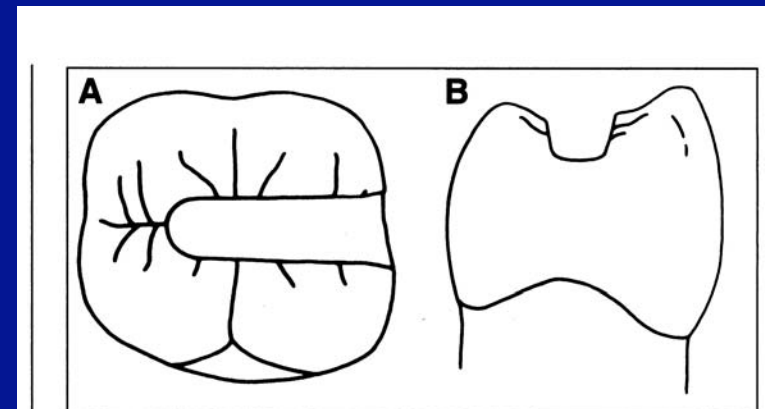


Fig. 9-13A & B. (A) A straight channel rest preparation extends more than one half the mesiodistal dimension of the tooth.

(B) Facial and lingual walls are nearly parallel.

Used with permission from Krol, et al.

Posterior

Krol 5th ed.

Rest preparations

Anterior

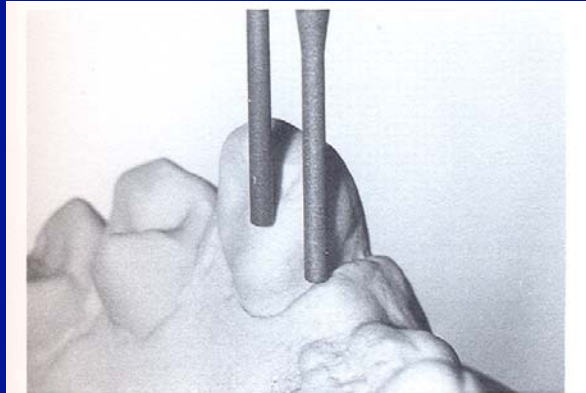
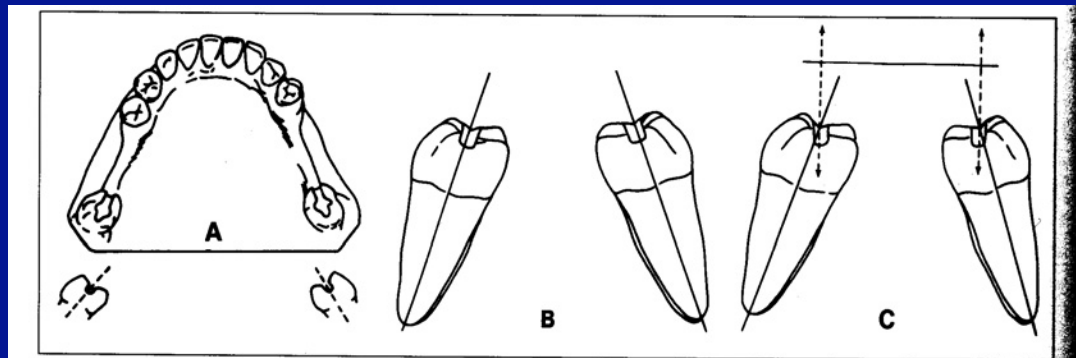


Fig. 9-28B. Double analyzing rod shows that the rest seat and the mesial surface of the canine will be accessible utilizing the initial straight path of placement.

Used with permission from Krol, et al.

Posterior



Figs. 9-15A, B & C. (A) Illustration of a mandibular arch with molars tipped mesially and lingually. (B) Occlusal rest seat preparations across the arch would not permit seating of the rests. (C) The facial walls of the rest seat preparations across the arch must be parallel or slightly divergent to permit placement of the rests.

Used with permission from Krol, et al.

Krol 5th ed.

Guide plane preparations




Fig. 9-19A. Divider whose arm or arms may be adjusted to parallel one another is type recommended.

Used with permission from Krol, et al.

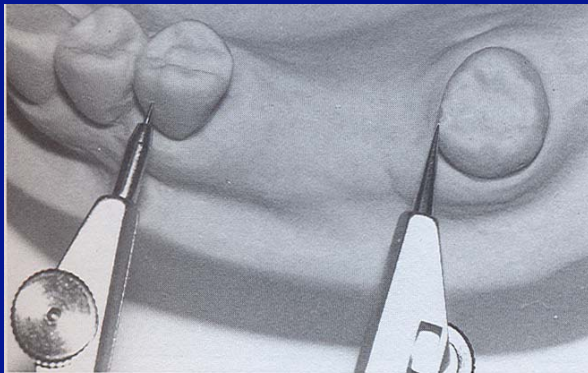


Fig. 9-20A. One point of the divider is placed on the axis around which the framework will rotate into position. The other point is placed in contact with the height of contour of the tooth surface requiring relief.

Used with permission from Krol, et al.

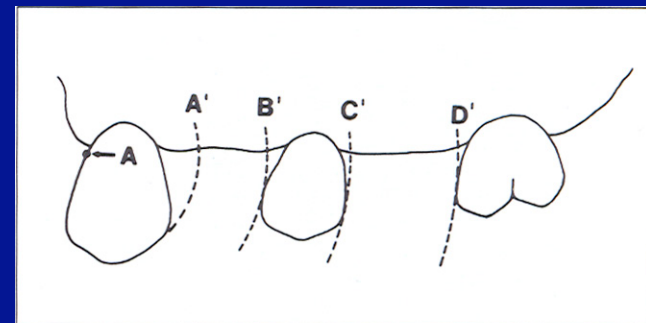


Fig. 9-36. Maxillary arch. The amount of blackout on the distal surface of the canine is much greater than that required on the mesial surface of the molar. This is due to the close proximity of the distal surface of the canine to the rotational center (A).

Used with permission from Krol, et al.

Guide planes are
curvilinear

Krol 5th ed.

Patient presentations

1. Posteroanterior (Category I)
2. Anteroposterior (Category II)
3. Anteroposterior (Category I)
4. Lateral (Category II)
5. Lateral (Category I)

Posteroanterior Category I

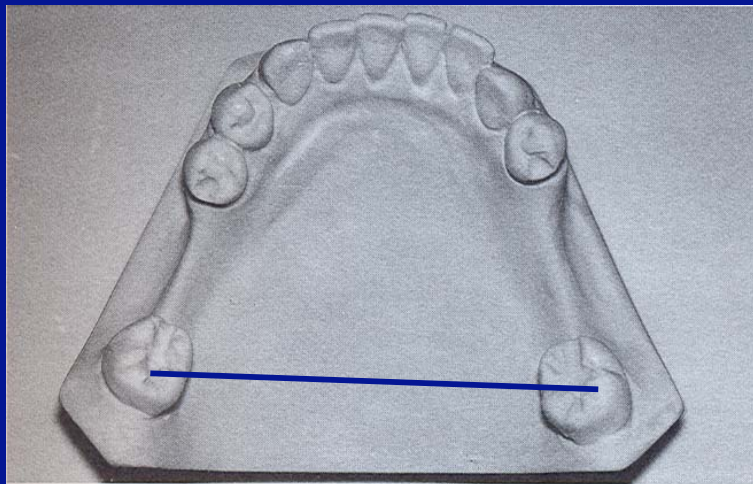


Fig. 9-23E. Master cast. Note dovetail rest preparation on the molar abutments.

Used with permission from Krol, et al.

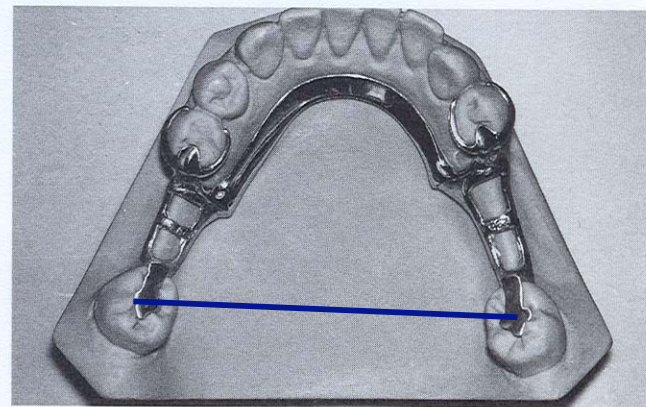
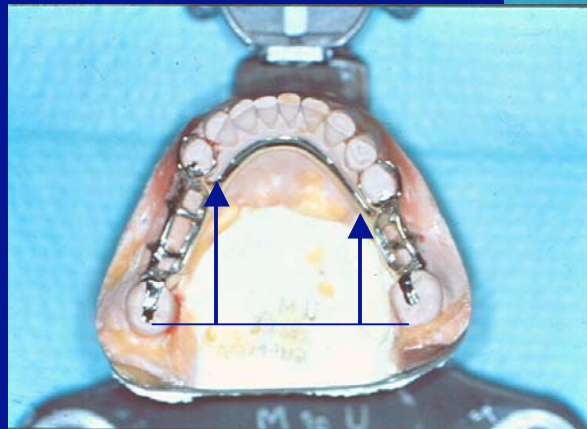
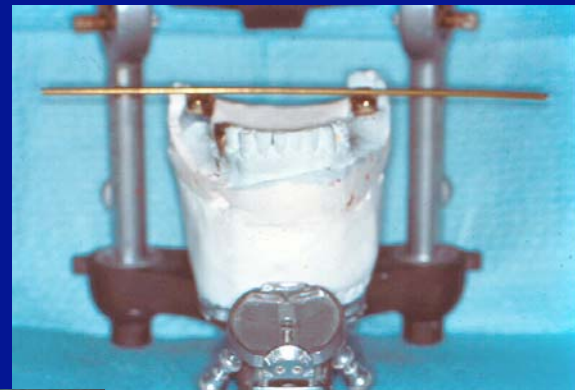
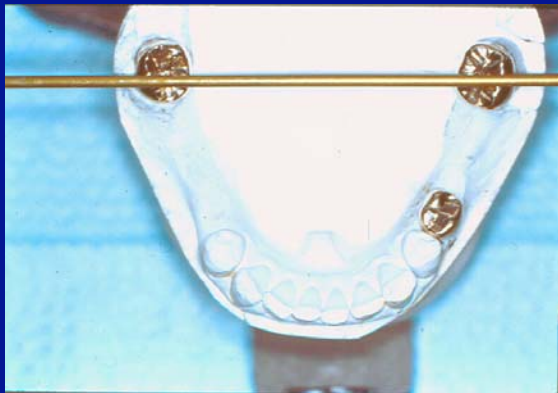


Fig. 9-23F. Partial denture completely seated.

Used with permission from Krol, et al.

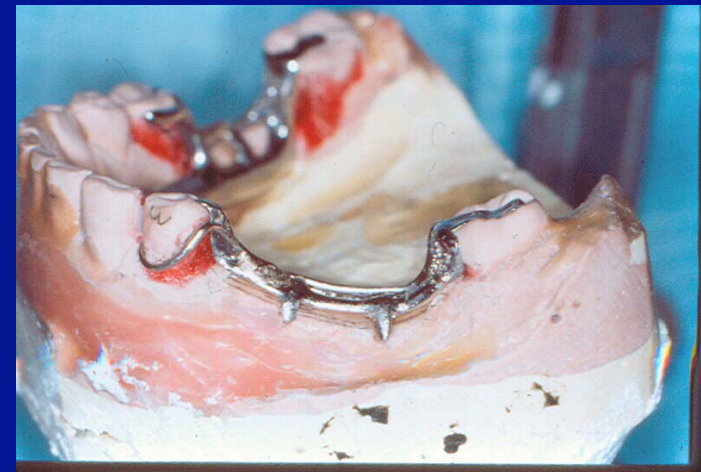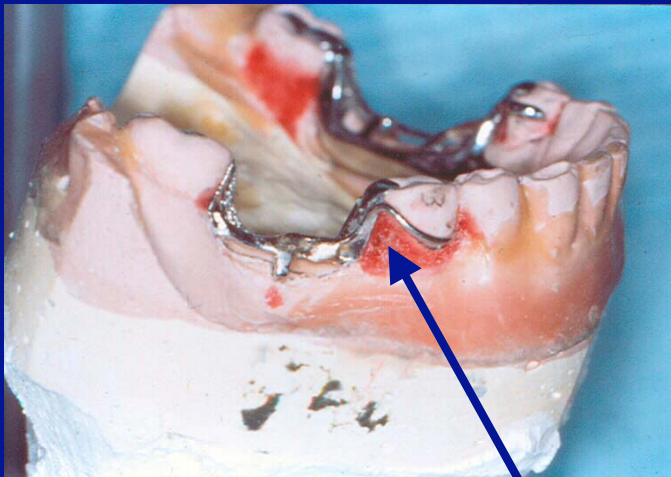
Krol 5th ed.

Posteroanterior Category I



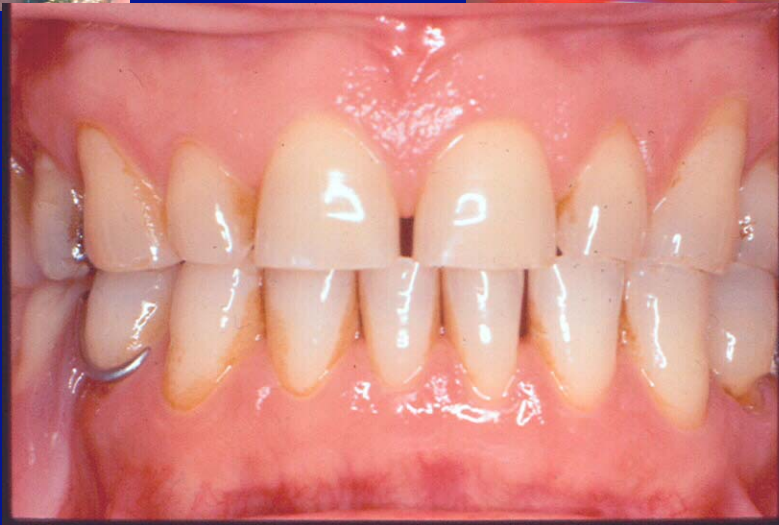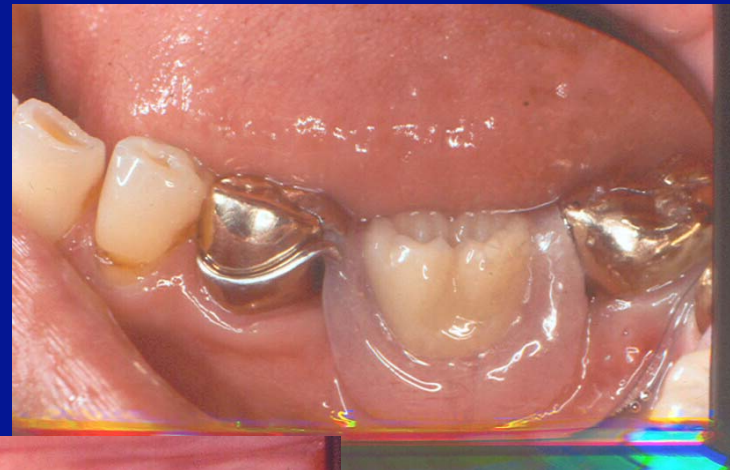
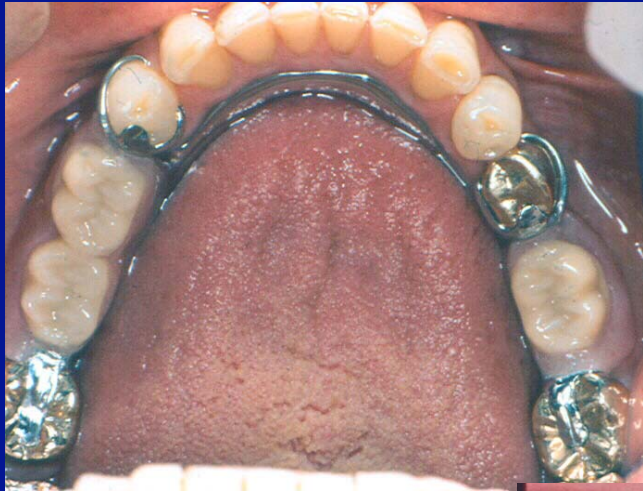Axis of Rotation

Posteroanterior Category I

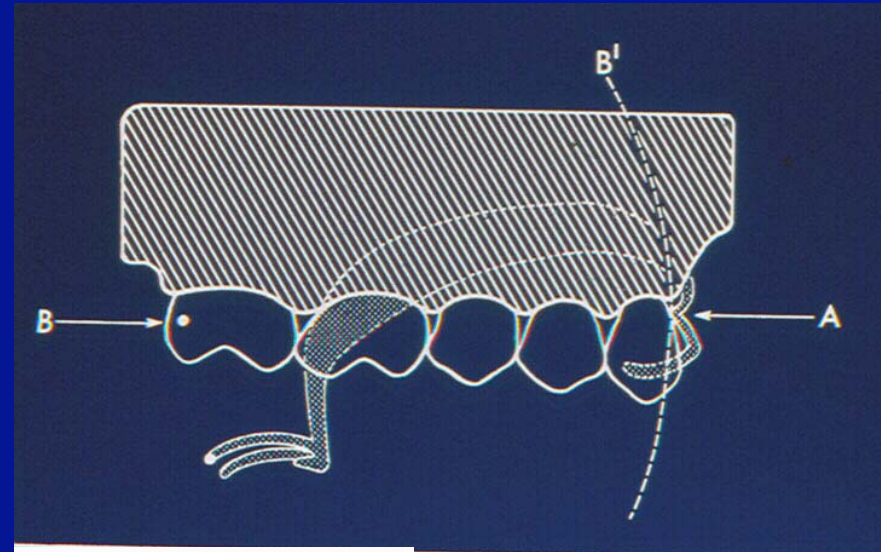


The shorter the span the
greater the blockout

Posteroanterior Category I



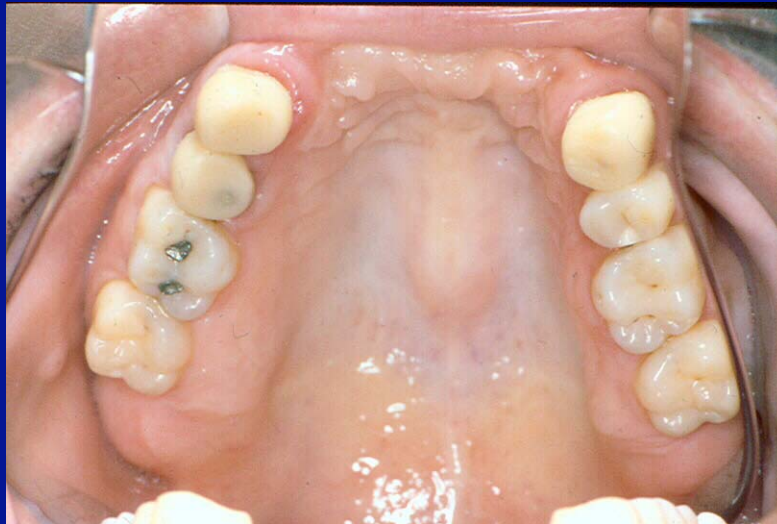Anteroposterior Category II



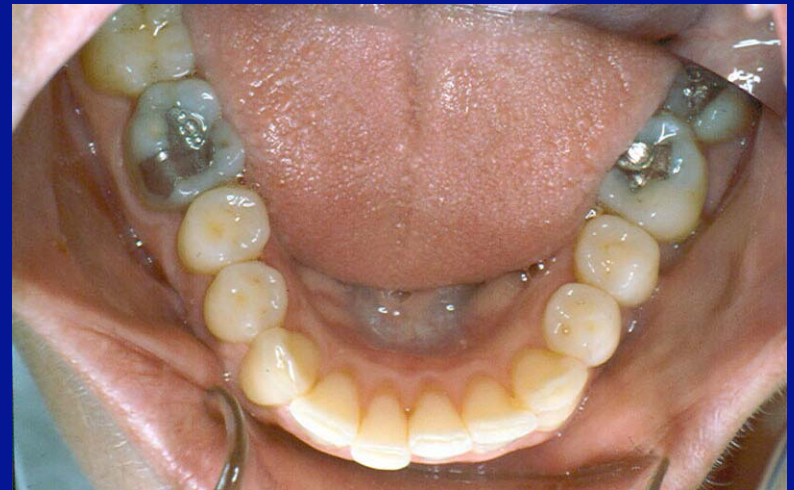Used with permission from Krol, et al.

Krol 5th ed.

Anteroposterior Category II

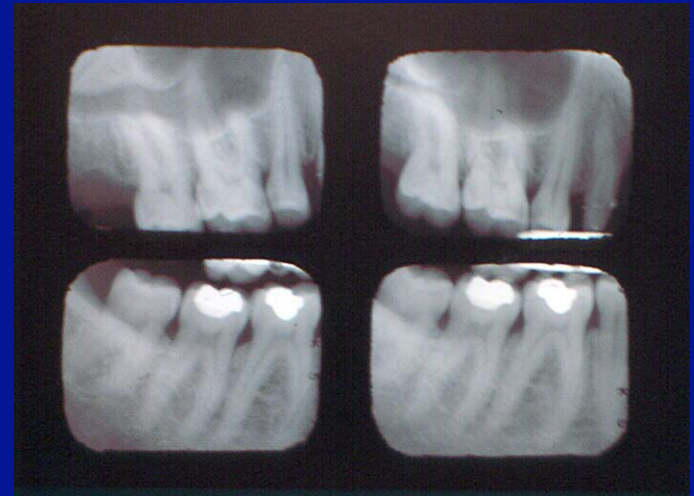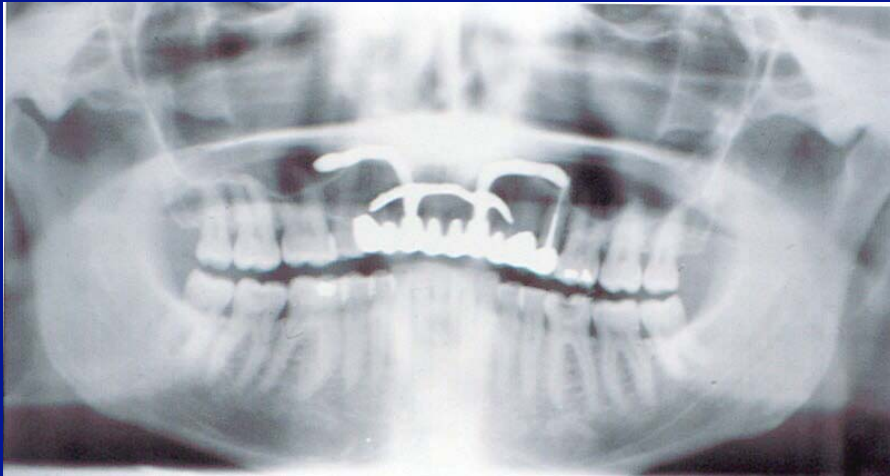


Maxillary



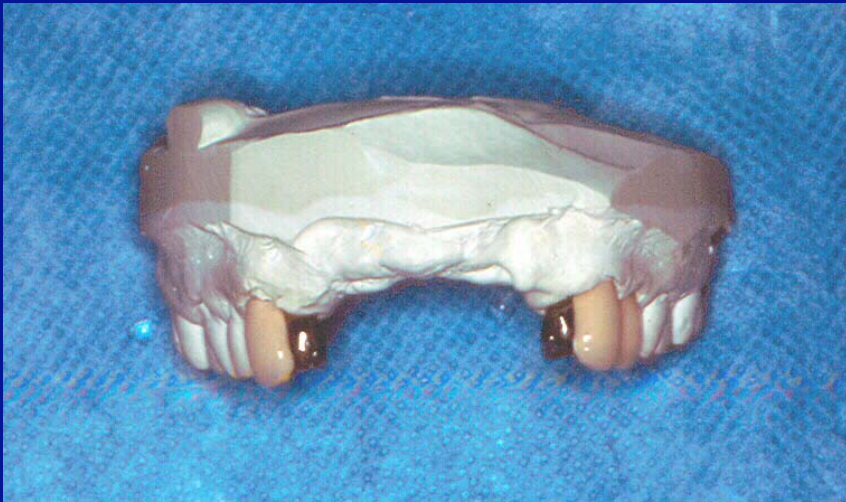Mandibular

Anteroposterior Category II

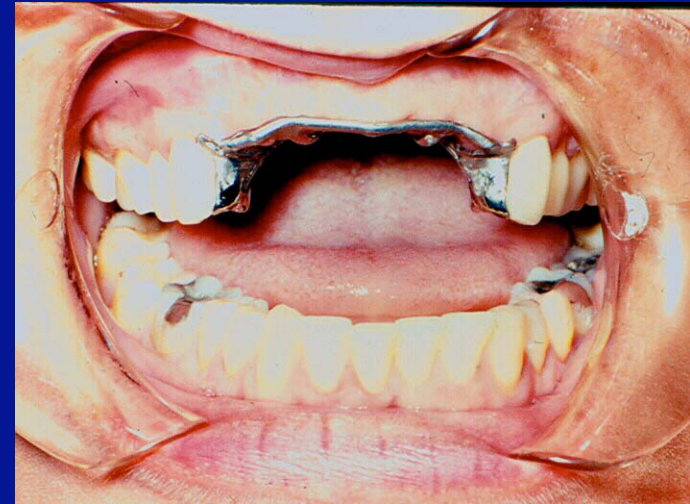

Radiographic Evaluation

Anteroposterior Category II

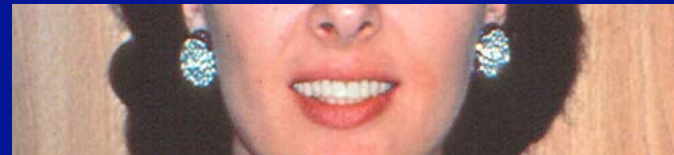
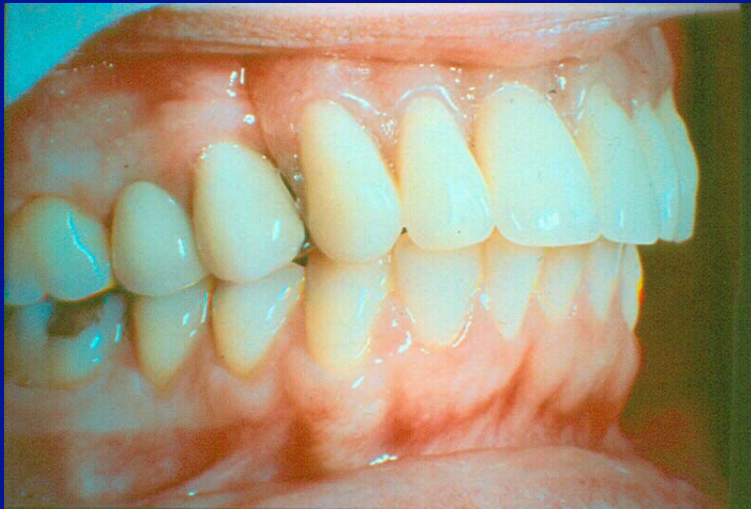
Crown Fabrication



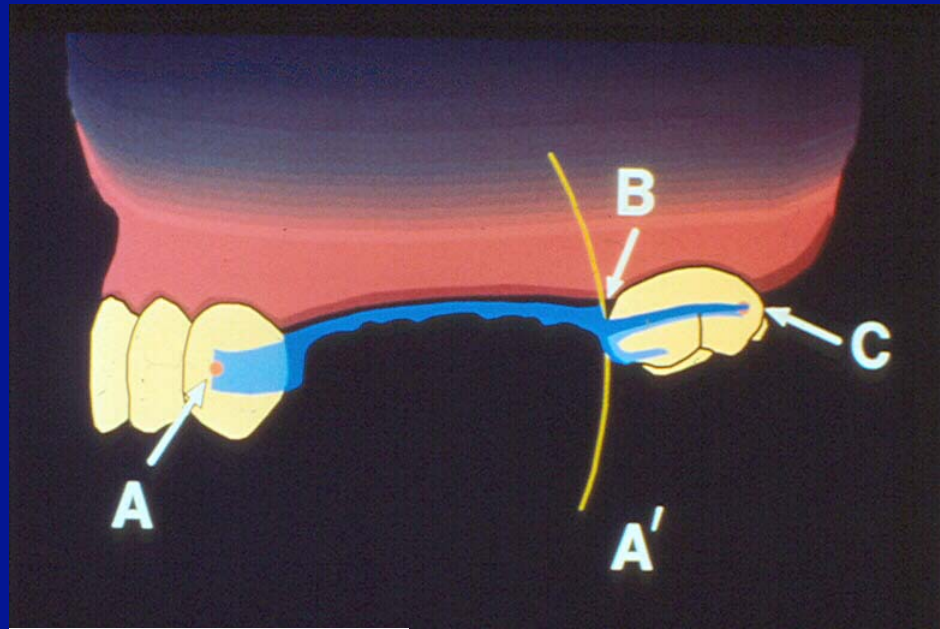
Try-in

Anteroposterior Category II



Final Result

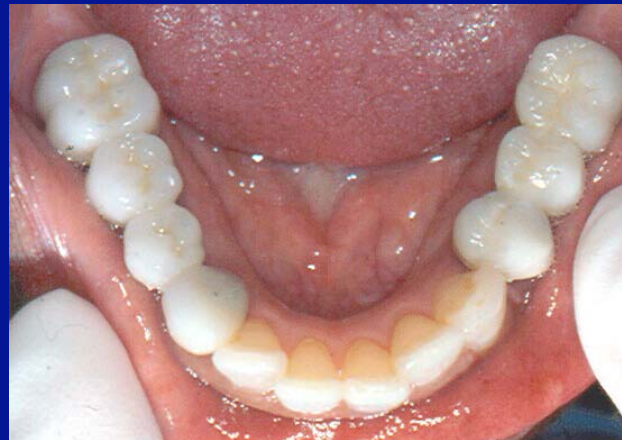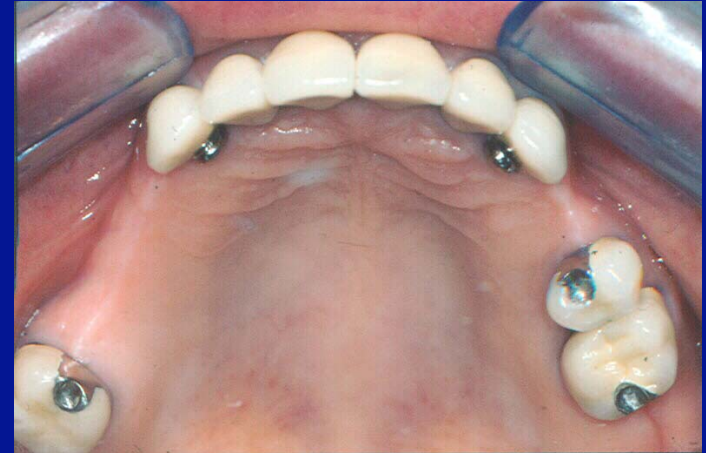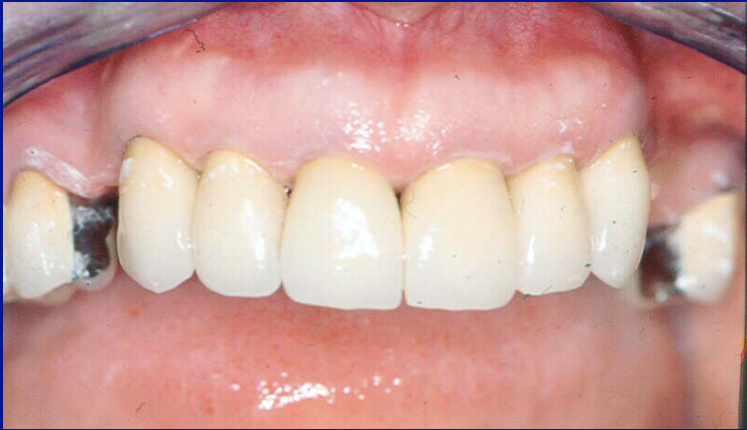Anteroposterior Category I



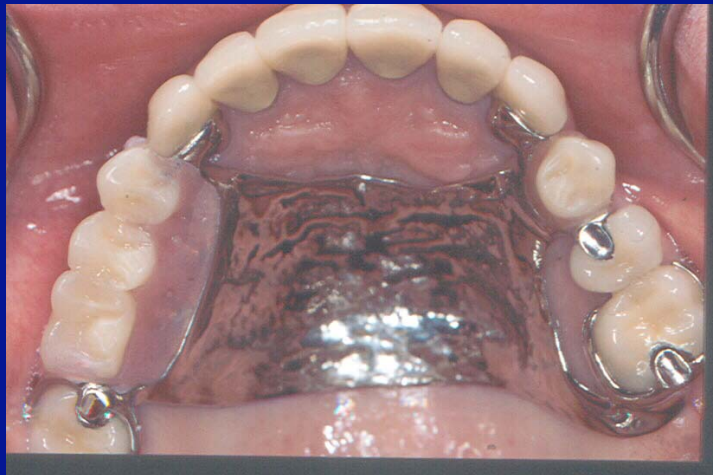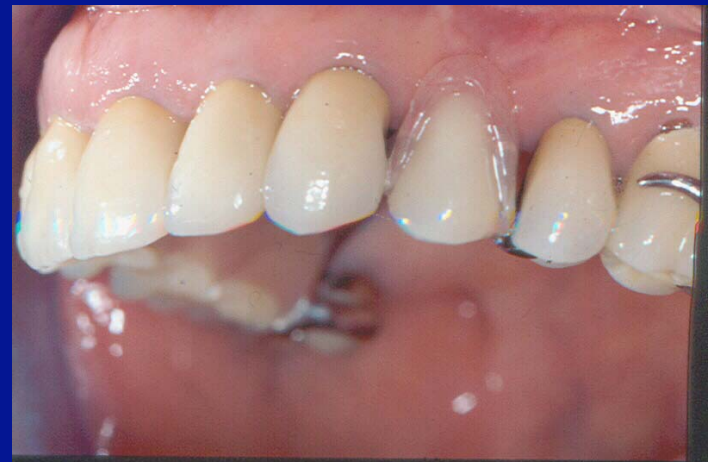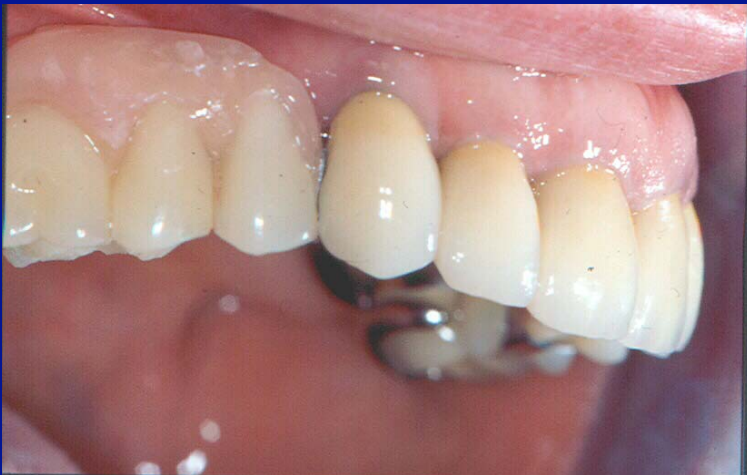Used with permission from Krol, et al.

Krol 5th ed.

Anteroposterior Category I



Anteroposterior Category I



Lateral Category II

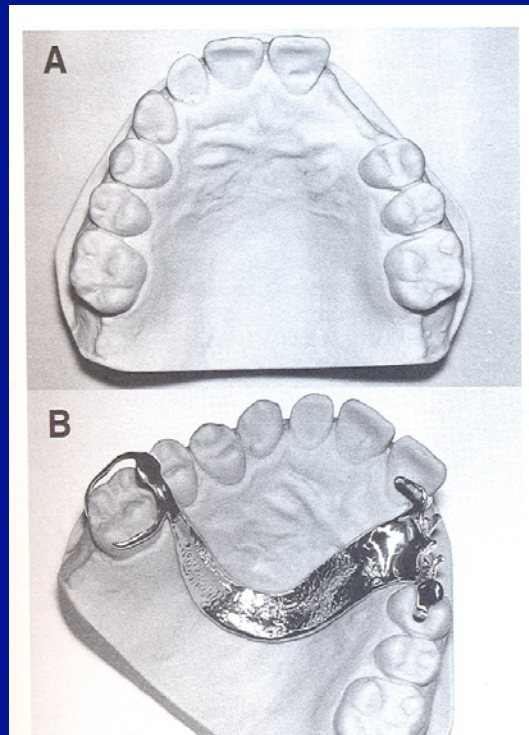


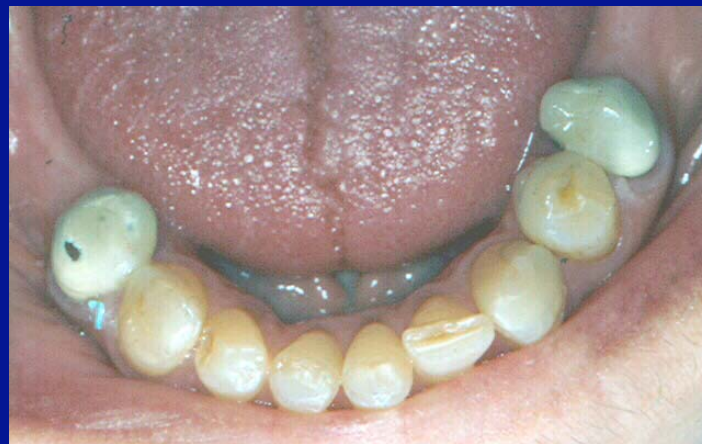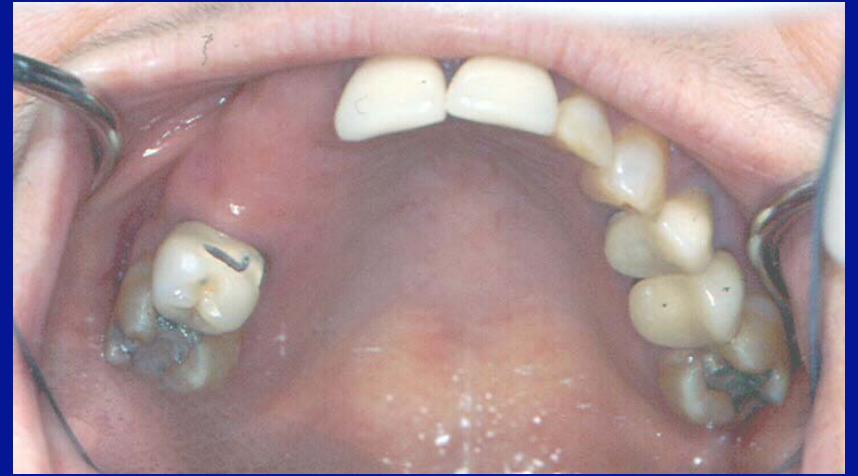
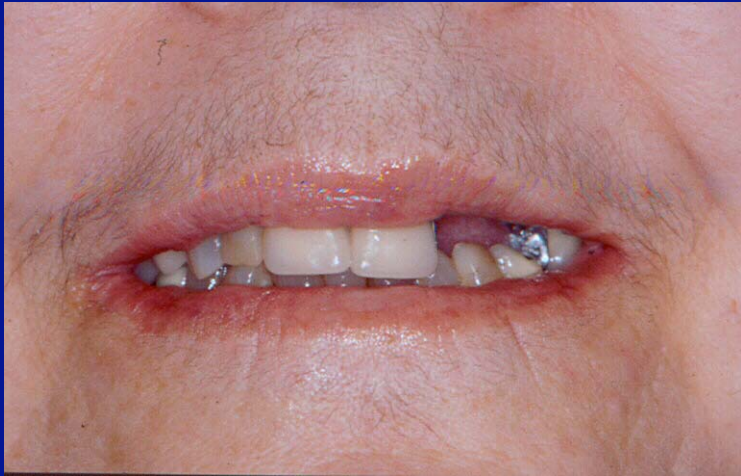Fig. 9-34A. Master cast of patient with lateral incisor and canine missing.

Fig. 9-34B. Lateral path of placement.

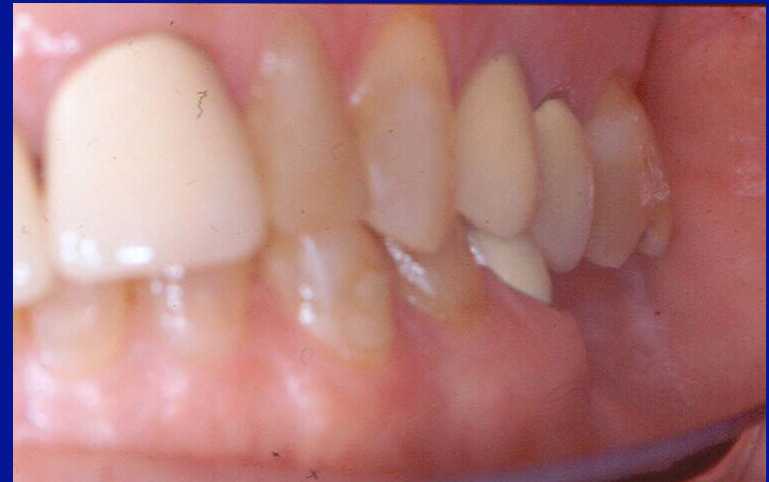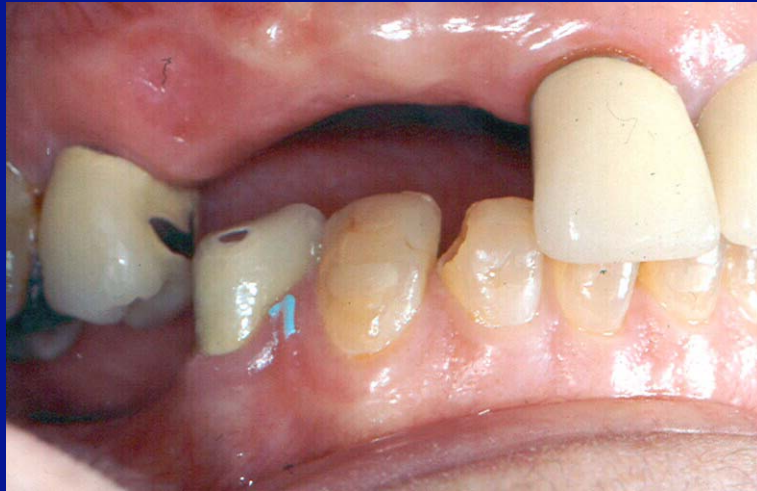Used with permission from Krol, et al.

Krol 5th ed.

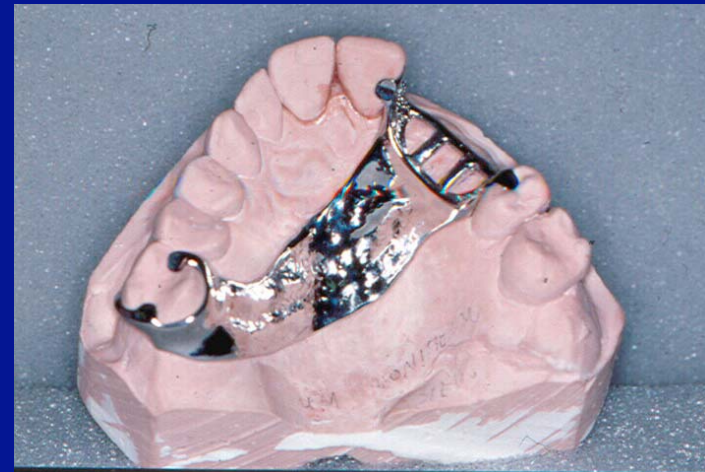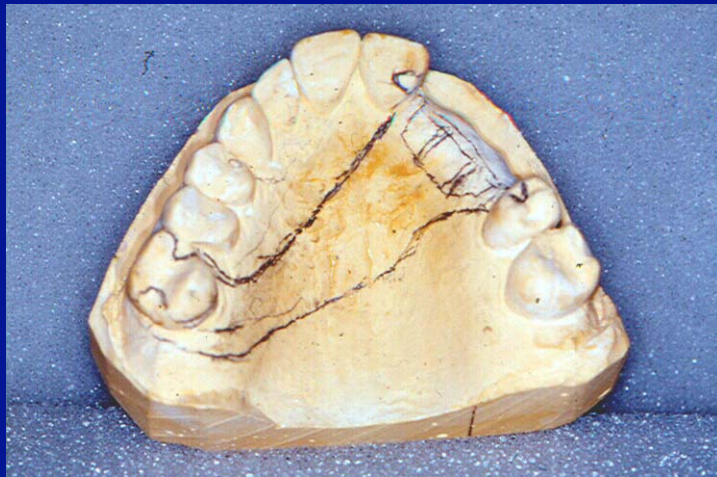Lateral Category II



Lateral Category II

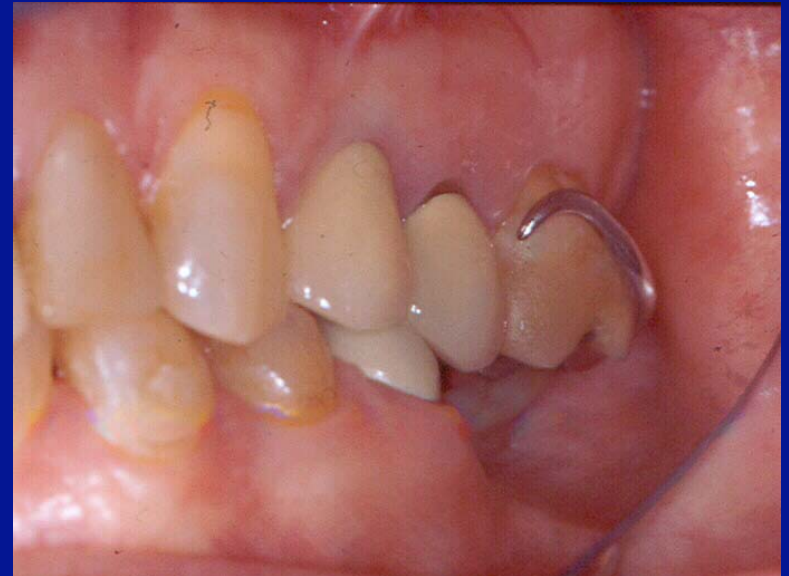
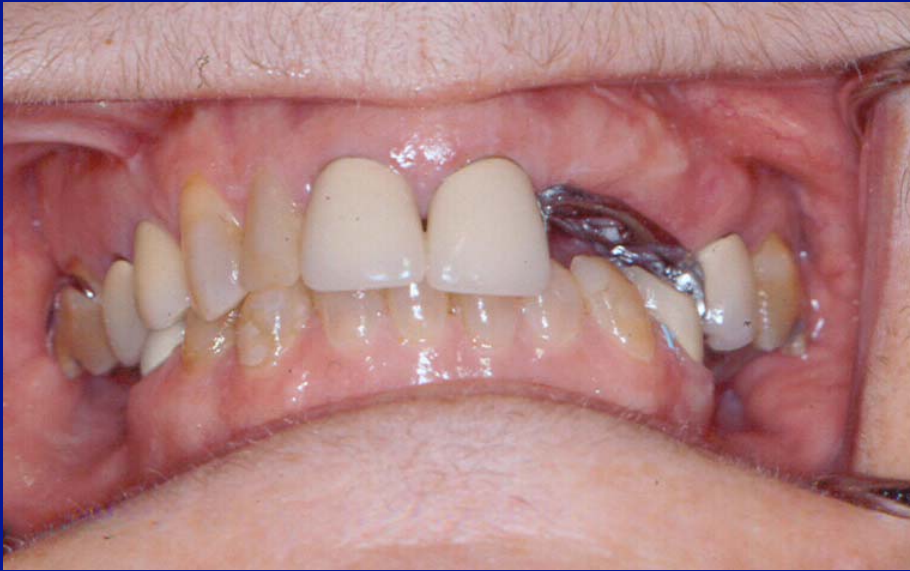
Lateral Category II

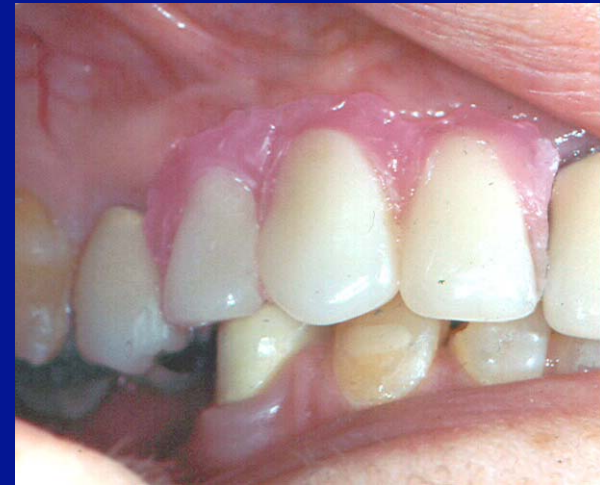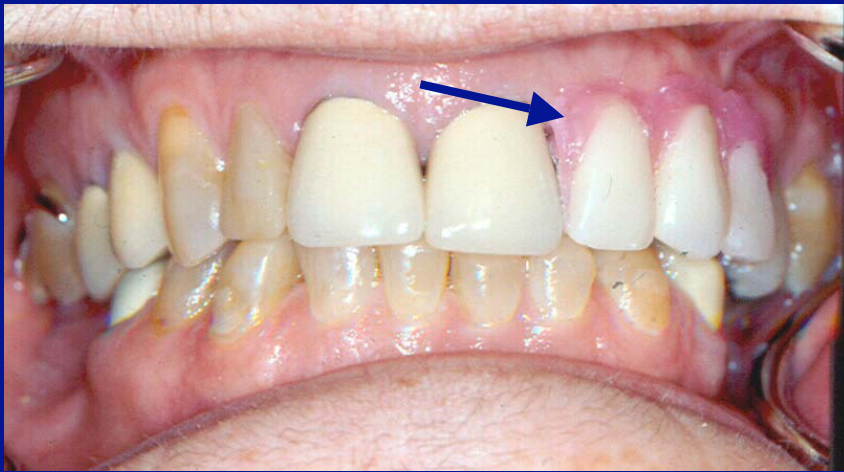


Framework Design

Lateral Category II

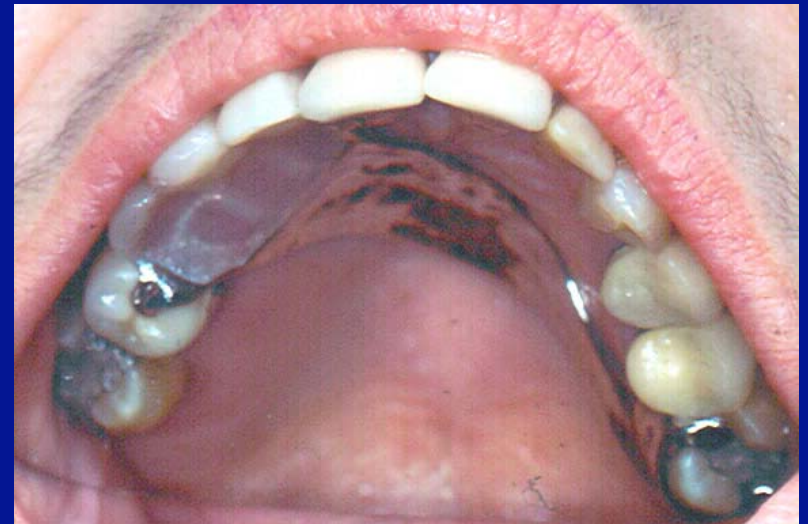
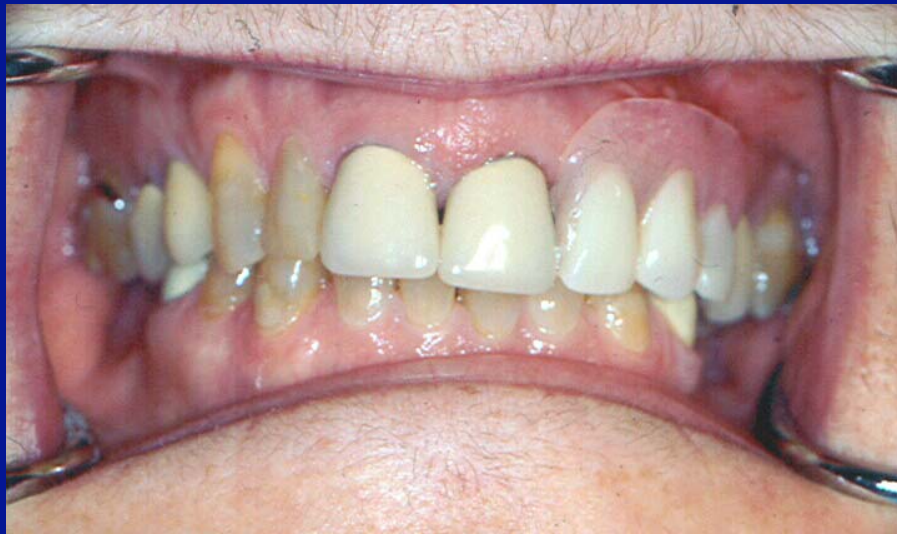
Lateral Category II

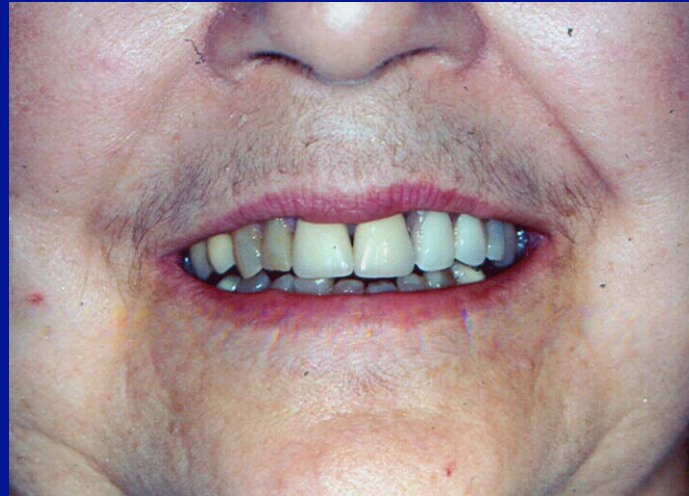

Try-in

Lateral Category II



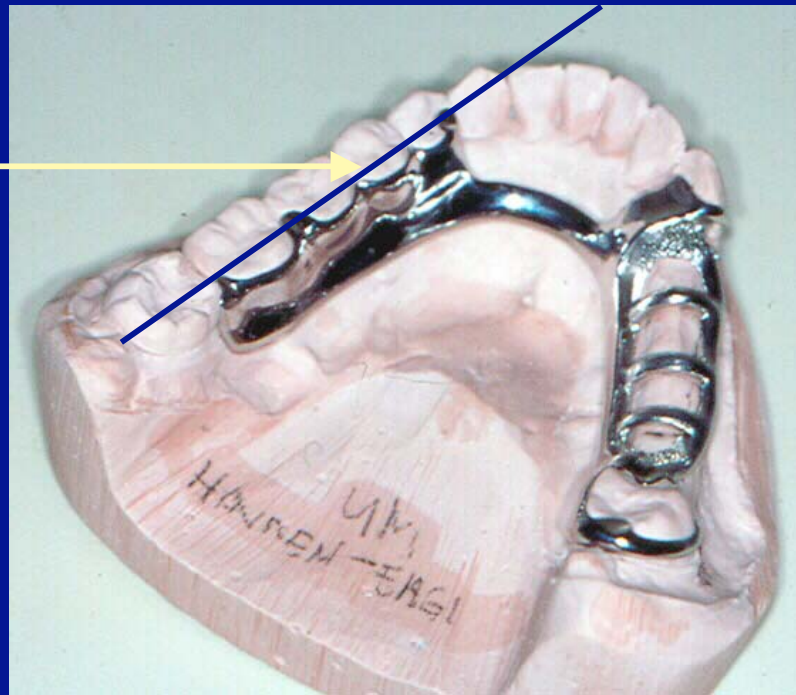
Lateral
Category II



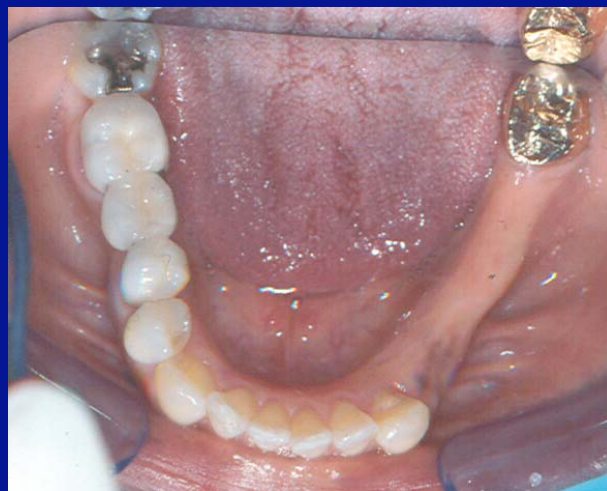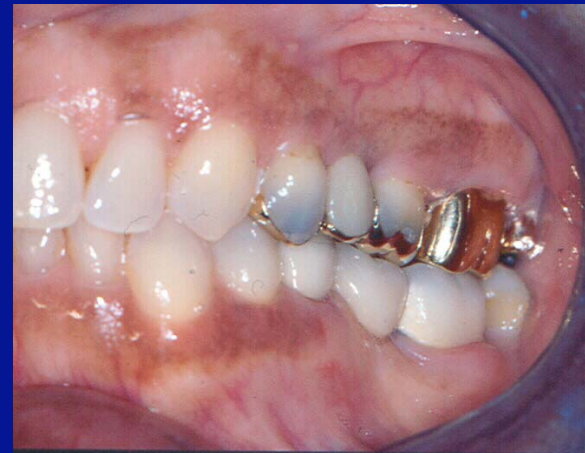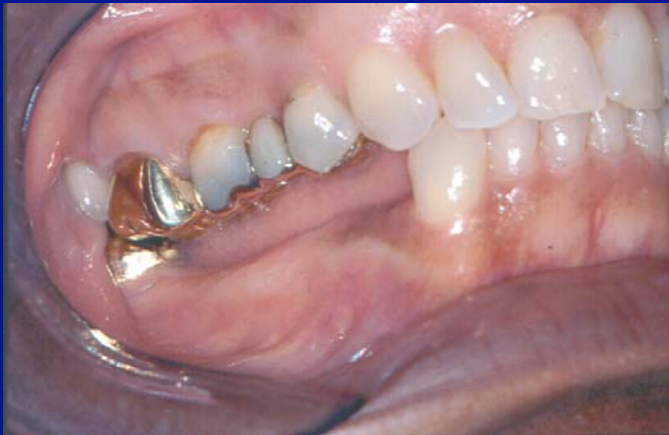Final Result

Lateral Category I

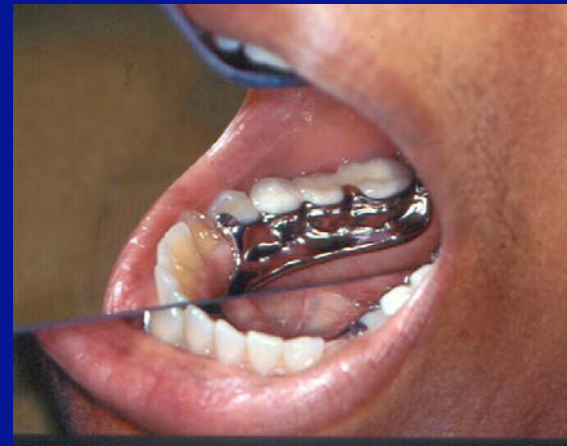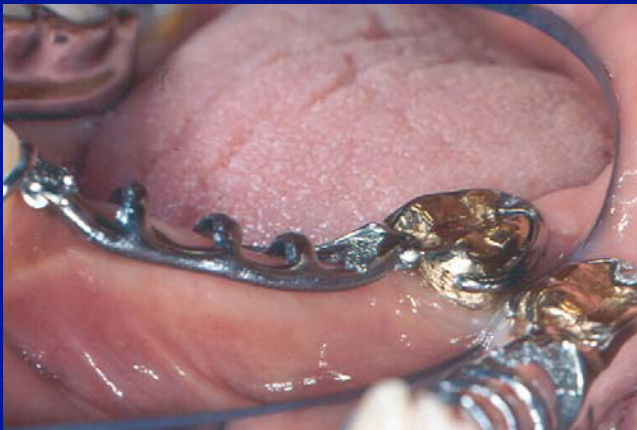
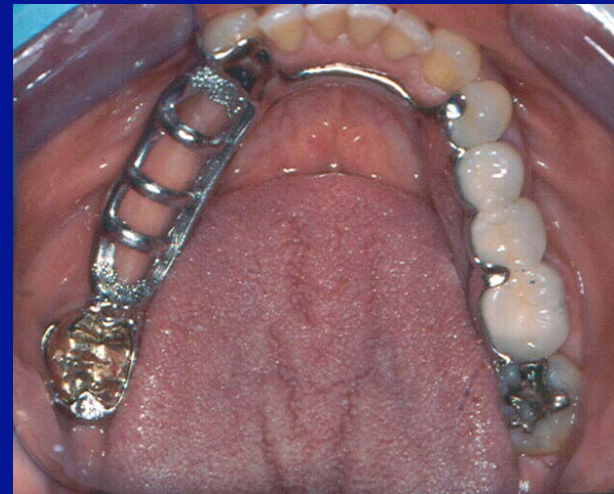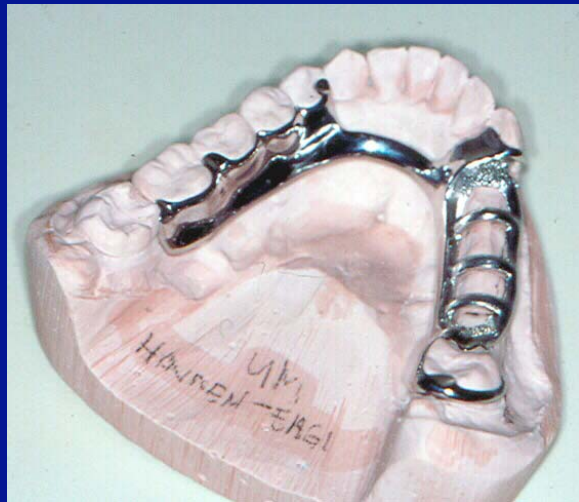Rotational Axis



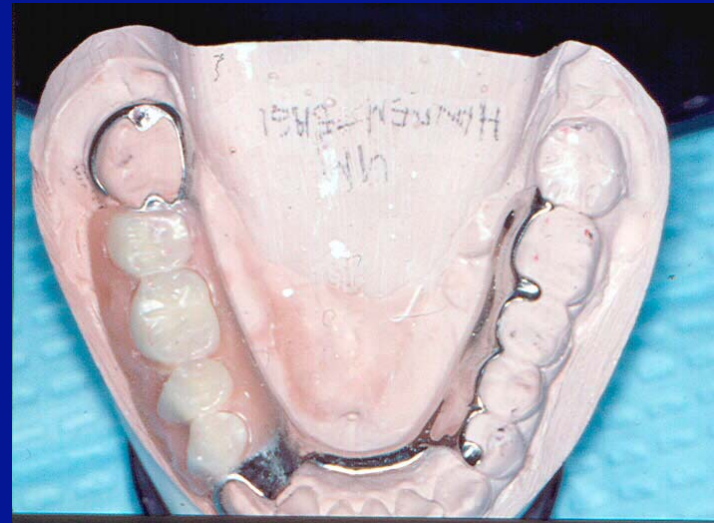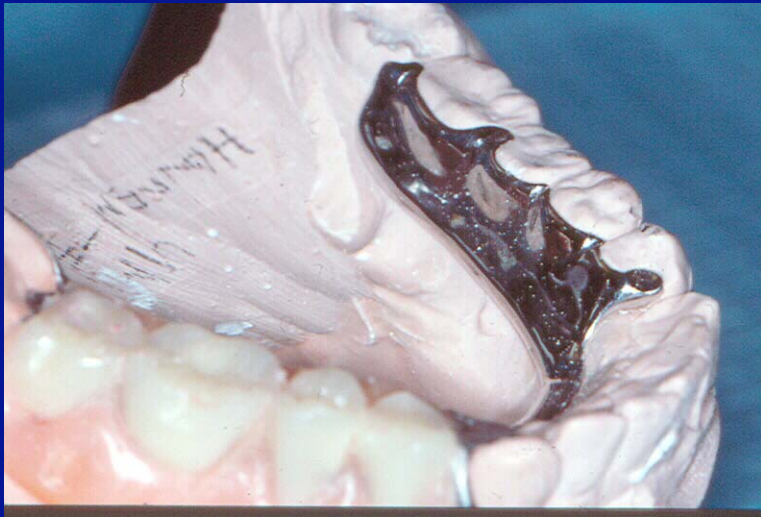Lateral Category I



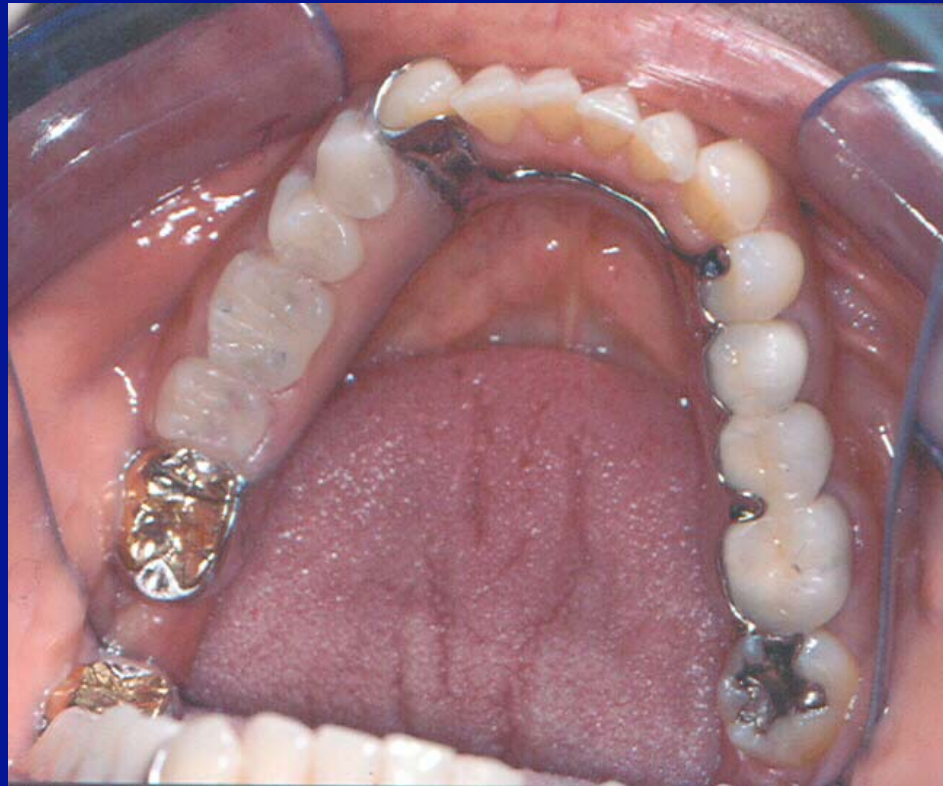Lateral Category I



Lateral Category I

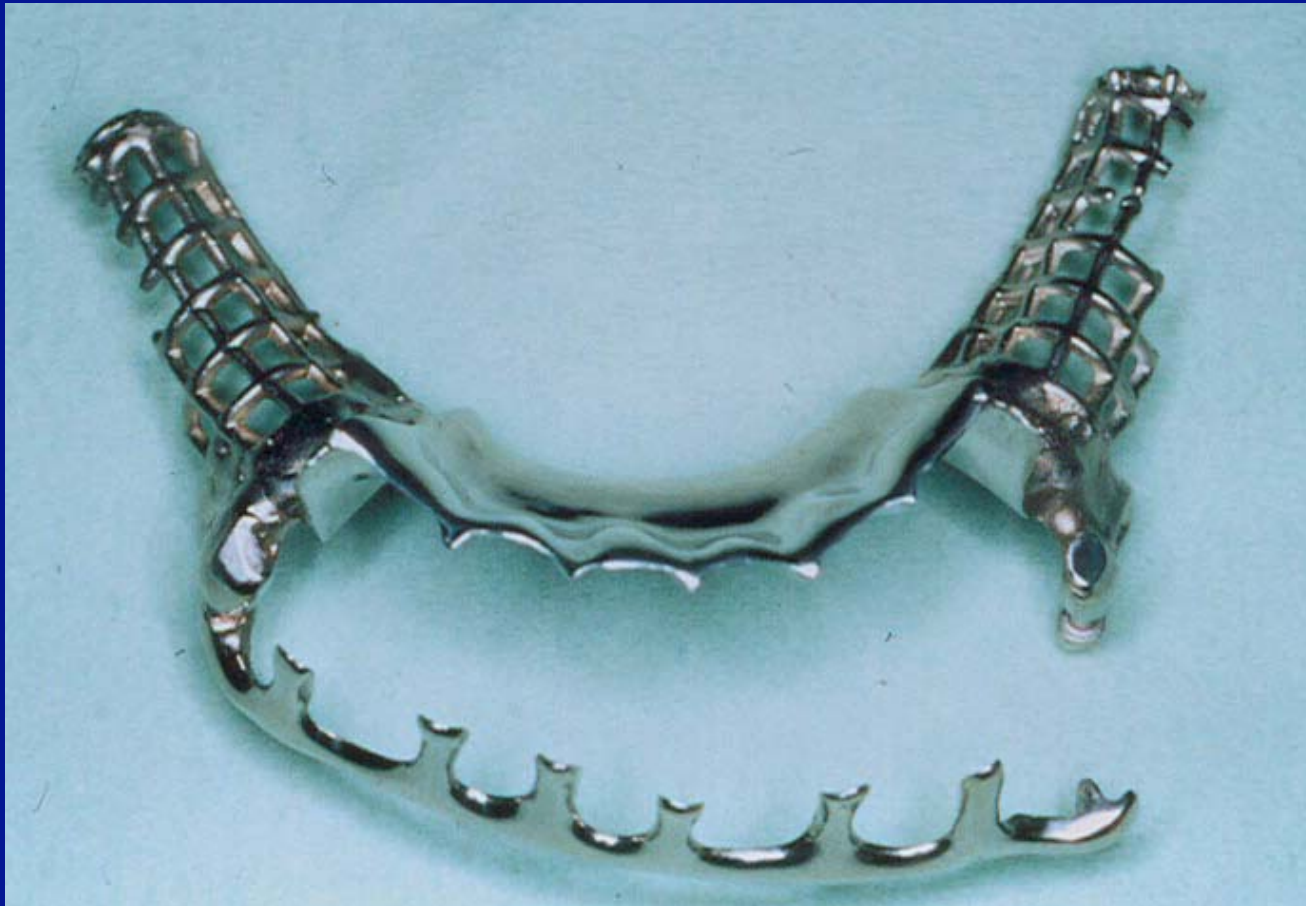

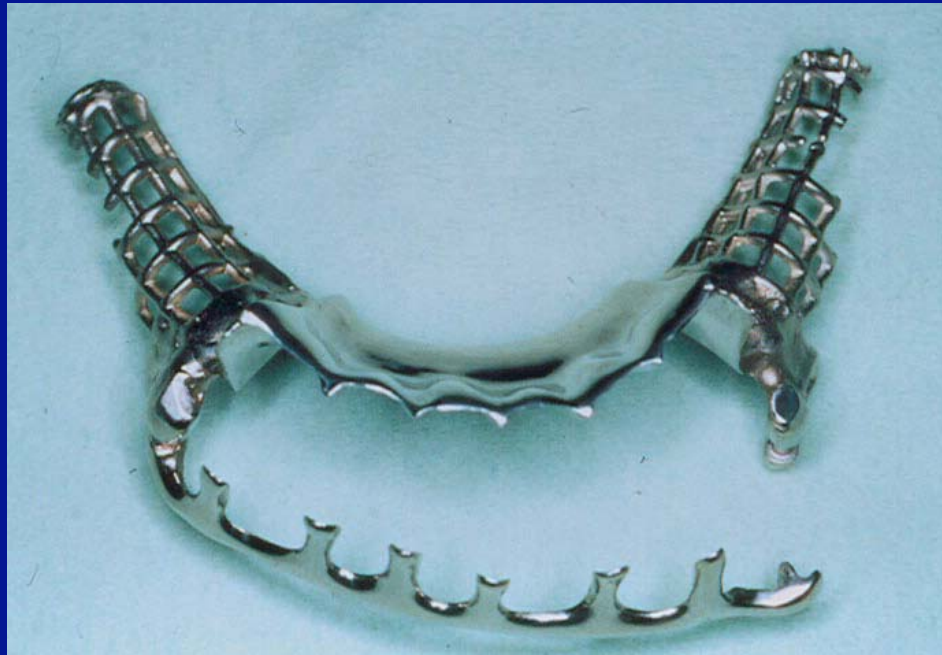Lateral Category I



Final Result

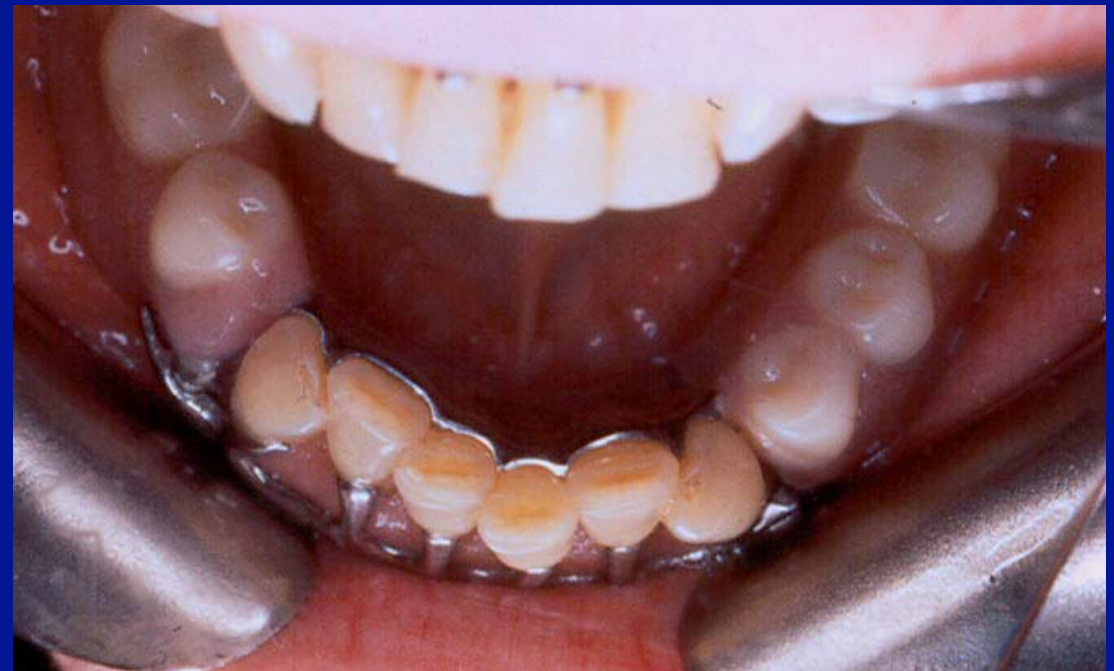Swinglock Removable Partial Denture Treatment

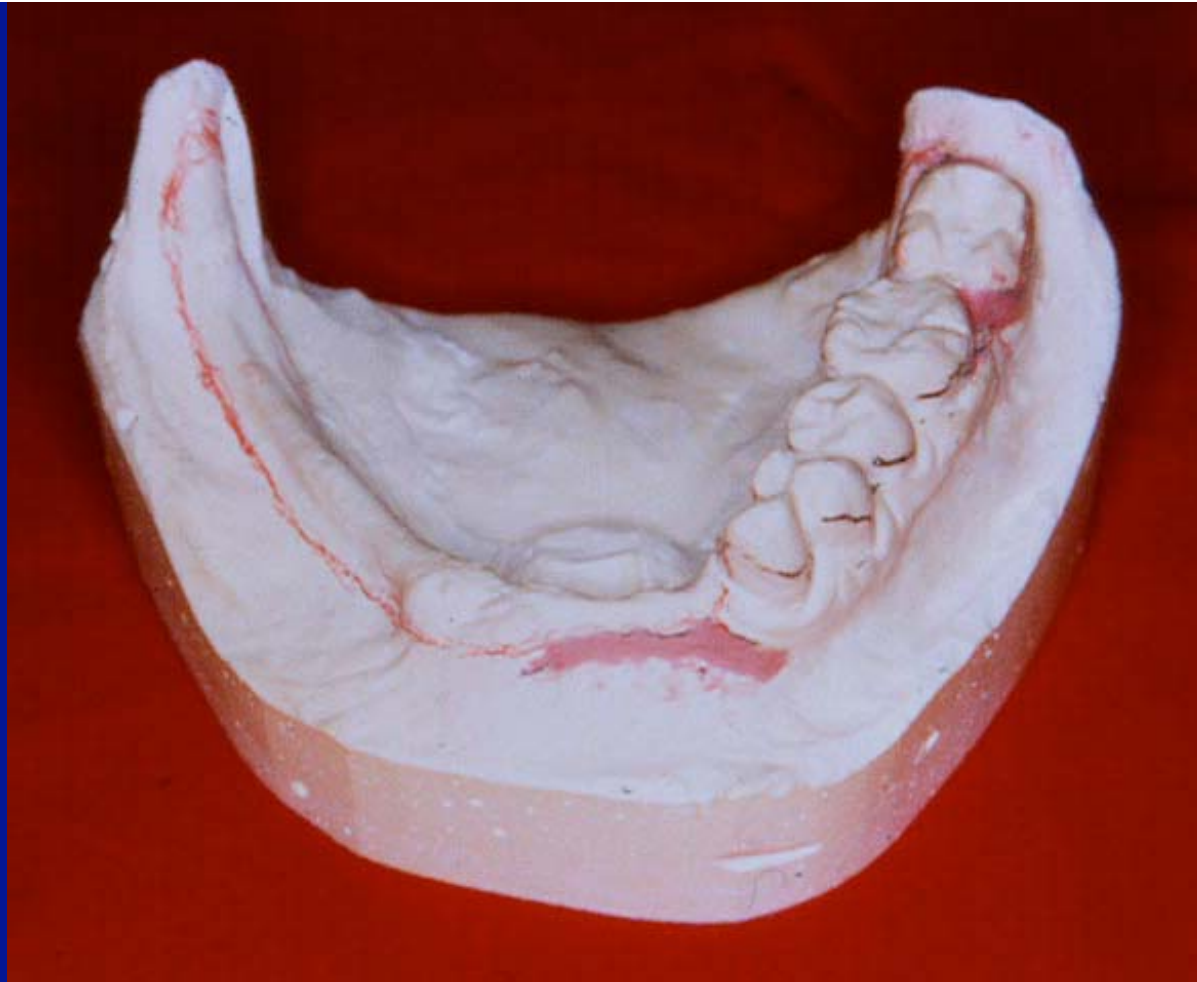



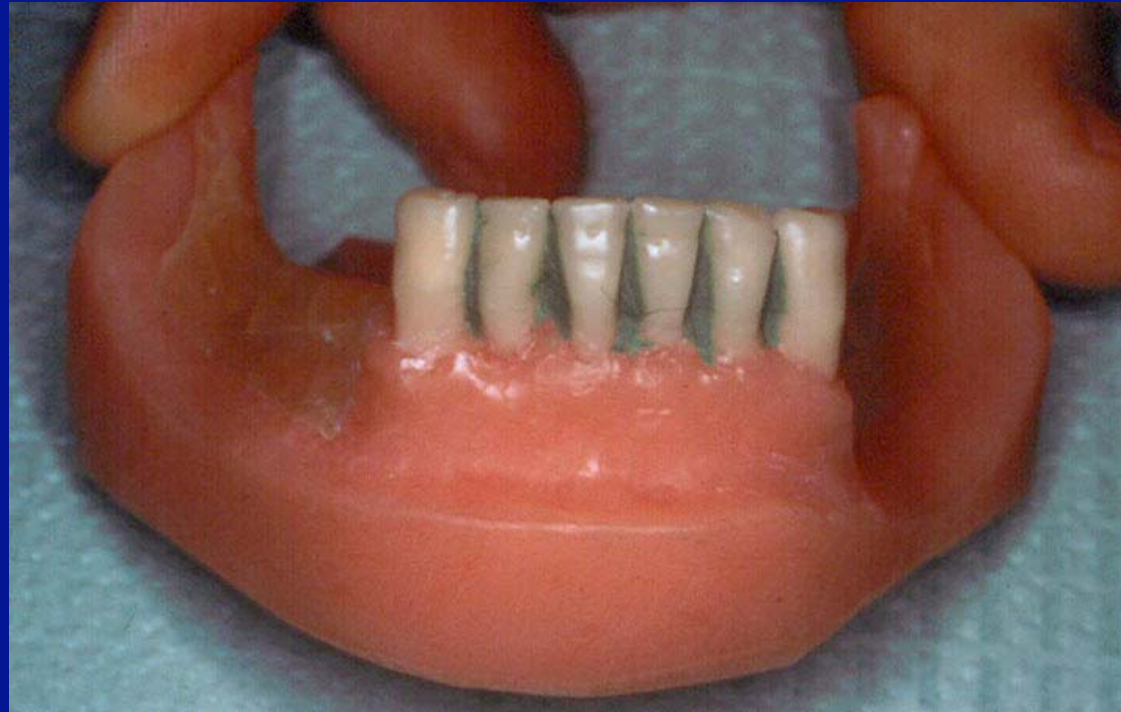Though less expensive than implants, this type of framework is significantly more expensive from the dental laboratory. Typically the cost will be \$200-\$250 more than a conventional framework.

Looking at the intraoral view at the right, could other options have been used? Six anterior teeth with slight to moderate crowding.

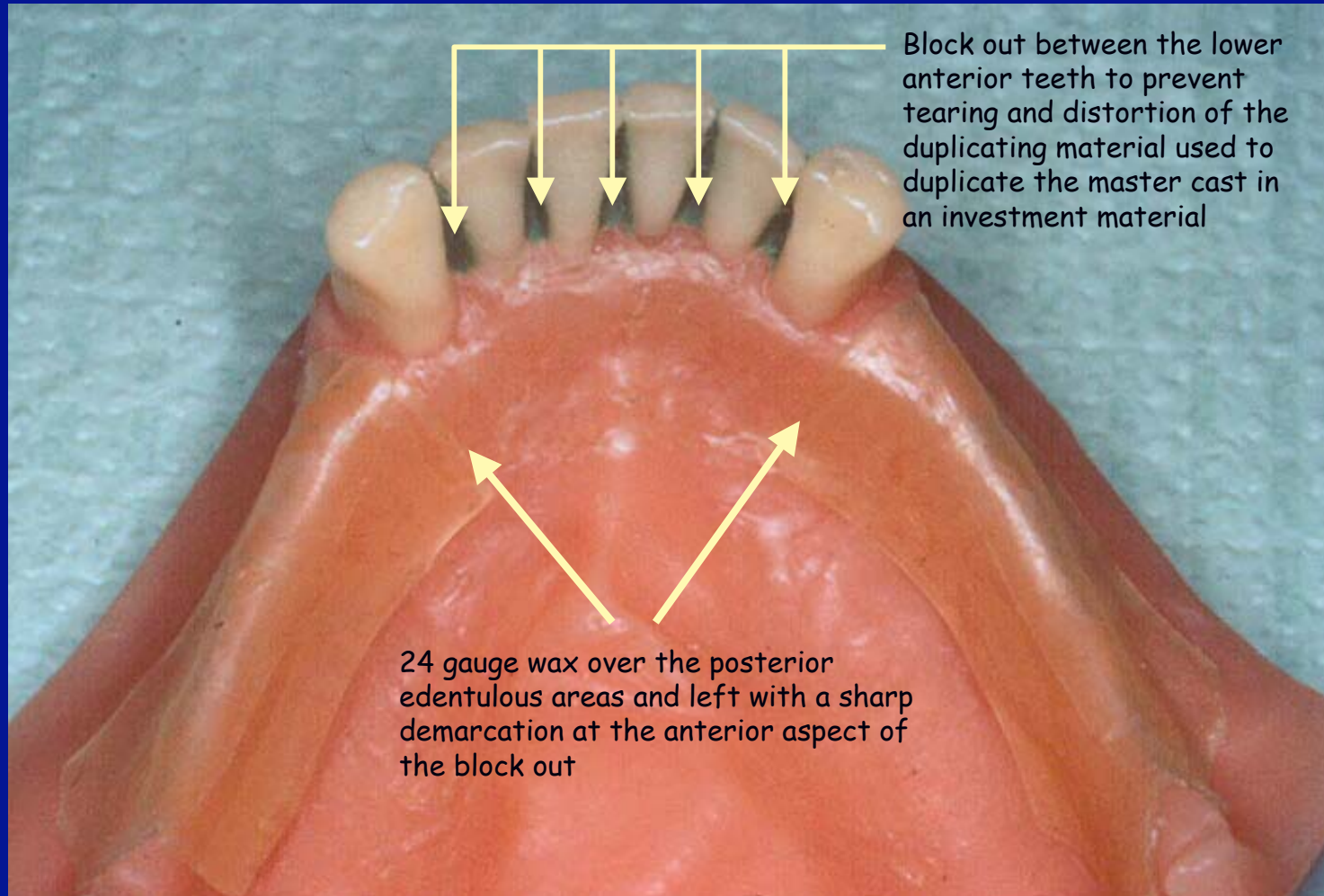




This is another example of a patient situation that may be suited for a swinglock RPD. Here again, are there other designs which would work?



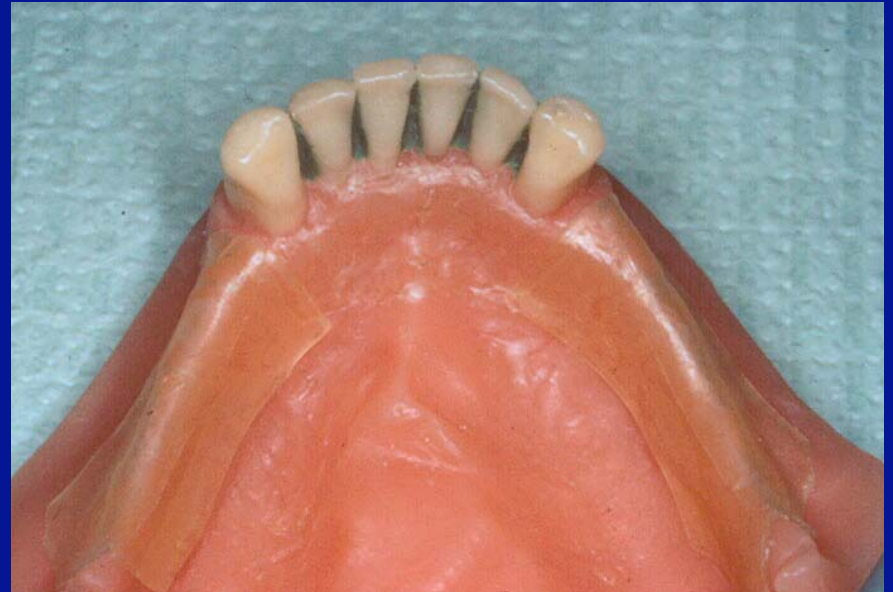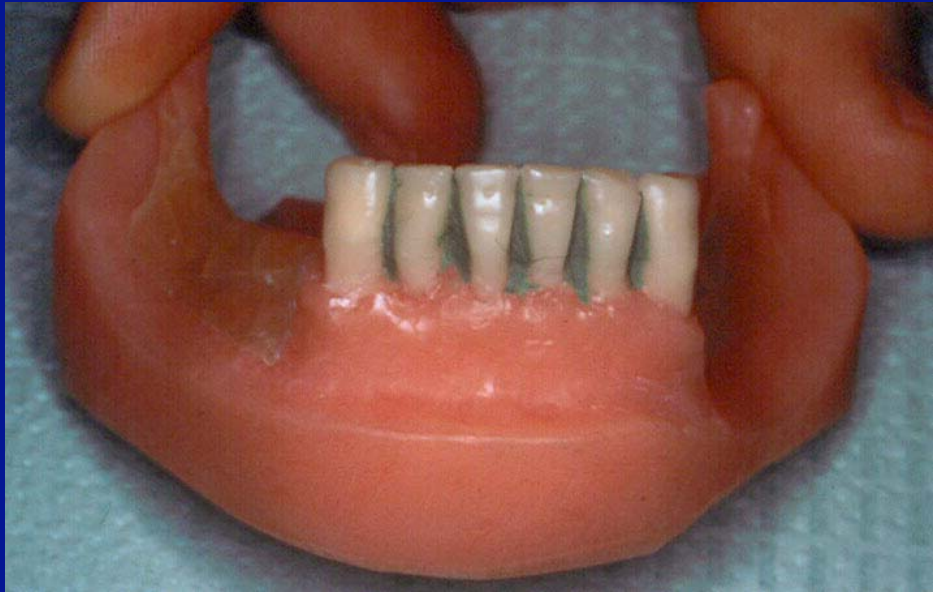This acrylic cast was duplicated from an actual patient treatment model to demonstrate the fabrication of a swinglock RPD framework.



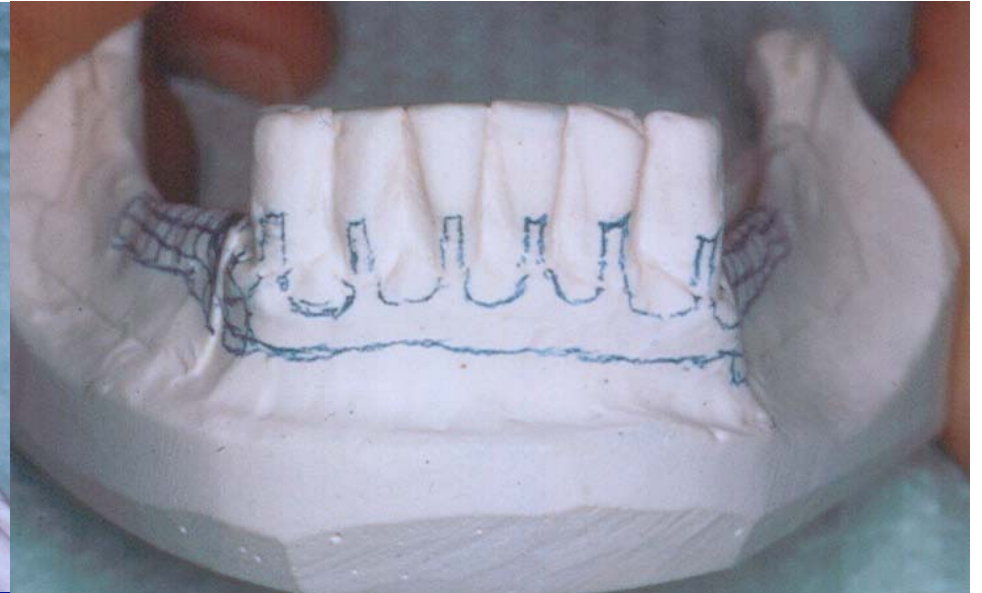
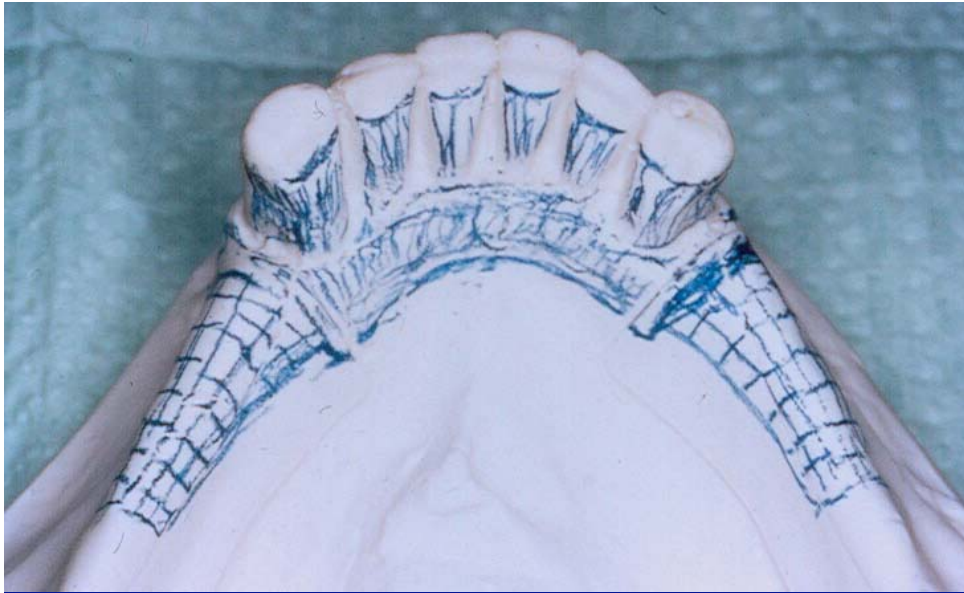Block out between the lower anterior teeth to prevent tearing and distortion of the duplicating material used to duplicate the master cast in an investment material

24 gauge wax over the posterior edentulous areas and left with a sharp demarcation at the anterior aspect of the block out

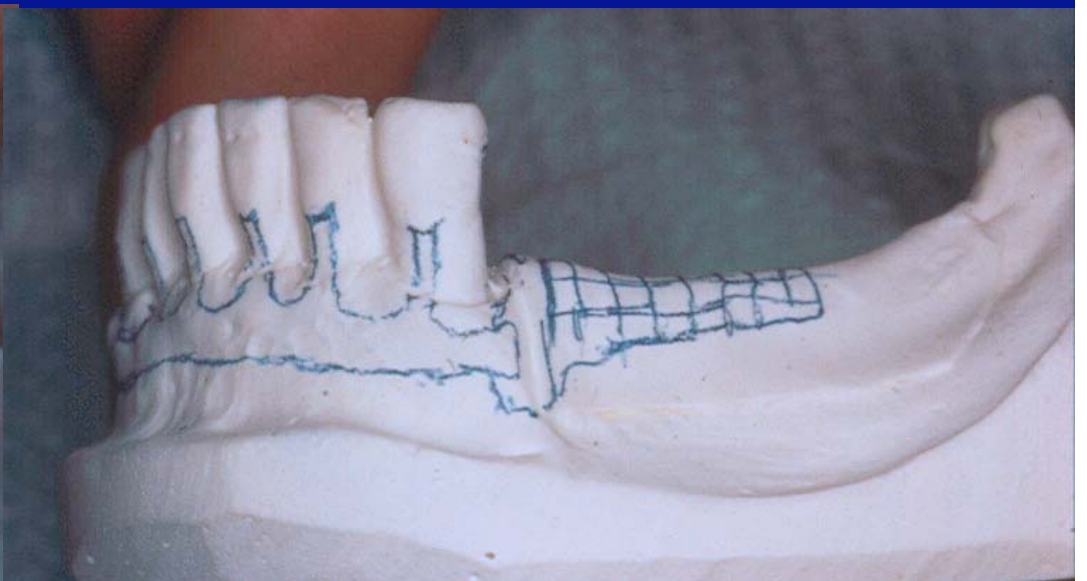
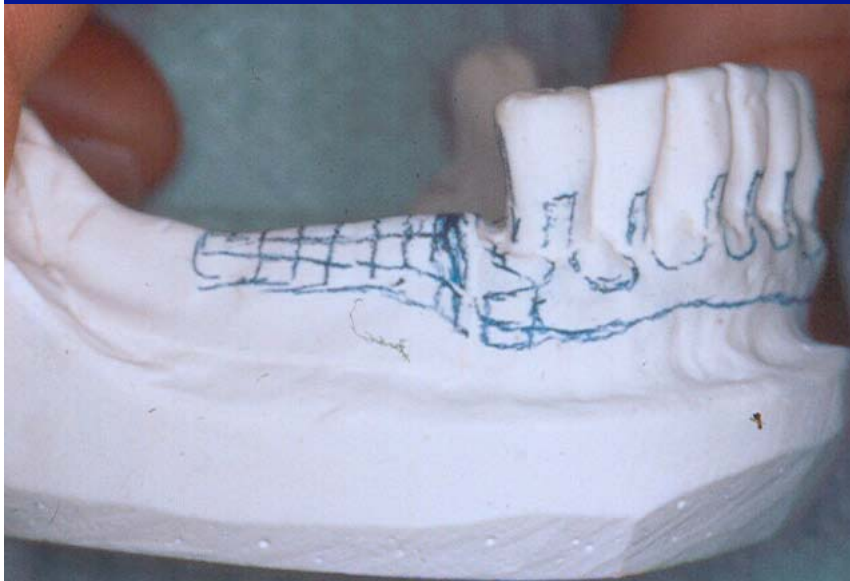
The block out of the master cast (normally done on an improved stone cast)




The blocked out cast ready for duplication. Remember, this would usually be done on a cast poured in improved stone (Jade Stone or another Die Stone) These examples provide a better example for the sake of this presentation.

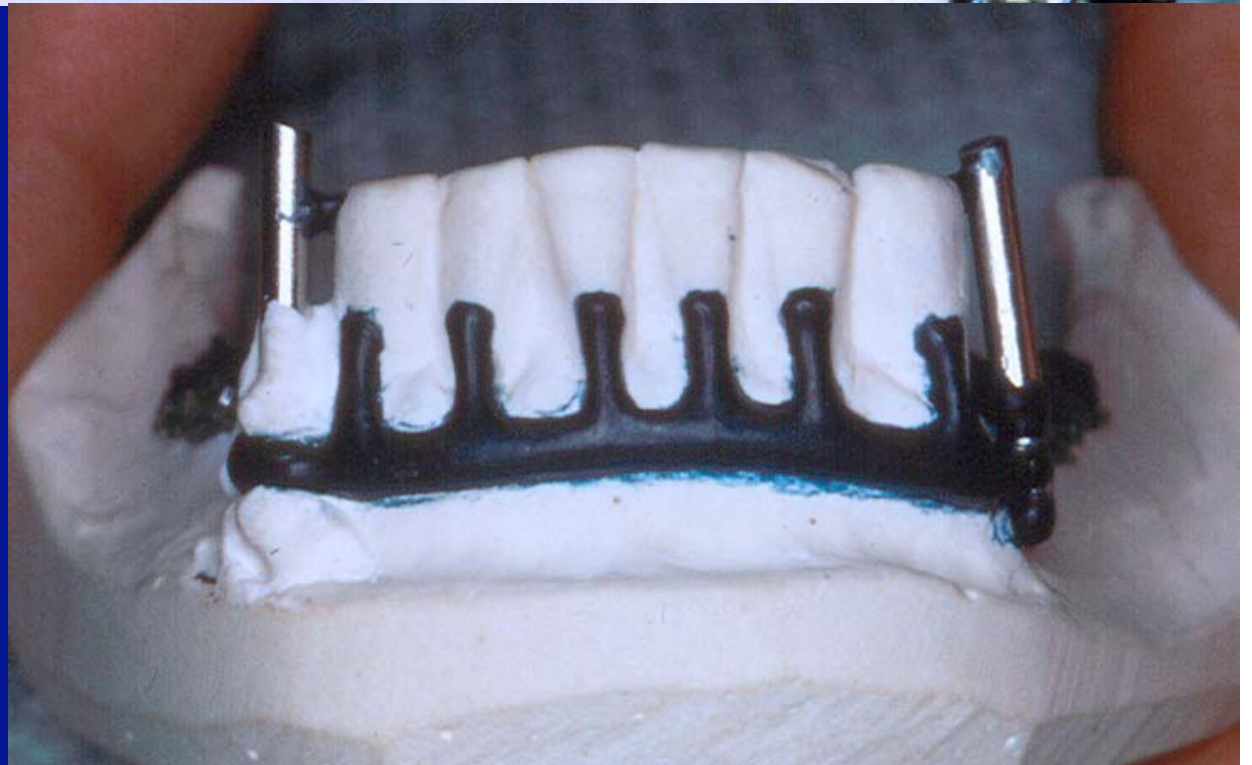


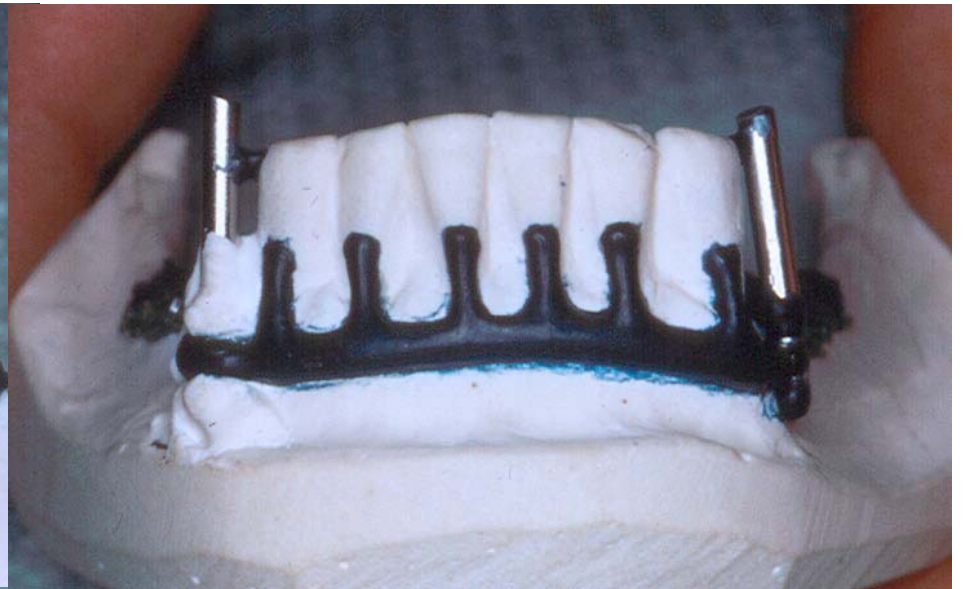
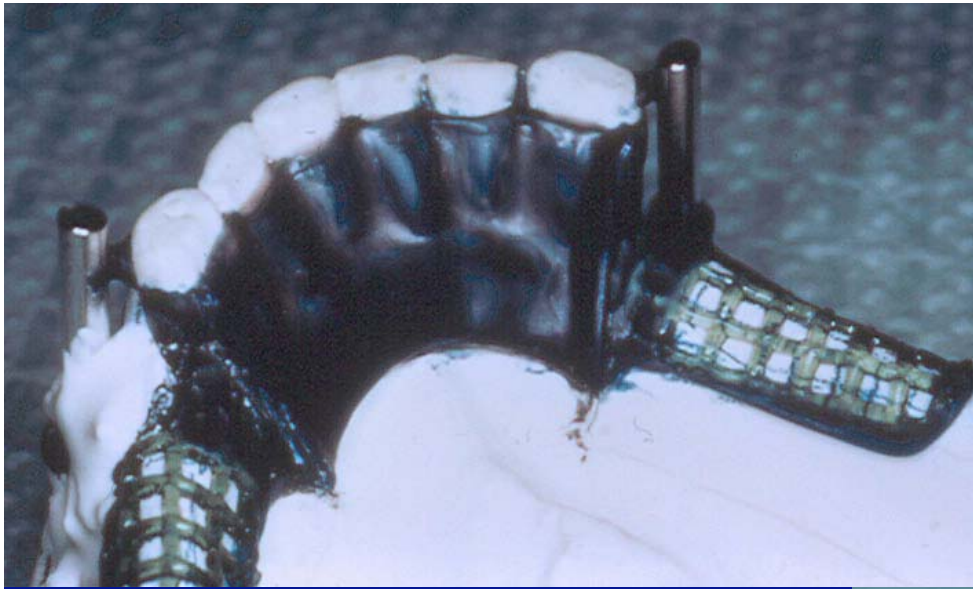
The framework design is drawn on a study cast to guide the laboratory with the fabrication of the framework.



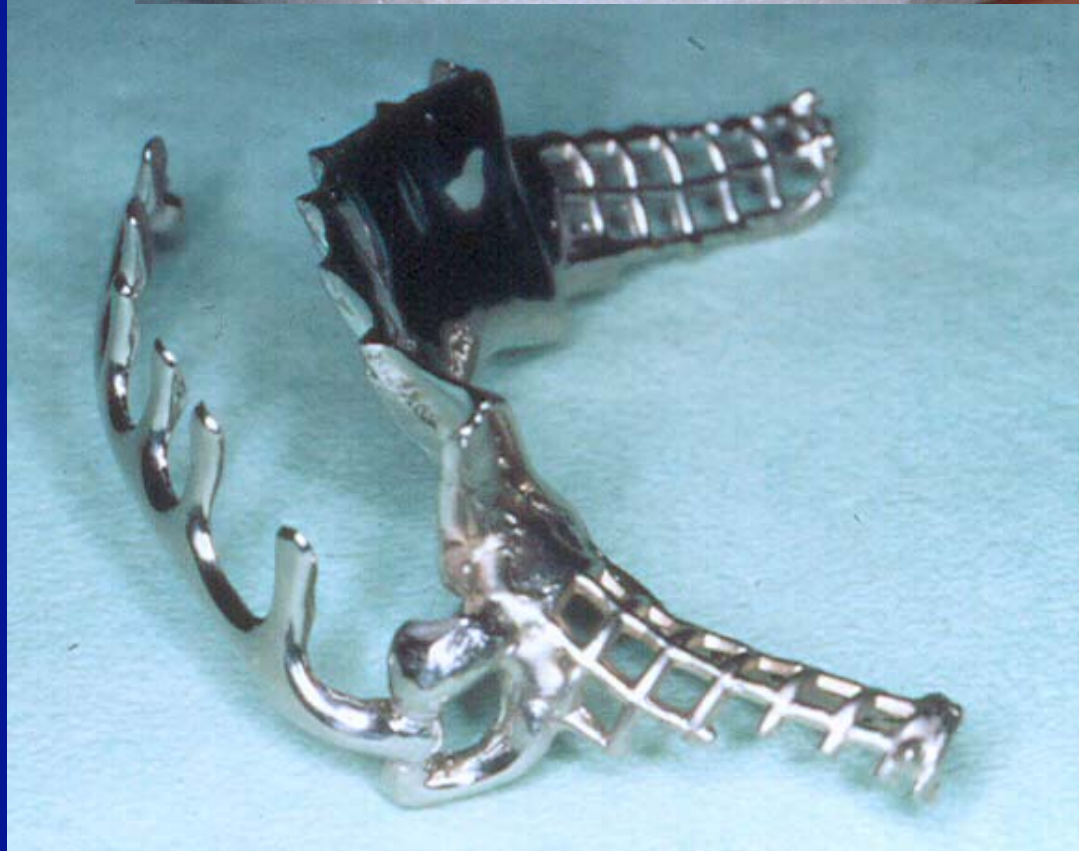

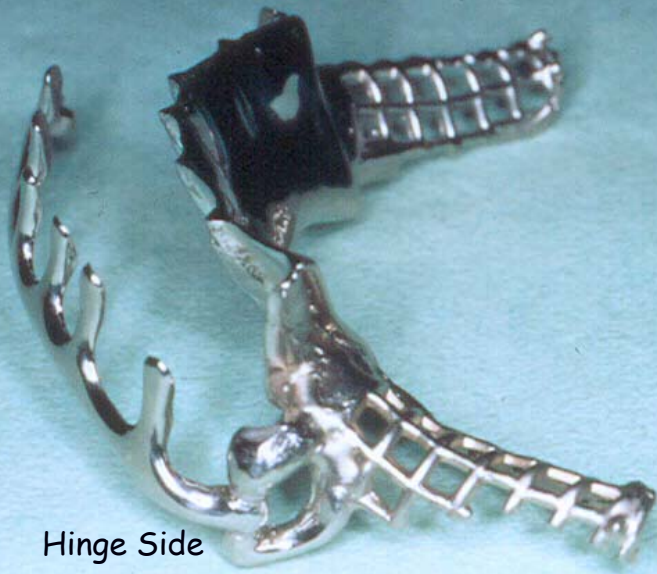The wax up of the framework seen here is performed on a cast made of refractory material not dental stone. This is a duplicate of the blocked out master cast.



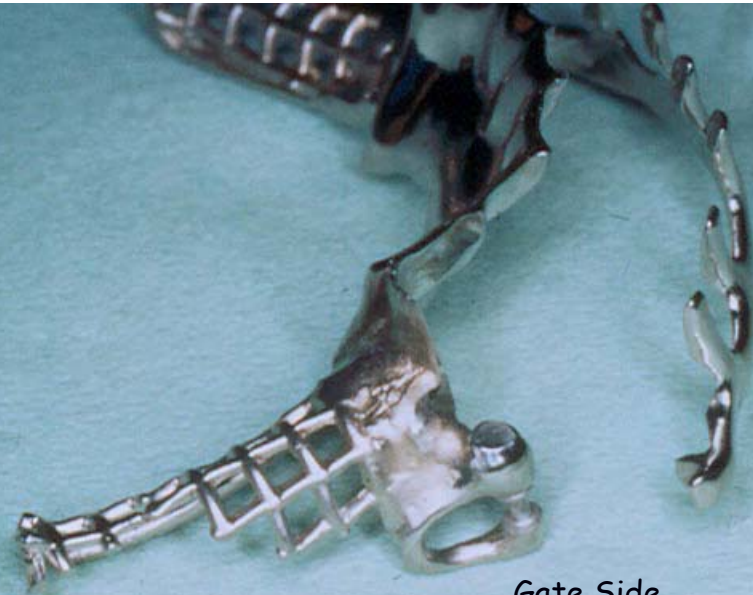

Once the wax up is completed, it is surrounded by more refractory material, placed in a burn out oven and cast in a Cr-Co alloy. After finishing, you have the polished framework seen at the right.

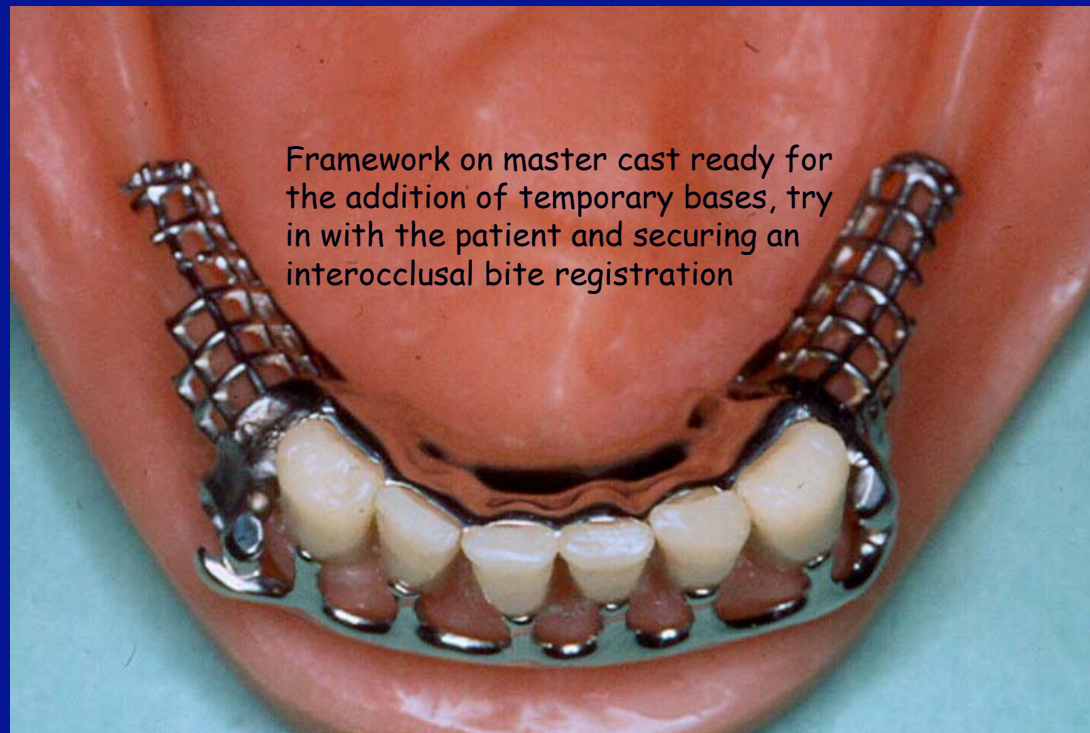




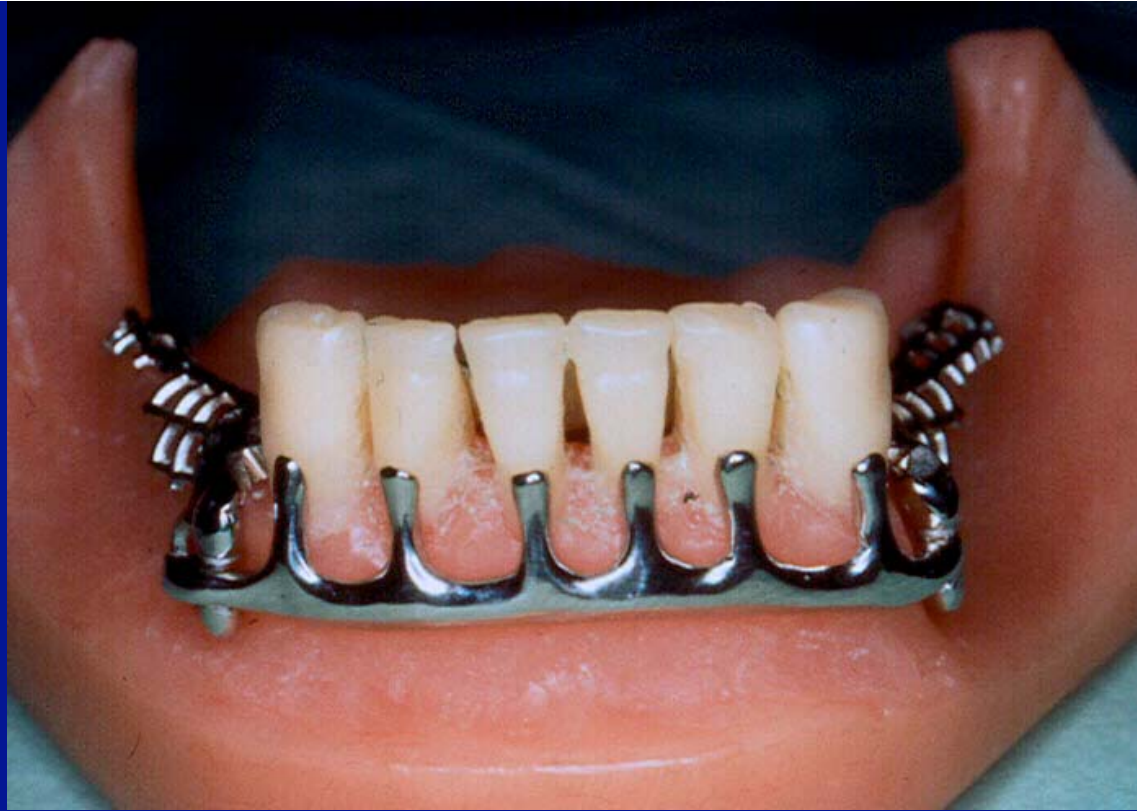Hinge Side



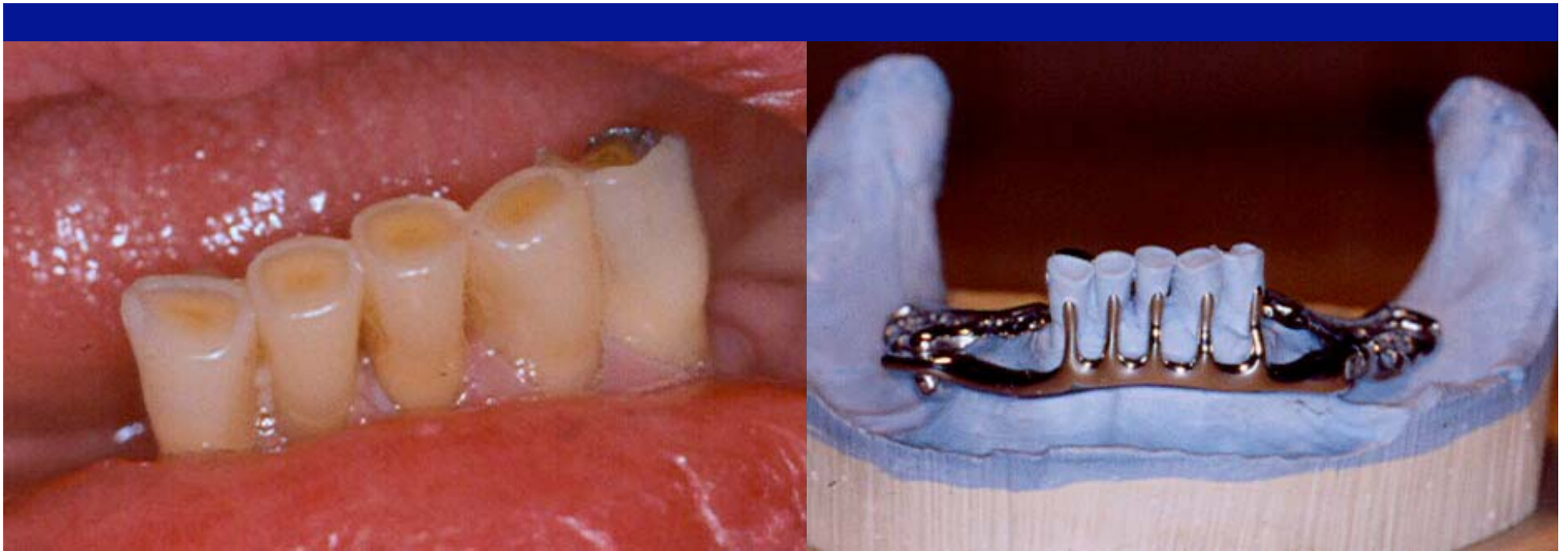
Gate Side



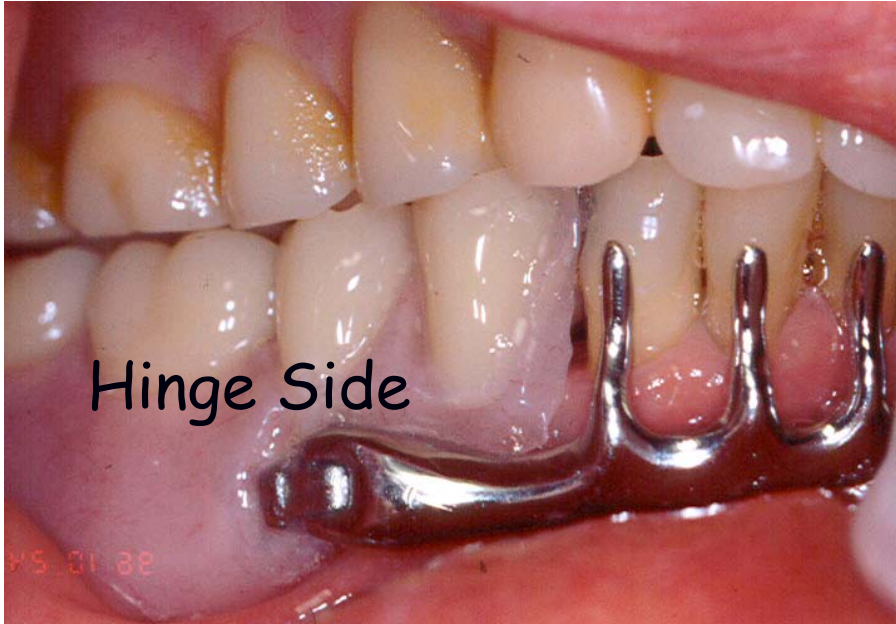Framework on master cast ready for the addition of temporary bases, try in with the patient and securing an interocclusal bite registration



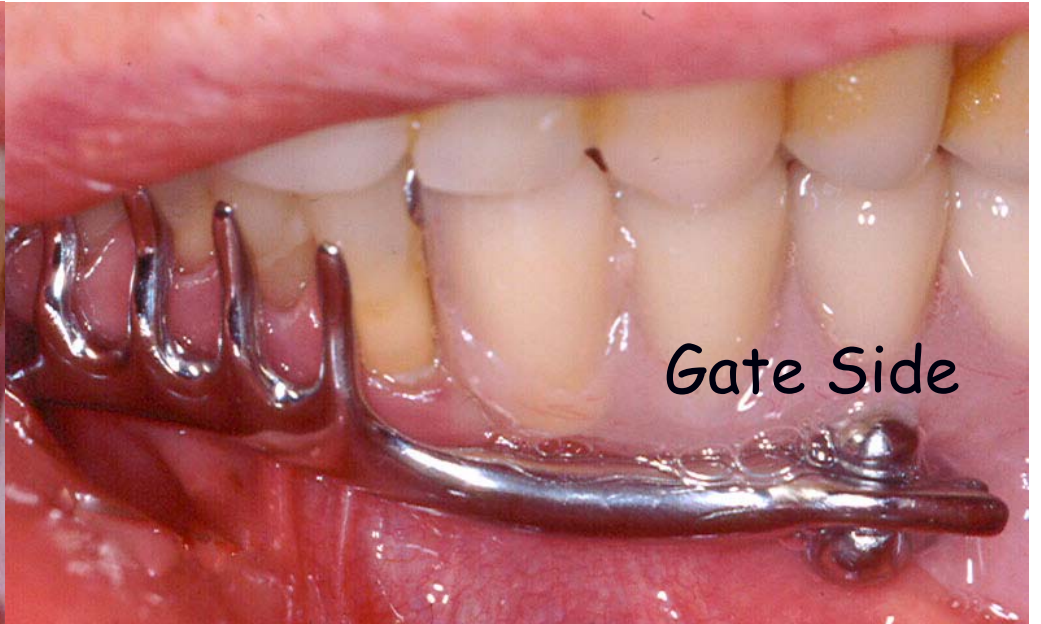
This view shows why lack of vestibular depth is a problem with this type of appliance. Also, you want to see if the patient is right or left handed when determining which side to put the hinge on. Why?



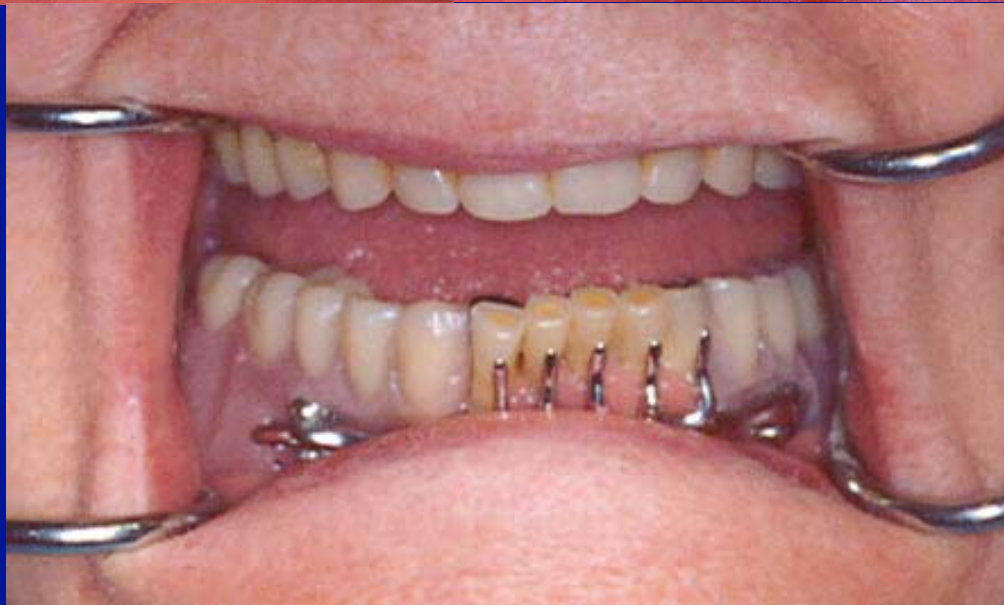A clinical example. Note how the hinge and gate are held back from the anterior teeth to allow room for the components. Why not place them immediately adjacent to the anterior teeth?



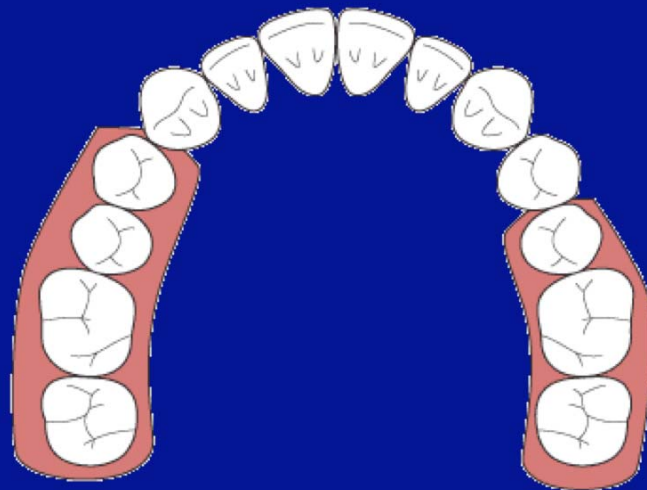
Hinge Side



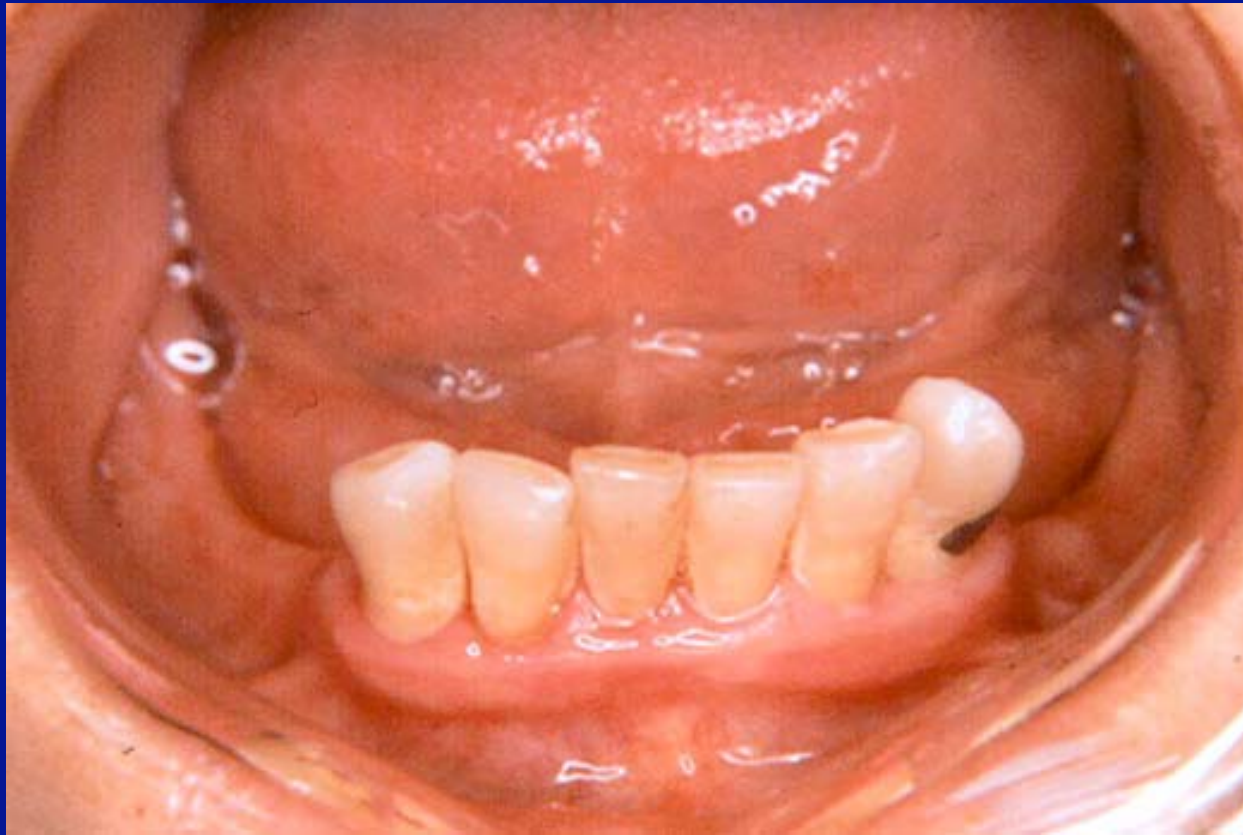
Gate Side



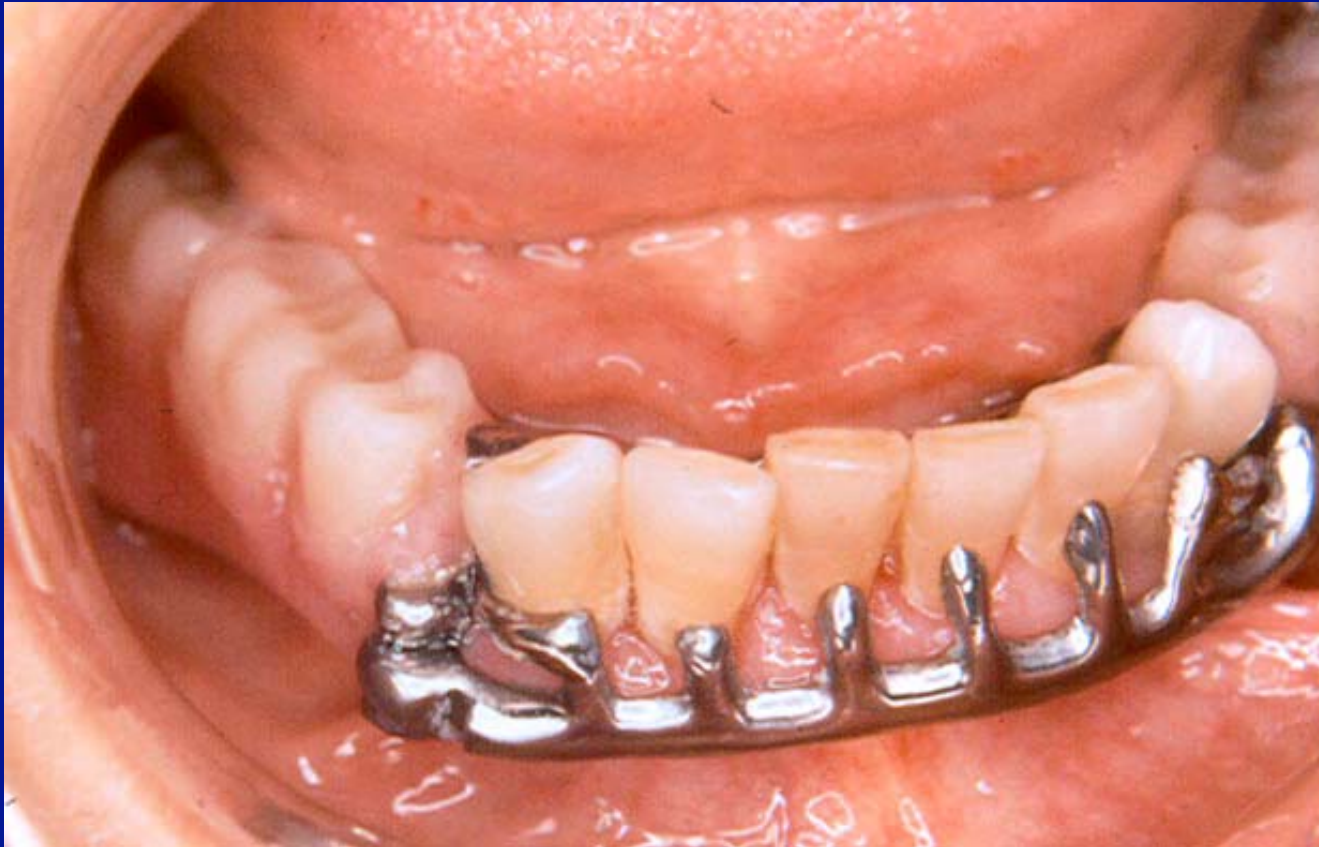Completed Treatment



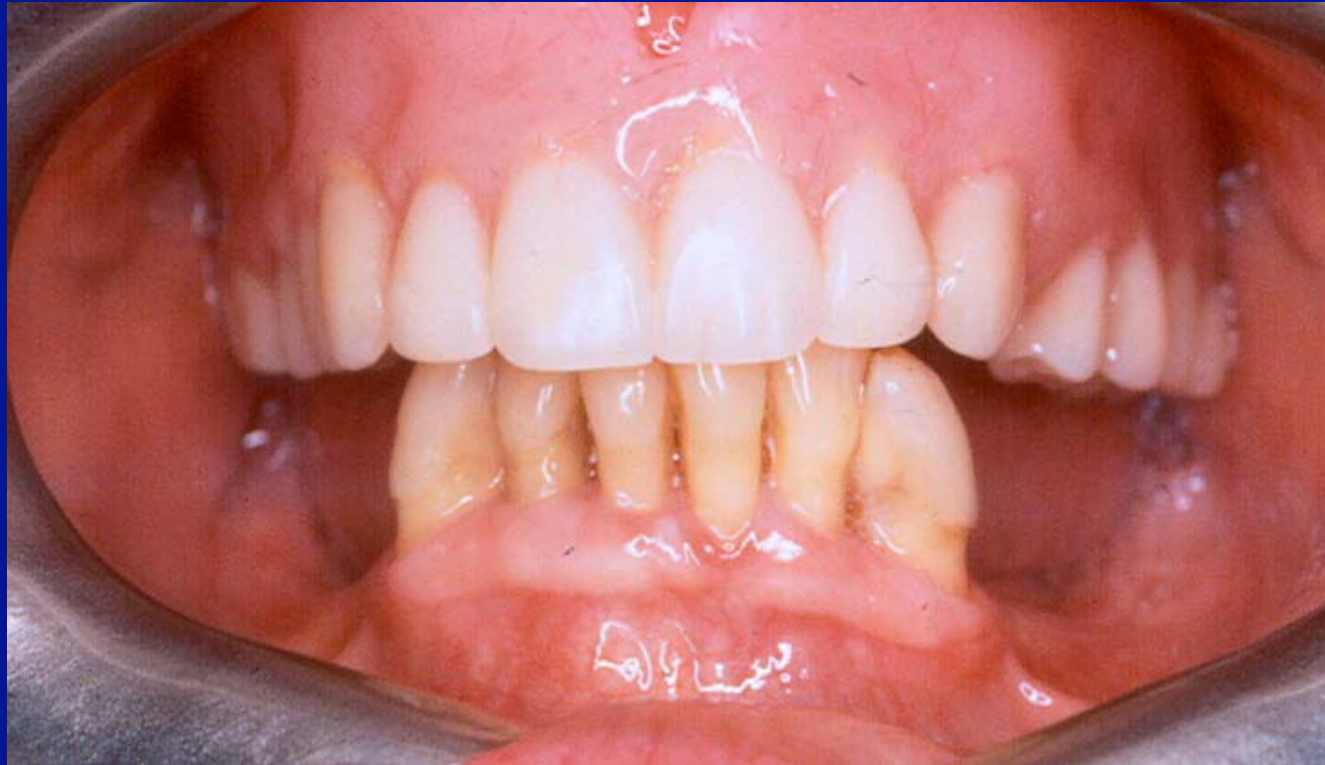
Further Examples Of Class I
Swinglock RPD's



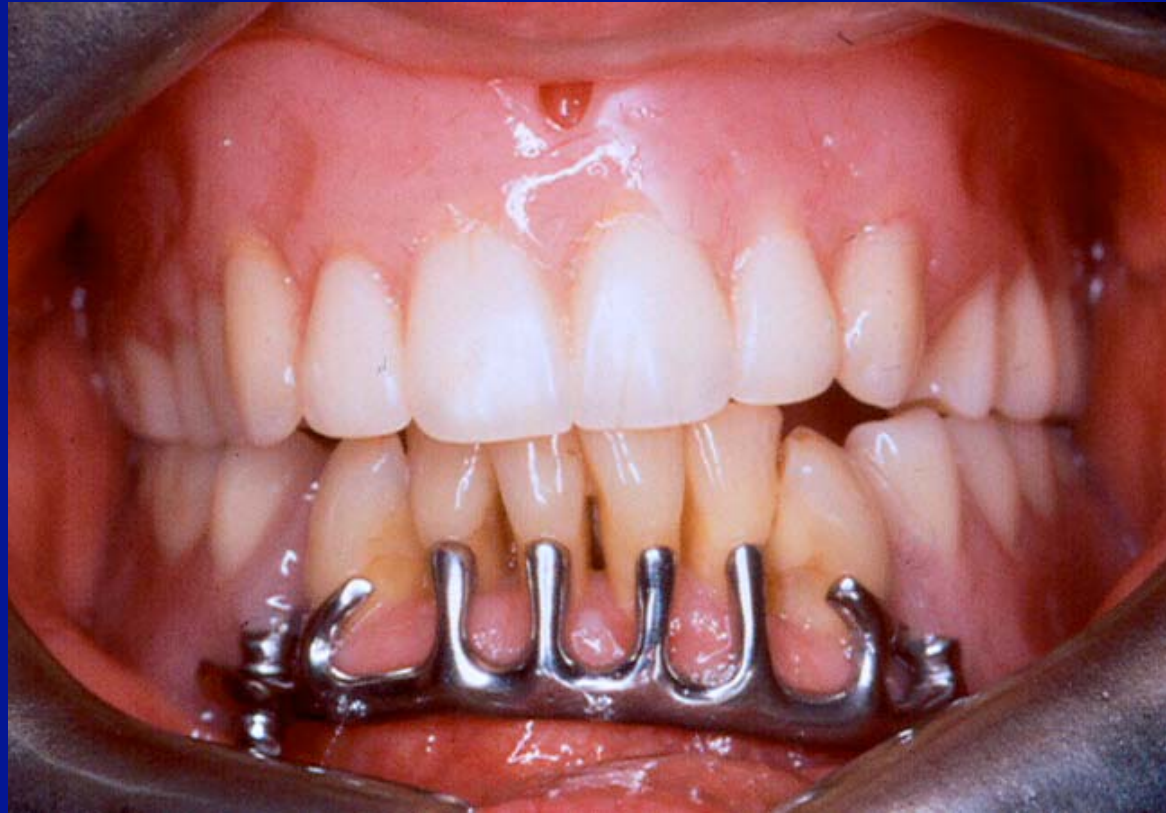In this patient, the remaining anterior teeth are both labially tilted and #22 and #27 are rotated. If these teeth were to be recontoured to make a conventional clasp partial possible, there would need to be extensive reshaping of #22. Due to the labial tilt and the rotation of the potential abutment teeth, a swing lock partial may be desirable here.



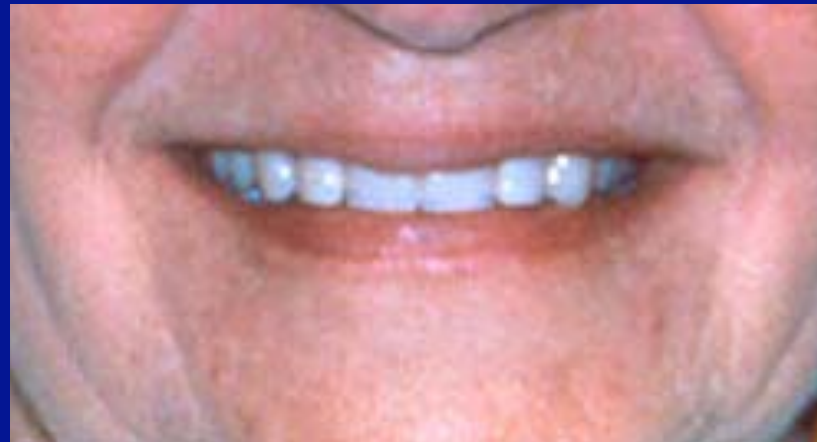As you can see, the swing lock gate has "fingers" which contact the labial surfaces of the anterior teeth. Most are in the configuration of an I bar and the finger on #27 is in the shape of a modified T bar clasp.



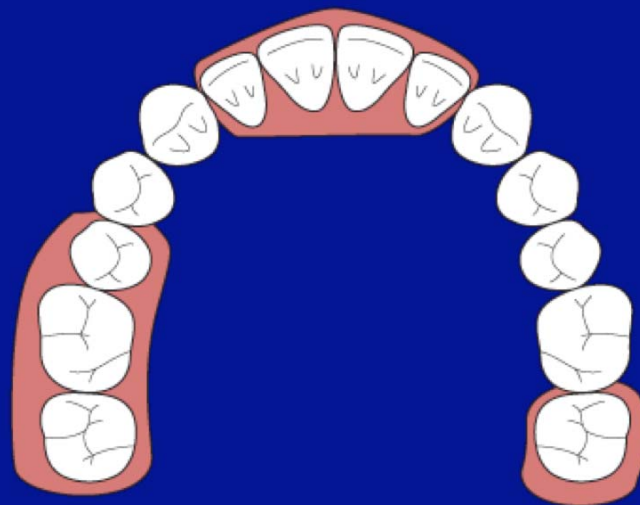
Upper complete denture for the patient. Note the plane of occlusion of the upper appliance. Fairly level and oriented from the anterior teeth to the approximate center of the retromolar pad in an A-P direction.



Note that the fingers on the gate have similar shapes to the previous appliance reviewed. The side of the RPD which has the hinge should be reviewed with the patient depending on their ability to reach and manipulate the gate side of the appliance.

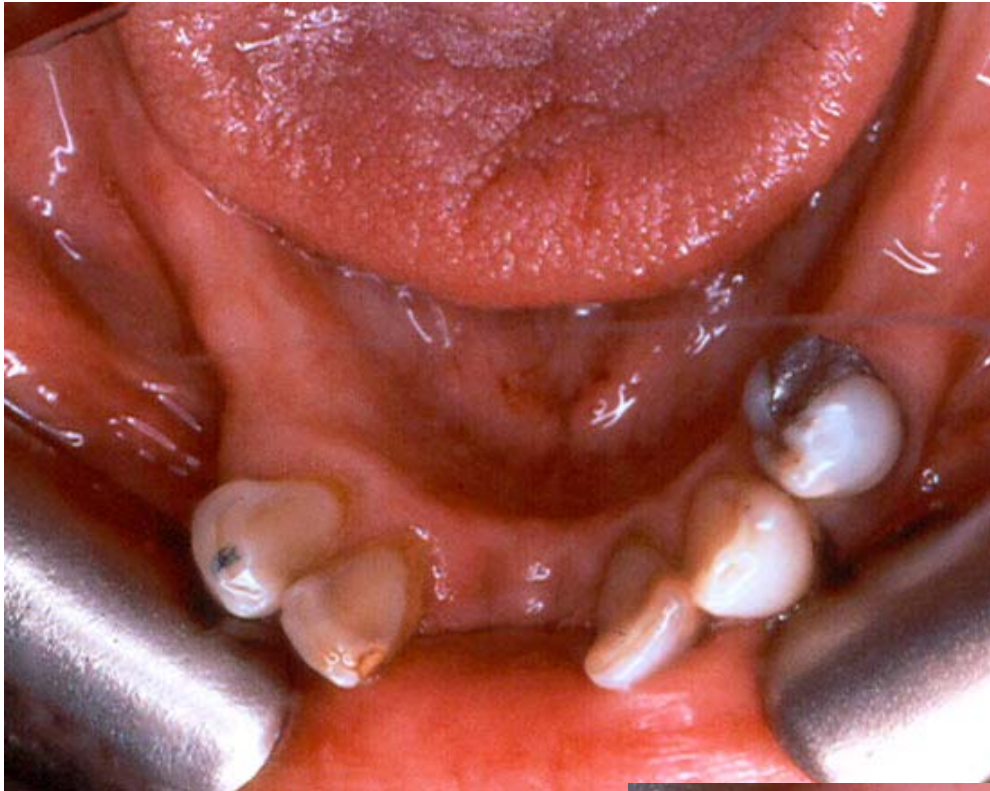


As you can see, the patient in full smile does not display the labial aspect of the lower removable partial denture.

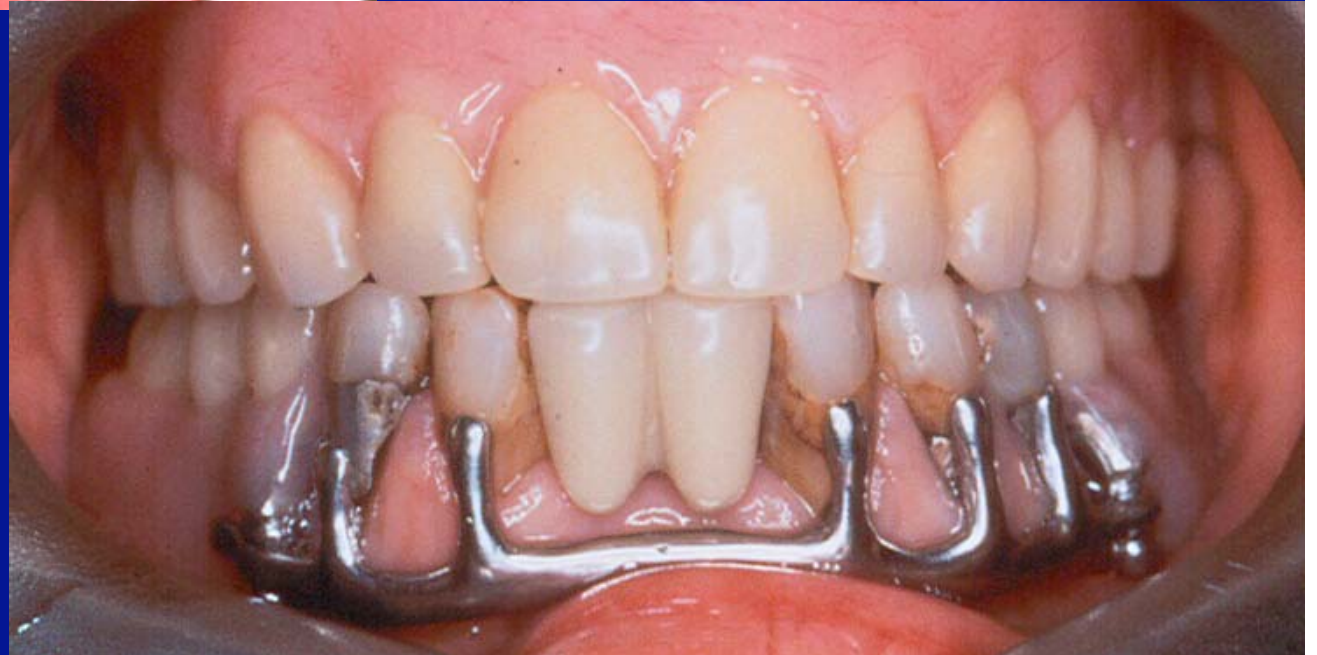

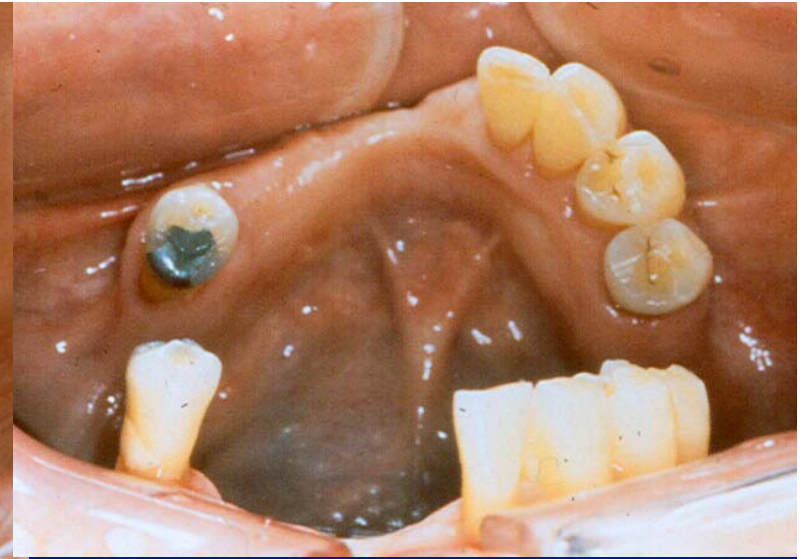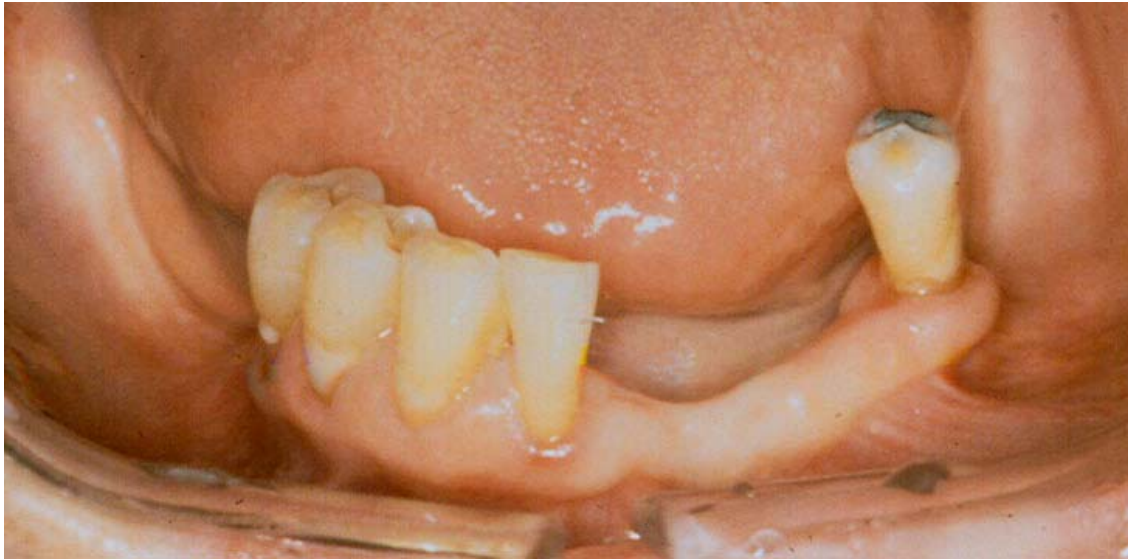Kennedy IA

Anterior Modification Space with the
Swinglock RPD

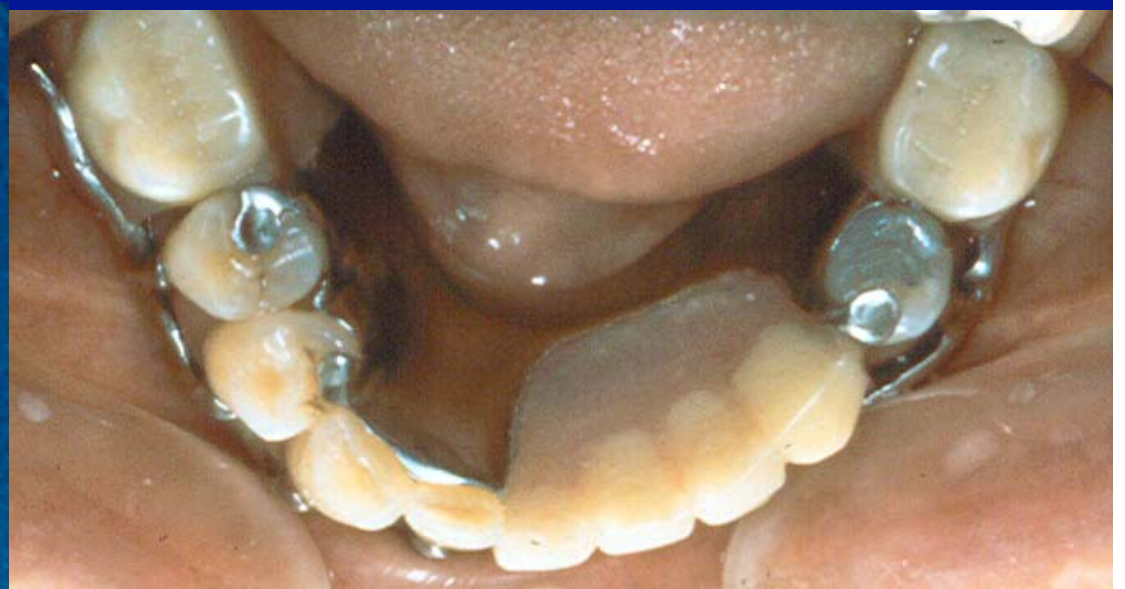
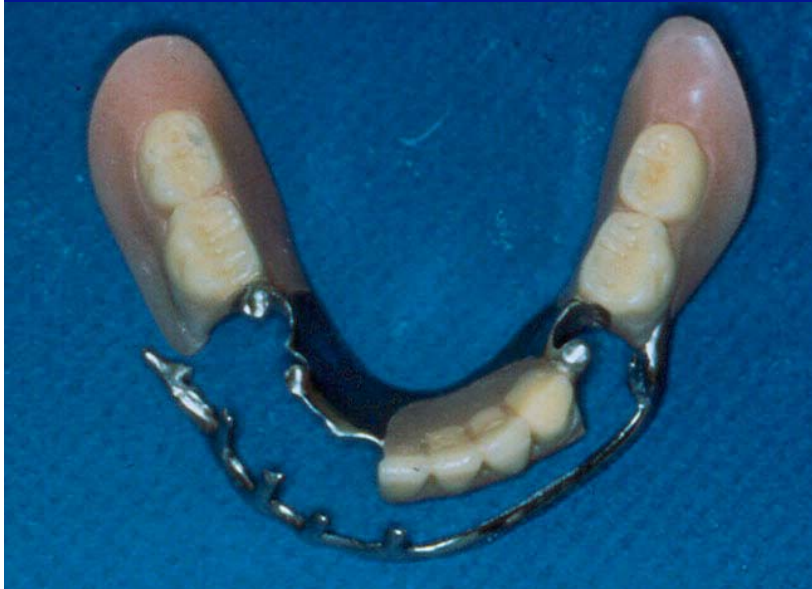
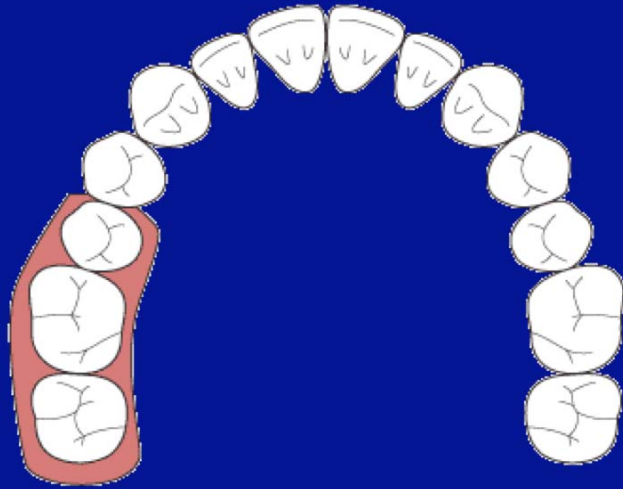
Alternate design thoughts?
As viewed from above and
from the labial, could this
appliance have been a
conventional clasp design?





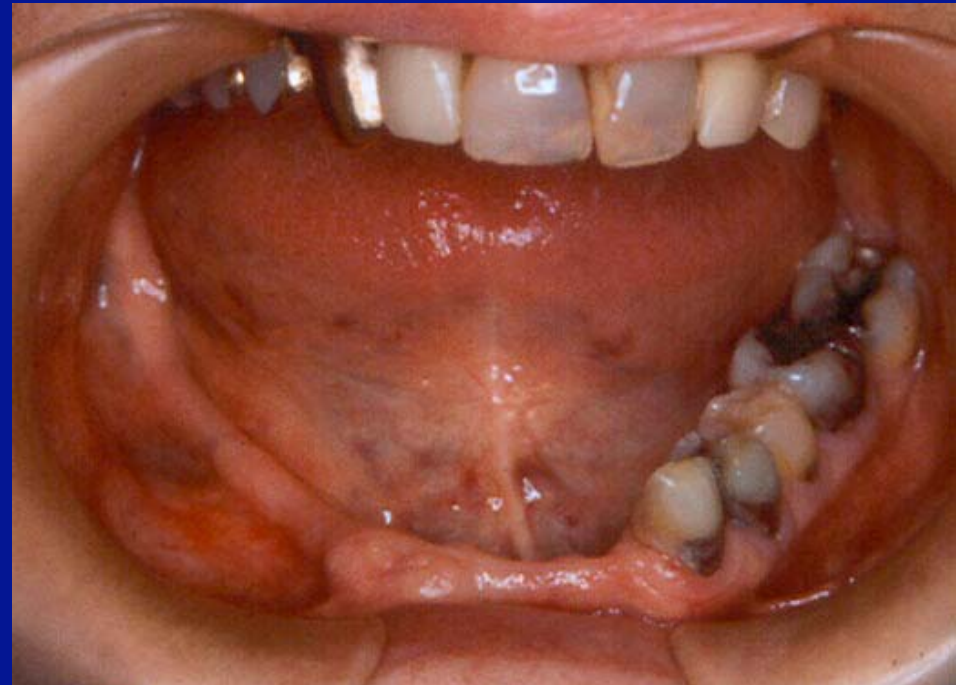
The same question as the previous image, could this patient have been treated with a conventional clasp RPD? Thoughts either way. Is there a "right" or "wrong" answer?

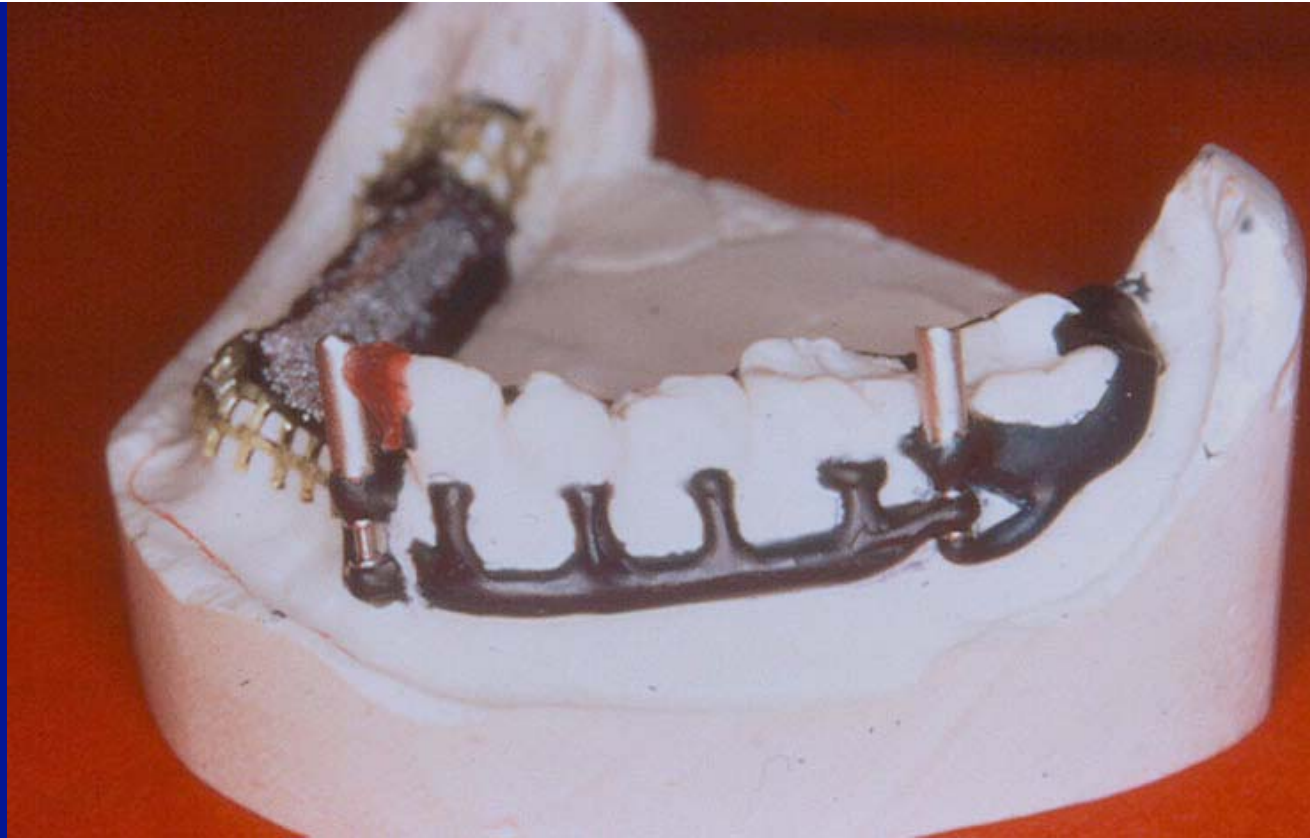



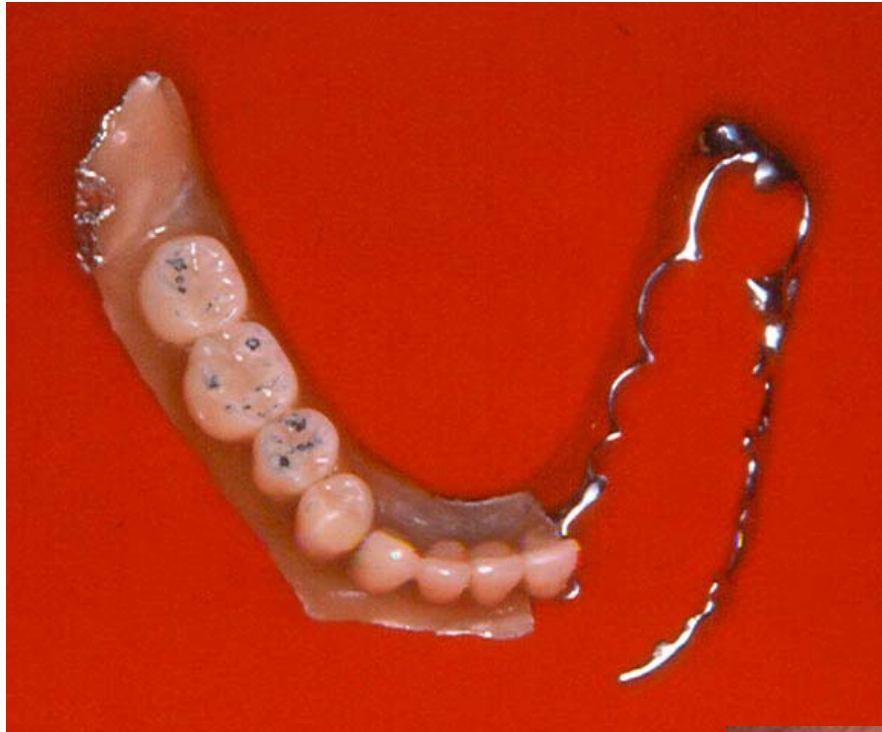Kennedy class II

Treating this case may be more challenging. Could we design a clasp type RPD for this patient?

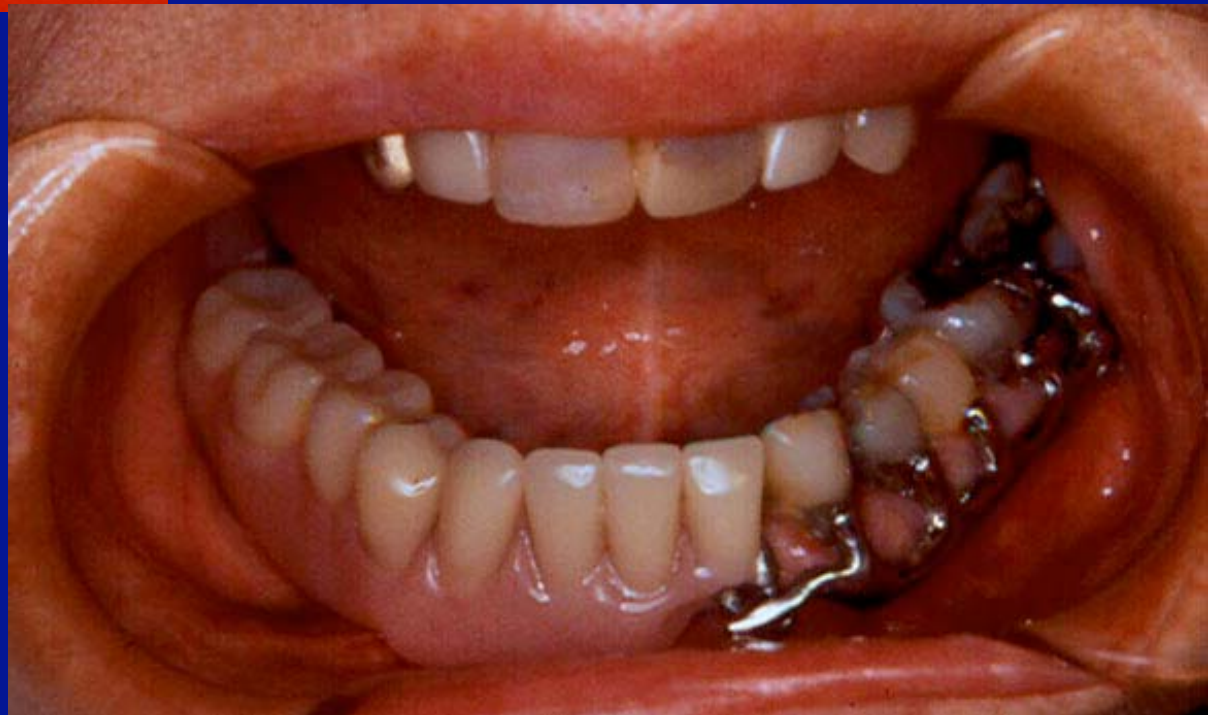

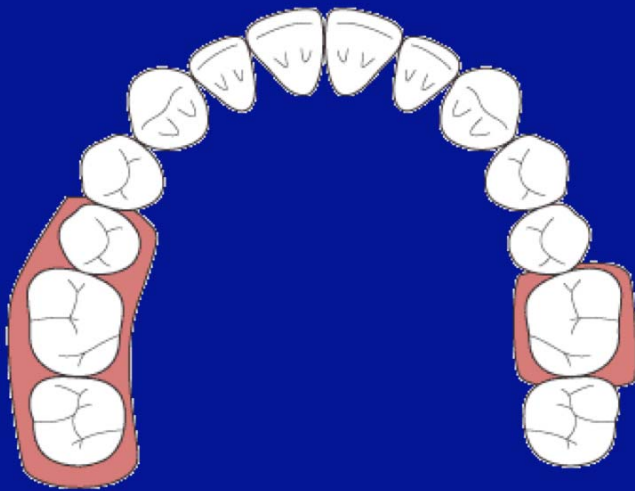


The actual wax up of the framework on the refractory model.

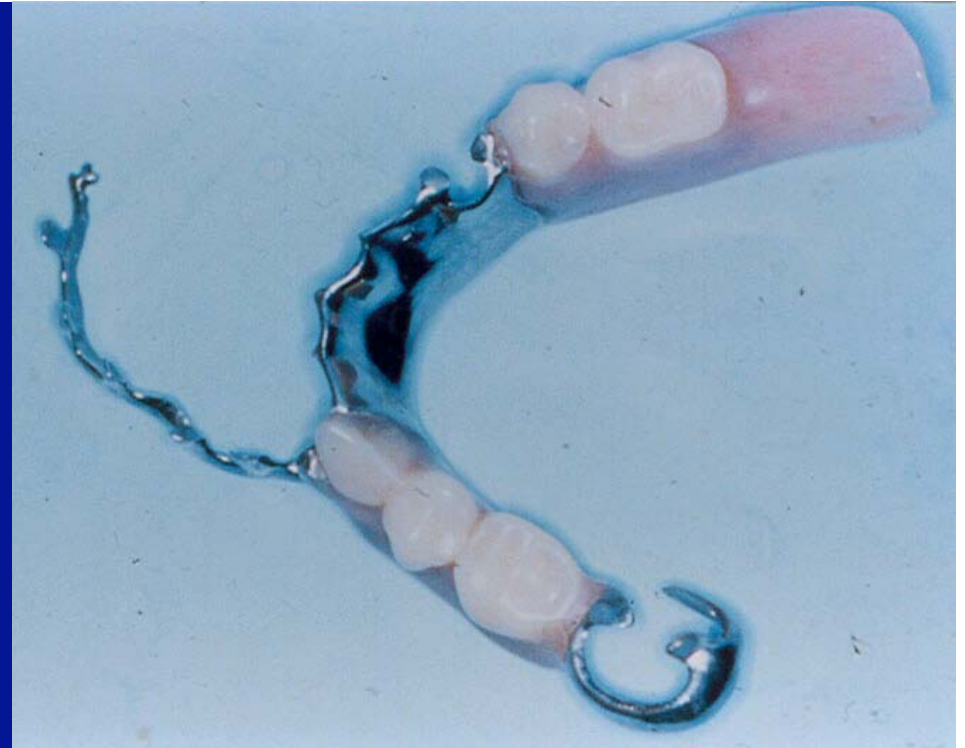

The image at the left shows the framework at the wax try in stage and below is the finished RPD.

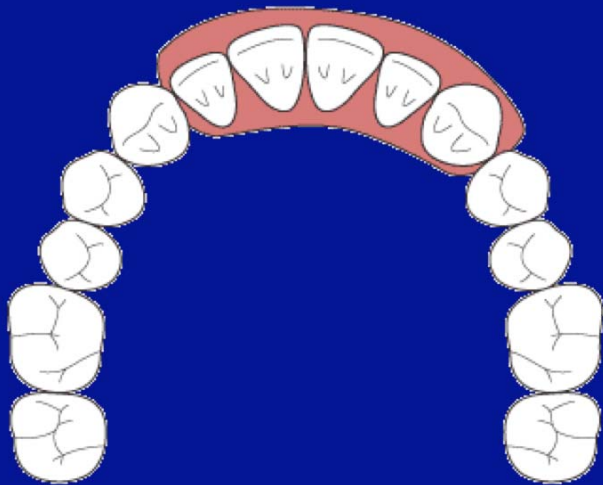




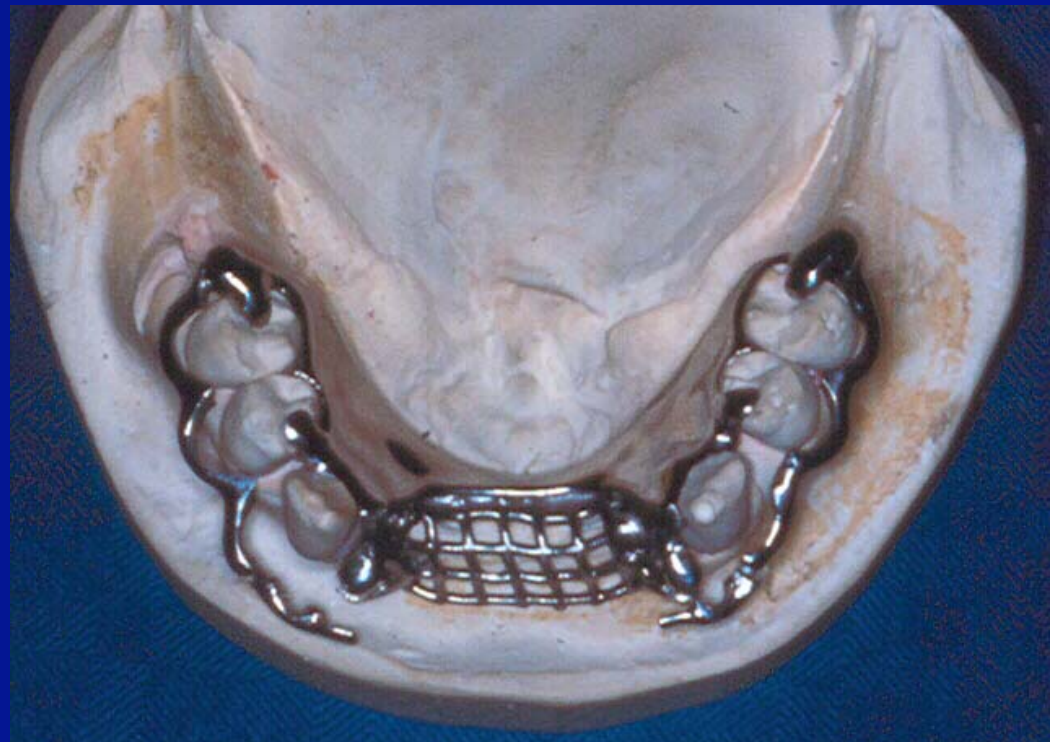
Kennedy IIP

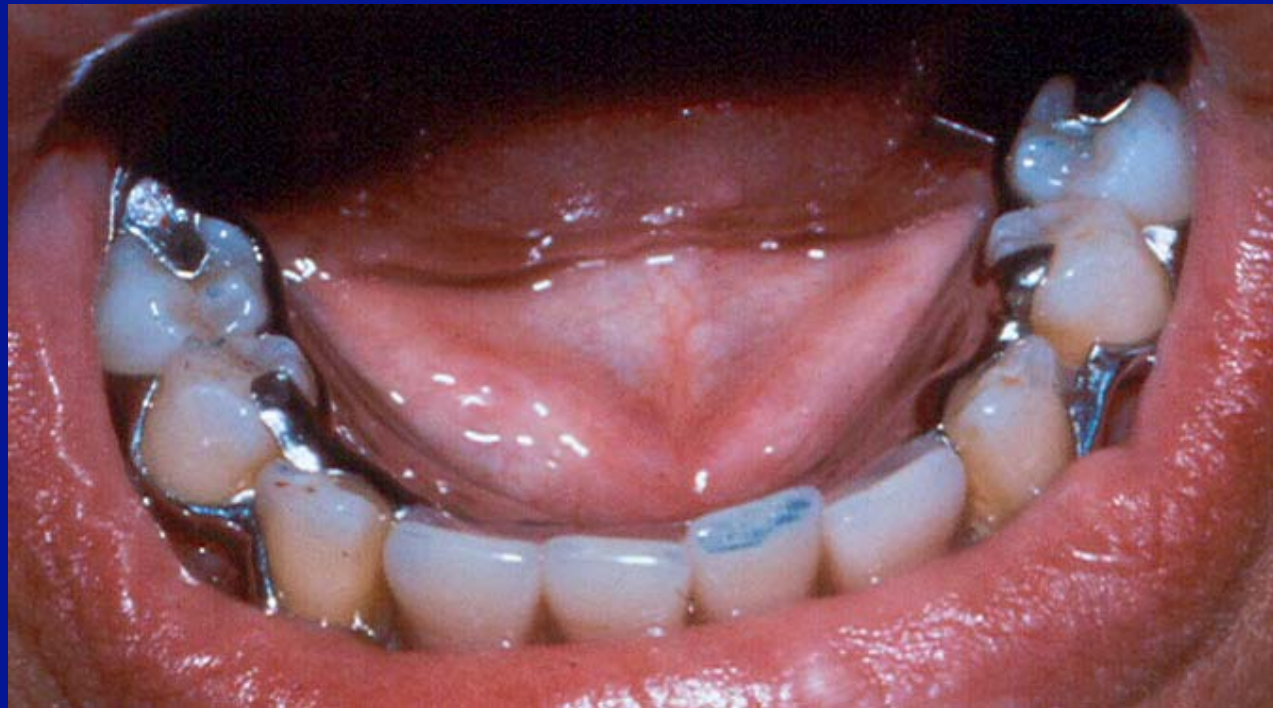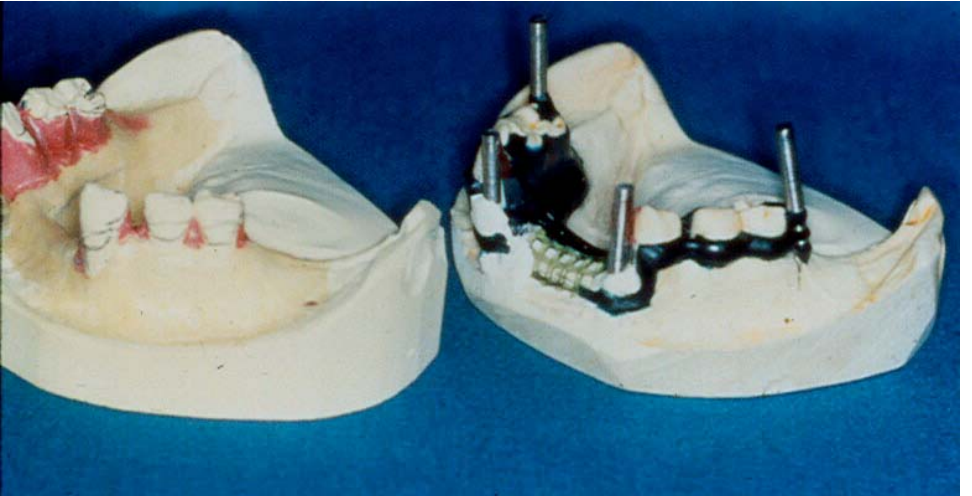

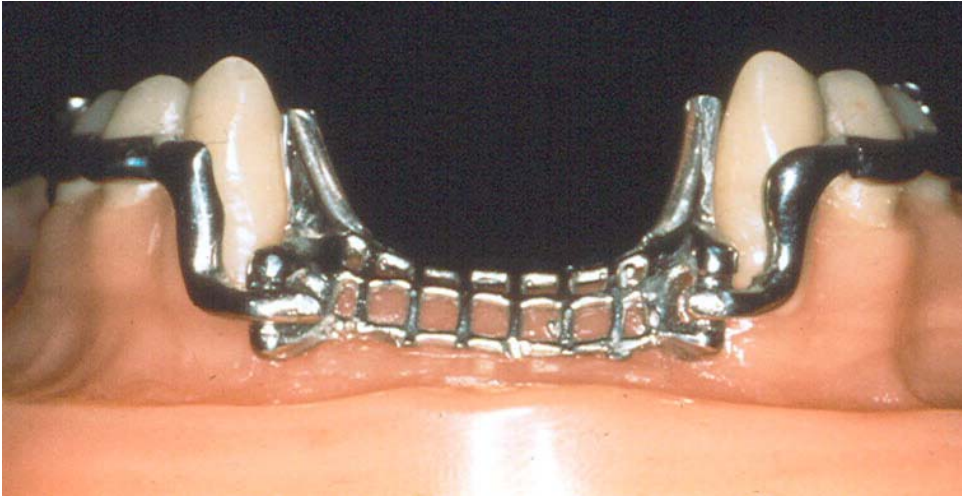
Another example showing a posterior modification space with a class II lower RPD. Here again, could other designs have been utilized?



Kennedy IV





Questions ????????