

Unless otherwise noted, the content of this course material is licensed under a Creative Commons Attribution - Non-Commercial - Share Alike 3.0 License.

Copyright 2008, Dr. Jeff Shotwell.

The following information is intended to inform and educate and is not a tool for self-diagnosis or a replacement for medical evaluation, advice, diagnosis or treatment by a healthcare professional. You should speak to your physician or make an appointment to be seen if you have questions or concerns about this information or your medical condition. You assume all responsibility for use and potential liability associated with any use of the material.

Material contains copyrighted content, used in accordance with U.S. law. Copyright holders of content included in this material should contact open.michigan@umich.edu with any questions, corrections, or clarifications regarding the use of content. The Regents of the University of Michigan do not license the use of third party content posted to this site unless such a license is specifically granted in connection with particular content objects. Users of content are responsible for their compliance with applicable law. See <http://www.dent.umich.edu/license/> for more information.

Mention of specific products in this recording solely represents the opinion of the speaker and does not represent an endorsement by the University of Michigan.

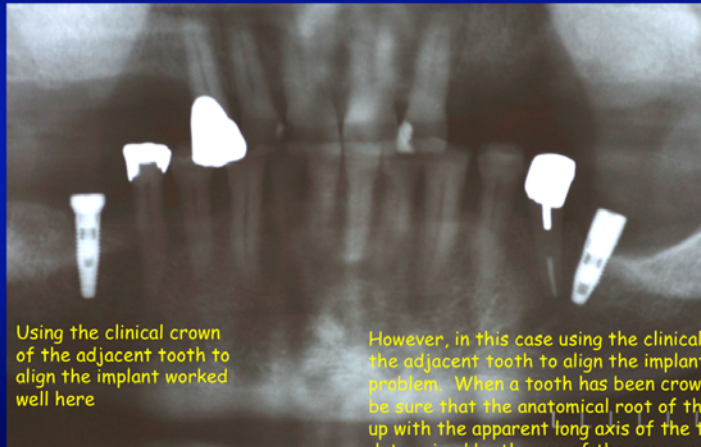
Viewer discretion advised: Material may contain medical images that may be disturbing to some viewers.

Prosthodontist's Perspective

Our implant planning process needs to be restoratively driven. We plan the implant treatment working from the proposed final restoration backwards.

Are all "empty spaces" best treated with an implant retained restoration?

Implant Planning

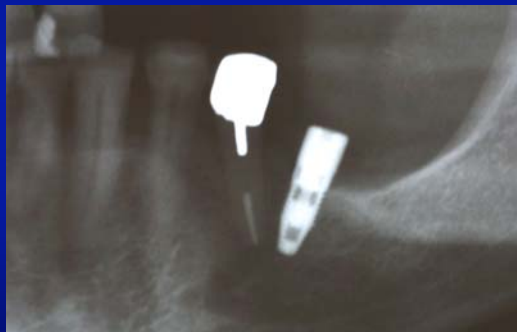

Using the clinical crown of the adjacent tooth to align the implant worked well here

However, in this case using the clinical crown of the adjacent tooth to align the implant posed a problem. When a tooth has been crowned, we can't be sure that the anatomical root of the tooth lines up with the apparent long axis of the tooth determined by the use of the crown restoration.

Source: Jeff Shotwell, University of Michigan, 2008

Implant Planning

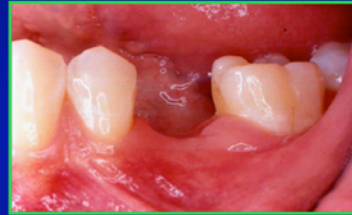
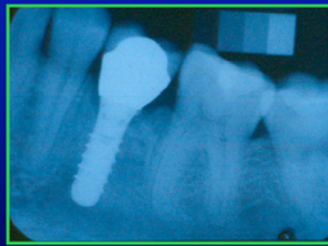
Here, the alignment of the implant looks pretty good if we compare it to the angulation of the restored crown of the adjacent tooth. Fabrication and use of a radiographic guide could help avoid this result.

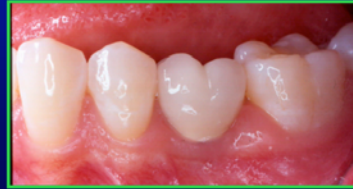Source: Jeff Shotwell, University of Michigan, 2008

Pre-Surgical Planning

Appropriate planning makes results like this predictable. Communication and co-ordination of the surgical and prosthodontic aspects of treatment are necessary to achieve consistent favorable results.



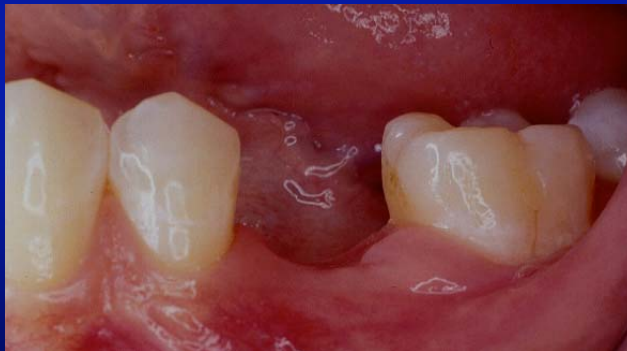Replacement of a primary molar which was extracted due to root resorption in a young adult.



Source: Jeff Shotwell, University of Michigan, 2008

Pre-Surgical Planning

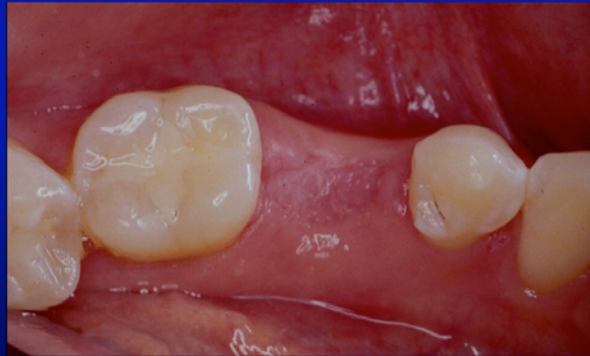
Implant Planning For Replacement of a Lost Primary Molar



Source: Jeff Shotwell, University of Michigan, 2008

Pre-Surgical Planning

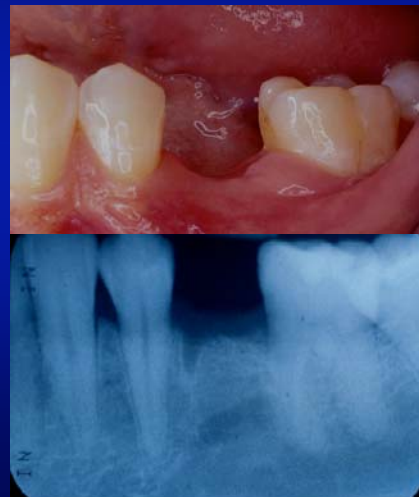Occlusal View of Proposed Site



Source: Jeff Shotwell, University of Michigan, 2008

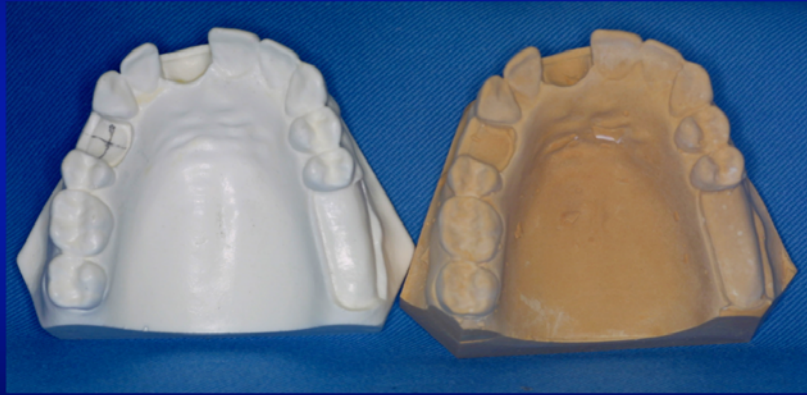
Pre-Surgical Planning

Verification of Root Angulation of Adjacent Teeth With a Radiograph



Source: Jeff Shotwell, University of Michigan, 2008

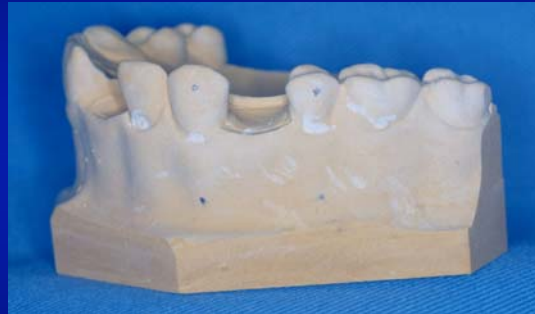Pre-Surgical Planning



Secure a good alginate impression and pour a study cast.

Source: Jeff Shotwell, University of Michigan, 2008

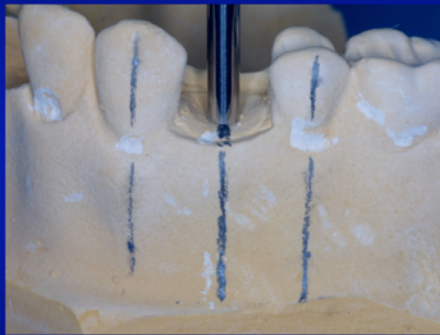
Pre-Surgical Planning



For a patient we would have a radiograph of the area to aid in our orientation for the surgical guide. Here I have placed a dot to mark "center mass" of the clinical crown and my estimate of the center of the root.

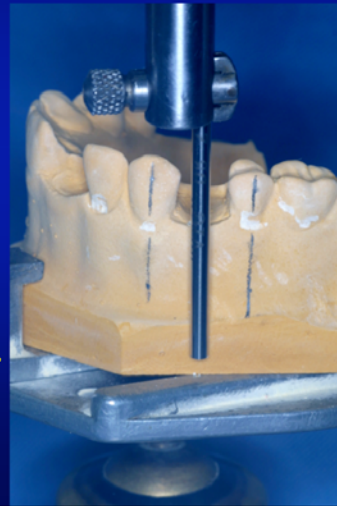Source: Jeff Shotwell, University of Michigan, 2008

Pre-Surgical Planning

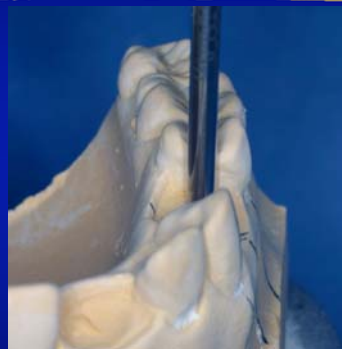
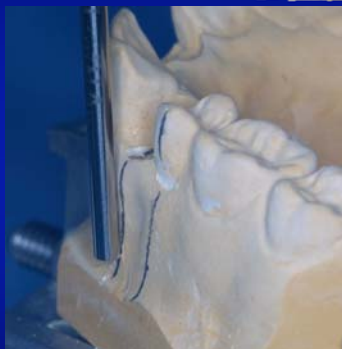
The lines placed on the cast are used to orient the model with the use of a dental surveyor.

Source: Jeff Shotwell, University of Michigan, 2008



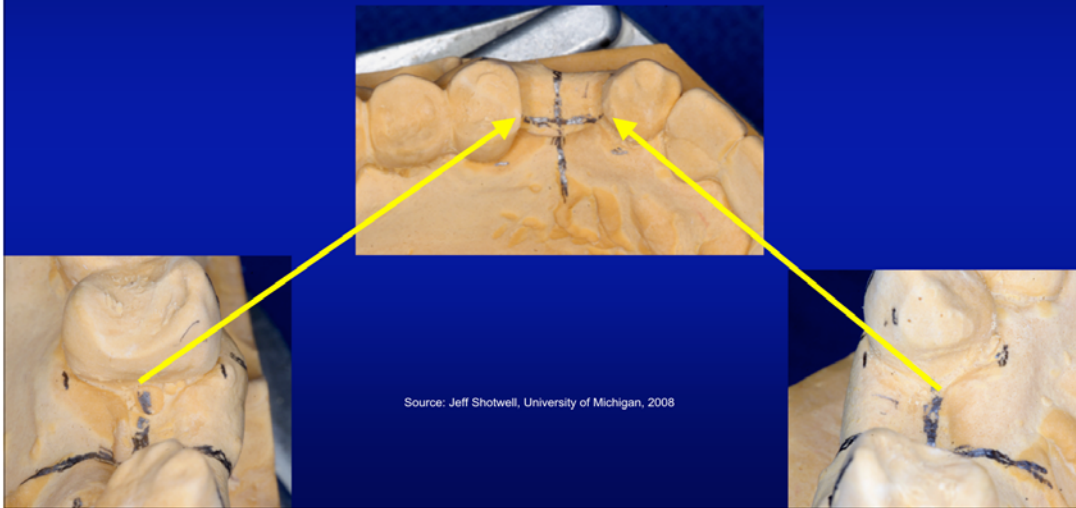
Pre-Surgical Planning



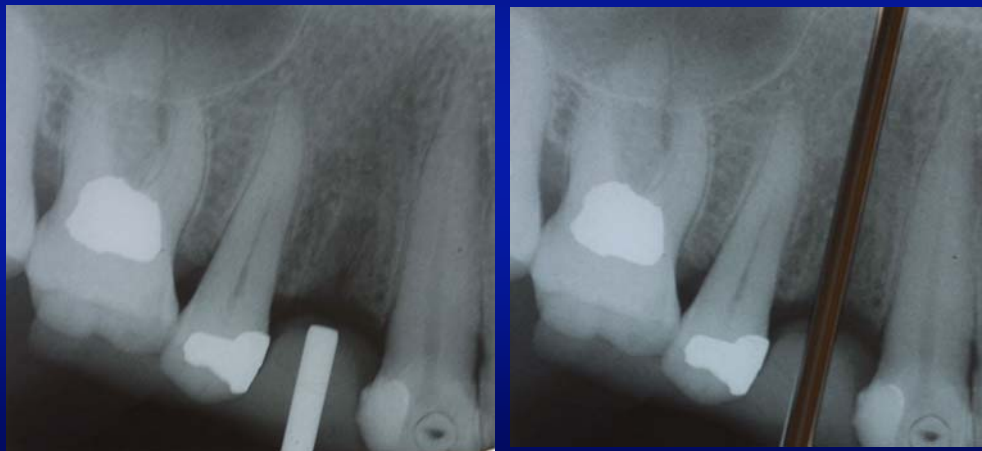The dental surveyor is also used to orient the cast bucco-lingually. We use the buccal plate as well as the proximal surfaces of the adjacent teeth if present.

Source: Jeff Shotwell, University of Michigan, 2008

Pre-Surgical Planning



The Use Of A Radiographic Guide For Evaluation Of The Proposed Angulation And Location of The Implant Placement



Pre-Surgical Planning

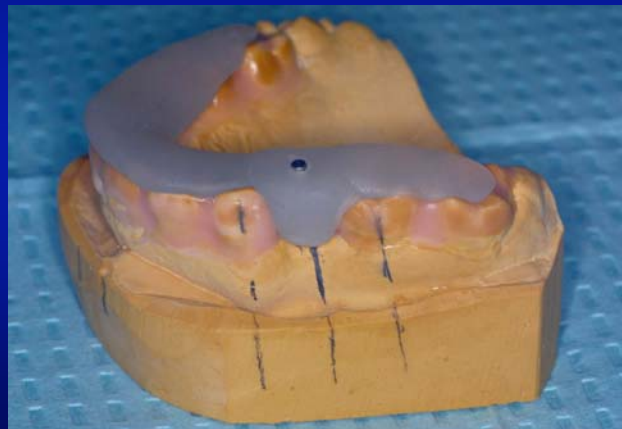
The Successive Sizes Of Drills And Drill Blanks For The Fabrication Of The Surgical Guides. From Top To Bottom The Sizes Are 2.2mm , 2.8mm, and 3.5mm



2mm Drill, Drill Blank, And 2mm x 10mm Dowel Used For Radiographic Guide Fabrication

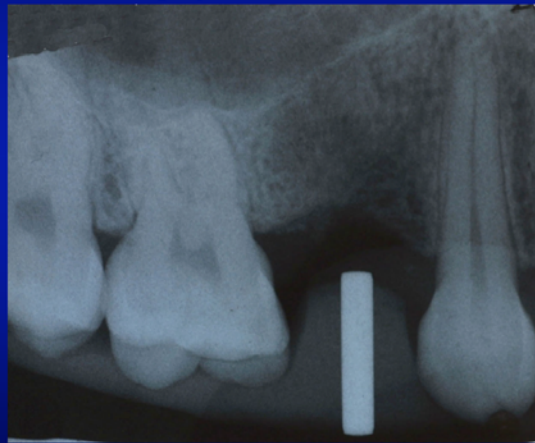
Source: Jeff Shotwell, University of Michigan, 2008

The Radiographic Guide



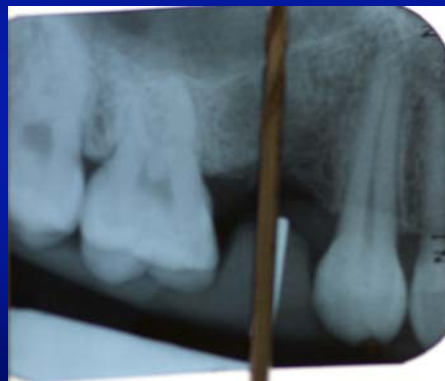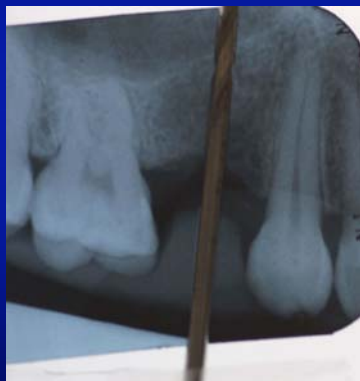Source: Jeff Shotwell, University of Michigan, 2008

Radiograph Of Patient Taken With Guide



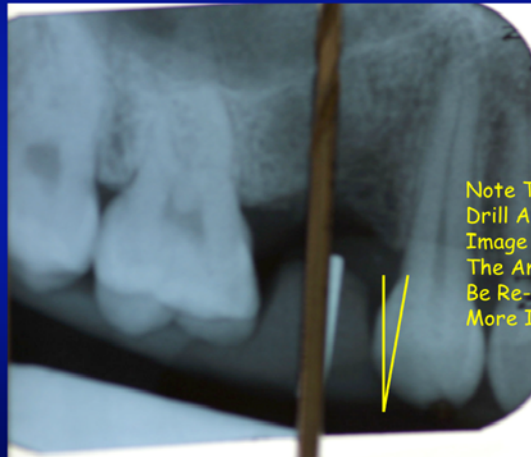
Source: Jeff Shotwell, University of Michigan, 2008

Adjustment Of Proposed Angulation Of Implant If Necessary / This Is Not Commonly Needed, But Is Included In Case You Find It Necessary



Source: Jeff Shotwell, University of Michigan, 2008


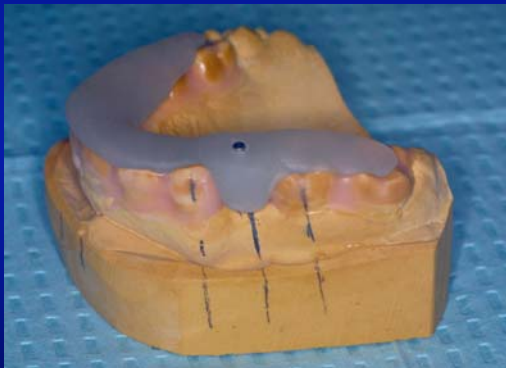
Determination Of The Amount Of Correction Needed For More Ideal Implant Placement



Note The Angle Created By The Drill And The Radiographic Image Of The Dowel. This Is The Amount The Cast Needs To Be Re-Angled To Provide A More Ideal Implant Placement

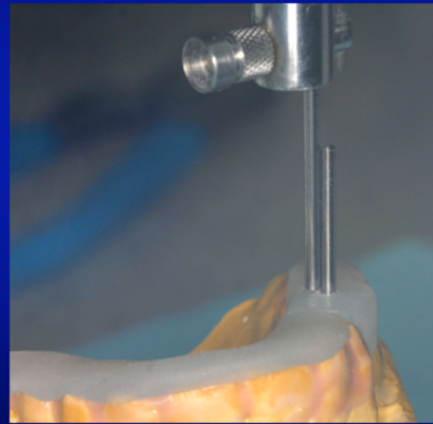
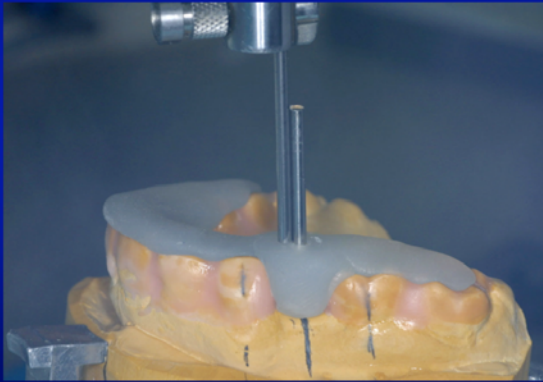
Source: Jeff Shotwell, University of Michigan, 2008

We First Remove The 10mm Dowel From Our Radiographic Guide



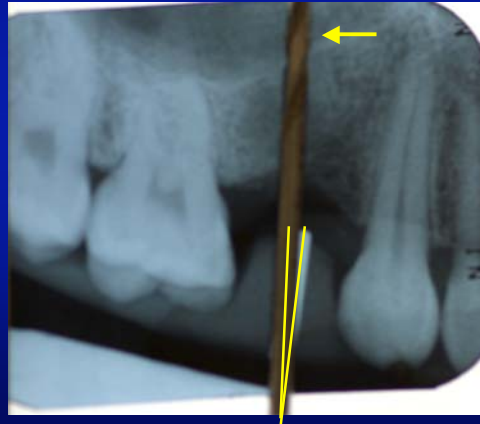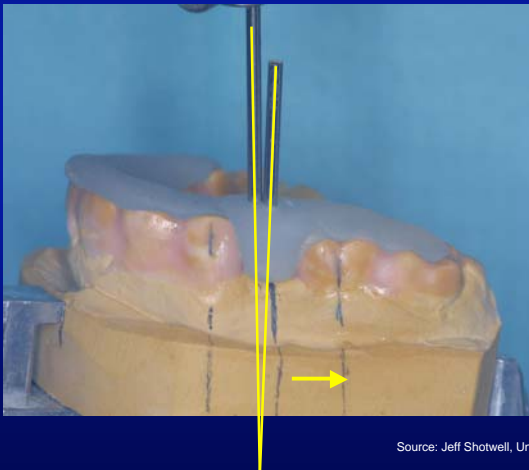
Source: Jeff Shotwell, University of Michigan, 2008

The Dowel Pin Is Replaced With A Longer Drill Blank
And We Orient The Surveyor Table As Necessary
To Align The Cast With Our Current Radiograph



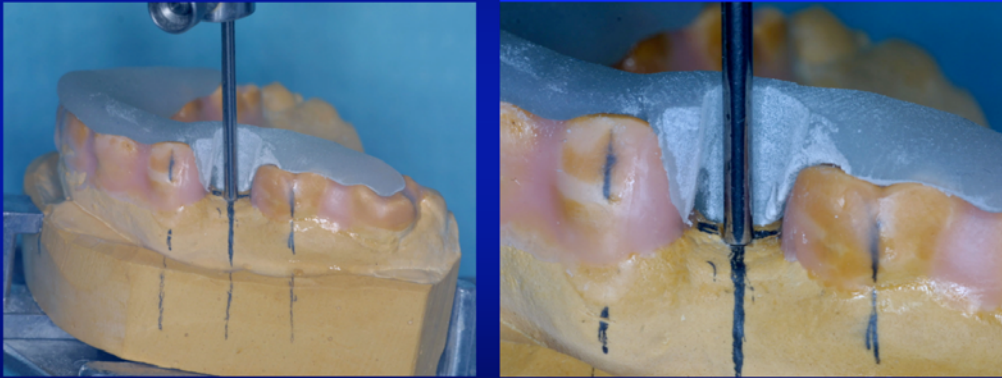
Source: Jeff Shotwell, University of Michigan, 2008

The New Orientation Moves The Apex
Of The Implant Toward The Molar



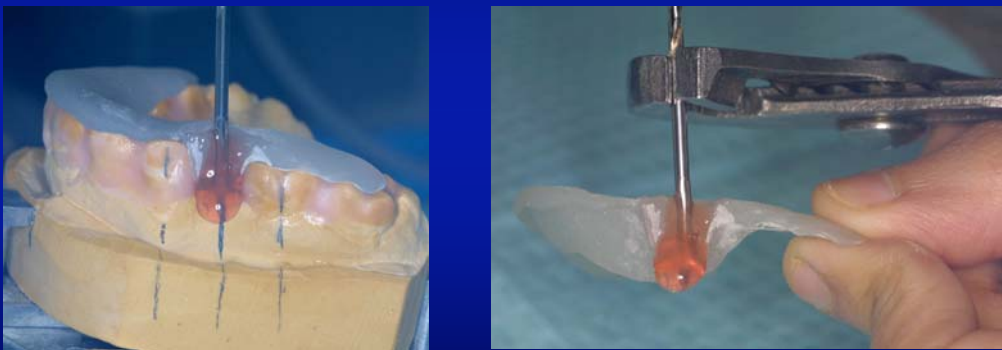Source: Jeff Shotwell, University of Michigan, 2008

The Radiographic Guide Is Ground Out To Allow The Placement Of The Drill Blank At The New Orientation



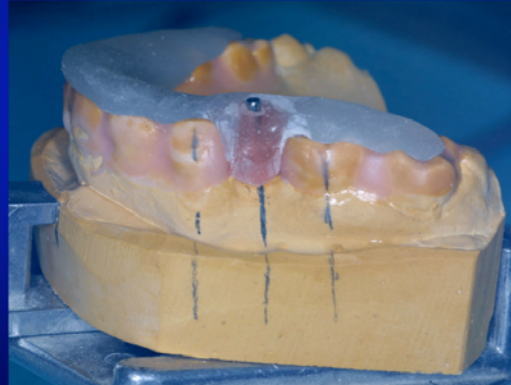
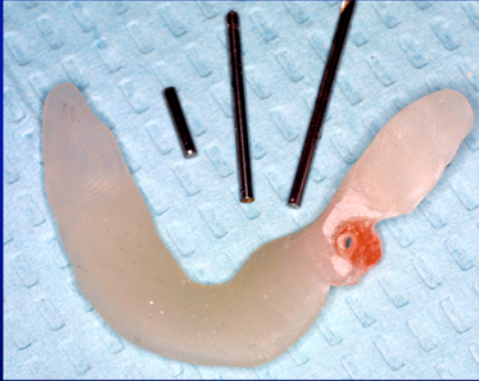
Source: Jeff Shotwell, University of Michigan, 2008

We Use Triad Gel To Surround The Drill Blank In The New Orientation And Cure It With A Hand Held Curing Light



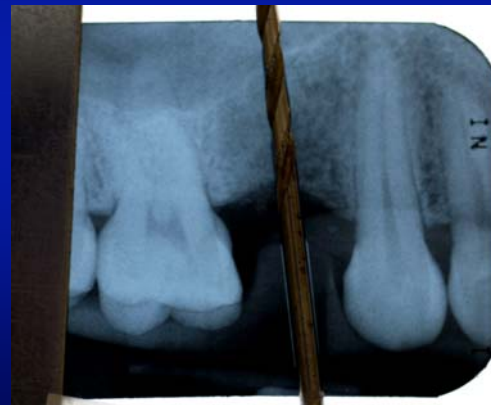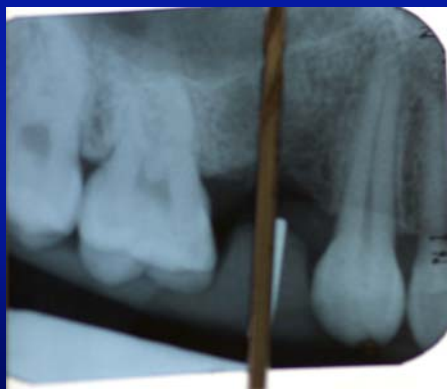Source: Jeff Shotwell, University of Michigan, 2008

We Replace The 2mm x 10mm Dowel In The Radiographic Guide And Take Another PA Film To Verify Our New Angulation With The Patient



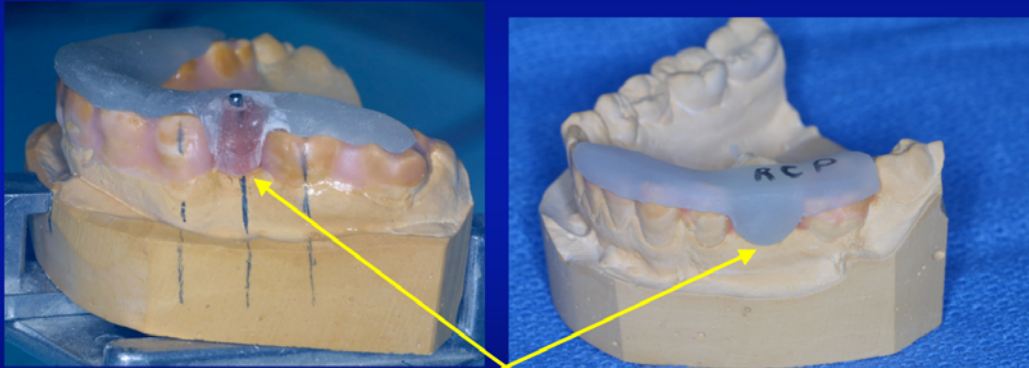
Source: Jeff Shotwell, University of Michigan, 2008

The Corrected Angulation Is Now Verified And We May Proceed To Fabricate Our Drill Guides



Source: Jeff Shotwell, University of Michigan, 2008

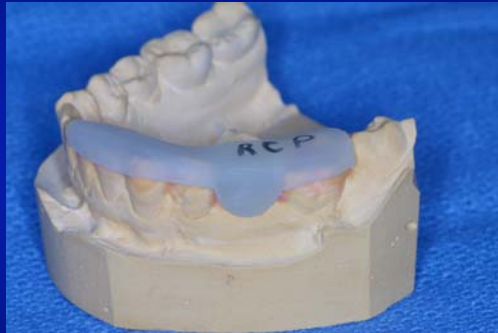
Verification Of The Superior - Inferior Placement Of The Implant



The radiographic guide may also be fabricated such that it can be used as a ridge crest preparation guide.

Source: Jeff Shotwell, University of Michigan, 2008

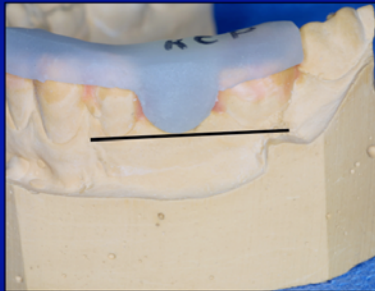
Verification That The Implant Is Not Placed Too Far Occlusally



The radiographic guide may be used for this purpose. Having this function separated from the radiographic guide is for the clarity of this presentation only. This guide is used to contour the crest of the ridge if necessary at surgery prior to performing the osteotomy for the implant placement.

Source: Jeff Shotwell, University of Michigan, 2008

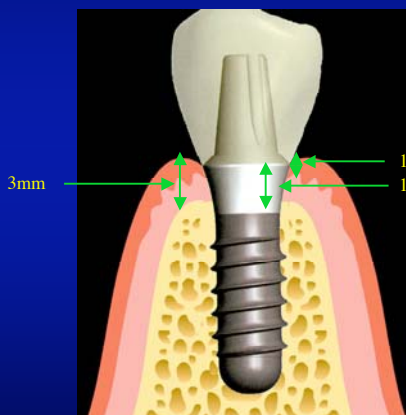
We Estimate The Final Position Of The FGM For Our Restoration As A Guide To The Superior-Inferior Placement Of Our Planned Implant



The RCP guide uses the FGM height of the adjacent teeth to determine the desired height of the FGM on the completed restoration.

Source: Jeff Shotwell, University of Michigan, 2008

Pre-Surgical Planning



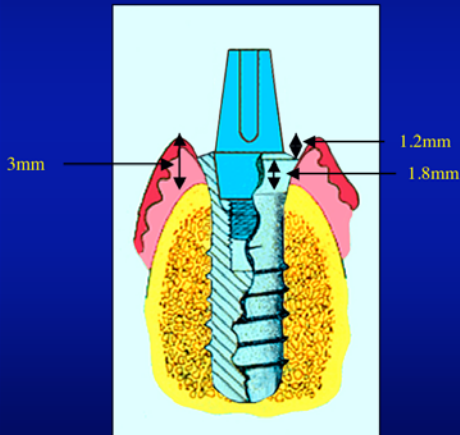
During surgery the junction of the "smooth-rough" surface of the implant is placed at the osseous crest. The Straumann Esthetic Plus implant extends 1.8mm above the "smooth-rough" junction.

The soft tissue will form 3mm above the osseous crest after healing.

This will place our crown margin 1.2mm below the healed gingival margin.

Source: Jeff Shotwell, University of Michigan, 2008

Pre-Surgical Planning

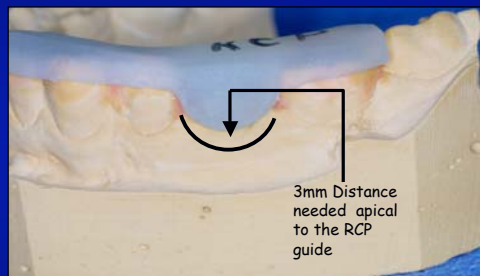


Reviewing: The soft tissue will heal 3mm higher than the bone.

Of this 3mm of space from the gingival margin and the bone, 1.8mm is the smooth portion of the implant and 1.2mm is the amount the margin of our crown will be below the crest of the gingiva.

Source: Jeff Shotwell, University of Michigan, 2008

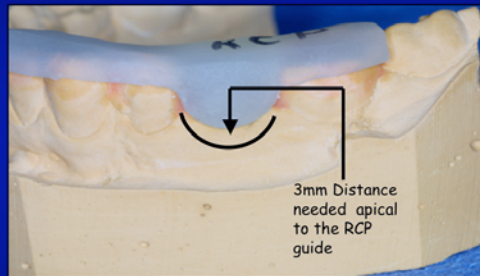
Pre-Surgical Planning



After laying a flap, the surgeon will ensure that the osseous crest is 3mm apical to the RCP stent. If there is LESS room than 3mm, this may create a problem with the final restoration in that the margin / collar of the implant may be exposed.

Source: Jeff Shotwell, University of Michigan, 2008

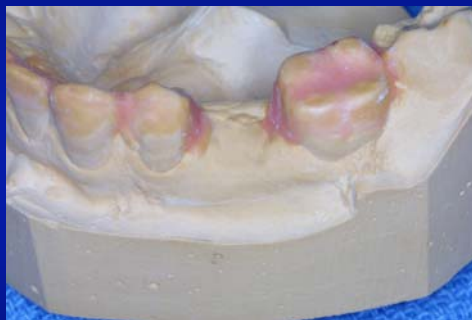Pre-Surgical Planning



Assuming there is less than 3mm between the guide and the alveolar crestal bone, the surgeon will use a high speed diamond to recontour the crest of the ridge until adequate space is created between the guide and the ridge crest. At this time, the drill guides may be used to create the osteotomy for the implant.

Source: Jeff Shotwell, University of Michigan, 2008

Pre-Surgical Planning



Our next task is placing the cast on a dental surveyor and determining the orientation for the preparation of the osteotomy for implant placement.

Source: Jeff Shotwell, University of Michigan, 2008

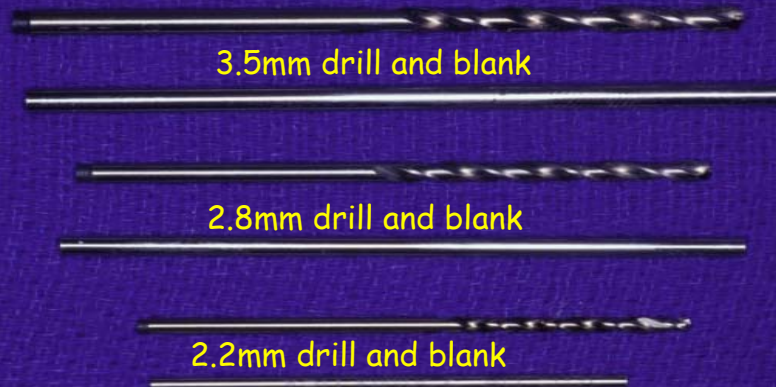
Pre-Surgical Planning

We will use the drill press as a surveyor.
For your purposes, the dental surveyor may be used for this procedure as well.
The cast has been placed in a surveyor table and there is a 3.5mm drill blank in the drill press to use as an "analyzing rod".
Using your surveyor, this could be done with a 2.8mm drill blank.



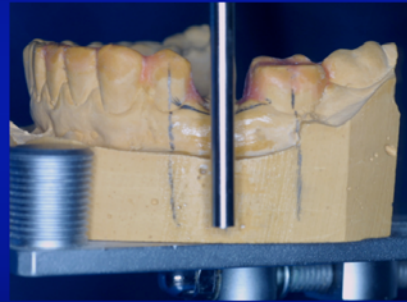
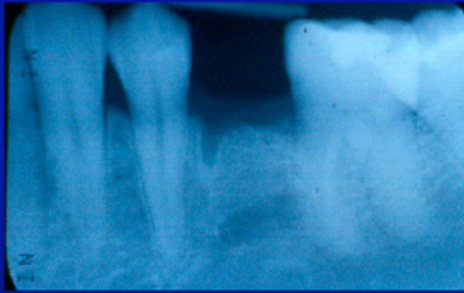
Source: Jeff Shotwell, University of Michigan, 2008

Pre-Surgical Planning



Source: Jeff Shotwell, University of Michigan, 2008

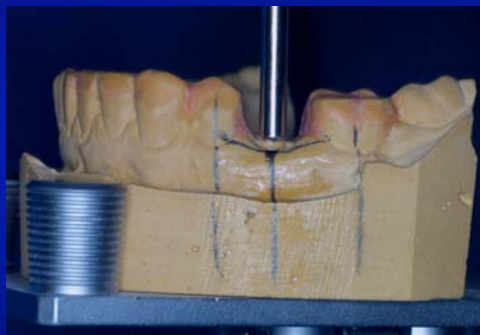Pre-Surgical Planning



We refer to the radiograph to help with the orientation.

Source: Jeff Shotwell, University of Michigan, 2008

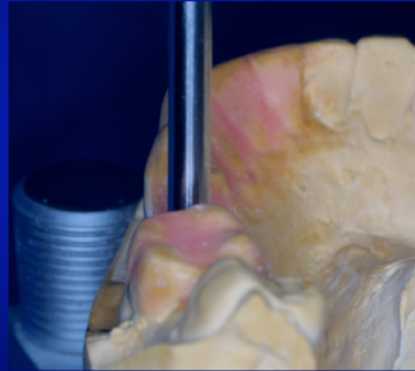
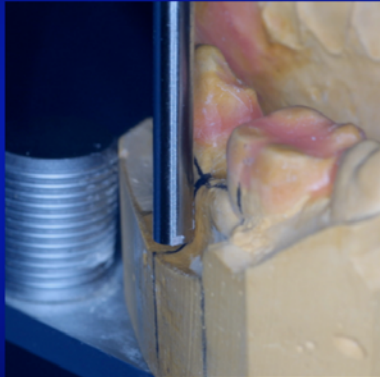
Pre-Surgical Planning



The use of a large drill blank helps evaluate that the proposed placement shows equal clearance with the adjacent teeth.

Source: Jeff Shotwell, University of Michigan, 2008

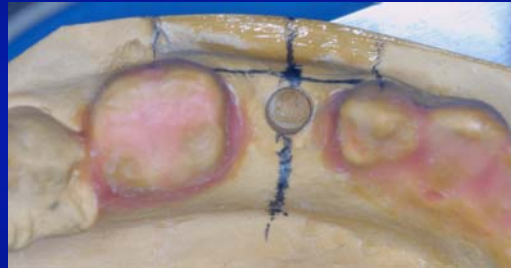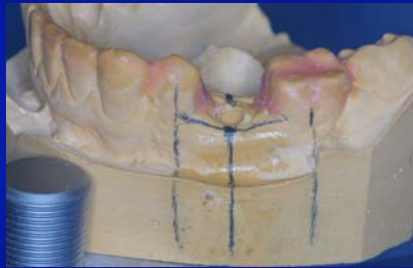Pre-Surgical Planning



Checking survey relative to the buccal plate as well as with the adjacent teeth.

Source: Jeff Shotwell, University of Michigan, 2008

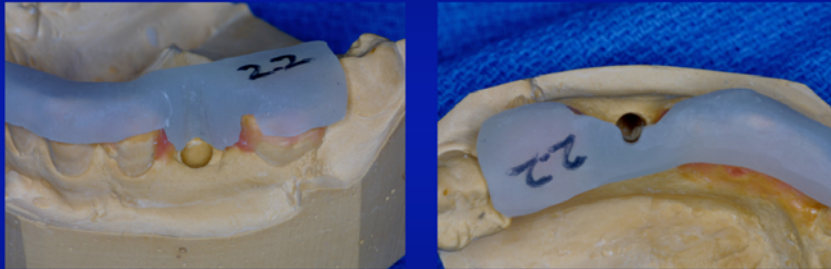Pre-Surgical Planning



This view shows the proposed placement. Note the view from the occlusal places the implant somewhat buccal to the center of the ridge crest.

Source: Jeff Shotwell, University of Michigan, 2008

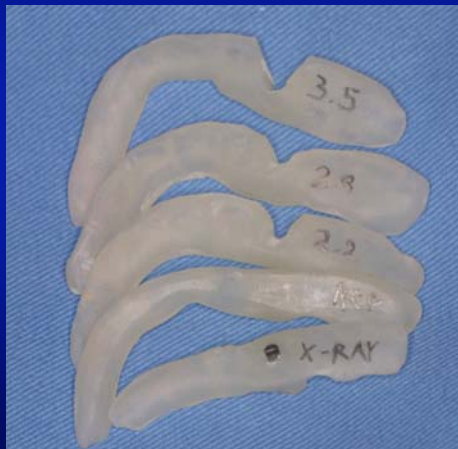Pre-Surgical Planning



The 2.2mm surgical drill guide viewed from the buccal and occlusal.

Source: Jeff Shotwell, University of Michigan, 2008

Pre-Surgical Planning

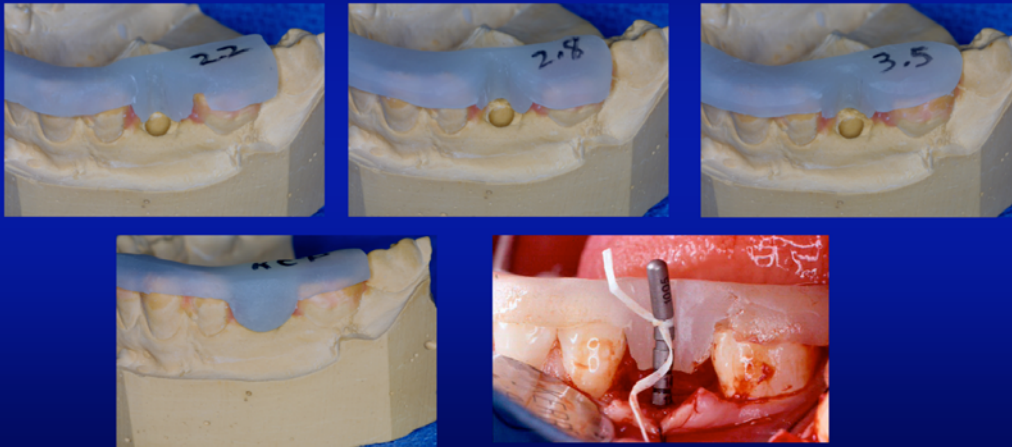


The complete set of pre surgical and surgical guides include:

Radiographic stent with 10mm marker
RCP stent (Ridge Crest Preparation)
Remember, the Radiographic stent and the RCP stent are usually combined
2.2mm surgical drill guide
2.8mm surgical drill guide
3.5mm surgical drill guide

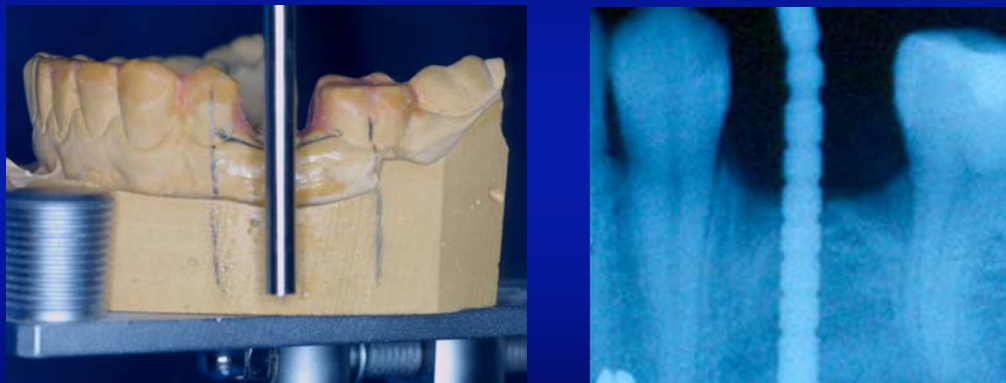Source: Jeff Shotwell, University of Michigan, 2008

Surgical Phase



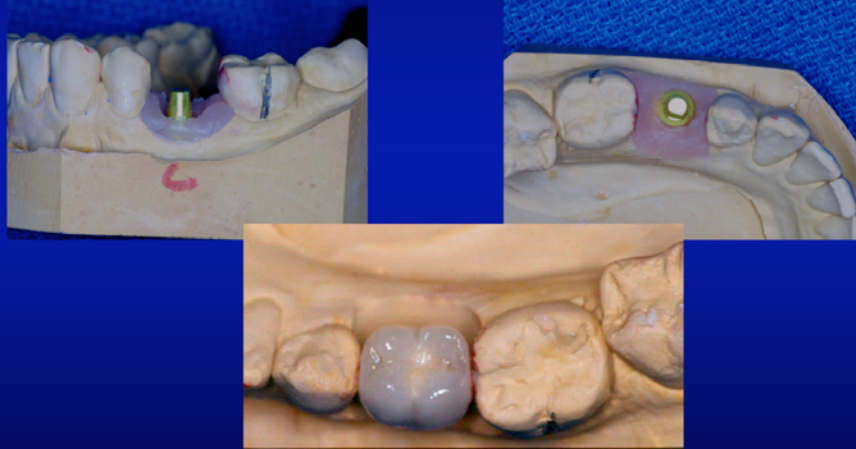
Source: Jeff Shotwell, University of Michigan, 2008

Pre-Surgical Planning (Left) Surgical Phase (Right)



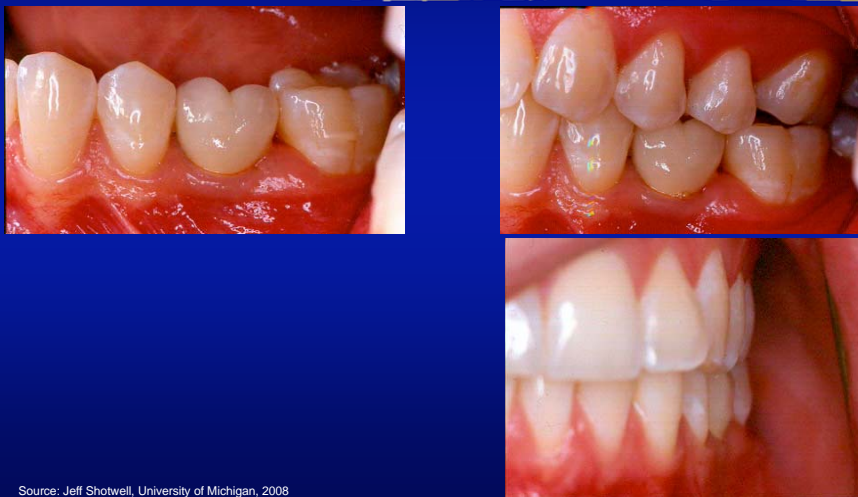Source: Jeff Shotwell, University of Michigan, 2008

Lab Phase of Final Restoration



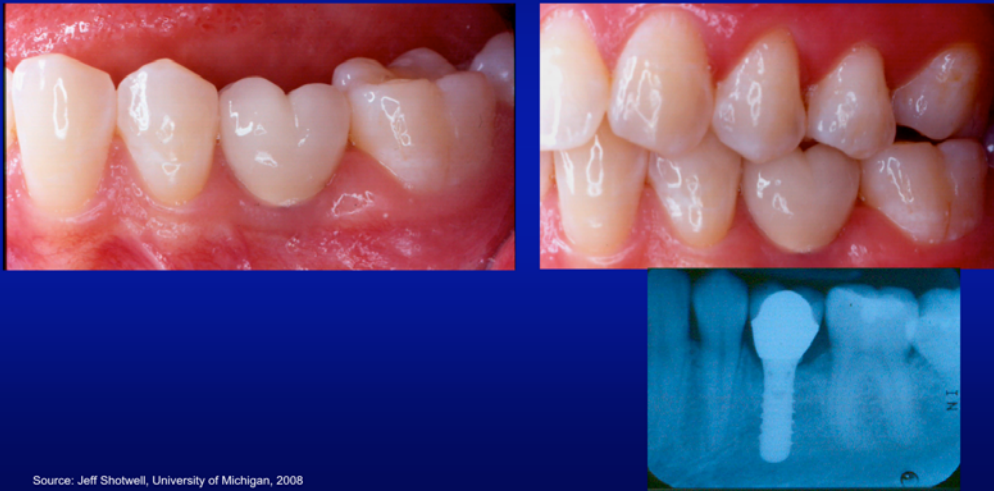Source: Jeff Shotwell, University of Michigan, 2008

Final Restoration Placed



Source: Jeff Shotwell, University of Michigan, 2008

Final Restoration Placed



Source: Jeff Shotwell, University of Michigan, 2008

Abutment Options For The Straumann System Used In The VIC Clinics

RN stands for regular neck or regular platform implant abutments. This is the 4.1mm x 4.8mm implant or the 4.8mm x 4.8mm implant. Used in the bicuspid area and at times in the molar area depending on anatomic requirements.




WN stands for wide neck or wide platform implant abutments. This is the 4.8mm x 6.5mm implant. This implant is used in the molar areas only.

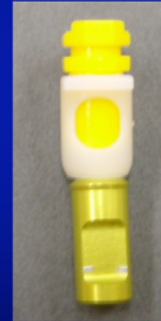

Source: Jeff Shotwell, University of Michigan, 2008

A Schematic Drawing Of The Placement Of The Abutment And The Orientation Of The Impression Components



Insert placed in impression basket to orient the position of the flat side of the solid abutment



Source: Jeff Shotwell, University of Michigan, 2008

Review Of The Impression Components Used With The Straumann System After Placement Of The Solid Abutment




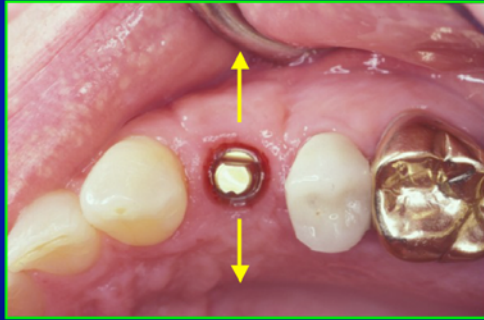
The impression components used for the 4mm tall solid abutment. Both sets of components shown here are for the regular neck implant.



The components used for the 5.5mm tall solid abutment.

Source: Jeff Shotwell, University of Michigan, 2008

When taking our impression, we always orient our white basket so that the tabs face to the buccal and lingual.



Also note the orientation of the flat side of the solid abutment after torquing to place. In this case it is oriented toward 12 o'clock (straight to the buccal)

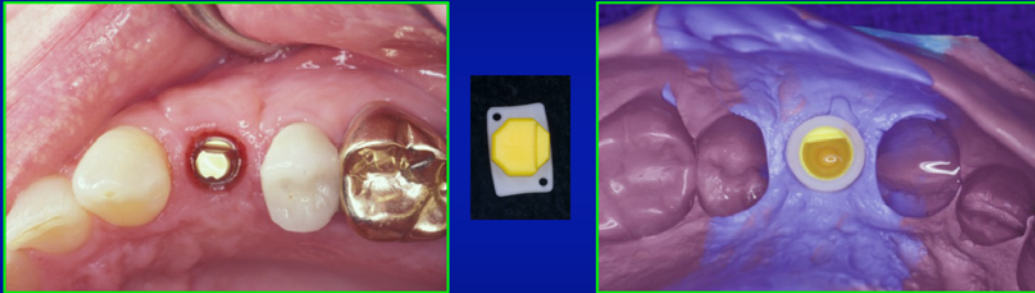
Source: Jeff Shotwell, University of Michigan, 2008

The White Basket Snaps Over The Margin Created By The Implant. The insert orients the flat side of the abutment for the impression.



Source: Jeff Shotwell, University of Michigan, 2008

We may then pre assemble the insert and the basket prior to placing them on the abutment for impression making.



In this situation, the pre assembled impression basket would have the tab indicating the flat side of the insert placed at the 12 o'clock position, not the 3 o'clock position as shown in the image at the left. After taking the impression, an analog is placed in the impression basket prior to pouring the impression in dental stone.

Source: Jeff Shotwell, University of Michigan, 2008

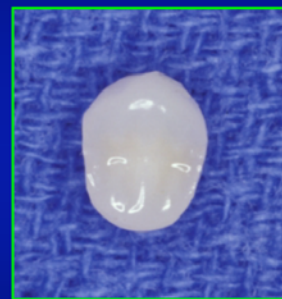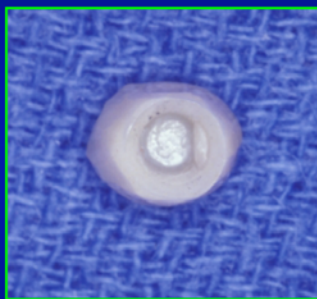
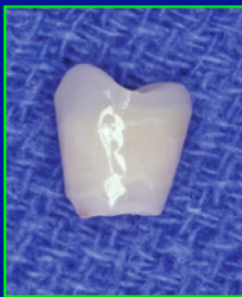The Use Of An Analog For Making Our Provisional Restoration After The Final Impression For Our Patient



This procedure may also be done using a coping made ahead of time on a spare analog and a hollowed out plastic tooth. We can use an aluminum crown form filled with self cure acrylic to make the plastic tooth ahead of time as well. We then just hollow out our plastic tooth after peeling the aluminum crown form off the self curing acrylic.

Source: Jeff Shotwell, University of Michigan, 2008

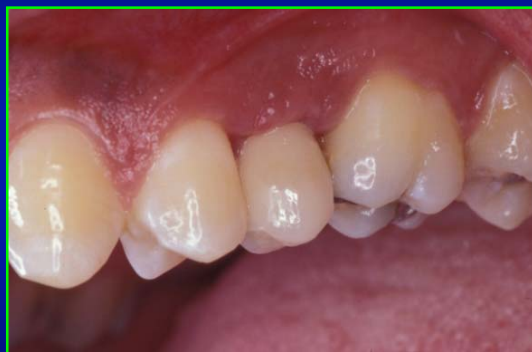Finalized Margins Of The Provisional Restoration For The Patient



The provisional will help form the emergence profile of the gingival sulcus for the final restoration.

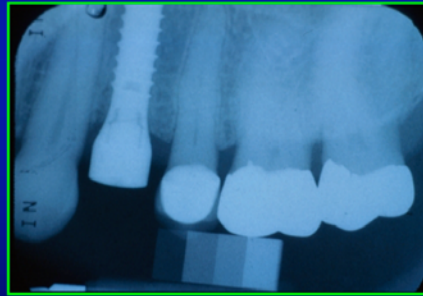
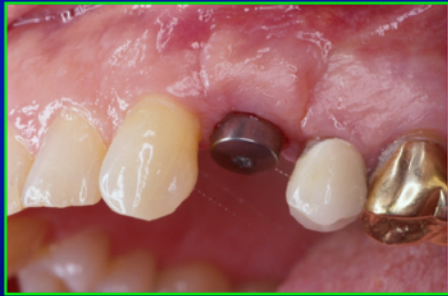Source: Jeff Shotwell, University of Michigan, 2008

Provisional Restoration Cemented



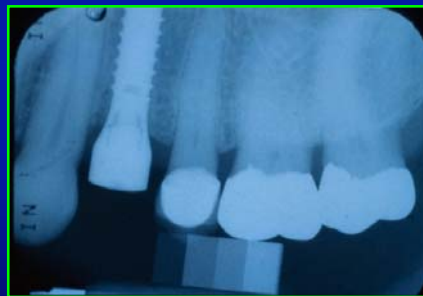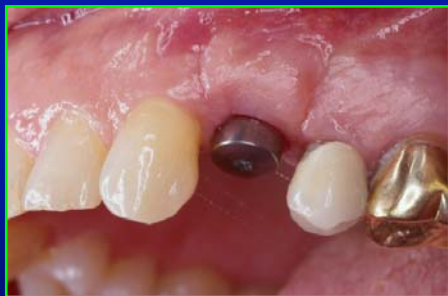Source: Jeff Shotwell, University of Michigan, 2008

Another Patient Three Months Post Placement



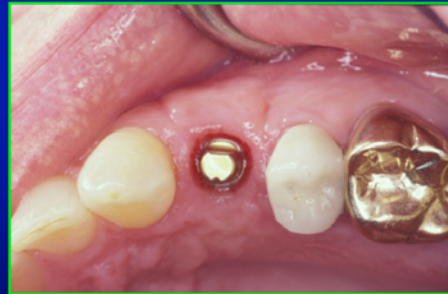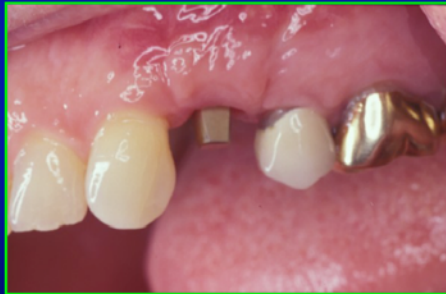Source: Jeff Shotwell, University of Michigan, 2008

Cover or Healing Abutment



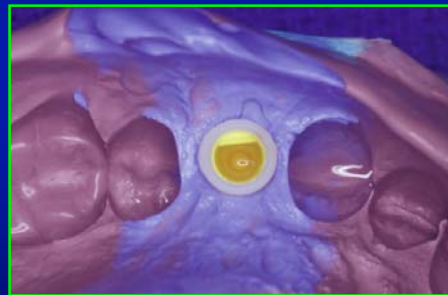
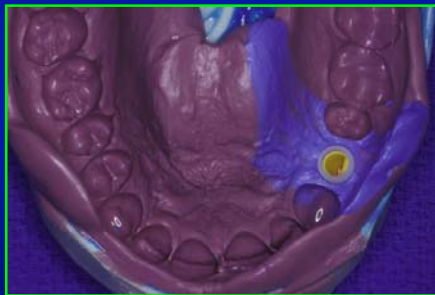
Source: Jeff Shotwell, University of Michigan, 2008

Healing Abutment Removed And A 4mm Tall
Regular Neck Solid Abutment Placed In The
Implant And Torqued To 35NCm



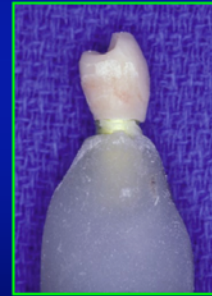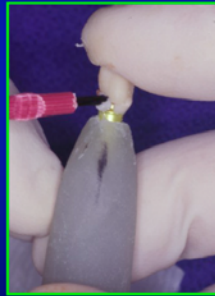
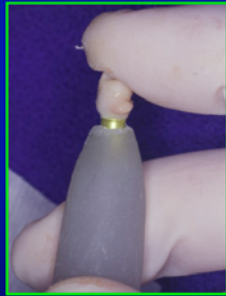Source: Jeff Shotwell, University of Michigan, 2008

PVS Impression



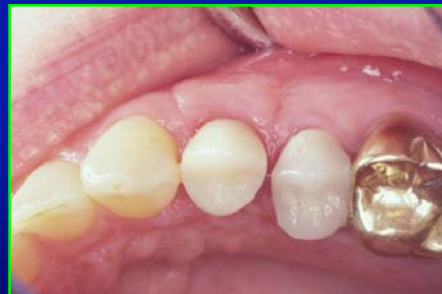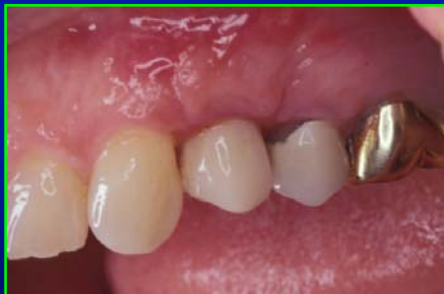Source: Jeff Shotwell, University of Michigan, 2008

Fabrication of Provisional



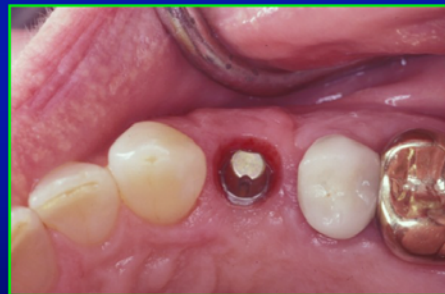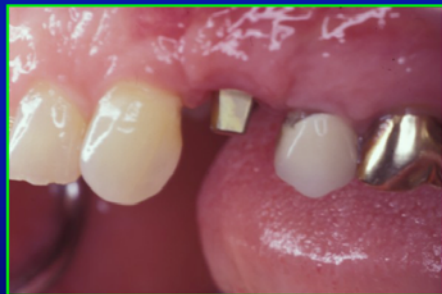Source: Jeff Shotwell, University of Michigan, 2008

Provisional Cemented



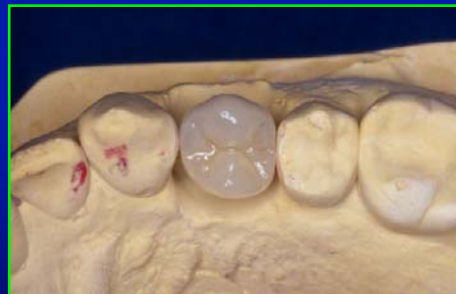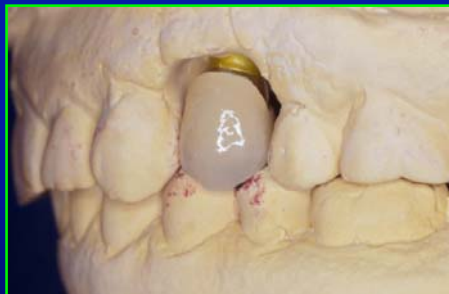Source: Jeff Shotwell, University of Michigan, 2008

Provisional Removed At Time Of Crown Placement



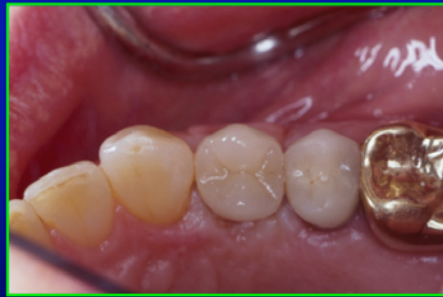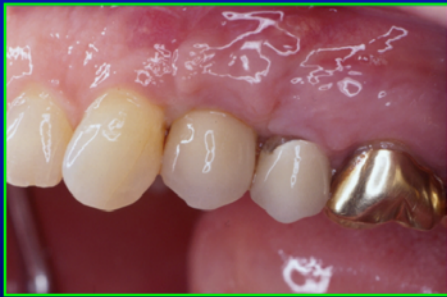Source: Jeff Shotwell, University of Michigan, 2008

Definitive Crown On Working Cast / Note Removal Of Silicone Gingival Area



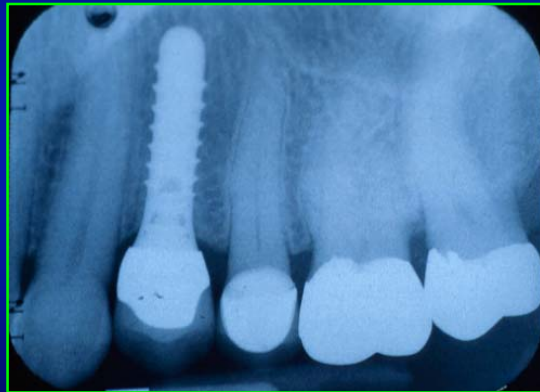
Source: Jeff Shotwell, University of Michigan, 2008

Crown Placement



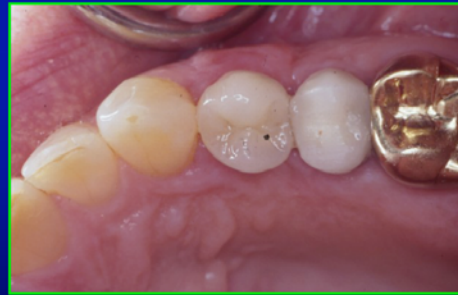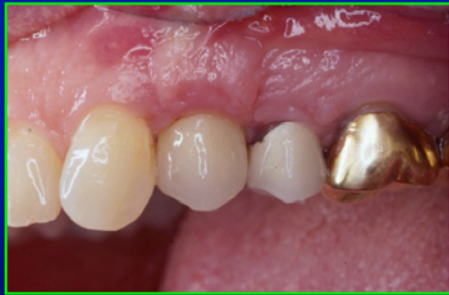Source: Jeff Shotwell, University of Michigan, 2008

Radiograph Of Final Crown



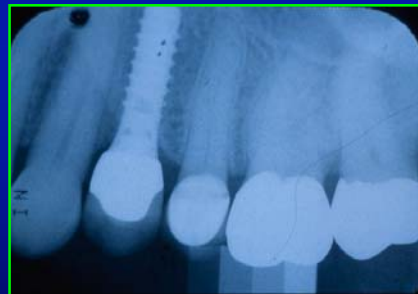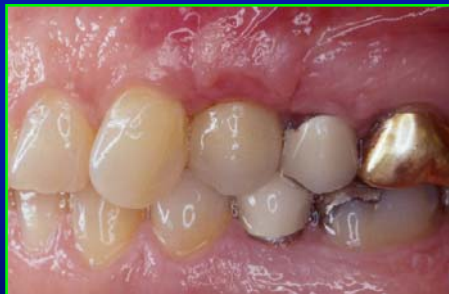Source: Jeff Shotwell, University of Michigan, 2008

6 Months Post Placement



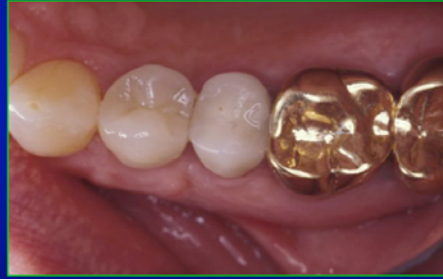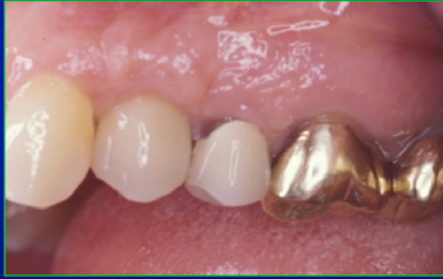Source: Jeff Shotwell, University of Michigan, 2008

Clinical And Radiographic Appearance At 6 Months



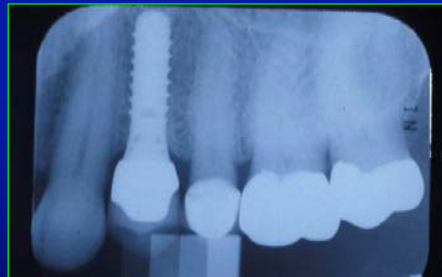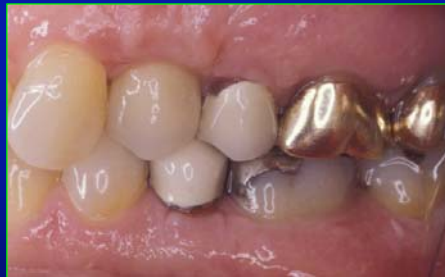Source: Jeff Shotwell, University of Michigan, 2008

12 Months Post Placement



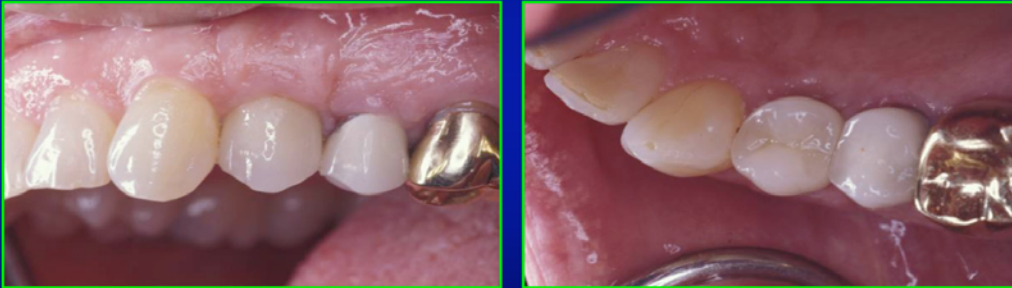Source: Jeff Shotwell, University of Michigan, 2008

Clinical And Radiographic Appearance At 12 Months



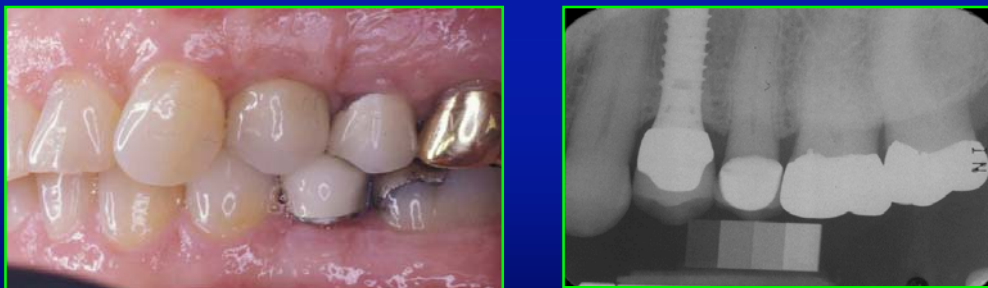Source: Jeff Shotwell, University of Michigan, 2008

24 Months Post Placement



Source: Jeff Shotwell, University of Michigan, 2008

Clinical And Radiographic Appearance At 24 Months



Source: Jeff Shotwell, University of Michigan, 2008

Overview Of Single Crown Implant Planning And Impression Making

Questions?????????