

Unless otherwise noted, the content of this course material is licensed under a Creative Commons Attribution 3.0 License.

Copyright 2008, Jeffrey Shotwell



The following information is intended to inform and educate and is not a tool for self-diagnosis or a replacement for medical evaluation, advice, diagnosis or treatment by a healthcare professional. You should speak to your physician or make an appointment to be seen if you have questions or concerns about this information or your medical condition. You assume all responsibility for use and potential liability associated with any use of the material.

Material contains copyrighted content, used in accordance with U.S. law. Copyright holders of content included in this material should contact [open.michigan@umich.edu](mailto:open.michigan@umich.edu) with any questions, corrections, or clarifications regarding the use of content. The Regents of the University of Michigan do not license the use of third party content posted to this site unless such a license is specifically granted in connection with particular content objects. Users of content are responsible for their compliance with applicable law.

# 718 Advanced Topics In Removable Prosthodontics / CD And RPD Repairs

Fractured Denture

Fractured or Damaged Tooth /  
Modification of RPD

Post Dam Modification

Clasp Repair

# Disclaimer:

Mentions of specific products in these slides represent the opinion of the speaker only and do not represent endorsement by the University of Michigan.

# Common Repairs For Complete Dentures / RPD's

Fractured Denture

Fractured or Damaged Tooth /  
Modification of RPD

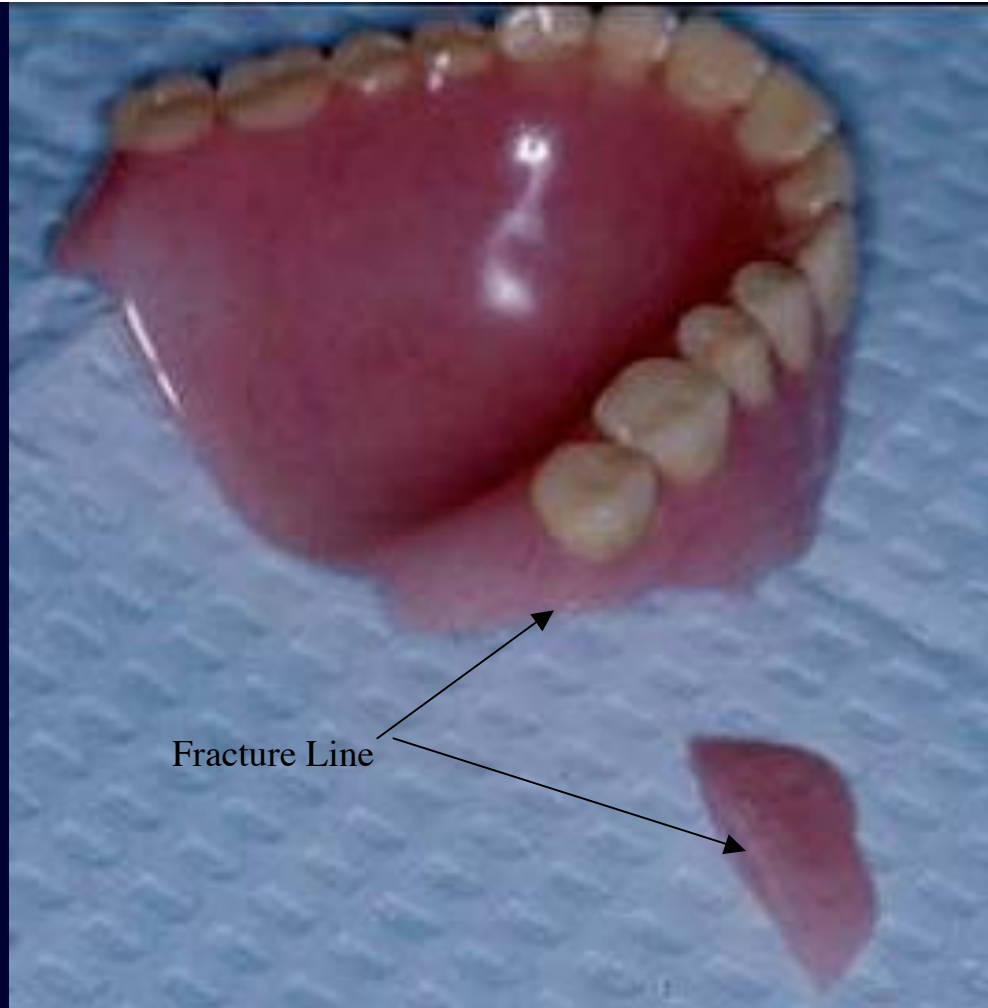
Post Dam Modification

Clasp Repair

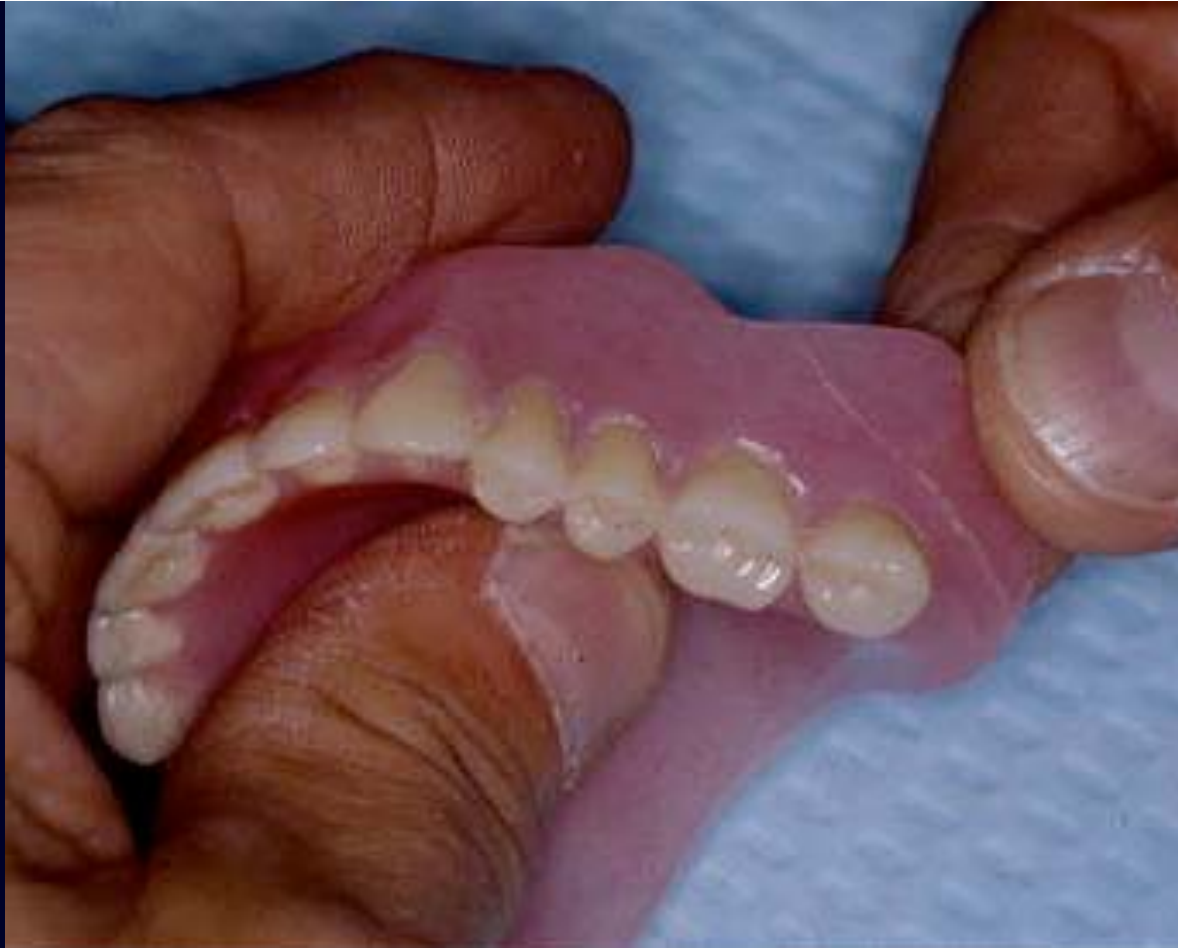# Types Of Materials Used In Repairs

Self-Cured Polymethylmethacrylate ( PMM )

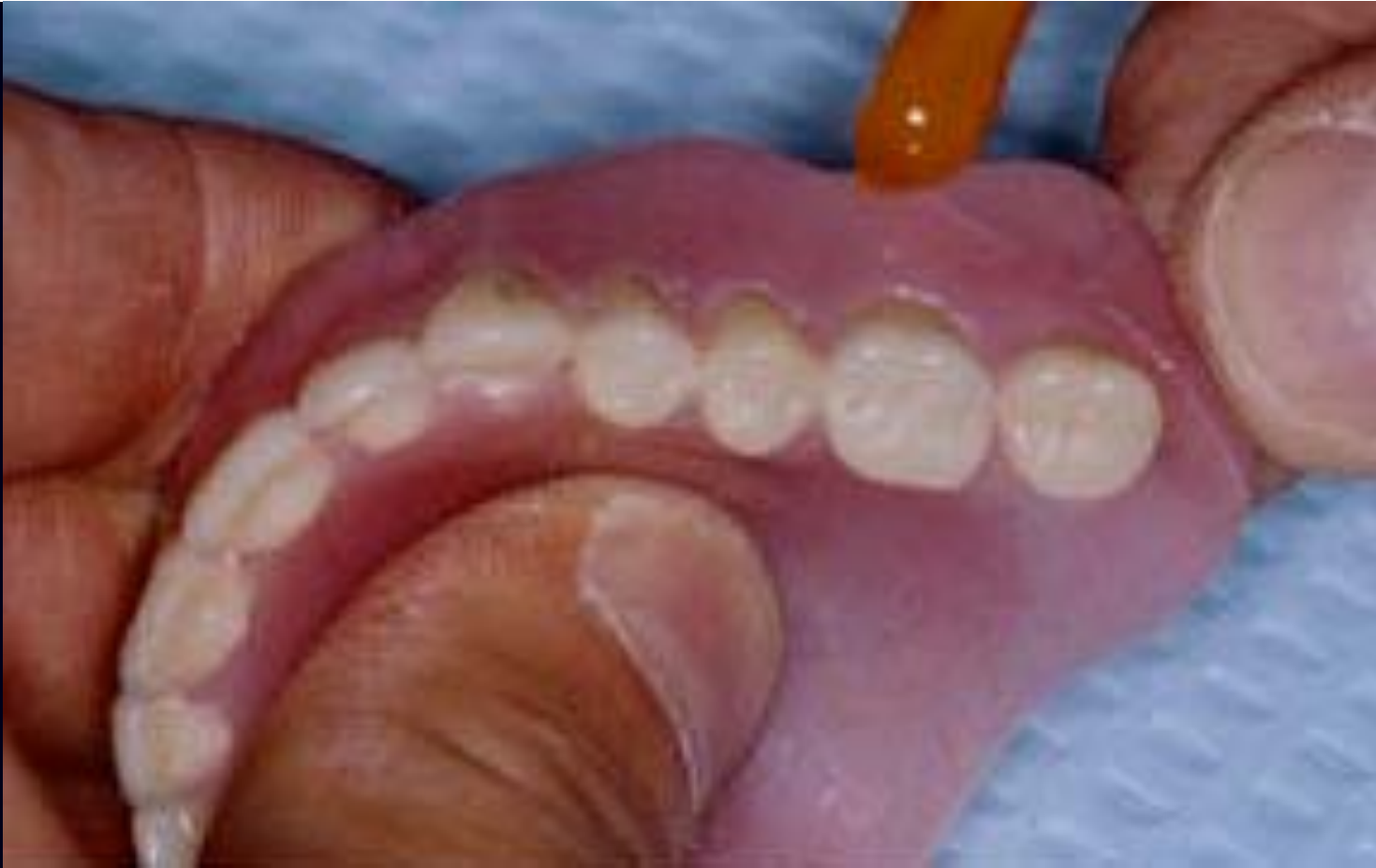Triad Light Cured Composite Material



Here a fractured flange is shown, but the process is the same for any fracture of a denture base. A midline fracture of a maxillary or mandibular denture would follow the same steps.

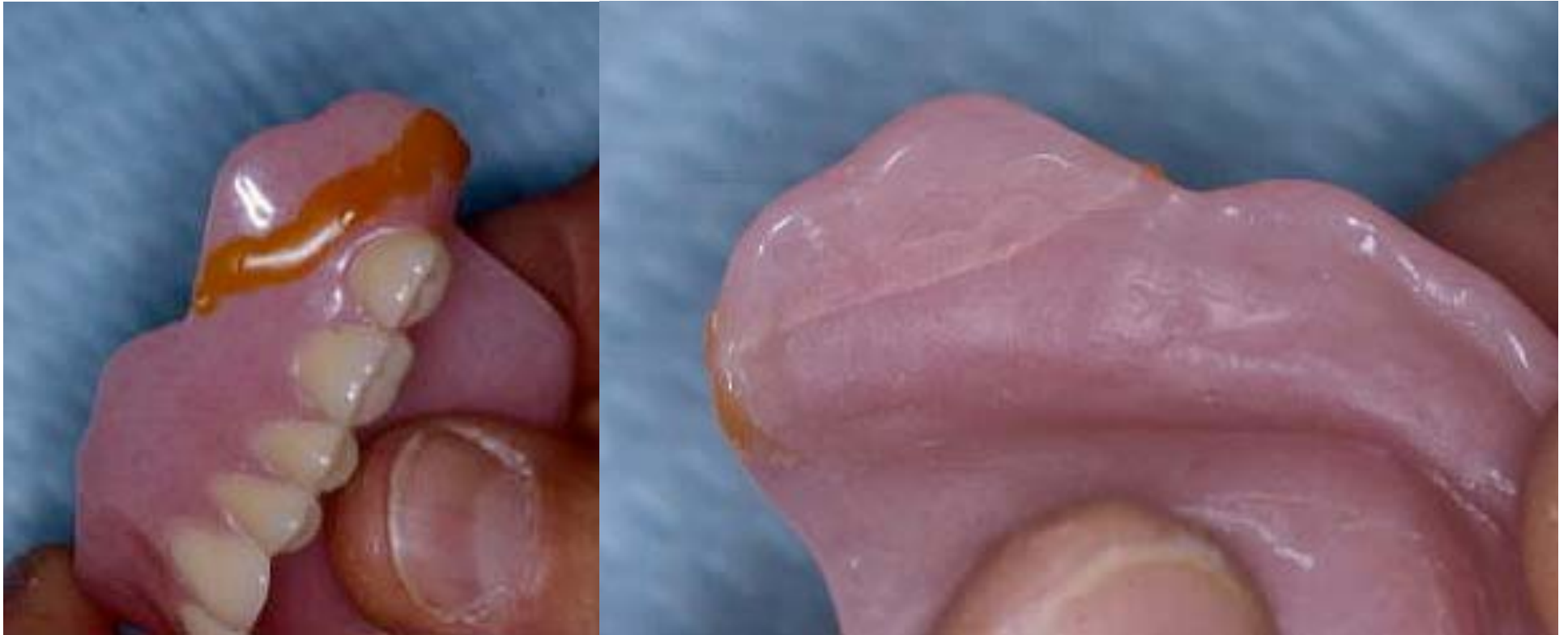


First, hold the pieces of the fractured appliance together to evaluate their “fit”. If the segments don’t relate very accurately, we have a problem at this stage.



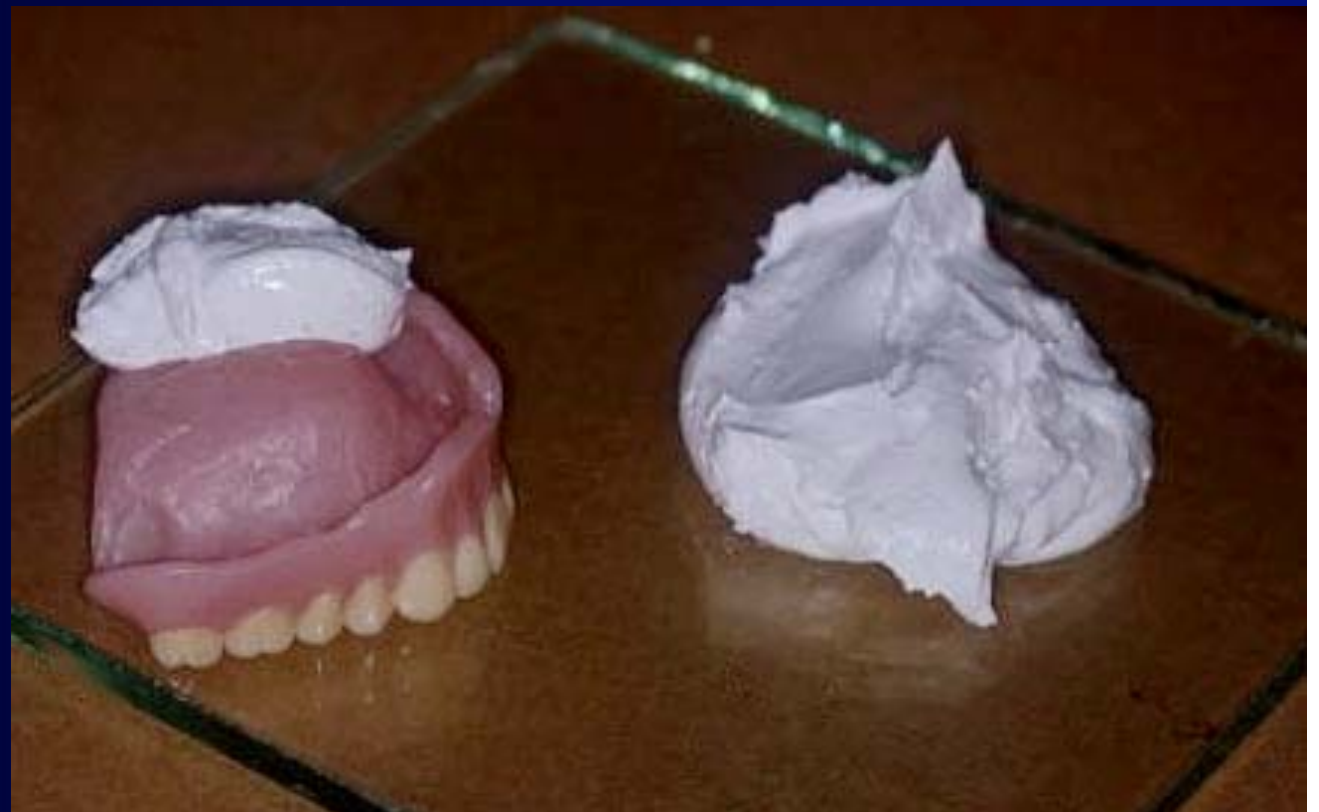
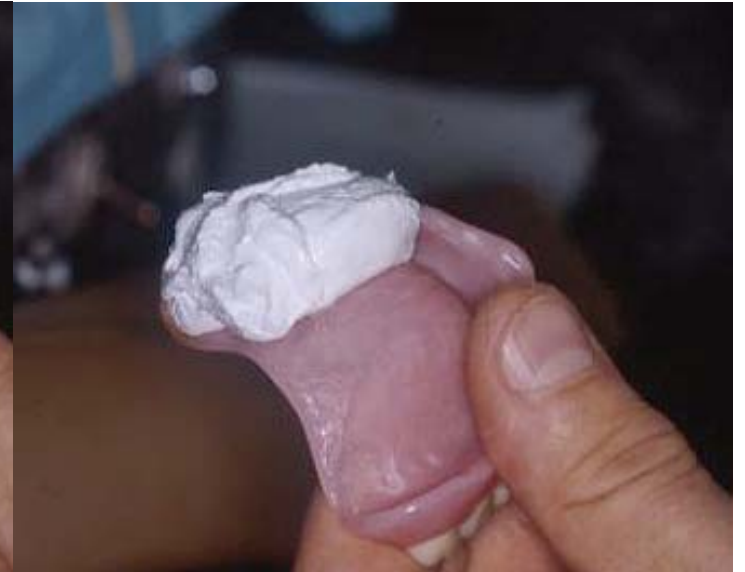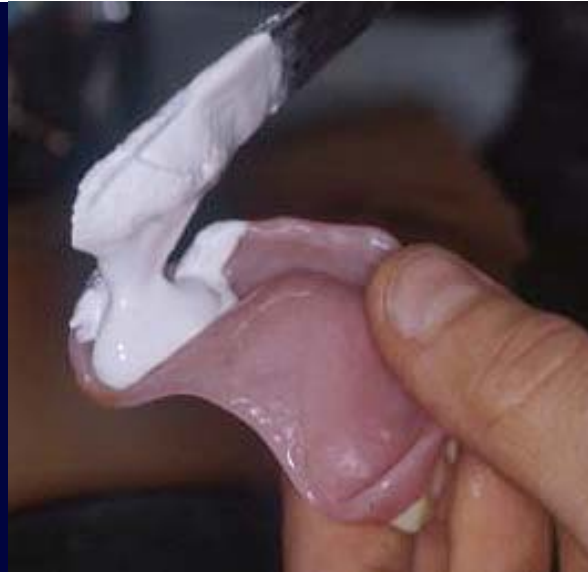While CAREFULLY holding the segments together, have someone flow sticky wax at the fracture line to temporarily hold the segments together.

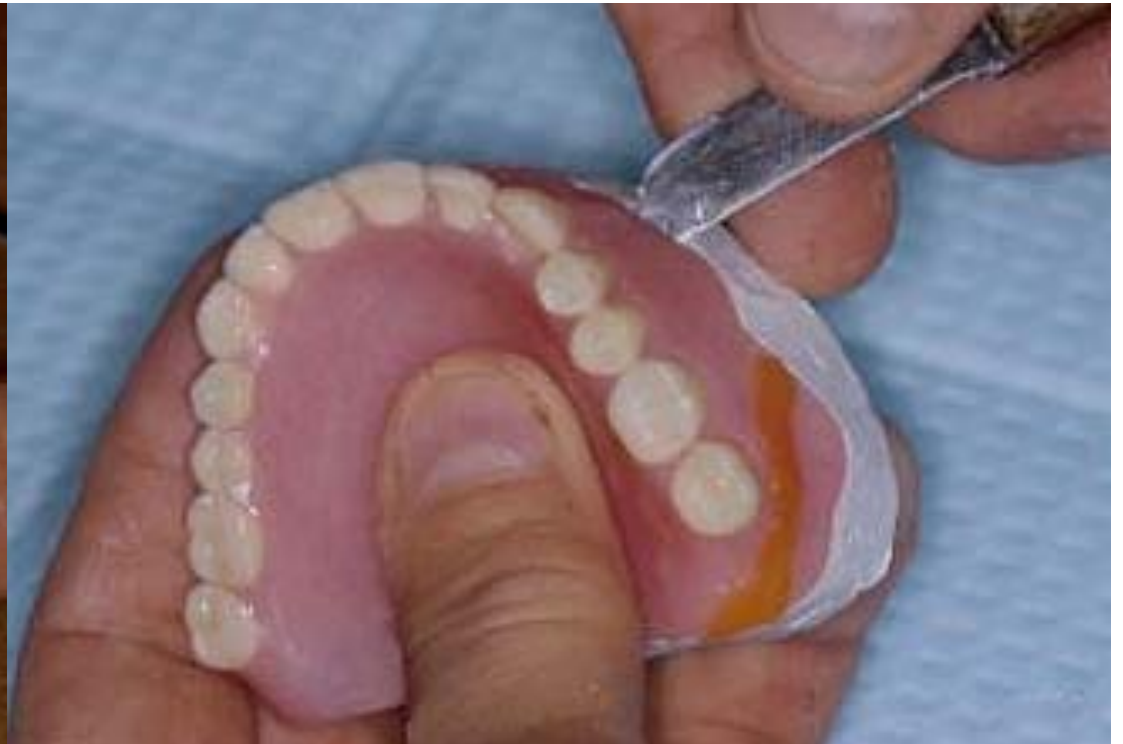
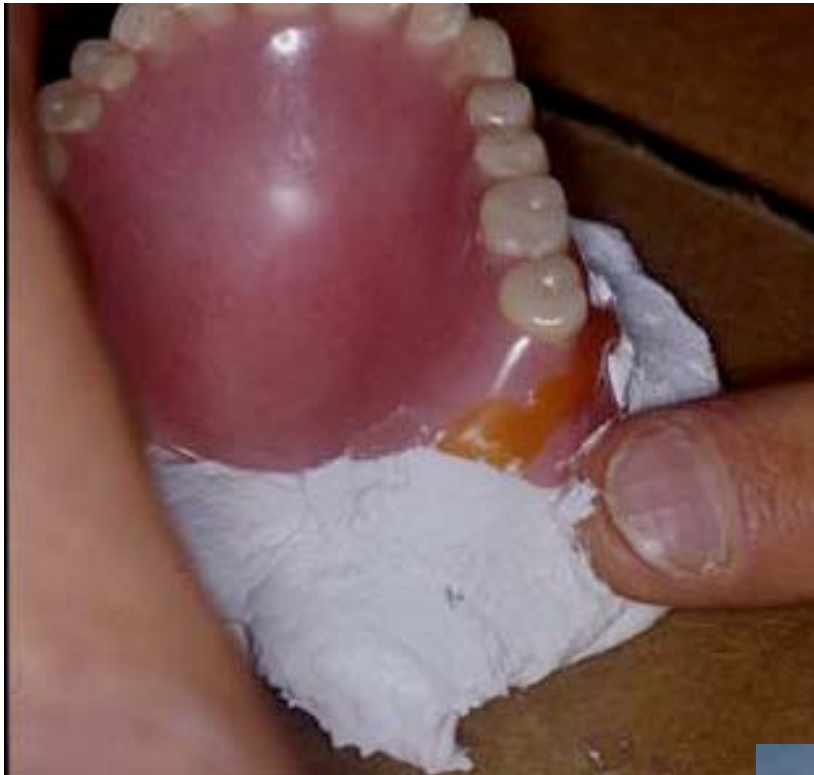


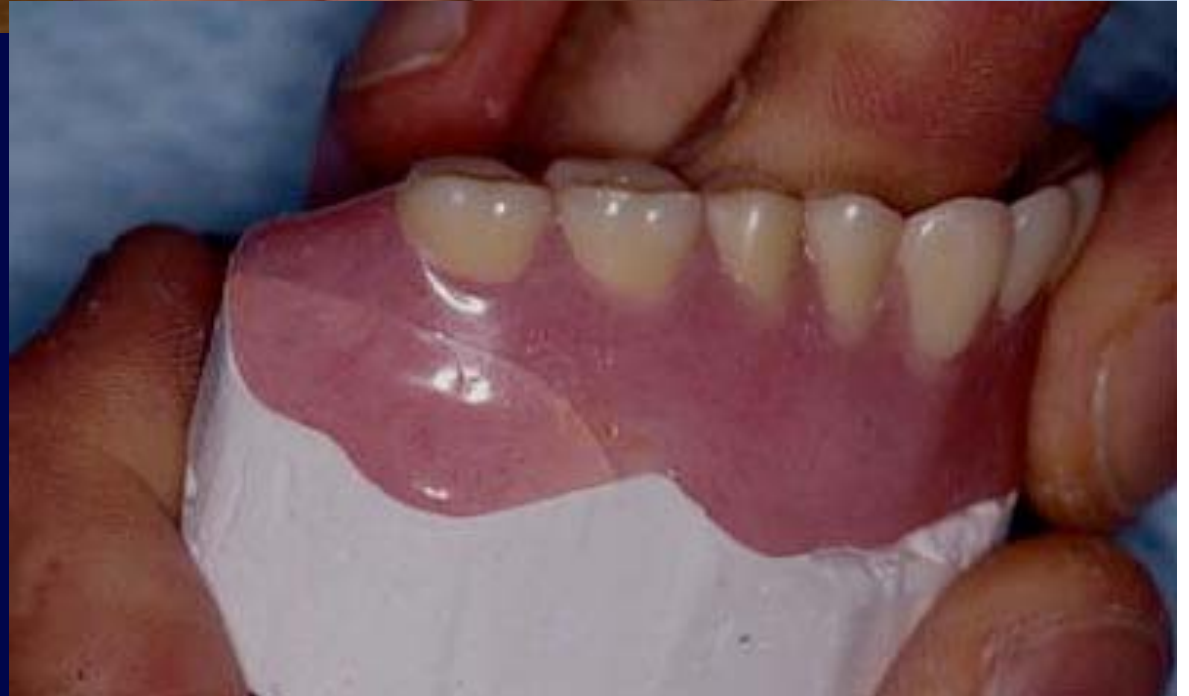These images show the segments held together with sticky wax. Note that the inner aspect of the denture has no wax in it at all. The fracture is visible as a fine line on the inner surface of the denture. We will now make an index which will orient the segments during the remainder of the repair process.

Once the segments of the denture have been related, we make an index using fast setting plaster. The plaster is first carefully placed in the denture in the area of the fracture so that we have no voids in the index in this area. The denture is then inverted on a small base of plaster to complete the index.

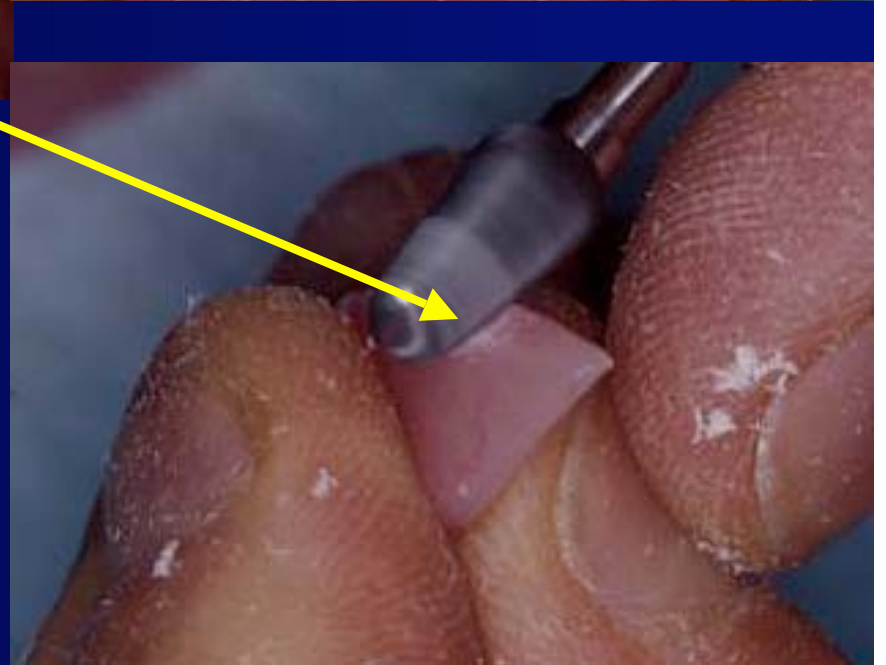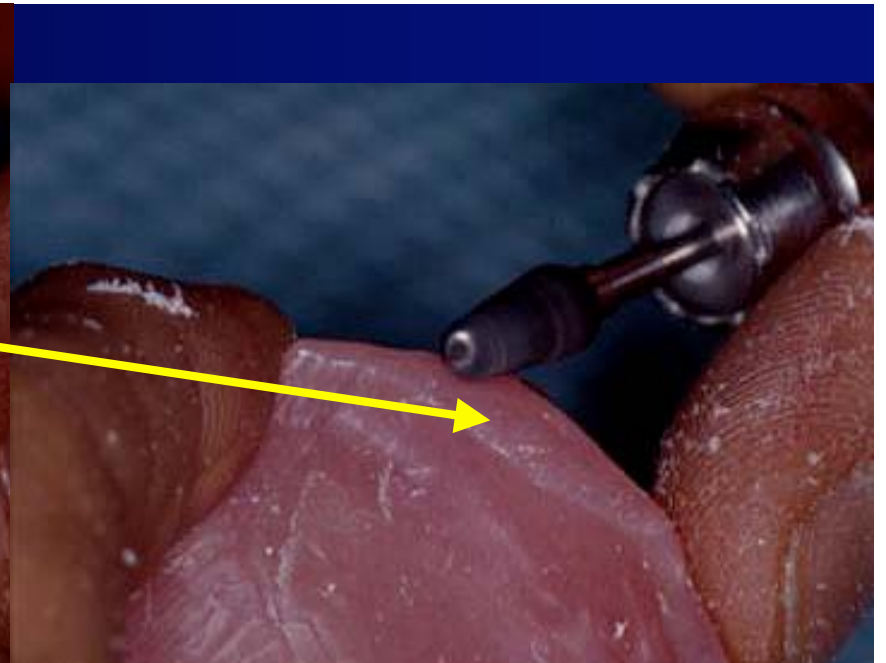
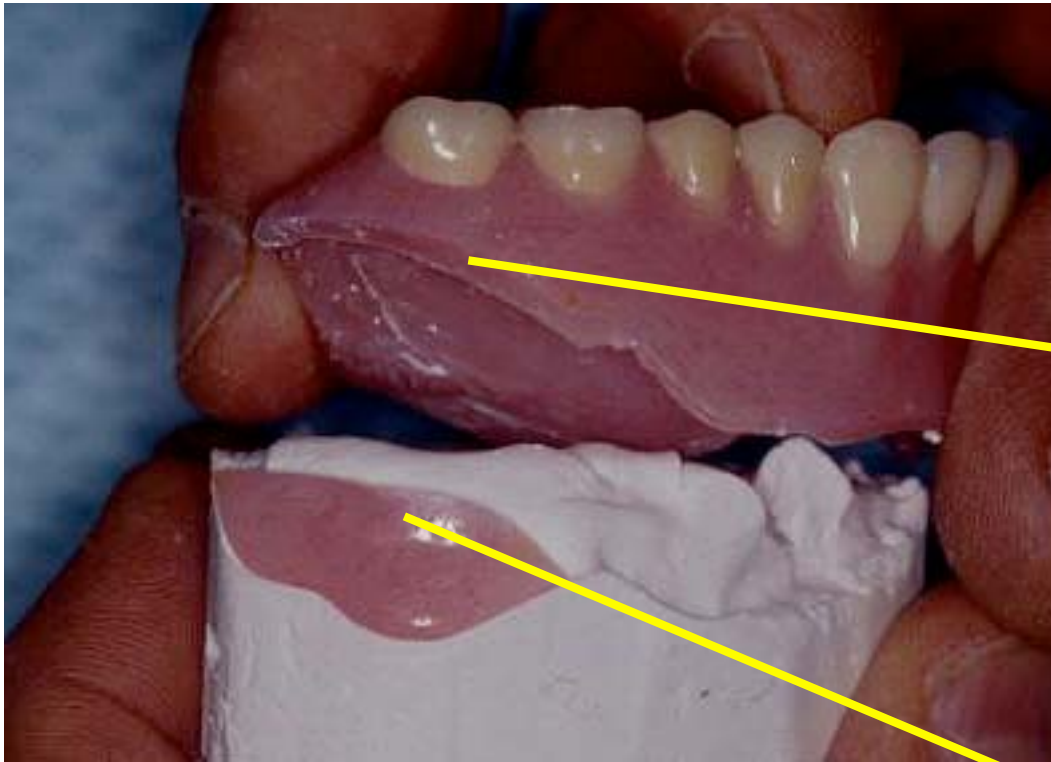




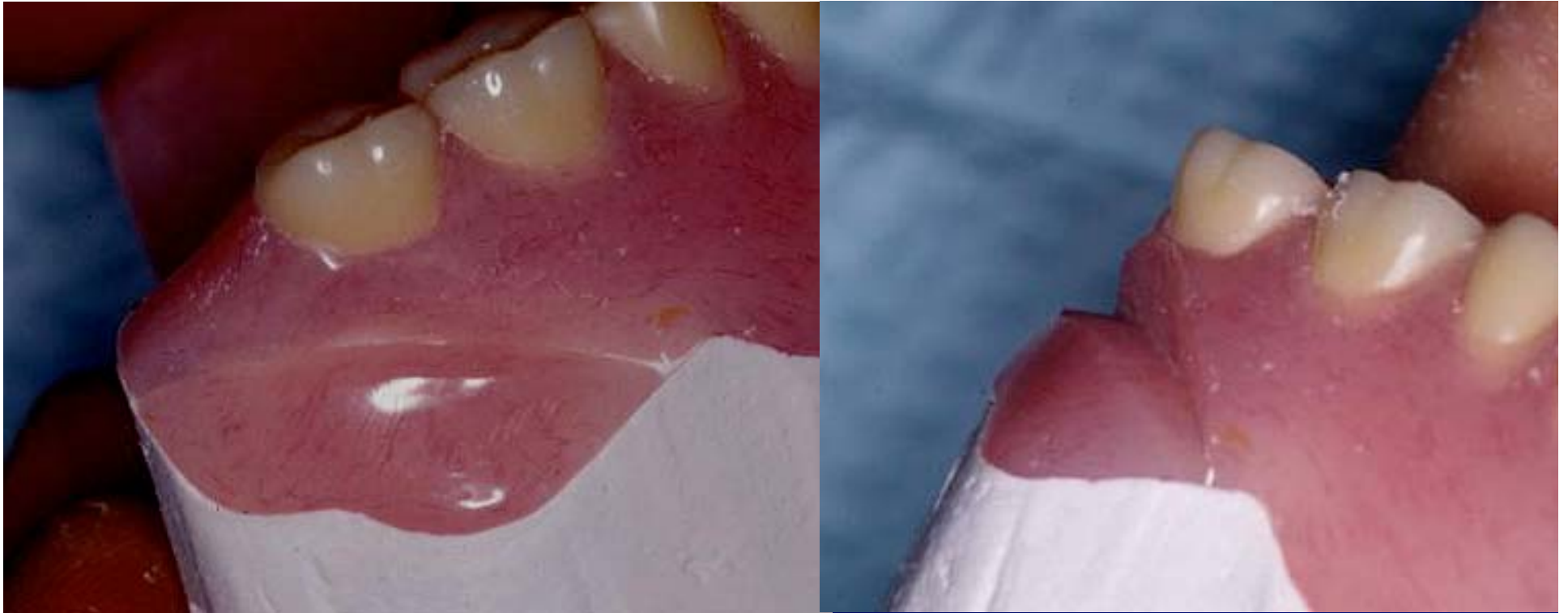
The denture is inverted on the base of plaster and the peripheries smoothed. After the plaster sets we have an index to relate the segments for the repair procedure itself.



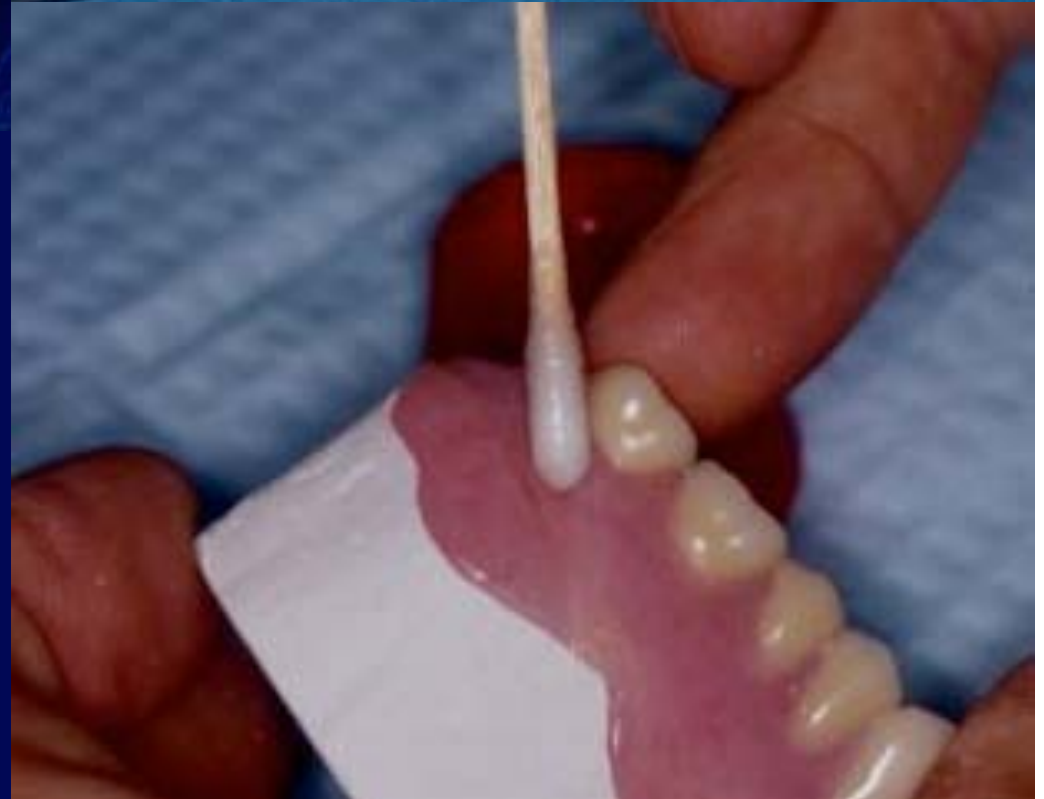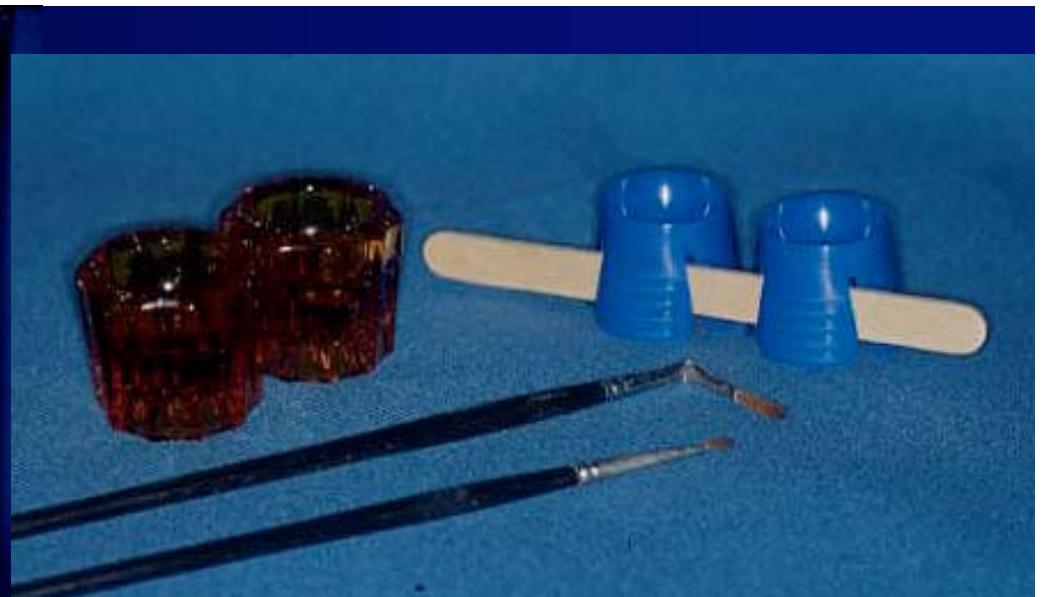




The denture is then lifted off the index and the edges of the broken segments are beveled toward the outer surface. This will provide fresh acrylic to allow a better repair as well as provide more surface area for the repair acrylic to bond to.

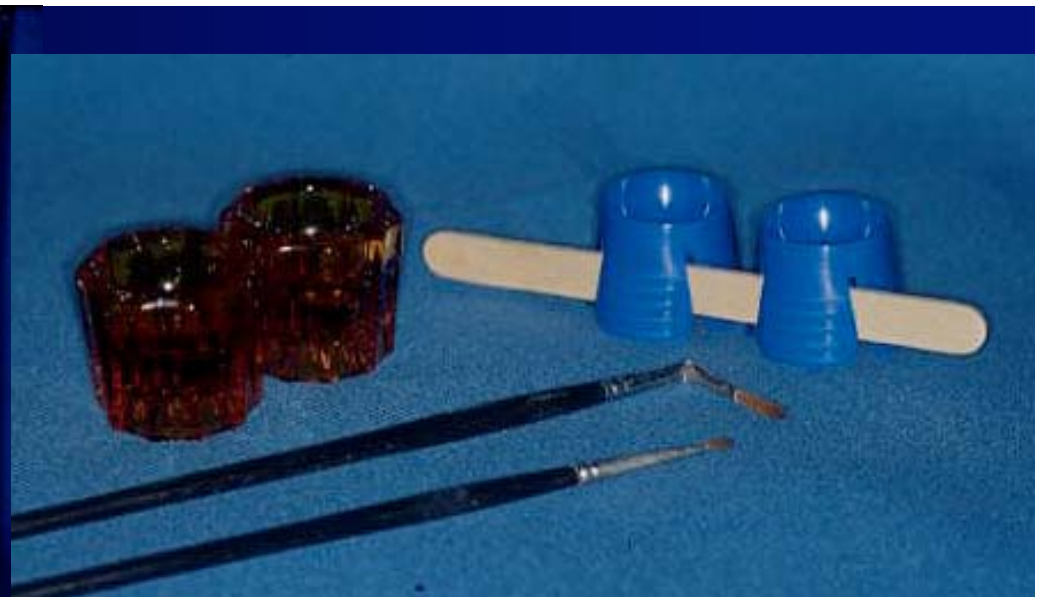


Here we have two views of the beveled surfaces ready for the addition of repair acrylic. Note the bevel is toward the outer surface of the denture. This leaves the inner surface minimally disturbed. We also have a large surface area for the new repair acrylic to form a bond with.

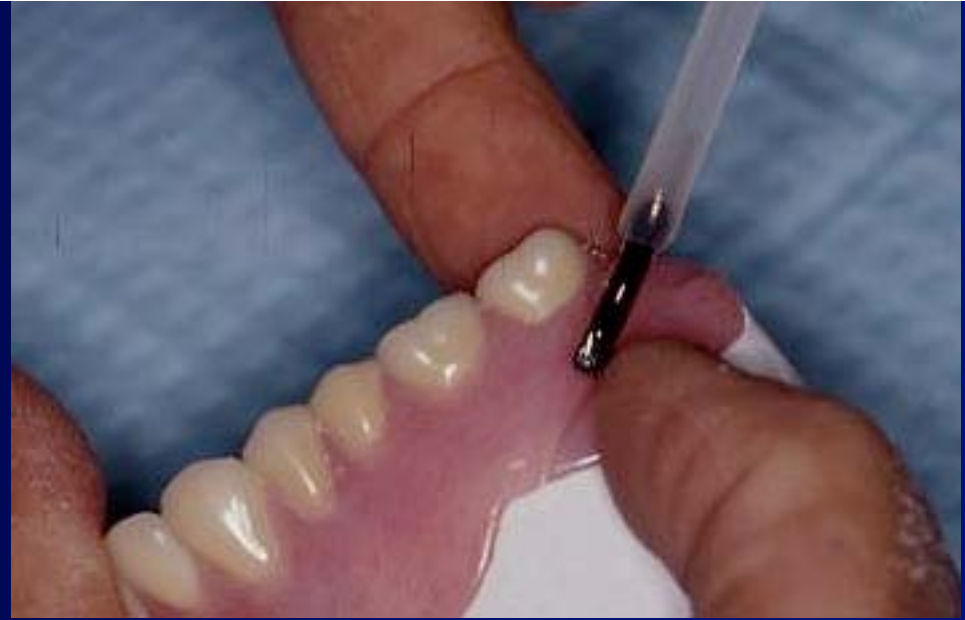
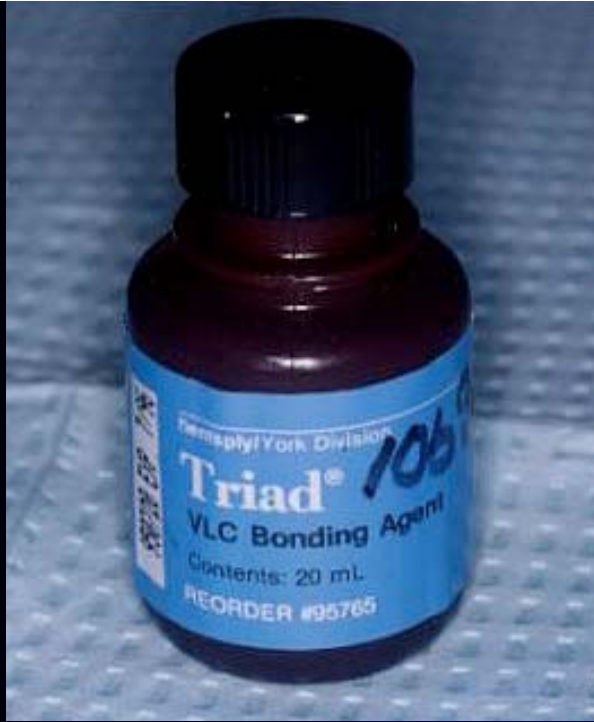
The repair acrylic is checked out from the desk. Place some liquid and powder in dappen dishes and use a paint brush to place the acrylic in the defect. Note the pre-moistening of the repair area with monomer prior to placing the repair acrylic.





Repair acrylic is then placed along the fracture line by dipping the brush in liquid and picking up a small increment of powder. The increments of repair acrylic are placed in the defect and the denture placed in warm water.

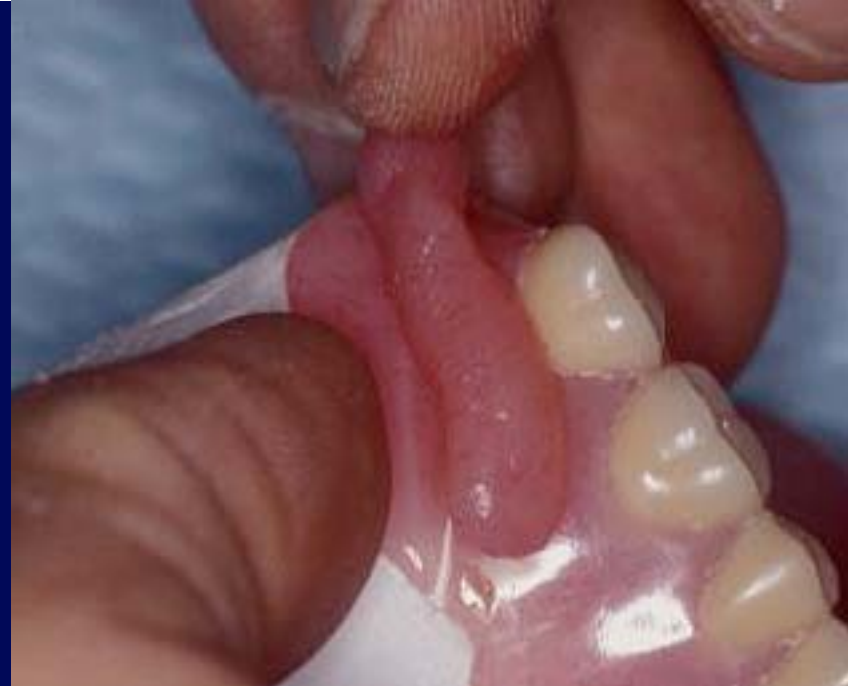

As an alternative, the repair may be performed with Triad light cure material. If this technique is used, the fracture line must be given a thin coating of VLC bonding material. A small segment of pink Triad light cured material is then placed along the fracture line and molded to fill the defect and blend with the surrounding acrylic.

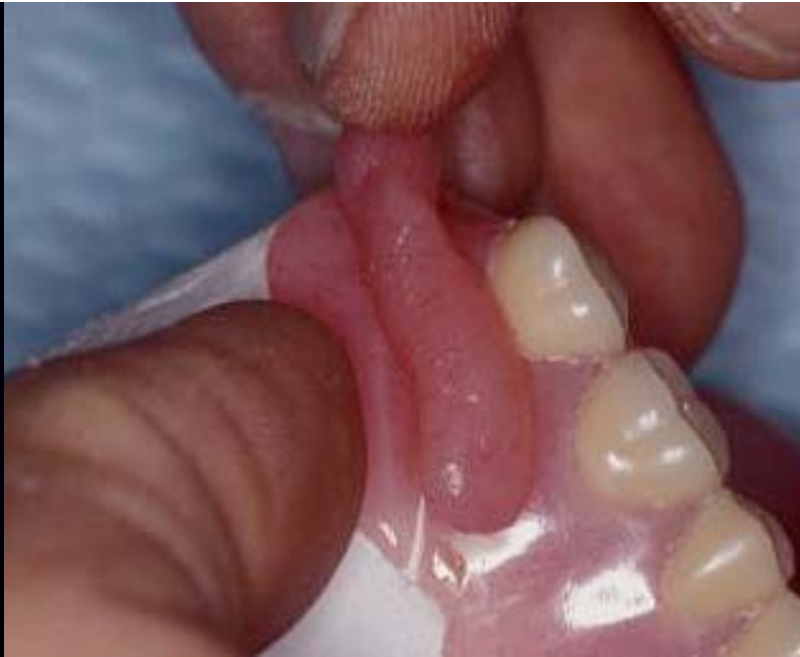

TRIAD®  
Reline  
VLC Resin  
Regular Pink  
Fibered

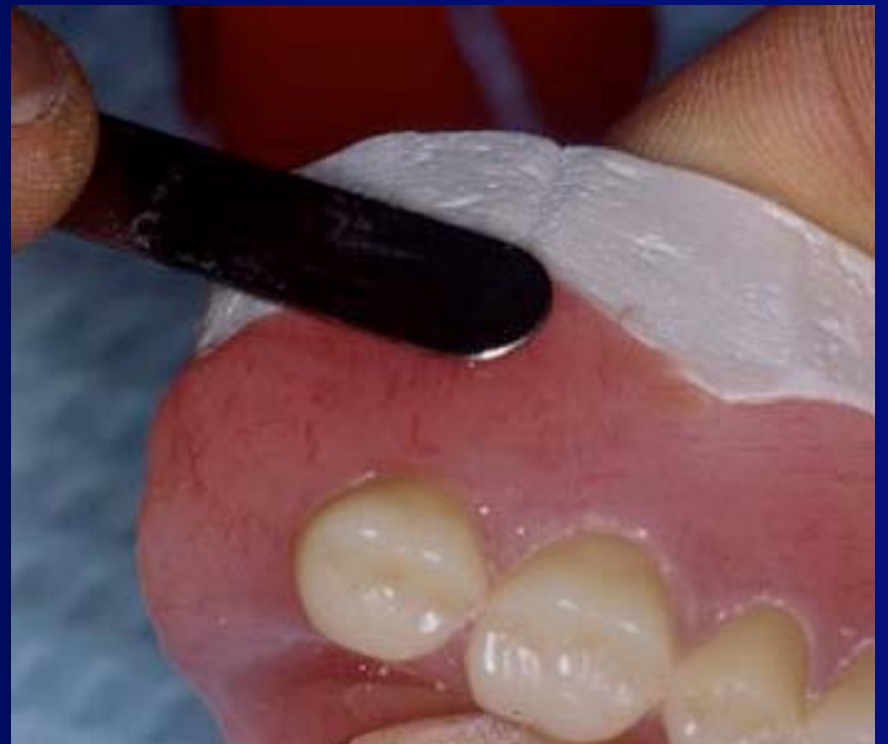931122B EXP 9603

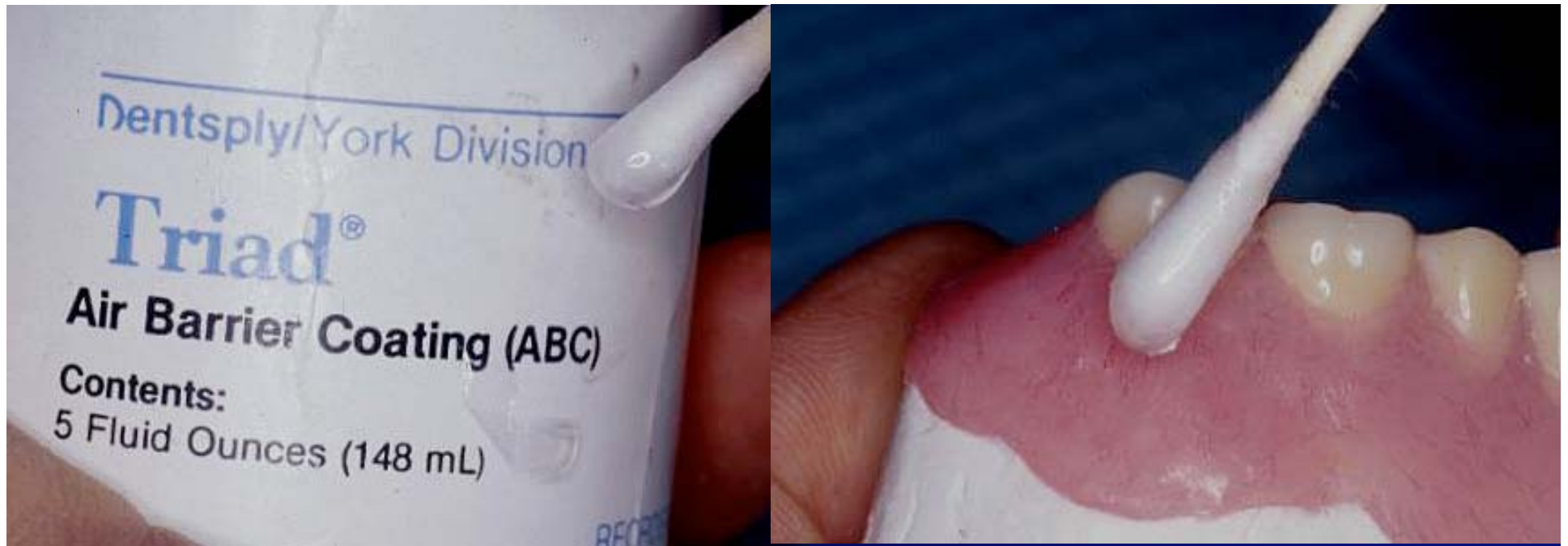


The plastic packet of the material is opened and a small piece of the material is cut from the sheet. The material is then shaped to a small rope and pressed into the defect at the fracture line. The material may be worked like clay at this point and blending with the surrounding material may be accomplished with a spatula and some repair acrylic liquid.

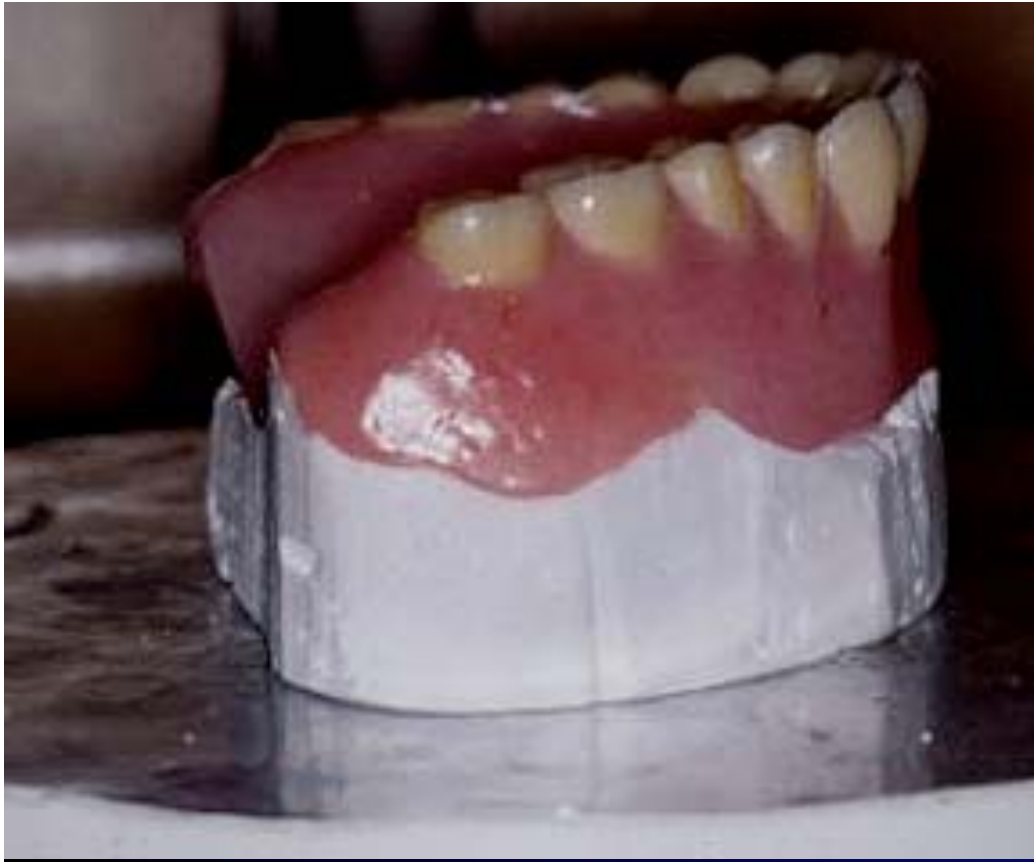

The material is blended in the defect and the margins are smoothed with the spatula moistened with self cure liquid as shown here.



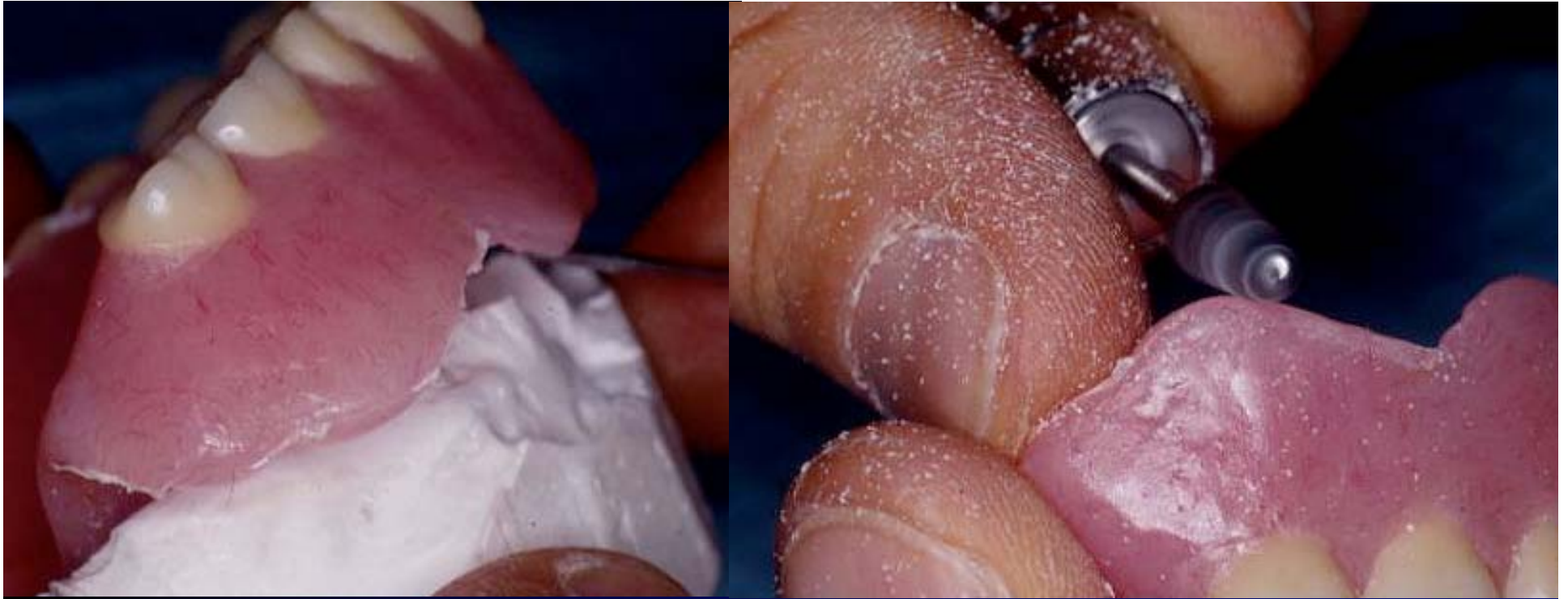

Once the Triad material has been blended, it is coated with an air barrier coating prior to curing in the light curing unit. The reason for the coating is that the surface of the Triad is inhibited from fully curing if it is in the presence of air. The thickness of the air inhibited layer is very thin and this is the reason we don't commonly use the ABC when making trays and baseplates. For the repair of a denture, however, we want the surface to be fully cured and use the air barrier coating.

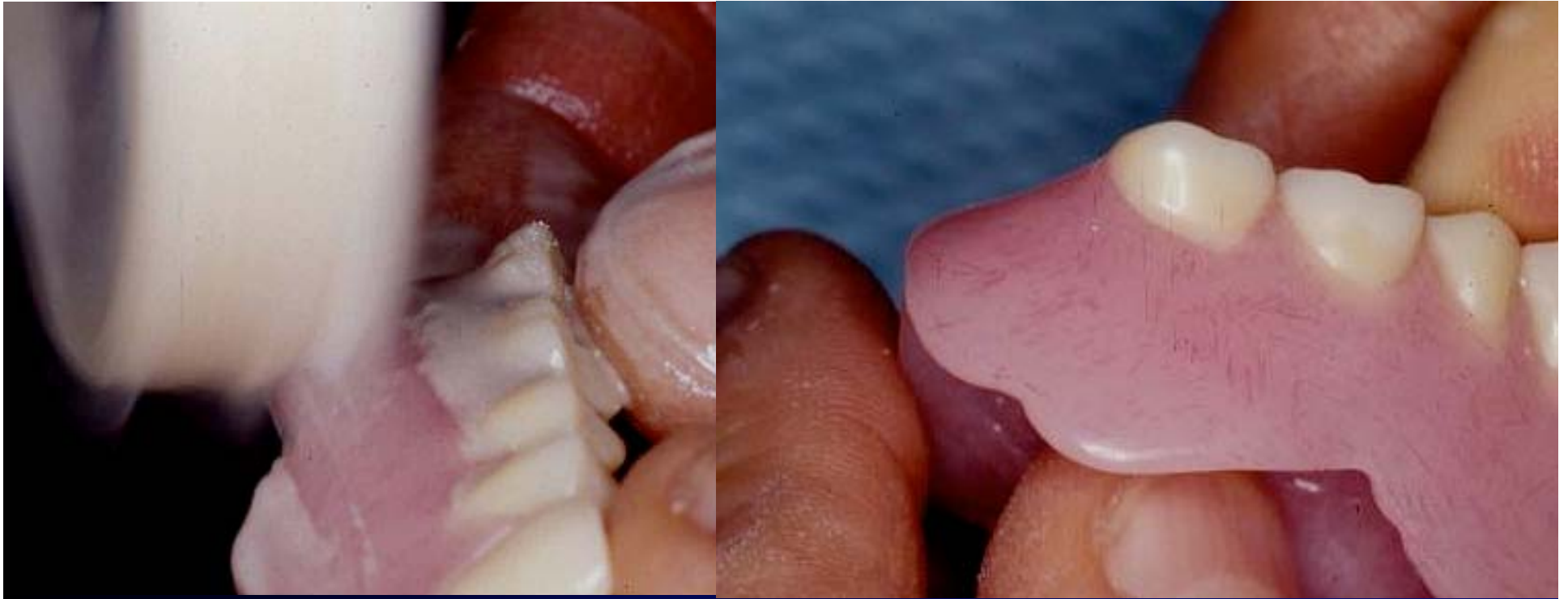

The denture is then placed in the curing unit and exposed to the intense visible light for 10 minutes. The material used for the repair of the denture requires a longer curing time than the material used for trays and record bases. The presence of the air barrier coating on the surface insures a complete cure of the outer surface of the material which provides a better finish to the cured denture.





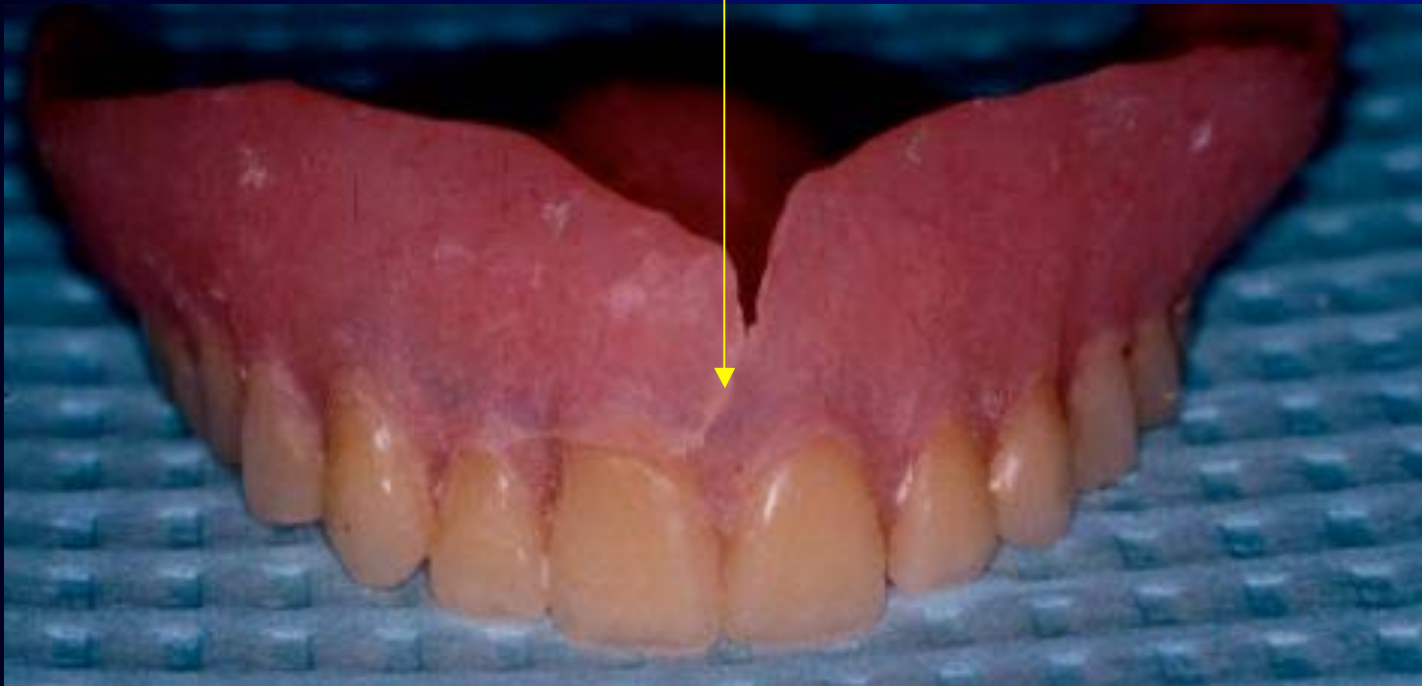
The completed repair is removed from the index and the area smoothed with an acrylic bur. If the repair is done with self cure acrylic rather than Triad, this procedure is will proceed in the same fashion.

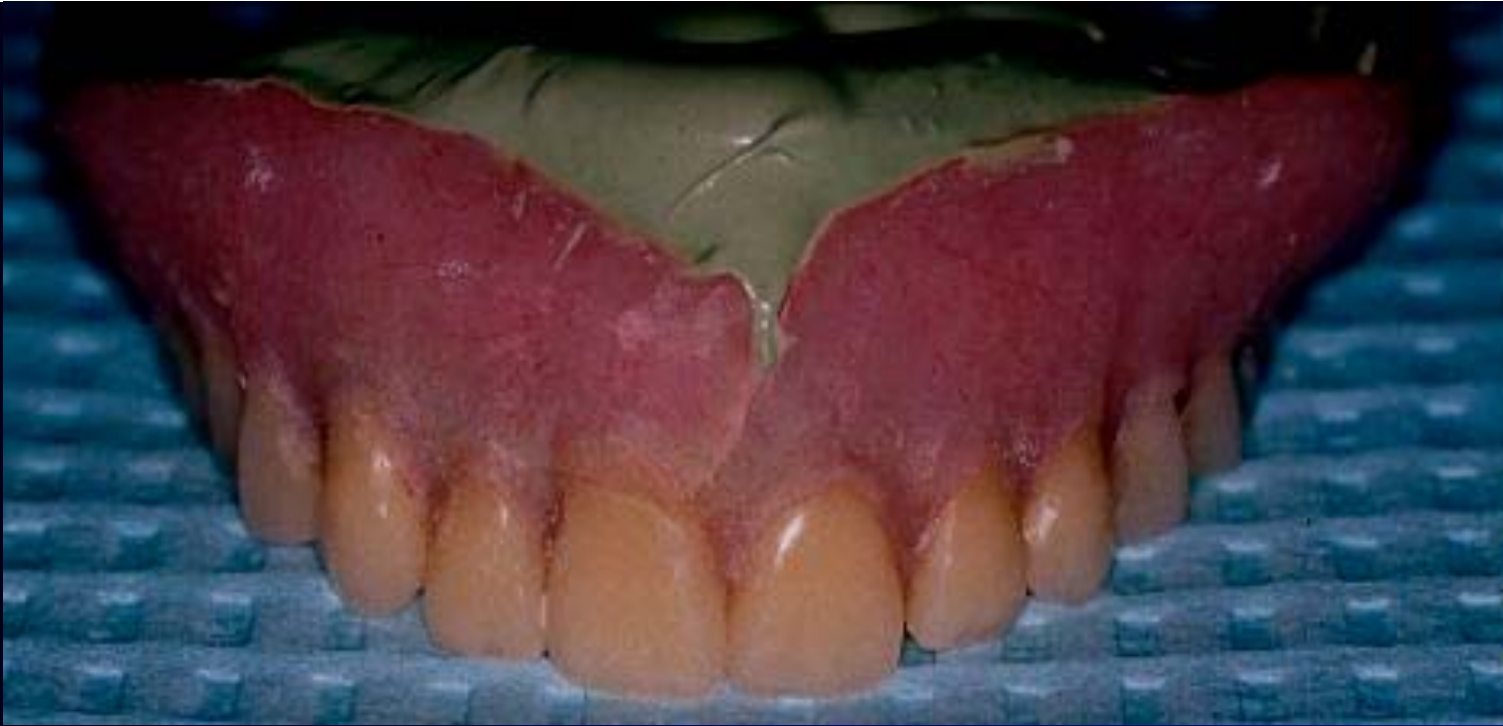

After the repaired area has been shaped and smoothed with a bur, the denture is polished with pumice and bendick. The completed repair will blend and be difficult to detect if done well. Again, a broken flange was demonstrated here, but a fracture of a lower denture in half or any fracture of the base of a denture is handled in the same manner.

Patient presents with a fractured maxillary denture.

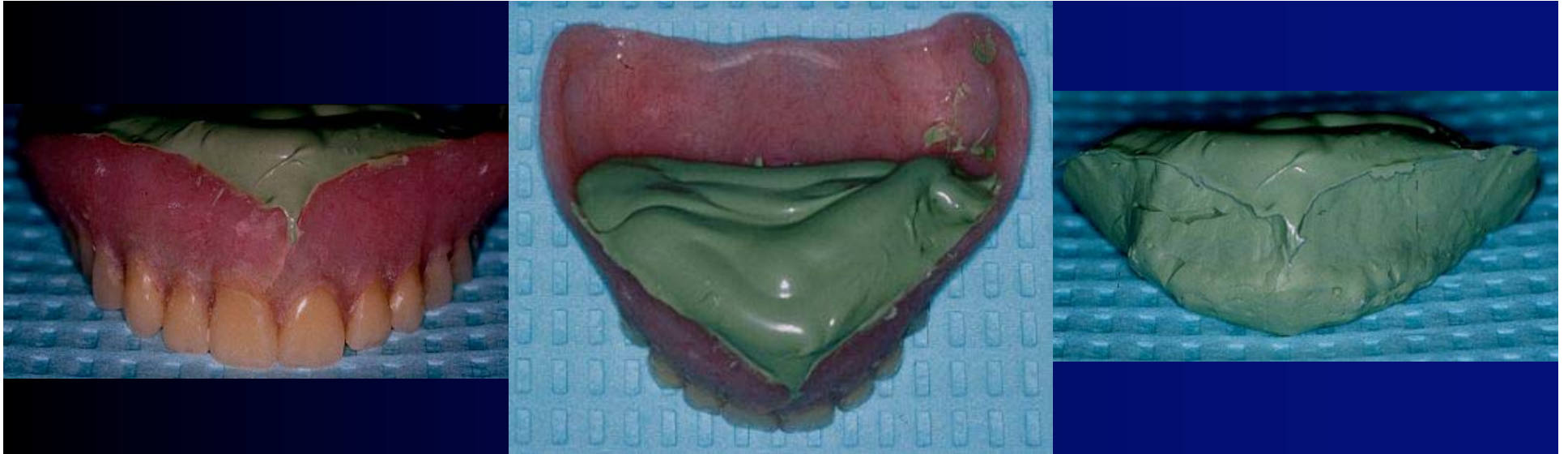
What do we do?



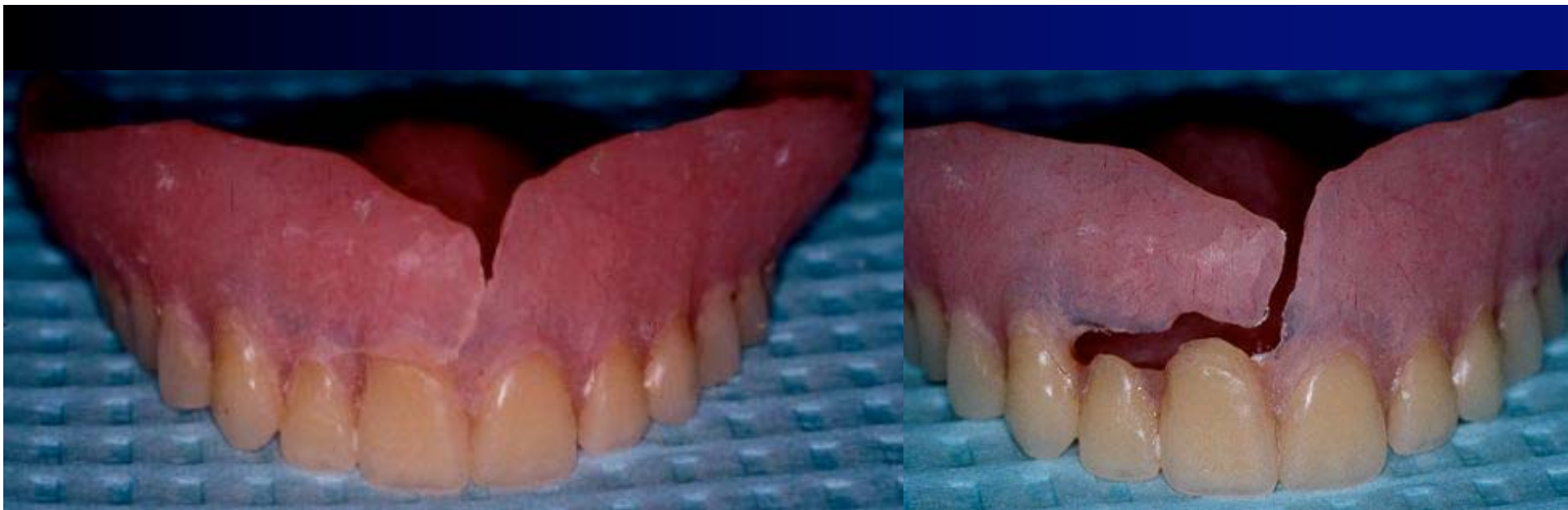


Fabricate a matrix inside the denture. This may be of an elastic material as shown here. If a material such as plaster is used, the undercuts may need to be blocked out. The block out may not allow the matrix to adapt closely to the inside of the denture.

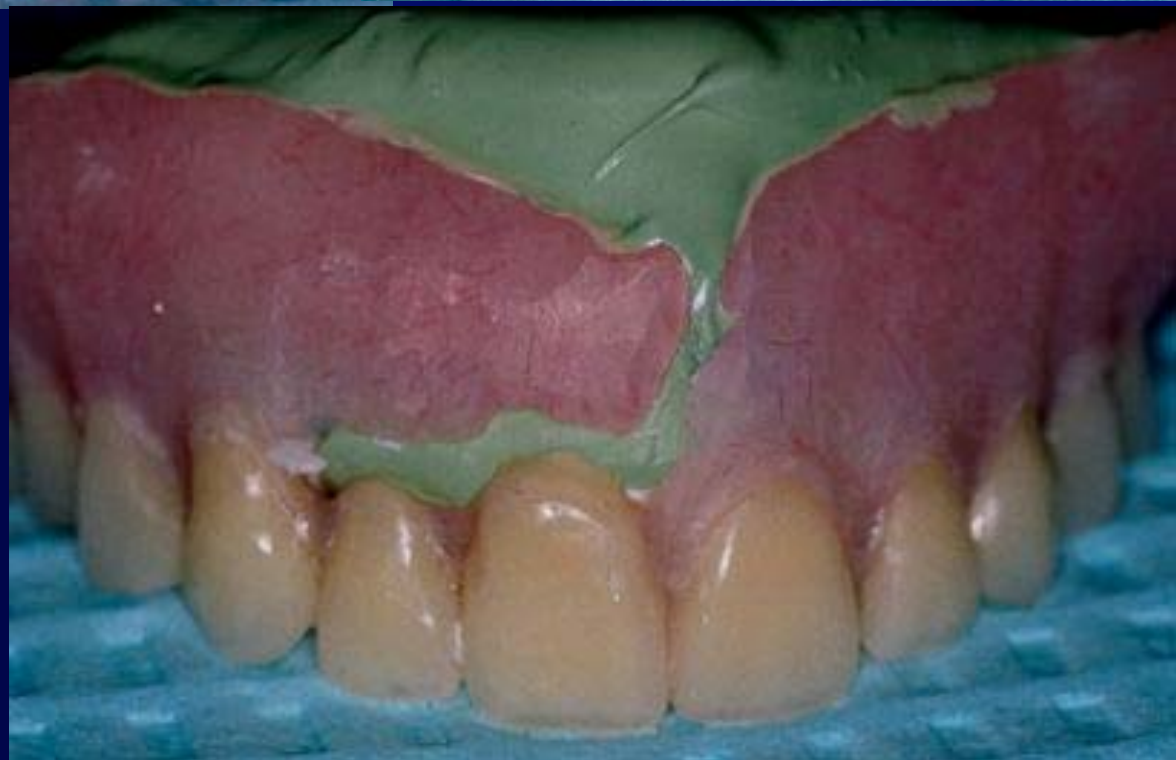



In this case, the matrix has been fabricated from medium bodied PVS. As you can see, the material can be removed from the denture easily. This will be the backing material when we perform our repair.



The fracture line on the denture is “cleared out” and self curing repair acrylic may be used to repair the defect.

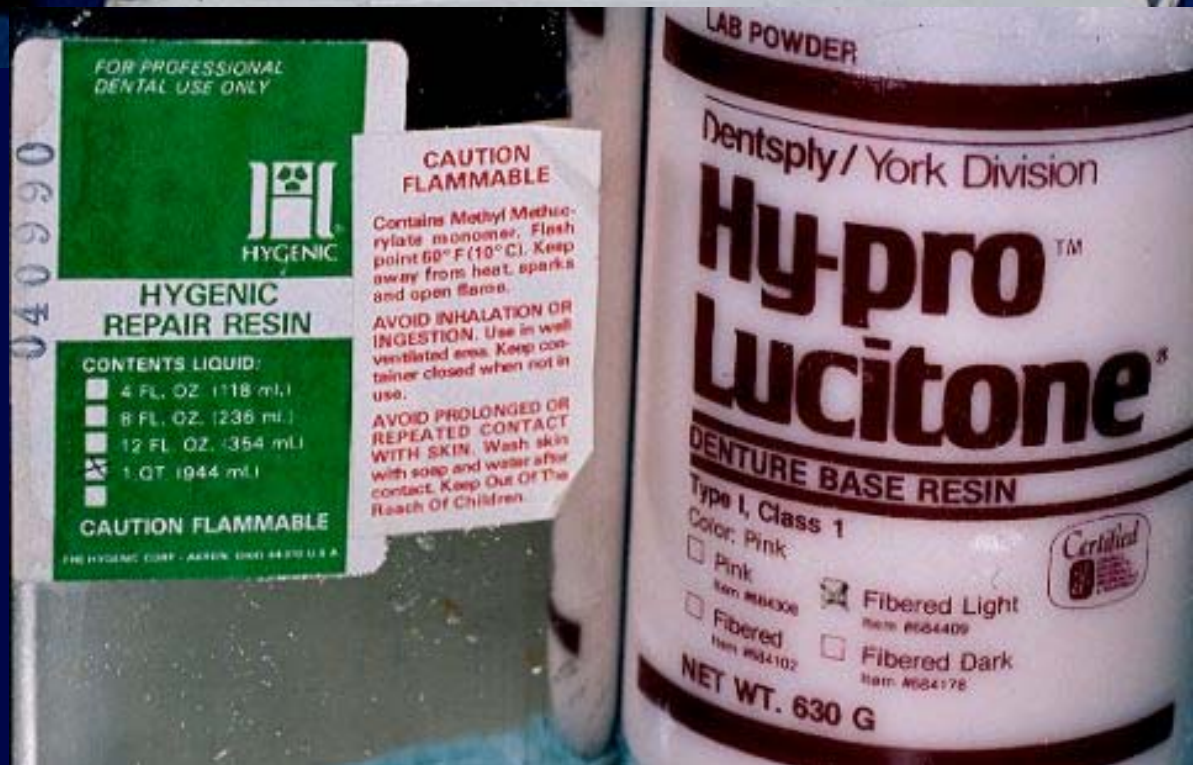




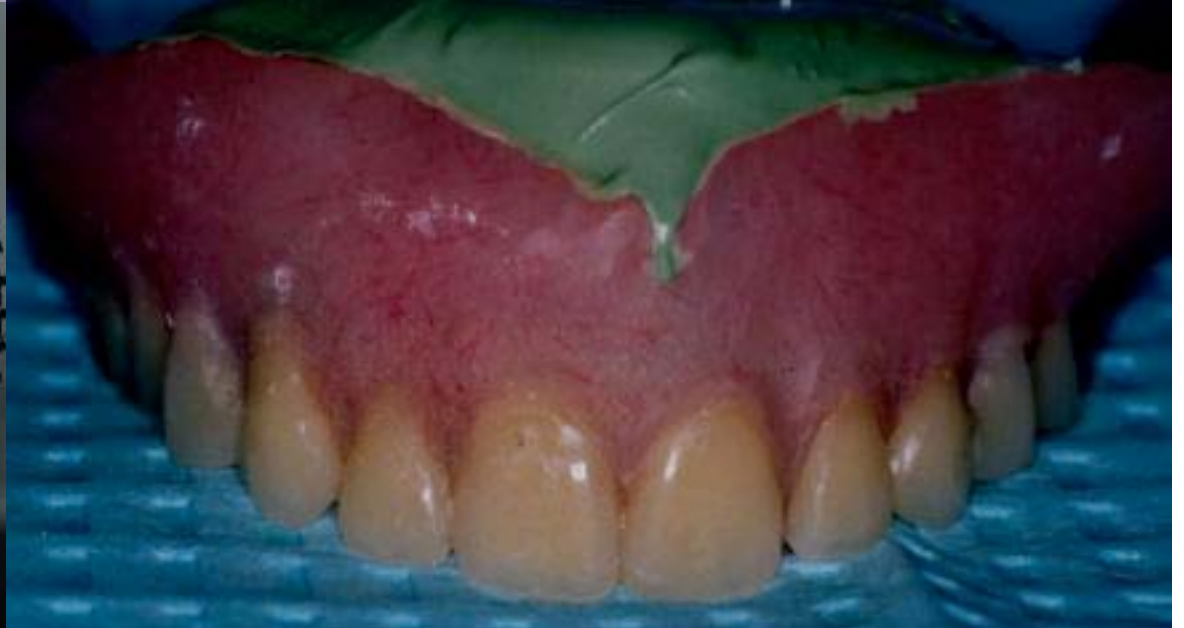
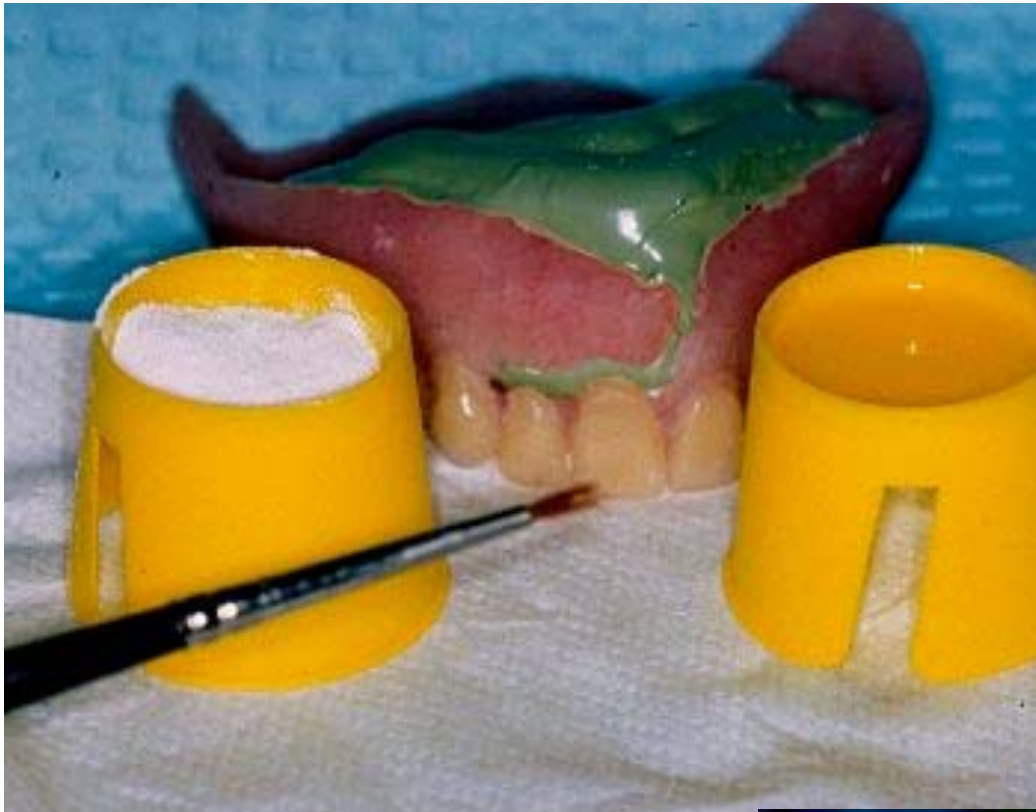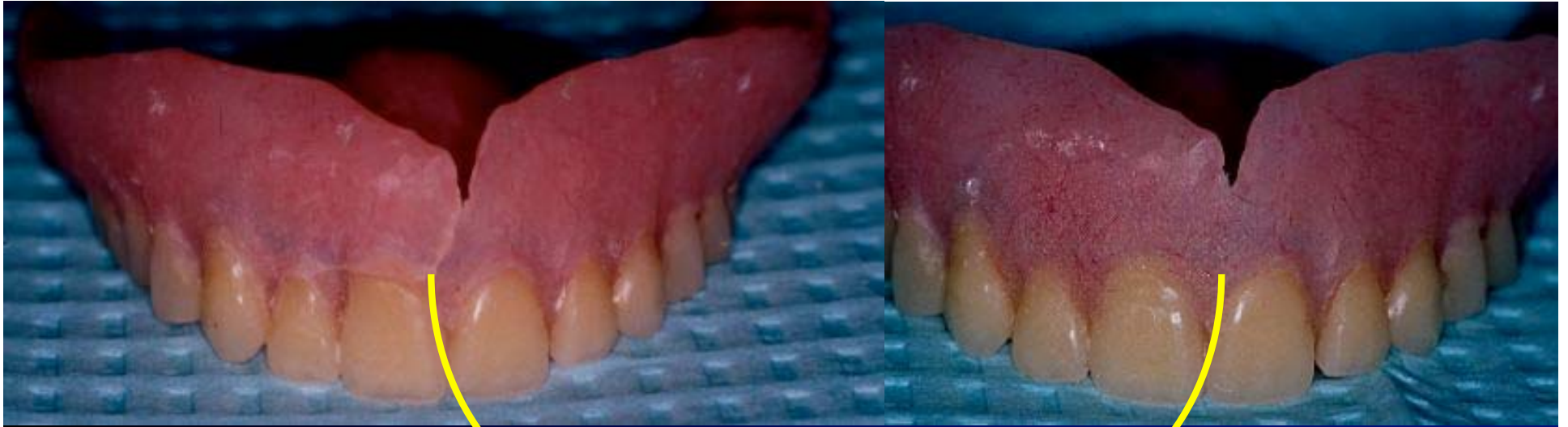Pictured here are two types of self cure acrylic and one “hybrid” repair combination.

Be aware of “Type I” and “Type II” acrylic when doing repairs.









Pre and Post Repair areas on the fractured maxillary denture.

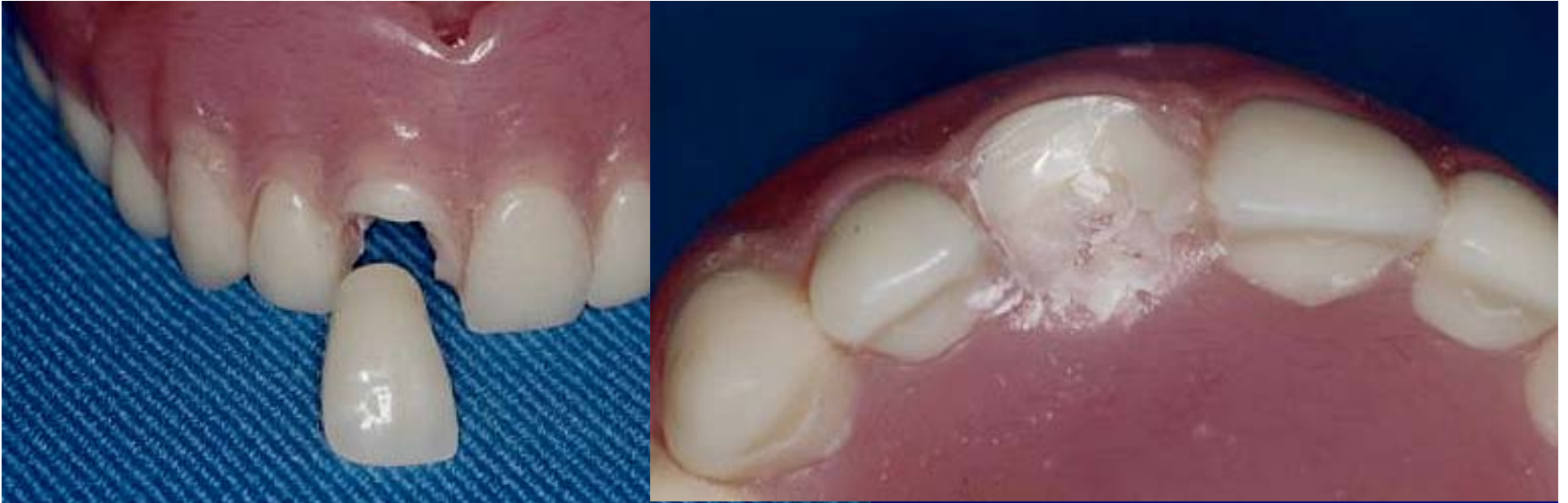# Common Repairs For Complete Dentures / RPD's

Fractured Denture

Fractured or Damaged Tooth /  
Modification of RPD

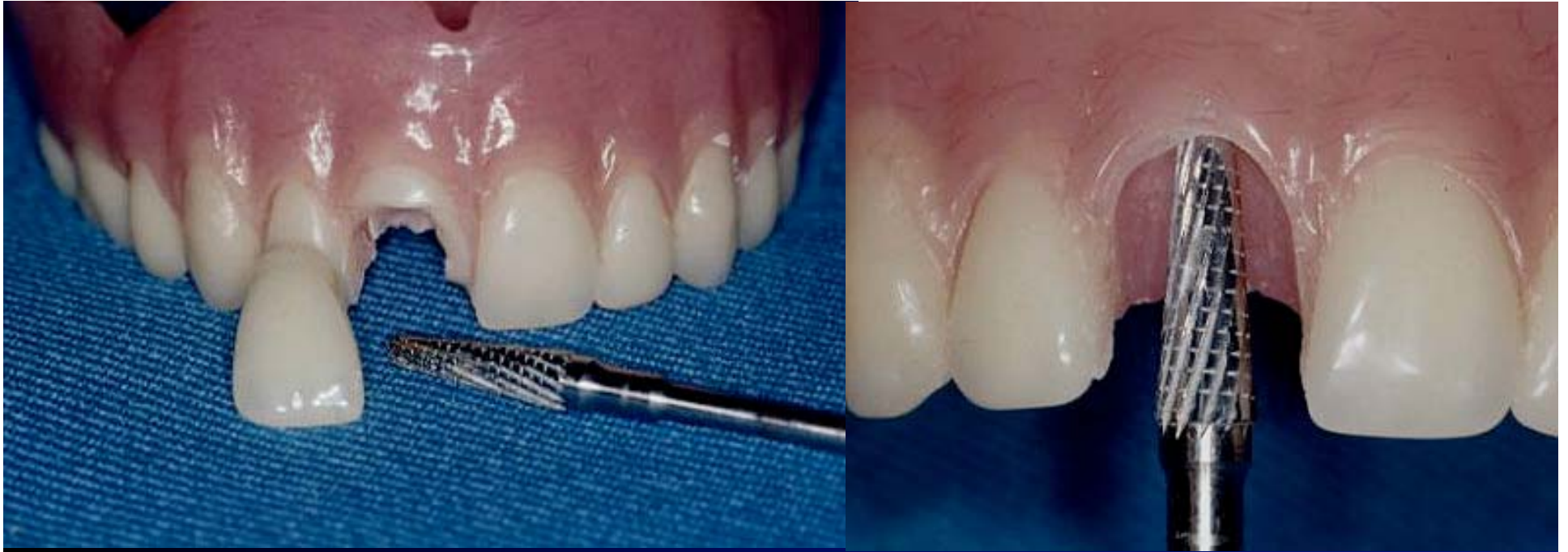Post Dam Modification

Clasp Repair



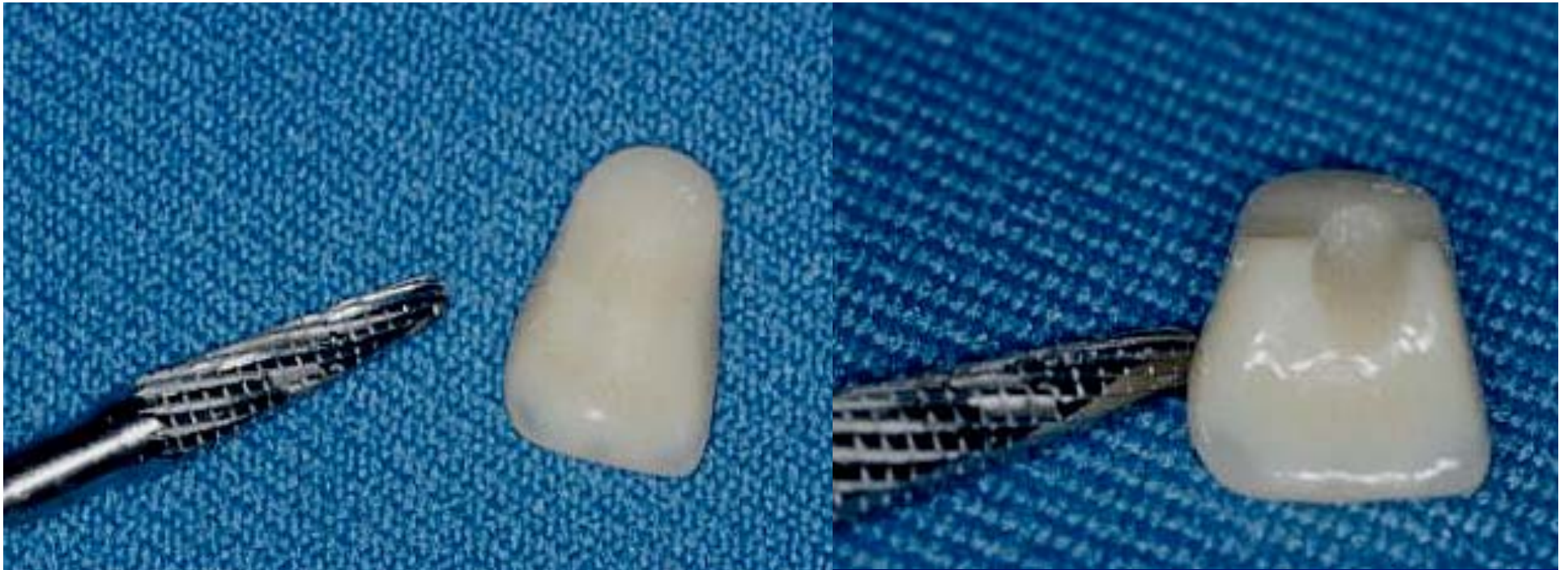
The typical tooth repair involves an anterior tooth. If you're lucky, the tooth will come out intact in which case it's just a matter of replacing the tooth with self cure acrylic. If the tooth is fractured, which is the case here, we need to select another tooth of the same size and shade for the repair.



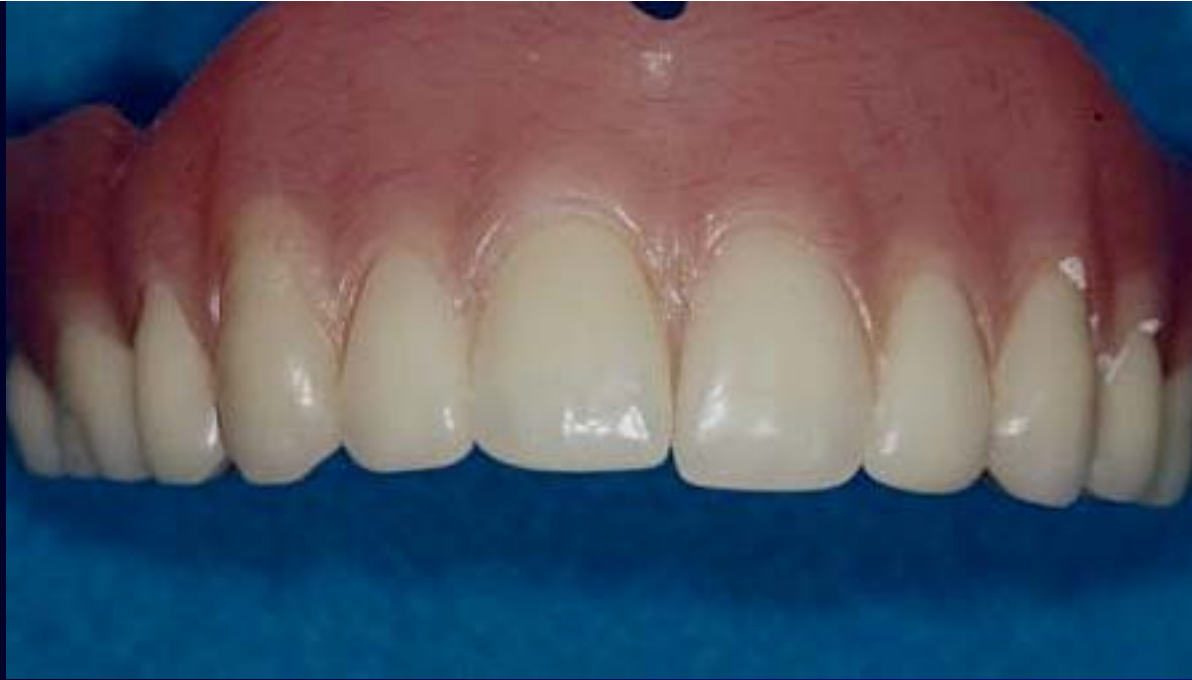

In this case which presents with a broken tooth, the remains of the fractured tooth are removed with an acrylic bur. Some care is taken to preserve the FGM area of the acrylic if possible. We have now created a recess into which the replacement tooth may be secured with self cure acrylic.



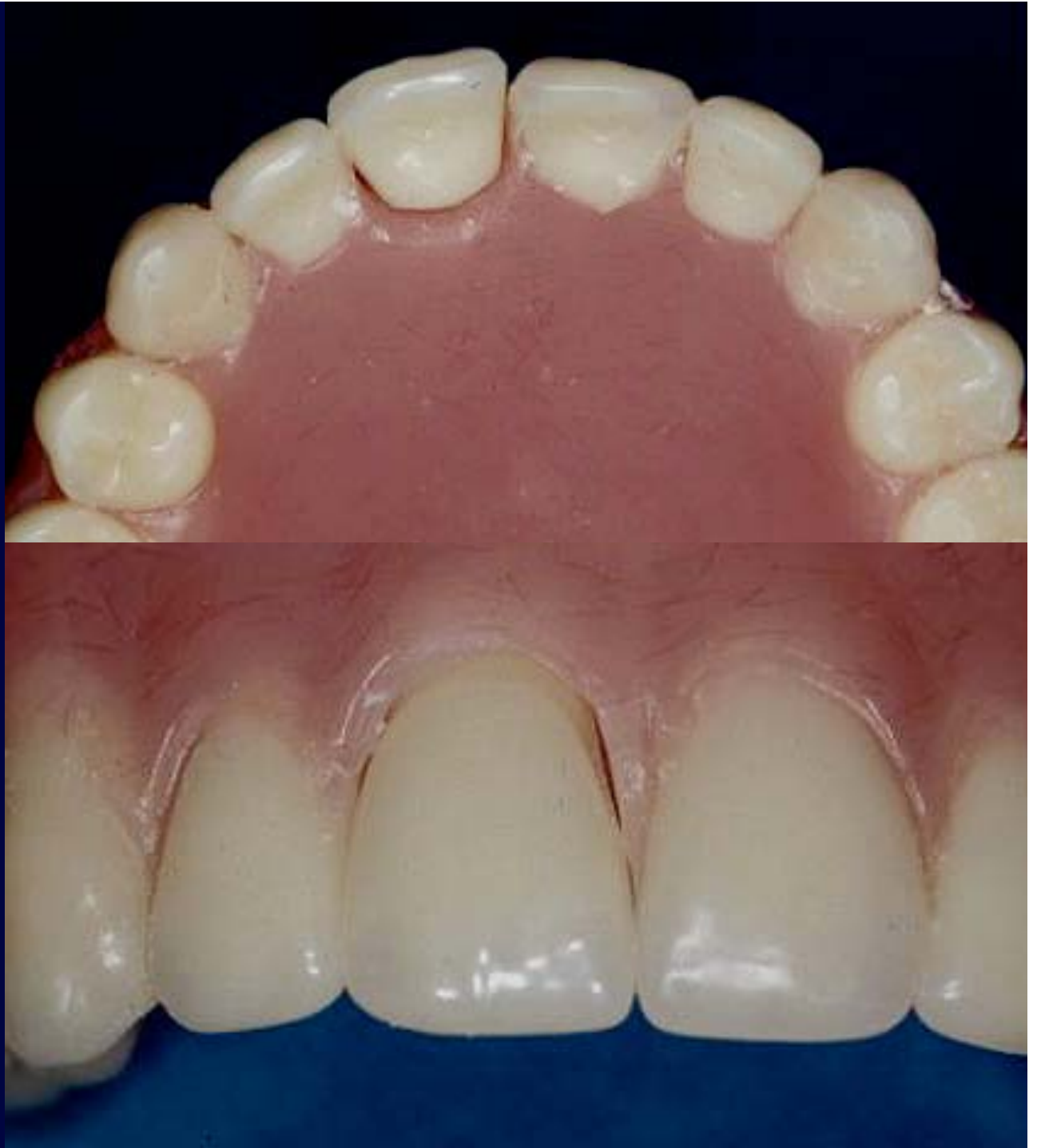

The replacement tooth is reshaped as well. It is common to shorten the cervical area of the replacement tooth. Additionally, the lingual surface needs to be reshaped and we can see that a groove has been placed on the lingual surface of the tooth. The groove gives more surface area for the repair acrylic to bond to which helps increase the retention of the replacement tooth in the denture repair.



Reshaping the tooth is a trial and error procedure. Here we can see that enough structure has been removed to allow the replacement tooth to “fit” into the recess provided. The tooth has not been secured with acrylic at this time, it is just set in the recess to check for fit.

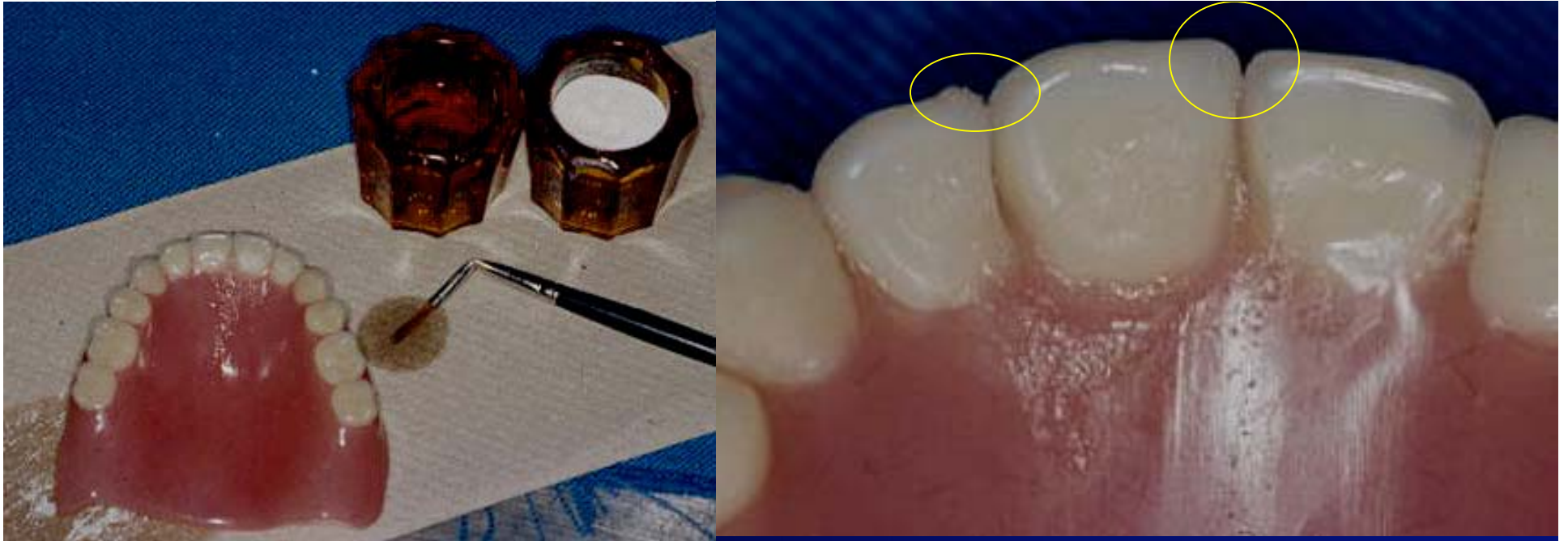Here we can see two views of the tooth tried in the prepared recess. There is a space around the tooth into which self cure acrylic will be placed to secure the tooth for the repair.





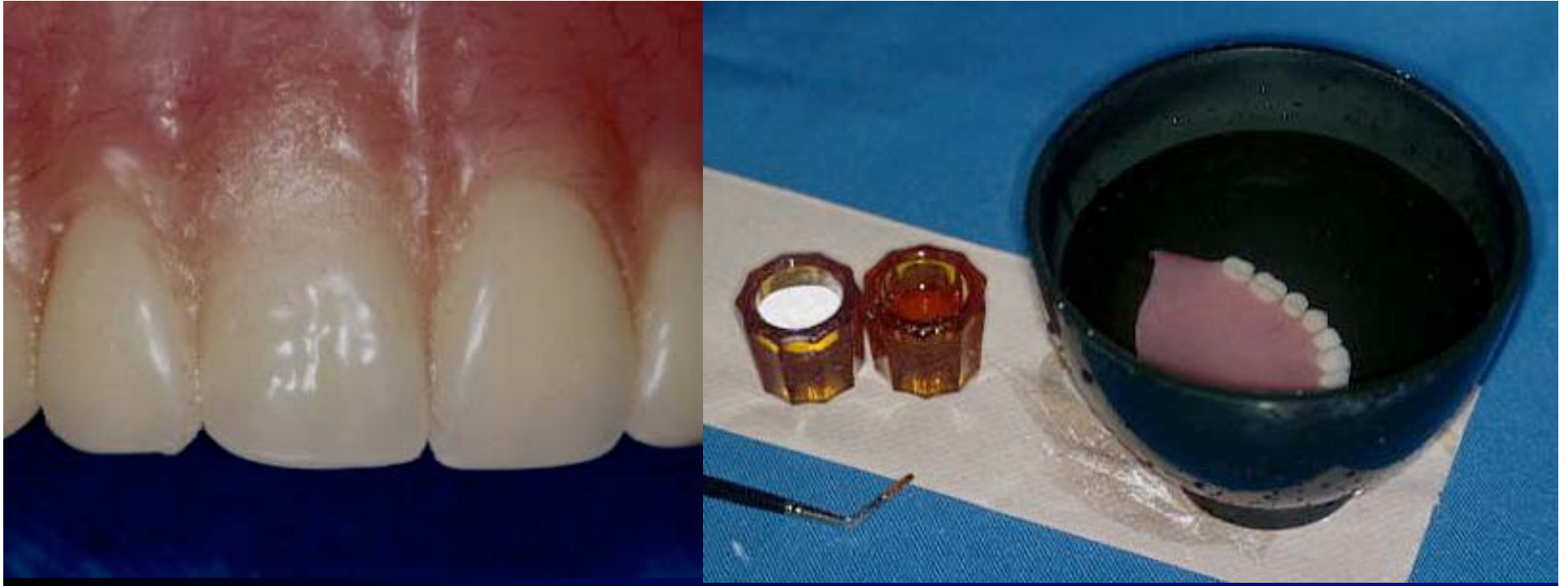

For the repair itself, we use our old friend the self cure acrylic. It is easiest to use by placing liquid and powder in separate dappen dishes and using a fine brush. Dip in liquid, pick up a small segment of powder and place around the tooth to be repaired.

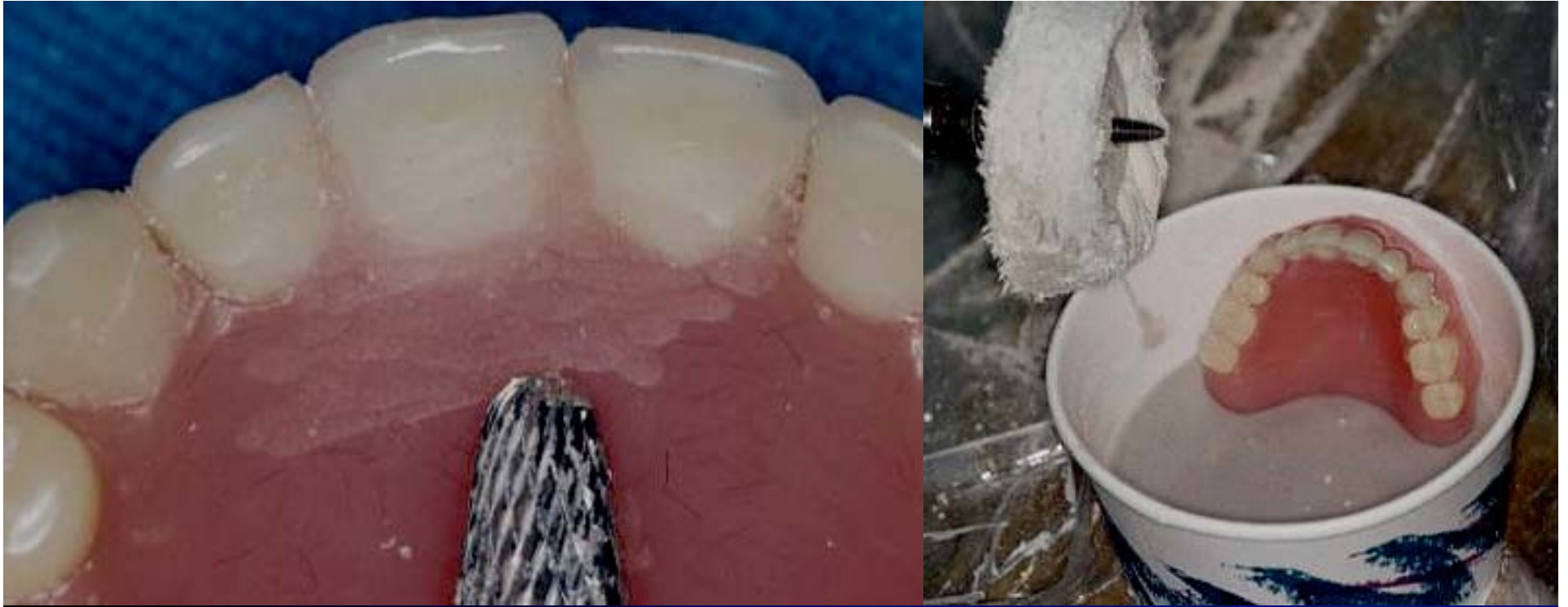

The brush is cleaned between each increment of acrylic by dipping it in liquid and cleaning it on a paper towel as shown here. The right image is a close up of the acrylic being flowed around the replacement tooth. It may be helpful to “tack” the tooth in place with small amounts of sticky wax at the incisal edges where the circles are.

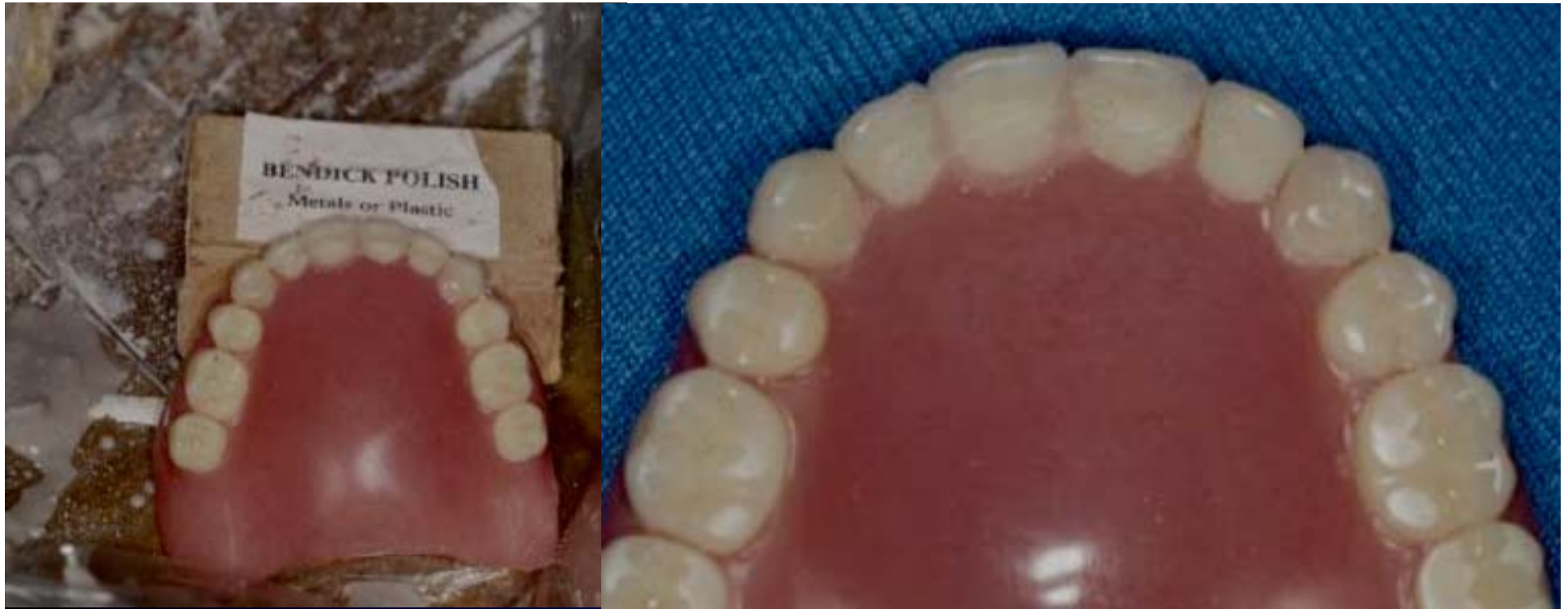



The labial view of the repair shows tooth #8 may be slightly shorter than tooth #9. The tacking in place with sticky wax at the incisal edges would have helped with this. Once the acrylic has been added, the denture is placed in warm water. Using a pressure pot at this point will result in repair acrylic which is stronger and more dense. For this demonstration the denture was simply placed in warm water in a green bowl and no additional pressure applied.

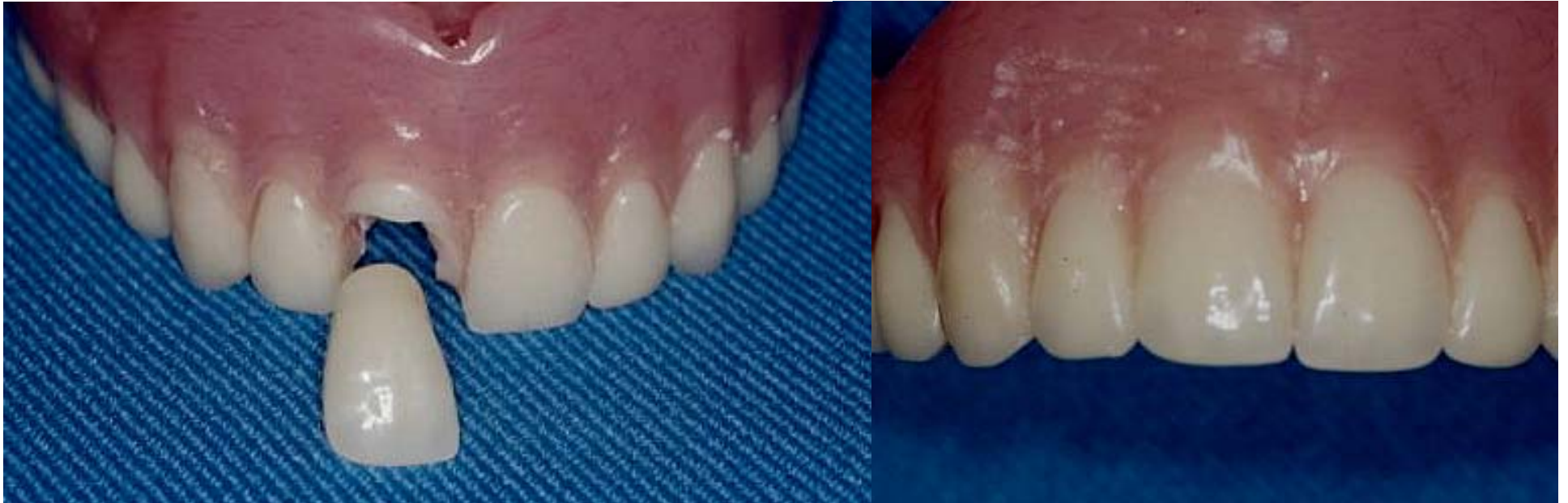

Once the acrylic has cured which takes about 5 minutes, the repair area is smoothed with a bur and the area is polished with pumice and a wet rag wheel. Once smooth with pumice the area is brought to a high shine using Bendick and the repair is complete.



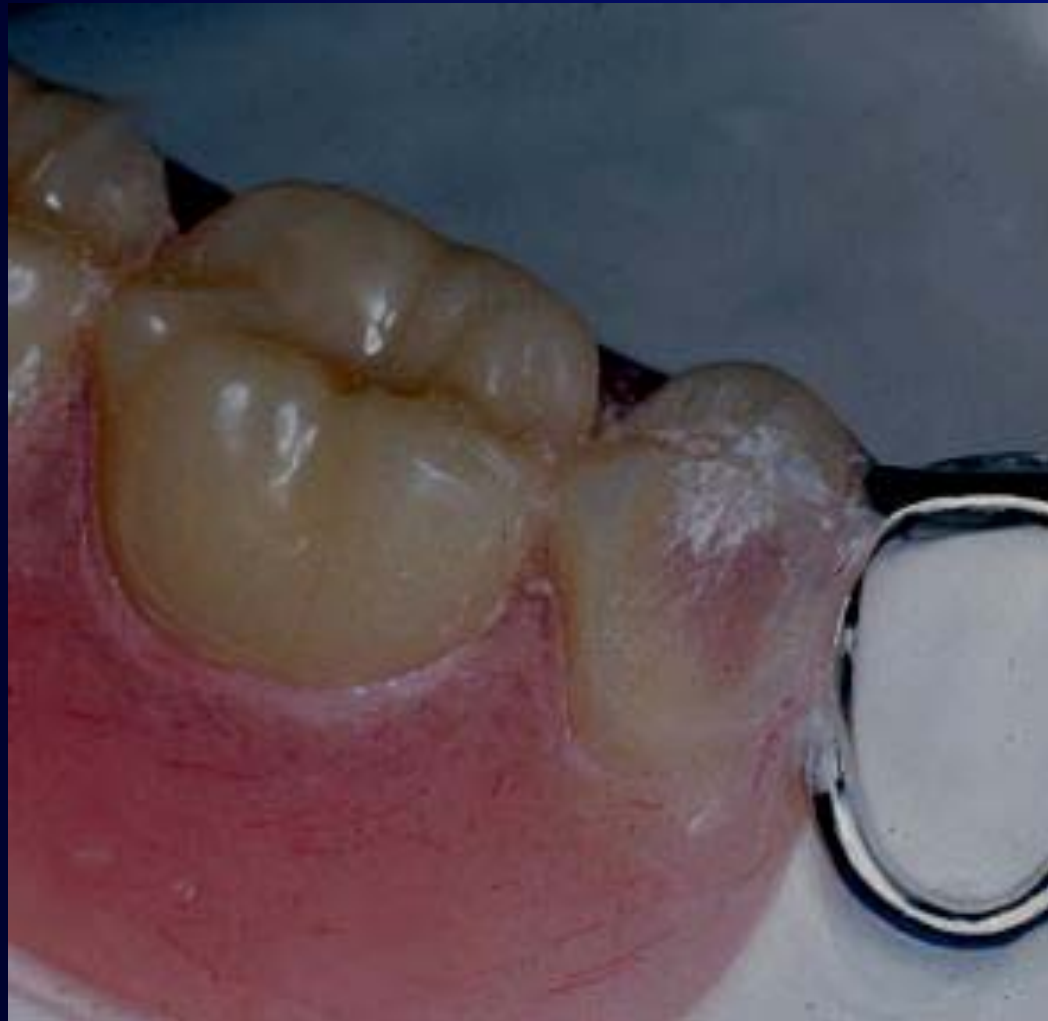Prior to using Bendick to shine the denture it is essential that the surface of the acrylic be very smooth. Don't try to put a shine on a surface which still has lots of ripples and defects. Getting the surface smooth with pumice takes most of the time. The high shine portion of the finishing procedure is a very short % of the total time spent finishing.

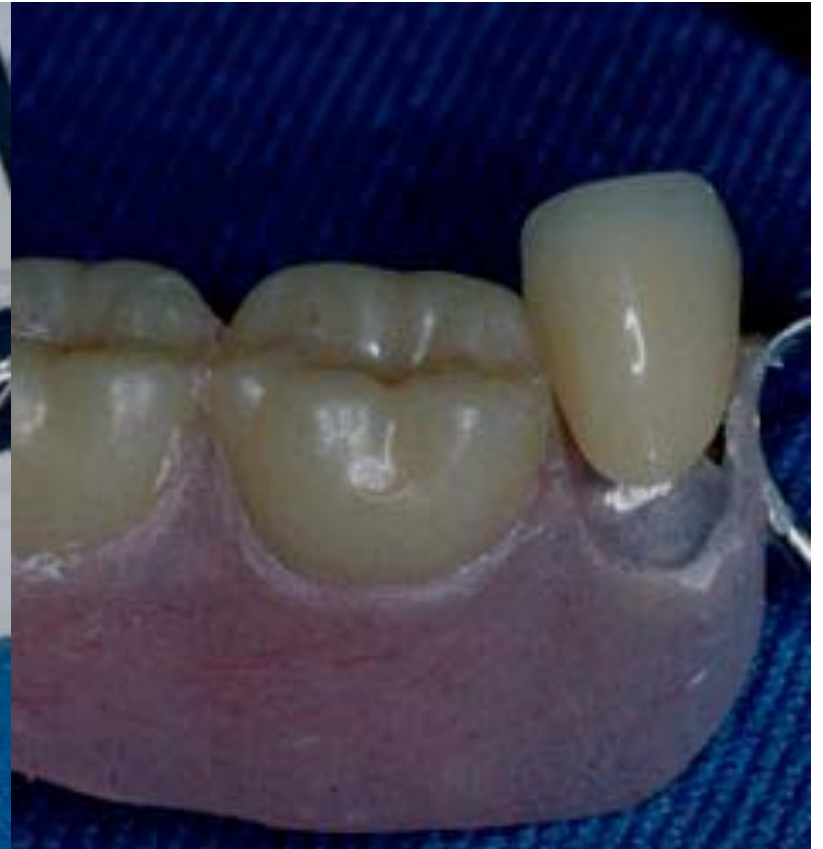
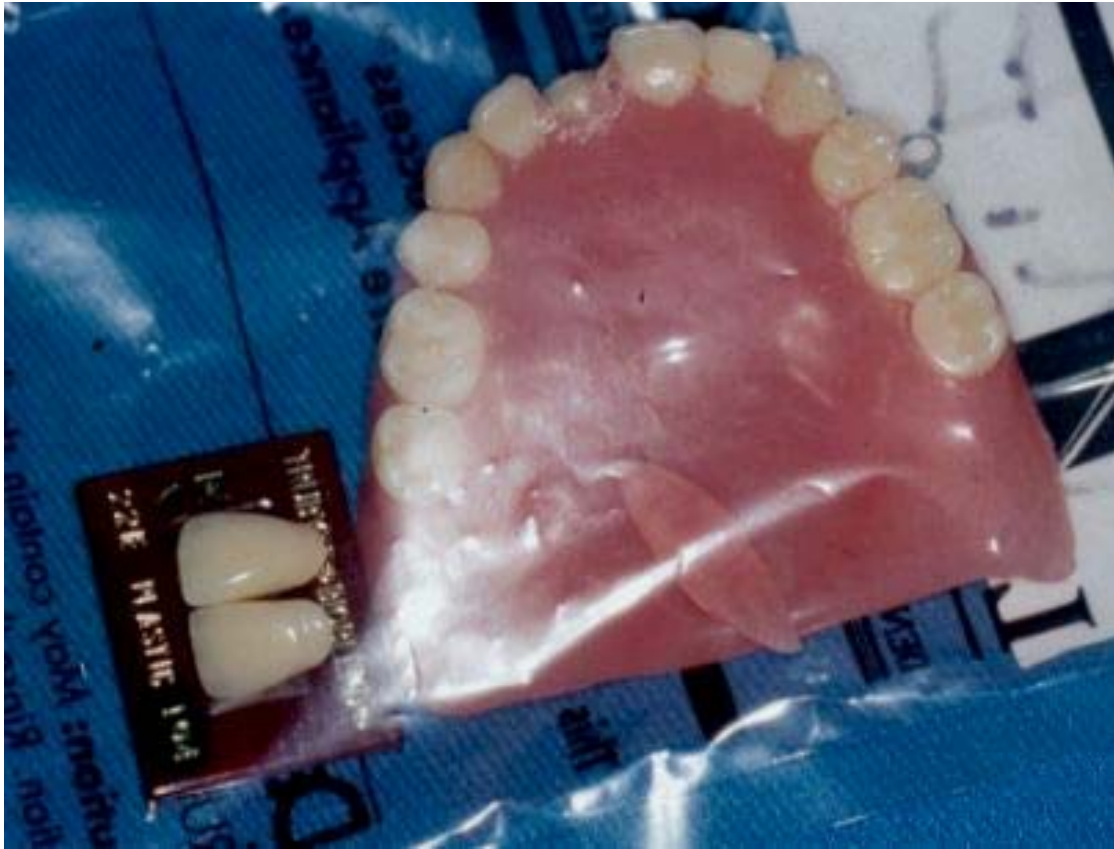


The before and after of the repair of a fractured tooth. In this case the entire tooth needed replacement. Simpler cases may just require that an existing tooth be replaced in the denture. The same sequence is used for these cases.

Another example of the replacement of a fractured or missing tooth.



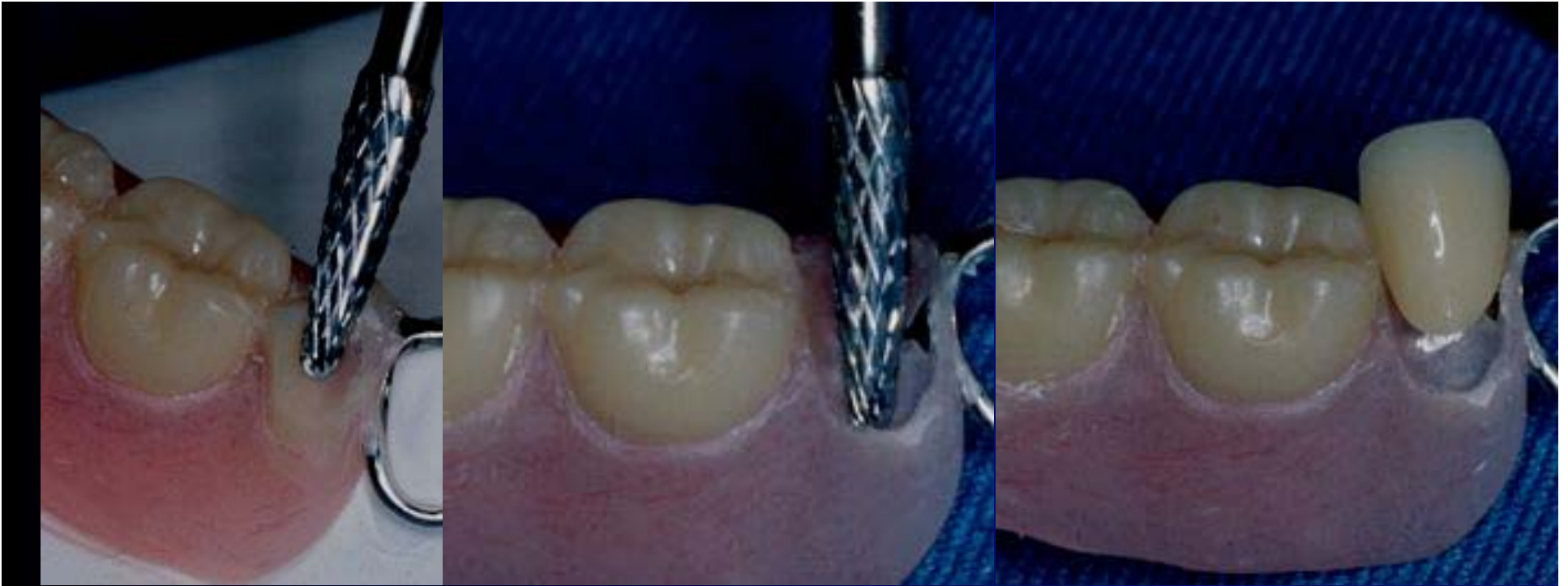

Whether anterior or posterior, determine the replacement tooth you will need if the tooth in question is either missing or fractured. Patient records may help, or it may be necessary to have the patient “drop by” for a match for the tooth.

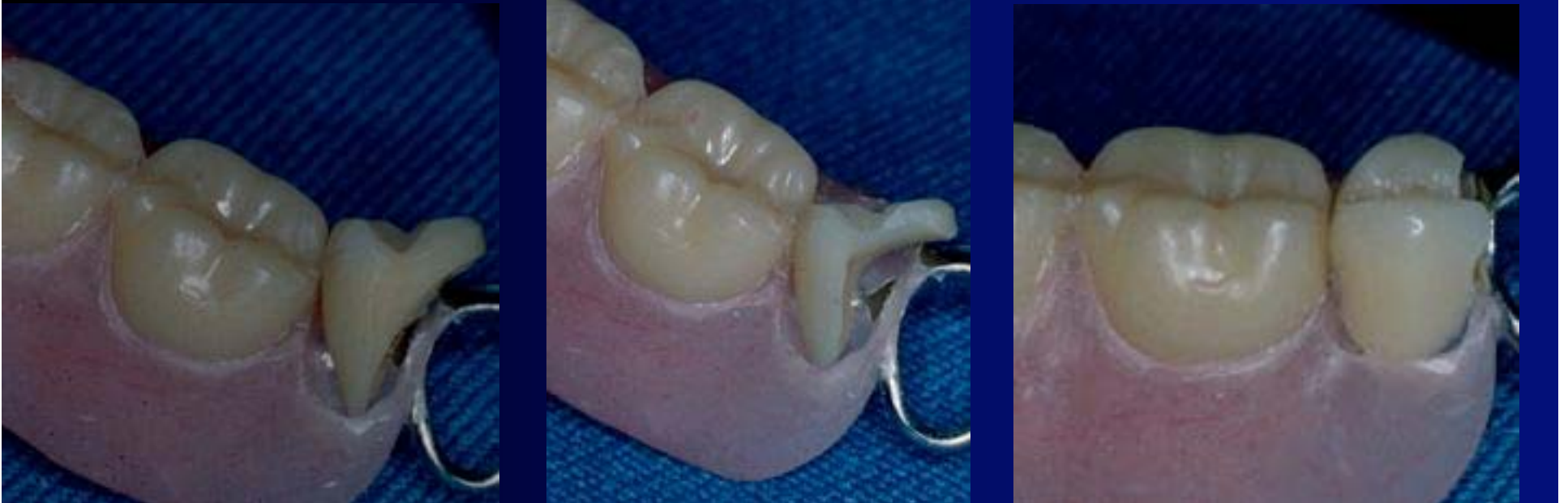Most general practices will probably not have a stock of “spare teeth” in the office lab. You may make an emergency repair with composite “bonded” to the fractured denture tooth. If the tooth is missing entirely, more creativity may be required.

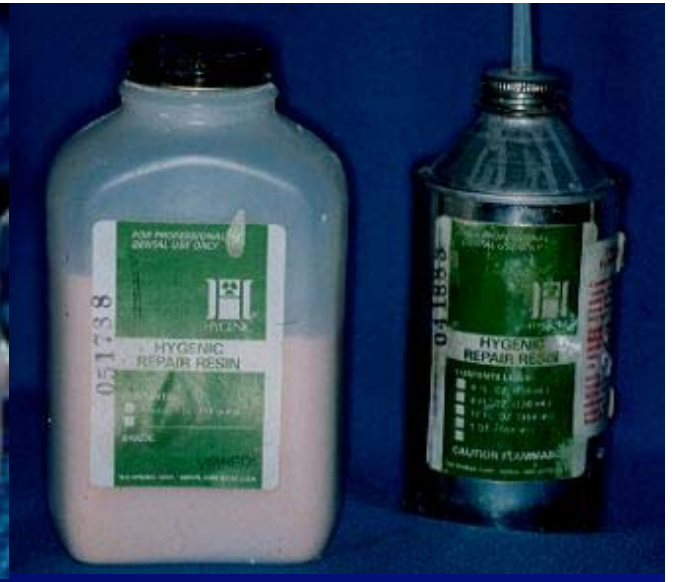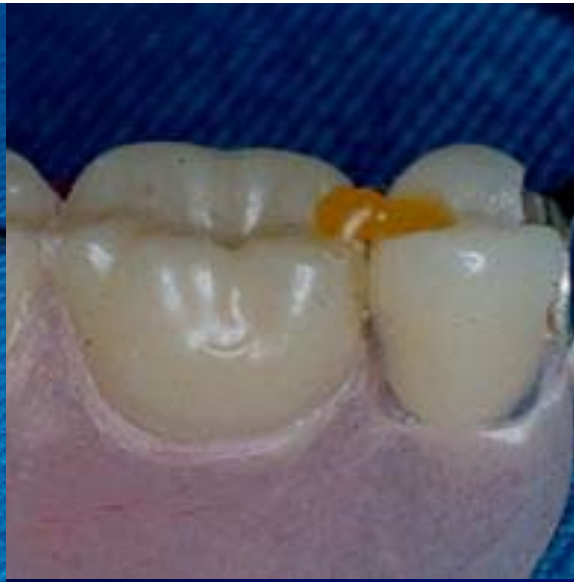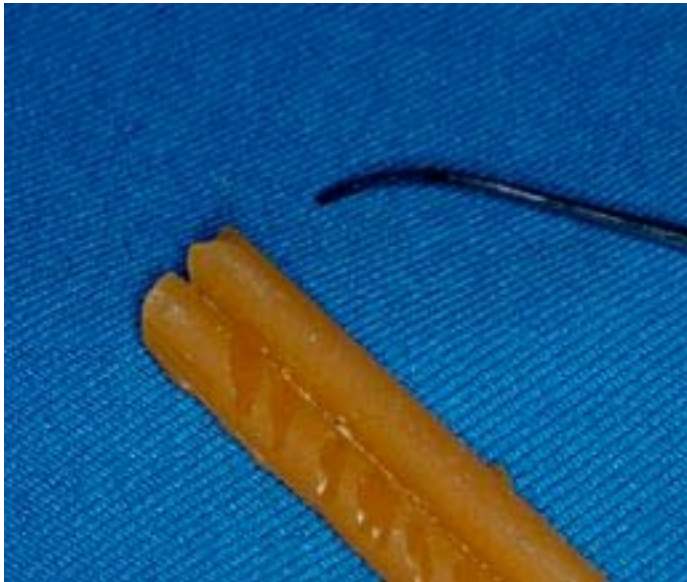If you have a dental laboratory you can have “pick up” the denture, you may be able to give 4-8 hour service.



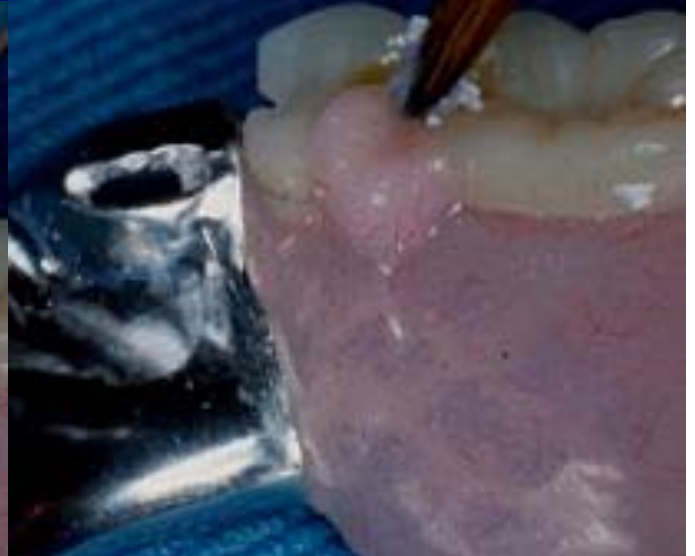
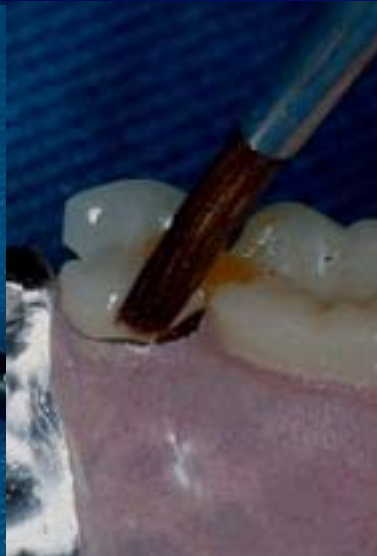
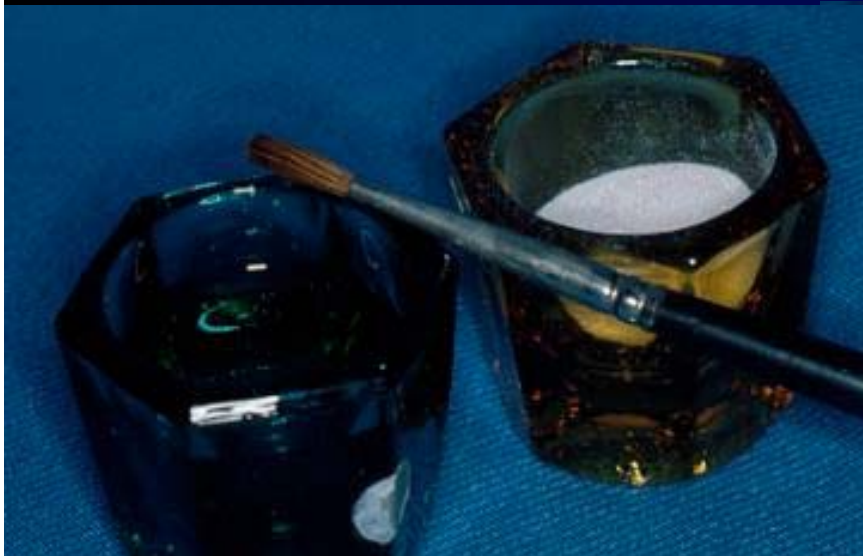Previous tooth ground out and new tooth ground to “fit”

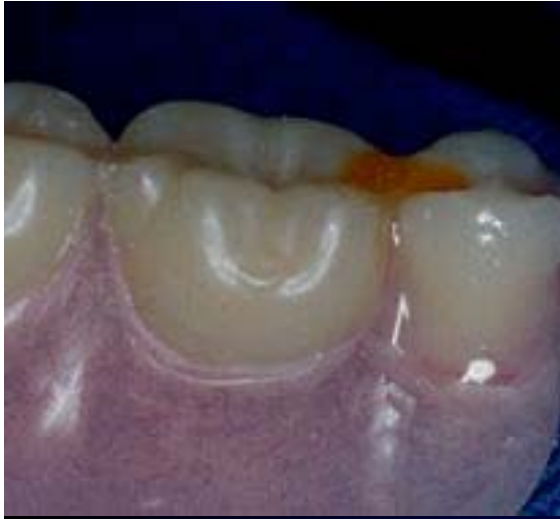



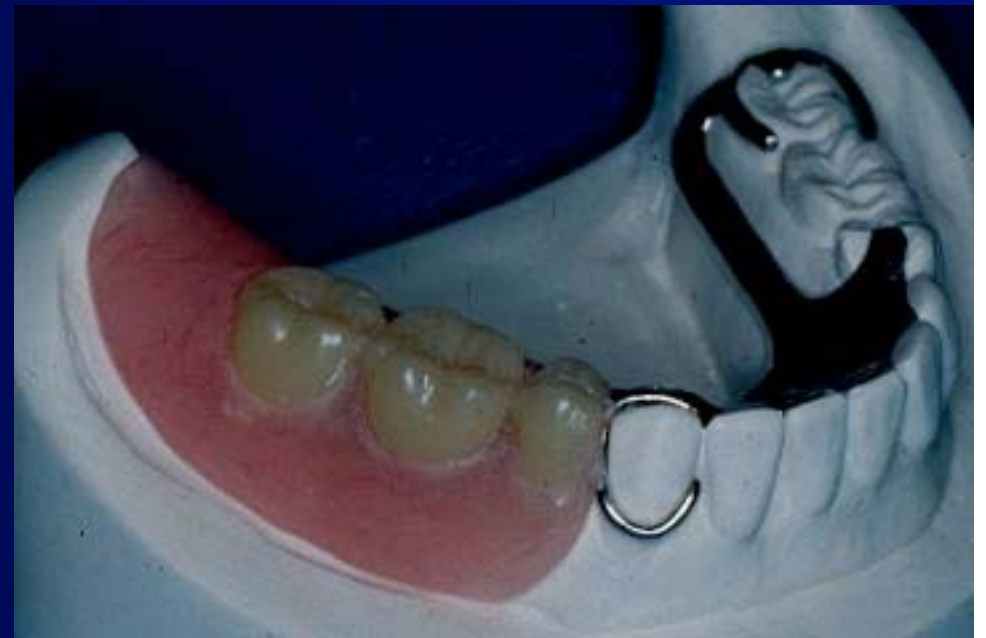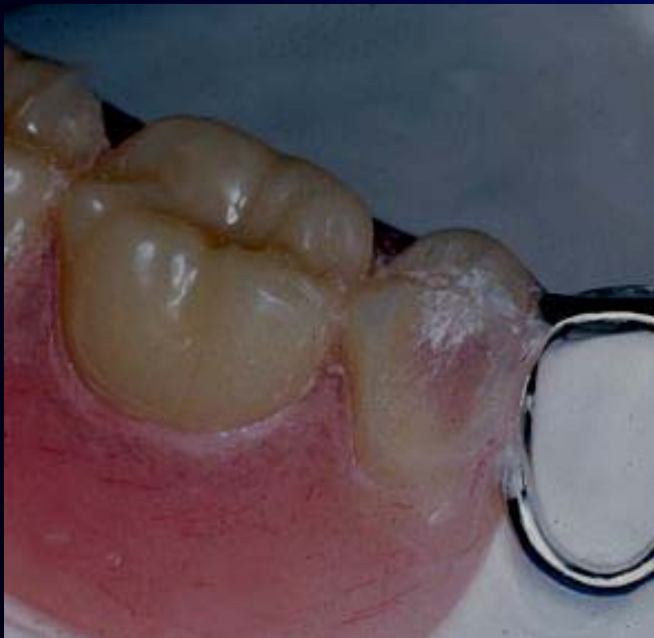Use a drop of sticky wax to position the tooth and self cure acrylic to flow around the tooth to secure it.





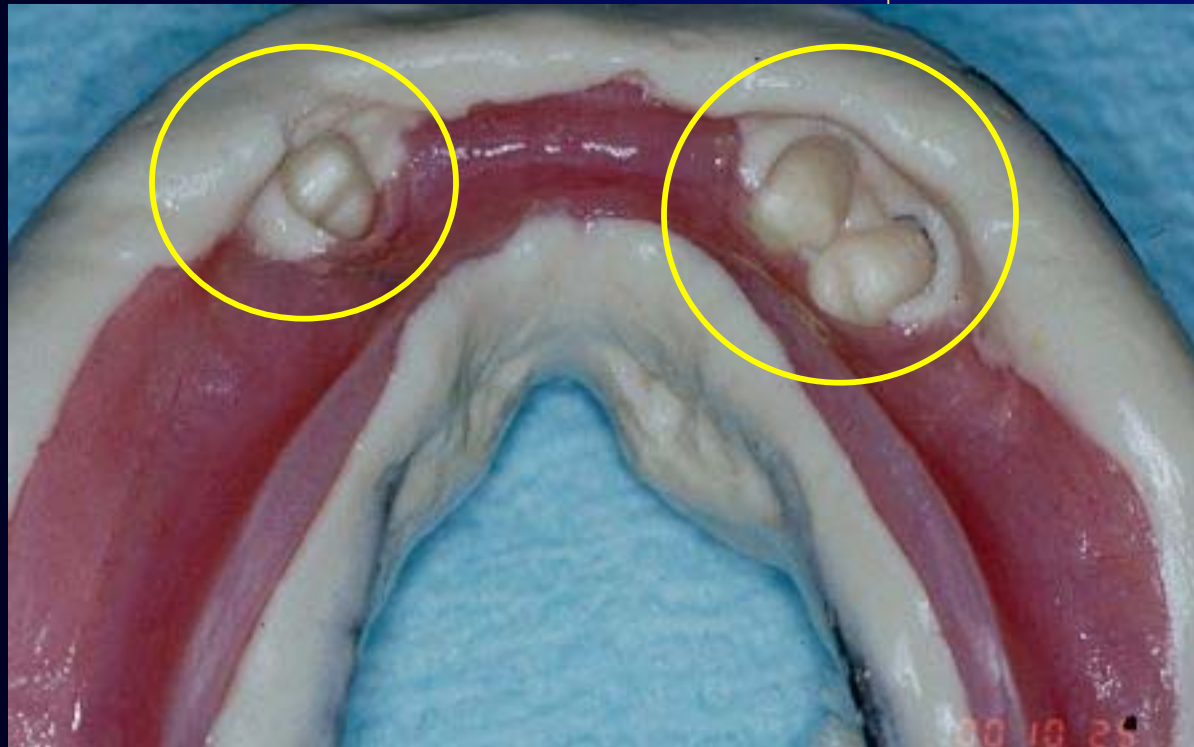


After adding the self cure acrylic, place in a pressure pot for curing. After curing finish with acrylic burs and polish. Before and after seen below.



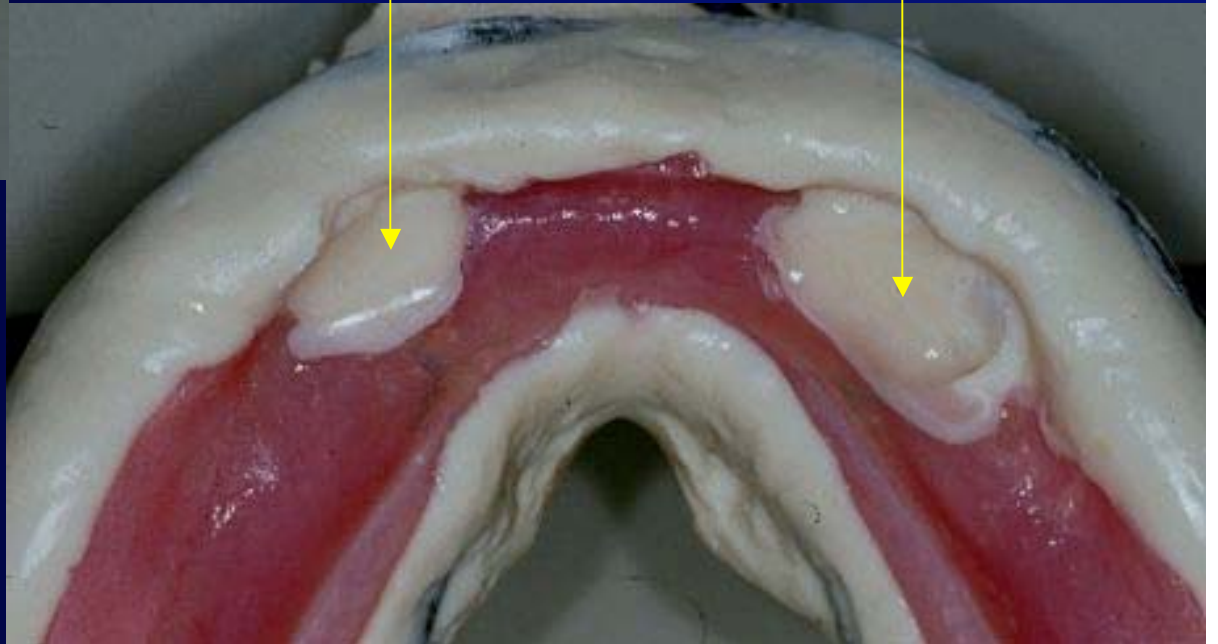
Converting a “provisional” partial denture to a full denture when the remaining teeth are being extracted.

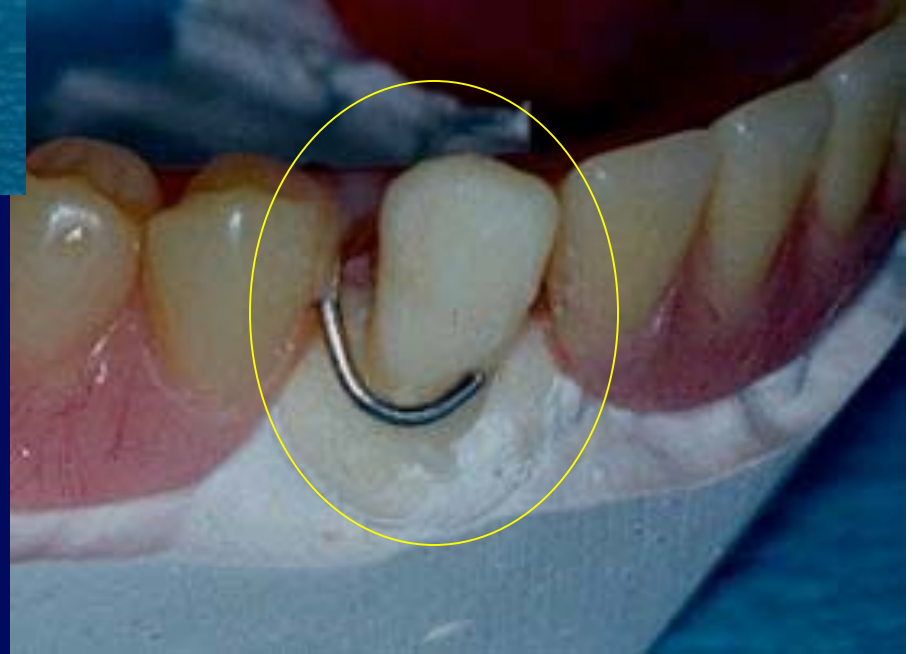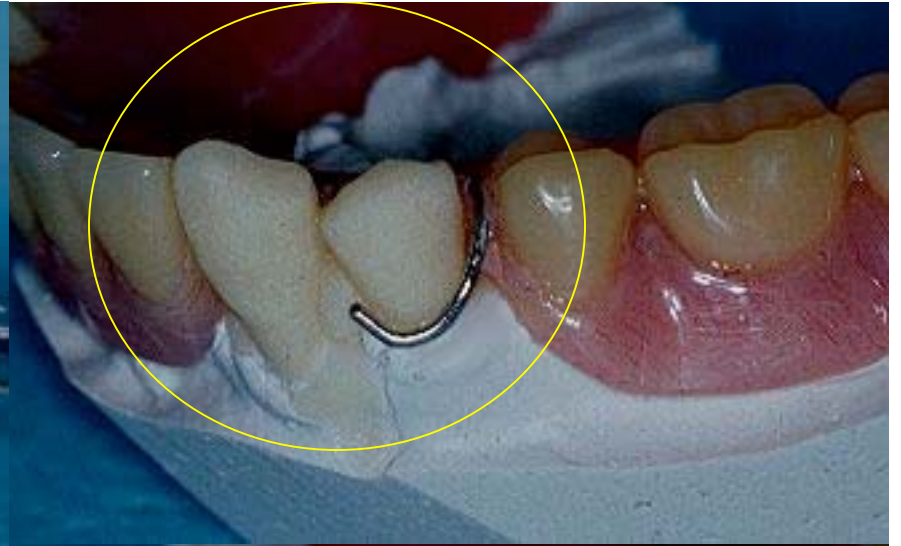
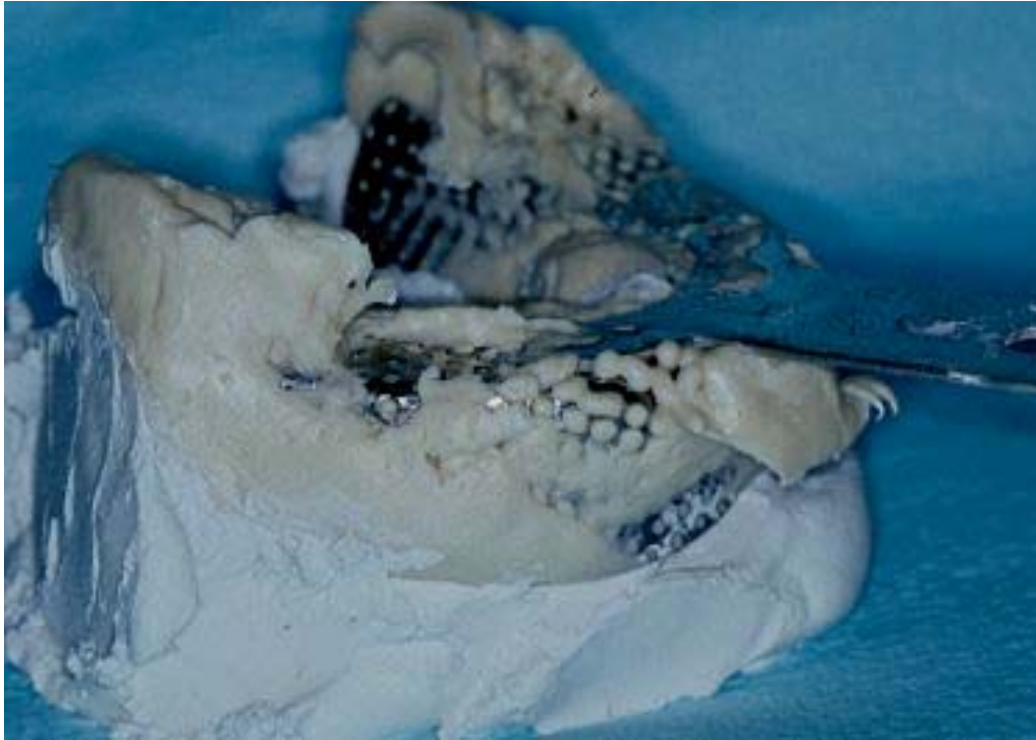These teeth are “hopeless” and will be extracted. We will modify the appliance while the patient is in surgery. We need to take a good alginate impression as seen here just prior to sending the patient to surgery for the extractions.





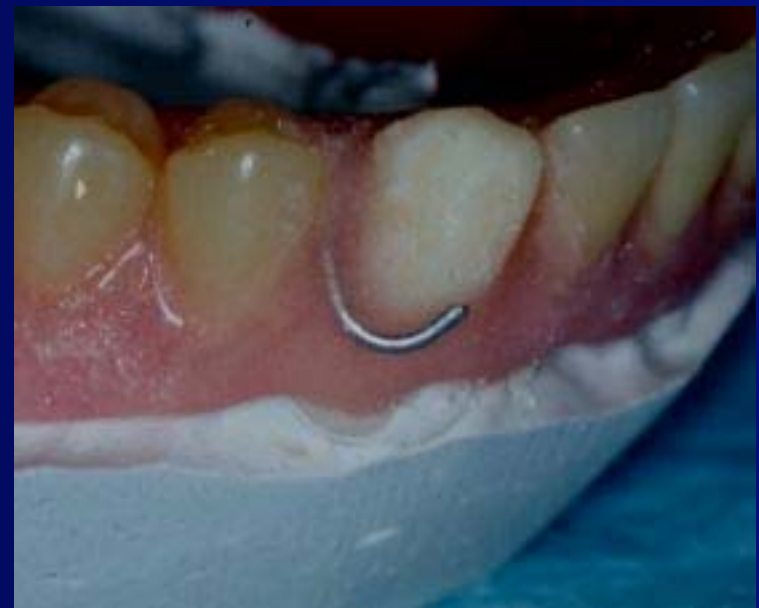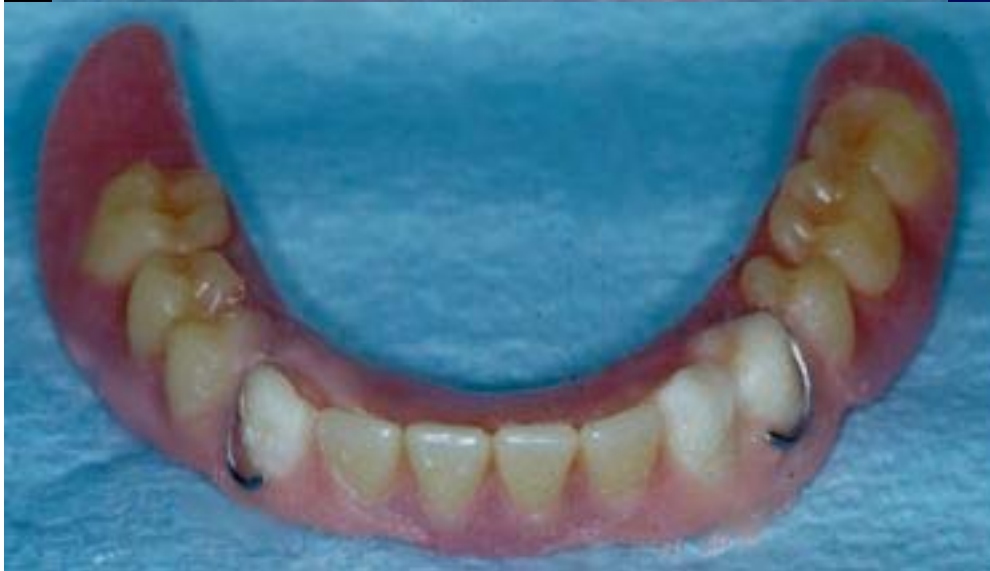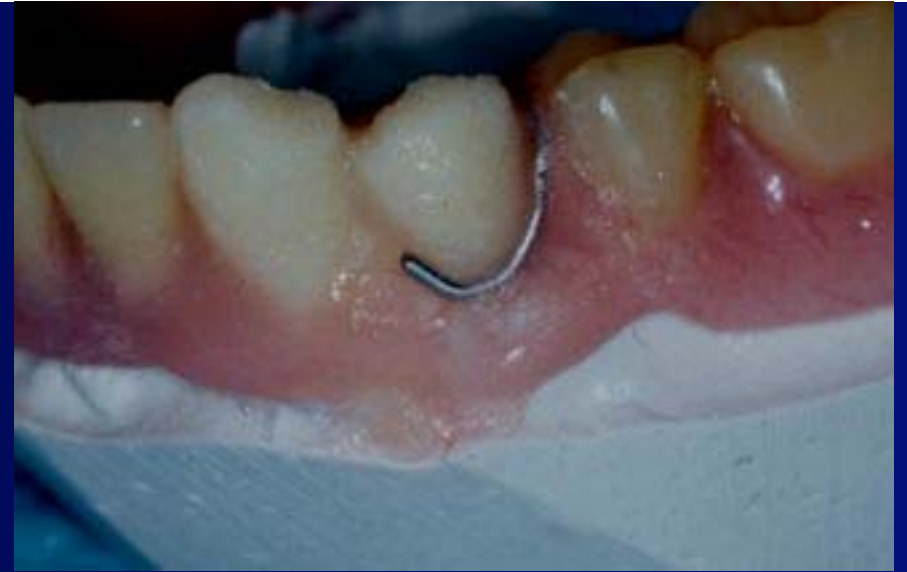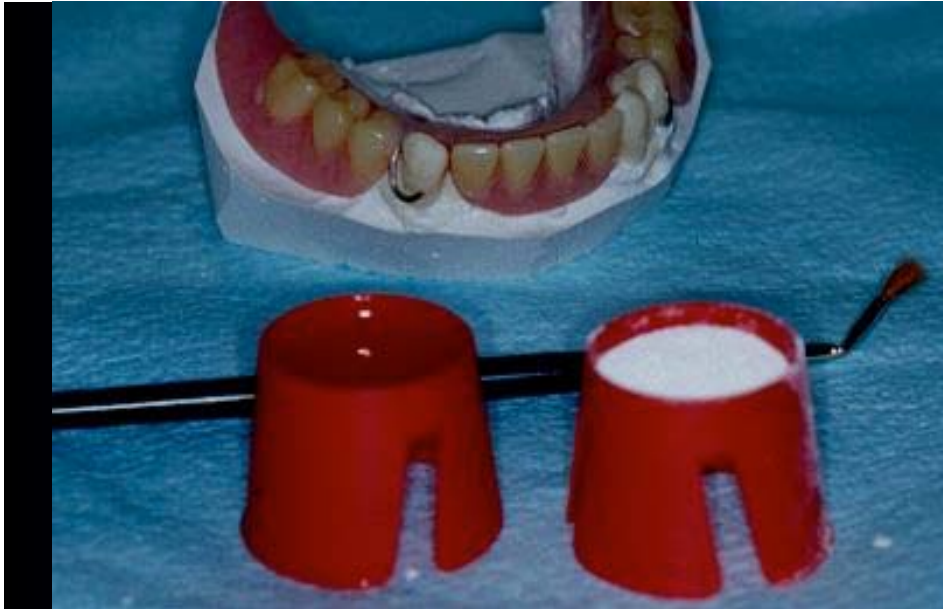Select an appropriate shade of self curing acrylic, bulk mix it and pour it in the impression of the teeth to be extracted as seen here.



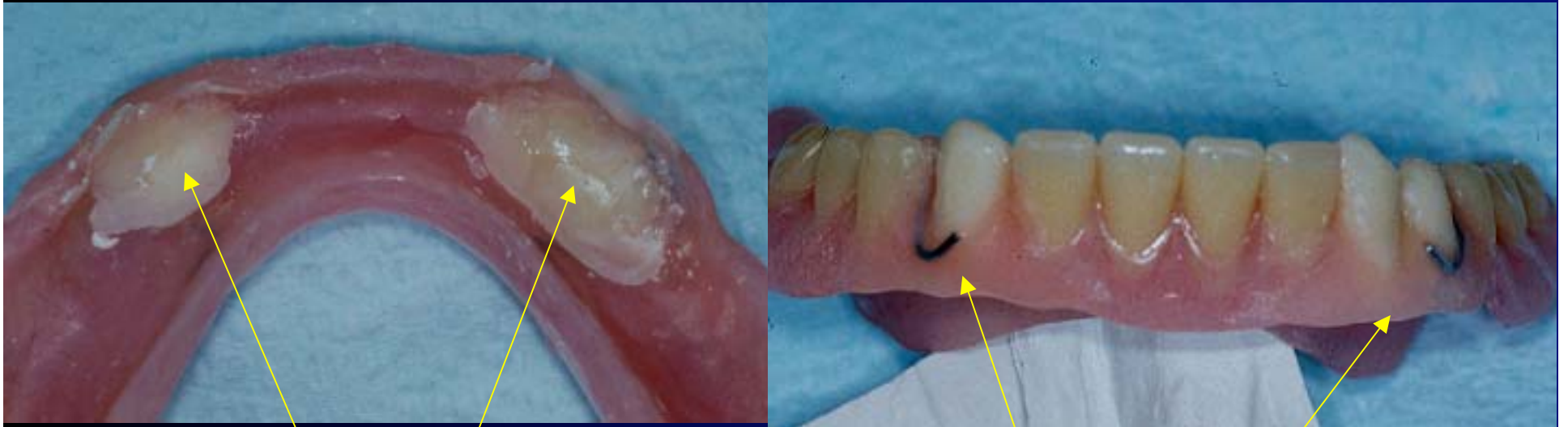

After the teeth have been poured in acrylic, a cast is poured into the impression and the appliance. The resulting cast with “acrylic teeth” is seen in the images on the right.





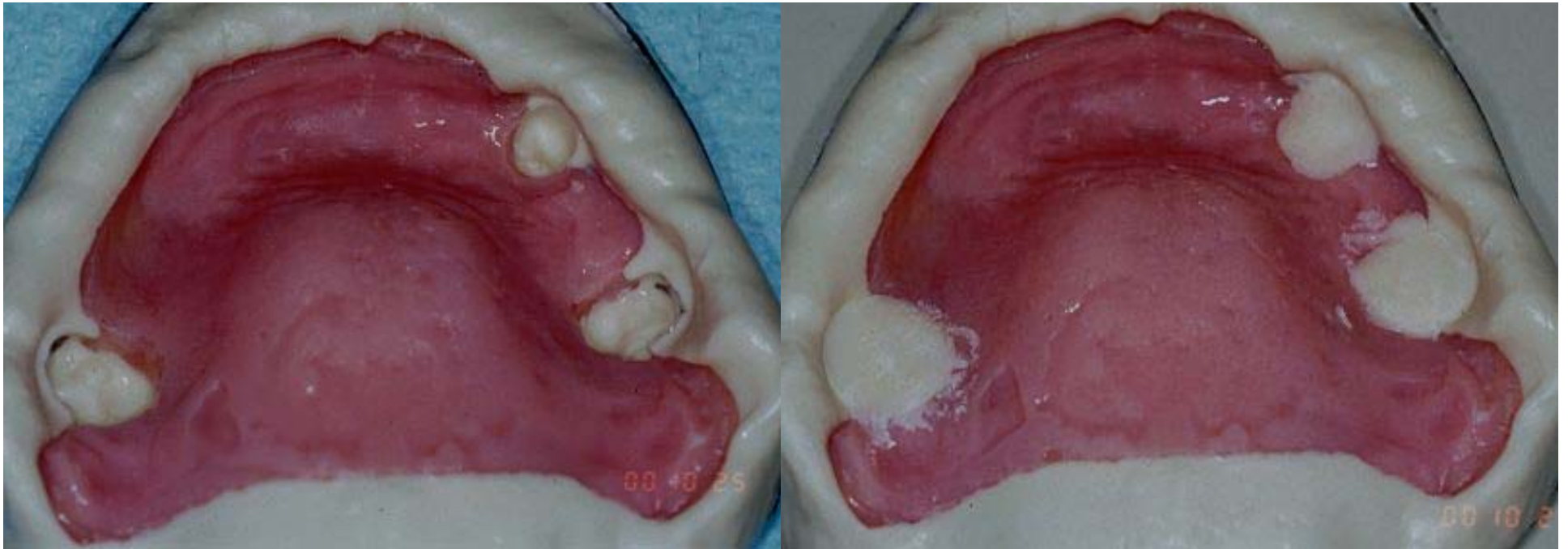
The acrylic flanges are painted on the model with self cure acrylic. After the self cure acrylic has hardened, the appliance is removed from the cast and the flanges and tissue side are contoured and polished.



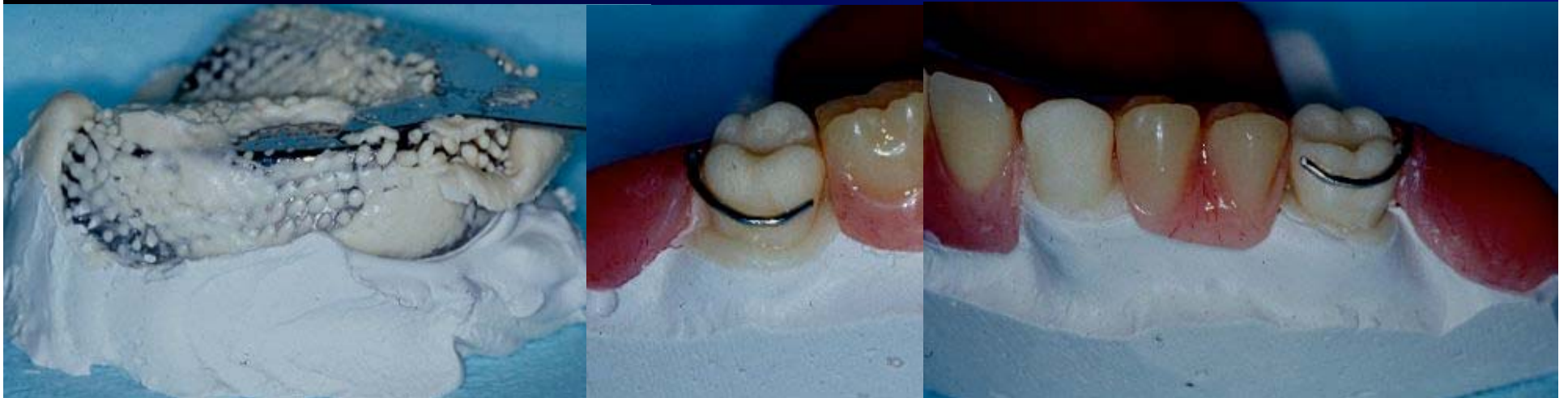These areas are shaped with an acrylic bur and the flanges made smooth.

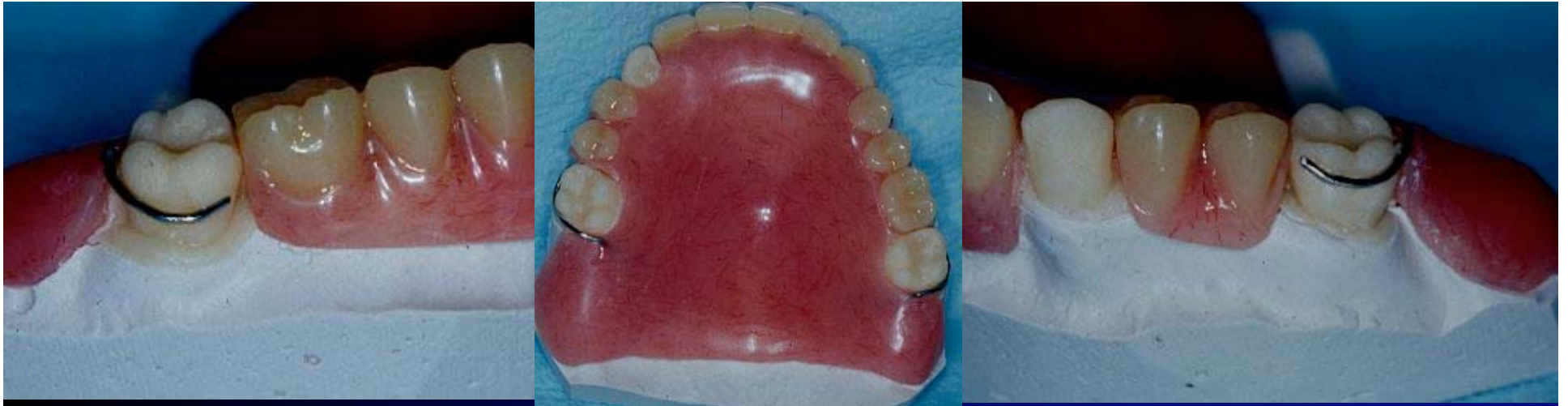Acrylic flanges smoothed ready for delivery to the patient on return from oral surgery.



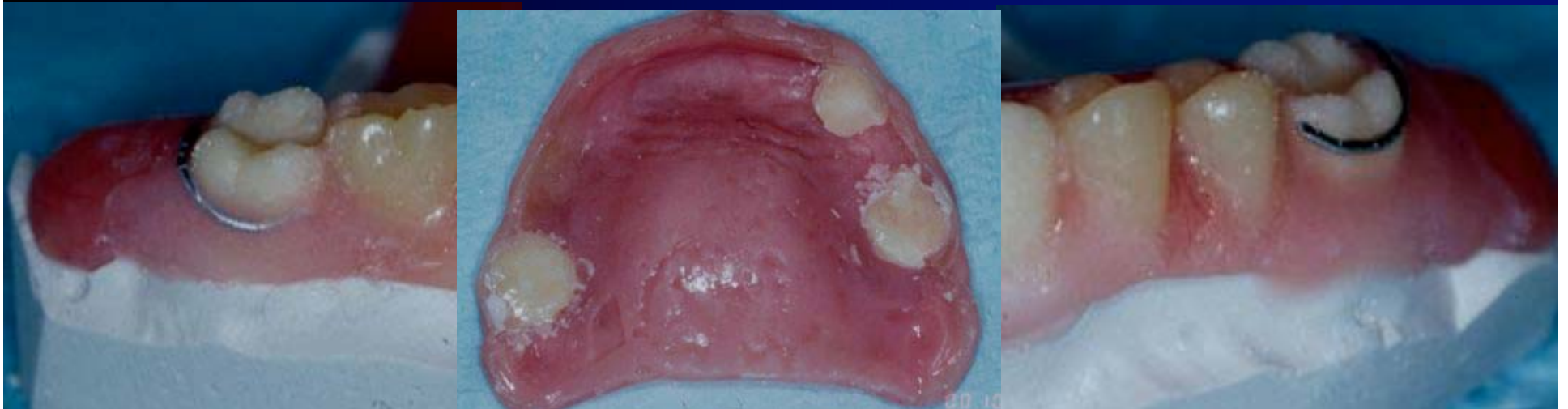

The same sequence for an upper provisional appliance being converted to a temporary full denture. Alginate impression just prior to surgery, modification during surgery.

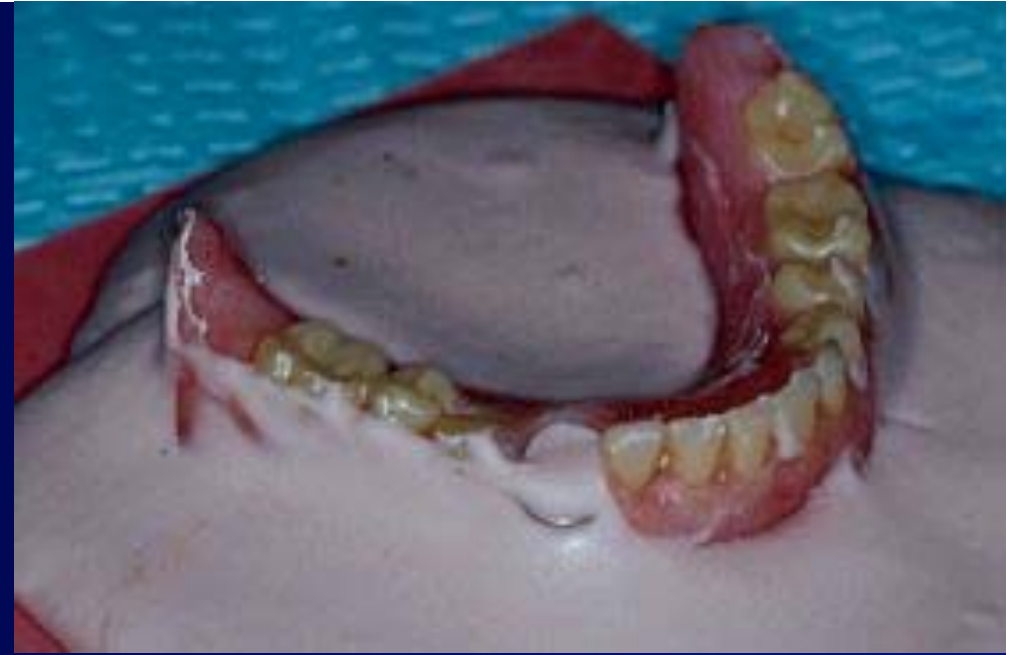
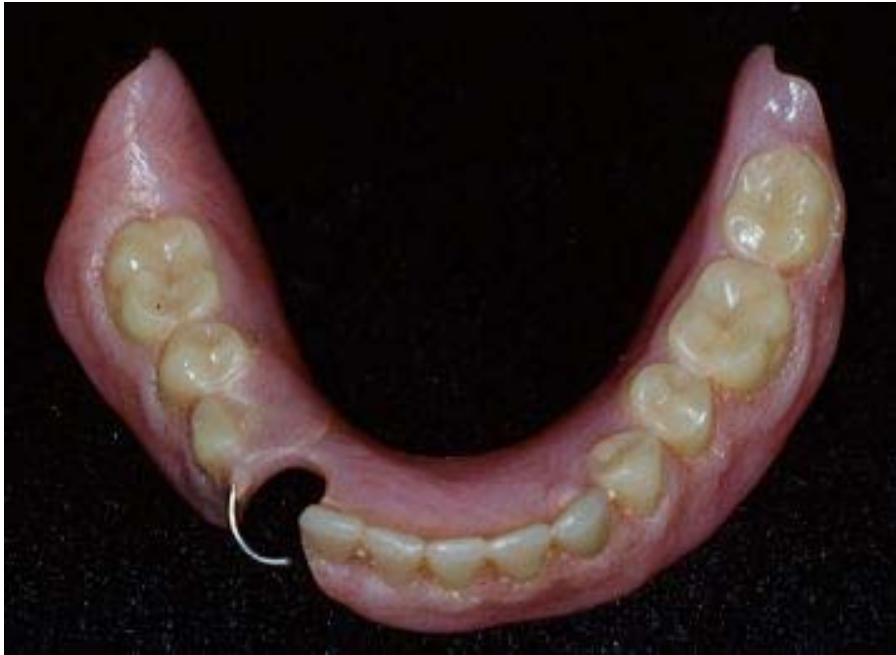


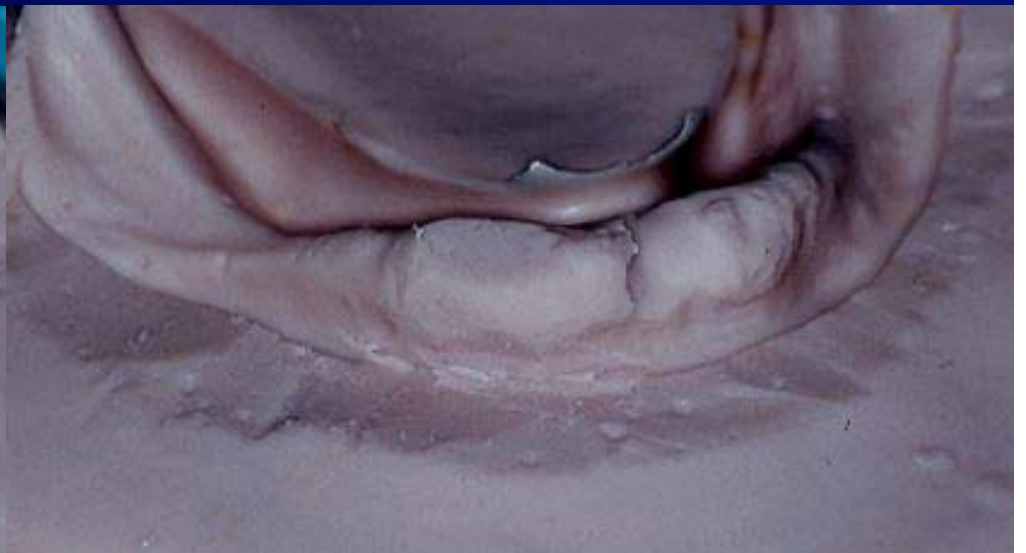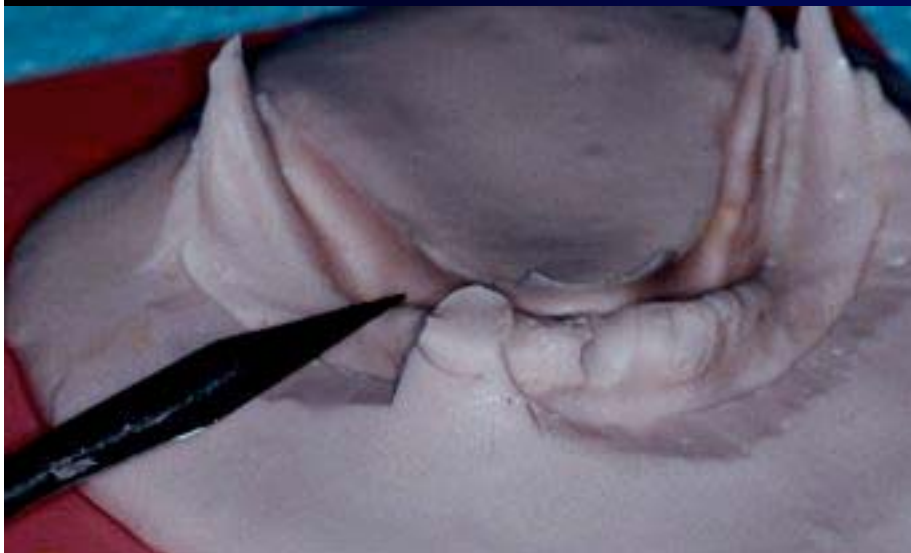
The same procedure is used for the upper provisional appliance after the acrylic teeth have been “poured” in the impression. Flanges are added to the temporary appliance with self cure acrylic and polished.

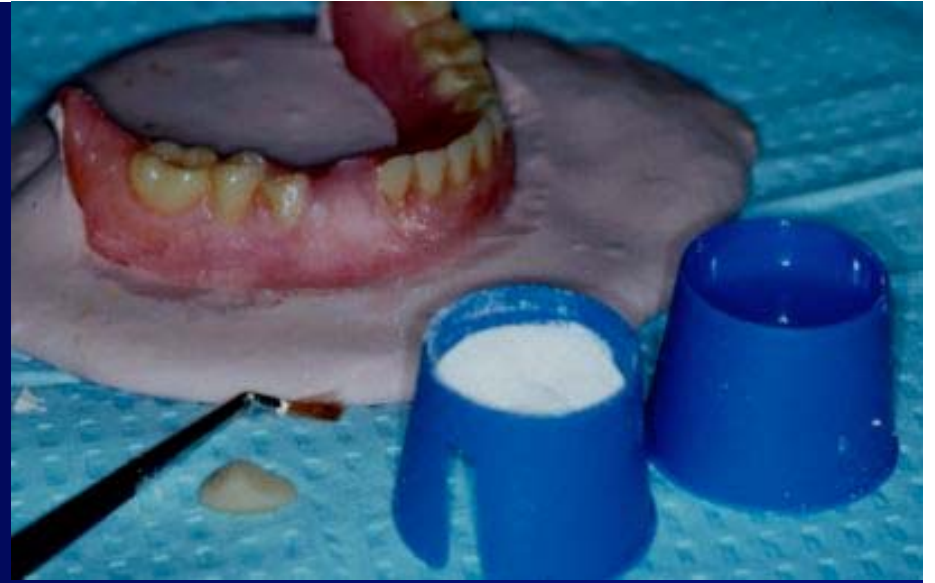
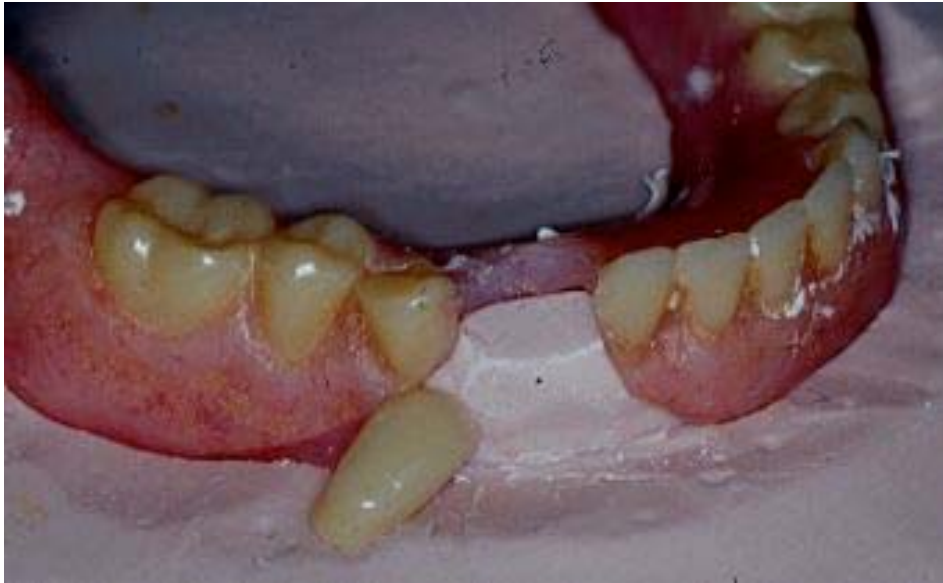




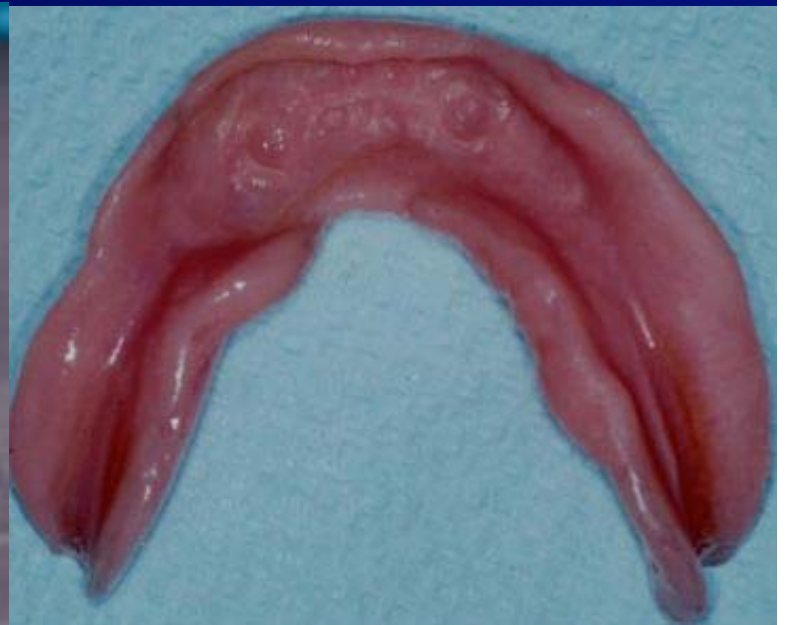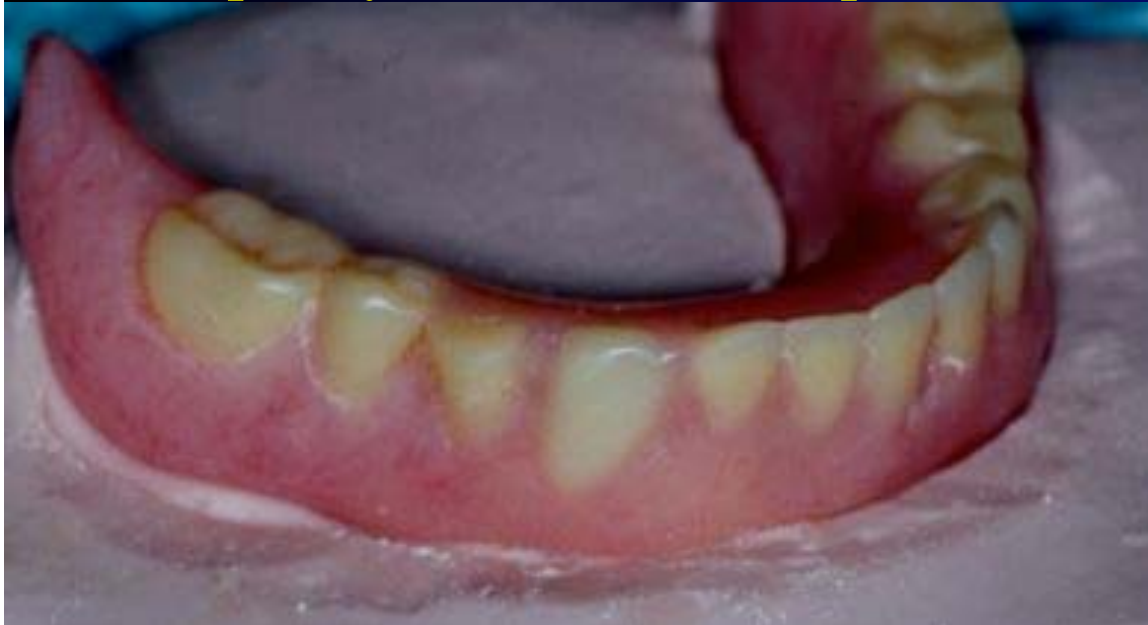Variation on the technique. Here an alginate “index” was poured in the denture and the position of the tooth was “shaped” with a scalpel blade.





Here self cure acrylic is used to create a pink acrylic layer in which we set the denture tooth. The temporary denture was then lined with a temporary soft liner for the patient.





# Common Repairs For Complete Dentures / RPD's

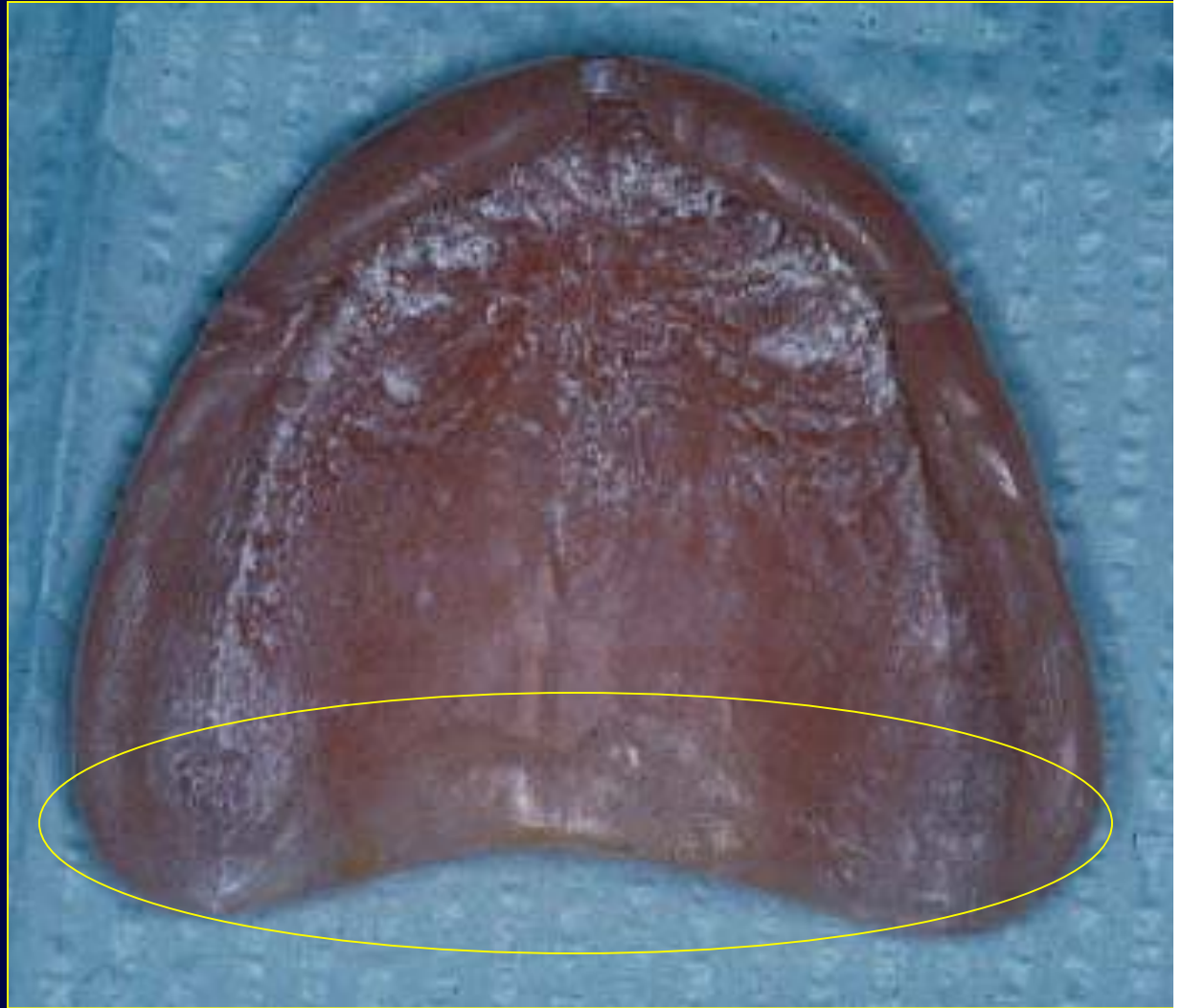Fractured Denture

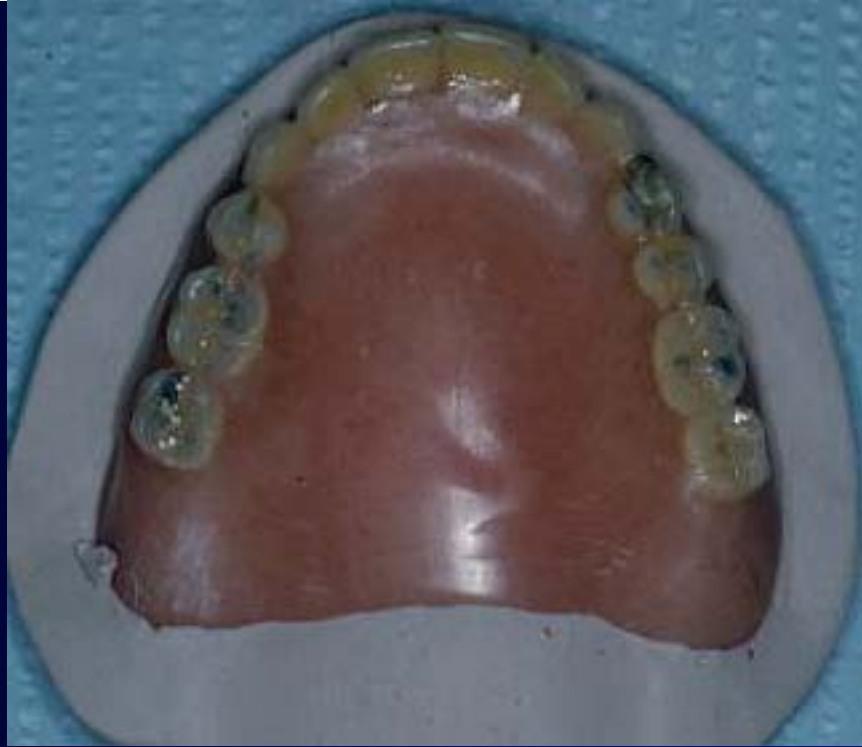Fractured or Damaged Tooth /  
Modification of RPD

Post Dam Modification

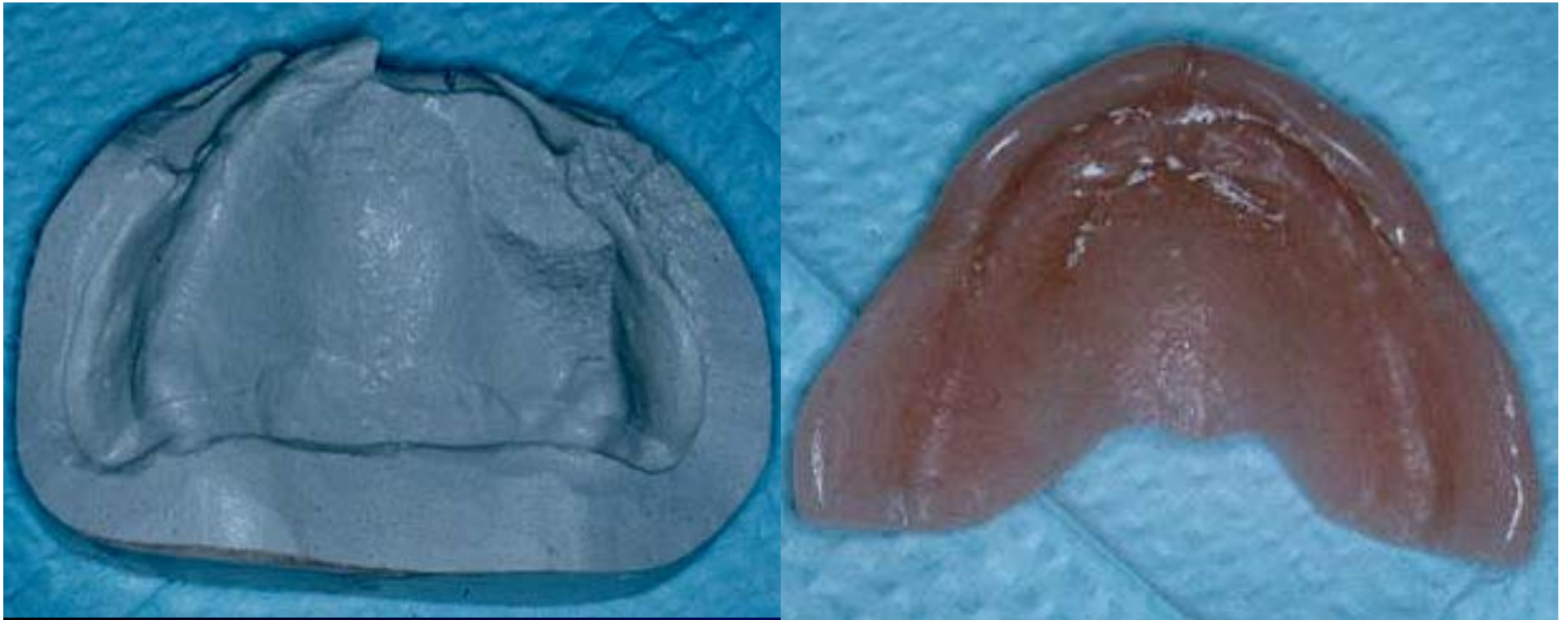
Clasp Repair

This denture had a problem with retention. On a diagnostic basis impression wax was added to the posterior border to see if the retention improves. In this case the retention was > significantly. The following images show the addition of the new posterior palatal seal.



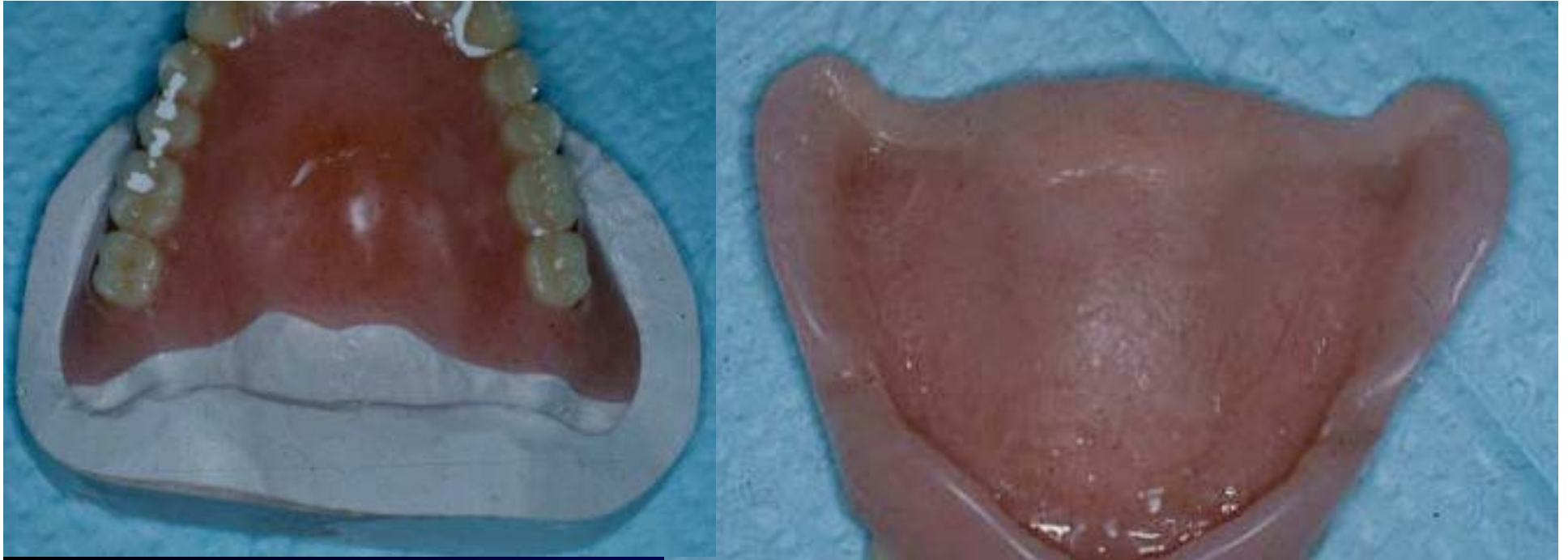

Afer block out of the undercuts in the denture a cast is poured into the denture itself. Care is taken to create a landing area around the denture especially in the posterior area.

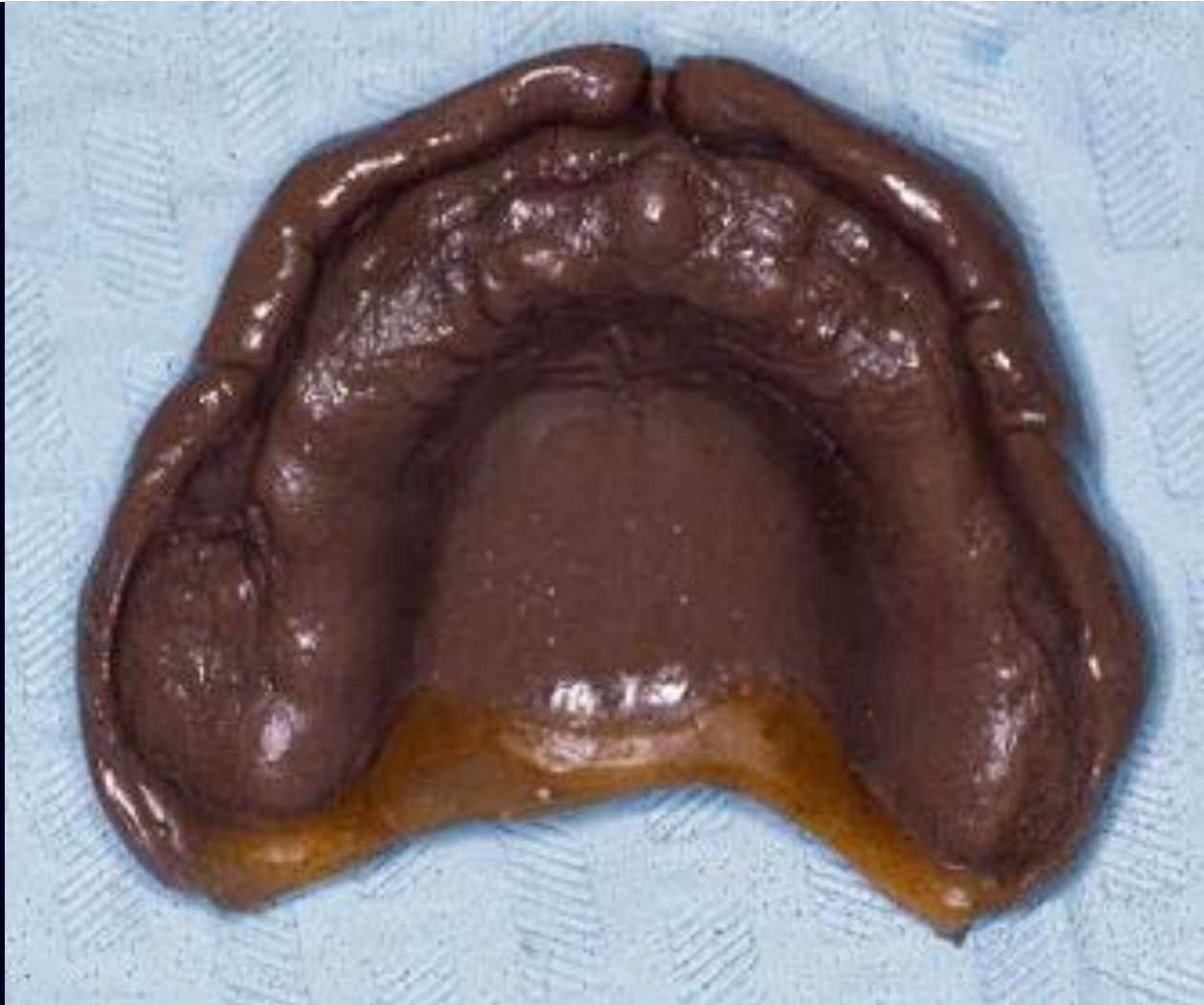

The denture is removed from the cast. You can see that the anterior aspect of the denture was blocked out and the cast is not a good reproduction of the inner surface of the denture in the anterior area. The posterior area corresponding to the palatal seal is a good reproduction of the inner surface of the denture with the impression wax. Remember, the impression wax had been molded in the patient's mouth and the retention was seen to have been increased.

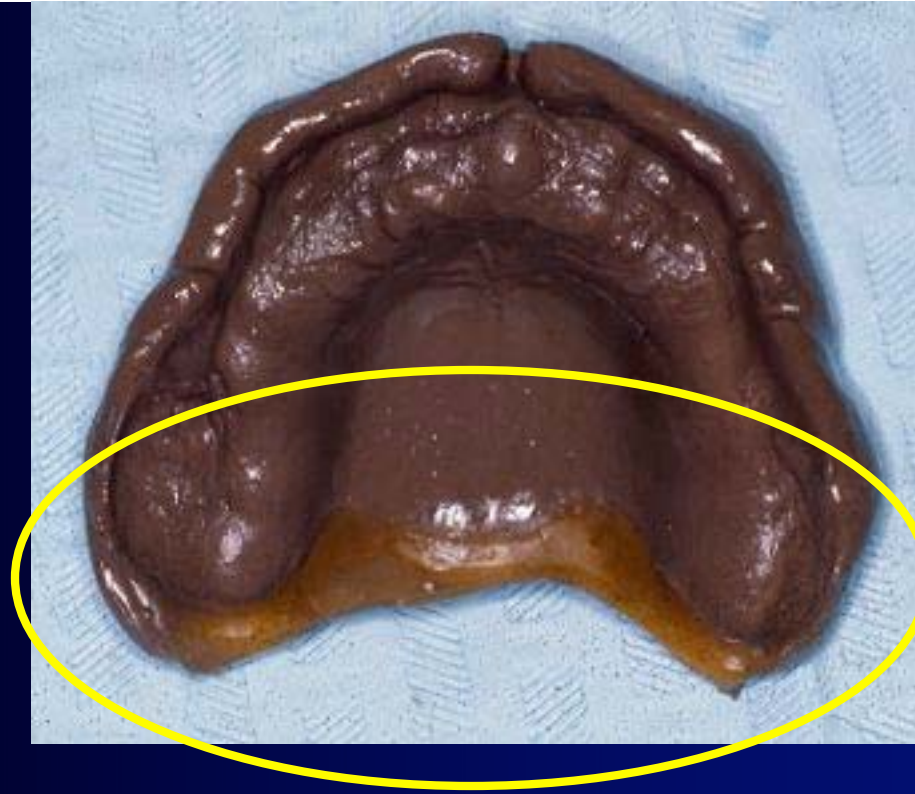



Here you can see the denture placed back on the repair cast with the posterior border removed. The new acrylic may then be added to the denture to contour to the cast and supply us with a new posterior palatal seal. This seal has the contour which was obtained with the impression wax after placement in the patient's mouth.

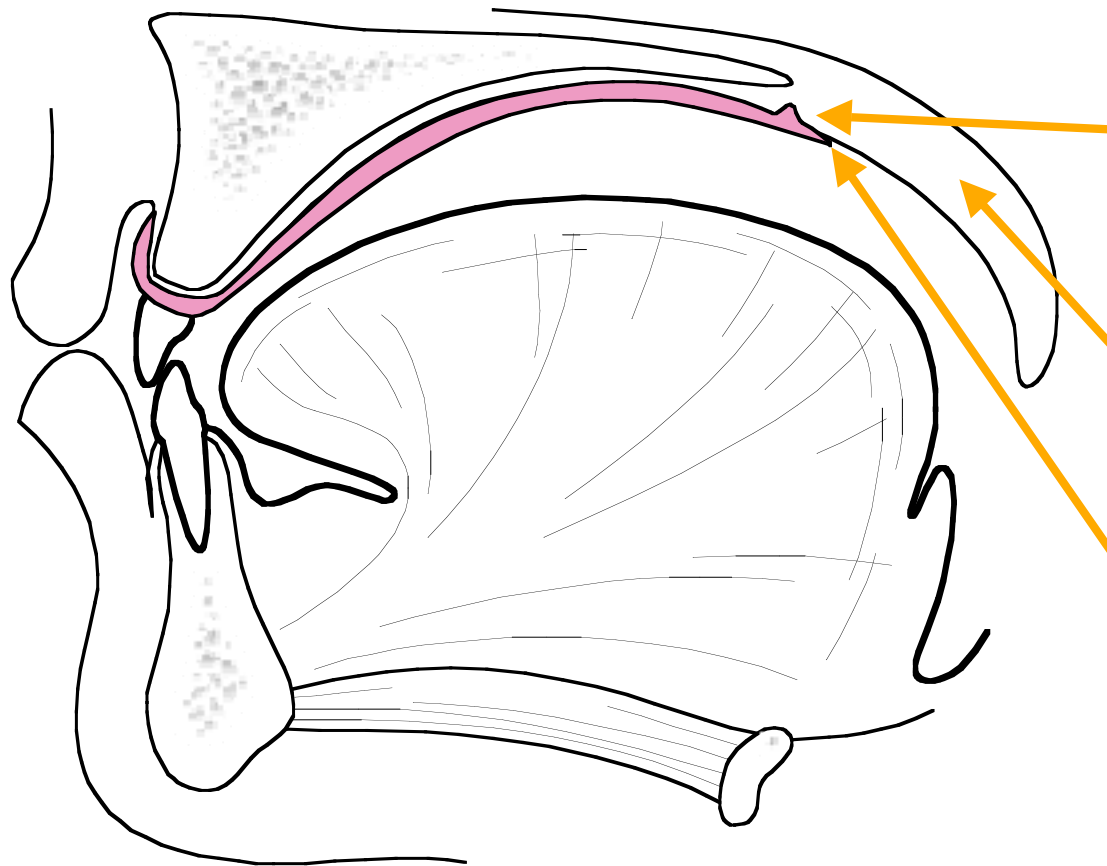


**Modification or Replacement of a Posterior  
Palatal Seal ( Post - Dam )**



The Posterior aspect of this impression has been modified in the mouth with fluid wax to provide a posterior palatal seal. The wax is placed along the posterior aspect of the impression. The impression is then returned to the mouth where the fluid wax is allowed to “adapt” for several minutes. The wax causes displacement of tissue in the area of the post-dam in a physiologic manner. This type of posterior palatal seal is called a “functional” post dam.

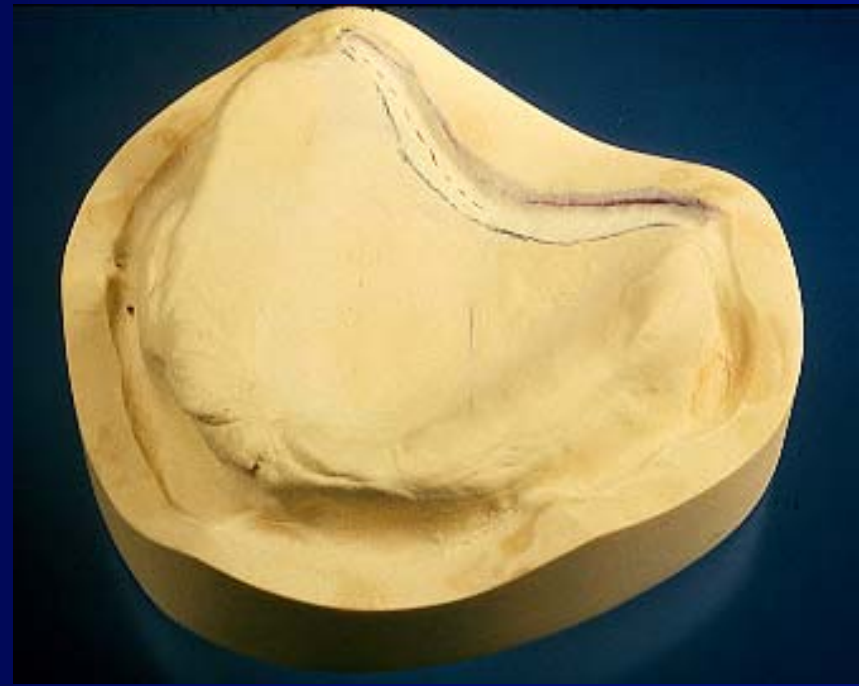
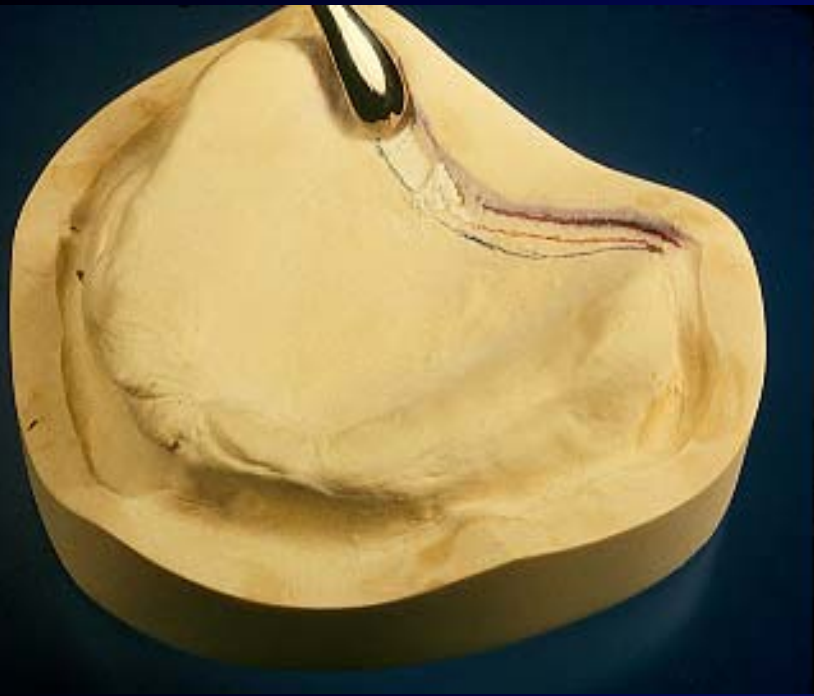


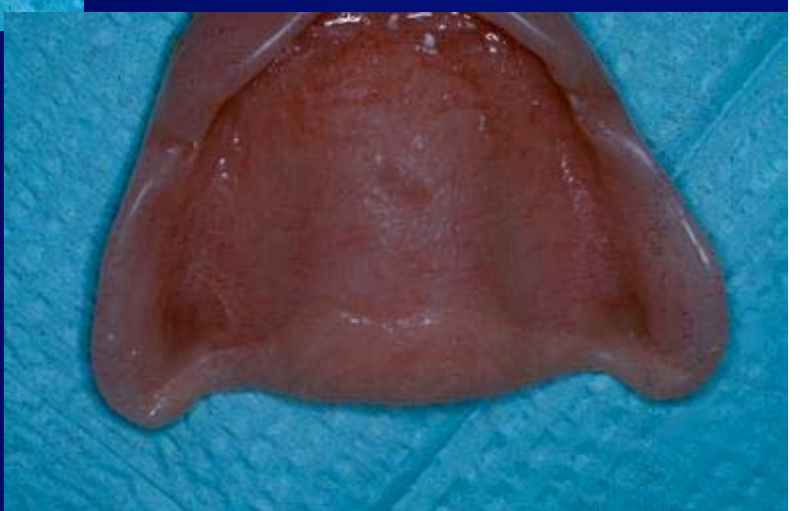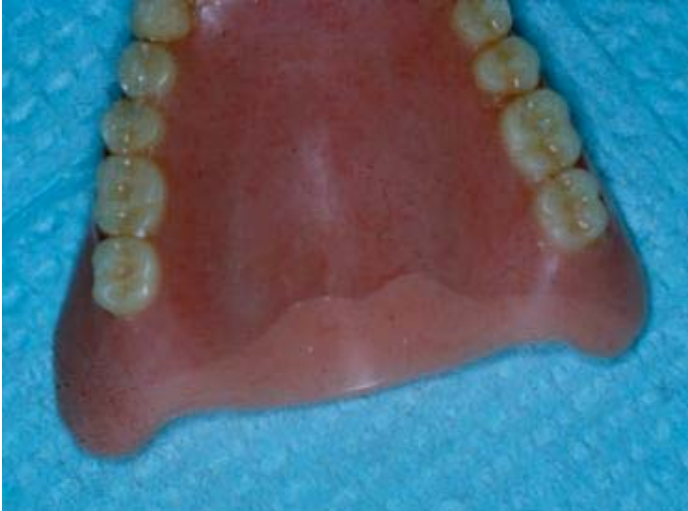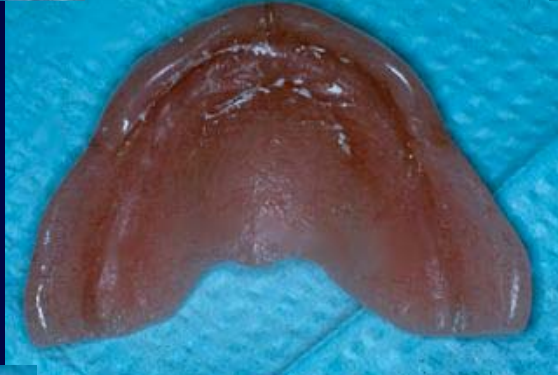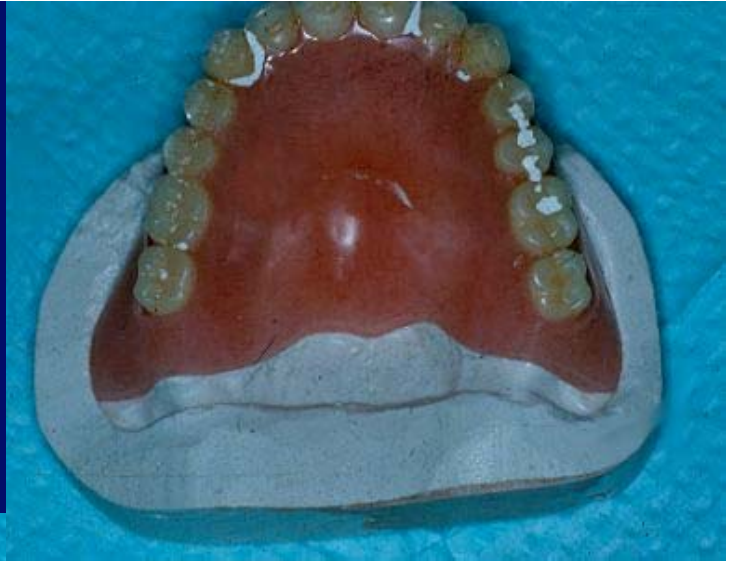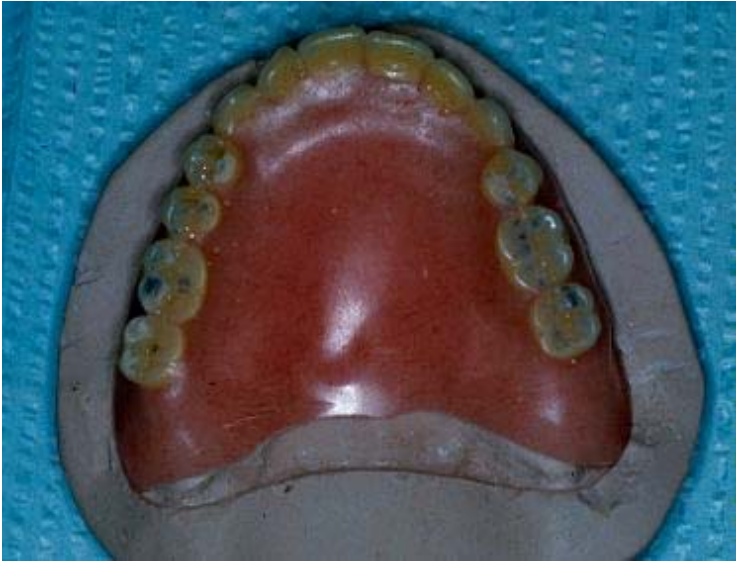A) Post Dam, which displaces tissue slightly

B) Movable Soft Palate

C) Posterior Extent of the Denture



This “bead” or “seal” can be mechanically cut into the master cast as well with an instrument. The idea is to provide the completed denture with an elevated area at the posterior border. This area slightly displaces tissue and provides an increased seal across the back edge of the maxillary denture.





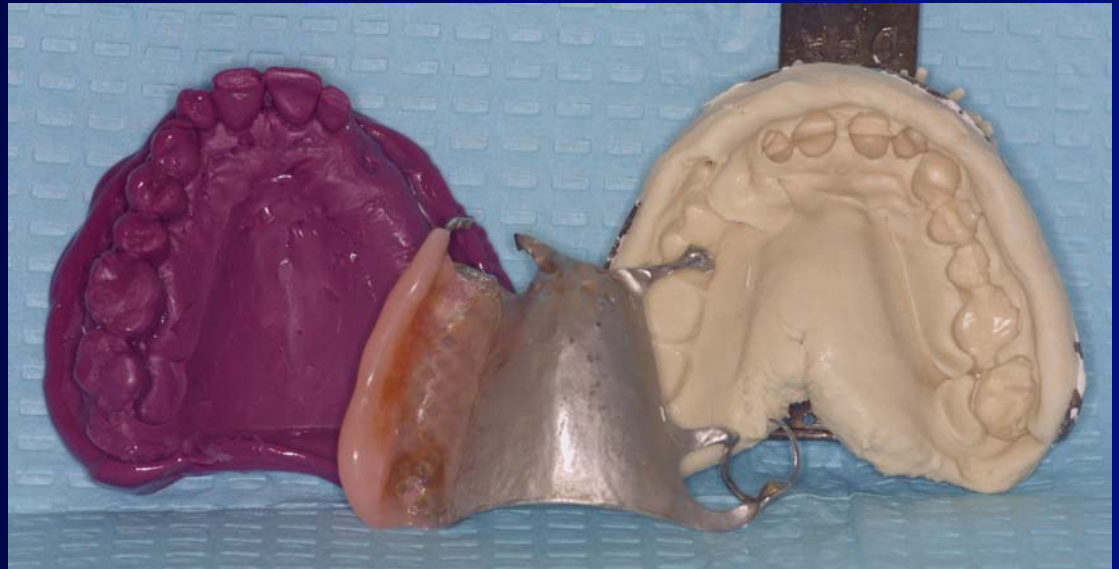
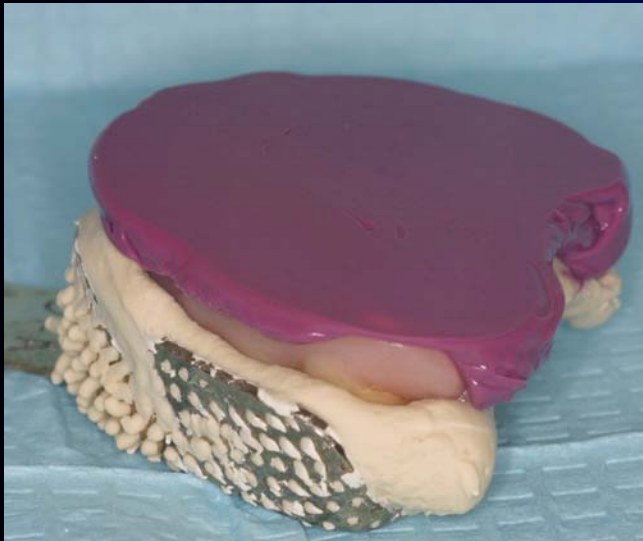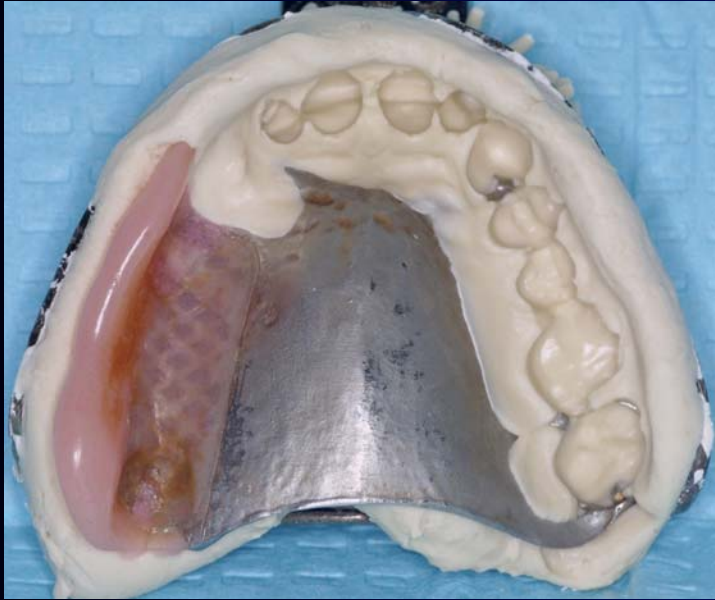
# Common Repairs For Complete Dentures / RPD's

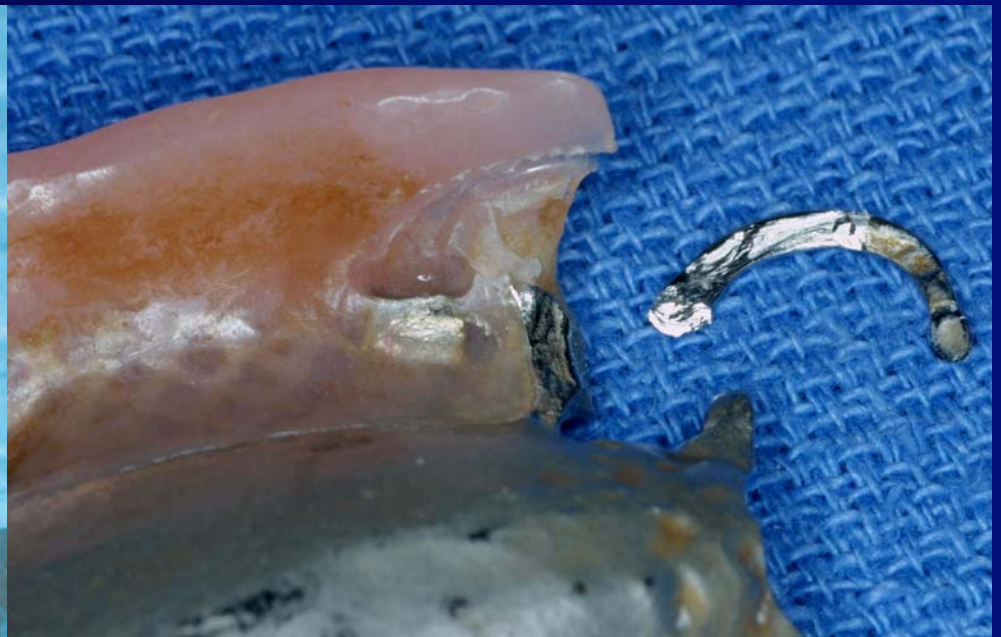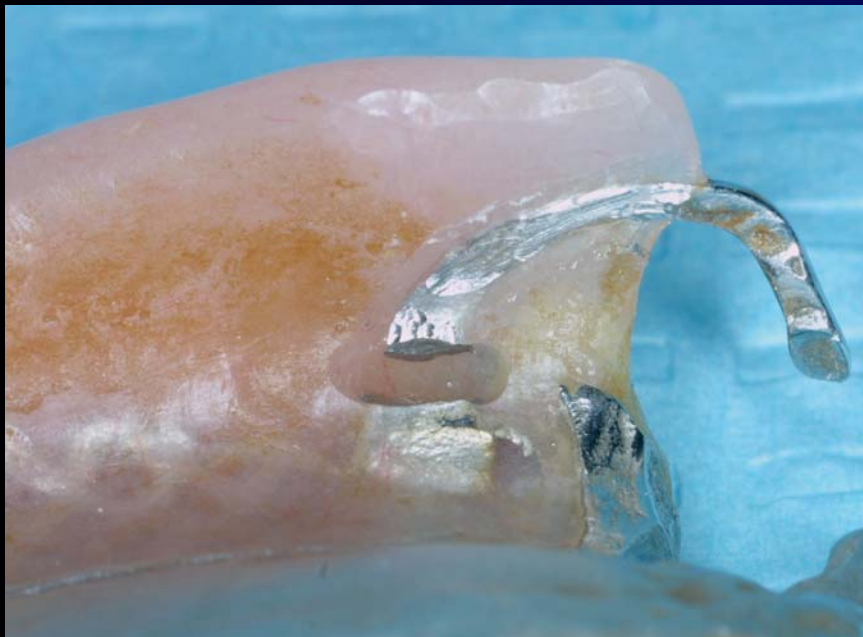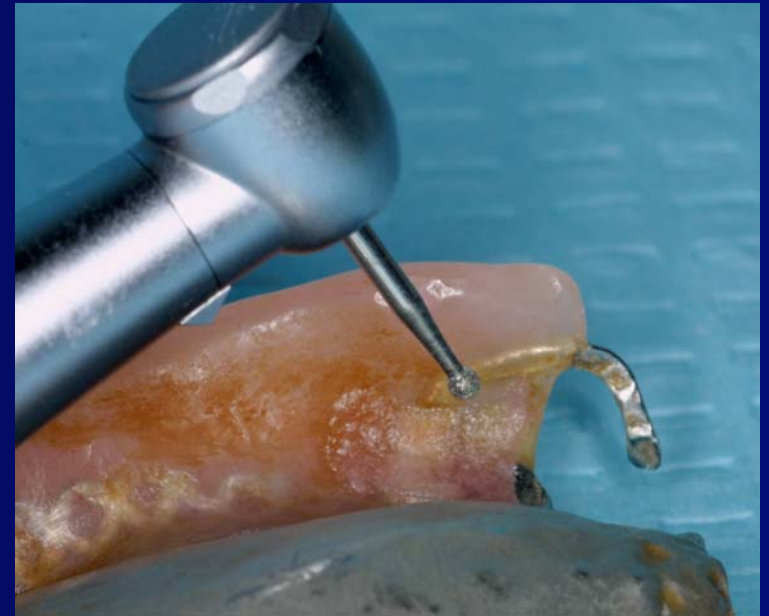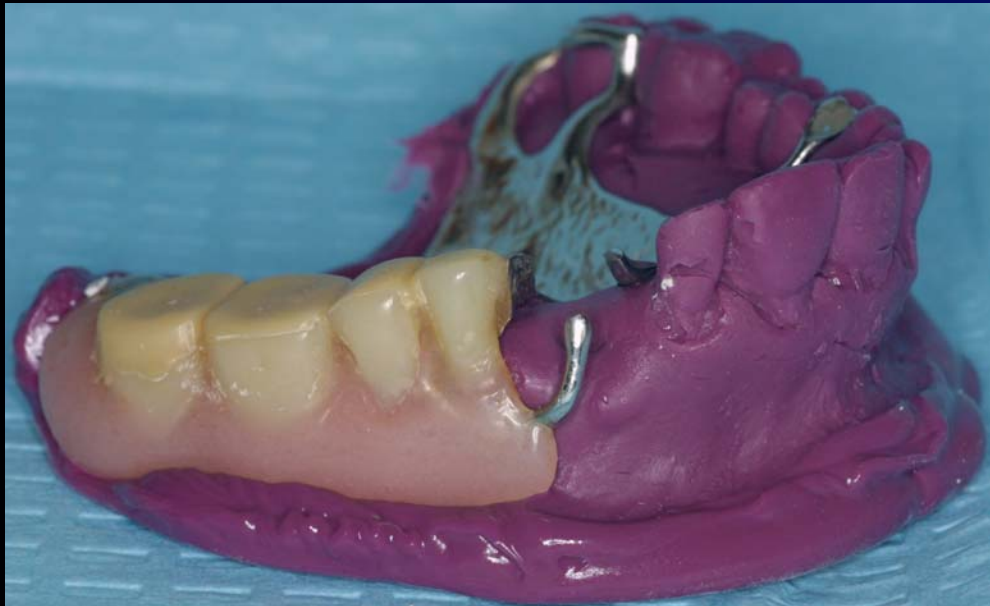Fractured Denture

Fractured or Damaged Tooth /  
Modification of RPD

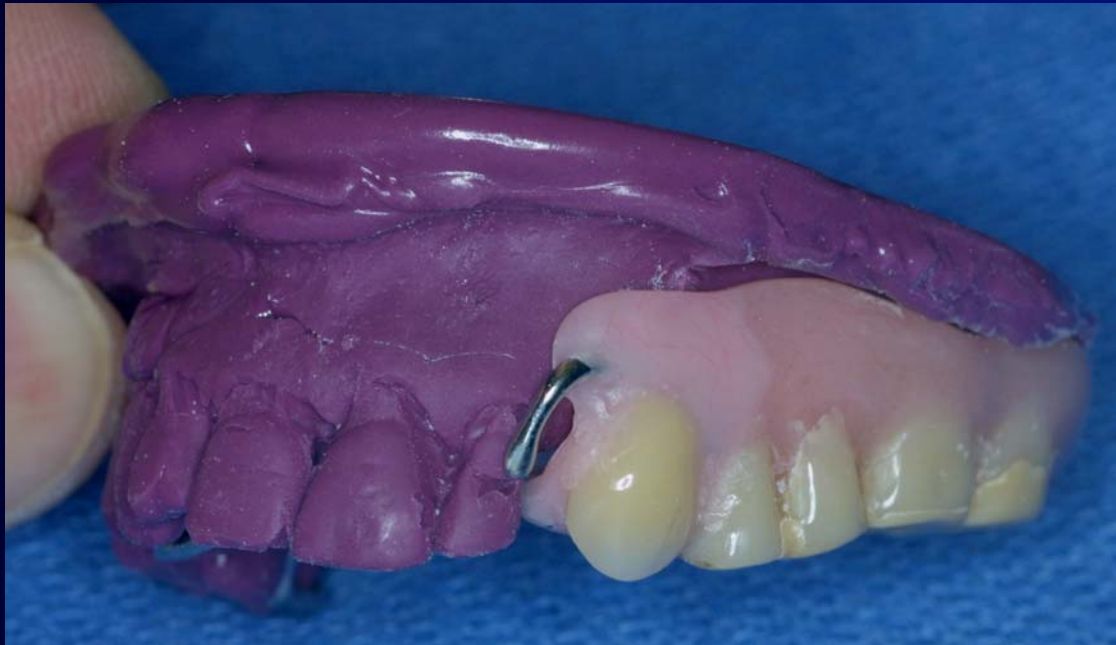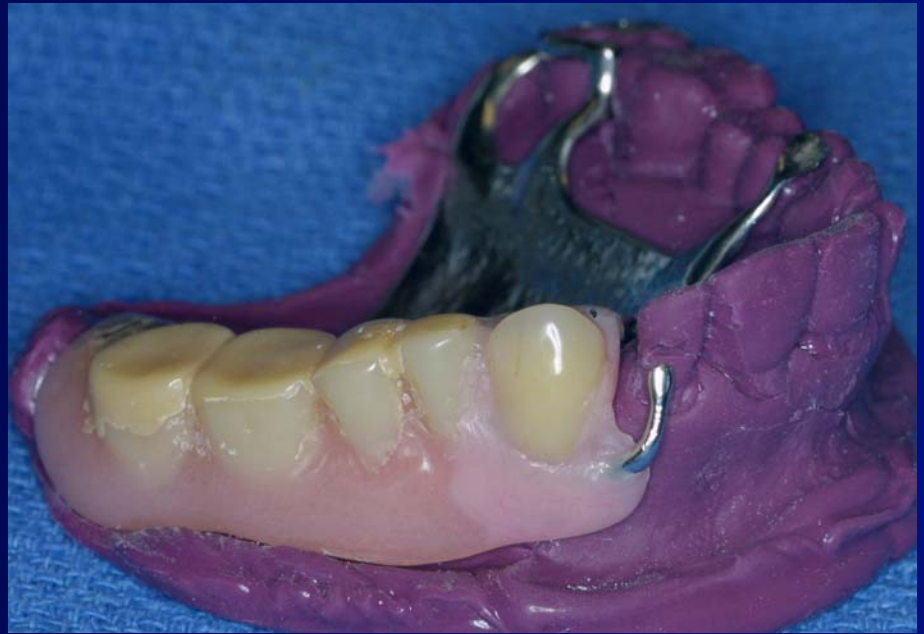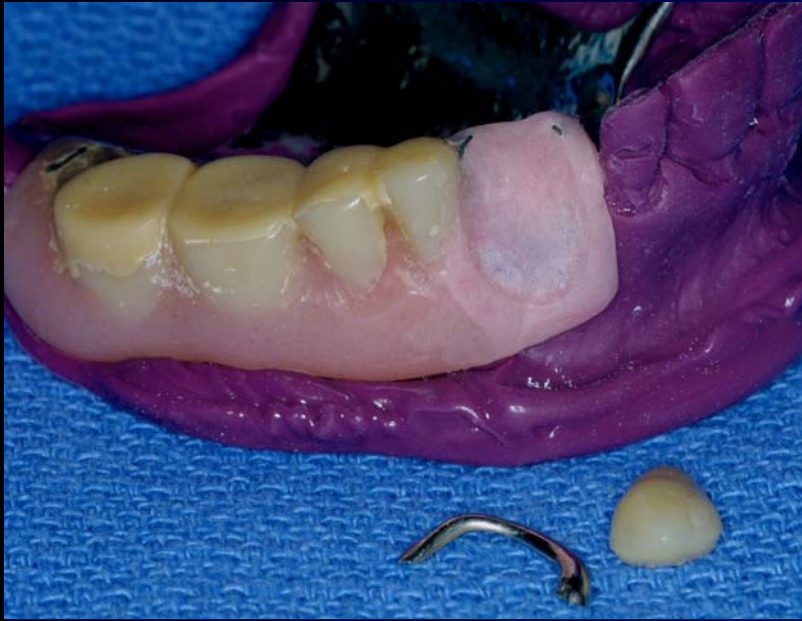Post Dam Modification

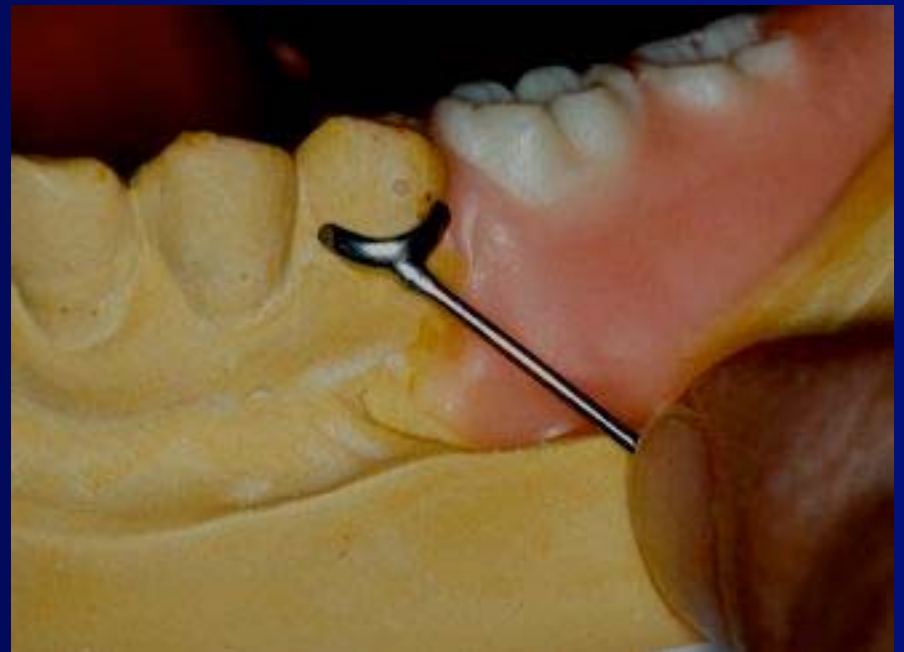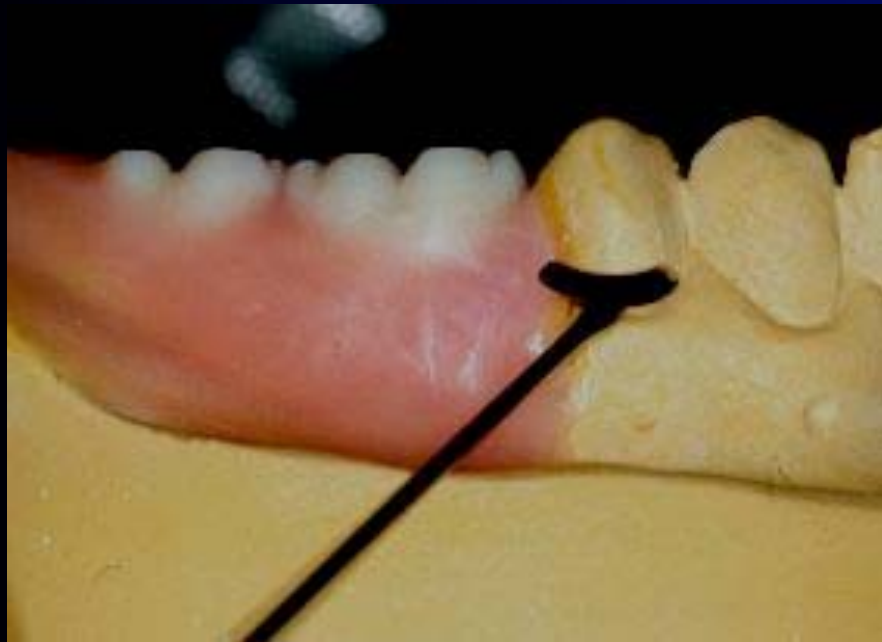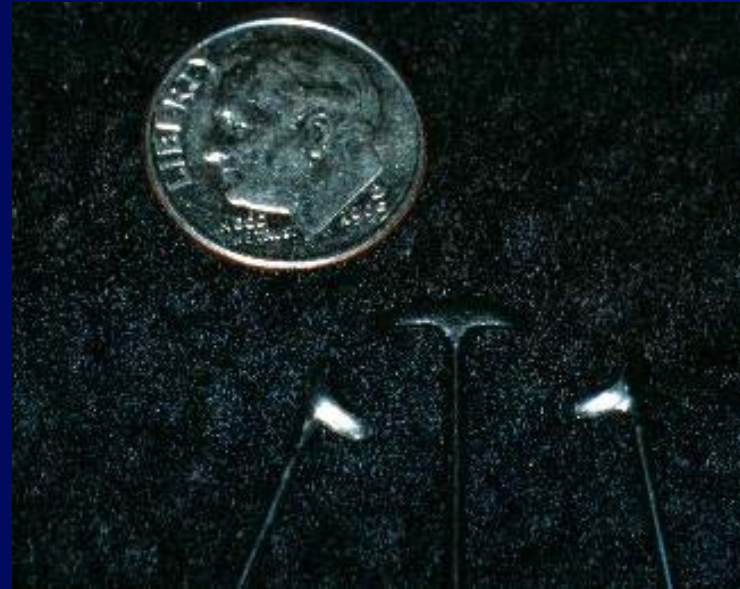Clasp Repair



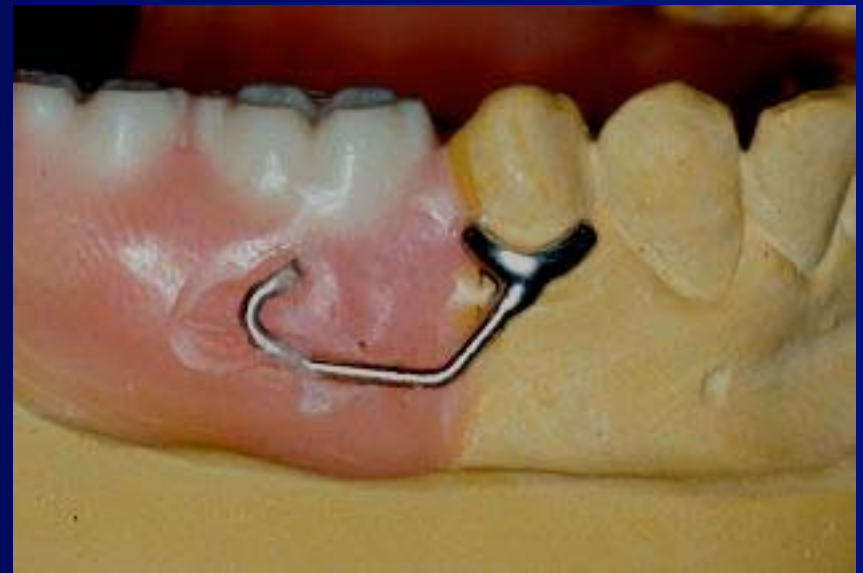
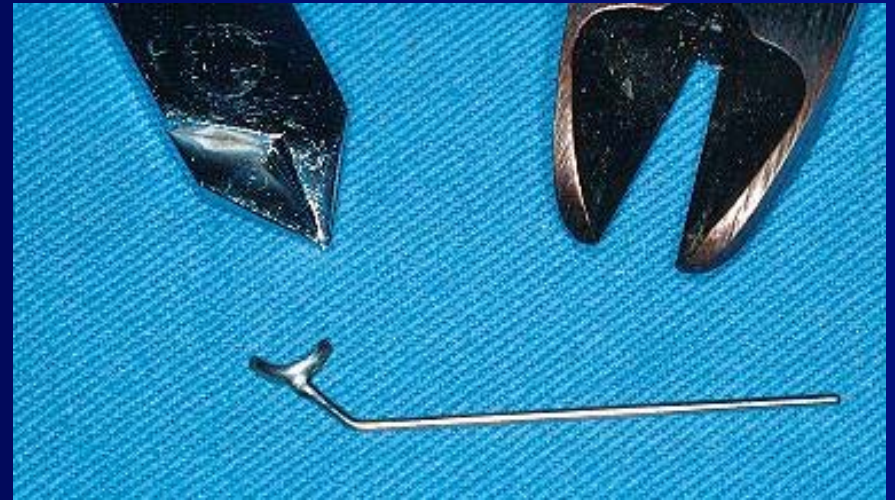




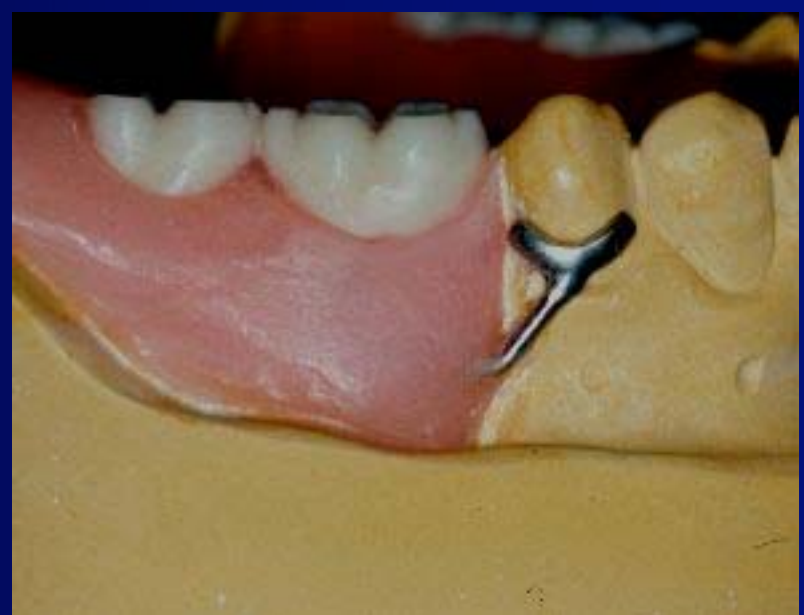
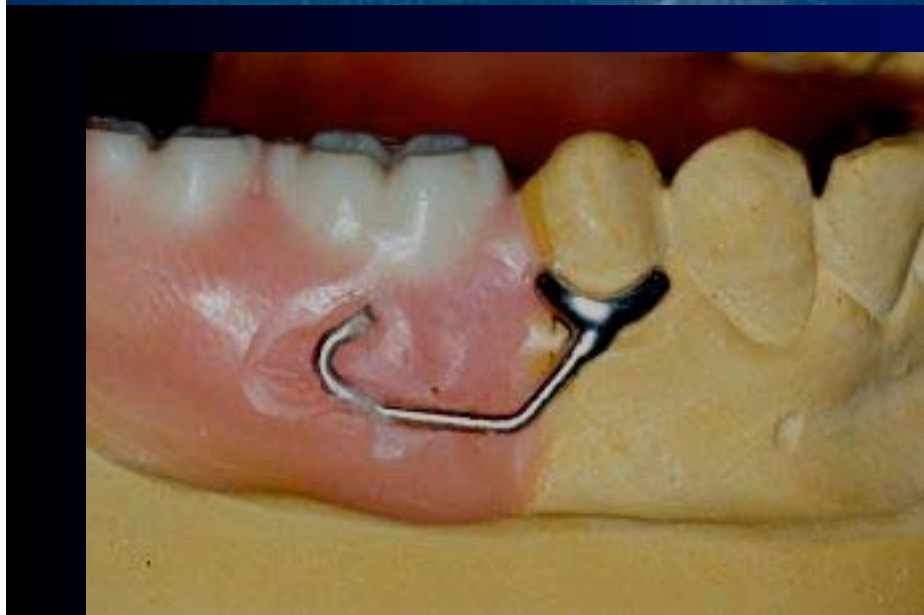


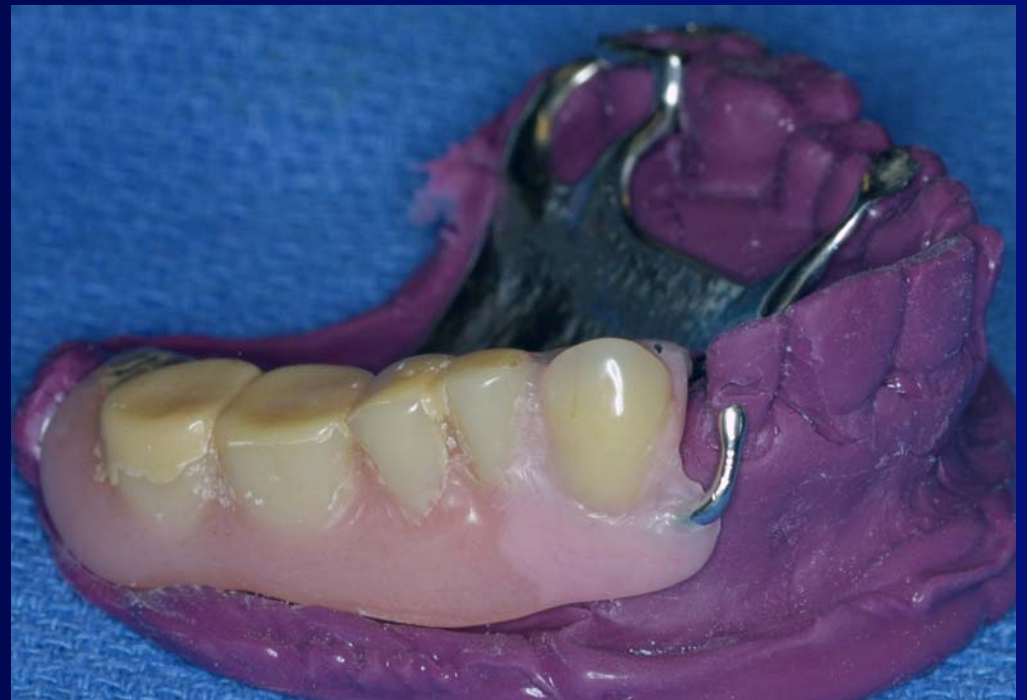
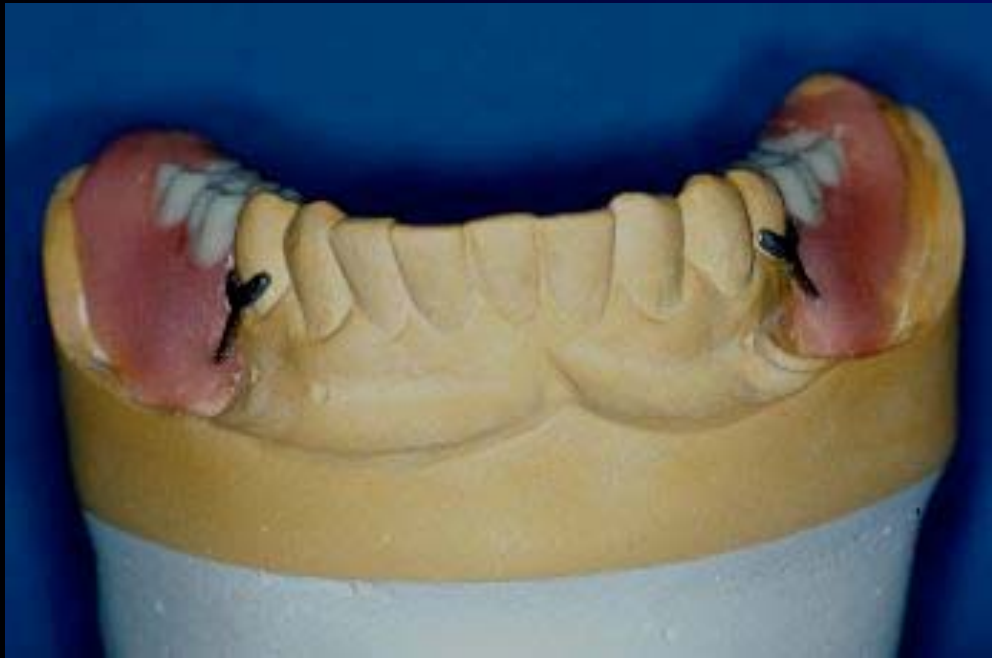









# Crown To Fit An Existing RPD

Often difficult to perform and achieve a “good fit” between new crown and pre-existing RPD.

Takes significant chair time.

Patient needs to be without the RPD.



