open.michigan

Unless otherwise noted, the content of this course material is licensed under a Creative Commons Attribution - Non-Commercial - Share Alike 3.0 License.

Copyright 2008, Gerald Abrams

The following information is intended to inform and educate and is not a tool for self-diagnosis or a replacement for medical evaluation, advice, diagnosis or treatment by a healthcare professional. You should speak to your physician or make an appointment to be seen if you have questions or concerns about this information or your medical condition. You assume all responsibility for use and potential liability associated with any use of the material.

Material contains copyrighted content, used in accordance with U.S. law. Copyright holders of content included in this material should contact open.michigan@umich.edu with any questions, corrections, or clarifications regarding the use of content. The Regents of the University of Michigan do not license the use of third party content posted to this site unless such a license is specifically granted in connection with particular content objects. Users of content are responsible for their compliance with applicable law. Mention of specific products in this recording solely represents the opinion of the speaker and does not represent an endorsement by the University of Michigan.

Viewer discretion advised: Material may contain medical images that may be disturbing to some viewers.

UNIVERSITY OF MICHIGAN

CC BY NC SA

Circulatory Derangements

- I -Congestion, Edema
- II -Hemorrhage
- III-Thrombosis
- IV-Embolism, Ischemia, Infarction
- V –Atherosclerosis, Ischemic Ht. Disease

CONGESTION
Too much blood in an area

Within the cardiovascular system

(unlike hemorrhage)

Vessels engorged with blood

ACTIVE CONGESTION (hyperemia)

Increased flow into the area

-erythema-

PASSIVE CONGESTION

Decreased outflow from area

-cyanosis-

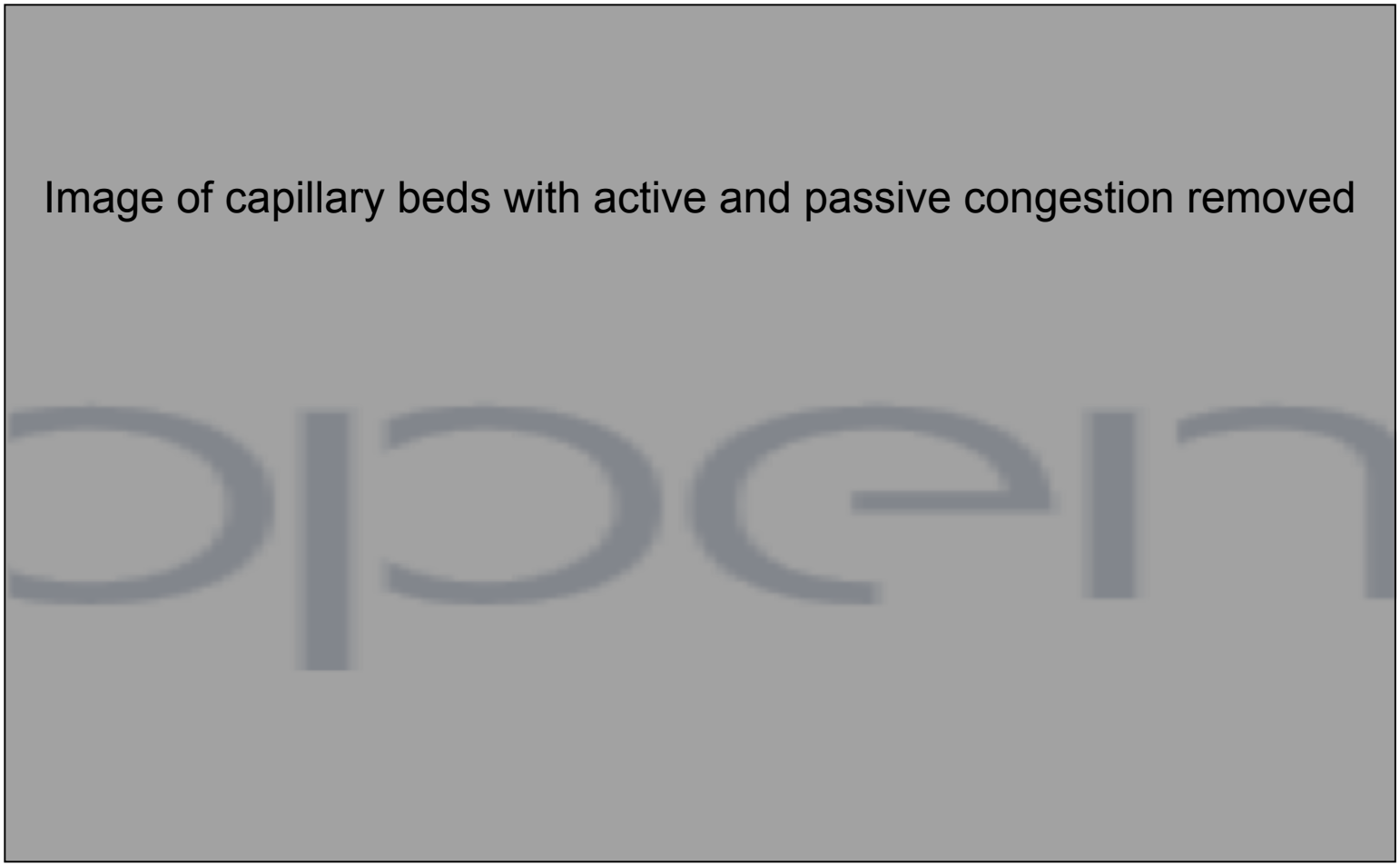
Image of capillary beds with active and passive congestion removed

Normal Lung

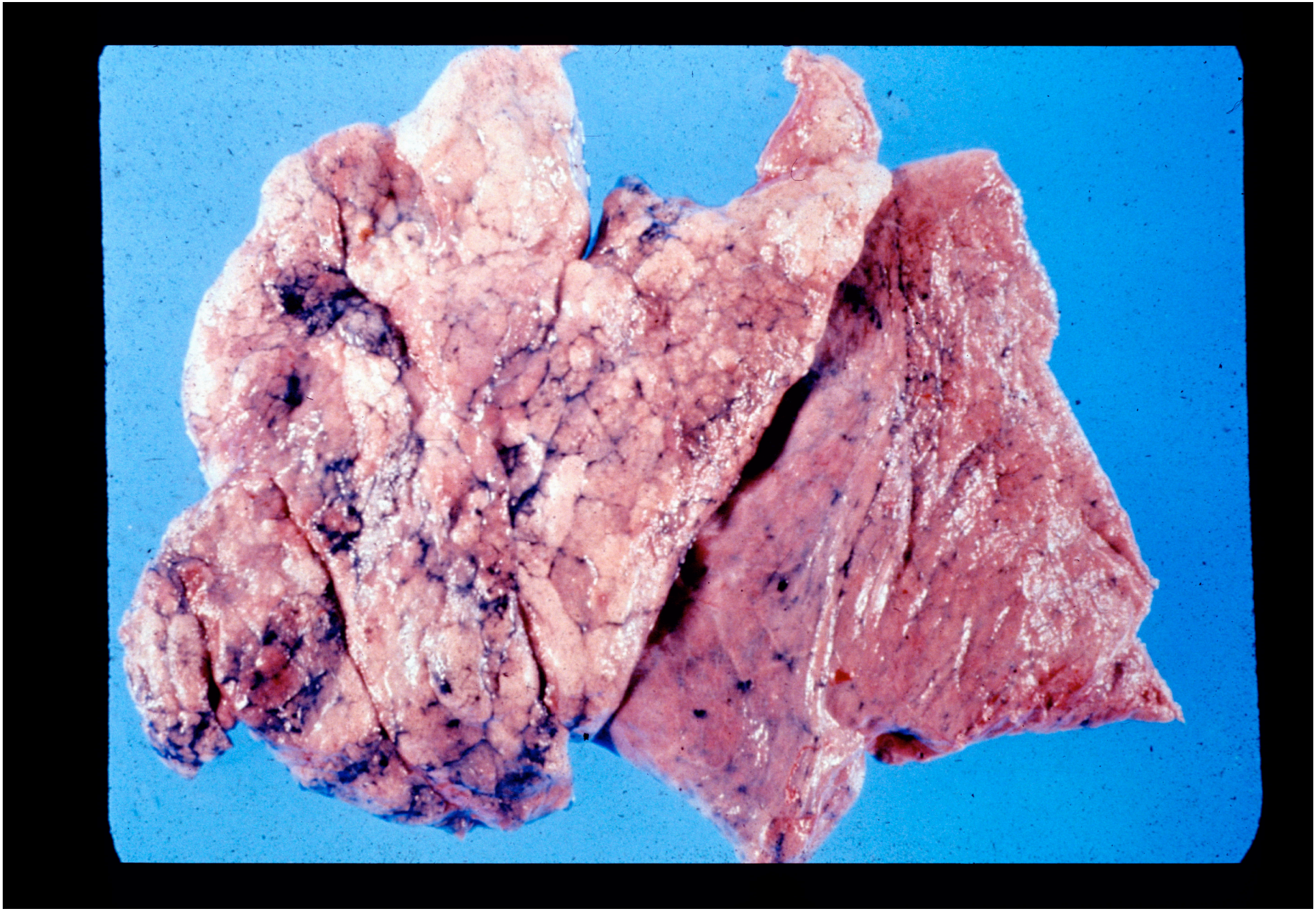

Congested Lung

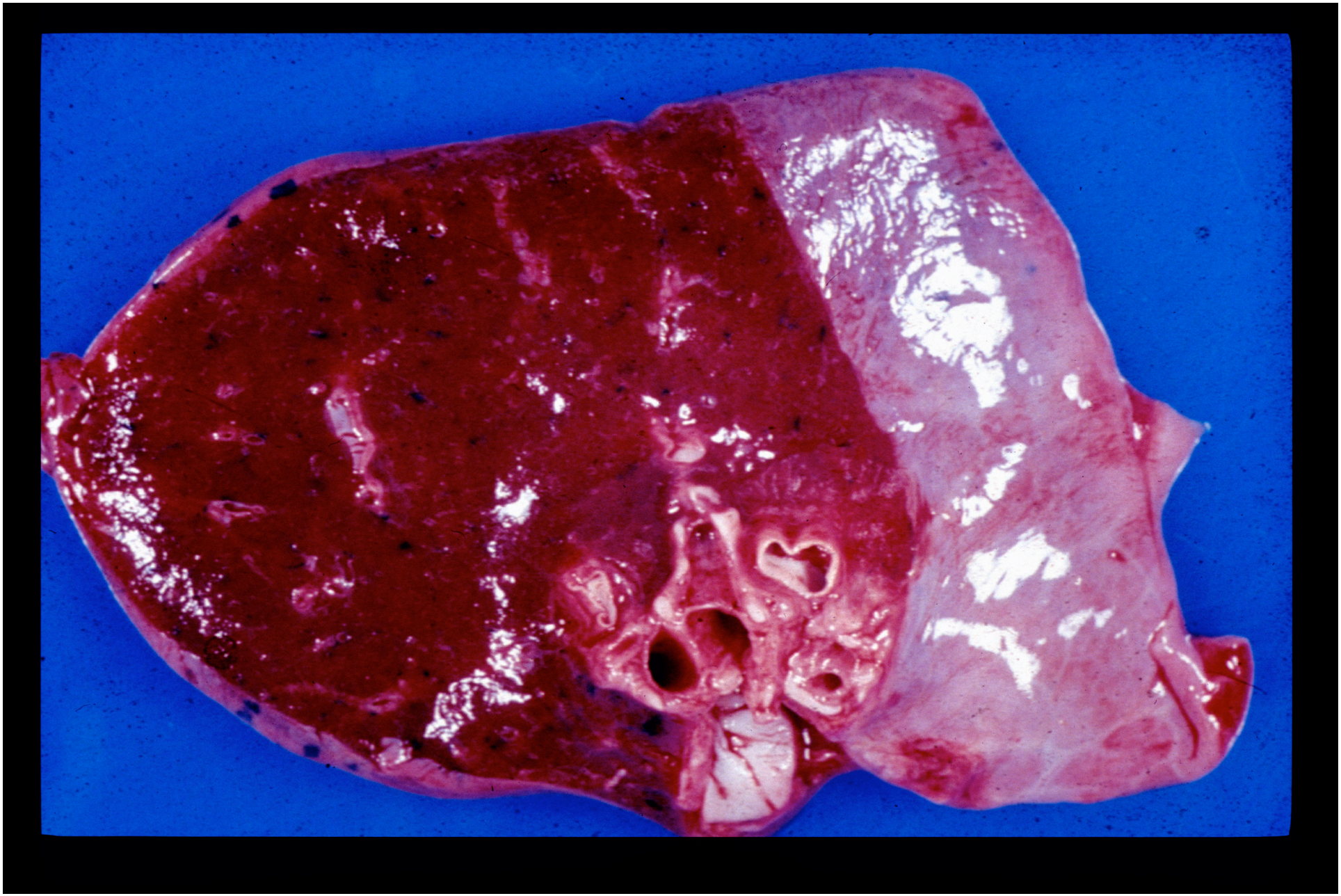

Normal Lung

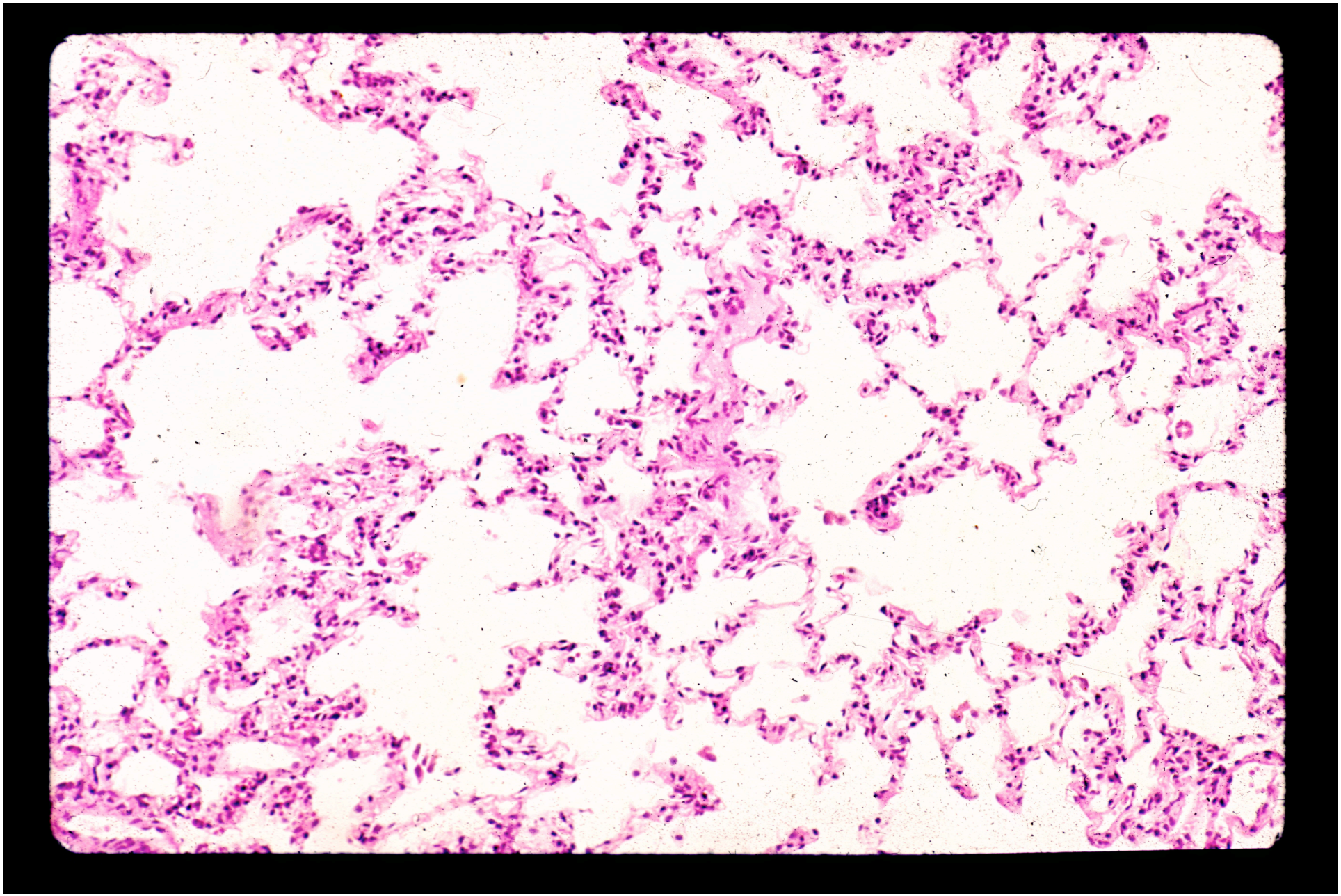

Congested Lung

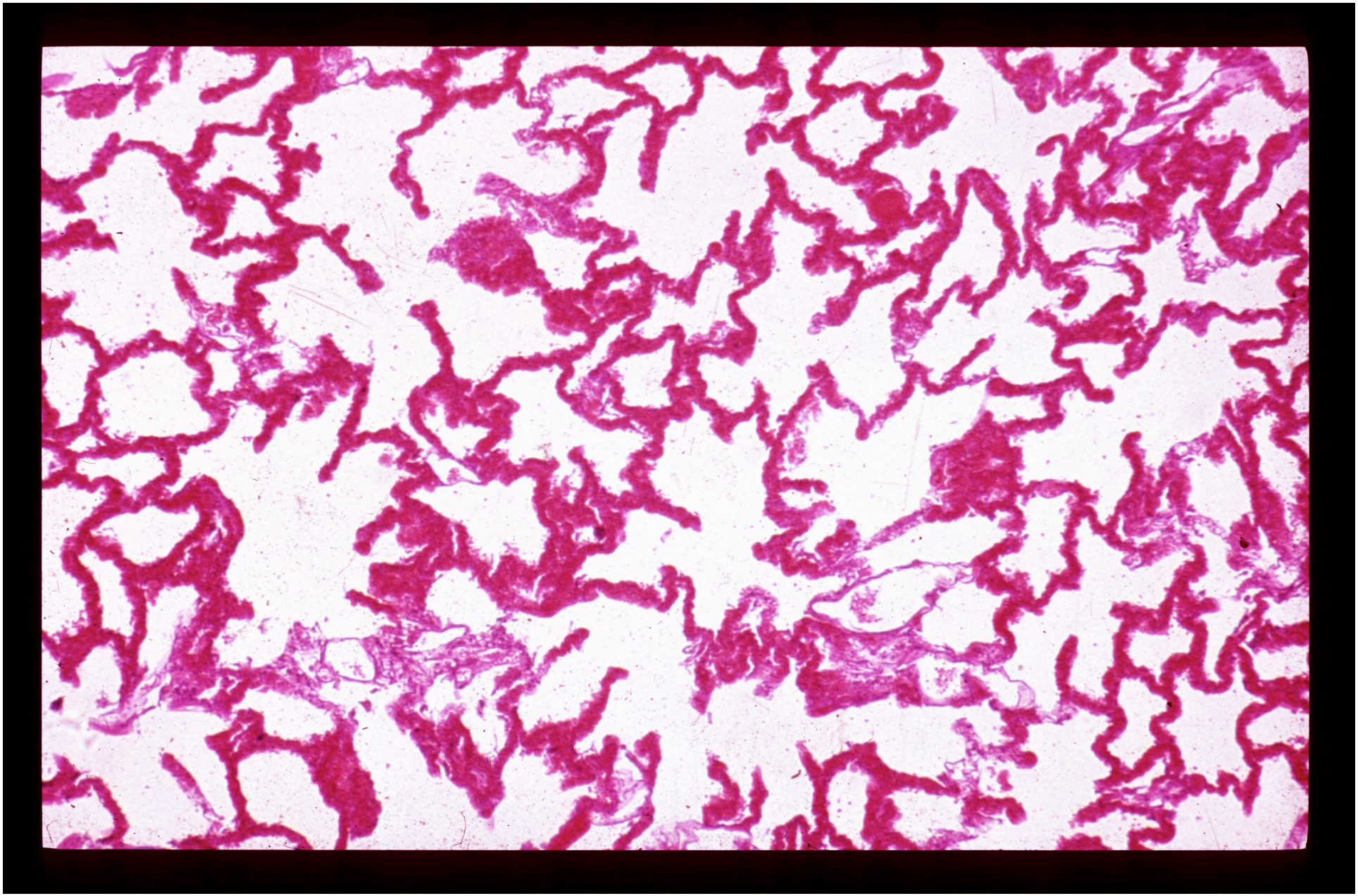

Congested Lung
Hemorrhage by Diapedesis

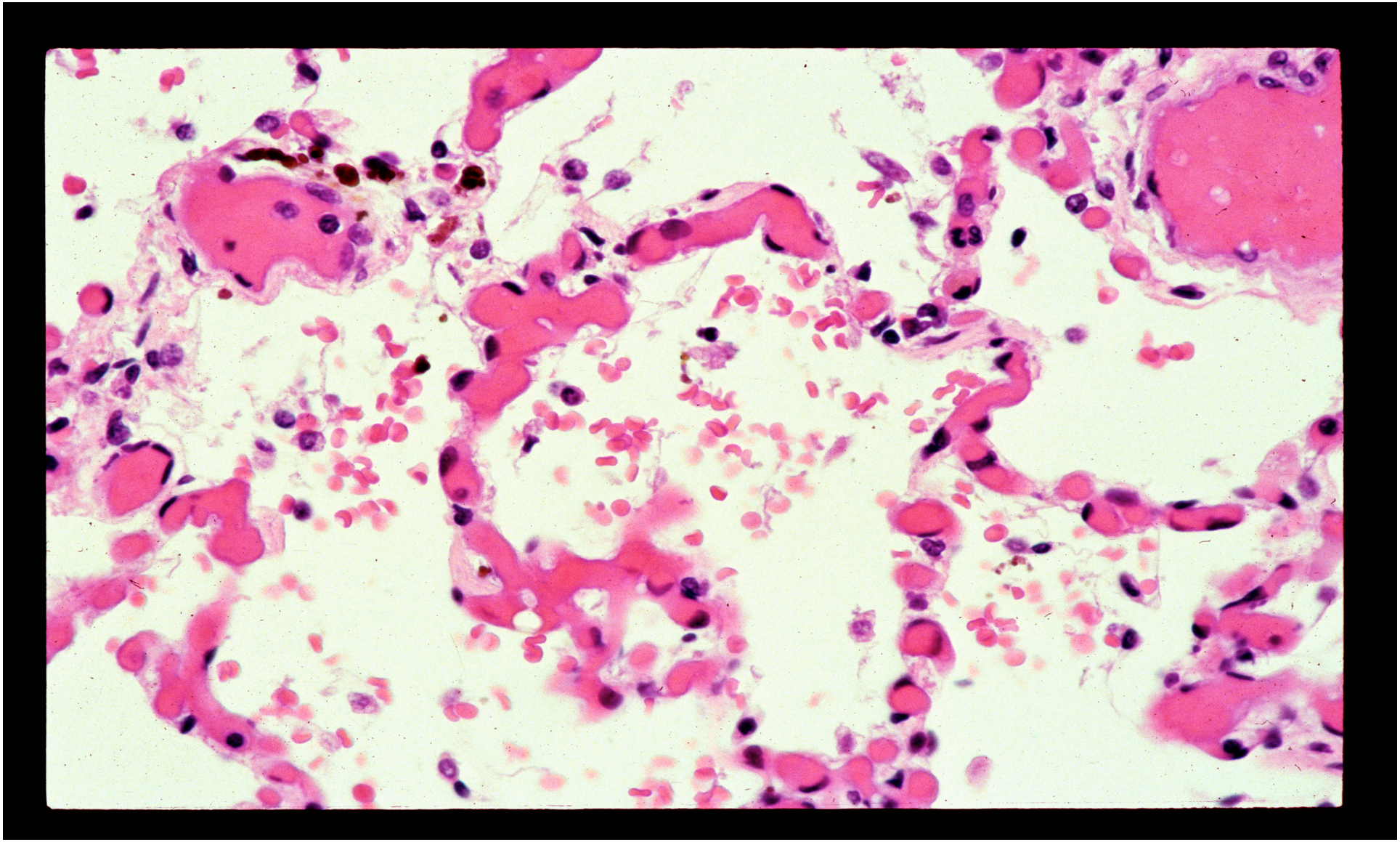

Congestion erythrophagocytosis

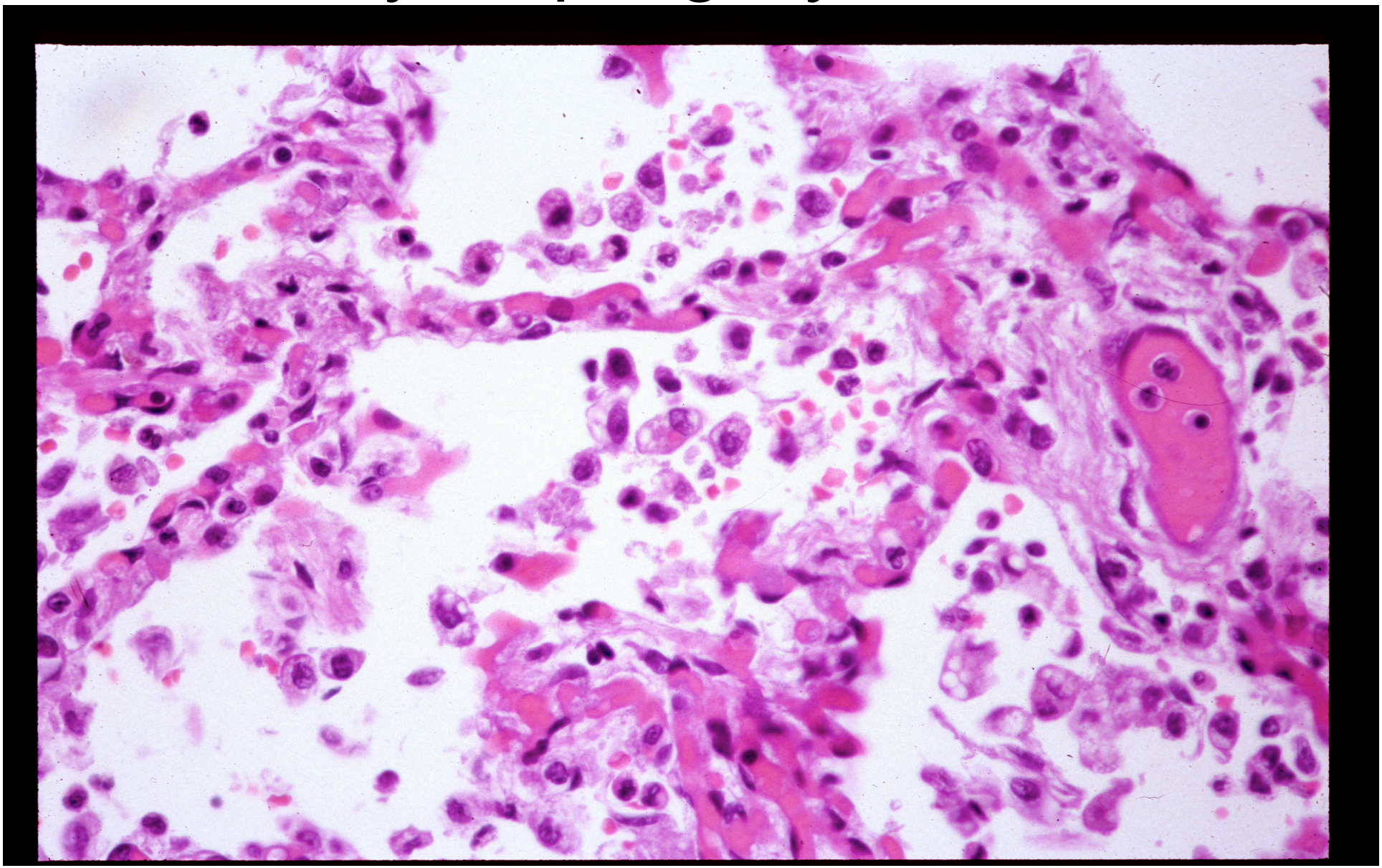

Early CPC

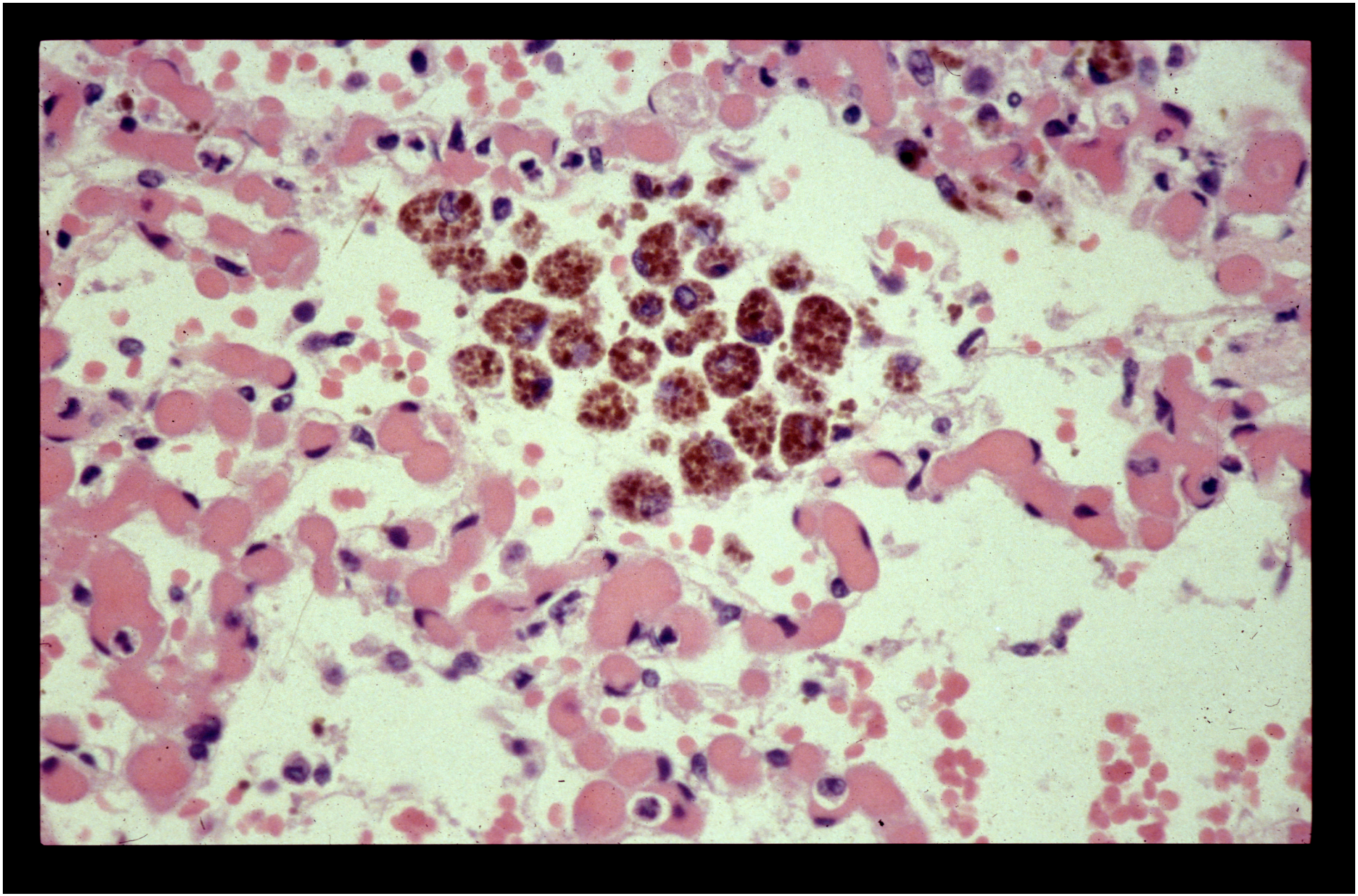

Advanced CPC

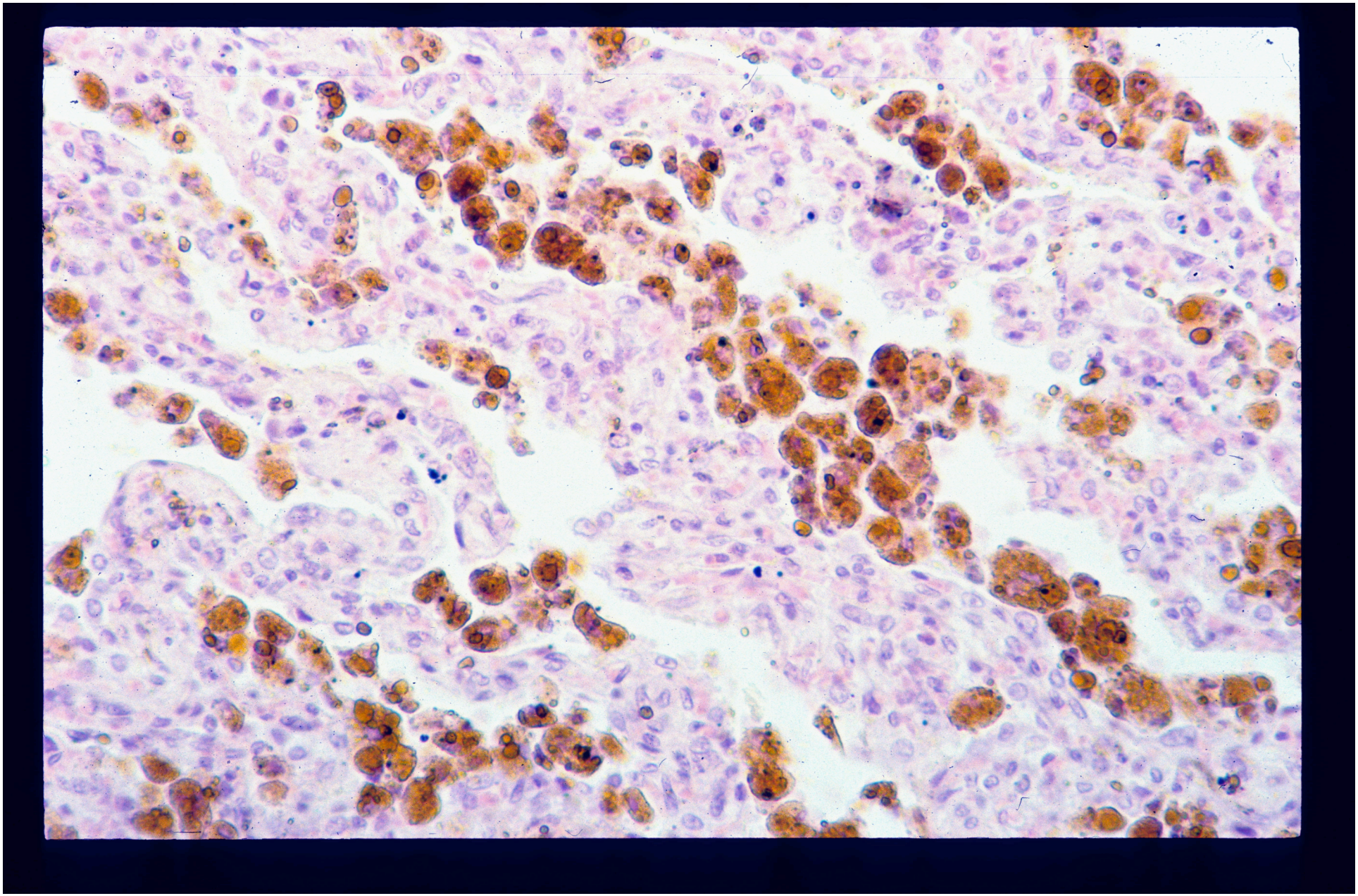

Normal liver

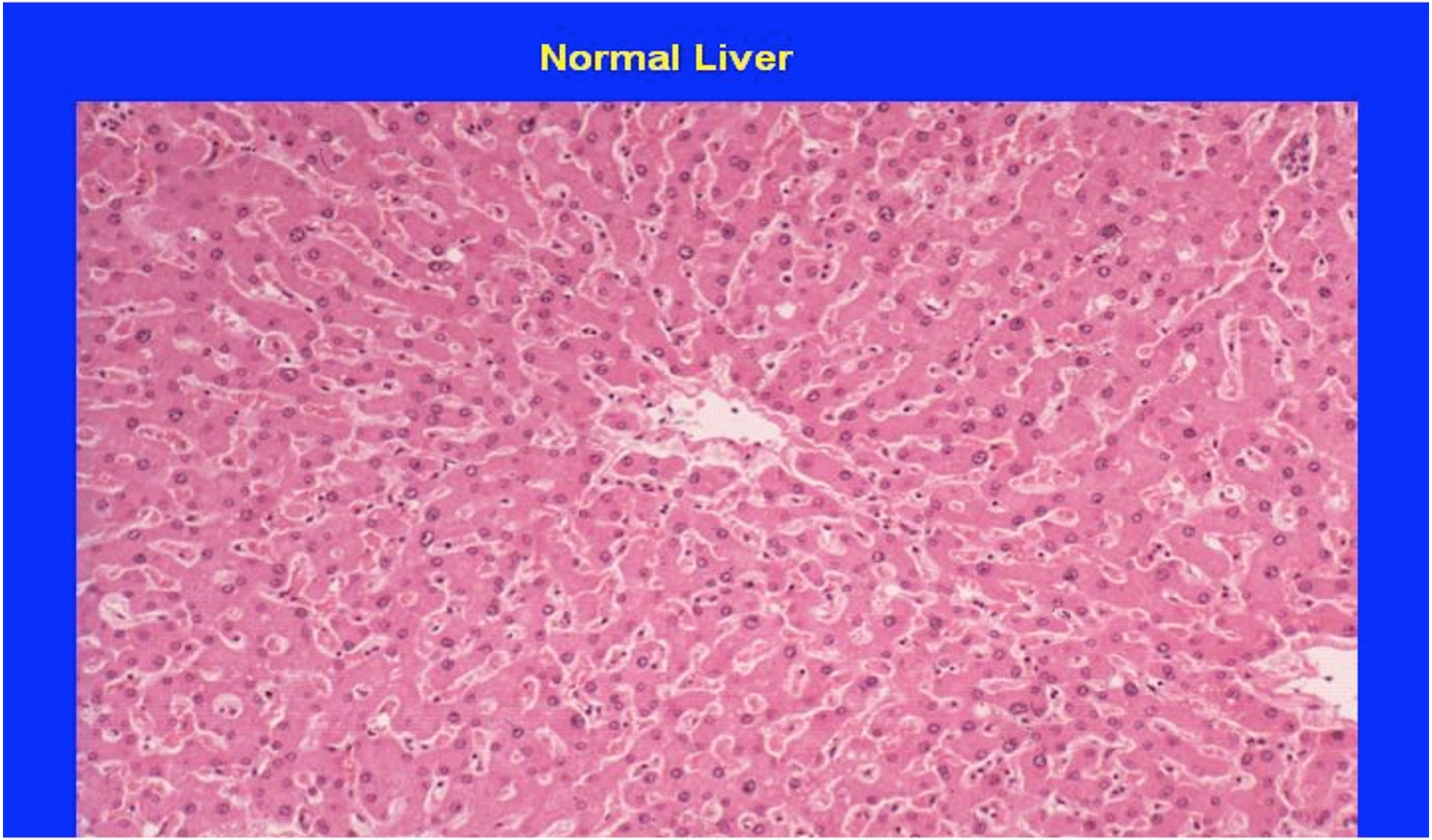

Liver – Outflow Obstruction

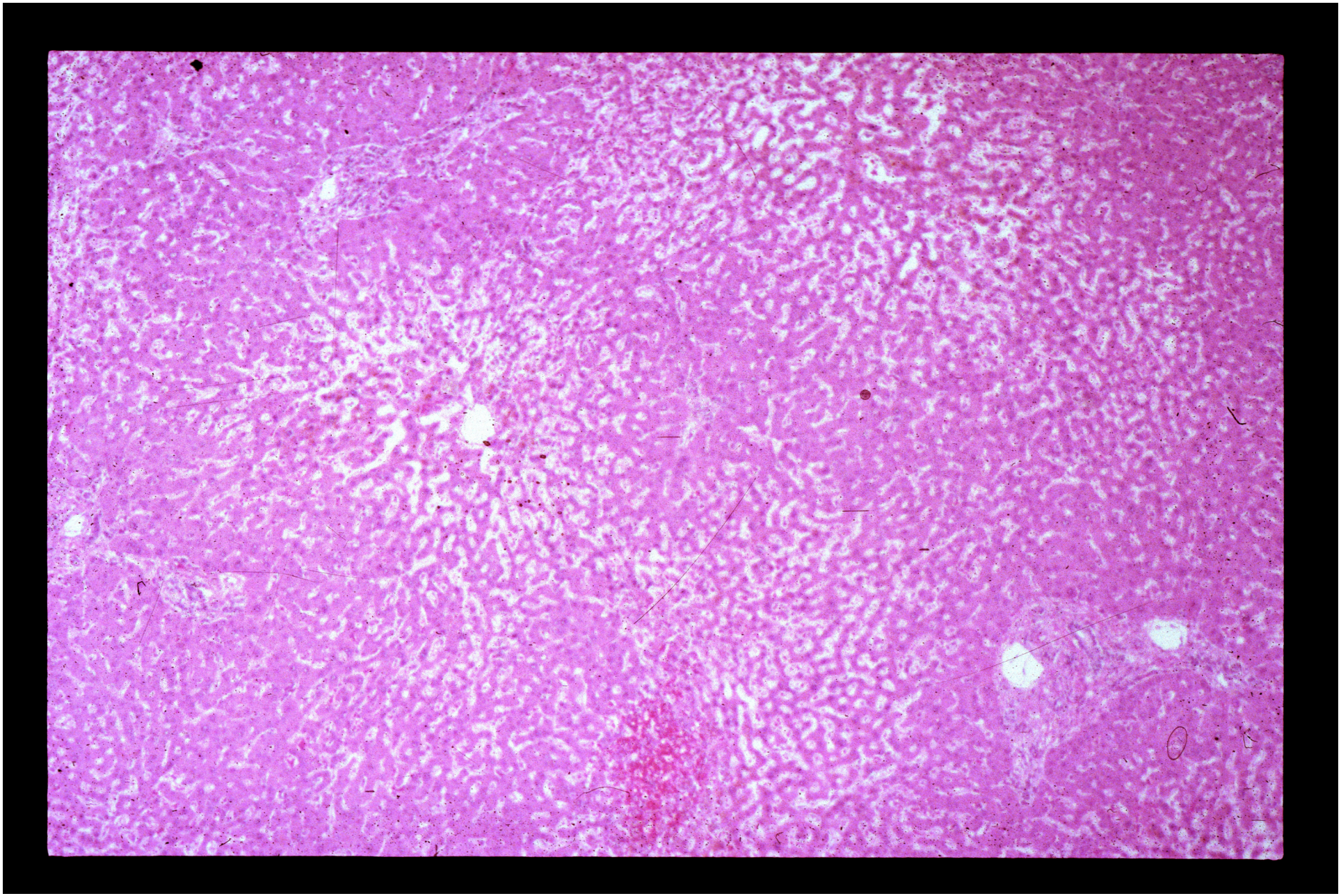

Liver – Outflow Obstruction

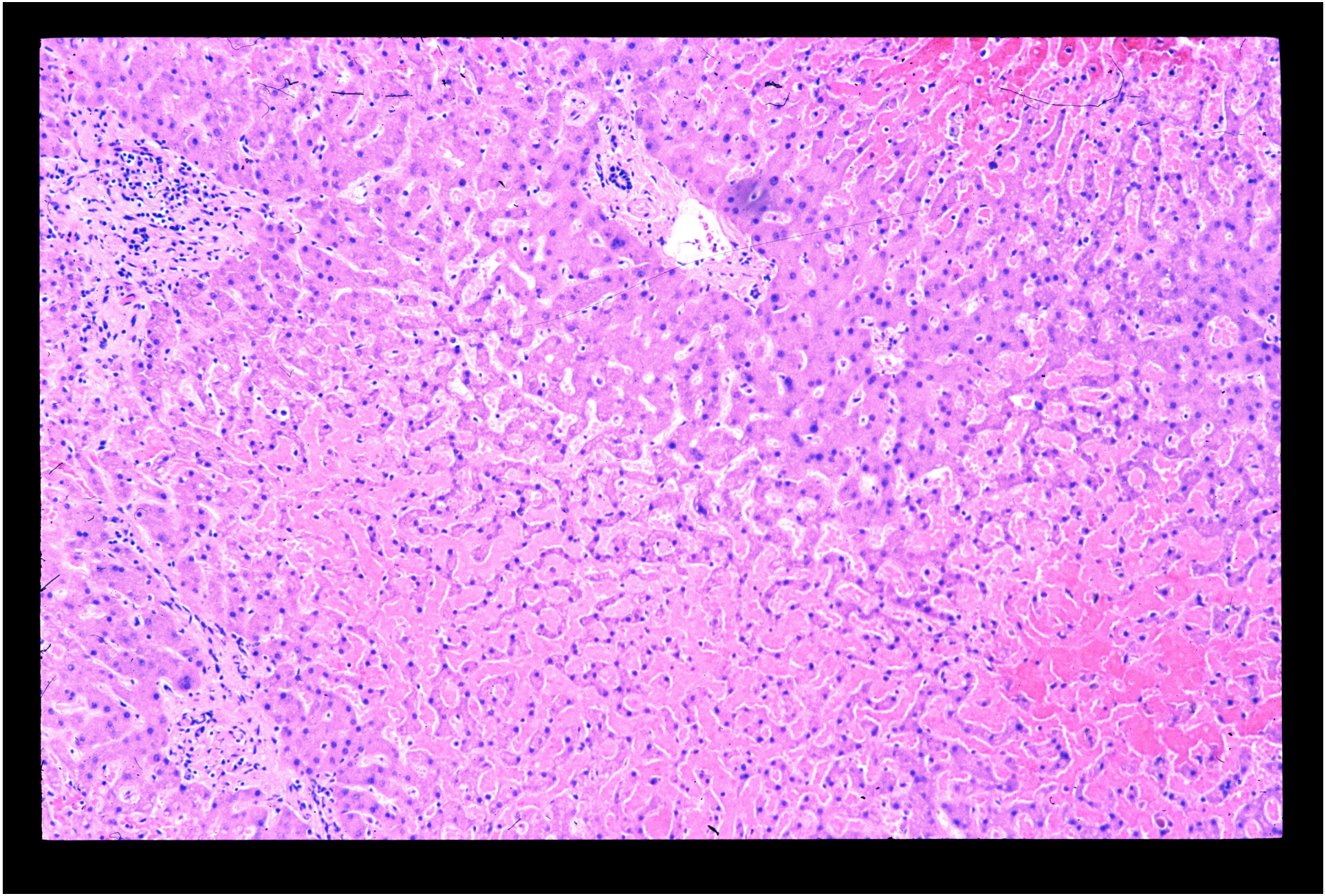

Liver – Outflow Obstruction

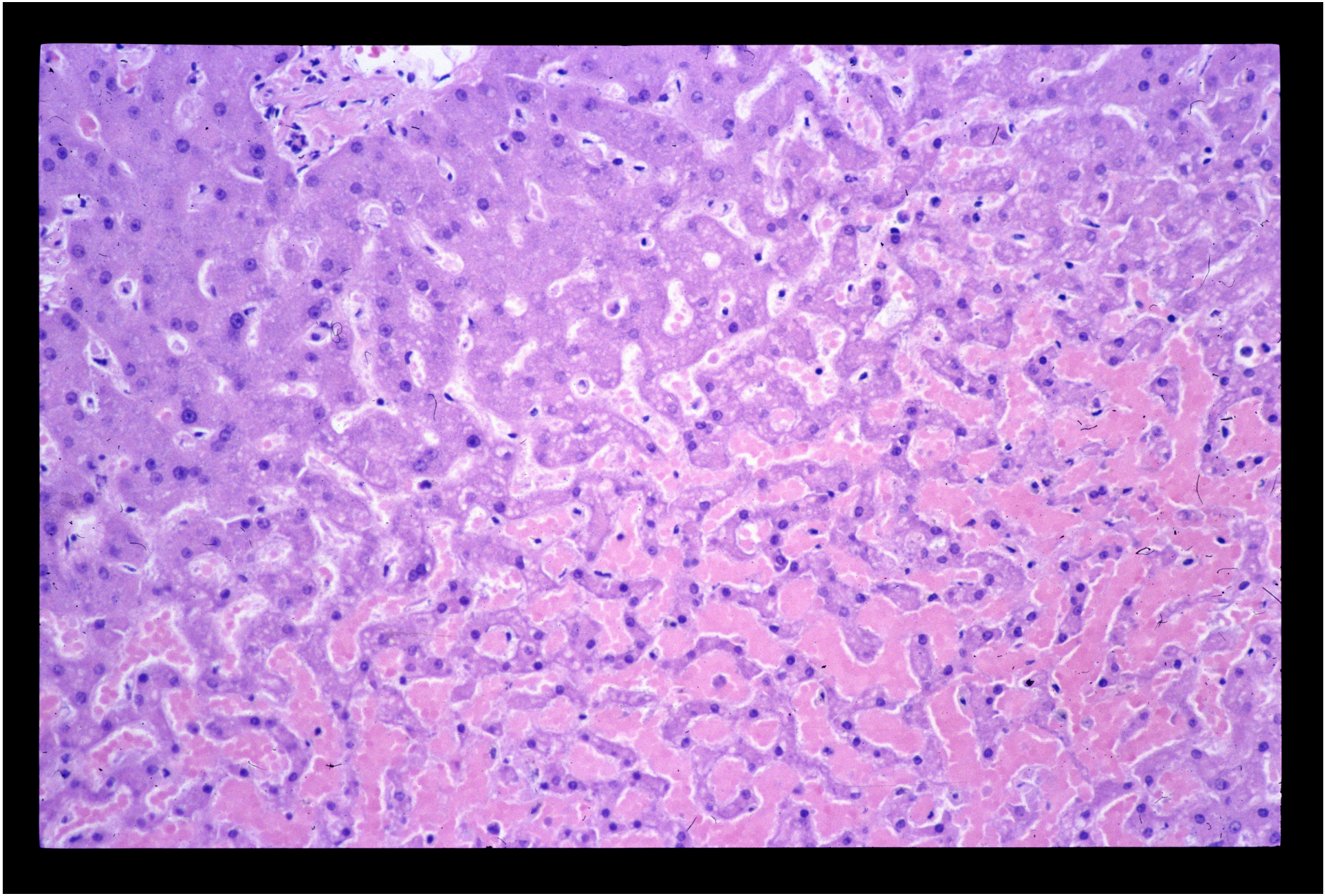

Liver
Central Hemorrhagic Necrosis

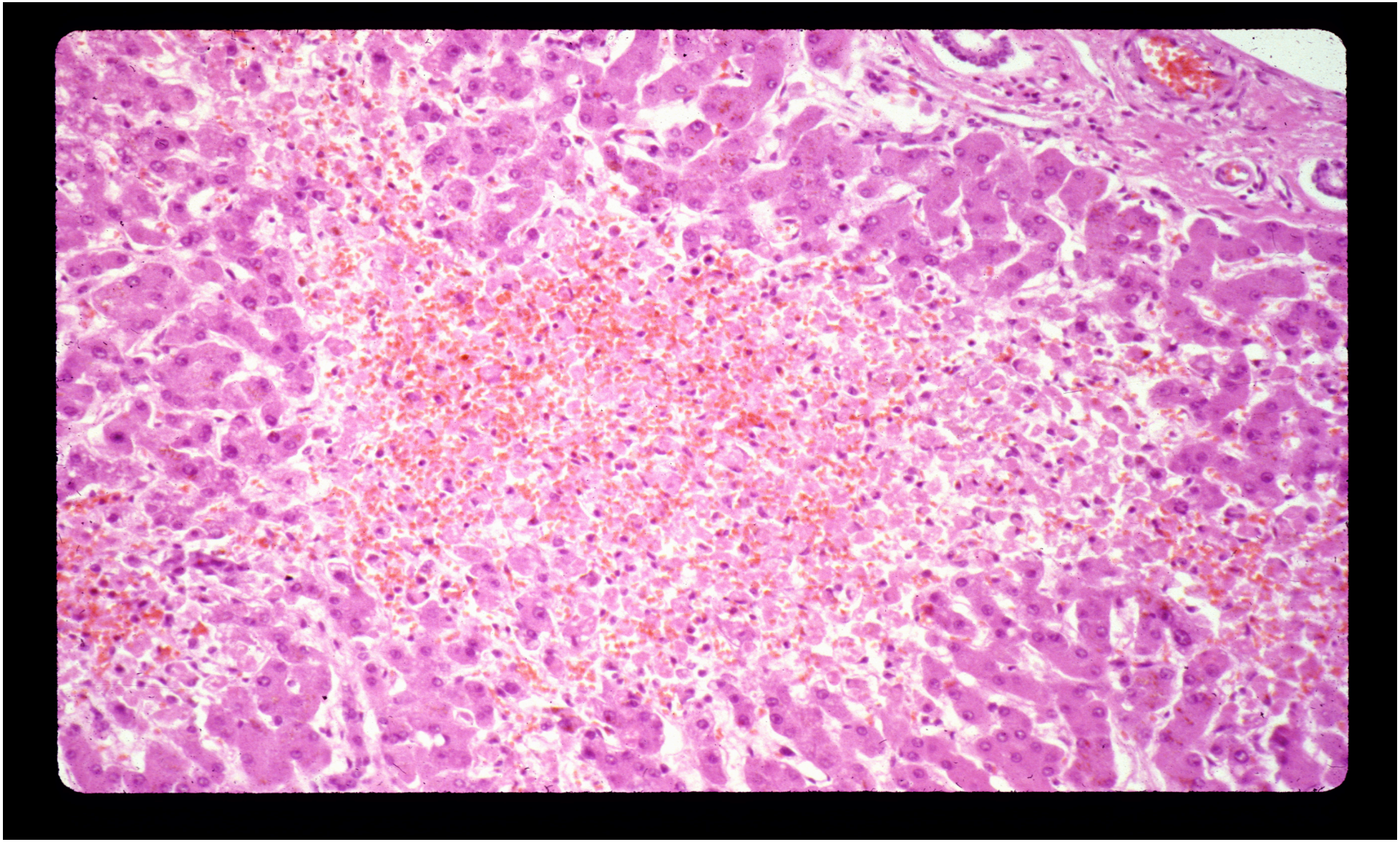

Liver
Central Hemorrhagic Necrosis

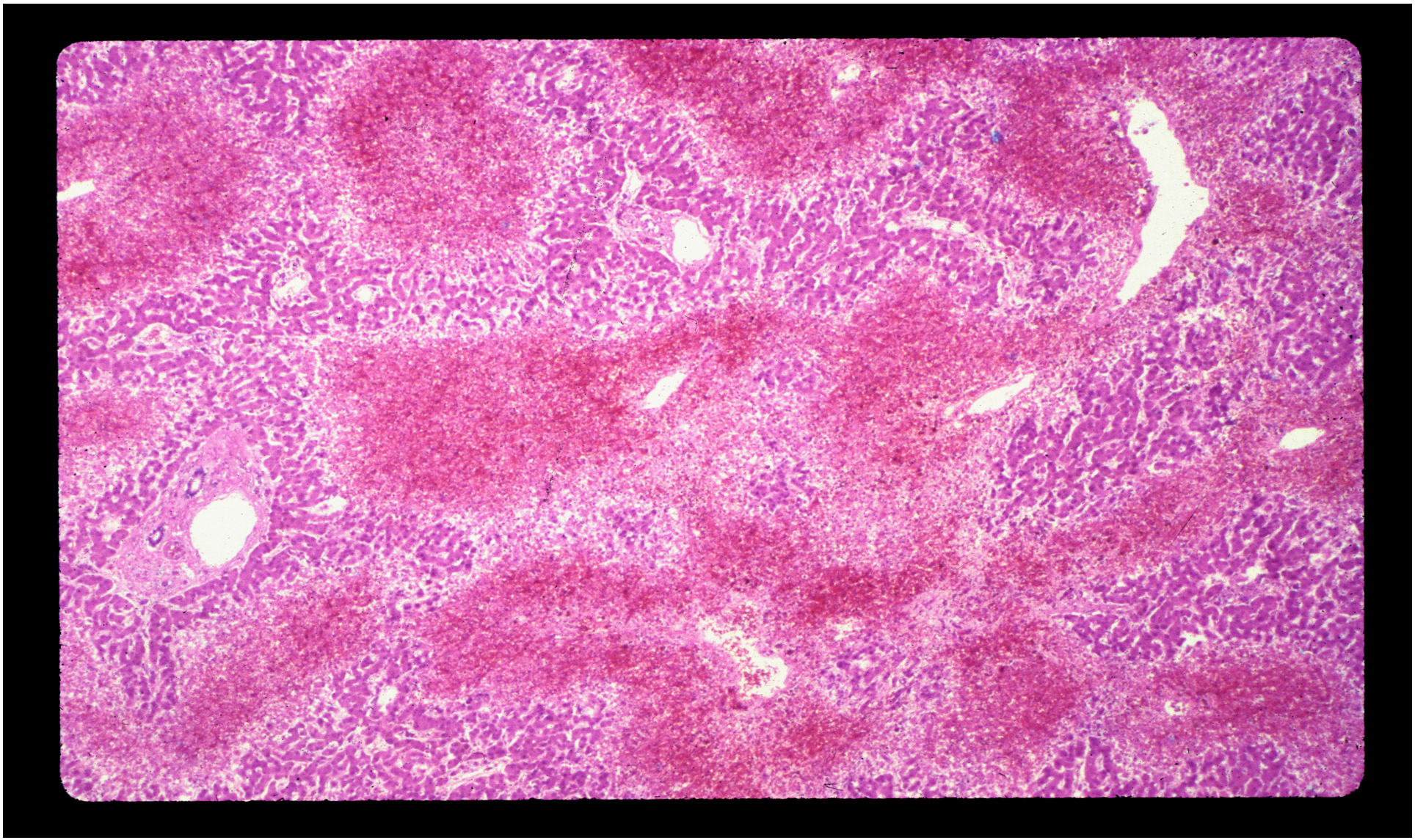

Liver
Cardiac Failure

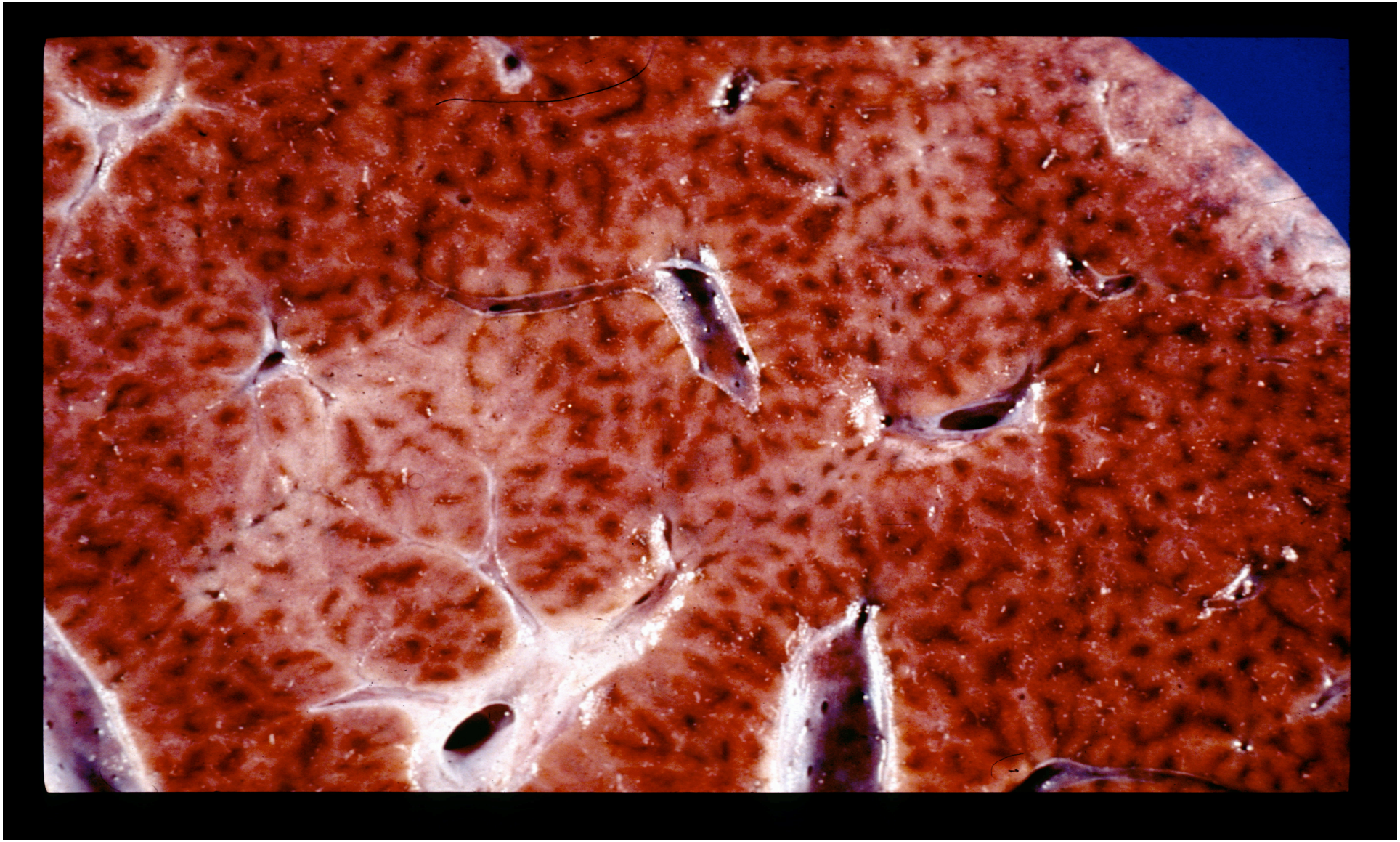

Nutmeg Liver

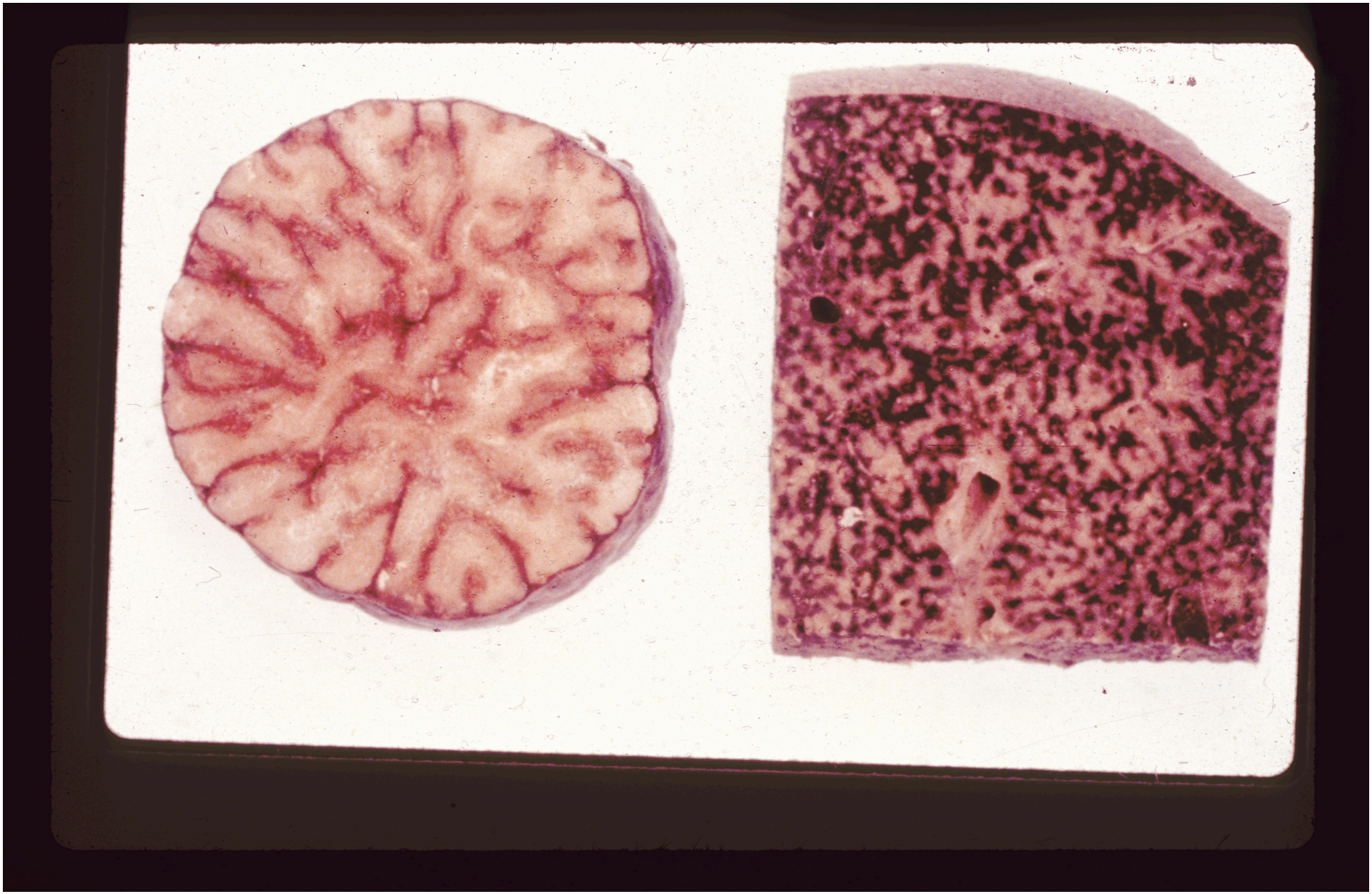

Esophageal Varices
Endoscopic View

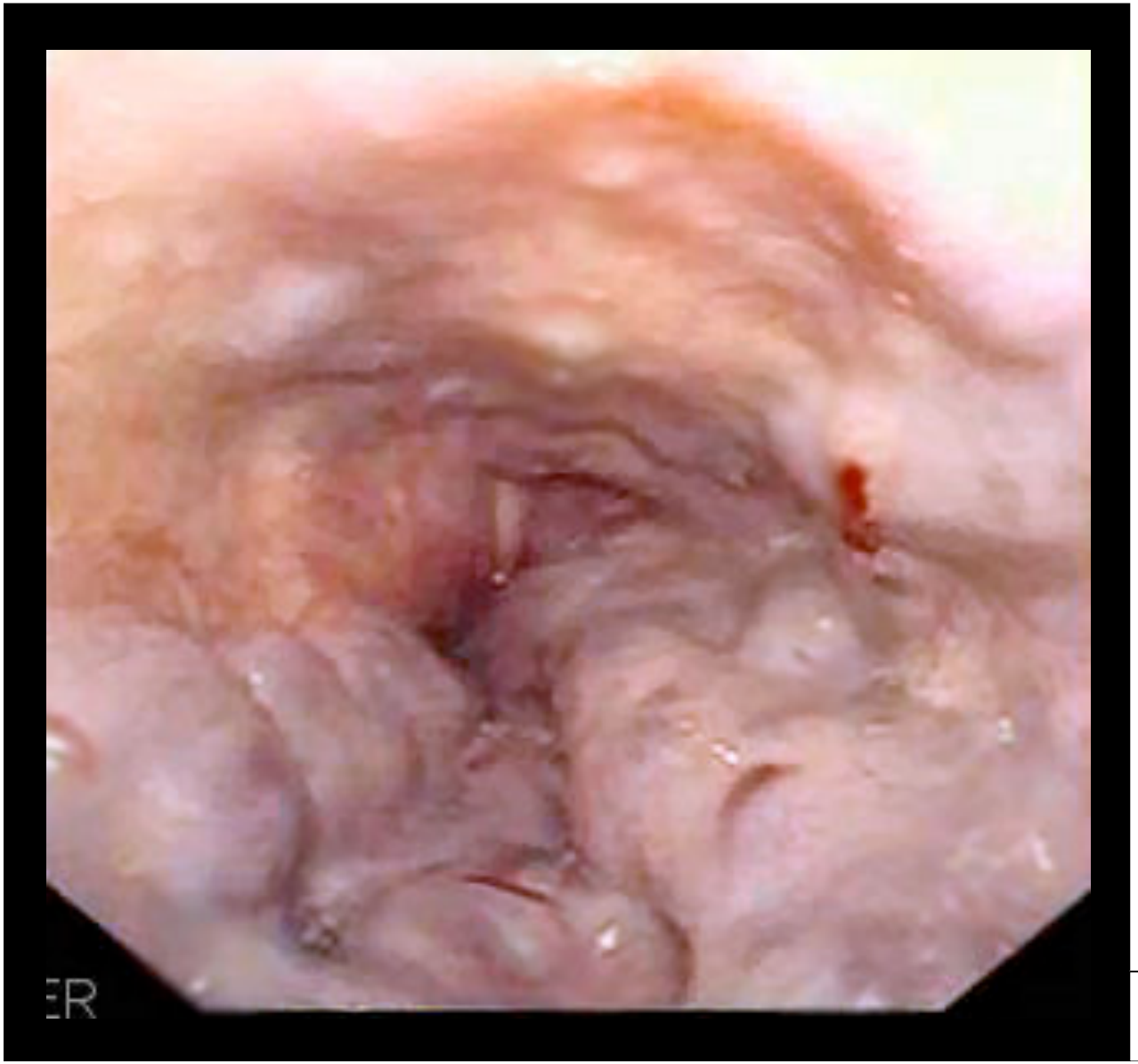

By: Samir (en.wikipedia.org)
http://www.gnu.org/licenses/fdl-1.2.html

Portal Circulation

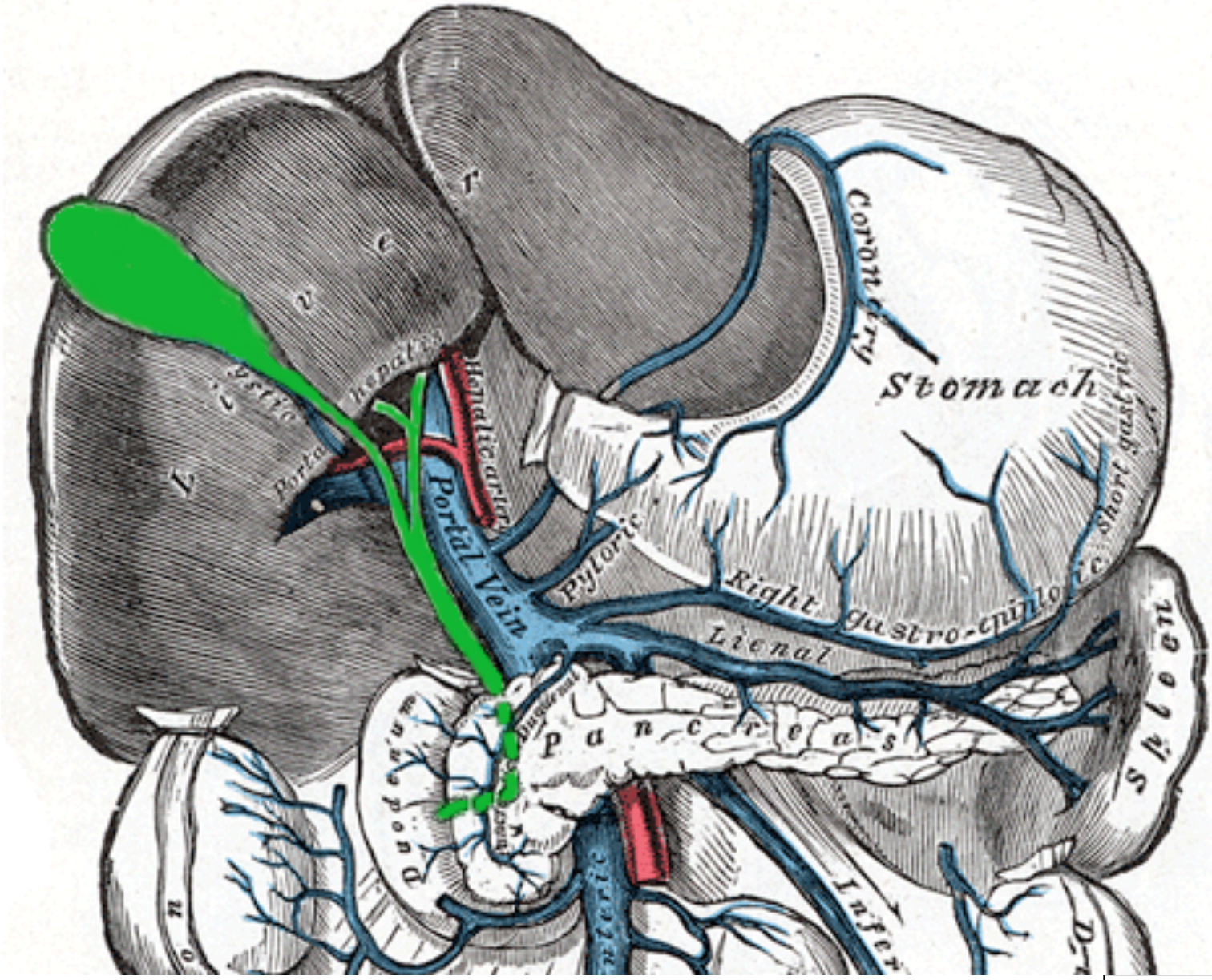

Source: Gray's Anatomy (wikimedia.org)

Liver - Cirrhosis

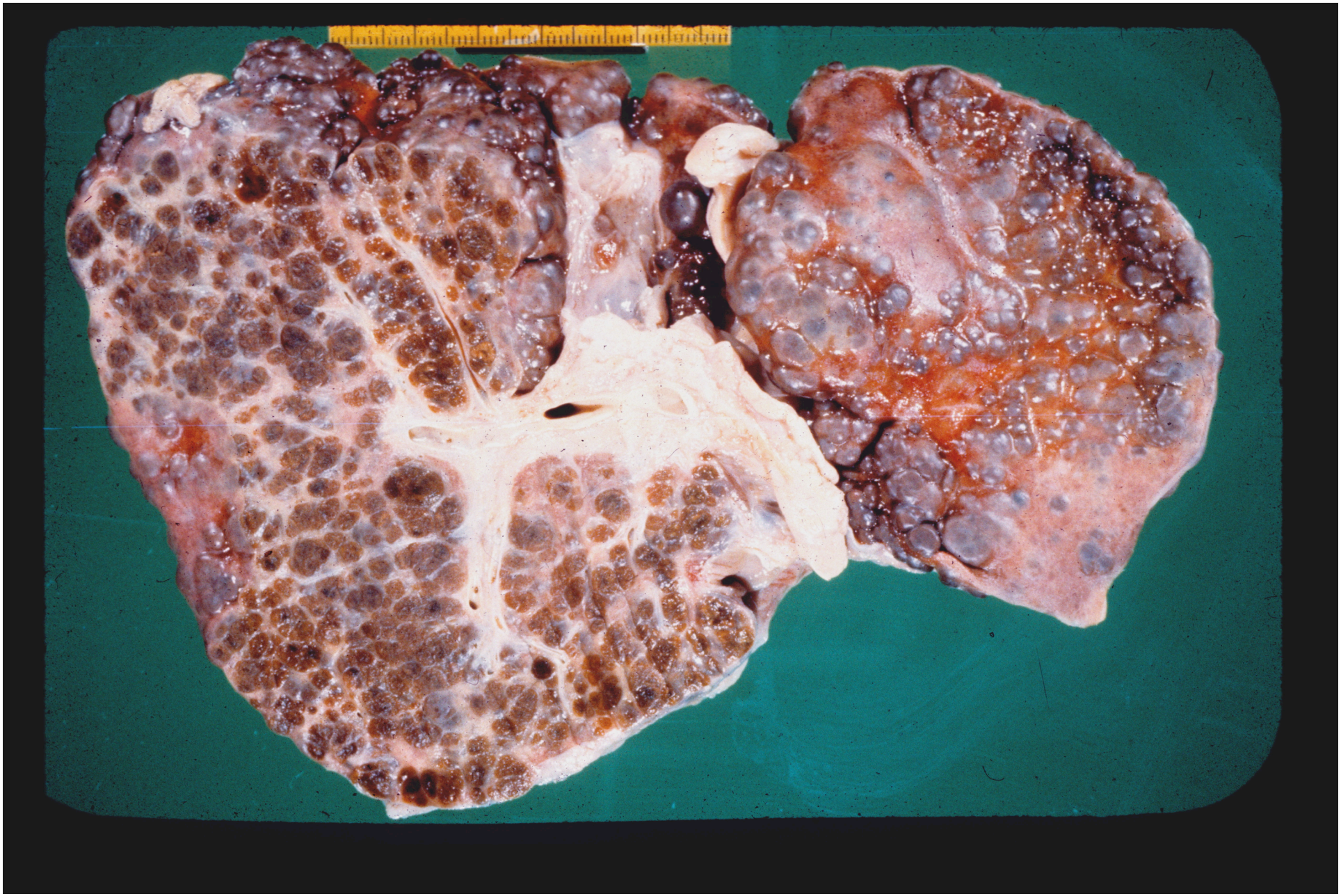

Esophageal Varices

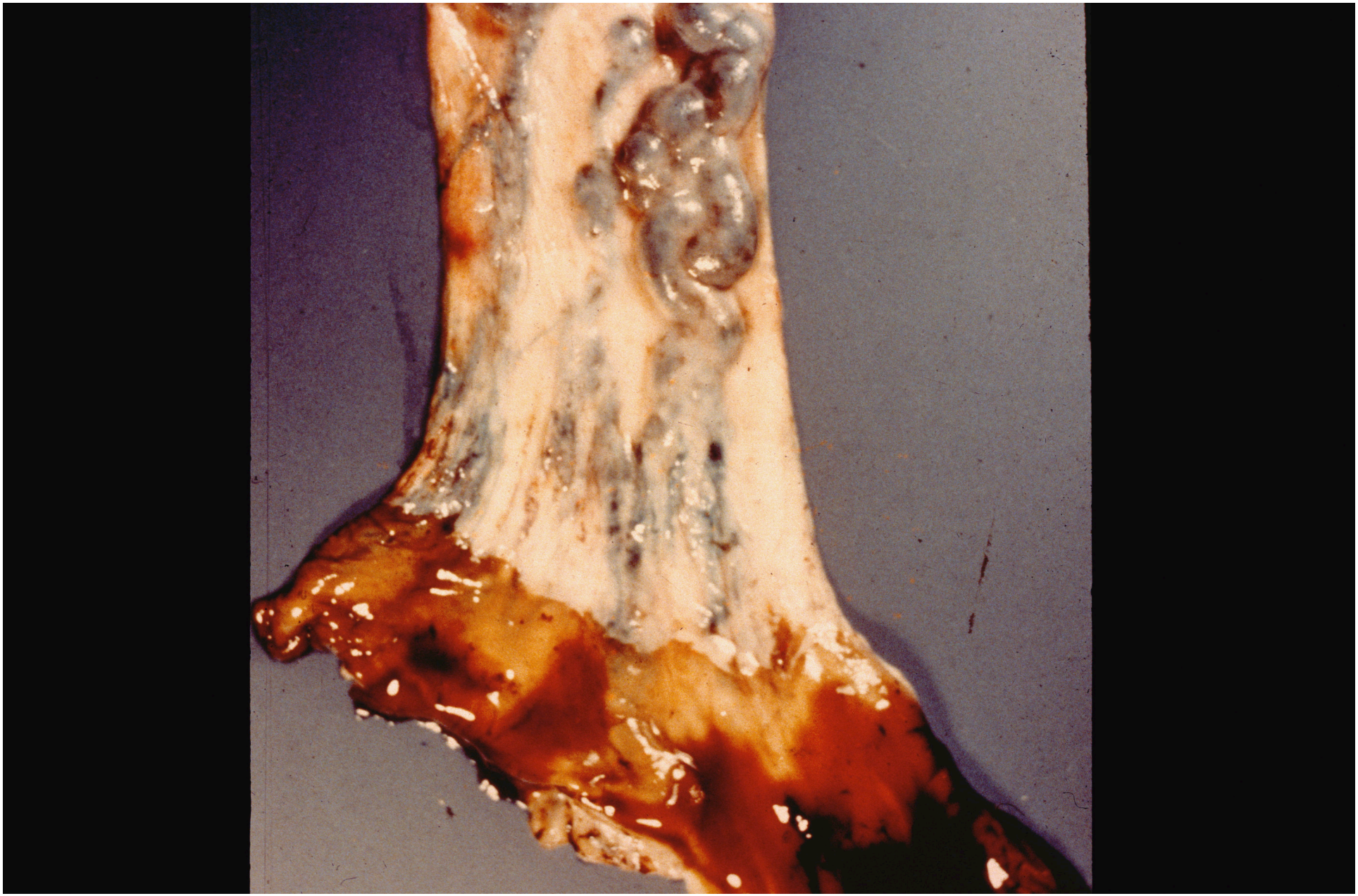

Esophageal Varices

EDEMA

Accumulation of excess fluid in the interstitial spaces / body cavities

Effusion

Fluid accumulation in a body cavity

- Pleural Effusion
- Pericardial Effusion
- Peritoneal Effusion = Ascites

Anasarca – Generalized edema,

a water-logged body


Image of capillary with acute inflammation removed

Fluid Collections

- Inflammatory collection = Exudate
- Non-inflammatory collection = Transudate

Edematous Connective Tissue

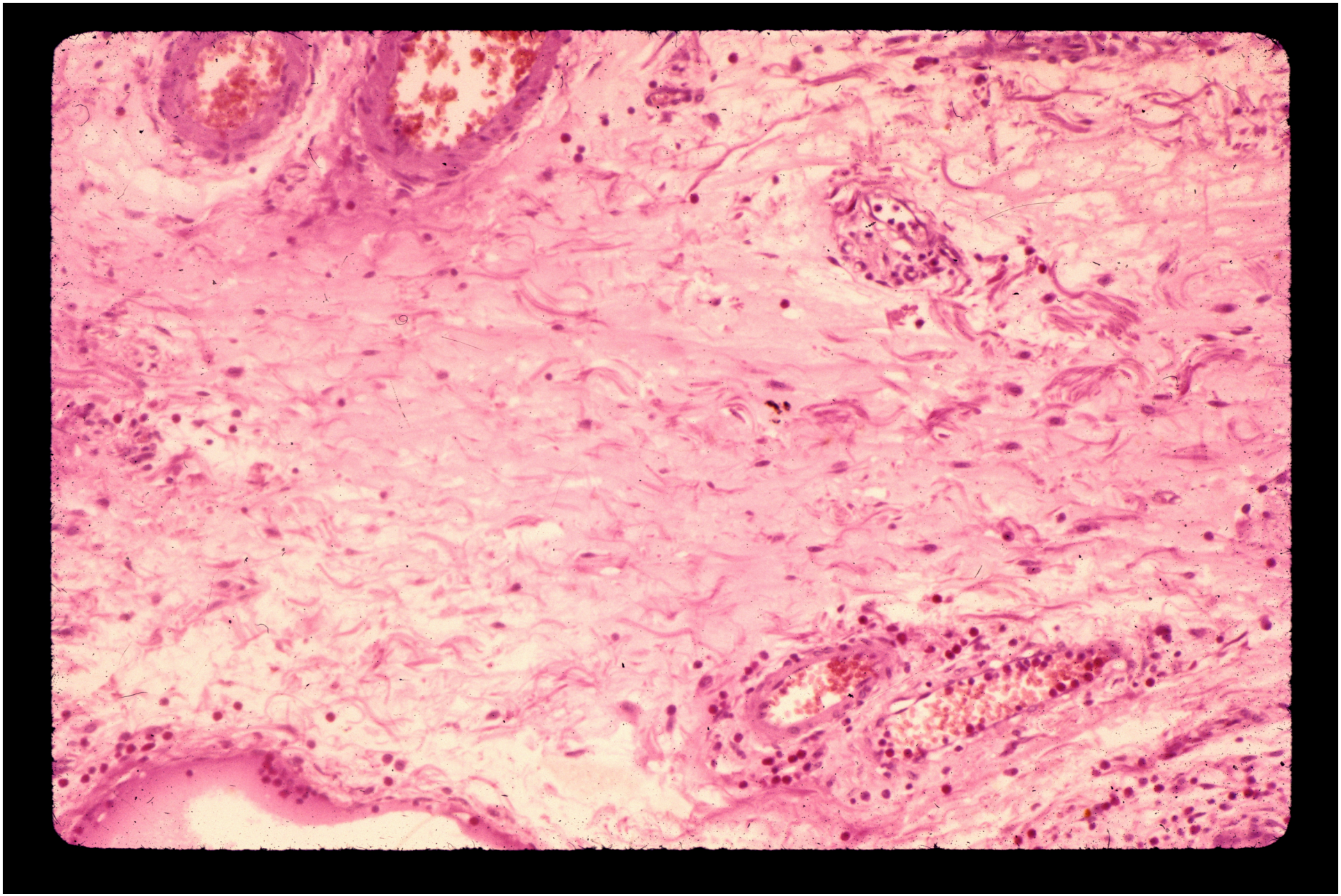

Peripheral Edema

BY: miss pupik (flickr)
http://creativecommons.org/licenses/by/2.0/deed.en

Pitting Edema (1)

Pitting Edema (2)

Pitting Edema (3)

Chronic Lymphedema

Source: Undetermined

Pulmonary Edema

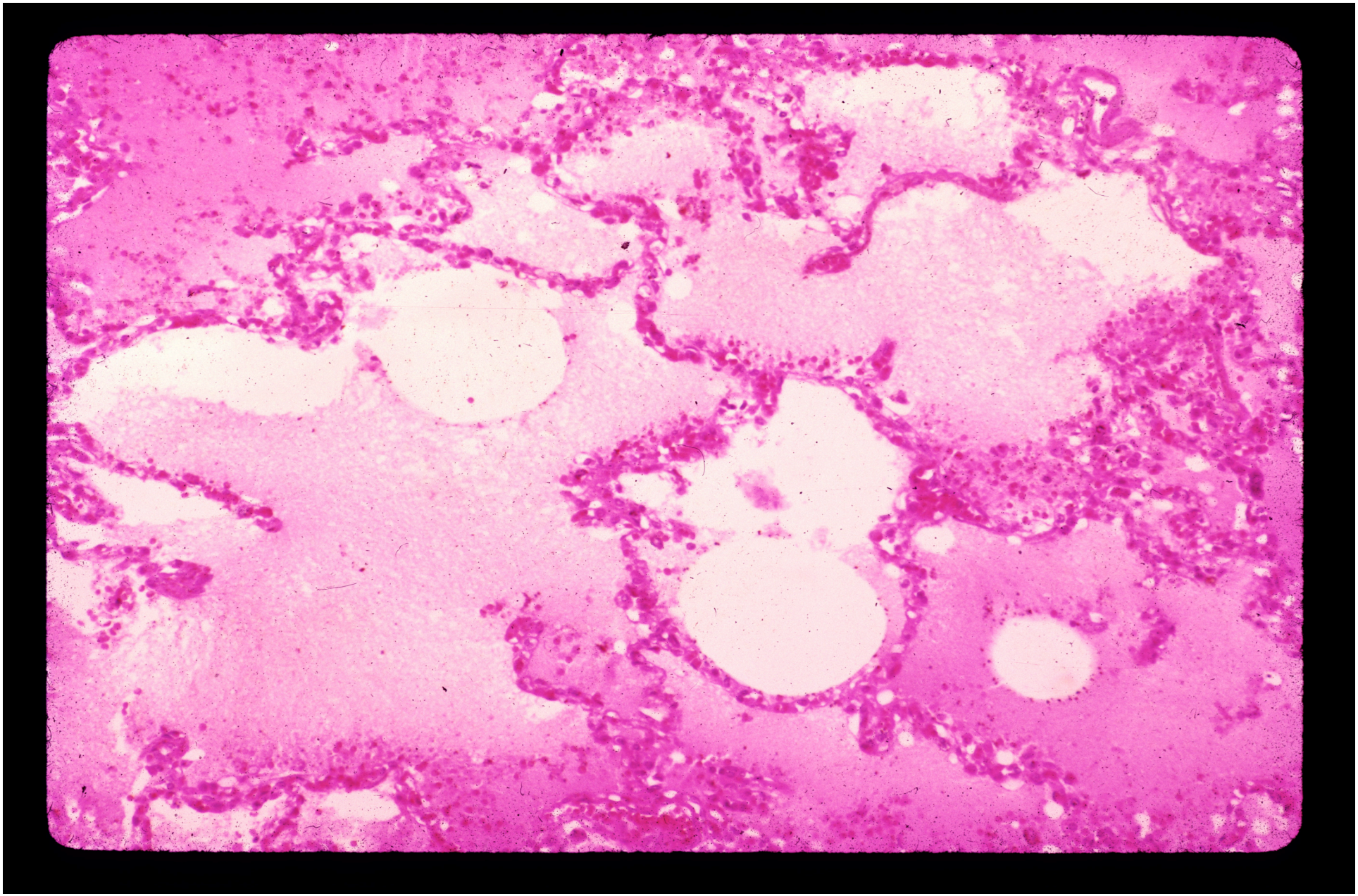

Pulmonary Edema

Source: Undetermined

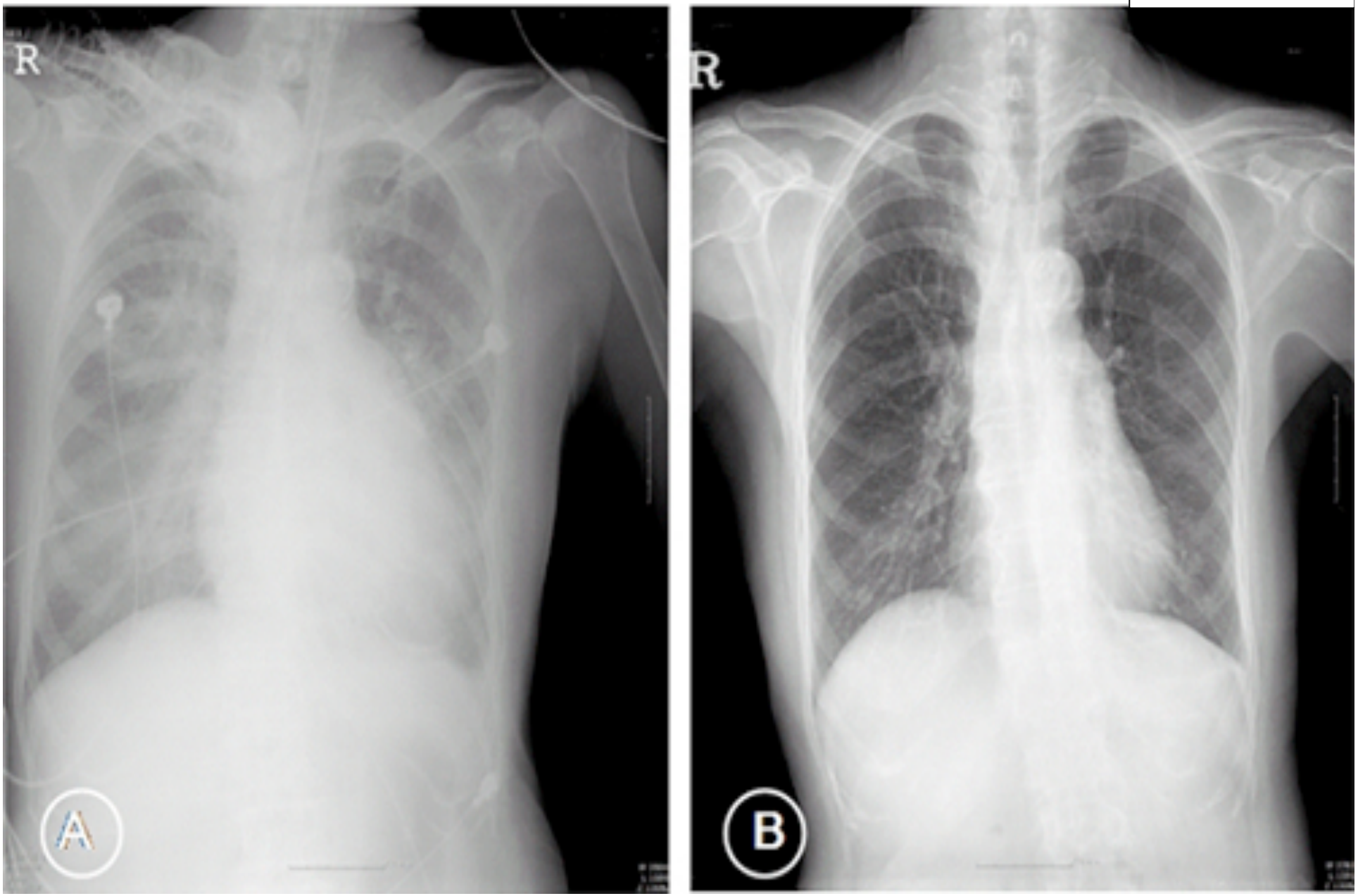

Pulmonary Edema

Source: Undetermined

Laryngeal Edema
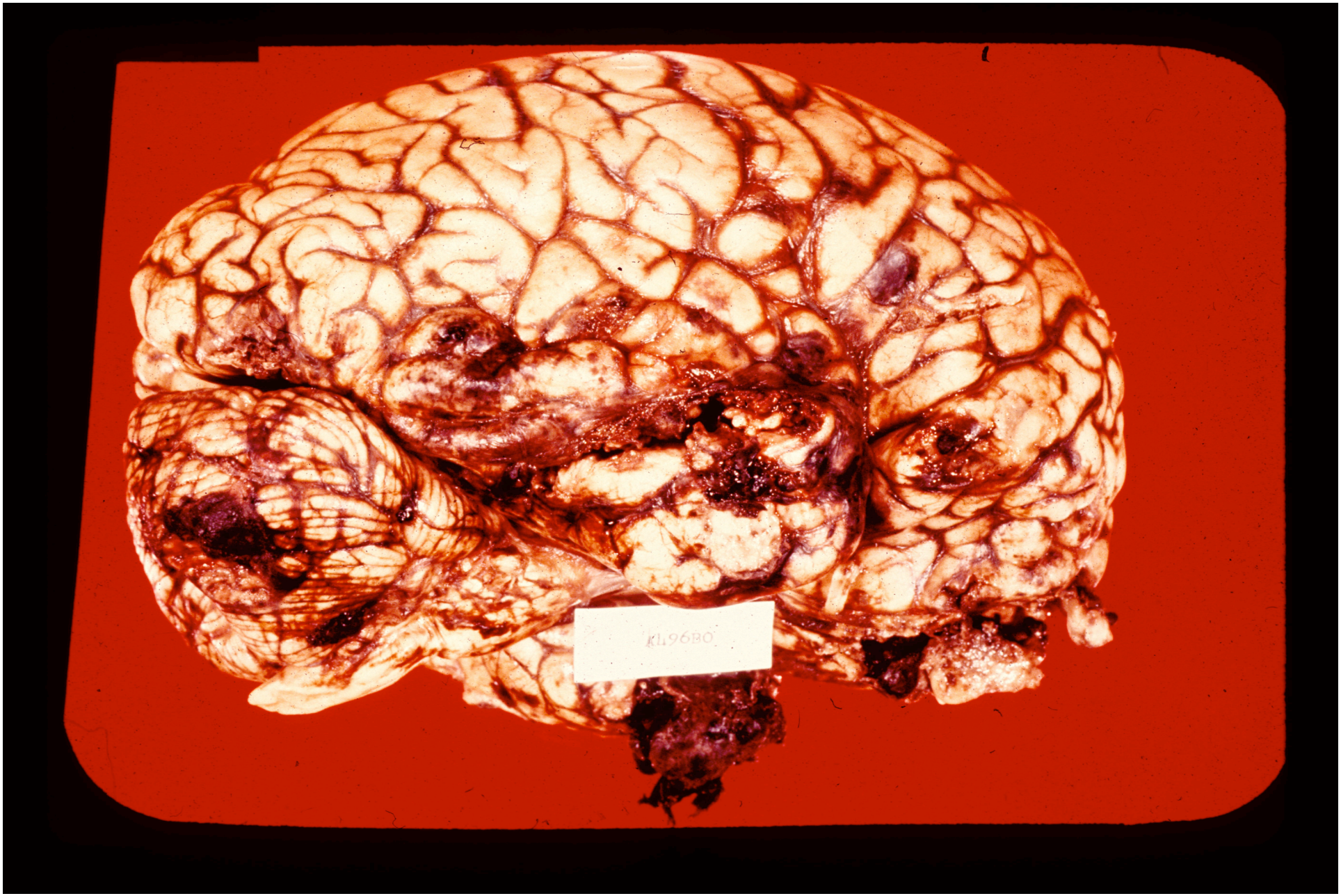
Cerebral Edema