

Therapeutic Plasmapheresis in Treatment of Patients with Waldenström's Macroglobulinemia

N. S. LAWSON, J. S. NOSANCHUK, H. A. OBERMAN AND M. C. MEYERS

From the Departments of Pathology and Internal Medicine (Simpson Memorial Institute), University of Michigan Medical Center, Ann Arbor, Michigan

The value of therapeutic plasmapheresis in effecting rapid lowering of serum globulins and viscosity in patients with Waldenström's macroglobulinemia has been reaffirmed. Three patients treated in this manner experienced biochemical improvement and two showed striking clinical improvement, manifested as cessation of bleeding and improvement in retinopathy.

AMONG the many complications suffered by patients with Waldenström's macroglobulinemia are those related to increased blood viscosity.¹⁶ These include vascular stasis, retinopathy, and a bleeding disorder due to acquired functional thrombopathy.⁴ The latter is considered due to coating of platelets by macroglobulin, rendering them incapable of participating normally in the coagulation process.¹¹ Plasmapheresis, a procedure well within the capability of the medium-sized laboratory, can reduce viscosity rapidly by lowering serum macroglobulin levels and, as a result, alleviate related symptoms. The three patients reported below exemplify the usefulness of this form of treatment.

Materials and Methods

Protein studies

Immunoelectrophoresis of serum was performed on agar gel-coated glass microscope slides using horse or goat polyvalent anti-human serum. Photographic prints were made using the glass slide with the precipitin bands as a negative. By noting density and width of the immunoglobulin arcs, rough semiquantitative estimates of these proteins were made.

Total proteins were determined by the biuret reactions, as adapted to the AutoAnalyzer. Routine serum electrophoresis was performed on cellulose acetate strips, buffered with barbital

Presented in part at the annual meeting of The American Society of Clinical Pathologists, Chicago, Illinois, September 26, 1967.

Received for publication January 12, 1968; accepted March 18, 1968.

at pH 8.6 to 1.5 milliamperes per strip for 60 minutes.

Quantitative radial immunodiffusion of serum was performed using commercially obtained agar containing anti-IgG, anti-IgA, and anti-IgM.* In the presence of the corresponding antigen the diameter of the resulting circular precipitin band is a logarithmic function of antigen concentration.⁹ Our laboratory's normal values (mg per 100 ml) are: IgG, 550-1,500; IgA, 70-400; and IgM, 40-200.

Plasmapheresis

Plasmapheresis as employed at the University of Michigan Medical Center previously has been described.¹³ A unit of blood is removed from the patient, centrifuged, and the packed cells and plasma are separated. The packed cells are returned to the patient and the plasma is discarded. This is repeated until approximately 500 to 600 ml of plasma are removed; the process requires 60 to 90 minutes. In anemic patients more plasma may be removed from each unit of whole blood due to the patient's reduced packed cell volume.

Case Reports

Case 1: A 39-year-old white male attorney (UMMC #072187), on whom a diagnosis of hemolytic anemia had been made three months previously, failed to improve on adrenocorticosteroid therapy.

On admission he complained of weakness, fatigue, and exertional dyspnea of approximately four months' duration. He had Cushingoid facies and retinopathy with exudates, splinter hemorrhages and dilated sausage-shaped veins. Sternal tenderness, hepatosplenomegaly, and lower extremity ecchymoses were present.

Pertinent laboratory values were: hemoglobin, 5.5 per 100 ml; Hct, 19%; RBC, 1.7 million per cu mm; platelets, 79,000 per cu mm; reticulocytes, 4.1%; WBC, 4,370 per cu mm (49% neutrophils, 39% lymphocytes). Erythrocytes on peripheral blood smear manifested polychromasia, anisocytosis and rouleaux. Serum uric acid was 9.3 mg per 100 ml, and total cholesterol was 76 mg per 100 ml. Total serum protein was 10.3 g per 100 ml and analysis of serum electrophoresis showed 27% albumin, 2% α_1 globulin, 6% α_2 globulin, 6% β glob-

* Hyland Laboratories, Los Angeles, California.

TABLE 1. (Patient 1). Effect on Serum Proteins (g %) of Plasmapheresis of 6,000 ml in Fifteen Days

	Before	After
Total protein	10.6	8.9
Albumin	2.7	2.8
Globulins		
α_1	0.11	0.20
α_2	0.73	0.69
β	0.81	0.80
γ	6.2	4.4

ulin, and 59% γ globulin, with a tall, narrow-based monoclonal spike in the gamma zone. A wide, prominent IgM arc was identified on immunoelectrophoresis. Total IgM was greater than 500 mg per 100 ml, IgG was 1,100 mg per 100 ml, and IgA was 115 mg per 100 ml. A Sia water test was positive. Nonspecific agglutinins were present in his serum at room temperature and in the cold. Bone marrow examination revealed erythrocytic hyperplasia. Approximately 25% of the bone marrow cell population was lymphoid.

Treatment with hydrocortisone, 200 mg daily, was begun the day after admission, but three weeks later the hematocrit was virtually unchanged. Multiple transfusions of packed cells were given. Splenectomy was performed on the twenty-sixth hospital day, and hydrocortisone was reduced to 80 mg daily. The patient was discharged on the forty-ninth day with a hematocrit of 33%.

He was treated as an outpatient with chlorambucil and hydrocortisone for the following 16 months during which period his hematocrit was about 40% and his reticulocytes were normal.

He complained of easy fatigue at his second hospital admission. Except for slight pretibial edema, physical examination was unremarkable. Neither retinopathy nor hepatomegaly was present. Pertinent laboratory values included Hct, 23%; WBC, 5,750 per cu mm; platelets, 10,000 per cu mm; and hemoglobin, 7.8 g per 100 ml. Poikilocytosis, anisocytosis, and rouleaux again were present in the peripheral blood smear. His total serum protein was 9.2 g per 100 ml with 40% γ globulin, largely monoclonal. IgM concentration was greater than 500 mg per 100 ml, IgG was 1,100 mg per 100 ml, and IgA was 115 mg per 100 ml.

Treatment with cyclophosphamide, 150 mg per day, instituted two weeks before his final admission, was continued, as was hydrocortisone. He had repeated episodes of epistaxis, requiring approximately two transfusions per week to maintain his hematocrit in the range of 35%. Phenylalanine mustard in an average dose of 3 mg per day, was substituted for cyclophosphamide on the twenty-ninth hospital day. Gross hematuria occurred on the fifty-fifth day.

During the following 15 days, 18 units of plasma (approximately 6,000 ml) were removed, resulting in a decrease in total serum proteins and γ globulins (Table 1), as well as lowering of the serum viscosity, relative to water, from 11.5 units to 3.5

units (Fig. 1). The serum albumin level remained constant.

Anemia and thrombocytopenia persisted. Repeat bone marrow examination revealed nearly complete replacement by lymphocytes and plasma cells. He was discharged on the seventy-fourth hospital day. He died suddenly at home ten days later. Autopsy was not performed.

Case 2: (UMMC #1027738). A 56-year-old white woman first noted blurred vision and epistaxis and, when seen six months later, appeared to be in good health but had pronounced dilatation and segmentation of retinal veins associated with flame hemorrhages and waxy exudates. Her vision was 20/20 O.D. and 20/40 O.S. Hepatosplenomegaly was present. Pertinent laboratory studies included: hemoglobin, 8.4 g per 100 ml; Hct, 24%; white blood count, 4,800 per cu ml (65% neutrophils, 29% lymphocytes); normal platelet count; rouleaux formation observed in peripheral blood smears. Her total serum protein was 10.4 g per 100 ml, and analysis of serum electrophoresis revealed albumin, 34.7%; α_1 globulin, 1.5%; α_2 globulin, 5.8%; β globulin, 7.1%; and γ globulin, 50.8%, the latter appearing as a tall, narrow-based spike. The bone marrow was hypoplastic with decreased normoblastic erythropoiesis. Twenty per cent of the marrow cells were lymphocytic with some plasmacytoid features.

Additional studies demonstrated spontaneous gelling of her plasma, positive Sia water and cryoglobulin tests, and cold agglutinins in the serum. The serum uric acid was 7 mg per 100 ml. The RISA ¹³¹I plasma volume was estimated at 5,700 ml. Her serum viscosity was 8.5 units. The abnormal globulin was identified as IgM by immunoelectrophoresis. Immunodiffusion revealed IgM concentration at 630 mg per 100 ml; IgG, 1,500 mg per 100 ml; and IgA, 200 mg per 100 ml. Because of the patient's retinopathy plasmapheresis was instituted. After removal of four units of plasma, her total serum protein had fallen to 8.5 g% (albumin, 38.8%; α_1 globulin, 1.6%; α_2 globulin, 7.2%; β globulin, 9.1%; and γ globulin 43%). There was objective and subjective ophthalmological improvement.

Cyclophosphamide therapy was begun with an initial dose of 150 mg daily. Subsequently the dose was varied from 75 to 150 mg per day, depending

TABLE 2. (Patient 3). Effect on Serum Proteins (g %) of Plasmapheresis of 4,000 ml in Seven Days

	Before	After	12 Days Post-cessation
Total protein	11.8	8.1	11.5
Albumin	4.0	3.1	4.0
Globulins			
α_1	0.23	0.28	0.21
α_2	0.66	0.73	0.72
β	0.86	0.73	1.1
γ	6.1	3.3	5.5

SERUM RELATIVE VISCOSITY
DURING PERIOD OF PLASMAPHERESIS

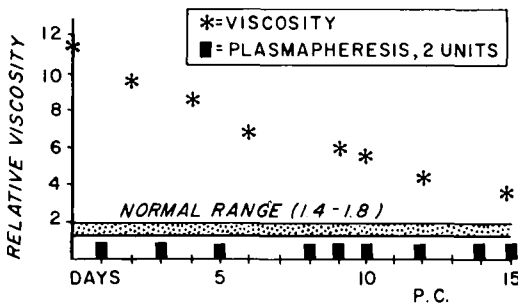


FIG. 1. (Patient 1). Reduction in serum viscosity during plasmapheresis.

on her white blood count. She noted further improved vision in her left eye one month later, her spleen no longer was palpable, the hemoglobin had risen to 9.6 g per 100 ml, and there was marked decrease in rouleaux formation seen on the peripheral blood film. The total protein was still 8.4 g per 100 ml with 50.6% albumin and 27.7% γ globulin.

Three months later, her serum viscosity was three units and IgM was 400 mg/100 ml. On her most recent clinic visit over a year later, the patient was asymptomatic, the liver and spleen could not be felt, and her eye grounds revealed slightly tortuous veins, pinpoint white exudates, but no new hemorrhages.

Case 3: (UMMC #1057362). A 55-year-old white woman complained of blurred vision, easy bruisability, and epistaxis. Two months before admission, she had been hospitalized elsewhere for upper gastro-intestinal bleeding and received four units of whole blood, and one month before admission she presented at another hospital with ophthalmopathy, monoclonal gammopathy, and markedly elevated IgM levels.

Her blood pressure at the time of admission was 140/90 mm Hg, her neck veins were distended, and a few cutaneous petechiae were present. Bilateral retinal hemorrhages, venous segmentation, and tortuosity were seen on funduscopy. There was no lymphadenopathy, but hepatosplenomegaly was present.

Pertinent initial laboratory data included hemoglobin, 8.5 g per 100 ml; Hct, 27%; white blood cell count, 10,600 per cu ml (55% lymphocytes); normal platelet count; prominent rouleaux; and positive cryoglobulin and Sia water tests. Her total serum protein concentration was 11.4 gm per 100 ml (albumin, 33.6%; α_1 globulin, 2.0%; α_2 globulin, 5.6%; β globulin, 7.5%; and γ globulin, 51.4%). The elevated γ globulin was manifest as a tall narrow-based monoclonal spike on electrophoretogram, and was identified as IgM by immunoelectrophoresis. IgM was greater than 7,000 mg per 100 ml, IgG was 300 mg per 100 ml, and IgA was less than 66 mg per 100 ml. Bone

marrow contained approximately 60% lymphocytes.

Plasmapheresis was instituted shortly after admission, two units of plasma (600 cc) being removed daily. After removal of approximately 4,000 ml of plasma in seven days the patient's vision was improved, and there was clearing of retinal hemorrhages and decreased tortuosity of retinal veins. At this time total serum protein was reduced to 8.6 gm per 100 ml with 44% albumin and 37.3% γ globulins (Table 2). IgM was 4,400 mg per 100 ml, IgG was 485 mg per 100 ml, and IgA was less than 10 mg per 100 ml. Cyclophosphamide, 100 mg daily, was instituted five days after admission. Two weeks later she was discharged and the cyclophosphamide dose was increased to 150 mg per day.

The patient was re-admitted one month later at which time 12 units (approximately 4,000 ml) of plasma were removed by plasmapheresis in a seven day period. She subsequently did well on cyclophosphamide, 100-150 mg per day, for three months when she developed a spontaneous right pneumothorax for which she required a brief hospitalization. At subsequent monthly clinic visits neither hepatosplenomegaly nor abnormal bleeding have been noted. Retinal scars persist, but no new retinal lesions have been noted.

Discussion

Plasmapheresis was described as early as 1914, when Abel *et al.*¹ showed that experimental animals could tolerate chronic removal of plasma if the removed red cells were returned to the animal. Plasmapheresis of human donors is now used by many blood banks to obtain relatively large amounts of plasma, plasma protein components, and platelets. Use of plastic collection units with transfer packs obviates the need to enter the donated unit when separating plasma from cells, and thereby virtually eliminates the risk of contamination of the blood. Chronic plasmapheresis of 1,000 ml of plasma per week should not result in protein depletion in normal human donors.¹⁴ In contrast, removal of greater volumes of plasma per week results in reduction of serum proteins.⁸ The latter is the rationale for this form of treatment in patients with Waldenström's macroglobulinemia.

Simple and effective, plasmapheresis for the purpose of decreasing pathologically elevated serum globulins and associated hyperviscosity has been the subject of several reports.^{5, 7, 10, 12, 15-17} Adams *et al.*,² in

1952, reported use of therapeutic plasmapheresis in a patient with multiple myeloma. Removal of 16 liters of plasma in 35 days resulted in transient depression of the plasma paraprotein level. Hyperviscosity syndrome can occur in patients with multiple myeloma as well as in patients with cryoglobulinemia and other non-Waldenström macroglobulinemias.¹⁸ In two patients with hyperviscosity syndrome associated with multiple myeloma, treated by Smith and associates, vigorous plasmapheresis achieved rapid lowering of serum viscosity, cessation of mucous membrane bleeding, and improvement in vision.¹⁷

Schwab and Fahey, 1960,¹² reported decreased serum viscosity and macroglobulin levels, and both objective and subjective improvement in ophthalmopathy, in two patients with Waldenström's macroglobulinemia treated with prolonged plasmapheresis. Skoog *et al.*¹⁵ demonstrated that removal of one unit of plasma daily for 15 days from a patient with Waldenström's macroglobulinemia effected a significant drop in serum macroglobulin levels while concentration of other serum proteins remained relatively constant. Ten days after cessation of this treatment, IgM levels had returned nearly to those noted before treatment.

Bleeding tendencies in two patients with Waldenström's macroglobulinemia and one with multiple myeloma were treated by Godal and Borchgrevink⁷ by removing as little as 1,000-1,500 ml of plasma. This resulted in cessation of hemorrhage and shortening of bleeding times. A most significant study on this subject is that of Solomon and Fahey,¹⁶ who reported clinical improvement in eight of ten patients with macroglobulinemia treated with plasmapheresis at the National Institutes of Health (two of these patients had been reported previously).¹² Decreased cold intolerance, improvement in retinopathy, elevation of hematocrit, and cessation of bleeding were noted. In nearly all patients, plasmapheresis therapy produced a fall in serum vis-

cosity as well as in macroglobulin levels.

Objective decrease in retinopathy following plasmapheresis has also been described by Skoog and associates.¹⁵ Fundic changes, *i.e.*, vascular tortuosity and dilatation with or without thrombosis and hemorrhage are thought to be due to blood hyperviscosity and associated stagnation.¹⁸ Two of our patients manifested objective and subjective ocular improvement following plasmapheresis.

With the availability of serologic methods for semiquantitation of serum IgM, the laboratory diagnosis of Waldenström's macroglobulinemia no longer requires ultracentrifugal analysis of the serum.³ Thus, even the small or medium-sized hospital laboratory can characterize the pathologic globulin immunochemically without determining the molecular weight.

Therapeutic plasmapheresis is not completely innocuous, and should not be used indiscriminately. Of concern is the possible depletion of platelets and of normal immunoglobulins in patients undergoing intensive plasmapheresis. Kliman *et al.*⁸ showed that intensive plasmapheresis (five liters in five days) in normal donors resulted in a substantial decrease in serum albumin and globulin concentration. Moreover, the γ globulins were the last fractions to return to normal. Because patients with gammopathy due to multiple myeloma or Waldenström's macroglobulinemia have increased numbers of infections and an impaired antibody response,⁶ it is of interest that one of Godal and Borchgrevink's patients developed pneumonia following this treatment.⁷ However, Solomon and Fahey,¹⁶ did not report infection as a complication in their ten patients, nor was this noted in our patients.

Platelet depletion by plasmapheresis can be minimized by re-infusing the buffy coat into the patient, together with the erythrocytes. This may be accomplished by utilizing a "hard" spin during centrifugation. Kliman *et al.*⁸ demonstrated an approximate 30 to 60 per cent drop in platelet count in

normal subjects undergoing rapid massive plasmapheresis (5,000 ml in five days). In contrast, studies in our laboratory¹⁴ have failed to demonstrate any significant alteration in platelet levels of subjects donating 1,000 ml of plasma weekly for over two years. In the present report thrombocytopenia noted in the first patient, was considered to be due to the primary disease, as severe thrombocytopenia was present before, as well as after, plasmapheresis therapy.

Because of the possible complications associated with transient fluid depletion in chronically ill patients, we require that a physician constantly observe the patient during the period of therapeutic plasma removal. In order to minimize patient discomfort, usually no more than two units are removed daily, requiring approximately 60 to 90 minutes.

We consider the indications for therapeutic plasmapheresis to be clinical rather than biochemical. The relationship between clinical findings, serum IgM levels and viscosity varies between patients, as do individual tolerances to hyperviscosity.¹⁶ Plasmapheresis is recommended as acute therapy for patients manifesting complications due to hyperviscosity. In patients with intractable complications, it may be utilized on an intermittent basis, together with chemotherapy, as in patient three in this report.

References

1. Abel, J. J., L. G. Rowntree, and B. B. Turner: Plasma removal with return of corpuscles (plasmapheresis). *J. Pharmacol. Exper. Therap.* **5**: 625, 1914.
2. Adams, W. S., W. H. Blahd, and S. H. Bassett: A method of human plasmapheresis. *Proc. Soc. Exper. Biol. Med.* **80**: 377, 1952.
3. Alper, C. A., F. R. Rosen, and C. A. Janeway: The gamma globulins. II. Hypergamma-globulinemia. *New Eng. J. Med.* **275**: 591, 652, 1966.
4. Bowic, E. J., J. H. Thompson, Jr., and C. A. Owen, Jr.: The blood platelet (including a discussion of the qualitative platelet diseases). *Mayo Clin. Proc.* **40**: 625, 1965.
5. Conway, N., and J. M. Walker: Treatment of macroglobulinemia. *Brit. Med. J.* **2**: 1296, 1962.
6. Fahey, J. L., R. Scoggins, J. P. Utz, and C. F. Szwed: Infection, antibody response and gamma globulin components in multiple myeloma and macroglobulinemia. *Amer. J. Med.* **35**: 698, 1965.
7. Godal, H. C., and C. F. Borchgrevink: The effect of plasmapheresis on the hemostatic function in patients with macroglobulinemia Waldenström and multiple myeloma. *Scand. J. Clin. Lab. Invest.* **17** (suppl. 84): 133, 1965.
8. Kliman, A., P. P. Carbone, L. A. Gaydos, and E. J. Freireich: Effects of intensive plasmapheresis on normal blood donors. *Blood* **23**: 647, 1964.
9. Mancini, G., A. O. Carbonara, and J. F. Heremans: Immunochemical quantitation of antigens by single radial immunodiffusion. *Int. J. Immunochem.* **2**: 235, 1965.
10. Mokeeva, R. A., R. A. Rutberg, V. Y. Chernyak, A. R. Maller, N. D. Papush, Y. G. Soboleva, V. A. Rahkmaeva, and G. E. Khutishvili: Use of plasmapheresis in macroglobulinemic reticulosis (Waldenström's disease). *Fed. Proc. (trans. suppl.)* **25**: 153, 1966.
11. Pachter, M. R., S. A. Johnson, T. R. Neblett, and J. P. Truant: Bleeding, platelets and macroglobulinemia. *Amer. J. Clin. Path.* **31**: 467, 1959.
12. Schwab, P. J., and J. L. Fahey: Treatment of Waldenström's macroglobulinemia by plasmapheresis. *New Eng. J. Med.* **263**: 574, 1960.
13. Simson, L. R., D. L. Lien, and H. A. Oberman: Plasmapheresis, an innovation in procurement of blood components. *Mich. Med.* **65**: 111, 1966.
14. Simson, L. R., D. L. Lien, C. L. Warner, and H. A. Oberman: The long-term effects of repeated plasmapheresis. *Amer. J. Clin. Path.* **45**: 367, 1966.
15. Skoog, W. A., W. S. Adams, and J. W. Coburn: Metabolic balance study of plasmapheresis in a case of Waldenström's macroglobulinemia. *Blood* **19**: 425, 1962.
16. Solomon, A., and J. L. Fahey: Plasmapheresis therapy in macroglobulinemia. *Ann. Int. Med.* **58**: 789, 1963.
17. Smith, E., S. Kochwa, and L. R. Wasserman: Aggregation of IgG globulin *in vivo*. I. The hyperviscosity syndrome in multiple myeloma. *Amer. J. Med.* **39**: 35, 1965.
18. Spalter, H. F.: Abnormal serum proteins and retinal vein thrombosis. *Arch. Ophth.* **62**: 868, 1959.

Noel S. Lawson, M.D., Resident and Teaching Associate, Department of Pathology, University of Michigan Medical Center, Ann Arbor, Michigan.
Jerome S. Nosanchuk, M.D., Resident and Teaching Associate, Department of Pathology, University of Michigan Medical Center, Ann Arbor, Michigan.

Harold A. Oberman, M.D., Associate Professor of Pathology, University of Michigan Medical Center, Ann Arbor, Michigan.

Muriel C. Meyers, M.D., Professor of Internal Medicine and Associate Director, Simpson Memorial Institute, University of Michigan Medical Center, Ann Arbor, Michigan.