

Management of eyelid trauma

Christine C. Nelson, MD

Abstract

The management of eyelid trauma presents some frustrating challenges to the general ophthalmologist. Because each case is unique, adaptation of general principles is essential for optimal ophthalmic treatment. This review includes the essentials of approaches to the evaluation and treatment of eyelid margin and canalicular lacerations. Specific attention is directed towards avoidance of complications.

Key words: Canalicular laceration, eyelid laceration, trauma.

It is the nature of trauma to occur in a variety of ways and often in complex combinations. To approach the problems presented by trauma to the eyelid effectively, the ophthalmologist needs to have not only a thorough training in eyelid and orbital anatomy, but also a firm knowledge of general approaches to trauma repair that can be intelligently adapted to the needs of each situation. This review of the evaluation and treatment of eyelid trauma discusses the repair of superficial and deep eyelid lacerations and the repair of lacerations of the eyelid margin and canaliculus. Techniques to avoid complications are also presented.

Evaluation

General considerations

Before attempting the repair of eyelid trauma, thorough systemic and ocular evaluations must be performed and other significant trauma problems resolved. A complete dilated fundus examination

is mandatory, since major and minor eyelid trauma may be associated with various ocular problems, including microscopic hyphaema, angle recession, and retinal detachment.¹ The primary reason for attending to the globe before the lids is to avoid inadvertent pressure applied to the potentially ruptured globe and special care is required when opening the oedematous eyelids. Wide exposure of the globe to facilitate evaluation and repair is much easier to achieve while the eyelids are lacerated. The lids should be taut after the lid lacerations are repaired and subsequent oedema will allow only minimal lid function. In addition, opening surgically repaired lids to inspect the globe puts considerable tension on the lid wounds, which could cause secondary dehiscence.

History

An accurate history of the injury is always important, and the initial history is often the most untainted by claims for compensation. The components of the history are listed in Table 1. Essential questions include the time and nature of the injury or accident to help define the extent and type of injuries, whether others were involved, whether glasses (safety or other) were worn, and whether there is a possibility of foreign bodies such as contact lenses being involved. If chemicals are involved, the type and concentrations should be noted; immediate irrigation is critical. If the injury is from a dog bite, in rabies-endemic countries the dog must be examined and confined for 10 days. The condition of the eyes and eyelids before injury should be documented by previous photographs, such as a driver's licence, and the patient's past medical history should be ascertained, including tetanus immunisation, suitability for anaesthesia, current medications and allergies.

While eyelid injuries can be classified as *blunt* or *penetrating*, many will have both characteristics.

From the Department of Ophthalmology, W. K. Kellogg Eye Center, University of Michigan, Ann Arbor, Michigan, USA.

Reprint requests: Dr C. C. Nelson, Kellogg Eye Center, University of Michigan, 1000 Wall Street, Ann Arbor, Michigan, 48105, USA.

Table 1. Components of evaluation and history

Time and nature of injury
Chemicals or foreign bodies
Previous visual acuity and lid function
Old photographs (driver's licence)
Safety glasses or contact lenses worn
Medical history: including tetanus immunisation

Blunt trauma may cause tissue oedema and ecchymosis as well as stretching or disruption of tissues such as the levator muscle and canthal tendons. Penetrating trauma slices through structures creating a more direct injury.

If there is evidence of skin penetration, foreign bodies must be suspected. Some foreign bodies may be quite difficult to locate, particularly if they are not radio-opaque. Wooden, plastic and some glass foreign bodies will not show up on plain films or CT scans. However, MRI T-1 weighted imaging reliably demonstrates wooden foreign bodies.² MRI imaging must not be done in the presence of ferrous metallic foreign bodies. Grease gun or high energy fluid explosions can inject foreign material into the orbit without causing apparent entry sites and may cause tissue necrosis out of proportion to the apparent injury.³

Ocular examination

A detailed ocular examination should include visual acuity, intraocular pressures, pupil reactions, and ocular movements as well as inspection of the anterior segment and fundus. Photographs and/or sketches are useful in documenting clinical findings.

The lid trauma examination should include both nerve and muscle evaluation. Sensory nerve function can be distorted by injury and tissue swelling, but absolute numbness in the typical distribution of a periocular nerve (supraorbital, supratrochlear, infratrochlear, infraorbital, lacrimal or zygomaticofacial) should raise suspicions of nerve transection.⁴ Injury to the motor nerves, especially the seventh cranial nerve, must be evaluated, because the condition of these nerves will affect the overall health of the eye, especially the cornea.

The orbicularis oculi muscle is rarely so severely disrupted that eyelid closure is hampered, but postoperative ptosis can be anticipated if a lacerated levator muscle is not repaired. Eyelid swelling can mask good levator function, but the presence of a crease and some lid function despite swelling usually indicates an intact levator. The presence of

prolapsed fat is an important indicator that the levator may be damaged.

Injuries may avulse part or all of the eyelids, and massive blunt trauma combined with penetration of dirt particles can render tissue non-viable. Therefore, attention should be directed to how much viable tissue remains and the type of tissue affected; i.e., whether full-thickness or partial eyelid tissue or hairbearing tissue, such as eyelash or eyebrow. If large pieces of tissue or eyelids are missing, the injury site should be searched for fragments of tissue that could be used as a free graft. Lacerations involving the lid margin or canaliculus should receive special attention. Assessment of the lid attachment to the orbital rim via the canthal tendons is important since the medial and lateral canthal angles are easier to position correctly at the time of the initial repair. Table 2 summarises the critical elements of the ocular examination.

Repair

General considerations

Treatment of eyelid lacerations follows certain basic rules. Ideally, eyelids should be repaired within 12 to 24 hours of the injury, and the *primary repair* of eyelid injuries can frequently reduce subsequent complications. *Debridement* of all foreign material is important to avoid infection, inflammation, and tattooing of the eyelid skin. This process should include continued copious irrigation with saline and removal of all the gravel, metal, chemical or glass particles. Rarely is it necessary to debride much lid tissue. Excellent blood supply in the eyelid area allows primary repair of dirty injuries, including animal and human bites. However, these wounds require meticulous irrigation and cleaning combined with prophylactic antibiotics.^{5,6} Damaged tissue may be viable even if replaced as a free graft, and emergency triage personnel should be made aware that avulsed material can be used in eyelid reconstruction.⁷

Before suturing, all wounds should be cleaned by irrigation and scraped with a scalpel blade to remove

Table 2. Components of examination

Complete eye and physical examination
Foreign bodies
Tissue loss: eyelash and eyebrow
Lid margin/canalicular laceration
Prolapsed fat/septal involvement
Levator function
Canthal tendon/angle integrity
Lagophthalmos

fibrin clot that may disrupt wound healing. Immaculate haemostasis and gentle handling of the skin edges help prevent infection and improve healing. The skin edges should be accurately apposed so that they have a tendency to eversion. In general, the finest suture that will adequately hold the tissue should be used. However, the type of suture material can be the surgeon's choice provided the sutures are removed at the appropriate time. Lid skin sutures should be removed after four to five days; periorbital skin and lid margin sutures should be removed after seven to 10 days. Lastly, it is important that the patient understand that the process of wound healing and scar maturation will take six to 12 months.

Simple non-margin lacerations

In order to have the narrowest scar, the wound and skin edges should lie well apposed and without tension. Undermining the skin deep to the dermis relieves tension and facilitates layered skin closure. Deep absorbable sutures may be required if the wound edges are not well apposed. The knots should be buried, and the suture placed partially in the dermis to close the subcutaneous tissue. Simple, interrupted sutures are usually adequate, but horizontal or vertical mattress sutures are occasionally needed if the wound is under tension. Subcuticular sutures are preferred to interrupted sutures for closure of a triangular flap tip to prevent necrosis. When repairing long ragged lacerations, certain key points should be approximated first, followed by repair of the remaining wound. One should not hesitate to remove any initial key sutures that seem misplaced later in the repair, especially when the injury is complex.

The skin suture needle enters perpendicular and, rather than making one curved motion for the entire passage, describes a right angle turn within the tissue to produce a slight eversion of the skin edges. Because the wound will naturally flatten as it matures, this mild 'bunching-up' of the deeper tissues will avoid a depressed scar or a lid margin notch.

The horizontal distance from the wound margin to suture entry must equal the vertical distance from the wound margin to the suture exit point, and this must be matched on the opposite side. The bites should be about 1 mm thick to include enough tissue to produce the desired slight eversion, but not so much that the skin edges gape apart.

Deep lacerations

The surgeon should be highly suspicious that a

foreign body may remain embedded within the orbit, even if the object appears to have been completely withdrawn from the point of entry. Therefore, if the history suggests, foreign bodies must be diligently sought by radiologic means prior to surgery and at the time of repair. Because vegetable foreign bodies may cause chronic abscesses, these should be cultured after removal. If the foreign object is thought to be inert or deep in the orbit, it may be left in place if attempts to remove it risk damaging vital ocular structures.

With deeper lacerations, prolapse of fat in the wound indicates disruption of the orbital septum and is a sign that the levator muscle may be damaged. However, the septum must not be closed or incorporated into deep or superficial sutures, both to avoid postoperative lagophthalmos and to lessen the effects of any postoperative haemorrhage.

If the levator is traumatically disinserted or transected, it should be repaired at the time of initial surgery. If ptosis is found postoperatively, six to 12 months should be allowed for spontaneous resolution or improvement to occur before undertaking repair of residual ptosis. The development of amblyopia must be considered in young children, particularly if damage to the levator leads to a prolonged ptosis.

Eyebrow lacerations

Frequently these present as multiple irregular wounds and flaps which must be carefully oriented correctly to avoid disfigurement. The eyebrow hair should not be shaved since the hair direction will help realignment and any potential loss of brow hair should be avoided.⁸ Retained eyebrow hair will often mask unevenness of the skin and small areas of hair loss.⁹ The eyebrow hair follicles are directed obliquely to the skin surface. Deep subcutaneous sutures should be accurately placed to avoid the ends of the hair follicle. Skin sutures in this area should be shallow to avoid strangulation of the follicle bulb.

Lid margin lacerations

Exact repair of the lid margin is critical to avoid notching or margin discontinuity which cause functional and cosmetic problems. The first step in lid margin repair is to identify the tarsus and the lid margin landmarks, such as the grey line, anterior lash line, and mucocutaneous junction. If the wound is ragged, freshening the edges with a scalpel blade may aid in structure recognition and apposition. However, minimal tissue should be

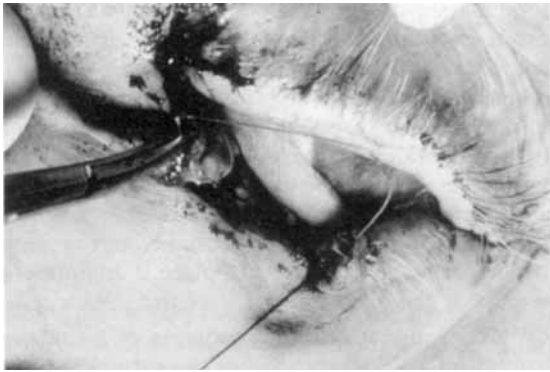


Fig. 1.—Lid margin laceration. A 5-0 Vicryl suture is passed vertically through the tarsus itself avoiding the conjunctiva and skin.

discarded, since dusky remnants frequently are revived after proper alignment and re-establishment of blood supply.

Using toothed forceps or skin hooks, the edges are brought together to allow assessment of the tension on the wound. If the wound is unduly tight, a lateral canthotomy with cantholysis may be needed; semicircular flaps are usually required only if a large portion of the lid is missing. It is important to choose the approach carefully because the horizontal canthotomy incision precludes the semicircular flap incision. More complex reconstructive techniques are rarely required.

A 5-0 Vicryl suture is passed in a circular vertical mattress fashion entirely within the tarsus of the cut edge on either side, burying the knot at the

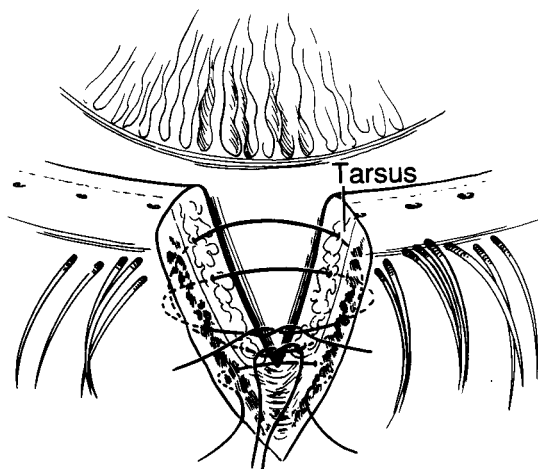


Fig. 2.—Lid margin laceration. An additional buried Vicryl suture supports the tarsus.

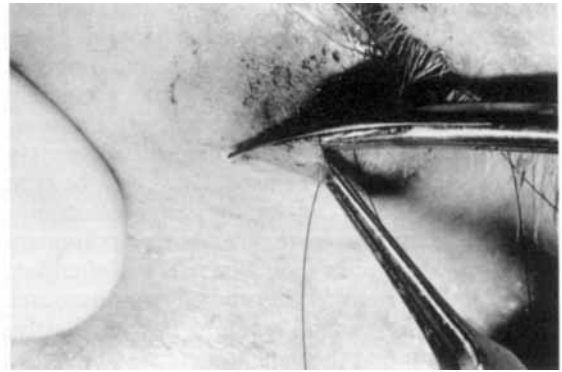


Fig. 3.—Lid margin laceration. The dog-ear is trimmed at an oblique cut off the axis of wound, followed by overlapping the tissue.

tarsal border (Figure 1). The suture can be either tied or left untied until the lid margin sutures are placed. Another buried horizontal 5-0 Vicryl suture is usually required in the lower lid at the inferior edge of the tarsus (Figure 2) and two additional tarsal sutures are used in the upper lid. These sutures support the wound and help to prevent a sag in the lid margin which may lead to a notch. Two or three 7-0 silk margin sutures are placed in the grey line, the anterior lash line, and the posterior mucocutaneous junction. The latter suture is optional; it may cause a keratitis if placed too posteriorly. (Absorbable suture material such as 7-0 chromic may be used for small children.) These sutures are tied after the tarsal Vicryl sutures are tied, and the lid margin suture ends are left long to be imbricated under a pretarsal skin silk suture.

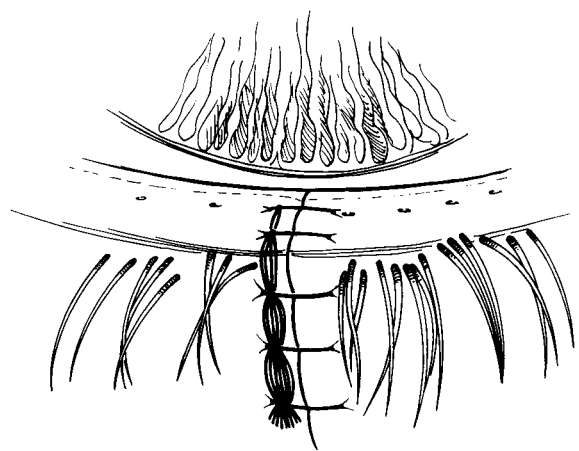


Fig. 4.—Lid margin laceration. Two 7-0 silk sutures are placed in the lid margin and the ends are tied into the already tied tarsal sutures.

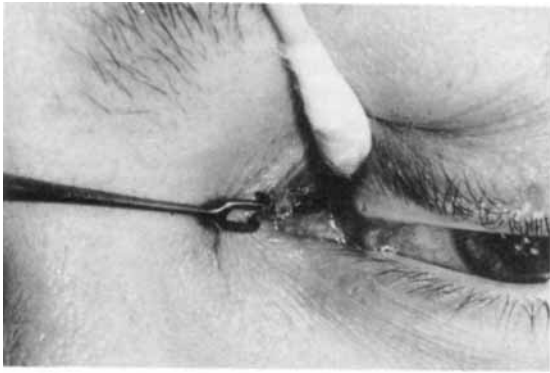

Fig. 5.—Canalicular laceration seen without magnification.

If present, the ‘dog-ear’ is excised by overlapping any excess tissue remaining and trimming along an oblique cut off the axis of the wound (Figure 3). The skin wound is then closed with interrupted silk sutures (Figure 4).

Canalicular lacerations

Disruption of the lacrimal drainage system, usually the canaliculus, is often encountered with medial eyelid trauma. Repair of the canaliculus is best accomplished at the time of the primary repair. Subsequent scarring may make future intubation impossible, and require placement of a Jones tube.

Once the wound is clean, the cut ends of the canaliculus usually may be located without additional magnification (Figure 5) or by gentle probing with a 0-00 Bowman probe in the emergency room (Figure 6). An operating microscope should be used if the ends are difficult to find

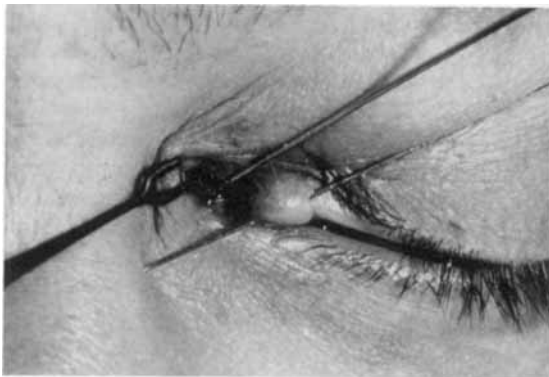


Fig. 6.—Canalicular laceration. 0-00 Bowman probe inserted into left upper punctum. Larger probe is inserted into distal cut end of canaliculus.

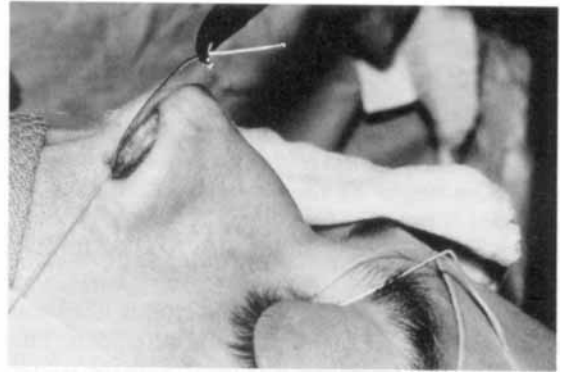


Fig. 7.—Retrieval of a Jackson tube from the nose after intubation of the lacrimal drainage system.

and for the repair of the canaliculus. An indwelling canalicular stent serves to align the cut ends and maintain the lumen during the healing phase. Various stents such as Viers rod or Johnson wire exist for monocular intubation.¹⁰ I prefer to repair a transected canaliculus using silastic tubing to intubate the upper and lower canaliculus (Figure 7). End-to-end anastomosis using 9-0 nylon sutures will bring the canaliculus into alignment. Stronger suture (5-0 absorbable) is placed into the muscle surrounding the canaliculus to relieve any tension on the nylon sutures. The ends of the silastic tubing in the nose are tied or attached to a small retinal band, taking care to adjust the tension to avoid subsequent punctal erosion (Figure 8). Facial or naso-ethmoid fractures may indicate injury of the lacrimal sac or nasolacrimal duct. A difference of opinion exists concerning the timing of the repair of these injuries.⁹

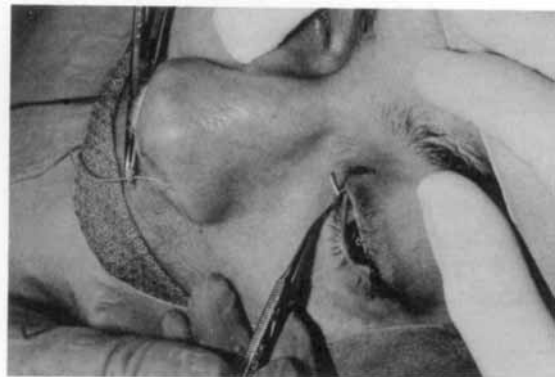

Fig. 8.—Carefully adjust the tension on the silastic tubing to avoid punctal erosion.

Canthal injuries

Because an injured canthus can be displaced in any combination of three directions, its location must be viewed in relation to the face and the other canthus, especially in unilateral injuries. The rounded configuration of the medial canthus and/or the acute angle of the lateral canthus can be distorted or lost. The integrity of the canthal tendon is tested by grasping the lid with toothed forceps and pulling toward the limbus.

Knowledge of the anatomic insertions is critical to reconstruction of an injured canthal tendon. The lateral canthal tendon inserts just inside the lateral orbital rim at the lateral orbital tubercle. The tendon should be sutured or wired at the tubercle so that it is 1 to 2 mm higher than the medial canthus and slightly higher than the contralateral lateral canthus.¹¹ Permanent large sutures (2-0 nylon) can be passed through drill holes to secure the tendon, thus avoiding future metallic wire disruption of radiologic studies such as CT scan or MRI.

The medial canthal tendon inserts onto both the anterior and posterior lacrimal crests. Severe disruption of the insertions typically indicates injury to the lacrimal sac or duct which will require intubation with silastic tubing. The posterior limb of the medial canthal tendon is primarily responsible for the medial canthal configuration; it must be repaired to avoid anterior displacement of the medial canthus postoperatively. If no fracture is present, the ruptured tendon can be sutured or wired (28 gauge) to the posterior lacrimal crest, taking special care not to injure the lacrimal sac. Any fracture must be stabilised, which may require insertion of a 26 to 30 gauge transnasal wire at the posterior lacrimal crest. The anterior head of the medial canthal tendon can be sutured directly to its anterior lacrimal crest insertion.¹²

Complications

Lid margin notching

This can be avoided by careful attention to lid margin alignment at the time of original repair. If small, spontaneous improvement often occurs. However, a large lid notch may need a full-thickness pentagonal resection and repair.

Lagophthalmos

Lagophthalmos from either unrecognised tissue loss, scarring or incorporation of the septum into the superficial wound is another common complication. Prevention is the key but, once the defect

is present, the skin shortage can be corrected by vertically lengthening the anterior lamella (skin and muscle). Similarly, lower lid ectropion can be caused by skin shortage or by vertical traction on the lid margin. For a minimal ectropion, upward massage of the skin with cocoa butter may avoid the need for surgical repair. If surgery is needed, Z-plasty and skin flap transpositions are often futile. Full thickness skin grafts combined with scar release and horizontal tightening of the eyelid margin are usually required.

Hypertrophic scars

These may improve spontaneously with time. Alternatively, they can be injected with steroid, using a Dermojet, within the first four to eight weeks after surgery.¹³

Infections

Infections rarely occur in the well-vascularised eyelids. Orbital abscess or fistula formation typically indicate an unrecognised foreign body, which must be removed before healing will occur.

Tearing

Tearing in trauma cases can have several aetiologies which need to be assessed individually. These may include lid malposition, poor lacrimal pump, or lacrimal drainage duct obstruction.

Traumatic ptosis

This may be of neurogenic origin from damage to the third cranial nerve due to associated orbital injury, or of myogenic origin due to damage to the levator muscle. Horizontal wounds, especially those with prolapsed orbital fat, are more likely to have injury to the levator muscle. If the patient is cooperative, the levator muscle tissue can be identified under local anaesthesia by having the patient look up and down, and thus repaired primarily. For the uncooperative patient or the child, general anaesthesia is required and the levator will be more difficult to identify. Postoperative residual ptosis should be followed for six to 12 months since some recovery often occurs. Traumatic ptosis should be repaired under local anaesthesia to facilitate identification of the levator muscle. There is an increased risk of overcorrection after repair of post-traumatic ptosis if good levator function is present.¹¹

References

1. Waller RR. Treatment of acute eyelid trauma to prevent late complications. *Trans Am Acad Ophthalmol Otolaryngol* 1976;81:OP556-559.

2. Green BF, Kraft SP, Carter KD, Buncic JR, Nerad JA, Armstrong D. Orbital Wood. Detection by magnetic resonance imaging. *Ophthalmology* 1990;95(5):608-611.
3. Wolter JR, Nelson CC. Lipogranuloma to foreign oil in eyelid after hydraulic injury. *Ophthalmic Plast Reconstr Surg* 1991 (In Press).
4. Aguilar GL, Nelson CC. Eyelid and anterior orbital anatomy. In: Hornblase A, ed. *Oculoplastic, orbital, and reconstructive surgery*. Baltimore: Williams & Wilkins, 1988;10-13.
5. Shannon GM. The treatment of dog bite injuries of the eyelid and adnexa. *Ophthal Surg* 1975;6:41-44.
6. Gonnering RS. Ocular adnexal injury and complications in orbital dog bites. *Ophthalmic Plast Reconstr Surg* 1987;3:231-235.
7. Spinelli HM, Sherman JE, *et al*. Human bites of the eyelid. *Plast Reconstr Surg* 1986;78:610-614.
8. Reeh MJ, Beyer CK. Mismanaged trauma. In: Soll DB, ed. *Management of complications in ophthalmic plastic surgery*. Birmingham: Aesculapius Publishing Company, 1976:78-92.
9. Mustarde JC. Repair and reconstruction in the orbital region. London: E & S Livingstone, 1966;226-237,238-253.
10. Zolli CL. Microsurgical repair of lacrimal canaliculus in medial canthal trauma. In: Hornblase A, ed. *Oculoplastic, orbital, and reconstructive surgery*. Baltimore: Williams & Wilkins, 1988;426-432.
11. Soll DB. Treatment of late traumatic eyelid problems. *Trans Am Acad Ophthalmol Otolaryngol* 1976;81:OP560-565.
12. Carroll RP. Management of eyelid trauma. In: Hornblase A, ed. *Oculoplastic orbital, and reconstructive surgery*. Baltimore: Williams & Wilkins, 1988;(1)45:409-414.
13. Wilkins RB, Kulwin DR. Wound healing. *Ophthalmology* 1979;86:507-510.