

Clinical reviews

Meckel's Diverticulum

D. Kim Turgeon, M.D., and Jeffrey L. Barnett, M.D.

Division of Gastroenterology, University of Michigan Medical Center, Ann Arbor, Michigan

Meckel's diverticulum is the most common congenital anomaly of the gastrointestinal tract, occurring in 1–3% of the population, based on autopsy studies (1) (Fig. 1). It was first described by Fabricius Hildanus in 1598 and was later named after Johann Friedrich Meckel, a German comparative anatomist, who first recognized its developmental origin in 1809 (2). It is a remnant of the omphalomesenteric duct which connects the primitive gut to the yolk sac in early fetal life. Normally, this structure is obliterated by the 7–8th wk of gestation when the placenta replaces the yolk sac as the source of nutrition for the fetus. Failure of obliteration may result in an omphalomesenteric fistula, an enterocyst, a fibrous band connecting the small intestine to the umbilicus, or a Meckel's diverticulum. Meckel's diverticula, with or without a fibrous connection to the umbilicus, account for 90% of all omphalomesenteric duct anomalies (Fig. 2).

Meckel's diverticulum is a true diverticulum because it arises from the antimesenteric border of the small bowel, and all layers of the intestinal wall are present (serosa, muscular layers, submucosa, and mucosa). It receives its blood supply through a remnant of the right vitelline artery originating from the superior mesenteric artery. The position of the diverticulum is highly variable and, although it has been reported as far proximal as the ligament of Treitz, it is usually found within 100 cm of the ileocecal valve (3). Diverticula are located somewhat closer to the ileocecal valve in children than in adults. The mean distance from the diverticulum to the ileocecal valve in one large study was 34 cm in children <2 yr old, 46 cm in those 3–21 yr old, and 67 cm in adults 21 yr and older (4). The average diverticulum is approximately 3 cm long (3, 5). Nearly 90% are 1–10 cm long, but record lengths of up to 100 cm have been reported (3, 6). Approximately 50% contain heterotopic mucosa, of which >60% contain gastric mucosa, 16% pancreatic acinar tissue, and the remainder Brunner's glands, pancreatic islets, colonic mucosa,

hepatobiliary tissue, or a combination of tissues (4). An increased incidence of Meckel's diverticulum is seen with congenital anomalies such as cleft palate, bicornuate uterus, and annular pancreas (7, 8). There may be an association between Meckel's diverticulum and inflammatory bowel disease. Two operative series found a 6–18% prevalence of Meckel's diverticulum in patients with Crohn's disease, compared with autopsy study prevalence rates of 1–3% (9, 10).

The incidental finding of this anomaly at laparotomy and the 1–3% incidence of this lesion in the general population based on autopsy studies are strong evidence for the usually asymptomatic nature of a Meckel's diverticulum. Meckel originally quoted a 25% complication rate, but a modern survey by Soltero and Bill (11) has identified a total lifetime complication rate of 4% which decreases to near zero with old age (11). Over 40% of those experiencing complications are under 10 yr old (4). Although Meckel's diverticulum occurs with equal frequency in both sexes, males have a 3:1 incidence of complications (3). When a symptomatic lesion does occur, it is difficult to diagnose, because its signs and symptoms are identical to such common disorders as Crohn's disease, appendicitis, and peptic ulcer disease. In fact, the disturbingly high mortality rate of 6–7% with complicated Meckel's diverticulum is probably related to delay in diagnosis. Recognition of the common patterns of presentation will allow the clinician to diagnose this lesion more rapidly so that definitive treatment can be instituted and mortality minimized. The symptomatic complications of Meckel's diverticulum fall into three major categories: bleeding, obstruction, and inflammation.

Bleeding is the most common presentation in children. In a pediatric series by Rutherford and Akers (12), outlining the major symptoms of 80 patients with Meckel's diverticula, over 50% presented with rectal bleeding and nearly one-half of these patients were less than 2 yr old. Not surprisingly, 90% of bleeding diverticula contain heterotopic mucosa (13). Bleeding is nearly always caused by ulceration of ileal mucosa

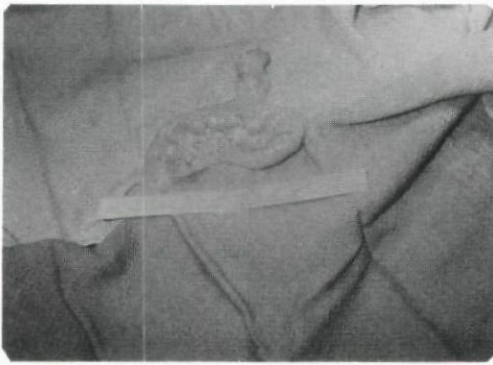


FIG. 1. Operative view of a Meckel's diverticulum.

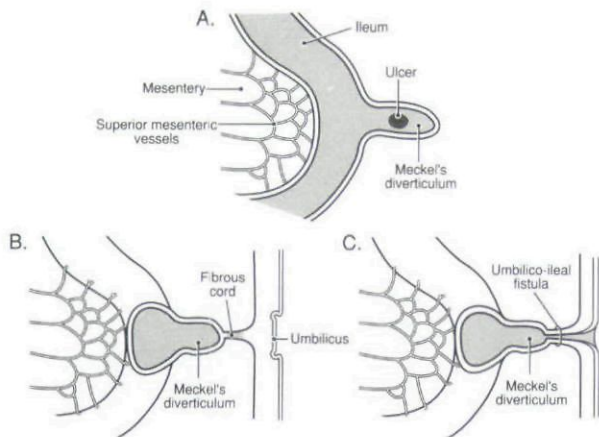


FIG. 2. *A*, schematic drawing of a loop of ileum containing an ulcer within a Meckel's diverticulum. *B* and *C*, the two most common variants of Meckel's diverticulum. *B* shows the diverticulum connected to the umbilicus via a fibrous cord. *C* illustrates an umbilico-ileal fistula caused by persistence of the intraabdominal portion of the yolk stalk.

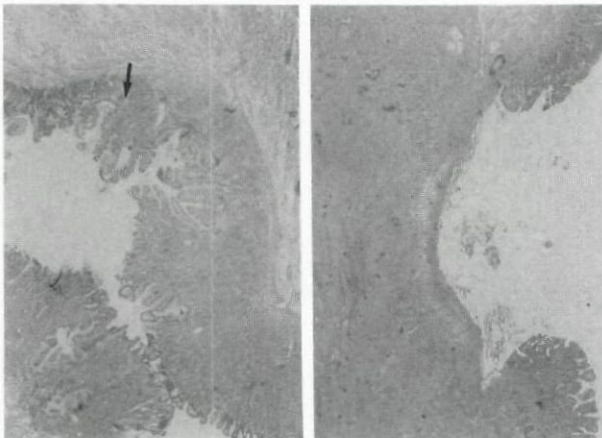


FIG. 3. *A*, histologic section of a Meckel's diverticulum containing gastric mucosa. The arrow points to the ileal-gastric junction (ileal mucosa is to the left). *B*, an acid-induced ulcer within the ileal mucosa.

adjacent to the acid-producing gastric mucosa (12, 14) (Fig. 3). The bleeding is classically acute, episodic, and painless. In the pediatric population, it appears most commonly as dark red, maroon, or "currant-jelly" stools and is frequently severe enough to require trans-

fusion. Only 40% have histories compatible with previous episodes of bleeding (12). In contrast to Rutherford's pediatric series which described tarry stools in only 7% of bleeding patients, Weinstein *et al.* (5), in their combined group of adults and children, found that melanic stools with associated abdominal cramping was the most common bleeding presentation (89%) (5). This suggests that adults are more likely to present with melena, and children with hematochezia, as the major symptom of a bleeding Meckel's diverticulum. Slower colonic transit in the adult population, or alternatively, a less severe hemorrhage, may account for this difference. Chronic anemia due to occult blood loss is an uncommon presentation for a Meckel's diverticulum (12). Even less common is hematemesis, which has been described in a single case report of a 48-yr-old man with a massively bleeding Meckel's diverticulum (15).

Obstruction is the most common presentation in the adult (3-5, 11, 16). Yamaguchi *et al.* (4) reported the largest modern series of symptomatic Meckel's diverticula. Nearly half of the patients in this series were adults, but unfortunately, symptomatic presentations were not grouped according to age. Nevertheless, intestinal obstruction (37%) was a more common complication than hemorrhage (12%) by a margin of more than 3 to 1. Furthermore, intussusception (14%) and volvulus (3%) were not grouped with the intestinal obstruction category in this report. Obstructive symptoms caused by a Meckel's diverticulum may occur when either 1) the diverticulum is attached by a fibrous band to the umbilicus, abdominal wall or other viscera, or 2) the diverticulum is free and unattached. Halstead (17), while elegantly discussing the mechanisms of obstruction in his 1902 review, recognized that an attached diverticulum was more likely to obstruct than one remaining free. Obstruction may be caused by entanglement of the small bowel around a fibrous cord, entrapment of an ileal loop within a mesodiverticular band, intussusception, volvulus, incarceration within a hernia sac, or chronic Meckel's diverticulitis. A mesodiverticular band is a vascular cord running between the diverticulum and the base of the mesentery. It predisposes to obstruction by allowing entrapment of a loop of ileum (12). Intussusception develops because the diverticulum serves as a lead point following simple invagination (18). However, inversion of the diverticulum into the gut lumen may occur without producing any symptoms or complications (17). Only anatomically free diverticula can invaginate. Volvulus occurs when there is a persistent fibrous band, and is related to the shape and degree of fixation of the diverticular tip (12). Fixation of the tip may also allow torsion of the diverticulum around its own axis. Occasionally, Meckel's diverticula become strangulated within in-

guinal, or less commonly, femoral or umbilical hernias (19). This has been termed a Littre's hernia after the author who originally described three cases of incarceration of small bowel diverticula within femoral hernias nearly 300 yr ago (20). Finally, a chronically inflamed Meckel's diverticulum can cause obstruction when the inflammation extends to the adjacent small intestine, producing cicatricial narrowing.

The third most common presentation of Meckel's diverticulum is caused by an inflammatory process such as diverticulitis, peptic ulceration of ileal mucosa, or, rarely, a foreign body within the diverticular lumen. Obstruction of the diverticular orifice with subsequent bacterial infection can occur in diverticula in a fashion analogous to appendicitis. In fact, appendicitis is the most common preoperative diagnosis in patients presenting with Meckel's diverticulitis (5). Peptic ulceration may cause tissue necrosis with resultant diverticulitis or even frank perforation with peritonitis. Foreign bodies may lodge in a diverticulum. In his review of 1605 patients, Moses reports 32 cases of foreign bodies within diverticula, including fish bones, gallstones, marbles, and bullets (6).

Meckel's diverticula occasionally harbor tumors. A recent literature review of neoplasms in Meckel's diverticula found that, of a total of 209 cases reported through 1985, 33% were carcinoid tumors, 27% sarcomas, 23% benign mesenchymal tumors, 12% adenocarcinomas, and the remainder, miscellaneous lesions (21). Although a carcinoid tumor is the most common neoplasm found in a Meckel's diverticulum, these lesions represent only 23% of all small intestinal carcinoids (22).

Diagnosis of a symptomatic Meckel's diverticulum may be difficult, especially in the adult, because of the lesion's ability to masquerade as one of a variety of much more common abdominal pathologies. However, even when the clinical index of suspicion is high, a preoperative diagnosis of Meckel's diverticulum is not easily made. Routine small intestinal barium studies will occasionally demonstrate this lesion, but, in general, are notoriously insensitive (Fig. 4). Several reasons for this have been offered, including stenosis at the diverticular neck, poor barium filling due to the presence of intestinal contents, and contraction of the tunica muscularis, which tends to expel barium from the diverticular lumen (23, 24). Careful compression radiographs at regular intervals during the examination may improve the sensitivity of routine barium x-rays. The technique of small bowel enteroclysis appears to have markedly increased the diagnostic yield of barium. Maglinte *et al.* (23) claim near-consistent demonstration of surgically documented Meckel's diverticula (23). Angiography is a useful examination in the evaluation of unexplained gastrointestinal bleeding. Angiographic

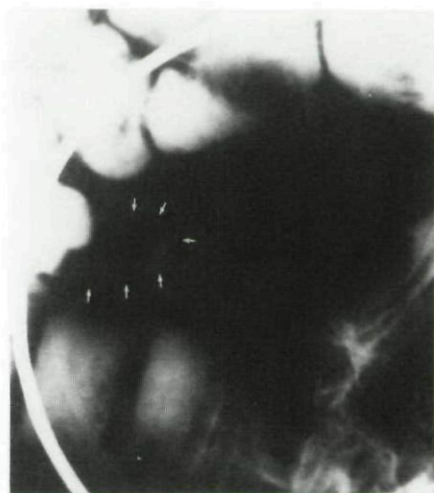


FIG. 4. Barium outlining a diverticular pouch (arrows) on small bowel radiography.

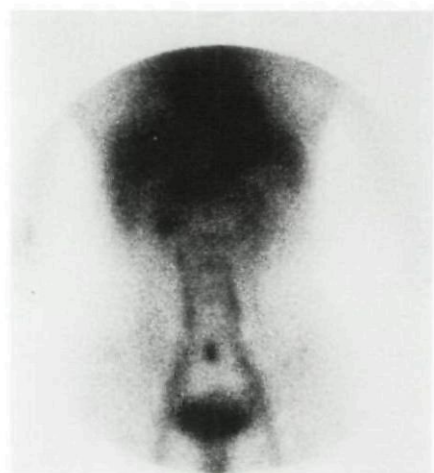

FIG. 5. A positive Meckel's scan at 10 min. The persistent focus of tracer in the midabdomen parallels stomach activity.

diagnosis of a Meckel's diverticulum on superior mesenteric artery injection depends upon demonstration of a branch of the ileocolic artery which represents a remnant of the right vitelline artery (25). Occasionally, late intense staining of the area supplied by this vessel is seen, representing increased vascularity of heterotopic gastric mucosa. Unfortunately, only 33% of proven cases are diagnosed by angiography (23).

A specific nuclear scintigraphic study was developed in an attempt to capitalize on the presence of gastric mucosa in most symptomatic Meckel's diverticula. Radioisotope scanning with ^{99m}Tc pertechnetate was first proposed by Harden *et al.* (26), in 1967, as a noninvasive test to detect such ectopic gastric mucosa (Fig. 5). Meckel's diverticula that contain other heterotopic mucosa in the absence of gastric mucosa are not detectable by this scan. At least 1.8 cm^2 of ectopic gastric mucosa is necessary for a positive scan (27). Several agents will theoretically improve the chance of a positive scan if a lesion is present. Pentagastrin accelerates uptake of

^{99m}Tc pertechnetate in both the stomach and ectopic gastric mucosa (28). Glucagon has been used to enhance imaging, because its inhibitory effect on peristalsis is thought to promote pooling of the radionuclide in the diverticular lumen (28). However, others have found diminution of ^{99m}Tc pertechnetate uptake in mouse gastric mucosa by glucagon (29). Cimetidine has been shown to improve Meckel's scan imaging (30). The presumed mechanism is inhibition of intraluminal release of the ^{99m}Tc pertechnetate anion once taken up by the cell (30).

The site of ^{99m}Tc pertechnetate anion uptake and excretion is debatable. Many texts report the parietal cell as the site of uptake and secretion, citing 1969 autoradiographic studies by Meier-Ruge and Fridrich (31), showing selective uptake in cat parietal cells (31). However, in 1973, Marsden *et al.* (32) reported autoradiographic studies in the dog which demonstrated ^{99m}Tc pertechnetate concentration in the gastric mucous cell and not in either parietal or chief cells. Subsequent studies by Keramidas *et al.* (33) support this contention by showing equal concentrations of the ion in the antrum and the body of surgically isolated dog stomachs. In 1975, Berquist *et al.* (34) retracted their previous report of the parietal cell as the site of uptake, stating that further autoradiographic studies in dog and rat showed intense staining in the surface epithelial cell and not in any other cell type. Clinically, visualization of the whole stomach (antrum, body, and fundus) by ^{99m}Tc pertechnetate scanning does not support the parietal cell, alone, as the cell responsible for uptake and secretion of this anion. Furthermore, in addition to the gastric mucosa, this anion is concentrated in thyroid, salivary, and lacrimal glands, as well as the choroid plexus (35). ^{99m}Tc pertechnetate scanning is also useful in demonstrating Barrett's mucosa, whether or not parietal cells are present (34). Finally, patients with pernicious anemia and achlorhydria have normal uptake and secretion of this anion (36). In summary, the exact cell type and mechanism of ^{99m}Tc pertechnetate ion uptake is unclear, but available evidence supports the gastric mucous cell and not the parietal cell as the primary site.

Meckel's scanning is reported to be a sensitive and specific noninvasive test for the detection of ectopic gastric mucosa, with an overall diagnostic accuracy of 90% (37). However, these results are based on a population in which the majority of cases are children. A retrospective review of 35 published adult cases of Meckel's scans correlated scintigraphy with surgical findings. A sensitivity of 62.5% and a specificity of 9% were identified, giving a positive predictive value of only 60% in the adult patient (38). False-positive scans have been reported with appendicitis, Crohn's disease, abscesses, vascular abnormalities, renal lesions, and

several other miscellaneous lesions, including any organ containing ectopic gastric mucosa (38). False-negative scans occur if there is an insufficient amount of gastric mucosa or if the gastric mucosa present is necrotic. False-negative scans may occur even in the presence of sufficient gastric mucosa, but the reasons for this are unclear. Certainly, a single diagnostic study alone is often inadequate to diagnose a Meckel's diverticulum. The combined use of pertechnetate scanning, small bowel enteroclysis, and angiography is reported to have a preoperative diagnostic accuracy of >90% (23). In our opinion, enteroclysis, combined with Meckel's scanning, offers the best diagnostic yield while minimizing risk and cost in the patient with a suspected bleeding Meckel's diverticulum. Frequently, especially in those presenting with obstructive symptoms, the diagnosis of Meckel's diverticulum will not be made until laparotomy.

The standard treatment of symptomatic diverticula is surgical resection. A straightforward diverticulectomy or a resection of the ileal segment containing the diverticulum with end-to-end anastomosis is performed. Many diverticula, however, are found incidentally at laparotomy or during radiographic studies performed for unrelated indications. Based on previous estimates of a 25–40% attack rate and a mortality of 15%, surgeons advocated prophylactic removal of incidental diverticula. This practice has become controversial since the late 1970s, when a lower incidence of symptomatic lesions (4%) and mortality rates (6–7%) was described. Based on these figures, it has been estimated that, to save one patient's life from the complications of a Meckel's diverticulum, 800 asymptomatic diverticula would need to be resected (11). This would produce an unacceptable amount of perioperative morbidity. Most current recommendations state that incidental removal in adults is probably not justifiable unless there are risk factors present, such as 1) a past history of unexplained abdominal pain or lower gastrointestinal bleeding, 2) a narrow diverticular neck which predisposes to diverticulitis and obstruction, 3) a palpable mass within the diverticulum which suggests ectopic tissue or tumor, 4) a fibrous band tethering the lesion to the umbilicus which predisposes to volvulus and obstruction, or 5) a diverticulum with a vitelline vessel that lacks a mesentery which predisposes to incarceration (30). However, some pediatric surgeons continue to argue for removal of incidental Meckel's diverticula in children because of their higher incidence of complications. One case report attributed the cessation of bleeding from a Meckel's diverticulum to antiulcer therapy with histamine-2 receptor antagonists (40). A similar conservative approach may be a reasonable alternative for the high risk surgical patient with gastrointestinal bleeding due to acid secreting mucosa in Meck-

el's diverticulum, although we know of no reports documenting such a strategy.

C. W. Mayo (41), in 1933, wrote "Meckel's diverticulum is frequently suspected, often looked for and seldom found." Despite obvious advancement in our diagnostic technologies, this statement remains true today. The 1-3% incidence of this congenital anomaly, in conjunction with a 4% complication rate, suggests that, although uncommon, this lesion will be encountered in clinical practice. A high index of suspicion in cases of unexplained gastrointestinal bleeding, obstruction, or inflammation, combined with nuclear scintigraphy and other diagnostic studies, will lead to proper diagnosis and management.

Reprint requests: Jeffrey L. Barnett, M.D., Instructor of Medicine, University of Michigan Hospital, 3912 Taubman Center, Ann Arbor, MI 48109-0362.

REFERENCES

- Soderlund S. Meckel's diverticulum. A clinical and histologic study. *Acta Chir Scand* 1959;(suppl 248):13-233.
- Meckel JF. Ueber die Divertikel am Darmkanal. *Arch die Physiol* 1809;9:421-53.
- Mackey WC, Dineen P. A fifty-year experience with Meckel's diverticulum. *Surg Gynecol Obstet* 1983;156:56-64.
- Yamaguchi M, Takeuchi S, Awazu S. Meckel's diverticulum investigation of 600 patients in the Japanese literature. *Am J Surg* 1978;136:247-9.
- Weinstein EC, Cain JC, ReMine WH. Meckel's diverticulum: 55 years of clinical and surgical experience. *JAMA* 1962;182:131-3.
- Moses WR. Meckel's diverticulum. Report of two unusual cases. *N Engl J Med* 1947;237:118-22.
- Caylor HD. Meckel's diverticulum. *Gastroenterology* 1949;33:31-46.
- Kiernan PD, ReMine SG, Kiernan PC, et al. Annular pancreas. *Arch Surg* 1980;115:46-50.
- Bondeson L, Starck-Bondeson AG. Crohn's disease in heterotopic gastric mucosa in a Meckel's diverticulum. *Acta Pathol Microbiol Scand* 1974;82(sec A):427-30.
- Ekman CN. Regional enteritis associated with Meckel's diverticulum: A report of five cases. *Gastroenterology* 1958;34:130-4.
- Soltero MJ, Bill AH. The natural history of Meckel's diverticulum and its relation to incidental removal. *Am J Surg* 1976;132:168-73.
- Rutherford RB, Akers DR. Meckel's diverticulum: A review of 148 pediatric patients, with special reference to the pattern of bleeding and to mesodiverticular vascular bands. *Surgery* 1966;59:618-26.
- Berman EJ, Schnieder A, Potts WJ. Importance of gastric mucosa in Meckel's diverticulum. *JAMA* 1954;156:6-7.
- Deneke. Ueber die entzündung des meckelschen divertikels und die gangran desselben. *Dtsch Z Chir* 1902;672:523-47.
- Shaunak S, O'Donohue J. Massive hematemesis and melaena from a Meckel's diverticulum. *Postgrad Med J* 1983;59:786-7.
- Leijonmarck CE, Bonman-Sandelin K, Frisell J, et al. Meckel's diverticulum in the adult. *Br J Surg* 1986;73:146-9.
- Halstead AE. Intestinal obstruction from Meckel's diverticulum. *Ann Surg* 1902;35:471-94.
- Ponka JL. Intussusception due to invaginated Meckel's diverticulum: presentation of two cases and an analysis of 52 cases collected from the literature. *Am J Surg* 1956;92:545-57.
- Castleden WM. Meckel's diverticulum in an umbilical hernia. *Br J Surg* 1970;57:932-4.
- Perlman JA, Hoover HC, Safer PK. Femoral hernia with strangulated Meckel's diverticulum (Littre's hernia). *Am J Surg* 1980;139:286-9.
- Dixon AY, McAnaw M, McGregor DH, et al. Dual carcinoid tumors of Meckel's diverticulum presenting as metastasis in an inguinal hernia sac: Case report with literature review. *Am J Gastroenterol* 1988;83:1283-8.
- Warner RRP. Carcinoid tumor. In: Berk EJ, ed. *Bockus, Gastroenterology*. Philadelphia: WB Saunders, 1985:19874-85.
- Maglente DDT, Jordan LG, Van Hove ED, et al. Chronic gastrointestinal bleeding from Meckel's diverticulum: Radiologic considerations. *J Clin Gastroenterol* 1981;3:47-52.
- Muroff LR, Casarella WJ, Johnson PM. Preoperative diagnosis of Meckel's diverticulum. Angiographic and radionucleotide studies in an adult. *JAMA* 1974;229:1900-2.
- Klein HJ, Alfidi RJ, Meaney TF, et al. Angiography in the diagnosis of chronic gastrointestinal bleeding. *Radiology* 1971;98:83-91.
- Harden RMcG, Alexander WD, Kennedy I. Isotope uptake and scanning of stomach in man with ^{99m}Tc-pertechnetate. *Lancet* 1967;1:1305-7.
- Priebe CJ, Marsden DS, Lazarevic B. The use of ^{99m}Tc-pertechnetate to detect transplanted gastric mucosa in the dog. *J Pediatr Surg* 1974;9:605-13.
- Anderson GF, Sfakianakis G, King DR, et al. Hormonal enhancement of technetium-^{99m}-pertechnetate uptake in experimental Meckel's diverticulum. *J Pediatr Surg* 1980;15:900-5.
- Khettery J, Effman E, Grand RJ, et al. Effect of pentagastrin, histalog, glucagon, secretion and perchlorate on the gastric handling of ^{99m}Tc pertechnetate in mice. *Radiology* 1976;120:629-31.
- Petrokubi RJ, Braum S, Rohrer GV. Cimetidine administration resulting in improved pertechnetate imaging of Meckel's diverticulum. *Clin Nucl Med* 1978;3:385-8.
- Meier-Ruge W, Fridrich R. Die verteilung von technetium ^{99m} und Jod-131 in der magenschleimhaut. *Histochemie* 1969;19:147-54.
- Marsden DS, Alexander C, Yeung P, et al. Autoradiographic explanation for the uses of ^{99m}Tc in gastric scintiphotography. *J Nucl Med* 1973;14:632.
- Keramidas DC, Coran AG, Zaleska RW. An experimental model for assessing the radiopertechnetate diagnosis of gastric mucosa in Meckel's diverticulum. *J Pediatr Surg* 1974;9:879-83.
- Berquist TH, Nolan NG, Stephens DH, et al. Radioisotope scintigraphy in diagnosis of Barrett's esophagus. *AJR* 1975;123:401-11.
- Cooney DR, Duszynski DO, Camboa E, et al. The abdominal technetium scan (a decade of experience) *J Pediatr Surg* 1982;17:611-19.
- Mikolajkow A, Chromicki OA. Scanning of the stomach with ^{99m}Tc. *Digestion* 1970;3:357-67.
- Sfakianakis GN, Conway JJ. Detection of ectopic gastric mucosa in Meckel's diverticulum and in other aberrations by scintigraphy. *J Nucl Med* 1981;22:647-54.
- Schwartz MJ, Lewis JH. Meckel's diverticulum: Pitfalls in scintigraphic detection in the adult. *Am J Gastroenterol* 1984;79:611-8.
- Soper RT. Meckel's diverticulum. *Hosp Med* 1988;2:83-108.
- Collins JC. Hemorrhage from a Meckel's diverticulum: A case with heterotopic gastric mucosa treated with cimetidine. *Arch Surg* 1980;115:83-4.
- Mayo CW. Meckel's diverticulum. *Mayo Clin Proc* 1933;8:230-2.

This document is a scanned copy of a printed document. No warranty is given about the accuracy of the copy. Users should refer to the original published version of the material.