

Key words: *Periodontium - periodontal disease - radiographs.*

Accepted for publication: October 25, 1976.

Radiographs in periodontics

NIKLAUS P. LANG¹ AND ROGER W. HILL²

¹School of Dental Medicine, University of Berne, Switzerland

²Department of Periodontics, School of Dentistry, University of Michigan, Ann Arbor, Michigan, U.S.A.

Abstract. Intraoral radiographs are widely used in periodontal diagnosis and research. However, accurate radiographic interpretation is only possible with high quality images. Some of the technical and geometric variables to consider have been presented.

Early periodontal lesions are not detected in radiographs. The amount of periodontal destruction in more advanced disease is generally underestimated. The accurate topography of periodontal pockets and the buccal and lingual aspects of the teeth cannot be visualized. Clinical probing is therefore a prerequisite for a complete periodontal diagnosis. However, radiographs are a valuable adjunct for the periodontal diagnosis and the diagnosis of trauma from occlusion. With standardized systems, radiographs may furnish additional quantitative data in clinical research.

Radiographs have been used in medicine since 1895 when Wilhelm Conrad Röntgen discovered the roentgen rays. One year later, the radiographic technique was used by Morton in the diagnosis of periodontal disease. With the introduction of the concept of focal infection, radiographs became commonly accepted in dentistry.

In periodontics, radiographs have mainly been used to assess the loss and destruction of alveolar bone and to confirm a clinical diagnosis of trauma from occlusion. Intraoral radiographs are generally preferred due to their sharpness and ability to demonstrate structural details (Barr 1966). When using radiographs in clinical diagnosis, it has to be kept in mind that a three-dimensional object is projected onto a two-dimensional plane resulting in a complex picture of different anatomical structures superimposed on each other (Regan & Mitchell 1963).

The purpose of this review is to present

some of the technical and clinical aspects of dental radiography in order to facilitate correct interpretation of radiographs in the diagnosis and treatment of periodontal disease.

Technical Considerations

Correct interpretation of radiographs is possible only if the image of the object is well defined and if there is not too much contrast. Contrast is defined as the difference between various degrees of density making details visible (Fitzgerald 1950). It may be altered by varying the kilovoltage or the processing time (Fitzgerald 1950, Guldener & Beissner 1970) (Fig. 1a, c). The increase of the kilovoltage from 65 KV to 90 KV produces shorter, more penetrating rays, resulting in a film with a dull and almost flat character (Updergrave 1951). This is due to the fact that rays of shorter wave length are more evenly absorbed into all tissues (Fitzgerald 1950).

The type of film used as well as its dark-room processing may affect the quality of the radiograph (Fig. 1a, b), e. g. developing temperature should be between 19° and 21°C. The quality of the picture is also affected by the milliamperage and kilovoltage used in the radiographic apparatus and by exposure time (Richards 1949, 1961) (Fig. 2).

The geometric quality of radiographic image is affected by the angulation of the central beam and the film in relation to the object. If the film is not placed parallel to the object, the parts of the object located at the longest distance from the film will be distorted (Richards 1949, 1961, Updegrave 1951). Increased distance between the X-ray source and the object will improve the quality of the picture because of less divergent rays (Richards 1949, Patur 1960). These facts lead many authors to advocate a change from the bisecting-angle technique to the paralleling long-cone technique (Fitzgerald 1947a,b, Updegrave 1951, Wuehrmann 1957, Fröhlich 1958, Patur & Glickman 1962, Guldener & Beissner 1970). The transition from the bisecting-angle to the long-cone technique in periodontics has resulted in radiographs of better diagnostic value. Superimposition and distortion of tooth-bone relationships could hereby be diminished (Patur & Glickman 1962, Regan & Mitchell 1963). Furthermore, the projection of the zygomatic process onto the buccal roots of the upper molars is eliminated (Fitzgerald 1947b). However, owing to the anatomical features of the mouth, it may often be difficult to apply the paralleling technique correctly, and compromises have to be made (Silha 1968).

Periodontal Health and Disease

Lamina Dura and Periodontal Membrane Space

The presence or absence of a lamina dura

on radiographs may be affected by slight variations in the angulation of the X-ray beam. The convexity or concavity of proximal tooth surfaces, the curvature of the roots, the level of the cemento-enamel junction and the thickness of the alveolar bone may cause variations in the thickness and clarity of the lamina dura (Ritchev & Orban 1953, Weinmann 1955, Manson 1963). With teeth that have a broad buccal-lingual width of elliptical-shaped roots, the X-ray beam must penetrate through a great amount of hard tissues before it reaches the film. Therefore, the lamina dura around such teeth will appear very dense. The lamina dura also follows the topography of the cemento-enamel junction which may give the appearance of angular bone defects if the teeth are tilted (Fig. 3). Changes in the horizontal and vertical angulation may also affect the thickness of the periodontal membrane space. A widened periodontal membrane space may be due to variation in the radius of the root curvature or the result of increased voltage or exposure time (van der Linden & van Aken 1970). Therefore, two teeth with roots of different size and curvature but surrounded by a periodontal membrane of the same size may in fact in the radiograph show periodontal membrane spaces of which one is twice as wide as the other. Furthermore, multiple lines may occur at the image of the periodontal membrane space of teeth with concave roots. The number of these lines varies according to the depth of the concavity and the width of the periodontal membrane (van der Linden & van Arken 1970).

Radiographs as a Diagnostic for Periodontal Disease

In children displaying severe gingivitis, Hollender et al. (1966) were unable to find roentgenographic evidence of the periodontal destruction. Also, Ramadan & Mitchell (1962) and Ainamo & Tammisalo (1973)

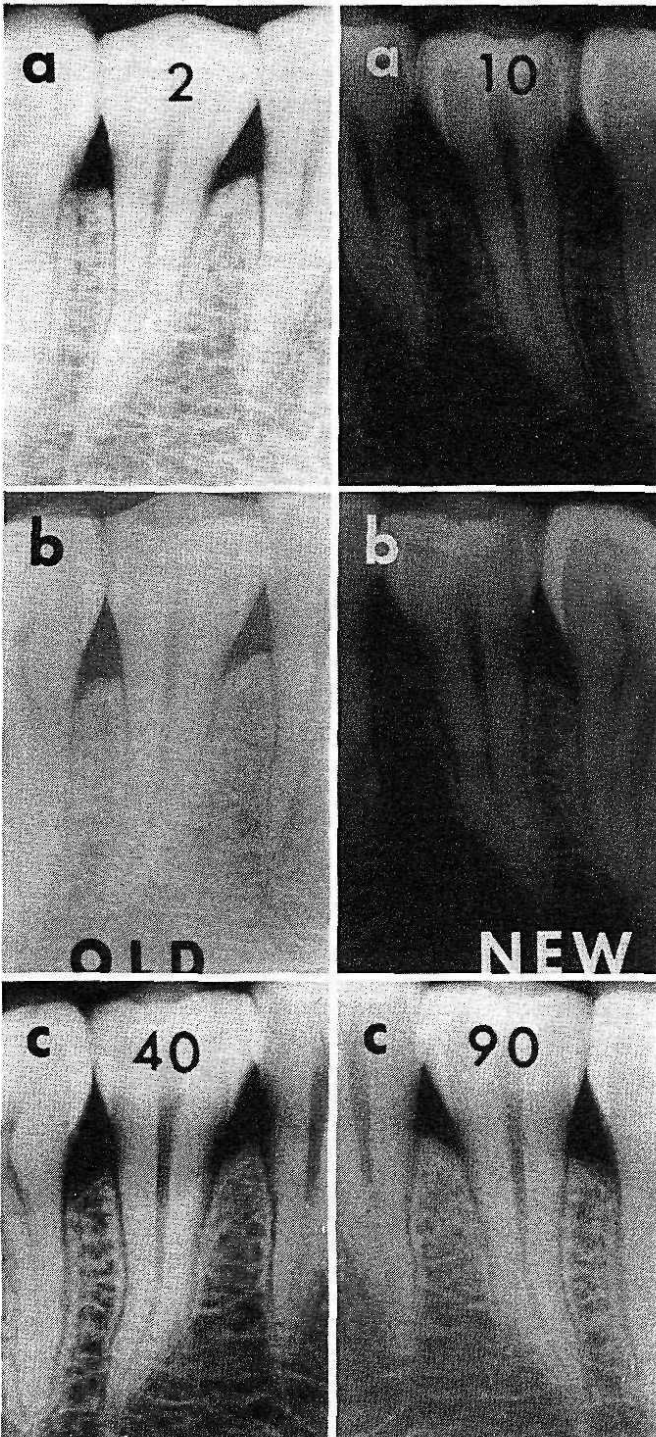


Fig. 1. Technical aspects of intraoral radiography.

- a) Radiograph showing lower contrast and density at 2-min developing time as compared with a 10-min developing time.
- b) Using old developer results in a fuzzy and washed out image.
- c) Influence of kilovoltage on the quality of the radiograph. Lower kilovoltage (40 KV) results in an image of higher contrast and density as compared to higher kilovoltage (90 KV).

(A. G. Richards, University of Michigan, Ann Arbor, USA).

Technische Betrachtungen zur intraoralen Radiographie.

- a) Ein Röntgenbild, welches während nur 2 Minuten entwickelt wurde, zeigt weniger Kontrast und Dichte als eines des während 10 Minuten entwickelt wurde.
- b) Alte Entwicklerlösungen führen zu einem verschwommenen und ausgewaschenen Bild.
- c) Einfluss der Kilovoltmenge auf die Qualität des Röntgenbildes. Eine niedrigere Spannung (40 KV) resultiert in einem Röntgenbild mit höherem Kontrast und höherer Dichte verglichen mit einer höheren Spannung (A. G. Richards, University of Michigan, Ann Arbor, USA).

Aspects techniques de la radiologie intra-orale.

- a) Radiographie montrant moins de contraste et de densité avec un temps de développement de 2 minutes qu'avec un temps de développement de 10 minutes.

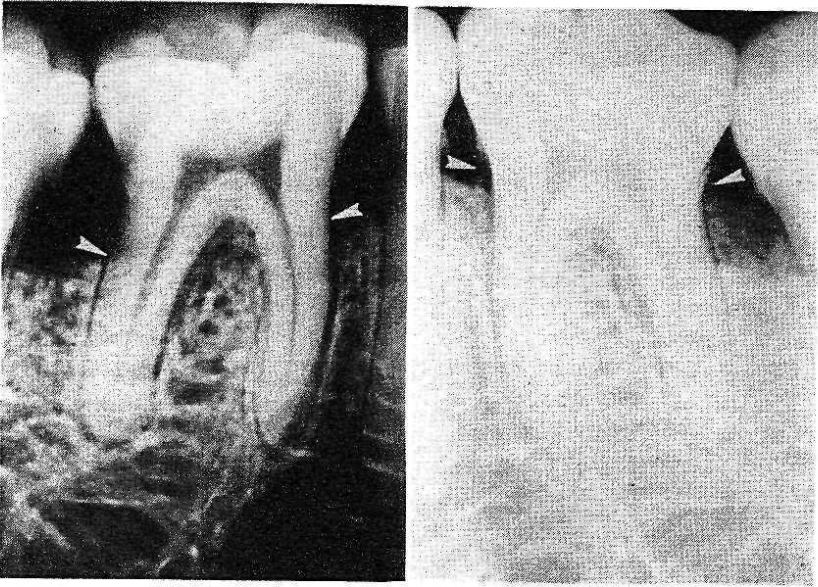


Fig. 2. Influence of exposure time as radiographic image. Too high exposure time results in a too dense image with high contrast resulting in "burn out" of the interproximal alveolar crest. (A. G. Richards, University of Michigan, Ann Arbor, USA).

Einfluss der Belichtung auf das Röntgenbild. Eine zu lange Belichtungszeit kann zu einem zu dichten Bild mit sehr hohem Kontrast führen, was in sogenanntem "Ausbrennen" des Alveolarkammes resultiert (A. G. Richards, University of Michigan, Ann Arbor, USA).

L'influence du temps d'exposition sur l'image radiologique: une exposition trop longue donne un image trop dense à haut contraste qui résulte en l'élimination de la crête alvéolaire interproximale (A. G. Richard, University of Michigan, Ann Arbor, USA).

were unable to reveal early crestal bone loss in radiographs. From these studies it can be concluded that radiographs are useless in the assessment of early destructive changes in the periodontium.

Several investigations have been carried out in order to determine the amount of bone resorption which can be visualized in radiographs. Lesions produced with burs in dried specimens of cancellous bone were not visible in radiographs unless the corti-

cal bone plates had been eroded extensively or penetrated (Goldman et al. 1957, Bender & Seltzer 1961a,b, Wengraf 1964). Likewise, Ramadan & Mitchell (1962) found that interproximal defects produced in dried human skulls could not be seen in radiographs when the buccal and lingual cortical plates were intact. Defects on the buccal and lingual root surfaces could only be seen if the cortical plate was thick, and a high degree of contrast existed between the de-

b) *L'usage d'un vieux révélateur donne une image floue et pâle.*

c) *L'influence du kilovoltage sur la qualité de la radiographie: un kilovoltage bas (40 KV) résulte en une image d'un contraste et d'une densité plus élevés qu'avec un kilovoltage élevé (90 KV).*

(A. G. Richards, University of Michigan, Ann Arbor, USA).

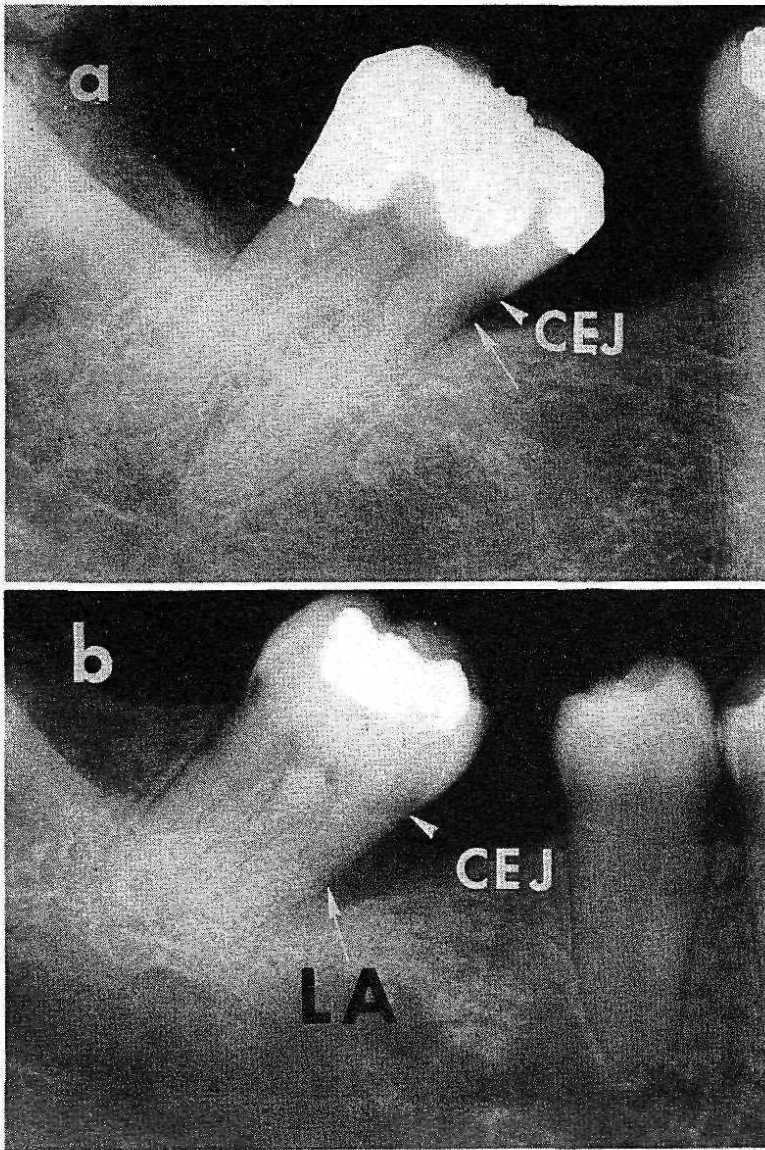


Fig. 3. In health the lamina dura follows the alignment of the cemento-enamel junction (arrows).

a) No angular bone defect.

b) True angular bone defect with loss of attachment (LA).

Im gesunden Parodont folgt die Lamina dura dem Verlauf der Schmelz-Zementgrenze (CEJ) (Pfeile).

a) Kein vertikaler Knochendefekt trotz gekipptem Zahn.

b) Wahrhafter vertikaler Knochendefekt mit Verlust des Attachmentapparates (LA).

Dans un cas normal la lamina dura suit l'alignement de la jonction émail-cément (flèches).

a) Absence de défaut osseux angulaire.

b) Véritable défaut osseux angulaire avec perte d'attachement (LA).

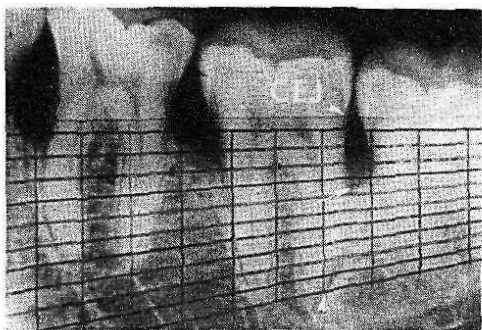


Fig. 4. Measurement of alveolar bone loss on the distal of the second molar according to Schei et al. (1959) demonstrating a loss of 35 %.

Alveolarer Knochenverlust auf der distalen Seite eines unteren zweiten Molaren gemessen nach der Methode von Schei et al. (1959). In diesem Falle beträgt der Knochenverlust 35 %.

Mesure de la perte d'os alvéolaire au niveau distal de la deuxième molaire mandibulaire selon la méthode de Schei et al. (1959); perte de 35 %.

fect and the surrounding bone. Septal defects created experimentally were noticed radiographically only if they had a minimal depth of 3 mm (Pauls & Trott 1966). Obviously, the actual size of a bony lesion must be much larger than its radiographic image. In a model system which was standardized for all radiographic variables (position of the mandible, film packet, source of radiation, exposure and processing conditions), bony lesions in the premolar areas without any involvement of the cortical plates could also be detected (Shoha et al. 1974). Since the cortical plates were thinner in the premolar areas, it was concluded that these plates did not attenuate as much of the X-ray beam as those of the molar region allowing for more contrast and earlier detection of bony lesions.

In none of the above-mentioned studies could it be ascertained whether septal lesions were present on the buccal or lingual aspects of the jaw. Due to the lack of sepa-

rate buccal and lingual visualization of the alveolar crest, the amount of bone loss is generally underestimated (Theilade 1960a,b). The interpretation of vertical bone destruction on the buccal and lingual aspects of the jaw is impaired by superposition of the tooth. Furthermore, furcation involvements cannot be diagnosed from radiographs before the bone resorption has extended apically beyond the furca. In order to register furcation involvements from radiographs before bone loss had progressed to the extent that the treatment of the lesion was unpredictable, Orban & Orban (1960) used a three-dimensional roentgenographic technique. This technique was based on the principle that the objects farthest away from the film plane (buccal aspects) will alter their position most in an up or down direction by changing the central X-ray beam in a vertical direction. The comparison of three films exposed at different vertical angulations of the central beam may thus yield furcation involvements at an earlier stage.

Although the buccal and lingual extensions of periodontal defects cannot be assessed accurately on radiographs (Patur & Glickman 1962), the visualization of interproximal intrabony pockets is generally possible. However, the exact topography of bony defects can only be determined by surgical exposure (Prichard 1961, 1966). Several diagnostic aids have been advocated to discover the bony topography of periodontal pockets without surgical exposure. Barium penetrations and Lipidol (Berry 1951) as well as periodontal dressing (Welty 1963) have been placed in pockets prior to taking radiographs. Introduction of these materials into periodontal pockets with adjacent inflamed and friable tissue is not recommended. The materials may be forced into the tissues and result in further irritation and subsequent loss of attachment (O'Leary et al. 1973). Clinical examination

with a periodontal probe is a safer and more effective means of determining the depth and topography of periodontal pockets.

Another method used to determine pocket depth is the insertion of calibrated silver points into the pocket prior to exposing the X-ray film. This technique may be useful to evaluate intrabony pockets and to locate fistulous tracts and periodontal abscesses in relation to the teeth (Hirschfeld 1953).

In order to visualize three-dimensional changes in alveolar crest height, a stereoscopic technique was introduced (Berg-hagen & Hjelmström 1956a,b, Berghagen & Blom 1961). Two films of the same object were exposed with different horizontal angulations. The radiographs were then observed with stereoscopic viewers. Super-imposed detail may be distinguished and definitions improved with this technique.

The diagnosis of absence or presence of calculus deposits should not be based on radiographic interpretation, since small deposits are not visible in radiographs (All-

dritt 1954). Radiographs are useful in detecting defective margins of restorations (Prichard 1961). However, if there is excessive vertical or horizontal angulation of the central X-ray beam, there is a risk of underestimating, but not overestimating the size of the defective margin (Björn et al. 1973, Haakonson et al. 1973). This emphasizes the importance of precise paralleling radiographic technique for periodontal diagnosis.

Radiographs in Evaluation of Periodontal Therapy and in Epidemiological Research

Standardization of Radiographs

Results of periodontal therapy may incorrectly be evaluated as successful if the pre-operative radiograph is under-angulated or over-exposed compared to that of the post-operative film (Wuehrmann 1957) (Fig. 2). Several devices have been suggested in order to standardize pre- and postoperative radiographs. Obviously, the technical specifications of the film and its exposure and processing have to be the same. One of

Fig. 5. Radiographic evidence of trauma from occlusion.

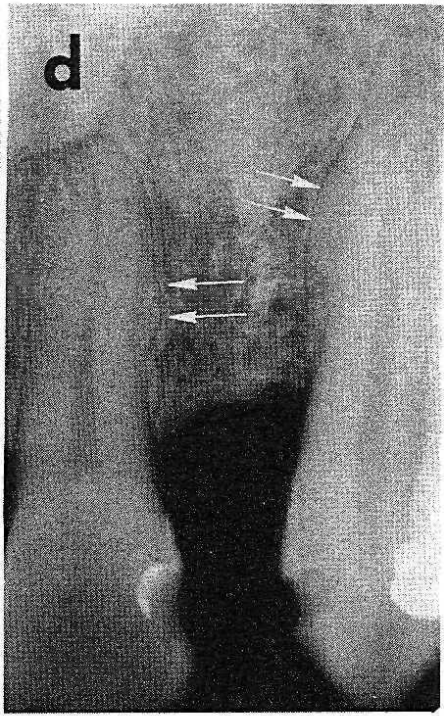
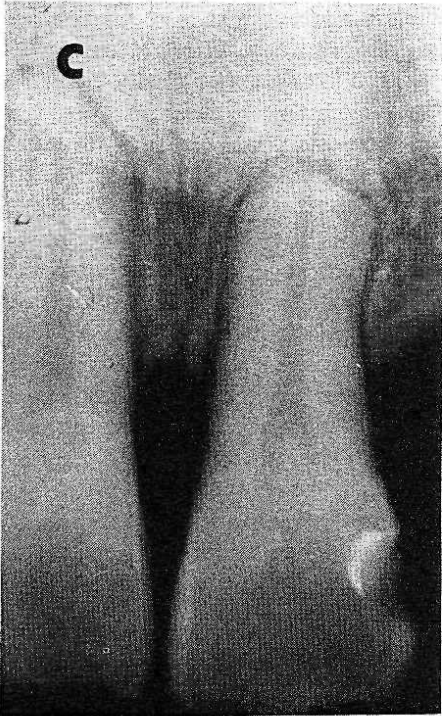
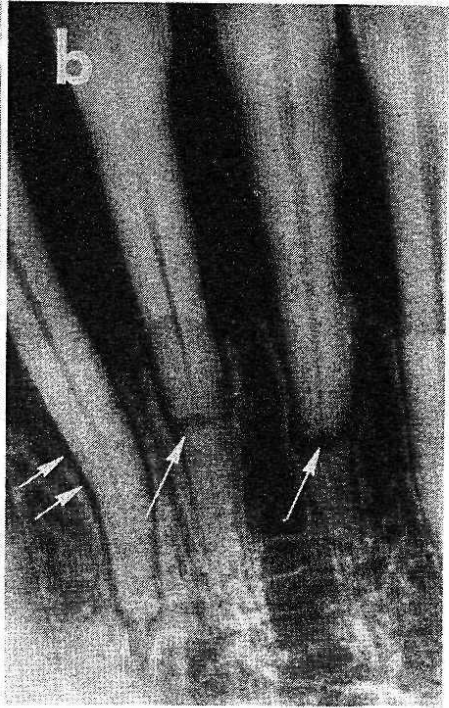
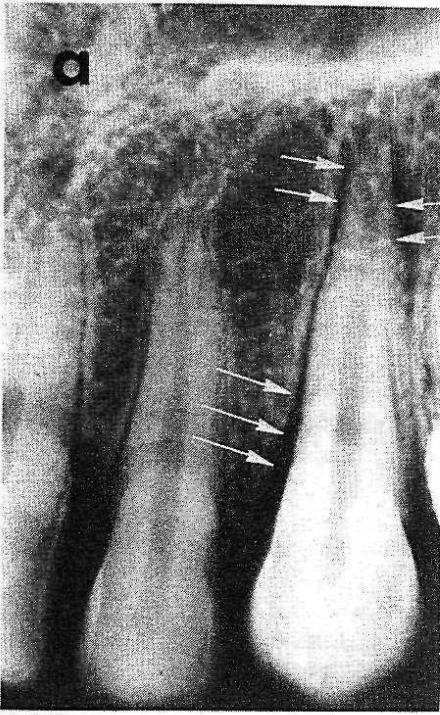
- a) Loss of continuity of the lamina dura (arrows) associated with coronal and apical widening of the periodontal membrane space.
- b) Widening of the periodontal membrane space and root fractures as a result of heavy bruxism.
- c) Root resorption following rapid orthodontic movement.
- d) Hypercementosis associated with trauma from occlusion (S. P. Ramfjord, University of Michigan, Ann Arbor, USA).

Okklusales Trauma im Röntgenbild.

- a) Verlust der Kontinuität der Lamina dura (Pfeile) im Zusammenhang mit koronaler und apikaler Erweiterung des Parodontalspaltes.
- b) Erweiterung des Parodontalspaltes und Wurzelfrakturen als Resultat schweren Bruxismus'.
- c) Wurzelresorption als Folge zu schneller orthodontischer Bewegung beim Erwachsenen.
- d) Hypercementosen können auch in Verbindung mit okklusalem Trauma gefunden werden (S. P. Ramfjord, University of Michigan, Ann Arbor, USA).

Evidence radiologique de trauma occlusal.

- a) Discontinuité de la lamina dura (flèches) associée à un élargissement coronaire et apical de l'espace occupé par le ligament parodontal.
- b) Elargissement de l'espace occupé par le ligament parodontal et fractures de racines résultant d'un bruxisme sévère.
- c) Résorption radiculaire suite d'un mouvement orthodontique rapide.
- d) Hypercémentose associée à un trauma occlusal (S. P. Ramfjord, University of Michigan, Ann Arbor, USA).



the first devices for identical exposures was designed by Benkow in 1956. This system consisted of a tray containing a thermoplastic compound impression of the occlusal surfaces in the area to be radiographed. The film was placed in the tray perpendicular to a steel bar which was parallel to the X-ray beam. The bar also assured an identical distance between the film plane and the cone of the X-ray machine. Using the same compound impression for the pre- and postoperative exposures, it was possible to obtain identical pictures. Similar devices have been constructed by Benkow (1960), Medwedeff et al. (1962), Dalitz (1964), Gilbers & Hanan (1968) and Puckett (1968). Recently Rosling et al. (1975) presented a device based on a similar principle for periodic reproducible radiographs. It consisted of an acrylic splint with five quadrangular metal tubes. A metal rod connecting the splint with the X-ray cone can be inserted. The splint has five paired tracks on the oral surface serving as film holders to allow orthoradial projection of either the premolar, canine or the incisor regions.

Quantitation of Bone Loss

Several attempts have been made to objectively determine the amount of bone loss in advanced cases of periodontal disease. One of the first methods was developed by Schei et al. (1959) who determined the percentage of alveolar bone on either a mesial or distal surface of a tooth. Using a plastic ruler, they assessed the bone height relative to the distance between the apex of the root and the "normal" level of the alveolar crest defined as 1 mm apical to the cemento-enamel junction (Fig. 4). This method has been modified by Engelberger et al. (1963) who used the total tooth length minus 1 mm as the reference. The "normal" bone level was thus between 60-70% of the total length.

Björn and co-workers (1969) modified their original determination system which also based on total tooth length. They introduced a scale of 20 units for the total length of the tooth as opposed to only 4 scale units in their original scoring system (Björn & Holmberg 1966, Björn et al. 1967).

In an attempt to quantify changes in the mineral content of interalveolar bone septa, Omnell (1957) developed a photometric system. He compared the density of the bone with a reference object consisting of an aluminum step wedge. The amount of radiation transmitted through the radiograph was compared with the transmission of radiation through the aluminum step wedge. With this method it was possible to study the healing of interalveolar septal bone following injury.

Several studies have been performed to evaluate the long-term effect of periodontal therapy (Ramfjord et al. 1973). Radiographic assessment of bone loss was positively correlated with tooth mobility, pocket depth and the level of attachment (Kelly et al. 1975). Suomi et al. (1968) determined the bone height on the basis of radiographic measurements, probing prior to and after surgical exposure of the bone. They demonstrated that there was no significant difference between radiographic and clinical measurements. These results indicate that radiographs are useful for an accurate evaluation of the level of alveolar bone, but that clinical measurements of the attachment level yield an equally accurate assessment of the periodontal destruction. Since measurements on radiographs require more time, equipment and money, it is reasonable to assess periodontal destruction in clinical trials on the basis of clinical attachment level measurements (Ramfjord 1959, Glavind & Löe 1967).

Radiographs have also been used to evaluate the results of reattachment procedures. The regeneration of the lamina dura asso-

ciated with the filling of intrabony defects with bone generally provides the radiographic evidence of successful treatment (Bell 1950). Following elimination of the inflammatory process, the bone marrow spaces may decrease in size and new crestal cortical layers may form (Friedman 1958). Since such changes may simulate the radiographic appearance of successful reattachment (Friedman 1958), conclusions regarding reattachment and bone regeneration on the basis of radiographs should be drawn cautiously. Radiographic information should be used only to support clinical measurements.

Radiographs as a Diagnostic for Trauma from Occlusion

The clinical diagnosis of hypermobility and soreness of teeth should be supplemented by radiographic evidence to support a diagnosis of trauma from occlusion (Pritchard 1961, Bohannon & Saxe 1965, Ramfjord & Ash 1971). The lamina dura may change from an uneven thickening to a loss of continuity or complete disappearance (Ramfjord & Ash 1971) (Fig. 5a). Resorption of supporting bone in the crevicular areas results in the appearance of "funnel-shaped" defects. An increased width of the periodontal membrane space, especially in association with resorption of the lamina dura, is often indicative of trauma from occlusion (Mühlemann 1955) (Fig. 5a,b). This may also be noted in furcation areas (Glickman 1972). These radiographic changes should not be confused with loss of periodontal attachment associated with inflammatory periodontal disease. Root resorption may result from severe trauma (Fig. 5c) and may be suspected initially from a loss of continuity of the root surface and a slight scalloping or fuzziness of the apical outline. Further

changes, which may indicate trauma from occlusion, are hypercementosis (Fig. 5d) osteosclerosis and root fractures (Fig. 5b) (Ramfjord & Ash 1971). Also the presence of vertical or angular bone resorption has been associated with the presence of occlusal trauma (Orban & Orban 1960, Patur & Glickman 1962).

Conclusions

Radiographs of high quality are an important adjunct in periodontal diagnosis. They provide a general overview of periodontal breakdown and of trauma from occlusion. They reveal changes only in the interproximal areas and do not show the exact topography of the periodontal lesions. Clinical examination using a periodontal probe is the only means of arriving at a complete diagnosis. Periodontal probing is also preferred to radiographs in evaluating treatment results. In clinical research periodic identical radiographs may be a valuable adjunct to supplement data on the progress of periodontal disease or the evaluation of periodontal therapy.

Zusammenfassung

Röntgenaufnahmen bei Parodontopathien

Intraorale Roentgenaufnahmen sind ein weit verbreitetes Hilfsmittel in der parodontalen Diagnose und Forschung. Eine genaue Interpretation ist jedoch nur mit qualitativ guten Bildern möglich. In der vorliegenden Arbeit werden einige der geometrischen und technischen Variablen, die die Qualität von Röntgenbildern beeinflussen können, diskutiert. Ferner werden die röntgenologischen Interpretationen des gesunden sowie des erkrankten Parodonts und des okklusalen Traumas erläutert.

Beginnende parodontale Läsionen können im allgemeinen mit Röntgenbildern nicht diagnostiziert werden. Bei fortgeschrittenen Parodontopathien wird der Knochenverlust eher unterschätzt. Ferner kann die genaue Topographie der parodontalen Taschen sowie die bukkalen und lingualen Flächen nicht dargestellt werden.

Die klinische Untersuchung mit der Parodontalsonde ist deshalb absolute Bedingung für eine genaue Diagnose der Parodontopathien. Die Röntgenbilder liefern aber einen recht guten Übersichtsbezug und bilden eine gute Ergänzung zur klinischen Diagnose der Parodontalerkrankungen und des okklusalen Traumas. Röntgenbilder, die in standardisierten Systemen aufgenommen worden sind, können auch zusätzliche quantitative Resultate in der klinischen Forschung vermitteln.

Résumé

Les radiographies en parodontologie

Les radiographies intra-orales sont couramment utilisées pour le diagnostic et la recherche parodontologique. Une interprétation exacte n'est possible qu'avec des images de haute qualité. Quelques variables géométriques et techniques qui influencent la qualité des radiographies sont discutées. L'interprétation radiologique du ligament parodontal sain et malade est évaluée.

Au début, les lésions parodontales ne peuvent pas être diagnostiquées par des radiographies. Avec des parodontites plus avancées la perte de l'os est généralement sous-estimée. En outre, la topographie exacte des poches parodontales et les surfaces buccales et orales ne sont pas visibles pour le diagnostic. C'est pourquoi l'examen clinique avec une sonde parodontale est indispensable pour le diagnostic exact des parodontopathies. Les radiographies peuvent, par contre, compléter et vérifier le diagnostic clinique d'une parodontite et d'un trauma occlusal. Si les radiographies sont exécutées d'une manière standardisée, elles peuvent fournir des résultats quantitatifs dans la recherche clinique.

References

- Ainamo, J. & Tammissalo, E. H. (1973) Comparison of radiographic and clinical signs of early periodontal disease. *Scandinavian Journal of Dental Research* **81**, 548-552.
- Alldritt, W. A. S. (1954) Radiology in periodontal practice. *Dental Practitioner* **5**, 123-133.
- Barr, J. H. (1961) The scope and limitations of roentgenography as a diagnostic procedure. *Dental Clinics of North America*, pp. 379-389, July. Philadelphia: W. B. Saunders.
- Barr, J. H. (1966) The information yield from radiographs. *Oral Surgery, Oral Medicine, Oral Pathology* **22**, 174-182.
- Bell, D. G. (1950) The periodontal lesion II. A roentgenographic evaluation of treated periodontal cases. A biological approach. *Journal of Periodontology* **21**, 70-78.
- Bender, I. B. & Seltzer, S. (1961a) Roentgenographic and direct observation of experimental lesions in bone: 1. *Journal of the American Dental Association* **62**, 152-160.
- Bender, I. B. & Seltzer, S. (1961b) Roentgenographic and direct observations of experimental lesions in bone: 2. *Journal of the American Dental Association* **62**, 708-716.
- Benkow, H. H. (1956) Periodisk-identiske og stereoskopiske intraorale røntgenopptak. *Den Norske Tannlaege Tidende* **66**, 239-255.
- Benkow, H. H. (1960) New principle for clinical roentgenographic tooth measurement. *Odontologisk Tidsskrift* **68**, 423-449.
- Berghagen, N. & Hjelmström, P. (1956a) Three-dimensional intraoral radiography. *Acta Odontologica Scandinavica* **14**, 189-220.
- Berghagen, N. & Hjelmström, P. (1956b) Radiographic measurement of bone changes in the alveolar limbus in a case of marginal periodontal disease. *Acta Odontologica Scandinavica* **14**, 221-229.
- Berghagen, N. & Blom, K. (1961) Periodontal pocket studied by three-dimensional radiography. *Dental Practitioner* **12**, 10-20.
- Berry, H. M. (1951) Radiopaque materials in the roentgenographic interpretation of periodontal lesions: a preliminary report. *Journal of the American Dental Association* **43**, 278-284.
- Björn, H. & Holmberg, K. (1966) Radiographic determination of periodontal bone destruction in epidemiological research. *Odontologisk Revy* **17**, 232-250.
- Björn, H., Holmberg, K. & Nylander, G. (1967) Maxillary sinus in periodontal disease. A clinical and radiographic investigation. *Odontologisk Revy* **18**, 83-114.
- Björn, H., Halling, A. & Thyberg, H. (1969) Radiographic assessment of marginal bone loss. *Odontologisk Revy* **20**, 165-179.
- Björn, H., Haakansson, H. & Johansson, O. (1973) Roentgenographic assessment of overhanging margins of dental restorations. I. Significance of variations in longitudinal projection. *Odontologisk Revy* **24**, 127-140.
- Bohannon, H. M. & Saxe, S. R. (1965) Periodontal roentgenographic interpretation. *Journal of the Tennessee Dental Association* **45**, 406-416.

- Dalitz, G. D. (1964) Variation of apparatus for obtaining serial roentgenograms. *Australian Dental Journal* **9**, 29-31.
- Engelberger, A., Rateitschak, K. H. & Marthaler, T. M. (1963) Zur Messung des parodontalen Knochenschwundes (Fehlerbestimmung einer Messmethode). *Helvetica Odontologica Acta* **7**, 34-38.
- Fitzgerald, G. M. (1947a) Dental roentgenography. I. An investigation of adumbration or the factors that control geometric unsharpness. *Journal of the American Dental Association* **34**, 1-20.
- Fitzgerald, G. M. (1947b) Dental roentgenography. II. Vertical angulation film placement and increased object-film distance. *Journal of the American Dental Association* **34**, 160-170.
- Fitzgerald, G. (1950) Dental roentgenography. IV. The voltage factor (KVP). *Journal of the American Dental Association* **41**, 19-28.
- Friedman, N. (1958) Reattachment and roentgenograms. *Journal of Periodontology* **29**, 98-110.
- Fröhlich, E. (1958) A comparison between anatomical and radiographic interpretation of marginal periodontal disease. *Parodontologie* **12**, 89-100.
- Gilbers, R. R. & Hanan, L. (1968) Duplication and quality control for intraoral roentgenographic use in clinical periodontics. *Oral Surgery, Oral Medicine, Oral Pathology* **26**, 31-38.
- Glavind, L. & Løe, H. (1967) Errors in the clinical assessment of periodontal destruction. *Journal of Periodontal Research* **2**, 180-184.
- Glickman, I. (1972) *Clinical Periodontology*, 4th ed., pp. 336-339. Philadelphia: W. B. Saunders.
- Goldman, H. M., Millsap, J. S. & Brenman, H. S. (1957) Origin of registration of the architectural pattern, the lamina dura, and the alveolar crest in the dental radiograph. *Oral Surgery, Oral Medicine, Oral Pathology* **10**, 749-758.
- Guldener, P. H. A. & Beissner, H. (1970) 5 Jahre Erfahrung mit der Langtubus-Röntgentechnik. *Schweizerische Monatsschrift für Zahnheilkunde* **80**, 139-162.
- Haakansson, H., Johansson, O. & Björn, H. (1973) Roentgenographic assessment of overhanging margins of dental restorations. II. Significance of variations in vertical angulation of the roentgen beam. *Odontologisk Revy* **24**, 245-256.
- Hirschfeld, L. (1953) A calibrated silver point for periodontal diagnosis and recording. *Journal of Periodontology* **24**, 94-98.
- Hollender, L., Lindhe, J. & Koch, G. (1966) A roentgenographic study of clinical healthy and inflamed periodontal tissues in children. *Journal of Periodontal Research* **1**, 146-151.
- Kelly, G. P., Cain, R. J., Knowles, J. W., Nissle, R. R., Burgett, F. G., Shick, R. A. & Ramfjord, S. P. (1975) Radiographs in clinical periodontal trials. *Journal of Periodontology* **46**, 381-386.
- Manson, J. D. (1963) The lamina dura. *Oral Surgery, Oral Medicine, Oral Pathology* **16**, 432-438.
- Medwedeff, F. M., Knox, W. H. & Latiner, P. (1962) New device to reduce patient irradiation and improve dental film quality. *Oral Surgery, Oral Medicine, Oral Pathology* **15**, 1079-1088.
- Mühlemann, H. R. (1955) Parodontale Röntgendiagnostik. *Schweizerische Monatsschrift für Zahnheilkunde* **65**, 1005-1013.
- O'Leary, T. J., Standish, S. M. & Bloomer, R. S. (1973) Severe periodontal destruction following impression procedures. *Journal of Periodontology* **44**, 43-48.
- Omnell, K.-Å. (1957) Quantitative roentgenologic studies on changes in mineral content of bone *in vivo*. *Acta Radiologica*, Stockholm, Suppl. 148, 71-79.
- Orban, T. R. & Orban, B. J. (1960) Three-dimensional roentgenographic interpretation in periodontal diagnosis. *Journal of Periodontology* **31**, 275-282.
- Patur, B. (1960) Roentgenographic evaluation of alveolar bone changes in periodontal disease. In *Dental Clinics of North America*, pp. 47-54. Philadelphia: W. B. Saunders.
- Patur, B. & Glickman, I. (1962) Clinical and roentgenographic evaluation of the post-treatment healing of infrabony pockets. *Journal of Periodontology* **33**, 164-171.
- Pauls, V. & Trott, J. R. (1966) A radiological study of experimentally produced lesions in bone. *Dental Practitioner* **16**, 254-258.
- Prichard, J. (1961) Role of the roentgenogram in the diagnosis and prognosis of periodontal disease. *Oral Surgery, Oral Medicine, Oral Pathology* **14**, 182-196.
- Prichard, J. F. (1966) Criteria for verifying topographical changes in alveolar process after surgical intervention. *Periodontics* **4**, 71-76.
- Puckett, J. B. (1968) A device for comparing roentgenograms of the same mouth. *Journal of Periodontology* **39**, 160-161.

- Ramadan, A. E. & Mitchell, D. F. (1962) A roentgenographic study of experimental bone destruction. *Oral Surgery, Oral Medicine, Oral Pathology* **15**, 934-943.
- Ramfjord, S. P. (1959) Indices for prevalence and incidence of periodontal disease. *Journal of Periodontology* **30**, 51-59.
- Ramfjord, S. P. & Ash, M. M. (1971) *Occlusion*. 2nd ed., pp. 384-397. Philadelphia: W. B. Saunders.
- Ramfjord, S. P., Knowles, J. W., Nissle, R. R., Shick, R. A. & Burgett, F. G. (1973) Longitudinal study of periodontal therapy. *Journal of Periodontology* **44**, 66-77.
- Regan, J. E. & Mitchell, D. F. (1963) Roentgenographic and dissection measurements of alveolar crest height. *Journal of the American Dental Association* **66**, 356-359.
- Richards, A. G. (1949) Roentgenographic techniques made to order. *Journal of the American Dental Association* **39**, 396-404.
- Richards, A. G. (1961) Technical factors that control radiographic density. In *Dental Clinics of North America*, pp. 371-377. Philadelphia: W. B. Saunders.
- Ritchev, B. & Orban, B. J. (1953) The crests of the interdental alveolar septa. *Journal of Periodontology* **24**, 75-87.
- Rosling, B., Hollender, L., Nyman, S. & Olsson, G. (1975) A radiographic method for assessing changes in alveolar bone height following periodontal therapy. *Journal of Clinical Periodontology* **2**, 211-217.
- Schei, O., Waerhaug, J., Løvdaal, A. & Arno, A. (1959) Alveolar bone loss as related to oral hygiene and age. *Journal of Periodontology* **30**, 7-16.
- Shoha, R. R., Dowson, J. & Richards, A. G. (1974) Radiographic interpretation of experimentally produced bony lesions. *Oral Surgery, Oral Medicine, Oral Pathology* **38**, 294-303.
- Silha, R. E. (1968) Technical errors with the paralleling technique. *Dental Radiography & Photography* **41**, 51-55, 65-68.
- Suomi, J. D., Plumbo, J. & Barbano, J. P. (1968) A comparative study of radiographs and pocket measurements in periodontal disease evaluation. *Journal of Periodontology* **39**, 311-315.
- Theilade, J. (1960a) Usikkerheden ved røntgenologisk bedømmelse af marginalt knoglesvind. *Tandlaegebladet* **64**, 351-371.
- Theilade, J. (1960b) An evaluation of the reliability of radiographs in the measurement of bone loss in periodontal disease. *Journal of Periodontology* **31**, 143-153.
- Updegrave, W. J. (1951) The paralleling extension-cone technique in intraoral dental radiography. *Oral Surgery, Oral Medicine, Oral Pathology* **4**, 1250-1261.
- Van der Linden, L. W. J. & van Aken, J. (1970) The periodontal ligament in the roentgenogram. *Journal of Periodontology* **41**, 243-248.
- Weimann, J. P. (1955) Variation in the structure of bone and bones and their significance in radiology. *Oral Surgery, Oral Medicine, Oral Pathology* **8**, 988-992.
- Welty, A. S. (1963) An evaluation of three radiographic methods for delineating periodontal disease. V + 37 p. Master Thesis. Ann Arbor: University of Michigan School of Dentistry.
- Wengraf, A. (1964) Radiologically occult bone cavities. An experimental study and review. *British Dental Journal* **117**, 532-536.
- Wuehrmann, A. H. (1957) The long cone technique. *Practical Dental Monographs*, July.

Address:

University of Berne
School of Dental Medicine
Freiburgstr. 7
CH-3010 Berne
Switzerland

This document is a scanned copy of a printed document. No warranty is given about the accuracy of the copy. Users should refer to the original published version of the material.