

Angioedema Presenting As Chronic Gastrointestinal Symptoms

Stephen L. Eck, M.D., Ph.D., James H. Morse, M.D., David A. Janssen, M.D.,
Stephen G. Emerson, M.D., Ph.D., and David M. Markovitz, M.D.

Department of Internal Medicine, University of Michigan Medical Center, Ann Arbor, Michigan

Gastrointestinal complaints may be the presenting feature of patients with acquired or hereditary angioedema. We describe two patients with episodic nausea, abdominal pain, and cramping secondary to C1 inhibitor deficiency. In one patient, an acquired deficiency arose as a paraneoplastic syndrome with abdominal complaints preceding the diagnosis of an occult lymphoma. The second patient presented at age 61 with abdominal complaints secondary to a hereditary deficiency of C1 inhibitor. The patients' symptoms were due to gastrointestinal angioedema, resulting from episodic unregulated complement activation. The biochemical mechanism of this unusual syndrome and its diagnostic importance are discussed. A C1 inhibitor deficiency should be considered in patients with unexplained abdominal symptoms suggestive of intestinal pseudo-obstruction.

INTRODUCTION

Intestinal pseudo-obstruction may occur as a primary idiopathic disorder, or secondarily as a result of an underlying illness, including neoplastic, rheumatologic, endocrine, neurologic, and other diseases (1). Intestinal pseudo-obstruction often presents as a recurrent illness with symptoms of obstruction of the intestines (crampy abdominal pain and distention, nausea, and vomiting) without evidence of mechanical obstruction. We describe two patients with a C1 complement inhibitor deficiency causing angioedema who had recurrent episodes of intestinal pseudo-obstruction as their primary manifestation of this disorder. In one case, an underlying lymphoma was identified as the cause of the angioedema, and in the second, case a hereditary deficiency of C1 inhibitor caused the angioedema.

CASE REPORTS

Patient 1

A previously healthy 28-yr-old man presented on September 21, 1978, with a fever to 39.5°C, chills, and profound fatigue, and was found to have cervical lymphadenopathy and a palpably enlarged liver and

spleen. A heterophile test was negative, as was a throat culture for streptococcal pharyngitis. Over the following year, his spleen remained palpably enlarged, and radionuclide scanning documented splenomegaly. This was attributed to the residua of mononucleosis. In June 1980, the patient developed recurrent episodes of abdominal bloating, nausea, and post-prandial crampy abdominal pain. These symptoms persisted intermittently over the next 10 yr. The patient underwent extensive evaluations including two esophagogastroduodenoscopies (EGD), abdominal ultrasound, two radionuclide scans of the liver and spleen, three colonoscopies, an ERCP, proctoscopy, and multiple stool evaluations for occult blood, ova, and parasites. These tests were unrevealing, except for the persistent finding of splenomegaly. At different times the patient was diagnosed as having irritable bowel syndrome, inflammatory bowel disease (based on the finding of lymphoid nodular hyperplasia of the sigmoid colon on one colonoscopy), and a somatization disorder. In June 1990, the patient developed pain and swelling of the left ankle, which resolved after casting for a presumed stress fracture. Similar swelling appeared transiently in the right ankle a few weeks later. In July 1990, he developed transient arthralgias and non-pitting edema of the right wrist and, over the next year, he continued to have migratory arthralgias with concomitant, transient, non-pitting edema involving the wrists and ankles. His CBC was normal on multiple occasions. He had no further episodes of fever since 1978, and he denied chills, night sweats, or significant weight changes over the preceding 13 yr.

A CT scan of the abdomen, performed in July 1991, showed a moderately enlarged spleen, increased in size from February 1989, and new nodular densities in the splenic hilum suggestive of adenopathy (Fig. 1). He was then referred to our medical center. Physical examination revealed a palpably enlarged, non-tender spleen, and non-pitting edema of the wrist, hand, ankle, and scrotum. Non-blanching, pigmented, macular skin lesions with "petechial" spots on the lower legs, clinically diagnosed as Schamberg's pigmented purpura, were biopsied and revealed atypical lymphocytes surrounding and infiltrating dermal vessels with localized edema

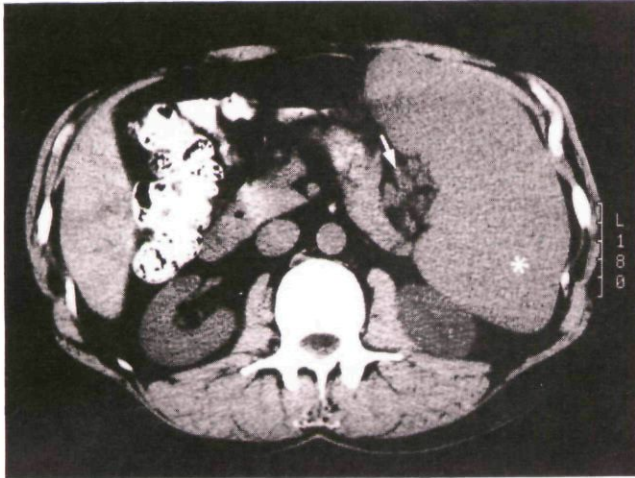


FIG. 1. Computed tomographic scan of the abdomen (patient 1) showing enlarged spleen (*) and perisplenic adenopathy (arrow), subsequently confirmed at laparotomy.

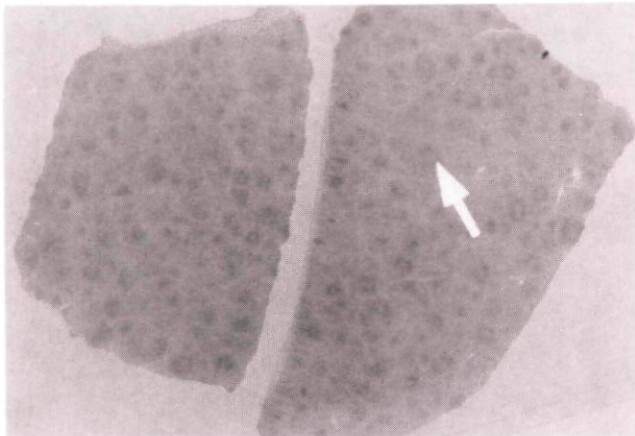


FIG. 2. Photomicrographs of hematoxylin and eosin-stained splenic tissue (patient 1) showing multiple foci of lymphoma (arrow) ($\times 15$).

and microhemorrhage. The patient was found to have decreased C1 inhibitor (1.9 mg/dl, normal 8–24 mg/dl), C1q (5 mg/dl, normal 7–15) and C4 (8 mg/dl, normal 10–46 mg/dl) levels with normal C3 levels, confirming the diagnosis of angioedema. His CBC, ANA, ENA, and rheumatoid factors all were normal. Serum protein electrophoresis revealed an IgM monoclonal gammopathy (IgM 746 mg/dl, normal 21–393), with normal IgG and IgA levels. In addition, his angiotensin-converting enzyme was elevated (67.6 U/ml, normal 20–50 U/ml).

Splenectomy (1500-g spleen) and bone marrow biopsy revealed extensive involvement of these tissues with a low grade follicular lymphoma (Fig. 2). Splenic artery and splenic hilar lymph nodes also were involved; however, multiple liver biopsies were negative for lymphoma. In the postoperative period, the patient's symptoms of fatigue, arthralgias, nausea, bloating, and abdominal pain resolved, as did his peripheral and scrotal edema, and they have remained absent for more than

1 yr. His serum complement levels have remained low, but his C1 inhibitor and angiotensin-converting enzyme levels returned to normal (8 mg/dl units and 43.7 U/ml, respectively) 2 wk after splenectomy. Fifteen months after splenectomy, the patient was found to have a large cell lymphoma (Richter's syndrome) with pulmonary involvement, but without symptoms of angioedema. He subsequently began systemic chemotherapy.

Patient 2

A 61-yr-old man was admitted to the hospital with complaints of abdominal cramping and distention, nausea, vomiting, and anorexia. He had been in good health until 6 months prior to admission, when he developed abdominal cramps, occurring in four self-limited episodes, each of successively greater intensity and characterized by a crescendo pattern. Colonoscopic and abdominal ultrasound examinations were performed and were unremarkable. In the three days prior to admission, his abdominal cramping became very severe, with associated nausea, vomiting, anorexia, and abdominal bloating. He noted that his daily bowel movements were "loose" and that he had significant flatus. Melena, hematochezia, and hematemesis were absent. The patient reported a history of migratory edema for several months, with episodic swelling of his extremities and scrotum.

Physical examination was remarkable for orthostatic blood pressure changes and a soft, non-tender abdomen that was tympanitic to percussion, with high-pitched tinkles on auscultation. No peripheral or scrotal edema was present. Serum chemistries and a complete blood count were normal. Stool evaluation for occult blood was negative. An abdominal roentgenogram revealed multiple dilated loops of small bowel with regular mucosal thickening. The patient was treated with bowel rest, nasogastric suction, and intravenous fluids. An upper gastrointestinal series performed the day after admission revealed localized "coin stacking" in the jejunum, compatible with angioedema (Fig. 3). By the second hospital day, the patient's condition had improved and his diet was gradually reinstated. Serum complement studies obtained shortly after admission revealed decreased levels of C4 (7.9 mg/dl; 11.5–50 mg/dl normal), CH50 (20 kU/ml; 22–84 kU/ml normal), and C1 inhibitor (6.8 mg/dl; 8–24 mg/dl normal), while the serum C1q and C3 levels were normal. Subsequent small bowel follow-through and enteroclysis studies were normal. The patient was discharged on the 10th hospital day. His symptoms returned approximately 1 month later, with small bowel dilation and air fluid levels noted on abdominal roentgenogram studies. He was begun on danazol for the treatment of the

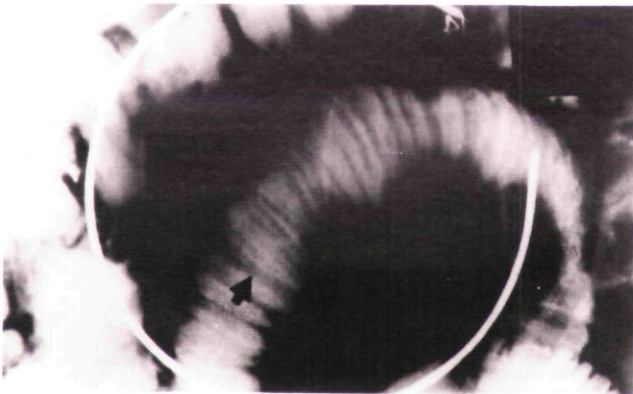


FIG. 3. Abdominal film with barium contrast showing localized mucosal thickening of the small bowel ["coin-stacking" (arrow)] during an acute episode of abdominal pain (patient 2).

angioedema, and has had no further episodes of gastrointestinal distress in over 2 yr of follow-up.

DISCUSSION

Angioedema is often unrecognized, although both the acquired and the hereditary forms are well described (2). Acquired angioedema most often appears as a paraneoplastic syndrome associated with a variety of lymphoproliferative (2-6) and other neoplastic (7-9) and autoimmune disorders (10, 11). It is most commonly associated with lymphomas, multiple myeloma, Waldenstrom's macroglobulinemia, and chronic lymphocytic leukemia. This condition results from anti-idiotypic antibodies directed against a monoclonal paraprotein (type I) (2). The resultant immune complexes bind the C1 complex (composed of C1q, C1r, and C1s) through the C1q subunit, leading to sequential activation of C1r and C1s. C1s, when activated, is able to cleave C2 and C4. This leads to the depletion of C2, C4, and C1 inhibitor and the release of vasoactive peptides. Normal serum levels of C1 inhibitor prevent the conversion of inactive C1 to its active form and the subsequent activation of the complement system. The absence of the inhibitor, whether acquired or hereditary (a dominant trait with irregular penetrance), results in the continued activity of C1r and C1s, leading to continued complement activation and depletion of C2 and C4 (12). A portion of the C2 molecule is believed to account for the increased vascular permeability (13) which results in tissue edema in diverse locations. Both acquired and hereditary angioedema can have a variety of manifestations, including malaise, arthralgias, crampy abdominal pain, diarrhea, laryngeal edema, and non-pitting edema of the extremities, scrotum, and face. The episodic submucosal and subcutaneous edema which results during attacks of angioedema was described by William Osler in 1888 (14). He noted that gastrointestinal symptoms were almost invariably present in patients with hereditary angioedema, a feature

that has not been fully appreciated in subsequent reports of acquired angioedema. Patients with acquired angioedema may have symptoms for many years prior to the diagnosis of an underlying malignancy (3), or symptoms may appear once therapy for the malignancy has been initiated (15). In rare instances, angioedema results from an acquired anti-C1 inhibitor antibody (type II) (16).

In the first case, it is highly likely that the occurrence of the symptoms of angioedema coincided with the development of the lymphoma. The patient's gastrointestinal complaints had been documented for 11 yr, and the joint swelling had been present intermittently for 1½ yr. Splenomegaly had been intermittently noted over a 13-yr period by physical examination, radio-nuclide scanning, and computed tomography. His symptoms of angioedema were manifested as peripheral and scrotal edema, Schamberg's pigmented purpura (17) of the lower extremities (secondary to repeated episodes of edema), nausea, abdominal bloating, and abdominal pain. His abdominal symptoms predated the other manifestations by approximately 10 yr, probably resulting from recurrent episodes of localized submucosal edema which occurred as a result of complement activation. In a retrospective analysis, the incidence of acquired angioedema was reported to be less than one per thousand cases of lymphoproliferative disorders (2).

The second patient was strongly suspected of having the hereditary form of angioedema because he had a normal serum protein electrophoresis and a normal C1q level (*vide infra*). Furthermore, no predisposing disorder has been identified in more than 2 yr of follow-up. The absence of a family history of angioedema is not inconsistent with this conclusion, given its variable penetrance (25% of individuals with hereditary angioedema have no family history of the disease).

The rarity of the identification of angioedema may be due, in part, to lack of recognition of its multiple manifestations. The diagnosis of angioedema should be considered in patients whose symptoms can be attributed to episodes of localized edema, including edema of the small intestine. Several laboratory tests may be helpful in establishing this diagnosis. Serum levels of C4, C2, and C1 inhibitor are typically decreased, whereas C3 levels are normal. Serum protein electrophoresis reveals an M component in most reported cases of acquired angioedema associated with lymphoproliferative and autoimmune disorders. C1q levels can differentiate the acquired form (low levels), from the inherited form (normal levels) (6). In addition, the family history may be helpful in establishing the presence of the inherited form; however, a negative family history does not exclude it. The regular thickening of small bowel folds seen on abdominal films ("coin stack-

ing") tends to be more localized in angioedema than in general intestinal edema due to other causes (18). The radiographic findings are entirely reversible and are seen only during an acute episode. Both the small and large intestine may be involved, including jejunum, ileum, duodenum, stomach, and colon in descending frequency of involvement.

Clinicians should consider angioedema as an underlying process in cases of unexplained chronic abdominal pain. The multiple, transient, and often subtle manifestations of angioedema may make diagnosis difficult if the clinician is not appropriately suspicious. Gastrointestinal symptoms may predate the development of cutaneous or respiratory symptoms by many years, or may be the only lifelong manifestation in patients with the hereditary form of angioedema (19). Indeed, the first patient was seen by several physicians over a period of many years before this diagnosis was entertained. Once the diagnosis of angioedema is established, an occult lymphoproliferative disease should be seriously considered. The clinical significance of acquired angioedema, as it relates to the prognosis of the underlying disorder, is unknown. It may, however, provide a clue to an occult malignancy and thus lead to an earlier diagnosis and treatment of the underlying process and the symptoms arising from angioedema.

Reprint requests and correspondence: Stephen L. Eck, M.D., The Institute for Human Gene Therapy, The Wistar Institute, Room 204, 36th and Spruce Streets, Philadelphia, PA 19104-4268.

REFERENCES

1. Faulk DL, Anuras S, Christensen J. Chronic intestinal pseudo-obstruction. *Gastroenterology* 1978;74:922-31.
2. Geha RS, Quinti I, Austen KF, et al. Acquired C1-inhibitor deficiency associated with antiidiotypic antibody to monoclonal immunoglobulins. *N Engl J Med* 1985;312:534-40.
3. Gottlieb M, Campbell K, Pelzmann K, Hu C-H. Long-standing angioedema with C1 esterase inhibitor deficiency associated with occult lymphoma. *West J Med* 1983;138:258-60.
4. Schreiber AD, Zweiman B, Atkins P, et al. Acquired angioedema with lymphoproliferative disorder: Association of C1 inhibitor deficiency with cellular abnormality. *Blood* 1976;48:567-80.
5. Hauptmann G, Lang J-M, North M-L, et al. Acquired C1-inhibitor deficiency in lymphoproliferative diseases with serum immunoglobulin abnormalities. *Blut* 1976;32:195-206.
6. Gelfand JA, Boss GR, Conley CL, et al. Acquired C1 esterase inhibitor deficiency and angioedema: A review. *Medicine* 1979;58:321-8.
7. Nilsen A, Matre R. Acquired angioedema and hypocomplementemia in a patient with myelofibrosis. *Acta Med Scand* 1980;207:123-5.
8. Cohen SH, Koethe SM, Kozen F, et al. Acquired angioedema associated with rectal carcinoma and its response to danazol therapy. Acquired angioedema treated with danazol. *J Allergy Clin Immunol* 1978;62:217-21.
9. Ross TF, Coleman DL, Naughton JL. Angioedema and small-cell carcinoma of the lung. *Thorax* 1982;37:950-1.
10. Wallington TB. Acquired C1 esterase deficiency with cold agglutinin disease associated with monoclonal IgM antibodies. *Br J Dermatol* 1978;99(suppl 16):39-40.
11. Costanzi JJ, Coltman CA, Donaldson VH. Activation of complement by a monoclonal cryoglobulin associated with cold urticaria. *J Lab Clin Med* 1969;74:902-10.
12. Rosse WF. *Clinical immunohematology: Basic concepts and clinical applications*, 1st ed. Boston: Blackwell Scientific Publications, 1990:72-7.
13. Donaldson VH, Ratnoff OD, Dias da Silva W, et al. Permeability-increasing activity in hereditary angioneurotic edema plasma. II. Mechanism of formation and partial characterization. *J Clin Invest* 1969;48:642-53.
14. Osler W. Hereditary angioneurotic edema. *Am J Med Sci* 1888;95:362-7.
15. Beretta KR, Spath PJ, Pedrazzini A, et al. Angioödem durch erworbenen Komplement-C1-Inhibitor-Mangel bei einer Patientin mit Non-Hodgkin-Lymphom und autoimmun-hämolytischer Anämie. *Schweiz Med Wochenschr* 1991;121:943-7.
16. Spath PJ, Wuthrich B, Matter L, et al. Acquired angioedema and anti-C1-inhibitor autoantibody. *Arch Intern Med* 1989;149:1213-4.
17. Moschella SL, Hurley HJ, eds. *Dermatology*, vol 1. Philadelphia: W.B. Saunders, 1985:1071-3.
18. Pearson KD, Buchignani JS, Shimkin PM, et al. Hereditary angioedema of the gastrointestinal tract. *AJR* 1972;116:256-61.
19. Weinstock LB, Kothari T, Sharma RN, et al. Recurrent abdominal pain as the sole manifestation of hereditary angioedema in multiple family members. *Gastroenterology* 1987;93:1116-8.

This document is a scanned copy of a printed document. No warranty is given about the accuracy of the copy. Users should refer to the original published version of the material.