

The t(2;5)-associated p80 NPM/ALK fusion protein in nodal and cutaneous CD30+ lymphoproliferative disorders

A high percentage of extracutaneous CD30+ anaplastic large cell lymphomas (nodal ALCL) carry a specific chromosomal translocation, t(2;5)(p23;q35), that results in abnormal expression of p80 NPM/ALK chimeric protein (p80). The protein p80 may be detected by immunohistochemistry using polyclonal (anti-p80) or monoclonal (ALK1) antibody directed against the ALK epitope. Although nodal ALCL, primary cutaneous ALCL, and lymphomatoid papulosis type A (lyp A) have similar histologic and immunohistochemical features, the expression of p80 in these cutaneous lesions has not been extensively studied. We immunostained tissues from 10 nodal ALCL, 8 primary cutaneous ALCL, 24 lyp A, and positive and negative controls using polyclonal rabbit anti-p80 and the avidin-biotin-peroxidase labeling method. Reactivity was determined by comparing staining intensity to positive controls [4 nodal ALCL with t(2;5)] and negative controls (21 non-ALCL lymphomas). Only cutaneous lesions staining positively with anti-p80 were further studied with the monoclonal antibody ALK1 and reverse transcription polymerase chain reaction (RT-PCR) for p80 messenger RNA. All positive controls (4/4), but none of the negative controls (0/21) nor lyp A (0/24), were immunoreactive for anti-p80. Sixty percent (6/10) of nodal ALCL and a single case (12%) of primary cutaneous ALCL were immunoreactive for anti-p80. In this exceptional cutaneous lesion, although we did not find NPM/ALK by RT-PCR, we detected strong expression of ALK using ALK1. We conclude that t(2;5) is rarely involved in the pathogenesis of cutaneous CD30+ lymphoproliferative disorders.

Su LD, Schnitzer B, Ross CW, Vasef M, Mori S, Shiota M, Mason DY, Pulford K, Headington JT, Singleton TP. The t(2;5)-associated p80 NPM/ALK fusion protein in nodal and cutaneous CD30+ lymphoproliferative disorders.

J Cutan Pathol 1997; 24: 597-603. © Munksgaard 1997.

Lyndon D. Su¹, Bertram Schnitzer¹, Charles W. Ross¹, Mohammad Vasef², Shigeo Mori³, Mami Shiota³, David Y. Mason⁴, Karen Pulford⁴, John T. Headington¹ and Timothy P. Singleton¹

¹University of Michigan, Ann Arbor, Michigan; ²City of Hope National Medical Center, Duarte, California; ³University of Tokyo, Tokyo, Japan; ⁴John Radcliffe Hospital, Oxford, UK

Lyndon D. Su, M. D., Stanford Univ. School of Med, Dept. of Dermatology and Pathology, H. -2110, 300 Pasteur Drive, Stanford, CA 94305, USA

Accepted 26 June, 1997

The specific chromosomal translocation t(2;5)(p23;q35) is identified in approximately one-third of nodal ALCL and results in the juxtaposition of the nucleophosmin gene (NPM) on chromosome 5q35 to a tyrosine kinase-encoding gene (ALK) on chromosome 2p23. A chimeric protein, p80 NPM/ALK, is produced that results in abnormal ALK expression in neoplastic lymphoid cells (1). Normal hematopoietic cells lack

ALK protein, although it is produced in some non-hematopoietic tissues (2). Expression of ALK protein in lymphoid cells appears to be restricted to those carrying t(2;5) or, rarely, other abnormalities of chromosomal region 2p23, such as t(1;2)(q25;p23) (2). Abnormal expression and regulation of ALK activity may be responsible for malignant transformation of lymphoid cells in nodal ALCL (3). Recently, overexpression of p80

has been found to induce neoplastic transformation *in vitro* (4).

The presence of t(2;5) may be demonstrated by karyotyping or by detection of NPM/ALK messenger RNA by reverse transcription polymerase chain reaction (RT-PCR) or *in situ* hybridization (ISH). The presence of t(2;5) may be inferred by detection of p80 protein in malignant lymphoid cells using rabbit polyclonal antibody for the ALK kinase domain of p80 (3, 5, 6). Several studies have shown anti-p80 immunostaining to be a sensitive and specific means of detecting t(2;5) when compared to the molecular techniques previously described (6–9). Recently, the murine monoclonal antibody ALK1 was developed against a formalin-resistant epitope in both the p80 NPM/ALK chimeric protein and normal human ALK protein. ALK1 also detects the t(2;5)-associated p80 fusion protein in nodal ALCL and abnormal ALK protein in lymphoid cells carrying t(1;2) (10). Only rarely is anti-p80 immunoreactive in the absence of t(2;5). Some of these cases may carry t(1;2) or other chromosome 2p23 abnormalities (2, 10). Delsol et al. (11) also recently described a new subtype of large B-cell lymphoma expressing full-length ALK receptor kinase and lacking t(2;5).

Primary cutaneous ALCL and lymphomatoid papulosis type A (lyp A) represent a clinical and histopathologic continuum of CD30+ lymphoproliferative disorders of the skin. These share some histologic and immunohistochemical features with nodal ALCL but are associated with a more favorable prognosis (12, 13). Understanding whether p80 is expressed in primary cutaneous ALCL and lyp A would aid in elucidating the pathogenesis of the cutaneous CD30+ lymphoproliferative disorders and their relationship to nodal ALCL. A study of p80 in primary cutaneous ALCL may also help to distinguish them from their aggressive nodal counterpart, which often secondarily affects skin. However, research in this area has yielded conflicting results. By combined molecular methods and immunohistochemistry, some investigators have detected p80 and NPM/ALK messenger RNA in several cases of primary cutaneous ALCL and lymphomatoid papulosis (8, 14), while others have not (3, 7, 10, 15, 16). In some studies the number of cases analyzed were few. However, in all of these studies immunoreactivity for anti-p80 in malignant lymphoid cells has been highly correlated with t(2;5) translocations or chromosome 2p23 abnormalities, indicating that the antibody has high sensitivity and high specificity for these abnormalities. We assayed for p80 using polyclonal anti-p80 immunohistochemistry on a relatively large number of primary cutaneous ALCL and lyp A. Additionally, for cutaneous lesions reac-

tive with anti-p80, we confirmed ALK expression with ALK1 and tested for the presence of t(2;5) by RT-PCR.

Material and methods

Case selection

We searched the pathology department files at the University of Michigan between 1987 and 1996 for all cases diagnosed as CD30+ anaplastic large cell lymphoma, regressing atypical histiocytosis, and lymphomatoid papulosis type A. Routine hematoxylin and eosin-stained sections were reviewed. Unstained sections or paraffin-embedded tissues (formalin or B5-fixed) were available on all cases.

Immunohistochemistry

Paraffin-embedded tissues were stained for CD30 (BerH2, 1:10, Dako, Carpinteria, CA), and T- and B-cell antigens including CD3 epsilon (rabbit polyclonal, 1:200, Dako), CD20 (L26, 1:500, Dako), CD43 (Leu22, 1:100, Becton-Dickinson, San Jose, CA), CD45RO (A6, 1:50, Zymed, San Francisco, CA) and/or CD45RO (UCHL-1, 1:50, Dako). Protease (for CD3 epsilon) or no pretreatment was used in earlier years at our institution. More recently, microwave antigen retrieval has been used with citrate buffer (10 mM, pH 6.0) for all of these markers (20). Antibody binding was detected with an avidin-biotin-peroxidase complex.

For anti-p80, deparaffinized tissue sections were pretreated with steam for 10 min in 5% urea and incubated overnight with rabbit polyclonal anti-p80 (1:100) (obtained from Dr. Mami Shiota, Dr. Shigeo Mori and Nichirei Corporation, Tokyo, Japan). Detection was with the avidin-biotin-peroxidase labeling method. Reactivity was determined by examining the CD30+ atypical large lymphoid cells for convincing cytoplasmic reactivity. Comparisons were made to formalin- and B5-fixed paraffin-embedded positive and negative tissue controls immunostained with anti-p80. The positive controls consisted of 4 cases of nodal ALCL previously karyotyped by the University of Michigan Cytogenetics Laboratory and found to carry t(2;5). The negative controls consisted of 21 randomly selected archival cases of Hodgkin's disease and non-Hodgkin's lymphoma.

Slides to be stained with ALK1 (obtained from Dr. Karen Pulford and Dr. David Mason) were deparaffinized and microwaved in citrate buffer (10 mM, pH 6.0) for 10 min, as described by Shi et al. (20). Monoclonal ALK1 antibody was applied at neat concentration and binding was detected with an avidin-biotin-peroxidase complex. Comparisons were made to a positive control, a t(2;5)-posi-

tive ALCL, and a negative control, a multitumor tissue section not containing ALCL.

Case definition

All cases had convincing expression of CD30 by atypical large cells. All cases had either a T-cell or null-cell phenotype. Cases were classified as nodal/extracutaneous ALCL, primary cutaneous ALCL, or lyp A according to well-known published criteria (17, 18). In our study, lesions displaying features of both primary cutaneous ALCL and lyp A (so-called borderline type) were arbitrarily classified as lyp A, as they appear to behave similarly (19).

RT-PCR

Only cases of cutaneous CD30+ lymphoproliferative disorders reactive with anti-p80 were analyzed for t(2;5)-associated NPM/ALK mRNA using RT-PCR. The messenger RNA-based PCR method has been previously described (14). Tissue mRNA was isolated from formalin-fixed paraffin tissue sections (Invitrogen, San Diego), and the RT-PCR reactions were performed according to manufacturer's recommendations (Perkin Elmer, Branchburg, NJ). Sup-m2 cell line known to carry t(2;5) was used as positive control, and normal liver tissue and the MOLT-4 cell line were used as negative controls. Briefly, 5 ul of reverse transcriptase product was used for each PCR reaction. PCR reactions were performed using oligonucleotide primers specific for the chimeric mRNA encoded by the fused NPM-ALK transcript (NPM 5', 5-TC-CCTTGGGGGCTTTGAAATAACACC-3; and ALK 3', 5-CGAGGTGCGGAGCTTGCTCAGC-3). Nested PCR reactions were carried out on the first-round PCR product using NPM and ALK 3' nested primers (NPM 5' nested primer, 5-CCAGTGGTCTTAAAGGTTG-3 AND ALK 3', 5-TACTCAGGGCTCTGCAGC-3). A primer pair derived from the NPM gene served as a control for RT and amplification of NPM mRNA (NPM 5' and NPM 3', 5-GCTACCACCTCCAGGGGCAGA-3). Primers for beta-actin also served as an additional control for RT and amplification of actin mRNA. Temperature conditions used for 45 amplification cycles were denaturation at 94°C for 1 min, annealing at 62°C for 1 min, and elongation at 72°C for 2 min. Electrophoresis was performed using 10 ul of PCR product in a 1.5% agarose gel. Detection of the 175-bp NPM-ALK fusion product was by hybridization to an end-labeled oligonucleotide homologous to sequences spanning the fusion junction (5-AGCACTTAGTAGTGATACCGCCGGA-3). The 185-bp NPM product reaction control was detect-

p80 expression in CD30+ lymphoproliferative disorders

Table 1. Detection of ALK expression in CD30+ lymphoproliferative disorders with anti-p80

	Immunophenotype	Anti-p80 immunostaining #positive/total #tested
Positive controls**	CD30+ T-cell	3 / 3
	CD30+ null-cell	1 / 1
Negative controls	Hodgkin's disease	0 / 7
	B-cell lymphomas	0 / 9
	T-cell lymphomas	0 / 5
Nodal ALCL	CD30+ null-cell	0 / 2
	CD30+ T-cell	6 / 8
Primary cutaneous ALCL	CD30+ T-cell	1* / 8
Lymphomatoid papulosis type A	CD30+ T-cell	0 / 24

* Immunoreactive with both p80 and ALK1. However, NPM/ALK mRNA was absent by RT-PCR.

** All carried t(2;5) by karyotype. One case had secondary skin involvement.

ed with an oligonucleotide homologous to normal NPM sequences (5-GTGCTGTCCACTAATATGCAC-3). The 310-bp actin product was detected by hybridization to an oligonucleotide homologous to normal actin sequences.

Results

Results are summarized on Table 1. All 4 positive controls, consisting of nodal ALCL (3 of T-cell and 1 of null-cell immunophenotype) with a t(2;5) karyotype, showed moderate-to-strong diffuse cytoplasmic staining of the atypical large cells with anti-p80. One positive control secondarily involved the skin.

In all 21 negative controls, the malignant lymphoid cells lacked staining for anti-p80. These cases consisted of 7 Hodgkin's disease (1 nodular lymphocyte predominant, 4 nodular sclerosis, 2 mixed cellularity); 9 B-cell lymphomas (5 diffuse large cell, 2 large cell immunoblastic, 2 small non-cleaved, non-Burkitt's); and 5 T-cell lymphomas (1 lymphoblastic, 4 large cell).

CD30+ large cell lymphoma cells in 60% (6/10) of nodal ALCL stained with anti-p80 (Fig. 1, 2). All positive cases had a T-cell phenotype. The negative cases had either T-cell (2) or null-cell (2) phenotype.

No cases of lyp A (Fig. 3) stained with anti-p80 (0/24). A single primary cutaneous ALCL (Fig. 4) had weak-to-moderate staining in the CD30+ large cells with anti-p80 (12%, 1/8). Using RT-PCR, we did not detect NPM/ALK fusion mRNA in this ex-

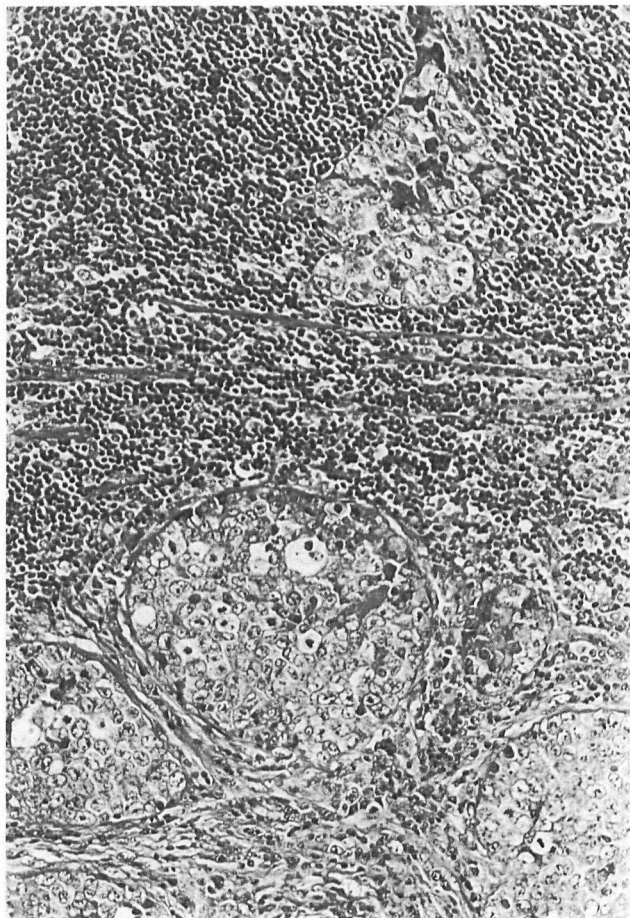


Fig. 1. Anaplastic large cell lymphoma (ALCL) in lymph node sinuses mimics carcinoma.

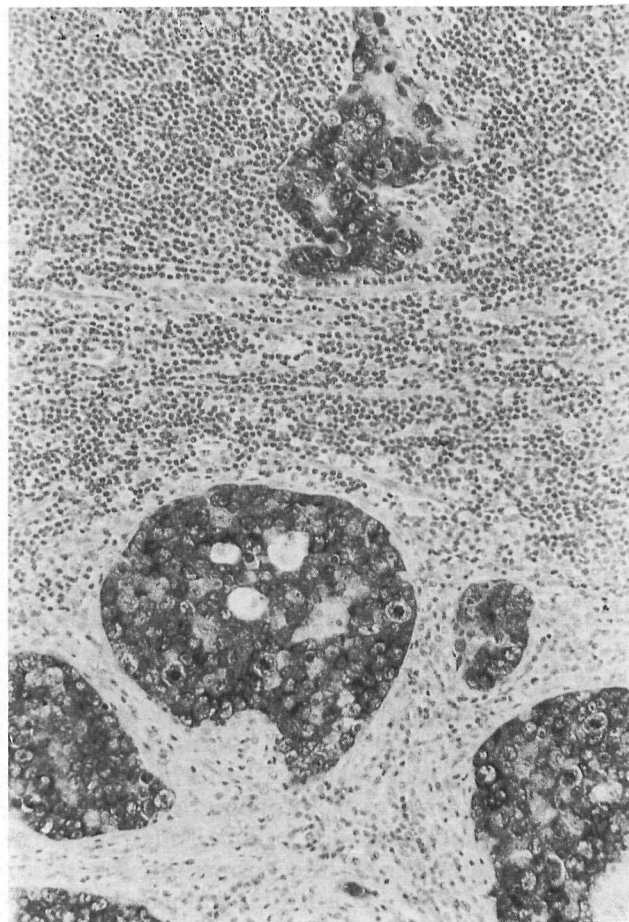


Fig. 2. Diffuse cytoplasmic immunoreactivity with anti-p80 in ALCL from Fig. 1. Neoplastic cells were also positive for CD30, CD45RO, and CD3, but negative for cytokeratin. Surrounding non-neoplastic lymphoid cells do not stain with anti-p80.

ceptional cutaneous lesion. Nevertheless, tumor cells showed strong immunoreactivity with monoclonal ALK1, thus confirming abnormal expression of ALK by these anaplastic lymphoid cells (Fig. 5). All lyp A and primary cutaneous ALCL had a T-cell phenotype.

In a few slides, anti-p80 showed variable reactivity to epidermis, sweat ducts, arrector pili muscle, lipocytes, endothelial cells, dermal fibroblasts, and reactive dendritic cells. In contrast to the diffuse cytoplasmic staining seen in positive controls, these cells displayed patchy granular cytoplasmic staining.

Discussion

Rabbit polyclonal anti-p80 was developed using a synthetic peptide corresponding to the ALK kinase domain of p80 NPM/ALK (6, 7). Because many non-lymphoid tissues express ALK (2), it is not surprising that immunostains with anti-p80 sometimes show staining of epidermal and con-

nective tissue components. Such phenomena have been noted by other investigators (6, 9, 10, 21). However, reactivity with anti-p80 in lymphoid cells is abnormal (2). In our cases, we correlated CD30 and T-cell immunostaining with anti-p80 reactivity in malignant lymphoid cells to ensure that reactive dendrocytes or myofibroblasts were not inadvertently designated positive. In all cases reviewed, the large anaplastic lymphoid cells were present in sufficient numbers to allow characterization by immunohistochemistry. Although Lyp also may be of null phenotype and CD30+ primary cutaneous ALCL also may be of null or B-cell phenotype, all of our cutaneous lesions by chance were of T-cell phenotype, which was defined as absence of CD20 immunoreactivity, and the presence of at least one of the following antigens: CD43, CD3, or CD45RO.

There is reported to be a high correlation between anti-p80 immunoreactivity in lymphoid cells and abnormalities of NPM/ALK. In one study (6), there was complete concordance between anti-p80

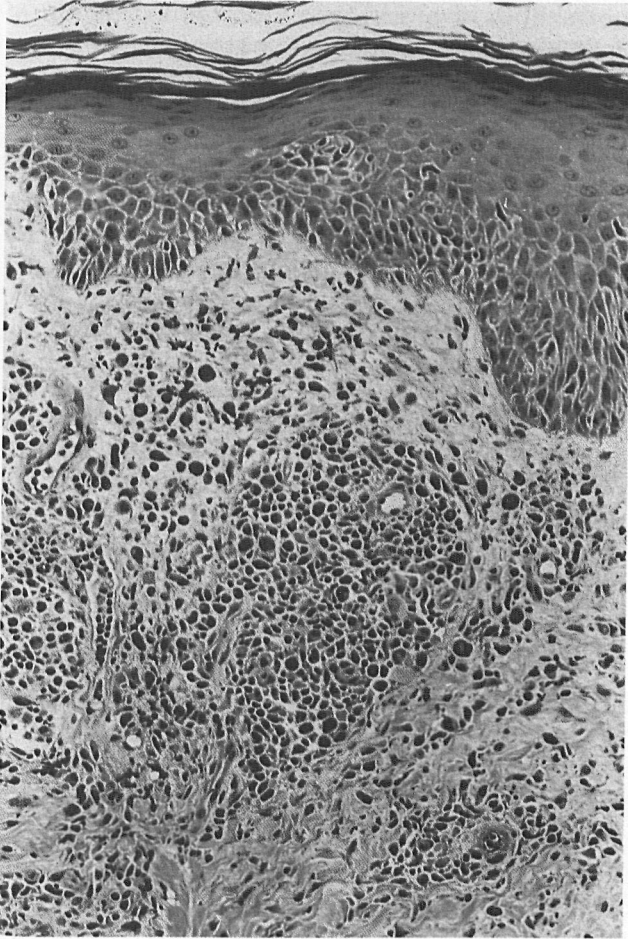


Fig. 3. Perivascular collections of pleomorphic lymphoid cells are admixed with lymphocytes, eosinophils, and some extravasated red cells in lymphomatoid papulosis type A. Endothelial swelling and slight exocytosis accompany the polymorphous dermal infiltrate. In all 24 cases, atypical cells were CD30+ T-cells that did not stain with anti-p80.

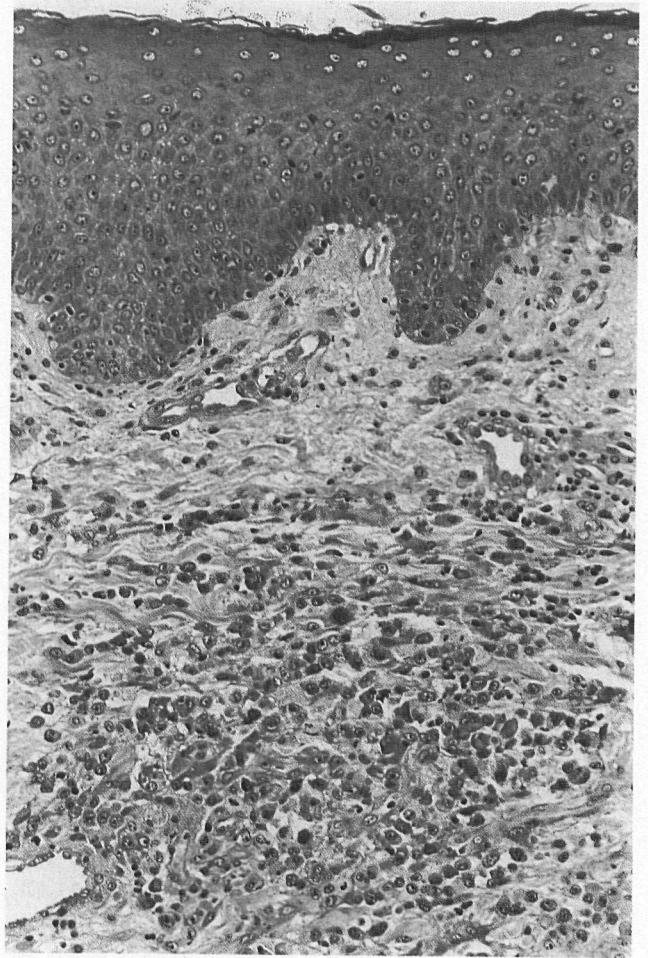


Fig. 4. Sheets of large anaplastic lymphoid cells within dermis in primary cutaneous ALCL from a 57-year-old woman.

staining and RT-PCR, with 3 of 47 lymphomas found positive by both methods. A second study (2) found identical results between anti-p80 immunostaining and in situ hybridization of ALK RNA transcripts in 89 ALCL, 88 Hodgkin's disease, and 40 other lymphoproliferative disorders, with 16 ALCL found positive for ALK gene products.

Only infrequently does anti-p80 immunostaining not correlate with karyotype or molecular assays for t(2;5). For example, in one study (9), 16 of 21 cases showed complete concordance between karyotype, RT-PCR, and anti-p80 staining. In 2 cases, anti-p80 staining agreed with RT-PCR results, but not with karyotype. One case positive for anti-p80 carried a t(1;2) translocation. The remaining 2 discordant cases positive for anti-p80 (1 designated as weak or doubtful positive staining) were not found to have t(2;5) by karyotype or RT-PCR.

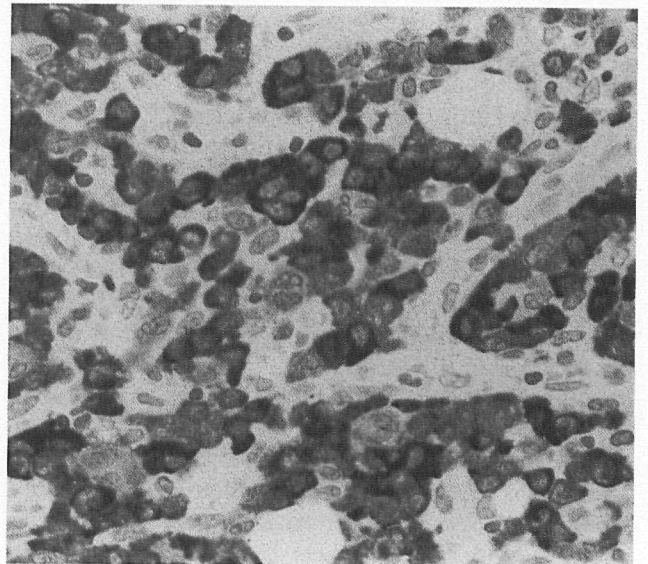


Fig. 5. The cytoplasm of large anaplastic lymphoma cells from Fig. 4 stain strongly with monoclonal ALK1 antibody. These cells also showed weak-to-moderate immunoreactivity with anti-p80 and marked for CD30 and CD43. The malignant cells did not mark for CD20, CD3, or CD45RO.

In a series by Beylot-Barry et al. (8), anti-p80 immunostaining correlated with either RT-PCR or nested RT-PCR in 22 of 23 cases. Interestingly, anti-p80 staining agreed with nested RT-PCR in 2 positive cases in which non-nested RT-PCR failed to detect t(2;5)-associated transcripts. These data suggest that anti-p80 immunohistochemistry will detect almost all lymphoid lesions expressing ALK caused by t(2;5) and perhaps by other abnormalities associated with the 2p23 region. The newly developed murine monoclonal antibody ALK1 appears to be similarly reliable and is reported to show stronger immunoreactivity for tumor cells and less cross-reactivity with non-lymphoid tissues (10).

The goal of our study was to identify CD30+ cutaneous lymphoproliferative lesions that express p80, to check if such cases also carry t(2;5), to compare their incidence to that of nodal ALCL, and to make some conclusion about the relationship of nodal ALCL to cutaneous ALCL. Because immunohistochemical methods are easily performed, we chose to screen our archival cases with anti-p80. Anti-ALK1 and RT-PCR were applied only to confirm anti-p80 immunoreactivity in CD30+ cutaneous lymphoproliferative lesions because such lesions are distinctly unusual.

In the current study, immunoreactivity for anti-p80 was detected in 60% (6/10) of nodal ALCL, one primary cutaneous ALCL (12%, 1/8) and no lymph A (0/24). Like other investigators (5, 9), we tended to see a younger mean age in p80-positive nodal ALCL compared to p80-negative nodal ALCL (29 versus 46 years). The presence of p80 in many nodal ALCL suggests that t(2;5) is involved in its pathogenesis, perhaps by abnormal expression and regulation of ALK (1, 4).

The single primary cutaneous ALCL reactive with anti-p80 occurred in a previously healthy 57-year-old woman who had multiple skin nodules on the trunk. At the time of diagnosis and throughout her follow-up, she did not have evidence of extracutaneous involvement by physical examination, bone marrow biopsy, chest and abdominal CT scans, and gallium scan. She was treated with 6 cycles of cyclophosphamide, adriamycin, vincristine, and prednisone and has had no recurrence of her skin lesions 13 months after initial diagnosis. The lymphoma expressed CD43, but not CD3, CD20, nor CD45RO, and therefore was assigned a T-cell phenotype. NPM/ALK fusion mRNA was not detected in her lesion by RT-PCR. However, abnormal ALK expression detected by anti-p80 was confirmed by immunostaining with monoclonal ALK1. Although the atypical lymphoid cells probably do not carry t(2;5), for which RT-PCR is specific and sensitive, the possibility of other ab-

normalities involving the chromosomal region of 2p23 cannot be excluded. For example, t(1;2) can result in abnormal ALK expression (9, 10).

Two other studies have detected p80 NPM/ALK in primary cutaneous ALCL and/or lymphomatoid papulosis. Beylot-Barry et al. (8) found p80 NPM/ALK in 3 of 10 lymphomatoid papulosis by nested RT-PCR, in situ hybridization, and anti-p80 immunostaining. Lopategui et al. (14) detected p80 in 2 of 6 primary cutaneous ALCL by RT-PCR. All of these data, taken together, suggest that abnormal ALK expression, in some instances attributable to t(2;5), may be seen in a minority of cutaneous CD30+ lymphoproliferative disorders and are infrequently involved in their pathogenesis. Given these results, primary cutaneous ALCL probably cannot be distinguished with certainty from nodal ALCL secondarily involving skin solely by immunostaining with ALK1 or anti-p80. We have no evidence to support a role for t(2;5) or abnormal ALK expression in other non-ALCL lymphomas, although only a few of each subtype were tested in this study.

Acknowledgement

We are grateful to Dr. L. Jeffrey Medeiros for his technical assistance and for editing this manuscript. Dr. Ricardo Valdez and Dr. Celina Kleer also assisted in editing this work. We acknowledge the financial assistance provided by the Leukemia Research Fund, UK, for the development of the ALK1 antibody.

References

1. Morris S, Kirstein M, Valentine M, et al. Fusion of a kinase gene, ALK, to a nucleolar protein gene, NPM, in non-Hodgkin's lymphoma. *Science* 1994; 263: 1281.
2. Herbst H, Anagnostopoulos J, Heinze B, Durkop H, Hummel M, Stein H. ALK gene products in anaplastic large cell lymphomas and Hodgkin's disease. *Blood* 1995; 86: 1694.
3. Wood G, Hardman D, Boni R, et al. Lack of the t(2;5) or other mutations resulting in expression of anaplastic lymphoma kinase catalytic domain in CD30+ primary cutaneous lymphoproliferative disorders and Hodgkin's disease. *Blood* 1996; 88: 1765.
4. Fujimoto J, Shiota M, Iwahara T, et al. Characterization of the transforming activity of p80, a hyperphosphorylated protein in a Ki-1 lymphoma cell line with chromosomal translocation t(2;5). *Proc Natl Acad Sci* 1996; 93: 4181.
5. Shiota M, Nakamura S, Ichinohasama R, et al. Anaplastic large cell lymphomas expressing the novel chimeric protein p80 NPM/ALK: A distinct clinicopathologic entity. *Blood* 1995; 86: 1954.
6. Shiota M, Fujimoto J, Takenaga M, et al. Diagnosis of t(2;5)(p23;q35)-associated Ki-1 lymphoma with immunohistochemistry. *Blood* 1994; 84: 3648.

7. DeCoteau J, Butmarc J, Kinney M, Kadin M. The t(2;5) chromosomal translocation is not a common feature of primary cutaneous CD30+ lymphoproliferative disorders: Comparison with anaplastic large-cell lymphoma of nodal origin. *Blood* 1996; 87: 3437.
8. Beylot-Barry M, Lamant L, Vergier B, et al. Detection of t(2;5)(p23;q35) translocation by reverse transcriptase polymerase chain reaction and in-situ hybridization in CD30-positive primary cutaneous lymphoma and lymphomatoid papulosis. *Am J Pathol* 1996; 149: 483.
9. Lamant L, Meggetto F, Saati T, et al. High incidence of the t(2;5)(p23;q35) translocation in anaplastic large cell lymphoma and its lack of detection in Hodgkin's disease. Comparison of cytogenetic analysis, reverse transcriptase-polymerase chain reaction, and p80 immunostaining. *Blood* 1996; 87: 284.
10. Pulford K, Lamant L, Morris S, et al. Detection of anaplastic lymphoma kinase (ALK) and nucleolar protein nucleophosmin (NPM)-ALK proteins in normal and neoplastic cells with the monoclonal antibody ALK-1. *Blood* 1997; 89: 1394.
11. Delsol G, Lamant L, Mariame B, et al. A new subtype of large B-cell lymphoma expressing the ALK kinase and lacking the 2;5 translocation. *Blood* 1997; 89: 1483.
12. Bruin P, Beljaards R, Heerde P, et al. Differences in clinical behaviour and immunophenotype between primary cutaneous and primary nodal anaplastic large cell lymphoma of T-cell or null cell phenotype. *Histopathology* 1993; 23: 127.
13. Beljaards R, Kaudewitz P, Berti E, et al. Primary cutaneous CD30-positive large cell lymphoma: definition of a new type of cutaneous lymphoma with a favorable prognosis. *Cancer* 1993; 71: 2097.
14. Lopategui J, Sun L, Chan J, et al. Low frequency association of the t(2;5)(p23;q35) chromosomal translocation with CD30+ lymphomas from American and Asian patients. *Am J Pathol* 1995; 146: 323.
15. Sarris A, Luthra R, Papadimitracopoulou V, et al. Amplification of genomic DNA demonstrates the presence of the t(2;5)(p23;q35) in anaplastic large cell lymphoma, but not in other non-Hodgkin's lymphomas, Hodgkin's disease, or lymphomatoid papulosis. *Blood* 1996; 88: 1771.
16. Wellman A, Otsuki T, Vogelbruch M, Clark H, Jaffe E, Raffeld M. Analysis of the t(2;5)(p23;q35) translocation by reverse transcription-polymerase chain reaction in CD30+ anaplastic large-cell lymphomas, in other non-Hodgkin's lymphomas of T-cell phenotype, and in Hodgkin's disease. *Blood* 1995; 86: 2321.
17. Willemze R, Beljaards R. Spectrum of primary cutaneous CD30 (Ki-1)-positive lymphoproliferative disorders – a proposal for classification and guidelines for management and treatment. *Am Acad Dermatol* 1993; 28: 973.
18. Stein H, Dallenbach F. Diffuse large cell lymphomas of B and T cell type. In: Knowles DM, ed. *Neoplastic Hematopathology*. Baltimore: Williams & Wilkins, 1992: 698.
19. Paulli M, Emilio B, Rosso R, et al. CD30/Ki-1-positive lymphoproliferative disorders of the skin – clinicopathologic correlation and statistical analysis of 86 cases: a multicentric study from the European Organization for Research and Treatment of Cancer Cutaneous Lymphoma Project Group. *J Clin Oncol* 1995; 13: 1343.
20. Shi SR, Key ME, Kalra K. Antigen retrieval in formalin-fixed, paraffin-embedded tissues: An enhancement method for immunohistochemical staining based on microwave oven heating of tissue sections. *J Histochem Cytochem* 1991; 39: 741.
21. DeCoteau J, Kinney M, Kadin M. Presence of t(2;5) in primary CD30+ cutaneous lymphoproliferative disorders. *Blood* 1996; 88: 3240.

This document is a scanned copy of a printed document. No warranty is given about the accuracy of the copy. Users should refer to the original published version of the material.