

Histopathologic evaluation of the effects of four calcium hydroxide liners on monkey pulps

D. R. HEYS, R. J. HEYS, C. F. COX AND J. K. AVERY

Departments of Oral Biology and Operative Dentistry, School of Dentistry, The University of Michigan, Ann Arbor, Michigan, U. S. A.

Abstract. Pulpal response of four calcium hydroxide liners, MPC 10®, MPC 12®, Dycal® and Pulpdent® were tested on primary and permanent teeth with zinc oxide and eugenol (ZOE) and silicate as controls. Responses of the pulps were evaluated in Rhesus monkeys, utilizing Class V cavity preparations at 3 days, 5 and 8 weeks. An equivalent number of anterior and posterior teeth were studied for all compounds. The Ca(OH)₂ liners, zinc oxide and eugenol (ZOE) and silicate controls were placed in 80 primary and 80 permanent teeth. Following perfusions the teeth were prepared utilizing routine histological procedures. The 3 day response of the calcium hydroxides was moderate with some disruption in the odontoblasts, vacuolization and mild inflammation underlying the cavity except Pulpdent which was more severe. At 5 weeks a decrease in inflammatory response and the formation of reparative dentin was similar for all calcium hydroxides tested at this time period. At 8 weeks more reparative dentin was noted with slight to moderate pulpal responses. At all time periods ZOE produced the least pulpal response while silicate produced the most severe response at 5 and 8 weeks.

This study reports the biological responses of four calcium hydroxide compounds used as cavity liners in non-exposures in a series of primary and permanent teeth of monkeys using ZOE and silicate as controls. Responses to the four Ca(OH)₂ compounds were moderate for all the experimental compounds except Pulpdent which was more severe at the early time period tested. ZOE produced a milder and silicate a severe response at all periods. All of these compounds were placed by random selection in anterior and posterior teeth of both arches and five teeth were evaluated in both primary and permanent teeth at 3 days, 5 and 8 weeks.

Received 17 November, accepted for publication 22 December 1975

For many years calcium hydroxide has been used principally as a direct pulp capping agent or in areas of deep decay as an indirect pulp capping agent. Today, the dental profession has turned to Ca(OH)₂ as a pulp-protecting liner under composite resins to protect the underlying pulp. Tron-

stad & Mjör (1972) placed cavities containing Pulpdent®, Dycal® and Hydrex® in permanent monkey teeth. After 8 days they observed a similar range of reaction for all compounds. The response was characterized by slight disturbances in the odontoblastic regions, mild hyperemia, and ?

This study was supported, in part, by a research grant from Kerr Manufacturing Company, Romulus, Michigan, U. S. A.

slight increase in cellularity resulting in loss of the cell-free zone. After 69 days, all teeth had varying amounts of reparative dentin, with Hydrex having less reparative dentin than Dycal or Pulpdent. Pulpal tissue underlying the reparative dentin appeared normal.

Ostrom & Lyon (1962) compared Pulpdent with heterogenous chemically treated bone in dog teeth with near exposures. After 30 days one specimen had a healthy appearance with minimal accumulation of inflammatory cells and necrosis beneath the cavity preparation. After 60 days four teeth were examined. One of the four had a healthy pulp while the remaining three showed an accumulation of inflammatory cells and zones of necrosis beneath the cavity preparation. After 90 days two teeth were examined and no healthy pulp tissue was seen beneath the cavity preparation. Pappas & Masler (1959) used Pulpdent as a liner in shallow and deep cavities under silicate and showed that Pulpdent reduced the severity of pulpal response when compared to unlined cavities.

Safer (1971) evaluated Hydrex in permanent monkey teeth. After one week in non-exposures he found odontogenic zone disruption and increased cellularity. After 3 weeks varying amounts of reparative dentin were present. After 8 weeks more reparative dentin was noted and the response was still in the moderate range. Baume et al. (1972) placed zinc oxide and eugenol (ZOE) and Hydrex in contralateral teeth for periods of 32, 120 and 200 days in cavities of approximately 1 mm. In 13 of 20 cases the zinc oxide eugenol provoked only a slight response. In seven instances there was sparse infiltration of leukocytes and a local apposition of tertiary dentin. In contrast, Hydrex was well tolerated in only four instances, five pulps showed moderate reaction and 11 a severe reaction. The more intense response

showed multiple vacuoles lined by macrophages and plasmocytes.

Hirschfeld et al. (1972) studied the effect of Hydrex on the pulps of rat molars in indirect non-exposures. Three teeth with deep cavities were studied at 4 weeks and another three teeth at 8 weeks. After 4 weeks, three animals were examined; two showed no changes and one had slight chronic inflammation. At 8 weeks all three showed congestion and two chronic inflammation.

It is the purpose of this study to make use of the American Dental Association standards (1974) for testing of dental materials which encourages the use of more uniform testing procedures in studying the effects of restorative agents on pulp response. The biologic response of various calcium hydroxides used as cavity liners were studied in both primary and permanent dentitions in the anterior and posterior teeth of the maxilla and the mandible. The response of the four calcium hydroxide compounds (Dycal®, Pulpdent®, MPC-10®, and MPC-12®) were compared utilizing ZOE and silicate as controls.

Material and Methods

The placement of the materials was predetermined according to a random selection of all teeth making certain that restorations were placed in anterior and posterior teeth of both arches. Each material was placed in five permanent and five primary teeth at three time periods: 3 days, 5 and 8 weeks according to the American National Standards Committee MD 156 (1974) recommendation of cavity selection and preparation for dental materials and devices.

A total of 80 permanent and 80 primary Rhesus monkey teeth were used. In the permanent teeth Class V cavities were prepared by high speed air turbine (200,000–300,000 RPM) with water and air spray

using # 35 inverted cone burs. The depth of the cavities was one and one-half times the height of the bur head and the width of the cavity was twice that of the bur head. This resulted in a cavity with approximately 0.5 mm remaining dentin. In primary teeth Class V cavities were prepared with a high speed air turbine using # 33 ½ inverted cone bur. The cavity depth was one and one half times the cutting head of the bur and the width of the cavity was twice that of the bur head. This resulted in a cavity depth with approximately 0.5 mm dentin between the floor of the cavity and the pulp.

The compounds in this study were Dycal*, Pulpdent**, Multi-Placement Compounds with pH of 10 (MPC-10)*** and Multi-Placement Compounds with pH of 12 (MPC-12)**** with ZOE (Cavitec®)***** and Silicate (M. Q.)***** controls.

At the time of sacrifice, the monkeys were anesthetized and perfused with 10 % phosphate buffered formalin (PBF). The teeth were surgically removed from the jaws, decalcified, embedded in paraffin, serially cut at 10 microns, and stained with hematoxylin and eosin.

In an attempt to control bias the tissue sections were evaluated by the investigators prior to their knowledge of which liners were involved. Histological evaluation of the tissues was accomplished by a modification of Stanley's criteria (Stanley &

Swerdlow 1959). Responses were categorized into slight, moderate and severe.

A slight reaction was characterized by a slightly increased cellularity in, and adjacent to, the cell-free zone corresponding to the cavity tubules. Some of these cells were typical inflammatory cells, mainly granulocytes. A mild hyperemia was found in the pulp tissue adjoining the cavity tubules, and small irregularities in the odontoblastic layer were found, often associated with a displacement of odontoblastic nuclei into the dentinal tubules. The predentin could be reduced in width.

A moderate reaction was characterized by a distinctly increased cellularity, and granulocytes were found. A localized hyperemia with occasional hemorrhage in the odontoblast and subodontoblastic region was observed. Furthermore, the odontoblastic layer was discontinuous, and many odontoblastic nuclei could be displaced into the dentinal tubules. The predentin could be reduced in width or absent entirely.

A severe reaction was characterized by marked cellular infiltration, mainly granulocytes, in the pulp tissue subjacent to the cavity tubules, and localized abscess formation could also be observed. Signs of congestion could be found surrounding the cellular infiltration, and hemorrhages could be seen. Furthermore, the odontoblastic layer was disrupted or destroyed, and sometimes many odontoblastic nuclei were displaced into the dentinal tubules. The predentin could be reduced in width or absent entirely.

The following responses were evaluated: (1) odontogenic zone disruption, (2) hemorrhage, (3) inflammatory cell infiltration, (4) fibrotic walling off, (5) necrosis and abscess formation, (6) response dentin formation according to amount and quality, and (7) changes in overall pulp architecture. Remaining dentin measurements were

* L. D. Caulk Company, Milford, Delaware.

** Pulpdent Corporation, Boston, Massachusetts.

*** Kerr Manufacturing Company, Romulus, Michigan.

**** Kerr Manufacturing Company, Romulus, Michigan.

***** Kerr Manufacturing Company, Romulus, Michigan.

***** S. S. White Company, Philadelphia, Pennsylvania, U. S. A.



Fig. 1

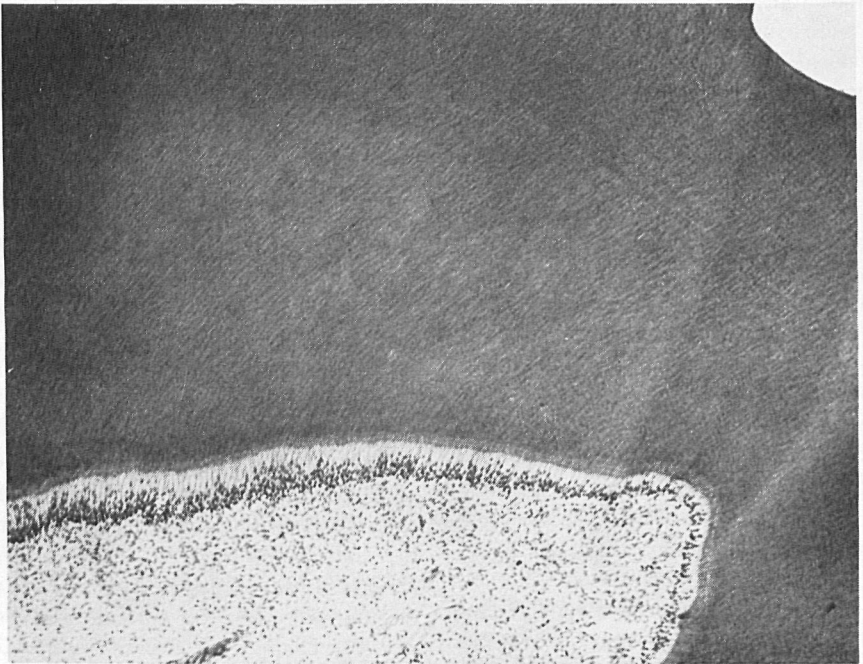

Fig. 2

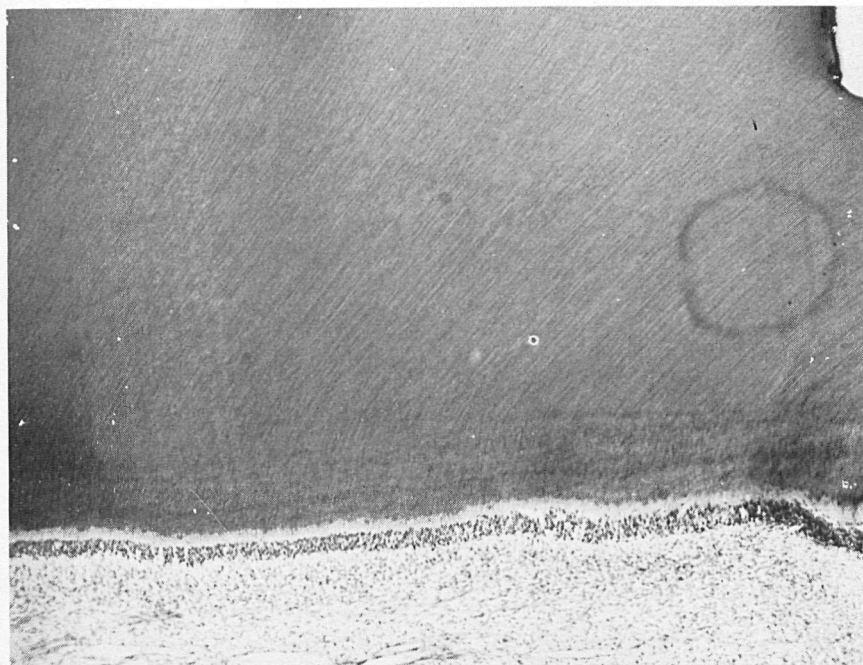


Fig. 3. Calcium hydroxide liner, MPC-10. A 3 day pulpal response of a permanent tooth. There is a moderate histological response with some vacuolization of the pulp adjacent to the disrupted odontoblasts. A few scattered inflammatory cells are present. $\times 58$.

made with a Zeiss micrometer. All measurements were made from the deepest area of the floor of the cavity and perpendicular to the pulp or to the site of deposition of reparative dentin. Reparative dentin thickness was measured from points perpendicular from its site of inception to the pulp.

Results

The three day responses of MPC-12 (Fig.

1), Dycal (Fig. 2), and MPC-10 (Fig. 3) were similar in both primary and permanent teeth. The pulpal response was moderate and it was characterized by disruption in the odontoblastic layer with areas where the odontoblasts had lost their columnar appearance and their nuclei were crowded near the predentin. The cell-free zone had been lost beneath the cavity preparation, due to the presence of polymorphonuclear leukocytes in this area. The surrounding pulpal tissue appeared normal.

Fig. 1. Calcium hydroxide liner, MPC-12. A 3 day pulpal response of a permanent tooth. The histologic response is moderate with disruption of odontoblasts adjacent to the tubules of the cavity preparation. Some scattered inflammatory cells are present in the adjacent pulp. $\times 58$.

Fig. 2. Calcium hydroxide liner, Dycal. A 3 day pulpal response on a permanent tooth. A slight to moderate histological response with some odontoblastic disruption. There is evidence of increased pulpal cellularity underlying the irritated odontoblasts. $\times 58$.

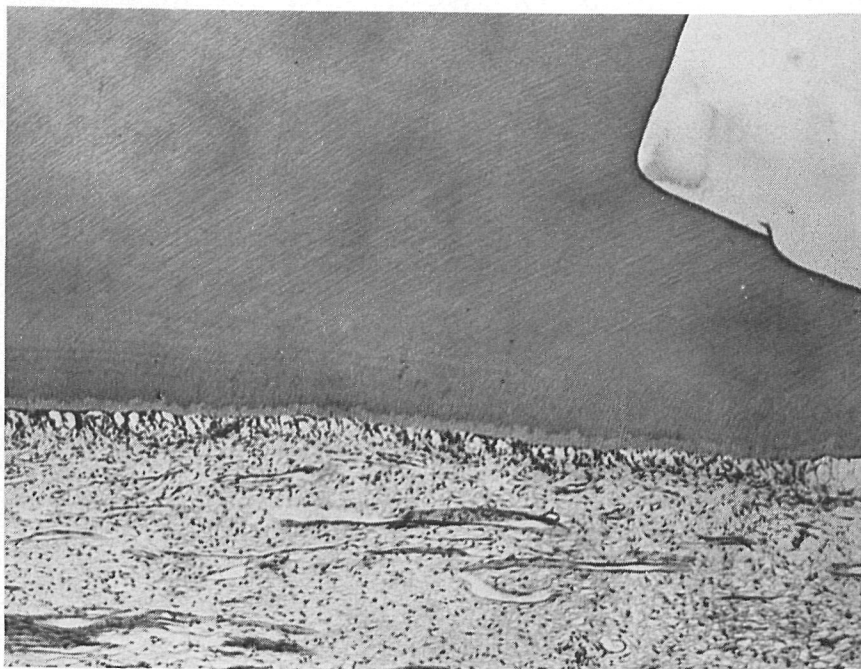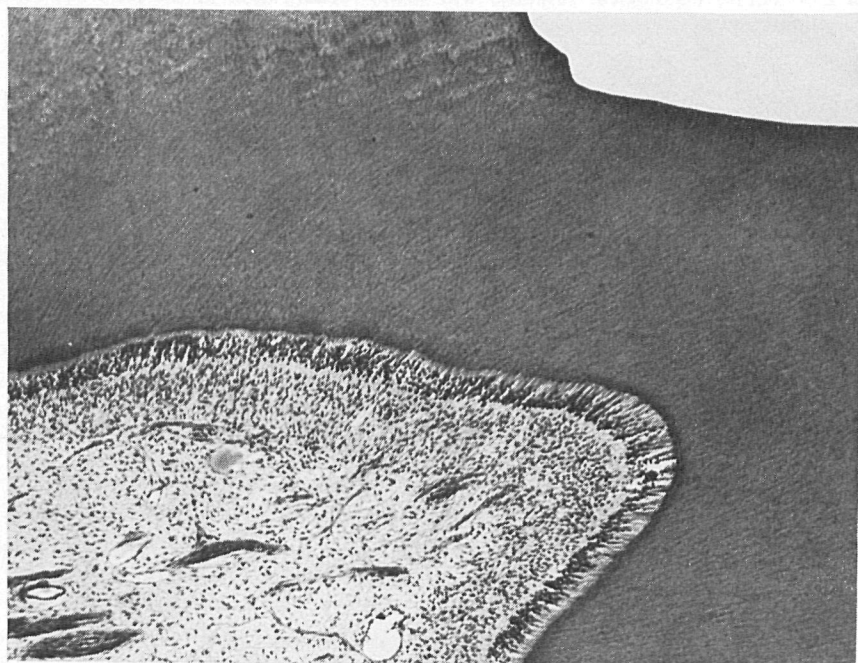*Fig. 4**Fig. 5*



Fig. 6. Control, Silicate, (MQ) - S. S. white. A permanent tooth 3 days after placement of Silicate shows a moderate histological response characterized by disruption, vacuolization and loss of the normal architecture of the odontoblastic layer. An increase in pulpal cellularity and presence of inflammatory cells in the subjacent pulpal tissues is evident. $\times 40$.

In contrast to this, Pulpdent's response in both dentitions (Fig. 4) was more severe. The response was characterized by an almost complete loss of the odontoblastic layer. The reaction extended further into the pulp with a larger amount of pulpal damage than seen with the other three calcium hydroxides, although not shown in Fig. 4. The 3 day response of the ZOE control (Fig. 5) was slight. The pulpal histology was characterized by slight disruption

of the odontoblastic region, although a loss of the cell-free zone was observed. The 3 day response of the silicate control (Fig. 6) was judged to be a moderate reaction, a response of obviously greater intensity than Dycal, MPC-10, and MPC-12. A disruption of the odontoblastic layer beneath the cavity preparation appeared and was characterized by a large number of inflammatory cells, areas of vacuolization, some aspirated nuclei and areas where

Fig. 4. Calcium hydroxide liner, Pulpdent. A 3 day pulpal response of a permanent tooth. A moderate to severe histologic response with vacuolization and partial loss of odontoblasts. $\times 58$.

Fig. 5. Control, zinc oxide eugenol, Cavitec. A 3 day primary tooth pulp response is slight with very little disruption of the odontoblastic zone. There is little increased cellularity or presence of inflammatory cells. $\times 40$.




Fig. 7

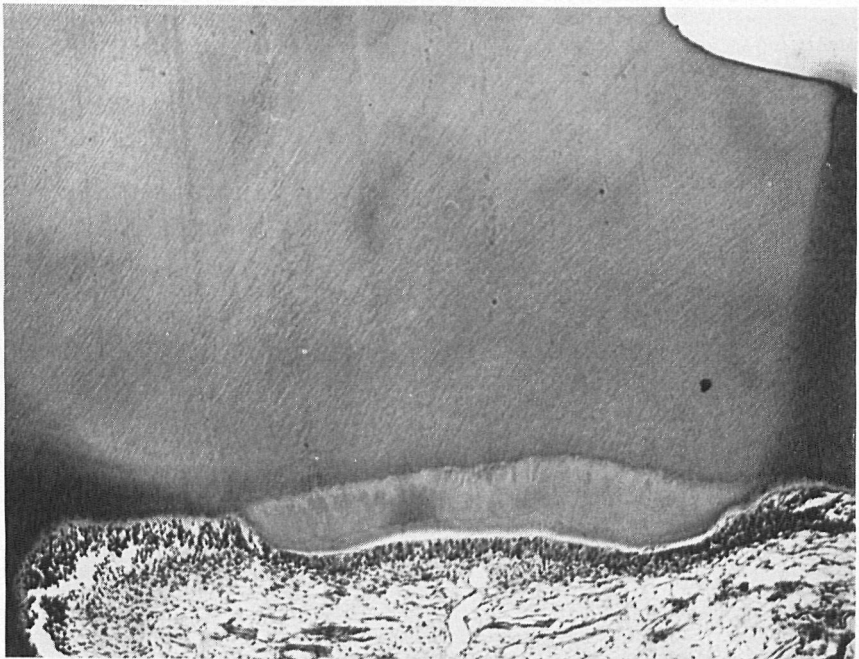


Fig. 8

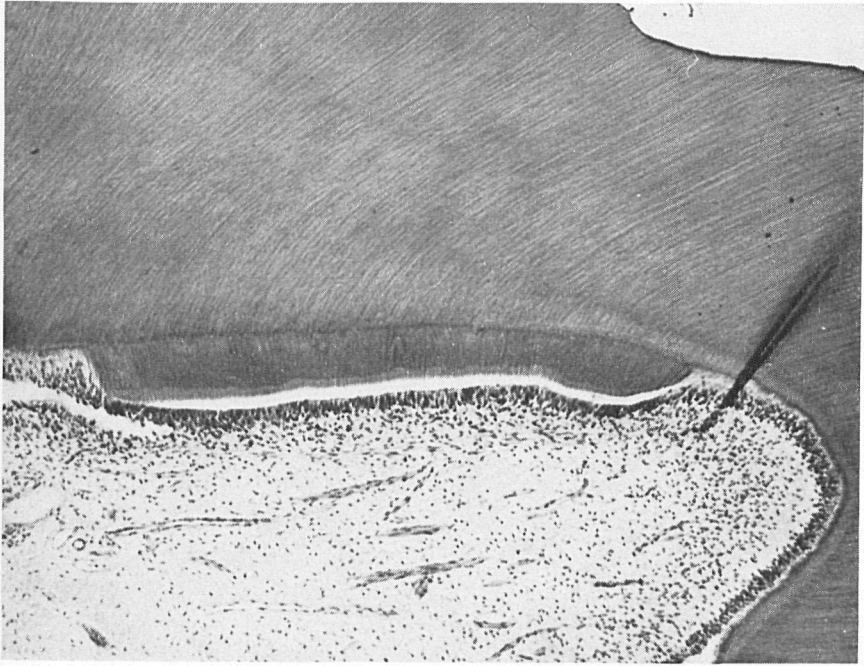

Fig. 9. Calcium hydroxide liner, MPC-10. A 5 week non-exposure response of an anterior permanent tooth. This is slight to moderate histological reaction, with tubular reparative dentin beneath the cavity preparation. A few inflammatory cells are present in the subjacent pulp tissues. $\times 64$.

the odontoblasts had changed from a characteristic columnar to an oval shape.

The 5 week responses for all the calcium hydroxide compounds appeared similar (Figs. 7-10). Pulpdent which presented a more severe reaction at 3 days now appeared similar in response to the other three compounds (Fig. 10). Each compound elicited a slight to moderate response in both primary and permanent teeth. Thus

there appeared to be a reduction in inflammatory cells from that seen at 3 days. The response was characterized in all cases by a zone of greater thickness of reparative dentin underlying the cavity preparation. This dentin was composed of several identifiable zones. First, there appeared a zone composed of initially deposited dentin which was irregular in nature containing many entrapped nuclei. A second zone

Fig. 7. Calcium hydroxide liner, MPC-12. A 5 week response non-exposure of a primary tooth. A slight histological response with very few inflammatory cells. An area of tubular reparative dentin is present beneath the cavity preparation. $\times 66$.

Fig. 8. Calcium hydroxide liner, Dycal. A 5 week non-exposure response of a primary tooth. A slight histological reaction with minimal inflammatory cell infiltration is present. A zone of tubular reparative dentin is present with the characteristic row of odontoblasts adjacent to it. The remainder of the pulp is normal in appearance. $\times 62$.

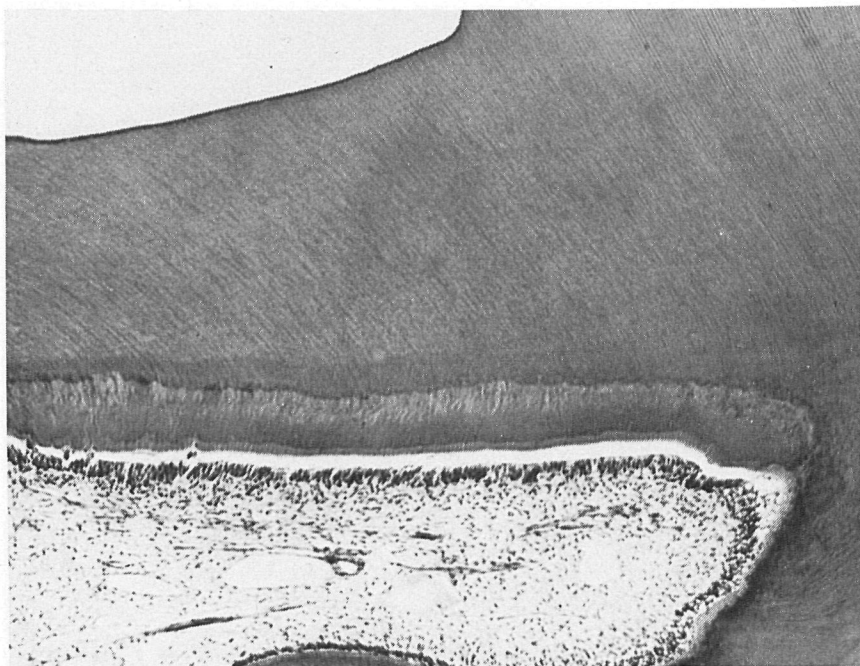
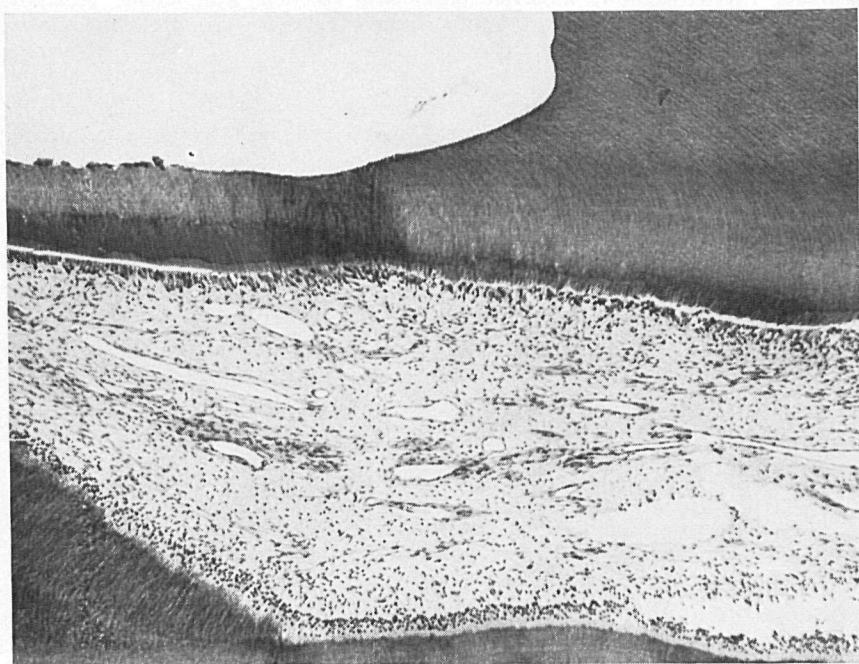
*Fig. 10**Fig. 11*



Fig. 12. Control material, silicate, (MQ) - S.S. White. A 5 week non-exposure characterized by a severe pulpal response. There is a thin band of reparative dentin with complete loss of the odontoblastic layer. Inflammatory cells affecting a large portion of the coronal pulp are evident. $\times 39$.

of reparative dentin contained regularly spaced tubules free of defects. The third zone was a band of pre-dentin ($15-18 \mu$). The odontoblastic layer was intact in all cases and the cytoplasm of the cells had a darker staining quality and seemed more granular in appearance than that found in areas not affected by cavity preparation. There were few inflammatory cells in the

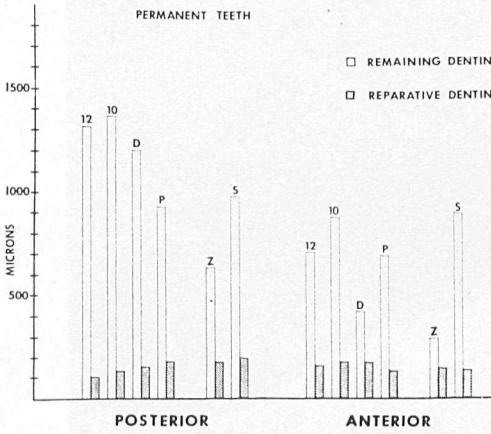
pulp underlying the cavities. The ZOE control at 5 weeks had a very mild response in both dentitions (Fig. 11). This response appeared as a small area of reparative dentin. Less irregularity was apparent in the initially deposited reparative dentin than was seen with the calcium hydroxide compounds. The odontoblastic layer appeared intact and had a darker staining quality

Fig. 10. Calcium hydroxide liner, Pulpdent. A 5 week non-exposure response of a permanent tooth. A slight to moderate histological pulpal response is evident. A tubular reparative dentin with some adjacent cellular inclusions and very few inflammatory cells are present below the cavity preparation. $\times 46$.

Fig. 11. Control material, zinc oxide eugenol Cavitec. A 5 week non-exposure response of a primary tooth. A very mild histological response is evident. A small amount of reparative dentin was found beneath the cavity preparation. The odontoblasts are intact and very few inflammatory cells are present beneath the cavity. $\times 44$.

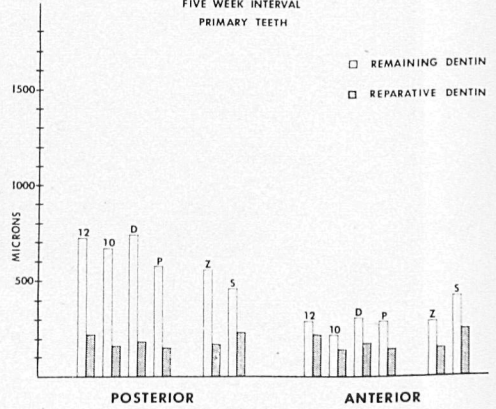
GRAPH 1

COMPARISON OF REMAINING
TO REPARATIVE DENTIN
FIVE WEEK INTERVAL
PERMANENT TEETH



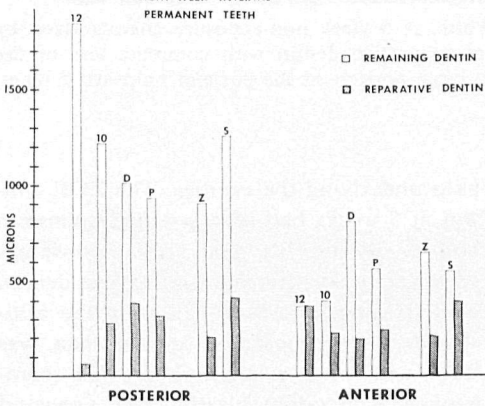
GRAPH 2

COMPARISON OF REMAINING
TO REPARATIVE DENTIN
FIVE WEEK INTERVAL
PRIMARY TEETH



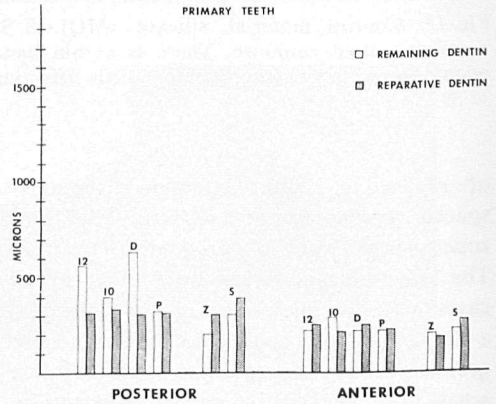
GRAPH 3

COMPARISON OF REMAINING
TO REPARATIVE DENTIN
EIGHT WEEK INTERVAL
PERMANENT TEETH



GRAPH 4

COMPARISON OF REMAINING
TO REPARATIVE DENTIN
EIGHT WEEK INTERVAL
PRIMARY TEETH



Graphs 1-4

Legend: 12 = MPC-12
10 = MPC-10
D = Dycal
P = Pulpdent
Z = Zinc oxide eugenol
S = Silicate

than other pulpal odontoblasts of the same tooth. The region of the cell-free zone contained a few inflammatory cells. The 5 week silicate response ranged from mode-

rate to severe depending on cavity depth (Fig. 12). In spite of the more severe response, this compound produced some reparative dentin at this time interval. The

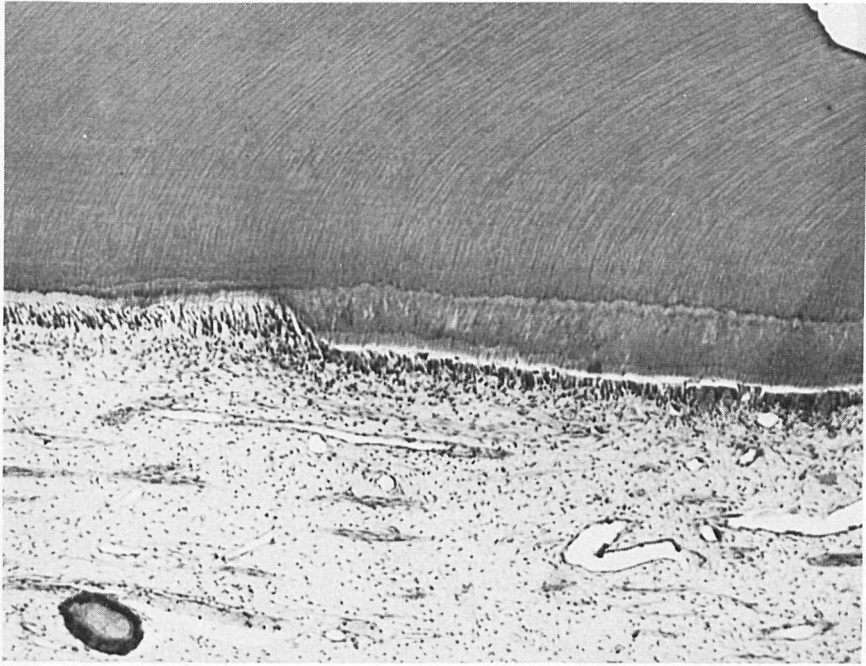


Fig. 13. Calcium hydroxide liner, MPC-12. An 8 week non-exposure response of a primary tooth. A slight pulpal response with a zone of tubular reparative dentin is present below the cavity preparation. The odontoblastic zone is present with minimal cellular infiltration. $\times 46$.

initial reparative dentin formed was irregular in nature and contained cellular inclusions. The remainder of this dentin was more regular in appearance except for a widened predentin zone. The odontoblastic layer was present but exhibited areas of slight vacuolization and disruption whereas in other areas it was almost completely lost. The underlying pulpal tissue had many inflammatory cells, areas of necrosis and abscess formation. Reparative dentin measurements of the permanent teeth (Graph I) for this time period show the amounts of reparative dentin vary. Generally it seemed that as the cavity depth increased, more reparative dentin was recorded. All the $\text{Ca}(\text{OH})_2$ compounds showed similar amounts of reparative dentin. Reparative dentin measurements

show that there is a difference between the amount of remaining dentin between anterior and posterior teeth. The measurements show that posterior teeth have more remaining dentin and yet have comparable amounts of reparative dentin to that recorded in anterior teeth. ZOE and silicate controls in both anterior and posterior teeth have similar amounts of reparative dentin to that the $\text{Ca}(\text{OH})_2$ compounds. Graph 2 shows the reparative dentin measurements of primary teeth after 5 weeks. The measurements show that there is less remaining dentin in primary than permanent teeth but the amounts of reparative dentin between primary and permanent teeth are very similar.

The 8 week response of all the calcium hydroxide compounds tested appeared to

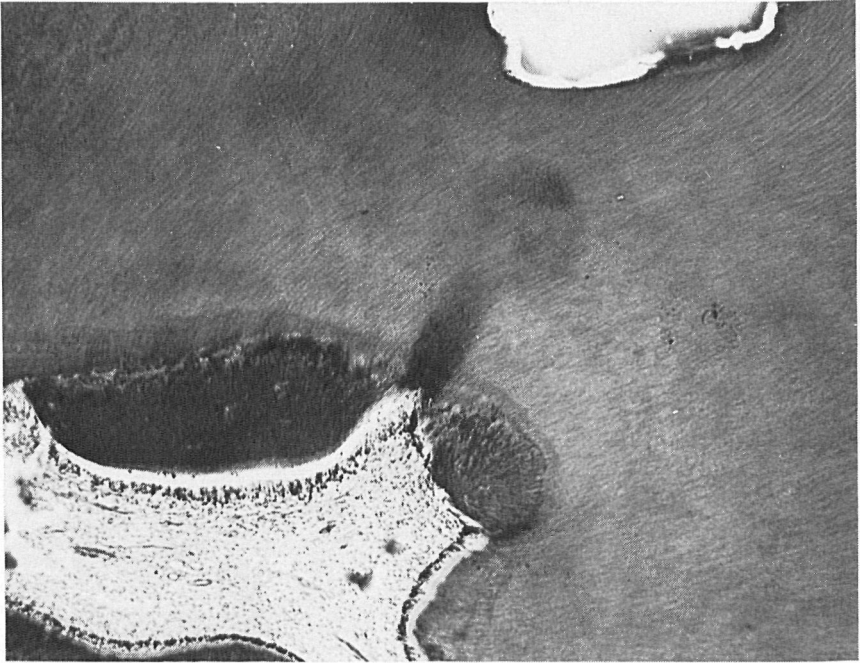

Fig. 14




Fig. 15

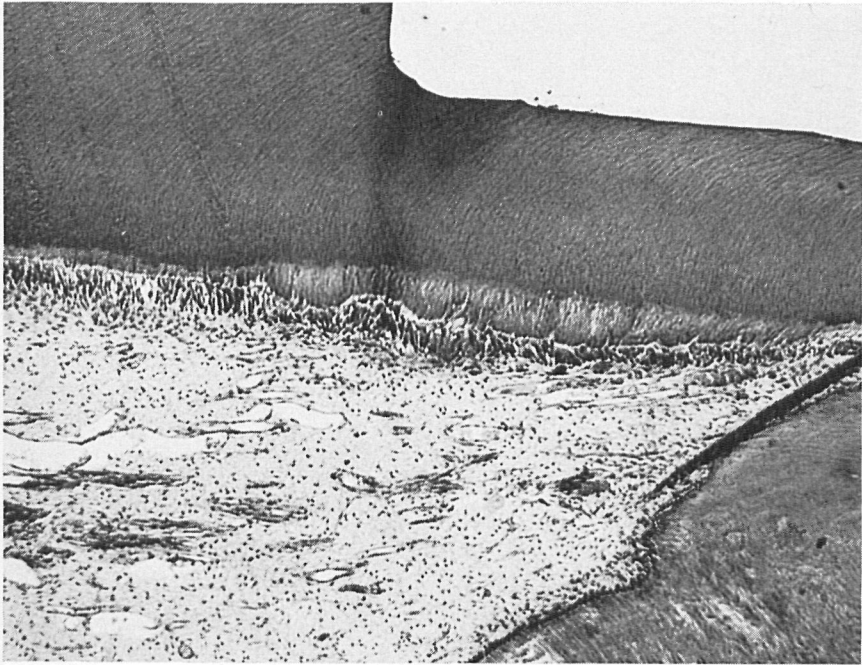


Fig. 16. Calcium hydroxide liner, Pulpdent. An 8 week non-exposure response with a band of tubular reparative dentin below the cavity preparation. Some inflammatory cellular infiltrates are present adjacent to the odontoblastic layer. $\times 64$.

be slight (Figs. 13–16). This response was generally characterized by additions of reparative dentin in excess of that seen at 5 weeks by 50–100 microns. The odontoblasts appeared columnar and retained a more granular staining cytoplasm than odontoblasts not affected by cavity preparation and these restorations. Few inflammatory cells were now present. The ZOE control at this time period exhibited a slight response (Fig. 17). Reparative dentin was present beneath the cut tubules

of this cavity preparation. This reparative dentin was regular and appeared similar to that developed by 5 weeks, representing only a slight increased amount over that period. The odontoblasts were columnar in shape with similar staining properties when compared with odontoblasts not affected by cavity preparation. There was some evidence of chronic inflammatory cell infiltration characterized by scattered macrophages and lymphocytes. The 8 week silicate controls exhibited a range of response ex-

Fig. 14. Calcium hydroxide liner, Dycal. An 8 week pulpal response of a positive permanent tooth. A tubular band of reparative dentin is present with a slight increase in the number of inflammatory cells adjacent to the odontoblastic zone. $\times 58$.

Fig. 15. Calcium hydroxide liner, MPC-10. An 8 week non-exposure response of a primary tooth. A very mild histological reaction is present with tubular reparative dentin adjacent to an intact odontoblastic layer. Very few inflammatory cells are present. $\times 83$.

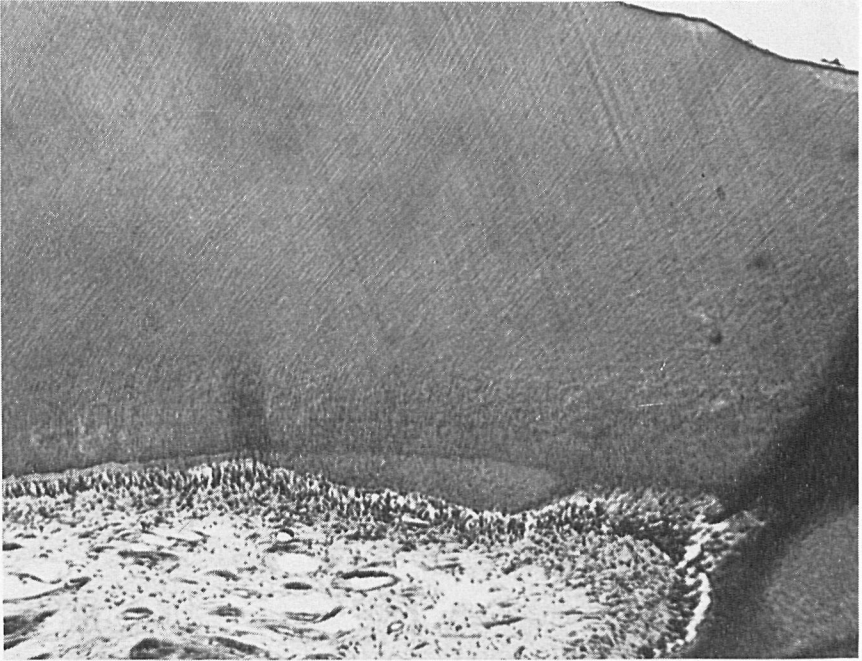


Fig. 17. Control zinc oxide eugenol, Cavitec. An 8 week non-exposure response of a permanent tooth. A very mild pulp reaction characterized by reparative dentin underlying the cavity preparation is present. The odontoblastic layer is intact with very few inflammatory cells. $\times 59$.

tending from moderate to severe (Fig. 18). In teeth with moderate responses there were large amounts of reparative dentin similar to the amounts recorded at 5 weeks although more abundant. The odontoblasts of the area were darker staining in character and exhibited more granular cytoplasm. Some chronic inflammation was present in the pulp adjacent to the odontoblasts. Deep cavities of less than 300 microns of remaining dentin produced a severe response with almost a total loss of the odontogenic zone and an extensive amount of chronic inflammation in the subjacent pulp. The response occupied the majority of the coronal pulp underlying the cavity preparation. Reparative dentin measurements of permanent teeth (Graph 3) for this time period show a similar

trend in the amount of reparative dentin as the quantity seen at 5 weeks. Differences in the amount and shape of the reparative dentin were noted between anterior and posterior teeth. In the incisors the reparative dentin was longer and thinner when compared to posterior teeth in which it appeared short and thicker. It can be noted that the dentinal tubule configuration in anterior teeth is less curved and the area of the cavity preparation is similar in size to that of the area of reparative dentin. In the posterior teeth the dentinal tubule configuration is more curved when compared to anterior teeth (Figs. 9 and 14) and the area of reparative dentin is smaller in size than the area of cavity preparation. At this time period the amount of reparative dentin found beneath ZOE




Fig. 18. Control silicate, (MQ) – S. S. White. An 8 week pulpal response with a moderate histological reaction. A very wide band of tubular reparative dentin is present. There is some disruption of the odontoblastic layer and subjacent pulpal tissue and inflammatory cells adjacent to the reparative dentin. $\times 46$.

tended to be less in amount when compared to the $\text{Ca}(\text{OH})_2$ compounds while silicate definitely produced more reparative dentin after 8 weeks than all the rest of the compounds tested. Graph 4 shows that the reparative dentin measurements of primary teeth are similar in amount and pattern to those seen with the permanent teeth.

Discussion

The purpose of this study was to evaluate the biological response of primary and permanent monkey pulps to four calcium hydroxide preparations with ZOE and silicate as controls and to exclude as many variables as possible by following the A. D. A. standards.

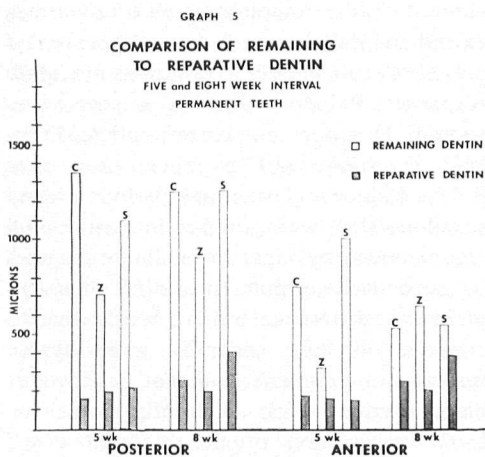
The four calcium hydroxide compounds showed similar responses at all time periods except for Pulpdent at 3 days. Whereas Dycal, MPC-10 and MPC-12 showed moderate responses Pulpdent showed a severe response. This does not correspond to Tronstad & Mjör's (1972) report that after 8 days Pulpdent, Dycal and Hydrex elicited reactions that were similar in nature and characterized by slight to moderate changes in the underlying pulp. It is difficult to explain this difference but we would like to comment on the generally more severe response of Pulpdent. Pulpdent has a water based carrier, which apparently allows for faster penetration of the material down the dentinal tubules in contrast to the other products in which salicylate systems are utilized. Thus faster penetration coupled

with the fact that Pulpdent has a pH of 12.5 may account for the increased severity of its initial response.

In comparing the calcium hydroxide compounds with ZOE at the various time periods, ZOE produced a milder response at all time periods, however, at 8 weeks, pulpal responses of ZOE and the calcium hydroxides are similar. The major difference at this time is that the ZOE tends to cause a smaller amount of reparative dentin to be developed under the cut tubules of the cavity preparations. The silicate control exhibits a similar response to the calcium hydroxides at 3 days. A possible explanation for this may be that most of the total response at this time period is due to cavity preparation, and the effects of the phosphoric acid has not yet noticeably affected the pulp. The 5 and 8 week silicate response was thus more severe than the calcium hydroxides tested. So apparently, after the trauma of cutting is overcome, the effect of the PO_4 acids becomes apparent.

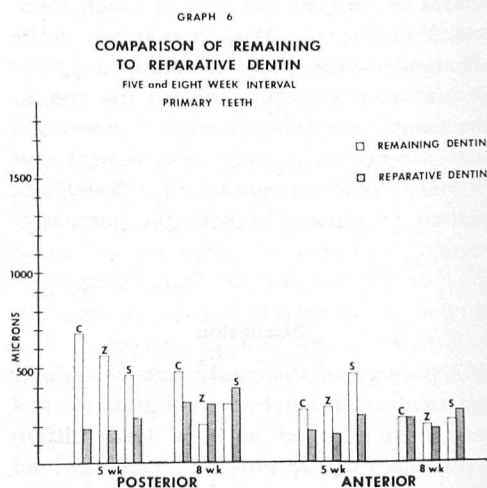
The effect of altering the pH of MPC from 10 to 12 did not seem to affect the histological response at any of the time periods observed. The response of both primary and permanent teeth was similar for both compounds tested. No specific reason can be given for this except that perhaps 0.5 mm remaining dentin is a sufficient amount to protect the pulp from excessive damage if the material placed within the cavity is not too caustic. Mjör & Haugen (1974) stated that the limiting factor in any evaluation criteria is the error introduced by the histological processing of the tissue. With this in mind it appears that any subtle changes in histological structure may be due to the tissue preparation as well as the effects of the material tested.

In recording the amount of remaining dentin underlying the cavity preparation, the data (Graphs 1-6) showed a range of values above and below 0.5 mm. This indicated that even though attempts were made to reduce these variations, they seem



Graphs 5-6

Legend: C = Combined calcium hydroxide compounds
Z = Zinc oxide eugenol
S = Silicate



impossible to eliminate totally. These variations are due to the difference in size from one monkey to the next and the variation in size from molars to incisors. Because of this variation in remaining dentin it is difficult to compare the amount of reparative dentin. Although no specific facts can be stated, general trends can be seen. ZOE seems to produce the least amount of reparative dentin whereas silicate produces the most reparative dentin after 5 and 8 weeks.

The four Ca(OH)_2 compounds produced similar amounts of reparative dentin, which was greater in amount than ZOE, but less than that of silicate. Reparative dentin production can be related to at least two things. One is that different compounds will induce the production of varying amounts of reparative dentin. Secondly, the deeper the cavity preparation, the more reparative dentin will be formed. A final point must be made. Since all these compounds were tested in teeth which had healthy pulpal tissue, nothing can be said about their effect upon inflamed pulps or teeth with carious lesions.

A statistical analysis was carried out on the data found in Graphs 1-6 in order to identify potential correlation between any variables such as the relationships between the compound and the amount of reparative dentin formed. Correlations were run on both 5 and 8 week data. There were no correlations between any of the variables in our data. One reason for this may be that there is a considerable range in the amount of remaining dentin underlying the cavity preparation. Another reason is that we classified our pulpal responses into three categories. It is our feeling that in doing so we are not being specific enough in our evaluations. Such categorization tends to place most of the results in the middle category with fewer in the two remaining categories. It is our opinion that a more

detailed categorization of pulpal response must be developed in order to delineate more subtle responses with a possible result of making our data more amenable to statistical evaluation.

In an attempt to quantify the amount of reparative dentin produced with various types of compounds tested, we have made use of histograms to compare the data. Comparing the data in Graphs 1-6 it can be seen that the amount of reparative dentin produced by all six compounds is within the same range. Variations can be seen relative to the amount of remaining dentin. Posterior teeth have more remaining dentin, but show similar amounts of reparative dentin. The 8 week Graphs (3-6) show greater differences. In comparing the anterior and posterior teeth it can be seen that even though there is more remaining dentin in the posterior teeth there is more reparative dentin produced.

In primary teeth the cavity preparations result in less remaining dentin than the permanent dentition, but the amount of reparative dentin is similar to that found in the permanent dentition. This is difficult to explain because usually the deeper a cavity preparation the more reparative dentin, but this is not the case when we compare the primary to permanent teeth. This may be due to a decrease in vascularity as the primary tooth ages and also an increased fibrosis which makes the pulp less responsive to stimuli.

The summary Graphs (5 and 6) show the comparison of anterior and posterior teeth at time intervals of 5 and 8 weeks. After 8 weeks there is a trend for ZOE to produce the least amount of reparative dentin and for silicate to produce the most. The Ca(OH)_2 compounds produce slightly more reparative dentin than ZOE.

References

- American National Standards Committee Z-156 for Dental Materials and Devices (1974).
- Baume, L. J., Holtz, J., Fiore-Donno, D. & Geneve, S. (1972) Produits intermédiaires d'obturation soumis au test biologique normalisé. *Journal of the Canadian Dental Association* 38, 18-27.
- Hirschfeld, Z., Sela, J. & Ulmanky, M. (1972) Hydrex and its effect on the pulp. *Oral Surgery, Oral Medicine and Oral Pathology* 34, 364-371.
- Mjör, I. A. & Haugen, E. (1974) Pulp structure in bilateral and opposing pairs of teeth. *Scandinavian Journal of Dental Research* 82, 128-134.
- Ostrom, C. H. & Lyon, H. W. (1962) Pulpal response to chemically treated heterogeneous bone in pulp capping sites. *Oral Surgery, Oral Medicine and Oral Pathology* 15, 362-376.
- Pappas, A. & Massler, M. (1959) Bioassay of cavity liners under silicate cement fillings in rat incisors. *Journal of Dentistry for Children* 26, 335-342.
- Safer, D. (1971) Histological evaluation of new dental materials. M.S. Thesis, The University of Michigan.
- Stanley, H. R., Jr. & Swerdlow, H. (1959) Reaction of the human pulp to cavity preparation: results produced by eight different operative grinding technics. *Journal of the American Dental Association* 58, 49-59.
- Tronstad, L. & Mjör, I. A. (1972) Pulpal reaction to calcium hydroxide containing materials. *Oral Surgery, Oral Medicine and Oral Pathology* 33, 961-965.

Address:

Dr. Donald R. Heys
Laboratory of Oral Histology
School of Dentistry
University of Michigan
Ann Arbor, Michigan
48109 U.S.A.

This document is a scanned copy of a printed document. No warranty is given about the accuracy of the copy. Users should refer to the original published version of the material.