

# AXIN2-Associated Autosomal Dominant Ectodermal Dysplasia and Neoplastic Syndrome

Monica L. Marvin,<sup>1,2\*</sup> Serina M. Mazzoni,<sup>1</sup> Casey M. Herron,<sup>1,3</sup> Sean Edwards,<sup>4</sup> Stephen B. Gruber,<sup>1,2,3</sup> and Elizabeth M. Petty<sup>1,2</sup>

<sup>1</sup>Department of Human Genetics, University of Michigan, Ann Arbor, Michigan

<sup>2</sup>Department of Internal Medicine, University of Michigan, Ann Arbor, Michigan

<sup>3</sup>Department of Epidemiology, School of Public Health, University of Michigan, Ann Arbor, Michigan

<sup>4</sup>Department of Surgery, University of Michigan, Ann Arbor, Michigan

Received 27 September 2010; Accepted 10 January 2011

We describe a family with a novel, inherited *AXIN2* mutation (c.1989G>A) segregating in an autosomal dominant pattern with oligodontia and variable other findings including colonic polyposis, gastric polyps, a mild ectodermal dysplasia phenotype with sparse hair and eyebrows, and early onset colorectal and breast cancers. This novel mutation predicts p.Trp663X, which is a truncated protein that is missing the last three exons, including the DIX (Disheveled and AXIN interacting) domain. This nonsense mutation is predicted to destroy the inhibitory action of *AXIN2* on WNT signaling. Previous authors have described an unrelated family with autosomal dominant oligodontia and a variable colorectal phenotype segregating with a nonsense mutation of *AXIN2*, as well as a frameshift *AXIN2* mutation in an unrelated individual with oligodontia. Our report provides additional evidence supporting an autosomal dominant *AXIN2*-associated ectodermal dysplasia and neoplastic syndrome. © 2011 Wiley-Liss, Inc.

**Key words:** *AXIN2*; polyposis; ectodermal dysplasia; oligodontia

## INTRODUCTION

Several inherited colorectal cancer syndromes result from germline mutations in tumor suppressor or mismatch repair genes. These include familial adenomatous polyposis (FAP) resulting from germline *APC* mutations, *MYH*-associated polyposis resulting from biallelic germline *MYH* mutations, and Lynch syndrome, also known as hereditary nonpolyposis colorectal cancer syndrome, resulting from mutations in one of four mismatch repair genes, *MSH2*, *MLH1*, *MSH6*, or *PMS2* [Lynch, 2008; Lindor, 2009]. These syndromes often include extracolonic manifestations. However, not all familial colon cancer can be attributed to these or other known, rare conditions, suggesting that other uncharacterized cancer syndromes and genes remain to be described.

Because mutations in several genes of the canonical WNT pathway (i.e., *APC*, *CTNNB1* which encodes B-catenin) have been implicated in colorectal tumorigenesis, other genes in this pathway

### How to Cite this Article:

Marvin ML, Mazzoni S, Herron CM, Edwards S, Gruber SB, Petty EM. 2011. *AXIN2*-associated autosomal dominant ectodermal dysplasia and neoplastic syndrome. *Am J Med Genet Part A* 155:898–902.

may play a role in these uncharacterized families, including *AXIN2*. Mutations in genes of the WNT signaling pathway that prevent the degradation of B-catenin lead to tumorigenesis by upregulating WNT signaling. Within the WNT pathway, *AXIN2* acts as a negative regulator by contributing to the assembly of the B-catenin degradation complex [Polakis, 2007]. Somatic *AXIN2* mutations have been described in a variety of human cancers, including colorectal cancers [Liu et al., 2000; Salahshor and Woodgett, 2005]. *AXIN2* has also been independently implicated in tooth agenesis and oral clefts [Mostowska et al., 2006; Callahan et al., 2009; Letra et al., 2009].

Of particular interest is the description of a four-generation Finnish kindred in which both oligodontia and a variable colorectal phenotype segregated with a nonsense mutation in *AXIN2* [Lammi et al., 2004]. In this family, the oligodontia phenotype (defined as congenital absence of six or more permanent teeth, third molars excluded) was entirely penetrant in mutation carriers. No other ectodermal findings such as those involving the nails, hair, or skin

Grant sponsor: National Cancer Institute; Grant number: RO1 CA81488; Grant sponsor: University of Michigan's Cancer Center Support Grant; Grant number: 5 P30 CA465920.

\*Correspondence to:

Monica L. Marvin, University of Michigan, Human Genetics, 4909 Buhl, 1241 E. Catherine Street, Ann Arbor, MI 48109-0618.

E-mail: monicama@umich.edu

Published online 17 March 2011 in Wiley Online Library (wileyonlinelibrary.com).

DOI 10.1002/ajmg.a.33927

were described. The colorectal phenotype in this family was variable. Six of the seven family members with oligodontia had colorectal neoplasms, ranging from polyposis to colorectal malignancy with no polyps. Lammi et al. [2004] also screened oligodontia patients for *AXIN2* mutations and identified a de novo germline mutation in a 13-year-old boy with oligodontia. Of note, the germline mutation in this patient was a 1-bp insertion in exon 7 that was identical to a frameshift mutation described in a colorectal cancer tissue [Liu et al., 2000].

We describe an unrelated family with an inherited *AXIN2* mutation segregating in an autosomal dominant pattern with oligodontia and variable other findings including colonic polyposis, gastric polyps, a mild ectodermal dysplasia phenotype with sparse hair and eyebrows, and early onset colorectal and breast cancers. This report provides additional clinical description of and support for an autosomal dominant *AXIN2*-associated ectodermal dysplasia and neoplastic syndrome.

## CLINICAL REPORT

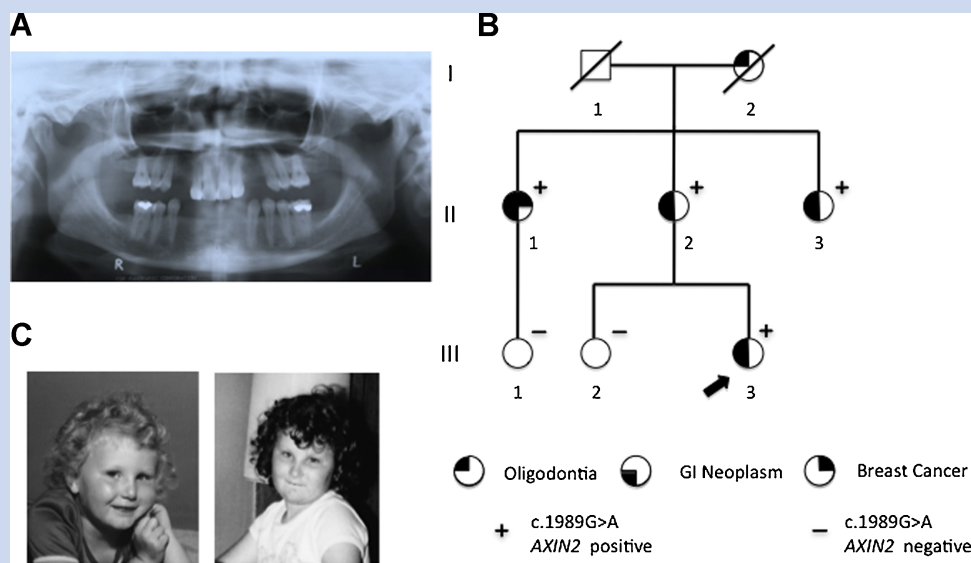
A 35-year-old woman presented for evaluation of a possible ectodermal dysplasia syndrome due to a history of oligodontia, including the congenital absence of >10 secondary teeth, and a family history of oligodontia (Fig. 1A,B). The proband was the product of a full-term, uncomplicated pregnancy with a birth weight of 3,232 g. Her past medical history was notable for intermittent nonbloody diarrhea, gastric reflux, peptic ulcer disease, iron deficiency anemia, polycystic ovary disease, decreased fertility, fibromyalgia, insulin resistance, fundic gland polyps, Sjogren disease, anxiety, and depression. She reported normal body hair, normal nails, and normal sweating. Previous evaluations included a normal colonoscopy and upper endoscopy exams revealing multiple

fundic gland polyps at age 33 and 35, normal capsule endoscopy at age 34, and normal rheumatology and celiac sprue evaluations.

At the time of her visit, physical exam was notable for hypognathia, malar hypoplasia, broad nasal bridge, very sparse eyebrows, fine scalp hair, and slightly upslanting palpebral fissures. Oropharyngeal exam was noted for a high palate, several missing teeth with increased spacing and conical shaping of several teeth (Fig. 1A). She was otherwise noted to have normal body hair distribution, normal nails, and normal skin. Review of photographs from age 4 to 8 years showed sparse eyebrows, slightly upslanting palpebral fissures, and thin upper vermillion (Fig. 1C).

Her family history was notable for oligodontia, absent eyebrows, sparse hair, colon polyps, early onset colon cancer, and early onset breast cancer (Fig. 1B and Table I). The proband's mother (II-2) had oligodontia with absence of most of her secondary teeth. She began colonoscopic screening at age 60 and was found to have >10 adenomatous polyps requiring a sigmoid colectomy at age 60 and a right hemicolectomy at age 62. She was evaluated in our clinic and was also noted to have soft skin with particularly scant body hair, minimal axillary hair, short eyelashes, and very sparse eyebrows, especially laterally.

The proband had two maternal aunts, including one (II-1) with oligodontia, breast cancer diagnosed at age 44, metachronous colon cancers diagnosed at age 50 and 59, and five adenomatous polyps of the transverse and ascending colon at age 69. The other maternal aunt (II-3) had a reported history of colon polyps, oligodontia, absent eyebrows, and sparse hair. Confirmation of her history was not available. The index patient's sister (III-2) had no dental or other ectodermal findings and had not undergone endoscopic screening. One cousin (III-1) also had no dental or ectodermal findings and had normal colon screening at age 41. The proband's maternal grandmother (I-2) died at age 97 with a reported history



**FIG. 1.** Oligodontia phenotype and pedigree. **A:** Panoramic radiograph demonstrating proband's congenital absence of teeth 2, 7, 10, 15, 18, 23, 24, 25, 26, 27, and 31. **B:** Autosomal dominant inheritance of oligodontia, c.1989A>G, and variable colorectal phenotype. **C:** Photographs of the proband at age 4 and 8 years showing sparse eyebrows, slightly upslanting palpebral fissures, and thin upper vermillion.

of oligodontia, absent eyebrows, and sparse hair, and no known history of colon polyps or cancers.

## METHODS

Informed consent and blood samples were obtained from the patient, her sister (III-2), mother (II-2), one maternal aunt (II-1), and one maternal cousin (III-1) under the Institutional Review Board approved University of Michigan Cancer Genetics Registry. Bidirectional direct sequencing of known *AXIN2* exons and flanking intronic regions was performed on the proband. Bidirectional sequencing of exon 7 and flanking intronic regions was performed in the other study participants. The proband's mother (II-2) also underwent clinical genetic testing of the *APC* gene including sequence analysis of exons 1–14 and the 5' end of exon 15, protein truncation testing for mutations in exon 15, and gene dosage analysis (MLPA) to test for the presence of large deletions, duplications, and other genomic rearrangements. The proband's mother (II-2) also underwent clinical testing for the p.Tyr165Cys and p.Gly382Asp mutations of the *MYH* genes by a PCR-based analysis (restriction enzyme digest).

The *AXIN2* DNA sequence (NCBI reference sequence NG\_012142.1) was cloned from the DLD-1 cell line (ATCC, Manassas, VA). The sequence was PCR amplified from cDNA using primers specific to *AXIN2* and inserted into the pCR2.1-TOPO vector (Invitrogen, Carlsbad, CA). The c.1989G>A mutation was introduced by site-directed mutagenesis using the QuickChangeII site-directed mutagenesis kit (Stratagene, LaJolla, CA). In vitro transcription and translation (TNT, Promega, Madison, WI) was performed following manufacturer's instructions. Biotinylated proteins were visualized following separation by SDS–PAGE with streptavidin-conjugated HRP. HEK 293 cells were transiently transfected with either a wild-type or c.1989G>A *AXIN2* construct using FugeneHD (Roche, Basel, Switzerland). Cell lysates were analyzed by immunoblotting, following resolution by SDS–PAGE, with a monoclonal *AXIN2* antibody (Cell Signaling, 76G6, Danvers, MA).

## RESULTS

Genetic testing in the proband showed a heterozygous c.1989G>A gene alteration (p.Trp663X) (Fig. 2). This is a novel mutation that introduces a stop codon at amino acid 663. The proband's mother (II-2) and maternal aunt (II-1) tested positive and her sister (III-2) and cousin (III-1) tested negative (Table I and Fig. 1B). In vitro transcription and translation of the c.1989G>A construct and expression of the construct in HEK 293 cells produced an approximately 80 kDa protein representing a truncated *AXIN2* product missing the last three exons (Fig. 2B). The proband's mother (II-2) did not have a germline *APC* mutation identified and was negative for the *MYH* p.Tyr165Cys and p.Gly382Asp mutations.

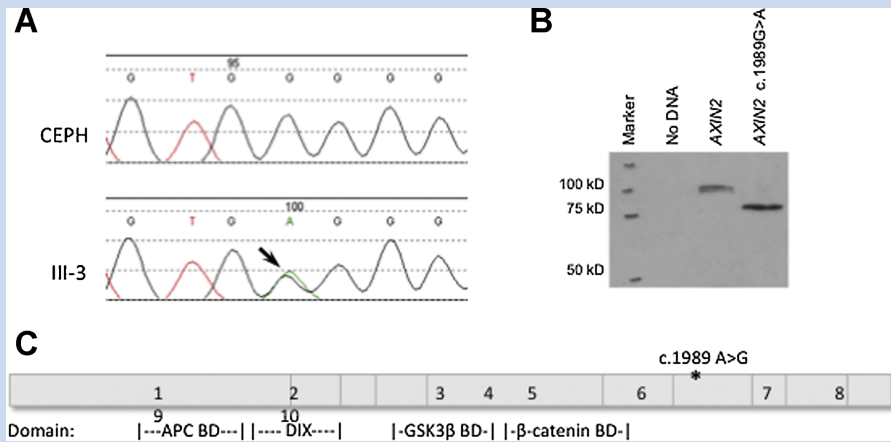
## DISCUSSION

Our findings provide further evidence of an autosomal dominant multisystem ectodermal and neoplastic phenotype associated with a germline *AXIN2* mutation. The novel mutation found in the family reported here predicts p.Tyr663X. This truncated protein is missing the last three exons, including the DIX domain. The DIX (Disheveled and *AXIN* interacting domain) is required for *AXIN2* homodimerization. Dimerization allows *AXIN2* to act as a scaffold for the assembly of protein complexes, in particular, the B-catenin destruction complex. Formation of this complex is important for the inhibition and negative feedback of WNT signaling. We predict that loss of the DIX domain will have functional consequences and destroy the inhibitory action of *AXIN2* on WNT signaling.

Similar to the findings of Lammi et al. [2004] the oligodontia phenotype in the family reported here is highly penetrant. In addition, members of the family had a mild ectodermal dysplasia phenotype characterized by absent or sparse eyebrows and body hair. Furthermore, three of the four *AXIN2* mutation carriers in the family had a colorectal neoplasia, including one with a modest number of adenomas (less than 10) who had two primary colon cancers in her 50s (II-1), one with polyposis reminiscent of FAP (II-2) and one with an unspecified number of colon

TABLE I. Summary of Clinical Findings and Mutation Analysis

ID number	Age	Ectodermal findings	GI findings	Malignancies	<i>AXIN2</i> c.1989G>A
I-2	Deceased at 97 years	Oligodontia, absent eyebrows, sparse hair	Unknown	None	Not tested
II-1	68 years	Oligodontia	At least five adenomas, no upper GI screening	Breast [44 year], colon [50 year], colon [59 year]	Positive
II-2	65 years	Oligodontia, scant body hair, minimal axillary hair, short eyelashes, very sparse eyebrows	>100 adenomas, no upper GI screening	None	Positive
II-3	63 years	Oligodontia, absent eyebrows, sparse hair	Colon polyps [details unknown]	None	Positive
III-1	39 years	Normal	Normal colonoscopy	None	Negative
III-2	38 years	Normal	No GI screening	None	Negative
III-3	35 years	Oligodontia, absent eyebrows, sparse hair	Normal colonoscopy, multiple fundic gland polyps	None	Positive



**FIG. 2.** c.1989G>A mutation produces a truncated protein. **A:** Sequencing of the proband's DNA (III-3) showed a heterozygous mutation, c.1989G>A, which encodes a premature stop codon. **B:** HEK 293 cells were transfected with wild-type *AXIN2* or *AXIN2* c.1989G>A DNA. Immunoblotting of cell lysates showed that *AXIN2* c.1989G>A produces an approximately 80 kDa protein representing a truncated *AXIN2* product. **C:** Schematic of the *AXIN2* protein and important binding domains shows the site of the identified mutation.

polyps (II-3). The youngest mutation carrier in the family, the proband (III-3), had normal colonoscopic findings in her mid 30s, but was noted to have multiple fundic gland polyps. Given that upper GI screening has not been performed in other mutation carriers and that the proband's fundic gland polyps could be related to proton-pump inhibitor use, further exploration is needed to determine if fundic gland polyps are related to *AXIN2* mutations [Choudhry et al., 1998].

The diagnosis of early onset breast cancer in one member of this family (II-1) is intriguing given that others have hypothesized that genetic variation influencing the expression of APC and *AXIN2* influences breast cancer risk [Wang et al., 2008]. Supporting evidence includes the finding that *AXIN2* maps to a chromosomal region at band 17q24 that has demonstrated allelic imbalance in breast cancer samples, and an increased rate of breast cancer in mouse models with upregulated WNT signaling [Zhang et al., 2010]. Additionally, *AXIN2* is involved in epithelial to mesenchymal transitions in mammary epithelial cells, which is thought to be a critical in the development of invasive and metastatic breast cancer [Yook et al., 2006]. It is unclear if the observed development of early onset breast cancer in one member of this kindred is related to the germline *AXIN2* mutation identified. Further studies are needed to substantiate a causal role.

*AXIN2* mutations have also been associated with the development of oral clefts, such as cleft lip and cleft palate (CL/CP). A recent analysis of 75 families with CL/CP compared to controls found that there was a significantly higher incidence of cancer in families with CL/CP. In fact, the rates of breast and colon cancer in these families were significantly higher [Menezes et al., 2009]. Additional studies to examine the correlation of *AXIN2* mutations with CL/CP associated with an increased risk of breast or colon cancer are needed to determine if a unique *AXIN2*-related syndrome of oral clefts associated with an increased risk for cancer exists.

This report describes a second family with an *AXIN2* mutation cosegregating in an autosomal dominant pattern with oligodontia

and early onset cancers. In addition, this study extends the phenotypic spectrum associated with germline heterozygous *AXIN2* mutations to include other ectodermal dysplasia features and raises the possibility of an association with increased breast cancer risk. Further studies are needed to determine the role of *AXIN2* mutations in inherited cancer predisposition and better characterize the phenotype associated with this newly recognized autosomal dominant *AXIN2*-associated ectodermal dysplasia and neoplastic syndrome. Similar to other inherited cancer predisposition syndromes, a careful family and personal medical history is critical to developing a complete differential. Specifically, cancer genetics professionals should inquire about the presence of ectodermal phenotypes when assessing patients with familial colorectal neoplasias. The co-occurrence of colorectal neoplasia, including polyposis and colorectal cancer, with oligodontia, other ectodermal dysplasia findings such as sparse hair and eyebrows, or oral clefts should prompt an evaluation for *AXIN2* mutations.

## ACKNOWLEDGMENTS

This work was supported in part by the National Cancer Institute RO1 CA81488 and the University of Michigan's Cancer Center Support Grant 5 P30 CA465920.

## REFERENCES

- Callahan N, Modesto A, Meira R, Seymen F, Patir A, Vieira AR. 2009. Axis inhibition protein 2 (*AXIN2*) polymorphisms and tooth agenesis. *Arch Oral Biol* 54:45–49.
- Choudhry U, Boyce HW Jr, Coppola D. 1998. Proton pump inhibitor-associated gastric polyps: A retrospective analysis of their frequency, and endoscopic, histologic, and ultrastructural characteristics. *Am J Clin Pathol* 110:615–621.

- Lammi L, Arte S, Somer M, Jarvinen H, Lahermo P, Thesleff I, Pirinen S, Nieminen P. 2004. Mutations in AXIN2 cause familial tooth agenesis and predispose to colorectal cancer. *Am J Hum Genet* 74:1043–1050.
- Letra A, Menezes R, Granjeiro JM, Vieira AR. 2009. AXIN2 and CDH1 polymorphisms, tooth agenesis, and oral clefts. *Birth Defects Res A Clin Mol Teratol* 85:169–173.
- Lindor NM. 2009. Hereditary colorectal cancer: MYH-associated polyposis and other newly identified disorders. *Best Pract Res Clin Gastroenterol* 23:75–87.
- Liu W, Dong X, Mai M, Seelan RS, Taniguchi K, Krishnadath KK, Halling KC, Cunningham JM, Boardman LA, Qian C, Christensen E, Schmidt SS, Roche PC, Smith DI, Thibodeau SN. 2000. Mutations in AXIN2 cause colorectal cancer with defective mismatch repair by activating beta-catenin/TCF signalling. *Nat Genet* 26:146–147.
- Lynch PM. 2008. Standards of care in diagnosis and testing for hereditary colon cancer. *Fam Cancer* 7:65–72.
- Menezes R, Marazita ML, Goldstein McHenry T, Cooper ME, Bardi K, Brandon C, Letra A, Martin RA, Vieira AR. 2009. AXIS inhibition protein 2, orofacial clefts and a family history of cancer. *J Am Dent Assoc* 140:80–84.
- Mostowska A, Biedziak B, Jagodzinski PP. 2006. Axis inhibition protein 2 (AXIN2) polymorphisms may be a risk factor for selective tooth agenesis. *J Hum Genet* 51:262–266.
- Polakis P. 2007. The many ways of Wnt in cancer. *Curr Opin Genet Dev* 17:45–51.
- Salahshor S, Woodgett JR. 2005. The links between axin and carcinogenesis. *J Clin Pathol* 58:225–236.
- Wang X, Goode EL, Fredericksen ZS, Vierkant RA, Pankratz VS, Liu-Mares W, Rider DN, Vachon CM, Cerhan JR, Olson JE, Couch FJ. 2008. Association of genetic variation in genes implicated in the beta-catenin destruction complex with risk of breast cancer. *Cancer Epidemiol Biomarkers Prev* 17:2101–2108.
- Yook JI, Li XY, Ota I, Hu C, Kim HS, Kim NH, Cha SY, Ryu JK, Choi YJ, Kim J, Fearon ER, Weiss SJ. 2006. A Wnt-Axin2-GSK3beta cascade regulates Snail1 activity in breast cancer cells. *Nat Cell Biol* 8:1398–1406.
- Zhang J, Li Y, Liu Q, Lu W, Bu G. 2010. Wnt signaling activation and mammary gland hyperplasia in MMTV-LRP6 transgenic mice: Implication for breast cancer tumorigenesis. *Oncogene* 29:539–549.