

## Bullous Dermolysis of the Newborn: Four New Cases and Clinical Review

Olga Radkevich-Brown, M.D., Ph.D.,\* and Tor Shwayder, M.D.†

\*University of Michigan Medical School, Ann Arbor, Michigan, †Department of Dermatology, Henry Ford Hospital, Detroit, Michigan

---

**Abstract:** Bullous dermolysis of the newborn (BDN) is a subtype of dystrophic epidermolysis bullosa caused by mutations in type VII collagen resulting in disorganized anchoring fibrils and sublamina densa blister formation. Disease activity is usually confined to the first year of life, with restoration of physiologic type VII collagen localization. We report four new cases of BDN and review the utility of immunofluorescence mapping in establishing the diagnosis.

---

Bullous dermolysis of the newborn (BDN), formerly known as transient bullous dermolysis of the newborn, is a subtype of autosomal dominant or recessive dystrophic epidermolysis bullosa (EB) characterized by mechanical fragility of the skin and blister formation primarily confined to infancy (1). Histologically a subepidermal blister forms below the lamina densa, and electron microscopy demonstrates disruption of anchoring fibrils and the presence of electron-dense stellate or rod-like bodies within dilated rough endoplasmic reticulum of basal keratinocytes (2). Independently, intracytoplasmic accumulation of type VII collagen in basal keratinocytes was detected in patients with clinical features consistent with BDN (3). This aberrant accumulation was self-limited, with type VII collagen localization reverting to linear distribution along the dermoepidermal junction (DEJ) with improvement in disease activity (4). The precise mechanisms of this reversal have not been elucidated. Several molecular defects in BDN were reported involving COL7A1 mutations

that probably result in abnormal intracytoplasmic processing, delayed transport, and intraepidermal accumulation of type VII collagen (5–8).

Because of the self-limiting and usually benign clinical course of BDN, as well as characteristic findings of granular intraepidermal type VII collagen staining on immunofluorescence (IF) studies, it is important to distinguish this form of dystrophic EB. IF mapping using specific monoclonal antibodies is currently recommended as the primary diagnostic evaluation for patients with suspected inherited EB (1). Here we report four cases of BDN, two of which occurred in siblings, and highlight the importance of clinical follow-up and immunologic studies in establishing the diagnosis.

### METHODS

Immunofluorescence mapping (Beutner Laboratories, Buffalo, NY) was performed using antibodies against type VII collagen (LH 7:2) (3), type IV collagen,

---

Address correspondence to Tor Shwayder, M.D., Department of Dermatology, Henry Ford Hospital, 3031 W Grand Blvd., Suite 800, Detroit, MI 48202, or e-mail: TShwayd1@hfhs.org.

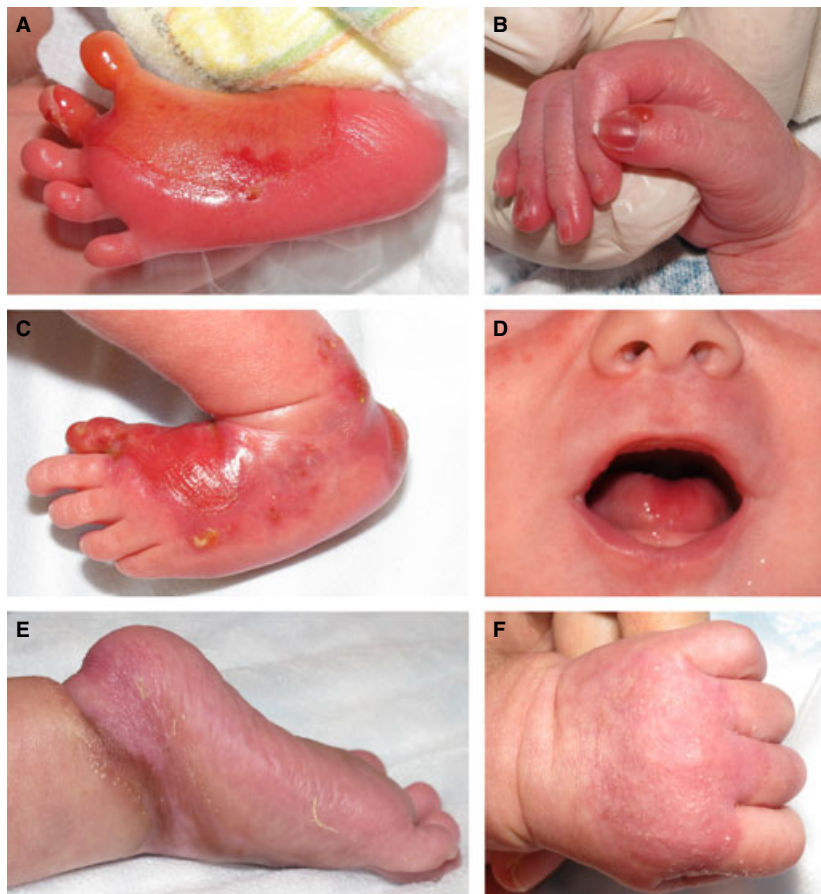keratin 14, laminin 332,  $\alpha 6$  integrin,  $\beta 4$  integrin, type XVII collagen, and plectin.

## CASE REPORTS

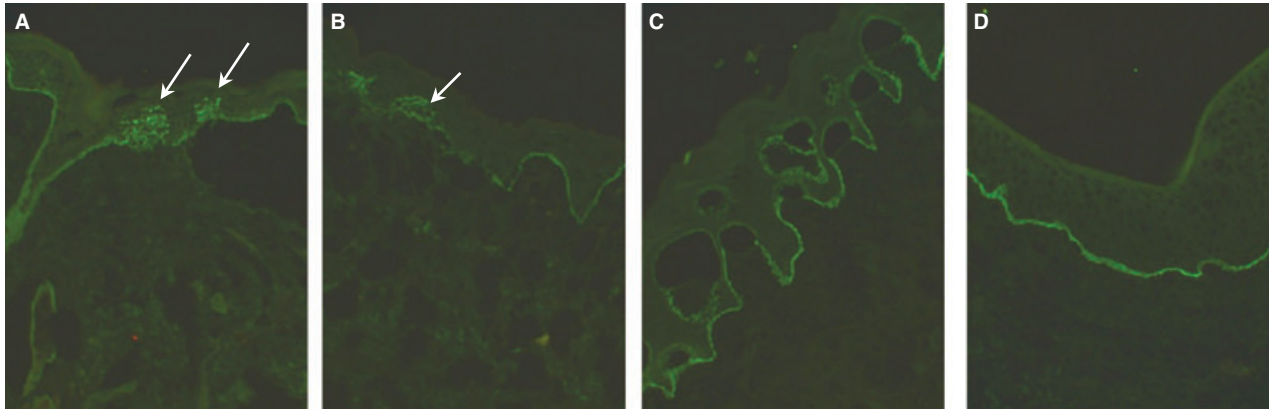
### Patient 1

A 2,500-g Caucasian boy was born at 36 and 3/7 weeks gestation via vaginal delivery. Pregnancy was complicated by maternal hypertension. At birth, desquamation of the right foot was noted and he subsequently developed blisters and erosions in the areas of friction. There was no family history of blistering diseases. Physical examination revealed bullae, vesicles, and erosions involving the right lower extremity, the right periauricular area, and portions of the scalp, thumb, and midback (Fig. 1A, B). Both parents were interviewed and the skin of their upper extremities, head, and neck was examined. We found no evidence of blistering disease in their history or

current physical examination. Punch biopsies of intact blisters on the left knee were performed and submitted for hematoxylin and eosin (H&E) staining and IF. H&E staining showed a paucicellular subepidermal vesicle, with periodic acid-Schiff–positive basement membrane in the floor of the vesicle, most consistent with EB of the junctional type. IF showed localization of laminin and type IV collagen along the intact DEJ. Type IV collagen was expressed solely in the roof of the central subepidermal microvesicle, consistent with sublamina densa split and dystrophic EB. Type VII collagen was detected in the roof but not the floor of the microvesicle, with prominent focal granular deposits of collagen VII in the cytoplasm of epidermal cells and interrupted staining along the DEJ (Fig. 2A), compared with linear staining in a healthy skin control (Fig. 2D). The presence of type VII collagen excluded severe generalized recessive dystrophic EB, previously known as Hallopeau–Siemens. Type XVII collagen and  $\alpha 6$  and  $\beta 4$  integrins were



**Figure 1.** Appearance of the skin lesions. Patient 1: (A) large bulla on the right foot and (B) vesicle on the right thumb at 3 days of age. (C) Patient 2: erosion involving the dorsum of the left foot with the loss of the great toenail at 5 days of age. (D) Patient 2: tongue erosion at 16 days of age. Patient 3: (E) milia and hyper- and hypopigmented patches on the left ankle at the site of a previous lesion and (F) an erythematous patch with milia on the left hand at 5 weeks of age.



**Figure 2.** Immunofluorescence mapping using anti-type VII collagen antibody. (A) Patient 1: left knee skin biopsy. (B) Patient 2: left calf skin biopsy. (C) Patient 3: right medial foot skin biopsy. (D) Normal human skin, used as a positive control. Arrows indicate the location of intraepidermal granules.

present in the roof of the microvesicle and basement membrane zone of the intact epidermis.

At the 16-week follow-up he had developed tongue and right heel erosions after trauma. At the 7-month visit, no new blisters were reported or identified on examination. There were hyperpigmented macules and milia in the areas of previous erosions and scarring loss of the right great toenail. At the 2-year follow-up he remained blister free. Based on clinical resolution of blistering and IF findings of prominent intraepidermal type VII collagen granules, he was diagnosed with BDN. Genetic testing was offered to the patient and his parents, but they declined because of the prohibitive cost.

### Patient 2

A full-term 3,500-g Caucasian boy was born via spontaneous vaginal delivery. The pregnancy and delivery were uncomplicated. He was the younger brother of patient 1. He presented at birth with desquamation of the left foot. On skin examination at 5 days of age he had erosions involving the extremities (with the loss of the left great toenail) and tongue (Fig. 1C, D). Punch biopsy of the flaccid blister on the posterior left calf was performed and submitted for IF only. Laminin and type IV collagen were normally expressed along the intact DEJ. Type IV collagen was expressed exclusively in the roof of the cleft, consistent with a sublamina densa split and dystrophic EB. Staining for type VII collagen revealed weak, focal positive staining at the roof of the cleft and absent staining at the floor of the cleft (Fig. 2B). One or two foci of granular type VII collagen were noted in the epidermis (Fig. 2B), although they were much less prominent than in patient 1. Staining for fibrin was

positive (data not shown), probably indicating that the biopsied lesion was older and had some reparative changes. The remainder of the tested antigens were present in the roof of the cleft, although overall IF staining of this biopsy specimen was less intense, probably because of the age of the lesion or a staining artifact.

At 7 weeks he had a new erosion secondary to trauma. The last erosion occurred at 4 months of age, and he had no new blisters at the 6-month follow-up. Based on clinical course, family history, and IF findings, he was diagnosed with BDN.

### Patient 3

A full-term 3,400-g Filipino boy was born via spontaneous vaginal delivery. The pregnancy and delivery were uncomplicated. At 1 day of age he developed multiple blisters on the abdomen, dorsal hands, and feet. There was no family history of bullous diseases. On examination at 5 weeks of age he had hyper- and hypopigmented macules on the left ankle at the previous erosion site and milia were present on the bilateral hands and left foot (Fig. 1E). He also had several erythematous macules and patches on the dorsum of both hands (Fig. 1F), both ankles, and abdomen. An intact vesicle was biopsied and sent for IF. Review of an H&E-stained pathology slide of a blister sent at birth demonstrated a cell-poor subepidermal blister, consistent with EB. On IF, laminin and type IV collagen were normally expressed along the intact DEJ. Type IV collagen was expressed exclusively in the roof of several subepidermal microvesicles, consistent with a sublamina densa split and dystrophic EB. Type VII collagen was uniformly present at the DEJ, and granular intraepidermal

staining was not observed in any of the examined sections (Fig. 2C). Type XVII collagen and  $\alpha 6$  and  $\beta 4$  integrins were present in the roof of microvesicles and the basement membrane zone of the intact epidermis. Clinically the blistering resolved spontaneously by 3 months of age, and he remained blister free at 5 months of age. Although type VII collagen staining did not demonstrate a granular pattern, his clinical course was most consistent with BDN.

#### Patient 4

A full-term 3,600-g Caucasian boy was born via caesarean section for arrest of labor. The pregnancy was complicated by pruritic urticarial papules and plaques of pregnancy starting in the second trimester. Within hours after birth he developed blisters and erosions on the scalp, lip, inside the mouth, in the axilla, and on the lower extremities. He has a distant paternal relative who was diagnosed with EB, unknown type, and died at 3 months of age in 1978. On initial examination he had multiple superficial erosions involving the face, hands, arms, feet, and legs. A punch biopsy specimen of a blister on day 2 of life was submitted for H&E and IF. H&E demonstrated subepidermal cleft-like separation at the DEJ consistent with EB. IF demonstrated a separated epidermis with focally attached dermis fragments with a scant amount of intact DEJ, suggesting that the punch specimen came apart during transport, making interpretation of the IF results difficult. Type IV collagen staining was strongly positive in the roof of the microvesicles, with weak focal positive staining in the floor of the microvesicles. Linear localization of laminin along the DEJ was observed, as well as in the roof, but not the floor, of the microvesicles. Type VII collagen was detected along the intact DEJ and in the roof but not the floor of the microvesicles, with prominent focal granular deposits of collagen VII in the cytoplasm of epidermal cells (data not shown). Type XVII collagen and  $\alpha 6$  and  $\beta 4$  integrins were present in the roof of the microvesicles and basement membrane zone of the intact epidermis. Although collagen IV staining was atypical, antigen localization was indicative of a sublamina densa split and dystrophic EB. The presence of prominent type VII collagen granules was consistent with BDN.

His last blister was at 5 months of age. He had delayed tooth appearance and brown discoloration despite appropriate dental hygiene, with bottom teeth appearing at 11 months and top teeth at 15 months. His big toenails are dystrophic. At the 17-month follow-up he remained blister-free.

## DISCUSSION

The most recent classification scheme (1) of inherited EB specifies the following clinical features of BDN: autosomal dominant or recessive pattern of inheritance; onset of blisters at birth or infancy; generalized skin distribution of blisters; variable presence of milia, atrophic scarring, and dystrophic or absent nails; and absence of extracutaneous involvement and skin cancer predisposition, although the most important characteristic of BDN is arguably its limited duration. In the majority of published cases with BDN diagnosis, blisters resolved by 1 to 7 months of age (2–18). Current classification does not indicate the duration of blistering as a diagnostic criterion and eliminated the term “transient” because rare patients exhibited blister formation, albeit diminished, beyond 12 months (4,10). In our patients, the blistering disappeared by 3 to 7 months of age, similar to most reported cases of BDN. Although BDN has an overall benign and limited course, certain functional complications such as pseudosyndactyly (7) or aesthetic complications such as nail dystrophy and residual scarring may be of concern to individual patients.

Electron microscopy was used initially to characterize a structural defect in BDN, but is impractical for widespread clinical use (1). With the development of specific antibodies, the presence of intracytoplasmic type VII collagen granules within keratinocytes emerged as an important finding in patients with BDN and was reported in all 17 proband patients in whom IF was performed, but intraepidermal collagen VII staining is not specific to BDN and has been noted at various intensities and frequencies in other dystrophic EB phenotypes (14,19,20). It is more likely that the relative abundance of intraepidermal staining is associated with BDN (14). Loss of intraepidermal staining and localization of type VII collagen to the DEJ appears to coincide with the resolution of blistering. Granular intraepidermal staining has been reported in family members many years after blistering stopped (6). Therefore infants presenting with a blistering disorder and intraepidermal type VII collagen granules on IF may have BDN, but their parents should be counseled that clinical follow-up is essential in establishing the diagnosis.

Conversely, the absence of intraepidermal type VII collagen granules does not exclude BDN because they may be rare in a given biopsy, the biopsy may have been performed after distribution of type VII collagen to the DEJ, or IF staining may be suboptimal because of the quality of the specimen. In patient 2, the blister was probably more than 24 hours old, as evidenced by

positive fibrin staining, and this may have accounted for the poor collagen VII granular staining and overall poor specimen quality. In patient 3, intraepidermal granules were not detected, but his blistering had already diminished by the time the biopsy specimen was obtained, and his clinical course otherwise fulfilled BDN criteria. Thus prominent intraepidermal type VII collagen staining is highly suggestive of BDN but is not essential for a clinical BDN diagnosis.

Several different mutations in type VII collagen have been identified in BDN (5–8), however, the specific effects of these mutations on type VII collagen protein structure and function have not been determined. In addition, the cost of individual gene sequencing is prohibitive. Once techniques to translate gene sequences into protein structures and functions become widely available, individual sequencing will play an important role in establishing the diagnosis and identifying pathogenic mutations.

In summary, we present four cases seen in our practice that met the diagnostic criteria for BDN. We found that three of four met IF mapping criteria for this condition. The clinical course is the critical diagnostic criterion, with IF as a secondary aid. In our cases, blistering ceased between 3 and 7 months of age. Intraepidermal granular deposits of type VII collagen are helpful but are not required for the diagnosis.

## REFERENCES

1. Fine JD, Eady RA, Bauer EA, et al. The classification of inherited epidermolysis bullosa (EB): report of the Third International Consensus Meeting on Diagnosis and Classification of EB. *J Am Acad Dermatol* 2008;58:931–950.
2. Hashimoto K, Matsumoto M, Iacobelli D. Transient bullous dermolysis of the newborn. *Arch Dermatol* 1985;121:1429–1438.
3. Fine JD, Horiguchi Y, Stein DH, et al. Intraepidermal type VII collagen: evidence for abnormal intracytoplasmic processing of a major basement membrane protein in rare patients with dominant and possibly localized recessive forms of dystrophic epidermolysis bullosa. *J Am Acad Dermatol* 1990;22:188–195.
4. Fine JD, Johnson LB, Crouse D, et al. Intracytoplasmic retention of type VII collagen and dominant dystrophic epidermolysis bullosa: reversal of defect following cessation of or marked improvement in disease activity. *J Invest Dermatol* 1993;101:232–236.
5. Christiano AM, Fine JD, Uitto J. Genetic basis of dominantly inherited transient bullous dermolysis of the newborn: a splice site mutation in the type VII collagen gene. *J Invest Dermatol* 1997;109:811–814.
6. Fassih H, Diba VC, Wessagowit V, et al. Transient bullous dermolysis of the newborn in three generations. *Br J Dermatol* 2005;153:1058–1063.
7. Nakano H, Toyomaki Y, Ohashi S, et al. Novel COL7A1 mutations in a Japanese family with transient bullous dermolysis of the newborn associated with pseudosyndactyly. *Br J Dermatol* 2007;157:179–182.
8. Frew J, Lim SW, Klausseger A, et al. Autosomal dominant bullous dermolysis of the newborn associated with a heterozygous missense mutation p.G1673R in type VII collagen. *Australas J Dermatol* 2011;52:e1–e4.
9. Hashimoto K, Burk JD, Bale GF, et al. Transient bullous dermolysis of the newborn: two additional cases. *J Am Acad Dermatol* 1989;21:708–713.
10. Hatta N, Takata M, Shimizu H. Spontaneous disappearance of intraepidermal type VII collagen in a patient with dystrophic epidermolysis bullosa. *Br J Dermatol* 1995;133:619–616.
11. Hanson SG, Fine JD, Levy ML. Three new cases of transient bullous dermolysis of the newborn. *J Am Acad Dermatol* 1999;40:471–476.
12. Eng AM, Keegan CA, Hashimoto K, et al. Transient bullous dermolysis of the newborn. Case report and review of pathogenesis. *J Cutan Pathol* 1991;18:328–332.
13. McCollough ML, Grimwood RE, Grabski WJ. Dominant dystrophic epidermolysis bullosa with intraepidermal type VII collagen. *J Am Acad Dermatol* 1991;24:512.
14. Phillips RJ, Harper JJ, Lake BD. Intraepidermal collagen type VII in dystrophic epidermolysis bullosa: report of five new cases. *Br J Dermatol* 1992;126:222–230.
15. Hashimoto K, Eng AM. Transient bullous dermolysis of the newborn. Retention of anchoring fibril- and basal lamina-like structures in keratinocytes and evidence of collagenolysis. *J Cutan Pathol* 1992;19:496–501.
16. Okuda C, Fujiwara H, Ito M. Transient bullous dermolysis of the newborn: new pathologic findings. *Arch Dermatol* 1993;129:1209–1210.
17. Hammami-Hauasli N, Raghunath M, Küster W, et al. Transient bullous dermolysis of the newborn associated with compound heterozygosity for recessive and dominant COL7A1 mutations. *J Invest Dermatol* 1998;111:1214–1219.
18. Murase K, Kanoh H, Ishii N, et al. Bullous dermolysis of the newborn and dystrophic epidermolysis bullosa pruriginosa within the same family: two phenotypes associated with a COL7A1 mutation. *Acta Derm Venereol* 2011;91:730–731.
19. Makino E, Nakano H, Sawamura D, et al. Recessive dystrophic epidermolysis bullosa: identification of a novel COL7A1 mutation of D44N. *J Dermatol Sci* 2012;68:109–112.
20. Muramatsu T, Ko T, Honoki K, et al. Intraepidermal expression of basement membrane components in the lesional skin of a patient with dystrophic epidermolysis bullosa. *J Dermatol* 1999;26:106–110.