

## Role of parathyroid hormone therapy in reversing radiation-induced nonunion and normalization of radiomorphometrics in a murine mandibular model of distraction osteogenesis

K. Kelly Gallagher, MD, Sagar Deshpande, BS, Catherine N. Tchanque-Fossuo, MD, MS, Alexis Donneys, MD, MS, Deniz Sarhaddi, BA, Noah S. Nelson, Douglas B. Chepeha, MD, MPH, Steven R. Buchman, MD\*

Departments of Otolaryngology–Head and Neck Surgery and Plastic Surgery, University of Michigan Health System, Ann Arbor, Michigan.

Accepted 28 September 2012

Published online 17 January 2013 in Wiley Online Library (wileyonlinelibrary.com). DOI 10.1002/hed.23216

**ABSTRACT:** *Background.* The use of mandibular distraction osteogenesis (MDO) for tissue replacement after oncologic resection or for defects caused by osteoradionecrosis has been described but, in fact, has seen limited clinical utility. Previous laboratory work has shown that radiation (XRT) causes decreased union formation, decreased cellularity, and decreased mineral density in an animal model of MDO. Our global hypothesis is that radiation-induced bone damage is partly driven by the pathologic depletion of both the number and function of osteogenic cells. Parathyroid hormone (PTH) is a U.S. Food and Drug Administration–approved anabolic hormonal therapy that has demonstrated efficacy for increasing bone mineral density for the treatment of osteoporosis. We postulate that intermittent systemic administration of PTH will serve as an anabolic stimulant to cellular function that will act to reverse radiation-induced damage and enhance bone regeneration in a murine mandibular model of DO.

*Methods.* A total of 20 isogenic male Lewis rats were randomly assigned into 3 groups. Group 1 (XRT-DO,  $n = 7$ ) and group 2 (XRT-DO-PTH,  $n = 5$ ) received a human bioequivalent dose of 70 Gy fractionated over 5 days. All groups including group 3 (DO,  $n = 8$ ) underwent a left unilateral mandibular osteotomy with bilateral external fixator placement. Four days later, mandibular DO was performed at a rate of 0.3 mm every 12 hours to reach a maximum gap of 5.1 mm. Group 2 was injected PTH (60  $\mu\text{g}/\text{kg}$ ) subcutaneously daily for 3 weeks following the start of MDO. On postoperative day 41, all left hemimandibles were

harvested. Micro-CT at 45- $\mu\text{m}$  voxel size was performed and radiomorphometrics parameters of bone mineralization were generated. Union quality was evaluated on a 4-point qualitative grading scale. Radiomorphometric data were analyzed using 1-way ANOVA, and union quality assessment was analyzed via the Mann–Whitney test. Statistical significance was considered at  $p \leq .05$ .

*Results.* Groups 1 and 2 appropriately demonstrated clinical signs of radiation-induced stress ranging from alopecia to mucositis. Union quality was significantly higher in PTH-treated XRT-DO animals, compared with XRT-DO group animals ( $p = .02$ ). Mineralization metrics, including bone volume fraction (BVF) and bone mineral density (BMD), also showed statistically significant improvement. The groups that were treated with PTH showed no statistical differences in union or radiomorphometrics when compared with DO in nonradiated animals.

*Conclusion.* We have successfully demonstrated the therapeutic efficacy of PTH to stimulate and enhance bone regeneration in our irradiated murine mandibular model of DO. Our investigation effectively resulted in statistically significant increases in BMD, BVF, and clinical unions in PTH-treated mandibles. PTH demonstrates immense potential to treat clinical pathologies where remediation of bone regeneration is essential.

© 2013 Wiley Periodicals, Inc. *Head Neck* 35: 1732–1737, 2013

**KEY WORDS:** parathyroid hormone, distraction osteogenesis, radiation, mandible, mineral density

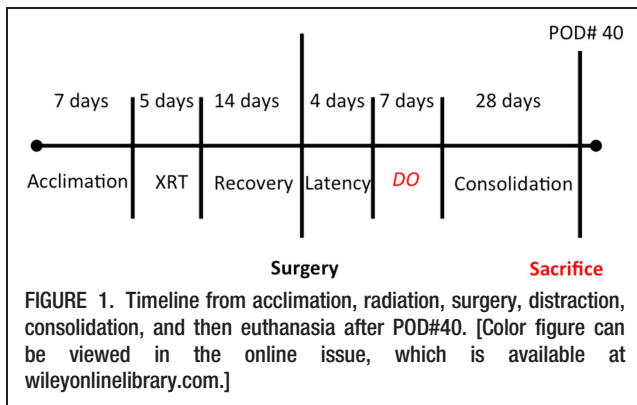
### INTRODUCTION

The mandible is often included in the radiation field when treating oral cavity and oropharyngeal squamous cell carcinoma.<sup>1,2</sup> Although the incidence of osteoradionecrosis (ORN) has decreased in the last few decades, it still has remained approximately 5% and remains a debilitating late complication of radiation therapy.<sup>3</sup> Furthermore, those patients who do develop osteoradionecrosis may have severe limitations in mandibular function and are at risk for pathologic fracture. Quality of life is often affected in patients with ORN, including limitations

related to diet, and altered aesthetics, all of which result in limitation of social interaction.

Segmental mandibulectomy is required for tumor invasion into bone or for severe, grade IV, osteoradionecrosis that has failed medical management. Reconstructive options in these cases are limited to osseous free tissue transfer or to soft tissue in combination with a reconstruction bar. The superiority of free tissue transfer in preventing plate exposure and wound infection has been previously reported and has led to increasing use of the harvest and inset of bony free tissue.<sup>4,5</sup> Free tissue transfer, however, is associated with a longer operative time and has the potential for increased donor site morbidity. Alternative reconstructive options, which would engineer autologous bone within the existing defect, are desirable.

\*Corresponding author: S. R. Buchman, MD, FACS, Mott Children's Hospital, Ann Arbor, Michigan. E-mail: sbuchman@med.umich.edu



Distraction osteogenesis (DO) is a form of *in vivo* tissue engineering whereby new bone formation is stimulated by the gradual separation of 2 osteogenic fronts.<sup>6</sup> Distraction osteogenesis has been used most extensively in the head and neck for congenital mandibular deformities,<sup>7</sup> and the use of DO may be a reconstructive option for tissue replacement after oncologic resection and/or osteoradionecrosis.

Distraction osteogenesis could have immense therapeutic utility but is a more formidable undertaking in the setting of previously irradiated tissue. The effects of ionizing radiation on the regeneration of bone within a fracture site include decreased osteocyte number, suppressed osteoblast activity, and diminished vascularity.<sup>8</sup> Direct cellular impairment and vascular injury are potential obstacles to successful distraction osteogenesis. Nonetheless, a small number of clinical cases and animal studies have reported using mandibular distraction osteogenesis following radiotherapy with mixed results.<sup>9</sup> Previous studies in our laboratory have also demonstrated the impairment of optimal bone regeneration in irradiated animals with regard to bone mineralization, biomechanical strength, and cellularity. Therapeutic adjuncts, therefore, will be important in improving the success and clinical utility of postradiation distraction osteogenesis.

Parathyroid hormone (PTH), a major regulator of  $Ca^{2+}$  homeostasis, can stimulate bone formation and/or resorption, depending on the mode of administration. Continuous infusions lead to greater bone resorption, whereas intermittent daily dosing has an anabolic effect and leads to increased bone mass.<sup>10</sup> PTH(1–34) has been shown to arrest and partially reverse bone loss in animals and humans,<sup>11</sup> and clinical trials have shown its benefit in osteoporosis.<sup>12</sup> Animal studies have also demonstrated that intermittent PTH(1–34) promotes osteogenesis in fracture healing and enhances the size and mechanical properties of calluses.<sup>13</sup> Intermittent PTH has also been shown to increase strength, stiffness, and bone mineral density (BMD) in a rat model of long bone distraction osteogenesis.<sup>14</sup>

Our goal was to investigate the effects of parathyroid hormone and radiotherapy in a murine model of distraction osteogenesis using qualitative union assessment and micro-computed radiomorphometrics. Our hypothesis is that intermittent systemic administration of PTH will serve as a stimulant to cellular function that will act to reverse radiation-induced damage and enhance bone

regeneration. Specific quantitative analysis of bone will allow us to compare outcomes of irradiated animals who have been treated with those that have not been treated with PTH. In addition we will gauge the efficacy of PTH to remediate radiation damage by comparing our results with those of nonirradiated animals who have undergone distraction osteogenesis alone.

## MATERIALS AND METHODS

### Experimental groups and model

Twenty 12-week-old male Lewis rats were assigned randomly to 1 of 3 experimental groups preoperatively: group 1, rats that would receive preoperative radiation followed by distraction ( $n = 7$ ); group 2, rats that would receive preoperative radiation followed by distraction and PTH ( $n = 5$ ); and group 3, rats that would undergo distraction alone ( $n = 8$ ).

The group 1 and group 2 rats underwent fractionated irradiation to the left hemimandible followed by a 2-week recovery period before surgery. All 3 experimental groups then underwent surgical osteotomy and placement of a distraction device with the osteotomy gap closed. All 3 groups were then subjected to a 4-day latency period followed by distraction 0.3 mm twice daily to a 5.1-mm total gap width. PTH (60  $\mu$ g/kg) + vehicle (0.9NS) were administered subcutaneously daily to group 2, beginning the first day of distraction for 21 days. The other 2 groups received vehicle injections during the same length of time. All 3 experimental groups underwent 28 days of regenerate consolidation after the last day of distraction (see Figure 1).

### Preoperative animal care

The male Lewis rats weighed approximately 350 g and were housed 3 animals per cage in a pathogen-free, restricted-access facility on arrival to our laboratory. Group 1 and group 2 animals were fed hard chow and water without restriction during a 3-day acclimation period and during radiotherapy. Group 3 animals were fed hard chow and water without restriction during the 3-day acclimation period. The diet was changed in all groups to moist chow 4 days preoperatively. All animal procedures were performed in accord with the National Institutes of Health *Guide for the Care and Use of Laboratory Animals* and approved by the University of Michigan Animal Care and Use Committee.

### Irradiation

Radiotherapy was performed at the Irradiation Core of the University of Michigan Cancer Center. Radiotherapy was delivered with a Phillips RT250 orthovoltage unit (250 kV, 15 mA; Kimtron Medical, Woodbury, CT). Dosimetry was carried out using an ionization chamber connected to an electrometer system. The group 1 and group 2 rats were irradiated after being anesthetized with isoflurane. Induction was begun at 4%, after which the rat was maintained at 1.5%. They were placed right-side down, to expose the left mandible. A lead shield was used to protect the remainder of the animal. A total of 35 Gy of radiation was delivered per rat in 5 fractions over 5

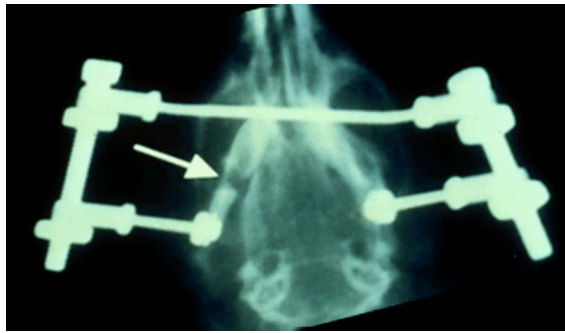


FIGURE 2. Each animal underwent bilateral external fixator placement and left mandible osteotomy. [Color figure can be viewed in the online issue, which is available at [wileyonlinelibrary.com](http://wileyonlinelibrary.com).]

days at a rate of 7 Gy per fraction, which is the bioequivalent dose of 70 Gy in humans.<sup>15</sup>

### Surgical procedure

Our surgical distraction procedure has been described and published before,<sup>16</sup> but briefly, preoperatively, animals were given prophylactic gentamicin (5 mg/kg, subcutaneously) 1 hour prior to incision. In addition, buprenorphine (0.03 mg/kg, subcutaneously) and lactated Ringer's solution (25 mL/kg, subcutaneously) were given for pain control and hydration, respectively. General anesthesia was induced with an isoflurane/oxygen mixture, and the animal's ventral submental hair was shaved in preparation for surgery. The animal was then placed in a supine position and prepped and draped in a sterile fashion, and the procedure commenced under sterile conditions.

A 1.5-cm midline incision was placed ventrally from the anterior submentum. Skin flaps were elevated, exposing the anterolateral mandible. After predrilling holes bilaterally 0.5 mm posterior to the symphysis, a 1.5-inch stainless steel threaded pin was inserted transversely across the anterior mandible, with the ends brought externally through the skin, creating the anterior portion of our modified external fixator/distraction device. On each side, an 8-mm incision was made through the masseter, down to and in line with the inferior border of the mandible, approximately 2.5 mm anterior to the angle. After predrilling 2 mm superior to the inferior border and 4 mm anterior to the angle, bilateral stainless steel threaded pins were inserted buccal-to-lingual and secured with our custom titanium washer and nut. The pin ends were brought externally through the skin for the posterior fixator placement with titanium cap screws. The right mandible was rigidly fixed, whereas the left mandible was fixed with a distraction screw for postoperative manipulation.

A vertical osteotomy was made in the left hemimandible approximately 2 mm anterior to the titanium washer using a 10-mm micro reciprocating blade (Stryker, Portage, MI) attached to a power saw (Stryker). The osteotomy extended from the inferior mandible border superiorly to the sigmoid notch along the anterior aspect of the coronoid process. The osteotomy edges were reduced and then resecured with the fixator (see Figure 2). The wound was irrigated, hemostasis verified, soft tissue approxi-

mated using 4-0 Vicryl (Ethicon, Inc., Somerville, NJ) suture, and the midline incision closed with staples.

### Postoperative animal care

All experimental groups were housed 1 animal per cage and fed moist chow with Hill's high-calorie diet (Columbus Serum, Columbus, OH) and water without restriction. Both groups of animals were given 2 postoperative doses of gentamicin (5 mg/kg subcutaneously every 12 hours). Buprenorphine was continued (0.03 mg/kg) with 10 mL of lactated Ringer's solution subcutaneously every 12 hours through postoperative day 4 and as needed thereafter. Bactrim was given with the moist chow postoperatively until euthanized prophylactically against postoperative wound infection. Pin care was performed with Silvadene (Monarch Pharmaceuticals, Inc., Bristol, TN) every other day. Maxillary incisors were clipped weekly because of overgrowth from crossbite and staples removed at postoperative day 10. Weights were monitored daily and diets adjusted as needed.

### Distraction protocol

Group 1, group 2, and group 3 animals underwent distraction after 4 days of latency. One 180° clockwise turn of the distraction screw corresponded to a 0.3-mm separation of the osteotomy fronts. A total of 17 half-turns were performed every 12 hours, resulting in a 5.1-mm distraction gap. No analgesic or sedation was required during the distraction. After 28 days of consolidation, all animals were euthanized (postoperative day 41).

### Microcomputed tomography

Mandibles were harvested and then scanned at 45- $\mu$ m resolution with micro-CT. The region of interest was defined as a distance measuring 2 mm after the third molar corresponding to the surgical site of the osteotomy and set gap distance. Only bone within each section was selected. In cases in which a part of the incisor or canal was present, the tooth, the canal, and the periodontal tissue were excluded for uniformity. Analysis of the left hemimandible region of interest was then performed with MicroView 2.2 software (GE Healthcare, Milwaukee, WI). Contours were defined highlighting the region of interest using the spline tool in MicroView.

Each voxel is assigned a grayscale value in MicroView; to calculate densities, it uses an algorithm that converts the grayscale value of each voxel to mineral content. Mature bone was thresholded at 2000 HU, whereas newly formed bone was thresholded at 800 HU. Our range for newly remodeled bone therefore extended from 800 to 2000 HU, as is the protocol in our laboratory based on previous studies, and this has been supported with histomorphometric correlation.<sup>15,17</sup> BMD was defined as the total mineral content of newly remodeled bone divided by the total volume of the region of interest, the distraction gap. Bone volume fraction (BVF) was defined as the volume of newly remodeled bone divided by the total volume of the region of interest, which included air and soft tissue.

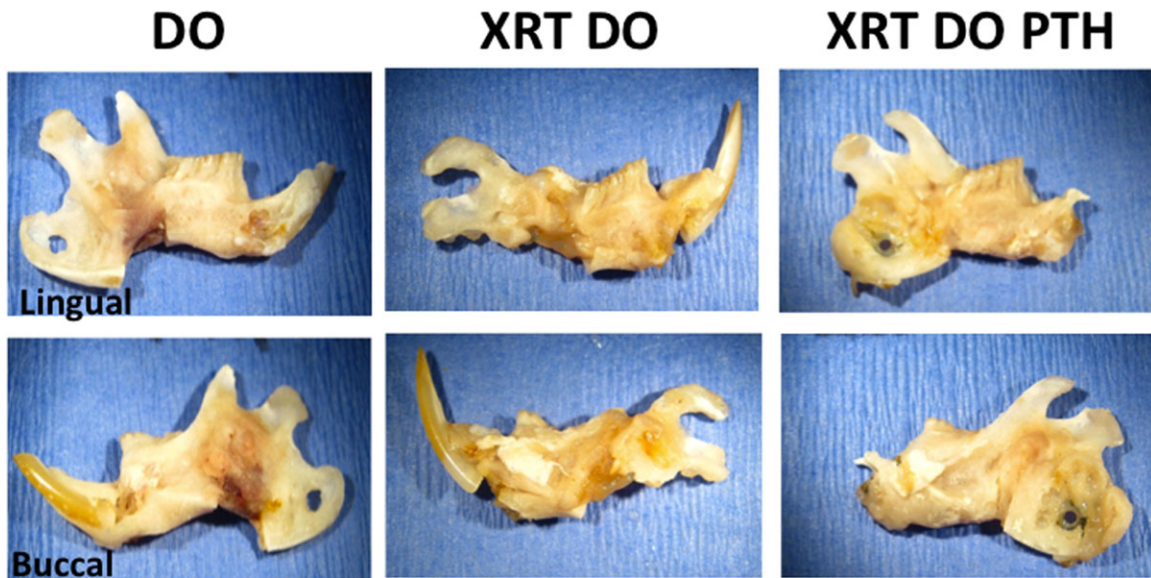


FIGURE 3. Lingual and buccal views from gross specimens from each experimental group: the specimen on the left underwent distraction alone (group 3), the middle group underwent radiation and distraction (group 1), and the group on the right underwent radiation/distraction + parathyroid hormone (PTH) (group 2). There were visible differences between the 3 groups, but the XRT-DO-PTH appears more similar to the nonradiated, distraction alone specimen. [Color figure can be viewed in the online issue, which is available at [wileyonlinelibrary.com](http://wileyonlinelibrary.com).]

### Union quality

Regenerate integrity was qualitatively assessed on a 4-point grading scale by 3 independent reviewers. In all cases, the grades were unanimous. A grade of 1 indicated complete nonunion, with no connection between the 2 fronts of the distracted region. A grade of 2 indicated fibrous union, with only fibrous tissue and no bone between the 2 fronts of the distracted region. A grade of 3 indicated bony bridging, with between 1 and 25% of the connection between to the fronts of the distracted region comprised of bone. A grade of 4 indicated bony union, with over 25% of the connection between the fronts of the distracted region comprised of bone.

### Statistical analysis

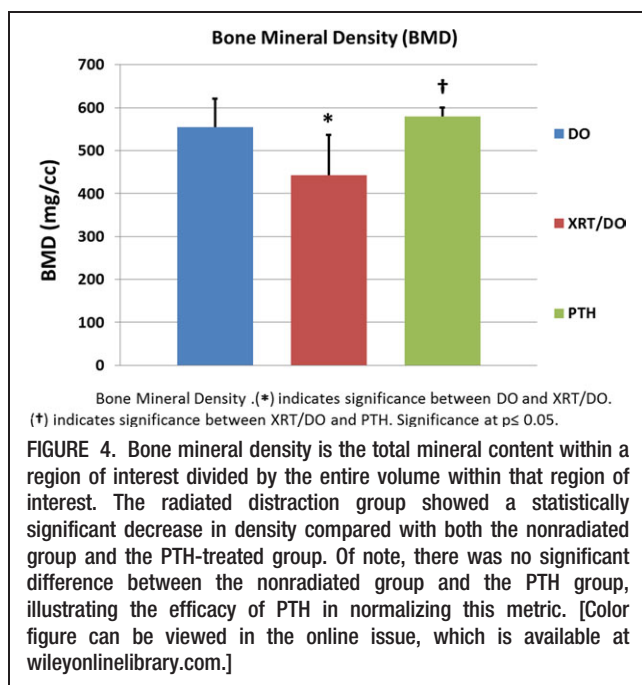
One-way analysis of variance (ANOVA) was used for analyzing BMD and BVF (SPSS version 16.0; SPSS, Inc., Chicago, IL). Due to the noncontinuous nature of union grading, a Mann-Whitney *U* statistical analysis test was used to analyze these data. Results were accepted as statistically significant at a value of  $p < .05$ .

### RESULTS

Animals in all 3 treatment groups tolerated the protocol. Animals treated with radiation demonstrated expected clinical signs of radiation treatment, ranging from alopecia to mucositis. Groups were assigned a priori and the variable number in each group reflects expiration during anesthetic for the procedure and/or postoperative weight loss requiring euthanasia. Postoperatively, animals included in the study lost weight initially but then gained weight once distraction was complete and in the consolidation phase. None of the animals experienced device dislodgement, and the fixators remained stable until the animals were euthanized on postoperative day 41.

Gross examination of the left hemimandibles showed significant qualitative differences in union quality. The overall union quality assessment was worst in the XRT-DO animals (group 1; median grade, 2; range, 1–3) and best in the DO alone animals (group 3; median grade, 4; range, 2–4). Interestingly, there was no statistical difference in union quality between radiated distracted animals treated with PTH (XRT-PTH-DO; group 2; median grade, 3; range, 2–4) and the nonradiated DO alone (group 3) animals. The union quality of XRT-DO animals (group 1; mean grade, 1.875), however, was significantly worse than the nonradiated (group 3) animals and animals treated with PTH (group 2; mean grade, 3.125) ( $p = .02$ ). In other words, there was more evidence of union in the radiated animals treated with PTH (XRT-DO-PTH, group 2) and nonradiated animals (DO alone, group 3) compared with the radiated distracted group (XRT-DO, group 1) (see Figure 3).

The radiomorphometrics, generated from the micro-CT data, which included BMD and BVF, was similar to gross examination and union quality. The group treated with radiation before DO without PTH showed a statistically significant decrease in BMD. However, despite being treated with radiation, the group treated with PTH (XRT-PTH-DO) demonstrated maintenance of BMD compared with the nonradiated DO alone group. In analyzing the BMD, the radiated distraction group (XRT-DO, 452 mg/mL) showed a statistically significant decrease in density compared with both the nonradiated group (DO alone, 552 mg/mL,  $p = .017$ ) and the PTH-treated group (XRT-PTH-DO, 558 mg/mL,  $p = .009$ ). There was no significant difference between the nonradiated group and the PTH group (552 mg/mL vs 558 mg/mL,  $p = .91$ ) (see Figure 4). Micro-computed tomographic analysis of BVF showed a significant decrease in the percentage of bone in our radiated group (51.19%) compared with the



nonradiated (72.46%,  $p < .001$ ) and PTH-treated groups (69.84%,  $p < .001$ ). There was no difference between the nonradiated group and the PTH group (72.46% vs 69.84%,  $p = .97$ ) (see Figure 5). Essentially, the addition of PTH to radiated-distraction animals normalized both metrics (BMD and BVF) toward the nonradiated group (DO alone, group 3).

## DISCUSSION

Radiation causes injury to cell populations, alters cytokine expression profiles, and leads to hypovascular and hypoxic conditions.<sup>8</sup> In vitro studies on irradiated mouse osteoblasts demonstrate decreased cell proliferation and a dose-dependent sustained reduction in collagen production compared with controls.<sup>18</sup> Radiation has also previously been shown to decrease bone quality, and BMD in particular.<sup>19</sup>

Mandibular distraction osteogenesis requires the differentiation and proliferation of osteoprogenitor cells after organization of the initial surgical wound.<sup>20</sup> It has previously been shown that radiation results in poorer regenerate outcomes in mandibular distraction osteogenesis with regard to cellularity, radiomorphometrics, and biomechanical strength.<sup>17,21,22</sup> Our findings of poorer union quality and decreased BMD and BVF in the radiated, distracted animals (group 1) are consistent with these previous outcomes.

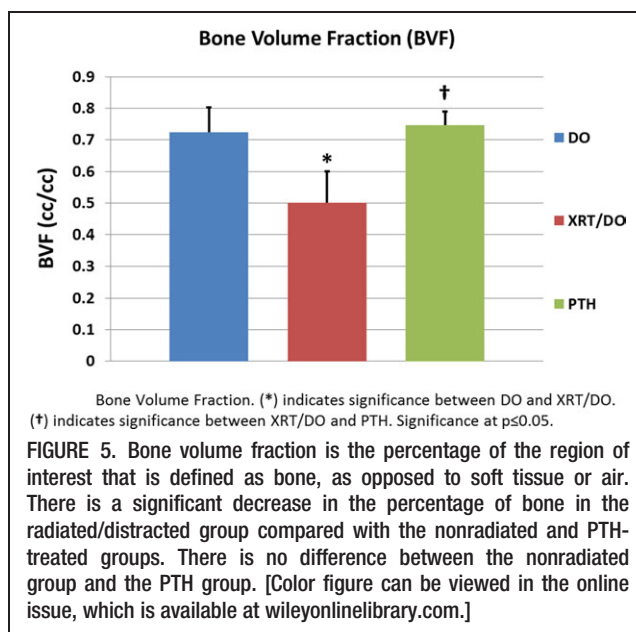
The finding that PTH improves regenerate outcomes in terms of union quality, BMD, and BVF in radiated animals that underwent mandibular distraction osteogenesis is an entirely novel application of PTH therapy. Parathyroid hormone (PTH) is the only U.S. Food and Drug Administration–approved therapy that stimulates bone formation in osteoporotic individuals and has been shown to reverse loss of BMD and prevent fractures in clinical trials.<sup>12,23</sup> PTH has been shown to increase bone formation on cancellous, endocortical, and periosteal bone surfaces. On the cellular level, intermittent PTH promotes

osteoblast differentiation and activation.<sup>24</sup> The overall osteoblast number is also increased by direct PTH activation of survival signaling over apoptosis.<sup>25</sup> Interestingly, it has been shown that radiation reduces osteoblast number and function. It is possible that these particular effects of radiation may be specifically negated by PTH. The improvement in cell number and function by PTH therapy explains the normalization of radiated and distracted bone in terms of the radiomorphometric measures of density and percentage of bone.

Our findings would support the potential of PTH to be used clinically to treat pathologic situations where remediation of bone regeneration is essential. The addition of PTH as a therapeutic intervention during postradiation mandibular DO would make this a more feasible and potentially more successful reconstructive option in oncologic resections or in reconstruction for defects after surgical treatment of osteoradionecrosis. The therapeutic efficacy of PTH to stimulate and enhance bone regeneration in our irradiated model of distraction osteogenesis suggests that its clinical application would result in an improvement in the mandibular union quality.

The use of PTH might even be extrapolated to cases of osteoradionecrosis that may have the chance for therapeutic salvage by intermittent PTH dosing. Interestingly, 2 cases have been reported in which terparatide (PTH 1–34) has successfully resolved osteonecrosis of the jaw caused by bisphosphonates.<sup>26,27</sup> Nonsurgical salvage of previous medical failures could be an exciting approach for PTH to remedy difficult cases of osteoradionecrosis.

We plan to further examine the effects of PTH on post-radiation distraction osteogenesis with other outcome measures, including quantitative histomorphometrics, to further confirm our hypothesis. In addition to the ability of PTH to ossify a tissue-engineered construct, we also plan to examine its potential vasculogenic effects during MDO. Importantly, biomechanical strength testing of PTH-treated mandibles is also currently under way, given that this will be the most relevant outcome measure for



clinical and functional purposes. Finally, we plan to study PTH in combination with other therapies, with the anticipation that multiple therapies may prove to be synergistic in improving bone regeneration after radiation. We are hopeful that the use of these innovative therapeutic strategies could accelerate the translation of our work from the bench to the bedside to provide novel remedies for both surgeons and their patients suffering from devastating radiation-related maladies.

## Acknowledgements

This work is supported by both a grant from the National Institute of Health (NIH-R01 CA 125187-01) to Dr. Steven R. Buchman and by a research grant "Effect of Anabolic PTH on Distracted Mandibular Bone" from the AAO HNS.

## REFERENCES

- Shah JP, Gil Z. Current concepts in management of oral cancer surgery. *Oral Oncol* 2009;45:394-401.
- Sedaghat AR, Zhang Z, Begum S, et al. Prognostic significance of human papillomavirus in oropharyngeal squamous cell carcinomas. *Laryngoscope* 2009;119:1542-1549.
- Jereczek-Fossa BA, Orecchia R. Radiotherapy-induced mandibular bone complications. *Cancer Treat Rev* 2002;28:65-74.
- Foster RD, Anthony JP, Sharma A, Pogrel MA. Vascularized bone flaps versus nonvascularized bone grafts for mandibular reconstruction: an outcome analysis of primary bony union and endosseous implant success. *Head Neck* 1999;21:66-71.
- Pogrel MA, Podlesh S, Anthony JP, Alexander J. A comparison of vascularized and nonvascularized bone grafts for reconstruction of mandibular continuity defects. *J Oral Maxillofac Surg* 1997;55:1200-1206.
- Rowe NM, Mehrara BJ, Dudziak ME, et al. Rat mandibular distraction osteogenesis: Part I. Histologic and radiographic analysis. *Plast Reconstr Surg* 1998;102:2022-2032.
- Swennen G, Schliephake H, Dempf R, Schierle H, Malevez C. Craniofacial distraction osteogenesis: a review of the literature: Part I: clinical studies. *Int J Oral Maxillofac Surg* 2001;30:89-103.
- Dudziak ME, Saadeh PB, Mehrara BJ, et al. The effects of ionizing radiation on osteoblast-like cells in vitro. *Plast Reconstr Surg* 2000;106:1049-1061.
- Sacco AG, Chepeha DB. Current status of transport-disc-distraction osteogenesis for mandibular reconstruction. *Lancet Oncol* 2007;8:323-330.
- Gunnes M, Hock JM. Anabolic effect of parathyroid hormone on cancellous and cortical bone histology. *Bone* 1993;14:277-281.
- Chalidis B, Tzioupis C, Tsiroidis E, Giannoudis PV. Enhancement of fracture healing with parathyroid hormone: preclinical studies and potential clinical applications. *Expert Opin Invest Drugs* 2007;16:441-449.
- Neer RM, Arnaud CD, Zanchetta JR, et al. Effect of parathyroid hormone (1-34) on fractures and bone mineral density in postmenopausal women with osteoporosis. *N Engl J Med* 2001;344:1434-1441.
- Nakazawa T, Nakajima A, Shiomi K, et al. Effects of low-dose, intermittent treatment with recombinant human parathyroid hormone (1-34) on chondrogenesis in a model of experimental fracture healing. *Bone* 2005;37:711-719.
- Seebach C, Skripitz R, Andreassen TT, Aspenberg P. Intermittent parathyroid hormone (1-34) enhances mechanical strength and density of new bone after distraction osteogenesis in rats. *J Orthop Res* 2004;22:472-478.
- Tchanque-Fossuo CN, Monson LA, Farberg AS, et al. Dose-response effect of human equivalent radiation in the murine mandible: part I. A histomorphometric assessment. *Plast Reconstr Surg* 2011;128:114-121.
- Buchman SR, Ignelzi MA Jr, Radu C, Wilensky J, Rosenthal AH, Tong L, Rhee ST, Goldstein SA. Unique rodent model of distraction osteogenesis of the mandible. *Ann Plast Surg* 2002;49:511-519.
- Fregene A, Jing XL, Monson LA, Buchman SR. Alteration in volumetric bone mineralization density gradation patterns in mandibular distraction osteogenesis following radiation therapy. *Plast Reconstr Surg* 2009;124:1237-1244.
- Gal TJ, Munoz-Antonia T, Muro-Cacho C, Klotch DW. Radiation effects on osteoblasts in vitro. *Arch Otolaryngol Head Neck Surg* 2000;126:1124-1128.
- Mitchell MJ, Logan PM. Radiation-induced changes in bone. *Radiographics* 1998;18:1125-1136.
- Mccarthy JG, Stelnicki EJ, Mehrara BJ, Longaker MT. Distraction osteogenesis of the craniofacial skeleton. *Plast Reconstr Surg* 2001;107:1812-1827.
- Inyang AF, Schwarz DA, Jamali AM, Buchman SR. Quantitative histomorphometric assessment of regenerate cellularity and bone quality in mandibular distraction osteogenesis after radiation therapy. *J Craniofac Surg* 2010;21:1438-1442.
- Schwarz DA, Jamali AM, Kakwan MS, et al. Biomechanical assessment of regenerate integrity in irradiated mandibular distraction osteogenesis. *Plast Reconstr Surg* 2009;123 (Suppl 2):114S-122S.
- Black D, Greenspan S, Ensrud K, et al. The effects of parathyroid hormone and alendronate alone or in combination in postmenopausal osteoporosis. *N Engl J Med* 2003;349:1207-1215.
- Jilka RL. Molecular and cellular mechanisms of the anabolic effect of intermittent PTH. *Bone* 2007;40:1434-1446.
- Jilka RL, O'Brien CA, Ali AA, Roberson PK, Weinstein RS, Manolagas SC. Intermittent PTH stimulates periosteal bone formation by actions on post-mitotic preosteoblasts. *Bone* 2009;44:275-286.
- Harper RP, Fung E. Resolution of bisphosphonate-associated osteonecrosis of the mandible: possible application for intermittent low-dose parathyroid hormone [rhPTH(1-34)]. *J Oral Maxillofac Surg* 2007;65:573-580.
- Lau AN, Adachi JD. Resolution of osteonecrosis of the jaw after teriparatide [recombinant human PTH-(1-34)] therapy. *J Rheumatol* 2009;36:34-37.