

CASE REPORTS

Pediatric Giant Right Atrial Aneurysm: A Case Series and Review of the Literature

Erika E. Harder, MD,* Richard G. Ohye, MD,[†] Marc D. Knepp, MD,[‡] and Sonal T. Owens, MD*

*Division of Pediatric Cardiology, Department of Pediatrics, [†]Section of Pediatric Cardiac Surgery, Department of Cardiac Surgery, University of Michigan, Ann Arbor, Mich, [‡]Division of Pediatric Cardiology, Department of Pediatrics, University of Illinois at Peoria, Peoria, Ill, USA

ABSTRACT

Giant right atrial aneurysm is a rare form of congenital heart disease with a wide spectrum of clinical presentation varying from asymptomatic patients to those with refractory atrial arrhythmias or severe airway obstruction. Diagnosis is often confused with other causes of right atrial dilation such as Ebstein disease. Because of its rare occurrence and variable clinical presentation, inconsistencies in medical and surgical management strategies exist between centers. We present five cases of giant right atrial aneurysm managed at our institution and discuss the clinical presentation, diagnostic challenges, and medical and surgical management.

Key Words. Giant Right Atrial Aneurysm; Pediatric; Infant

Introduction

Giant right atrial aneurysm (GRAA), otherwise known as idiopathic dilatation of the right atrium or congenital enlargement of the right atrium, is a rare form of congenital heart disease defined as an isolated enlargement of the right atrium in the absence of additional cardiac lesions known to cause right atrial dilatation. This lesion was initially described in the medical literature in 1955 by Bailey.¹ With advancing imaging technology, the diagnosis of GRAA is being made more frequently in pediatric patients and is often identified in the prenatal period.² Case reports in the current literature describe a highly variable presentation. Although many patients with GRAA may be asymptomatic, a number of reports describe significant atrial arrhythmias or intracavitary thrombi.²⁻⁴ Optimal management for GRAA, including the role of prophylactic aneurysmal resection, remains controversial and varies between centers.

Because of its rare occurrence, limited information regarding the presentation, clinical course, and management is available to guide physicians who are managing pediatric patients with GRAA.

We report five cases of GRAA managed at our institution with varying presentations and describe their clinical course and medical management strategies in the postnatal period.

Case 1

A 26-month-old child presented to a referring institution with a 5-day history of progressive shortness of breath and fatigue. Three weeks prior to her presentation, she had been diagnosed with left lower lobe pneumonia by clinical exam and treated with antibiotics and systemic steroids with only marginal improvement. The child's medical history was remarkable for slow weight gain through childhood, recurrent respiratory infections, and increasing diaphoresis with activity in the preceding year. On presentation, she was found to have atrial tachycardia with variable atrioventricular conduction and a ventricular rate of 240 bpm. Adenosine administration did not convert the tachycardia, but revealed atrial flutter. Sedated direct current cardioversion was unsuccessful so the child was started on antiarrhythmic therapy including amiodarone and digoxin. Progressive respiratory distress prompted intubation

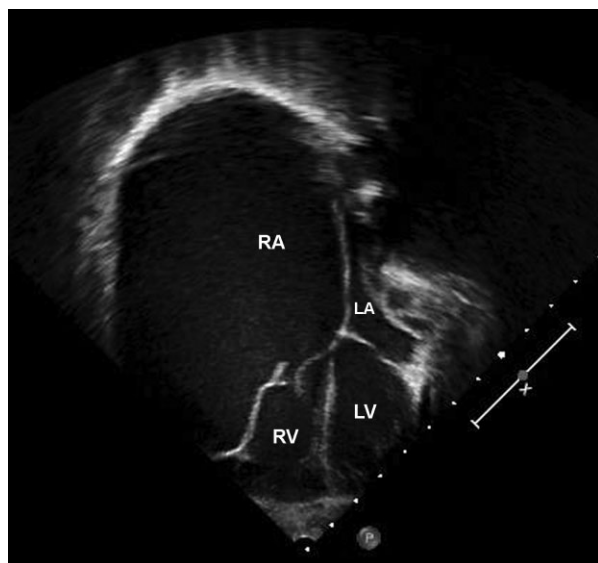


Figure 1. Case 1. Apical four-chamber view demonstrating a massive right atrial aneurysm and left atrial compression. RA, right atrium; LA, left atrium; RV, right ventricle; LV, left ventricle.

and mechanical ventilation. Initial echocardiogram revealed severe right atrial dilatation with severe ventricular dysfunction and the diagnosis of Ebstein disease was made. Hypotension improved with dopamine and milrinone infusions and she was transferred to our institution for further assessment and management.

Transfer was complicated by recurrent atrial tachycardia with hypotension requiring direct current cardioversion. Upon arrival to our institution, patient stability improved after amiodarone infusion was initiated and sedation was optimized. Digoxin therapy was discontinued. Investigations completed on arrival to our institution revealed severe cardiomegaly on chest radiograph with complete opacification of the left hemithorax. Echocardiogram (Philips iE33, Philips Ultrasound, Bothell, WA, USA) revealed massive right atrial enlargement (Figure 1) with compression of the left atrium and pulmonary veins with no significant flow acceleration. The attachment of the tricuspid valve septal leaflet was not apically displaced but the septal leaflet appeared tethered with restricted movement. The anterior tricuspid valve leaflet appeared shortened, and its movement was restricted by compression from the right atrial aneurysm. No intracardiac thrombus was seen. The diagnosis of a GRAA rather than Ebstein disease was made. On an amiodarone infusion, the child remained primarily in sinus rhythm with intermittent junctional bradycardia. Episodes of

atrial tachycardia and hypotension occurred with any significant handling or positional change. Ventilation remained difficult due to asymmetric lower airway obstruction presumed to be secondary to airway compression of the left bronchi from cardiac enlargement. Empiric antibiotic therapy was also initiated due to her preceding infectious symptoms and potential for post-obstructive pneumonia. Further investigations identified a significant coagulopathy and transaminitis, reflecting acute hepatic injury. Additional thoracic imaging and bedside bronchoscopy could not be completed to further delineate her cardiac and thoracic airway anatomy due to patient instability and recurrent atrial tachycardia.

The child's hemodynamic status improved over 72 hours, although her ventilation management remained tenuous due to presumed asymmetric airway compression. Neuromuscular blockade and sedatives were required to maintain adequate ventilation. Endotracheal secretion and urine cultures identified pathologic organisms and antibiotic therapy was tailored. Because of persistent airway obstruction, a decision was made to proceed with intraoperative bronchoscopy and right atrial aneurysm resection. During a limited preoperative bronchoscopy, narrowing the left bronchus was noted and a large mucus plug was removed. Right atrial aneurysm resection was completed, and a thin-walled massive atrial aneurysm was resected. Because of poor coaptation of the tricuspid valve leaflets, partial annuloplasty was completed obliterating the posterior leaflet to form a bicuspid valve. Intraoperative transesophageal echocardiogram showed a mildly dilated right atrium significantly smaller than preoperative size with mild tricuspid regurgitation and stenosis. No arrhythmias occurred during the procedure, and permanent epicardial leads were placed to manage potential postoperative and long-term arrhythmias.

The initial postoperative period was complicated by difficult ventilation due to residual dynamic airway obstruction. Ventilation improved with the use of high positive end expiratory pressure and prone positioning. Respiratory aspirate cultures obtained during the bronchoscopy confirmed the preoperative diagnosis of post-obstructive pneumonia. A complete course of antibiotic therapy was completed prior to discharge. A prolonged ventilatory support wean was required and the child eventually extubated on postoperative day 14. The amiodarone infusion was weaned and no atrial arrhythmias recurred in the

postoperative course. No oral anti-arrhythmic medications were initiated. Pacemaker placement was not required. The child's coagulopathy and transaminitis resolved and heparin infusion was used for thromboprophylaxis until oral aspirin therapy could be initiated. Echocardiogram prior to discharge showed a mildly dilated right atrium and mild tricuspid regurgitation and stenosis. The child was discharged home 20 days after the procedure. In the 4 months of subsequent follow-up since discharge, she has remained asymptomatic and has had no recurrence of atrial tachyarrhythmias.

Case 2

Giant right atrial aneurysm was diagnosed by fetal echocardiogram at 20 weeks gestation. Serial echocardiograms were completed through pregnancy and showed no evidence of significant tricuspid regurgitation or left atrial compression. Postnatal echocardiogram confirmed the fetal diagnosis of GRAA. A large atrial aneurysm was seen along the lateral right atrial wall with extension from the inferior vena cava to superior vena cava. The remaining intracardiac anatomy was normal with normal tricuspid valve morphology and no insufficiency. The infant was discharged home at 4 days of life on low-dose aspirin for thromboprophylaxis. The infant maintained normal growth with no respiratory symptoms or arrhythmias. At 4 months of age, the child underwent elective resection of the GRAA. A significantly enlarged thin-walled and broad-based right atrial aneurysm was resected with no evidence of thrombus. The postoperative course was uncomplicated with early extubation and no arrhythmias. Echocardiogram prior to discharge showed normal right atrial size with no aneurysmal tissue and trivial tricuspid regurgitation. At 3 years of age, the child is thriving with normal right atrial size by echocardiogram.

Case 3

Antenatal diagnosis of right atrial dilatation was made at a referring institution by fetal echocardiogram. After uncomplicated full-term delivery, the infant was managed at the referring institution and clinically remained asymptomatic with persistent right atrial dilatation with normal tricuspid valve anatomy and no insufficiency on serial echocardiograms. Aspirin for thromboprophylaxis was not initiated. Septations and a possible membrane dividing the right atrium were identified raising the concern for a possible diagnosis of cor triatri-

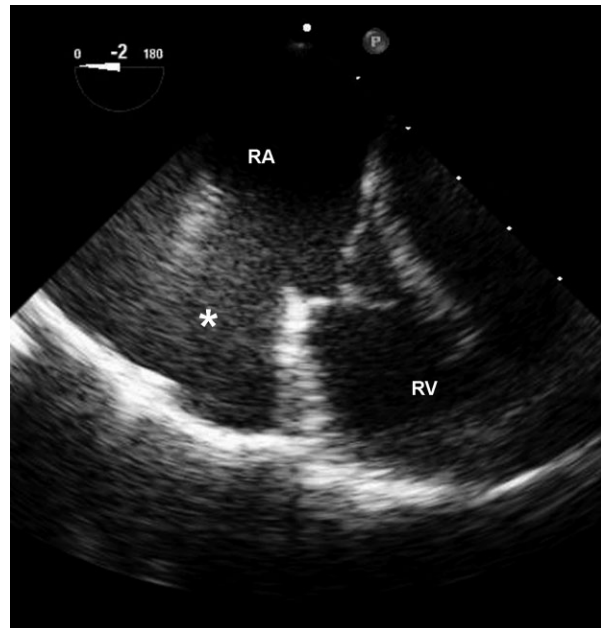


Figure 2. Case 3. Preoperative transesophageal echocardiogram. RA, right atrium; RV, right ventricle. *Giant right atrial aneurysm.

tum dexter. To better define the systemic venous and right atrial anatomy, cardiac catheterization was pursued at 1 year of age at the referring institution. Angiography revealed a GRAA with dimensions of 5.5×3.5 cm with multiple membranes consistent with remnant venous valves. The remaining intracardiac anatomy was normal with no tricuspid regurgitation and normal right heart hemodynamics. At 15 months of age, the child was referred to our institution for prophylactic resection of the GRAA. Preoperative echocardiograms at our institution showed a large anterior out-pouching of the right atrium that extended apically and anteriorly with normal tricuspid valve anatomy and systemic venous return, findings consistent with a GRAA (Figure 2). Thin septations were noted within the aneurysm with no thrombus or obstruction to flow. The thin-walled GRAA was resected. The postoperative course was uncomplicated with no respiratory concerns or arrhythmias. The discharge echocardiogram showed a mildly dilated right atrium with no residual aneurysmal tissue and trivial tricuspid regurgitation. Four years after atrial resection, the child has remained asymptomatic with only mild right atrial dilation with no significant tricuspid regurgitation.

Case 4

After an incidental finding of cardiomegaly on chest radiograph, an asymptomatic 5-year-old was

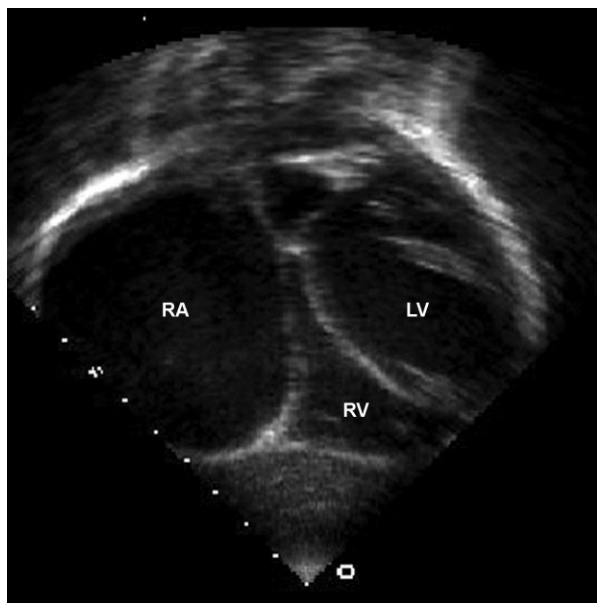


Figure 3. Case 4. Subcostal coronal view demonstrating a giant right atrial aneurysm. RA, right atrium; RV, right ventricle; LV, left ventricle.

diagnosed with GRAA and referred to our institution. Baseline Holter monitor showed no atrial arrhythmias. Echocardiogram identified a GRAA (Figure 3) with anterior extension causing impingement of the anterior right ventricular wall and tricuspid valve annulus with resultant mild tricuspid regurgitation. The decision was made to proceed with prophylactic right atrial aneurysm resection, and a thin-walled right atrial aneurysm was found. The tricuspid valve anatomy was normal with no thrombus seen. The postoperative course was uncomplicated. Discharge echocardiogram showed normal right atrial size with no aneurysmal tissue and trivial tricuspid regurgitation. At 15 years of age, he is asymptomatic with normal right atrial size and no significant tricuspid regurgitation.

Case 5

At 18 weeks gestation, the diagnosis of GRAA was made by fetal echocardiogram. The fetus was followed with serial echocardiograms through pregnancy with persistence of the GRAA (Figure 4A) with mild central tricuspid regurgitation, but no arrhythmias or fetal hydrops. Delivery occurred at 39 weeks gestation by planned Cesarean section for maternal indications. Postnatal echocardiogram (Figure 4B) confirmed the fetal diagnosis of GRAA with otherwise normal intracardiac anatomy, normal ventricular function, and mild to

moderate tricuspid regurgitation. After 4 days of observation, the infant was discharged home. Low-dose aspirin was started prior to discharge for thromboprophylaxis. Serial echocardiograms were done that showed progressive enlargement of the GRAA causing compression of the left atrium with mild to moderate tricuspid regurgitation although the infant remained asymptomatic with normal growth. Possible right atrial thrombus was identified on an echocardiogram completed at an outside institution at 5 weeks of age and prompted the decision to proceed with right atrial aneurysm resection. Preoperative transthoracic echocardiogram completed at our institution did not show any evidence of intracardiac thrombi but the decision was made to proceed with elective right atrial resection due to progressive GRAA enlargement and degree of tricuspid regurgitation.

At 6 weeks of age, surgical resection of the GRAA was completed. A large, thin-walled right atrial aneurysm was identified with no significant thrombus. Per operative documentation, direct inspection of the tricuspid valve revealed no clear mechanism of regurgitation so the tricuspid valve was not manipulated. Intraoperative transesophageal echocardiogram showed moderate to severe tricuspid regurgitation with tethering of the septal leaflet. The initial postoperative course was complicated by hypotension requiring vasoactive support and pulmonary hypertension managed with conservative measures and inhaled nitric oxide. Increased edema and ascites limiting mechanical ventilation imposed the need for peritoneal drain placement, which immediately improved ventilation. No fixed or dynamic airway obstruction was noted. The infant was extubated on the third postoperative day and was discharged home on the seventh postoperative day. Echocardiogram prior to discharge showed a mildly dilated right atrium with no appreciated aneurysmal tissue. Severe tricuspid regurgitation was noted due to poor coaptation of the tricuspid valve leaflets and mild septal leaflet tethering. No arrhythmias were noted during the hospital course. Two years after resection, the child has remained clinically asymptomatic with stable, but persistent severe tricuspid regurgitation. No further surgical procedures have been required to date.

Histologic Findings

Histologic evaluation of the right atrial tissue specimens resected from the cases showed a variety of findings including focal nodular myxoid

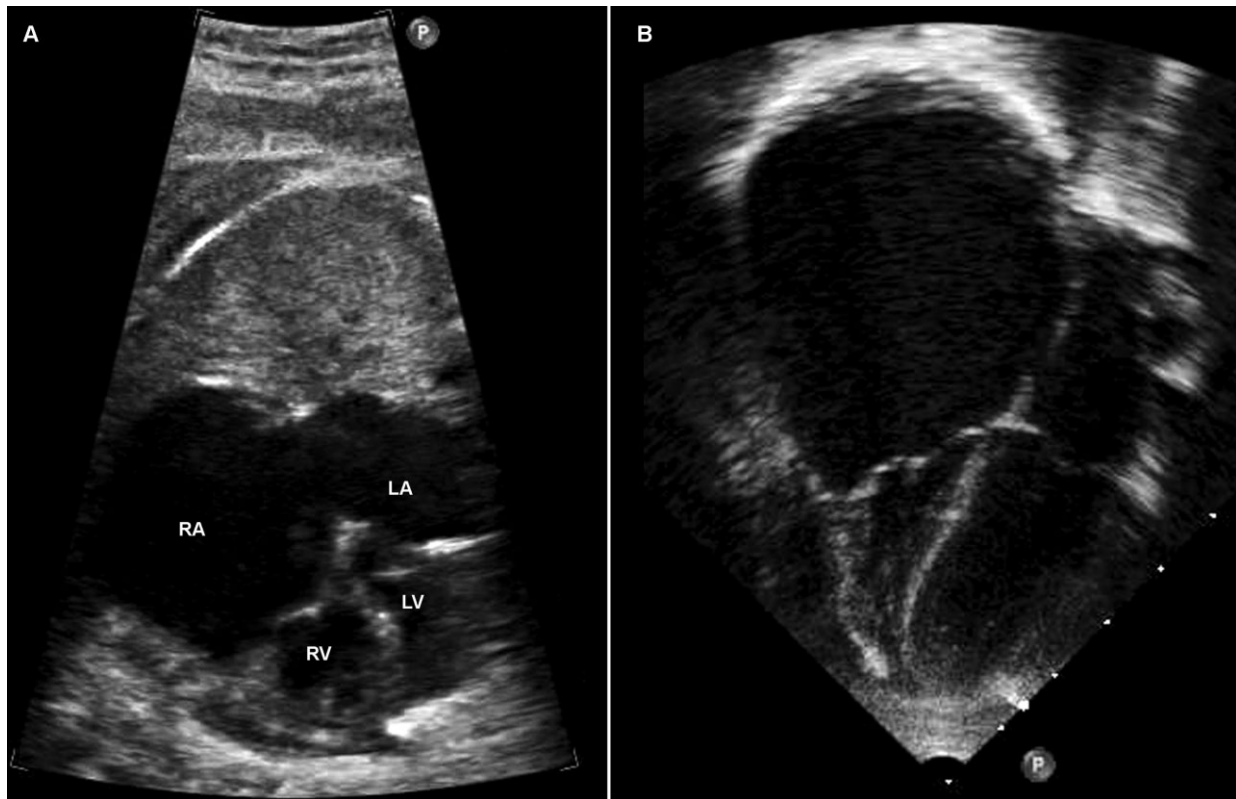


Figure 4. Case 5. (A) Fetal echocardiogram, 36 weeks gestation. A four-chamber view demonstrating a giant right atrial aneurysm contiguous with the main body of the right atrium. (B) Postnatal echocardiogram. RA, right atrium; LA, left atrium; RV, right ventricle; LV, left ventricle.

changes, mild subendocardial fibrosis, and normal atrial tissue. No mural thrombi were identified. Similar to other reported pediatric GRAA cases, we did not identify any specific histologic findings differentiating GRAA from other causes of right atrial enlargement.

Discussion

Giant right atrial aneurysm is a rare form of congenital heart disease that has been identified in many age groups, although the majority of the reported cases involve adult patients.³ Given the paucity of pediatric cases in the literature, medical decision making is difficult for physicians managing pediatric patients with GRAA. Regardless of age at diagnosis, clinical presentation may be variable, diagnosis challenging, and medical and surgical management recommendations ambiguous. In the five pediatric cases presented, we emphasize these clinical issues and discuss the role of prophylactic atrial aneurysm resection in the management of these patients.

Despite imaging advancements, the diagnosis of GRAA remains challenging in all age groups and is now being made more frequently in fetal and pediatric patients.³ The diagnosis can be difficult as it is easily mistaken for more common anomalies that involve right atrial enlargement. Alternative diagnoses that can mimic GRAA include Ebstein disease, pericardial effusion, pericardial cysts, and tumors.⁵⁻⁷

Multiple imaging modalities are currently available, but in the pediatric population, the diagnosis of GRAA is often made by transthoracic echocardiography alone. Fetal echocardiography often provides adequate imaging for prenatal diagnosis. In our series, three cases were initially diagnosed prenatally. With suboptimal transthoracic imaging, alternative modalities such as transesophageal echocardiography with contrast study, cardiac magnetic resonance imaging, and computed tomography have also been used to confirm the diagnosis of GRAA.⁸⁻¹¹ Angiography is currently used infrequently given the improved quality and availability of noninvasive imaging modalities.

Regardless of the selected modality, imaging should demonstrate a disproportionately enlarged right atrium with normal tricuspid valve anatomy. Tricuspid valve regurgitation may be due to valvar annular dilation or compression by the GRAA. Although the right ventricle may appear disproportionately small compared with the right atrium, the tricuspid valve annulus should be normally positioned in relation to the mitral valve. Spontaneous echogenic contrast due to slow atrial flow is often seen in cases with massive right atrial dilatation making the identification of intra-atrial thrombus difficult.

The clinical presentation of GRAA is variable within the pediatric population. The majority of patients are asymptomatic and diagnosed with GRAA after an incidental finding of cardiomegaly on chest radiograph.^{2,3} The symptomatic presentation of GRAA is reported to be low, but cannot be accurately quantified.² Common symptomatic presentations are due to intra-atrial thrombi and atrial arrhythmias resulting in palpitations, dyspnea, and syncope.³ Many cases with atrial tachyarrhythmias have been described with highly variable response to anti-arrhythmic therapy.⁴ Although quite rare, a few published cases of pediatric GRAA have presented with respiratory symptoms including recurrent lower respiratory tract infections and pneumothorax.^{12,13} Only two cases in the literature describe symptomatic airway obstruction.^{4,14} In both cases, airway obstruction was reversed after right atrial aneurysm resection, but the postoperative course was complicated by atrial tachycardia. The presentation of fetal GRAA cases is variable with the majority of cases identified on routine anatomical screening ultrasound. Some can alternatively present symptomatically with atrial arrhythmias or fetal hydrops due to severe tricuspid regurgitation.^{4,15}

Our cases demonstrate both extremes of the clinical spectrum. Four cases were asymptomatic on presentation. The first case in our series was acutely symptomatic with refractory atrial arrhythmias, proximal airway obstruction, and post-obstructive pneumonia. Although most patients will be asymptomatic on presentation, clinicians should be aware of the diverse presentation of this cardiac lesion as some may present with acute cardiac or respiratory compromise.

As GRAA remains a rare congenital anomaly, the optimal medical and surgical management is ill defined. The majority of patients are asymptomatic on presentation, which makes decisions regarding initiation of preventative medications

and prophylactic surgery difficult. For patients that present with significant arrhythmias, initiation of antiarrhythmic medications prior to considering surgical intervention is essential and well accepted as uncontrolled atrial arrhythmias can lead to ventricular dysfunction.⁴ The need for thromboprophylaxis is controversial, although it should be considered in all patients with massive right atrial dilation, evidence of stagnant flow within the aneurysm, or presence of thrombus. At our institution, transthoracic echocardiography is the preferred imaging modality to assess for intracardiac thrombi. Transesophageal echocardiography is completed if there is suspicion of an intracardiac thrombus that cannot be confirmed by transthoracic imaging. Low-dose aspirin is the preferred medication for thromboprophylaxis at our institution due to the low risk of adverse effects and lack of need for serial monitoring.

The role of surgical intervention, including prophylactic atrial aneurysm resection, remains controversial.

Surgical right atrial aneurysm resection was first described by Morrow and Behrendt.¹⁶ The procedure has since been used in both adult and pediatric GRAA patients. Pediatric indications for atrial aneurysm resection include atrial arrhythmias,^{4,17} intracavitary thrombus,^{2,3} major atrial dilatation, and right ventricular compression.^{13,14,18} The procedure has a low operative mortality rate and can be completed with or without cardiopulmonary bypass.³ All of the presented cases were completed with cardiopulmonary bypass. Clinical course is frequently improved by reduction in atrial size as demonstrated in our cases, although occasionally atrial surgery has been reported to prompt additional atrial arrhythmias.⁴ In subsequent follow-up after atrial resection, all of our cases were asymptomatic and had not developed atrial arrhythmias, atrial thrombus, or recurrence of significant right atrial dilatation. A conservative nonsurgical approach is encouraged in asymptomatic patients with only mild to at most moderate atrial dilatation and no evidence of thrombus or atrial arrhythmias.^{3,4} Regardless of symptoms, elective surgical intervention is recommended at our institution for patients with massive right atrial dilatation, severe tricuspid regurgitation due to annular compression, and right ventricular compression. For asymptomatic patients in the gray zone, those with moderate but not massive right atrial enlargement, serial follow-up is recommended and management plans are individualized on a case-by-case basis. The interval for serial

follow-up for all patients with GRAA should be determined by the primary cardiologist and will be variable depending on symptoms and echocardiographic findings. Elective surgery optimally occurs after the neonatal period to avoid the increased risks associated with cardiopulmonary bypass.

Conclusion

The five presented cases demonstrate the challenges in diagnosis and the diverse clinical presentation of GRAA. Diagnostic accuracy has been improved by the increased quality and availability of pediatric and fetal imaging modalities. Although rare, symptomatic presentation with atrial arrhythmias or airway obstruction can occur and should prompt medical stabilization and surgical intervention. Medical and surgical management of this rare form of congenital heart disease remains inconsistent between centers. At our institution, a conservative approach with serial follow-up is indicated in patients with only mild to moderate atrial dilatation and no atrial arrhythmias or thrombus. Thromboprophylaxis is recommended in these patients using low-dose aspirin. All symptomatic patients and those with massive right atrial dilatation, severe tricuspid regurgitation due to annular compression, and right ventricular compression are medically stabilized and considered for surgical intervention. The long-term follow-up in our particular cases (ranging from 4 months to 10 years) has demonstrated an excellent overall prognosis for these patients.

Author Contributions

Erika E. Harder—Concept/design, chart review, drafting article, image preparation, revision of article

Richard G. Ohye—Critical revision of article, approval of article

Marc D. Knepp—Critical revision of article, approval of article

Sonal T. Owens—Concept/design, image preparation, critical revision of article, approval of article

Corresponding Author: Sonal T. Owens, MD, University of Michigan Congenital Heart Center, CS Mott Children's Hospital, 1540 E. Hospital Drive, Ann Arbor, MI 48109-4204, USA. Tel: 734-936-6703; Fax: 734-936-9470; E-mail: sthakkar@med.umich.edu

Sources of funding: None.

Conflicts of interest: None.

Accepted in final form: March 15, 2013.

Congenit Heart Dis. 2014;9:E70–E77

References

- 1 Bailey C. *Surgery of the Heart*. Philadelphia: Lea & Febiger; 1955.
- 2 Blaysat G, Villain E, Marcon F, et al. Prognosis and outcome of idiopathic dilatation of the right atrium in children. A cooperative study of 15 cases. *Arch Mal Coeur Vaiss.* 1997;90:645–648.
- 3 Binder TM, Rosenhek R, Frank H, Gwechenberger M, Maurer G, Baumgartner H. Congenital malformations of the right atrium and the coronary sinus: an analysis based on 103 cases reported in the literature and two additional cases. *Chest.* 2000;117:1740–1748.
- 4 Forbes K, Kantoch MJ, Divekar A, Ross D, Rebeyka IM. Management of infants with idiopathic dilatation of the right atrium and atrial tachycardia. *Pediatr Cardiol.* 2007;28:289–296.
- 5 Maione S, Giunta A, Betocchi S, Ferro G, Vigorito C, Chiariello M. Two-dimensional echocardiography in idiopathic enlargement of the right atrium. Reliability and limitations. *Cardiology.* 1983;70:216–222.
- 6 Reinhardt-Owlya L, Sekarski N, Hurni M, Laurini R, Payot M. Idiopathic dilatation of the right atrium simulating Ebstein's anomaly. Apropos of a case diagnosed in utero. *Arch Mal Coeur Vaiss.* 1998;91:645–649.
- 7 Thompson SI, Vieweg WV, Alpert JS, Humphrey CB, Hagan AD. Mediastinal teratoma masquerading as idiopathic enlargement of the right atrium. *Am Heart J.* 1977;93:375–377.
- 8 Cianciulli TF, Rubineti ER, Saccheri MC, Dethinne SD, Prezioso HA. Contrast echocardiography in the non-invasive diagnosis of giant aneurysm of the right atrial appendage. *Eur J Echocardiogr.* 2010;11 (7):E26.
- 9 Ishii Y, Inamura N, Kayatani F. Congenital aneurysm of the right atrial appendage in a fetus. *Pediatr Cardiol.* 2012;33:1227–1229.
- 10 Klisiewicz A, Szymanski P, Rozanski J, Hoffman P. Giant congenital aneurysm of the right atrium: echocardiographic diagnosis and surgical management. *J Am Soc Echocardiogr.* 2004;17:286–287.
- 11 Tejero-Hernandez MA, Espejo-Perez S, Suarez-de-Lezo-Cruz-Conde J. Congenital aneurysm of the right atrial appendage in a newborn: a rare anomaly. *Rev Esp Cardiol.* 2012;65:99–100.
- 12 Corti F, Sciuchetti JF, Ferro O, Porta F, Redaelli M, Paolini G. Symptomatic right atrial appendage aneurysm: diagnosis and resection. *J Cardiovasc Med (Hagerstown).* 2008;9:314–316.
- 13 Navabi MA, Kiani A, Shabani R. Congenital right atrial aneurysm in an infant. *Pediatr Cardiol.* 2008;29:998–999.
- 14 Divekar A, Soni R, Ross D. Rapidly progressive idiopathic dilation of the right atrium in infancy associated with dynamic obstruction of the airways. *Cardiol Young.* 2002;12:491–493.

- 15 Barberato MF, Barberato SH, Gomes CC, Costa SL, Krawiec A. Right atrial aneurysm associated to fetal hydrops: diagnosis through fetal echocardiography. *Arq Bras Cardiol.* 2005;85:65–67.
- 16 Morrow AG, Behrendt DM. Congenital aneurysm (diverticulum) of the right atrium. Clinical manifestations and results of operative treatment. *Circulation.* 1968;38:124–128.
- 17 Scalia GM, Stafford WJ, Burstow DJ, Carruthers T, Tesar PJ. Successful treatment of incessant atrial flutter with excision of congenital giant right atrial aneurysm diagnosed by transesophageal echocardiography. *Am Heart J.* 1995;129:834–835.
- 18 Narain VS, Puri A, Sethi R, et al. Giant right atrial aneurysm presenting as right heart failure. *Indian Heart J.* 2012;64:200–202.