

good test-retest reliability. We used an interview format because it offers the advantage of minimizing missing and inappropriate responses.<sup>7</sup> In our study, 18 of 19 residents were able to successfully complete the instrument, allowing calculation of a global score. This is an essential part of the PSQI because it is this global score that differentiates good from poor sleepers. Because all of our subjects were cognitively intact, our results cannot be generalized to all nursing home residents. Even though the interview-administered PSQI does not provide a specific diagnosis, its discriminative ability makes it an attractive research instrument as well as a clinical screening tool to identify older subjects who have poor sleep quality and need further evaluation. Clinicians and investigators might consider expanding its use to older people in other settings. It could be useful, for example, in outpatient clinics and assisted living situations for those subjects who are cognitively intact but too frail to self-administer a questionnaire.

Angela Gentili, MD  
Debra K. Weiner, MD  
Maggie Kuchibhatla, PhD  
Jack D. Edinger, PhD  
Duke University Medical Center  
Durham, NC  
GRECC, Durham VAMC  
Durham, NC

## REFERENCES

1. Cohen D, Eisdorfer C, Prinz P et al. Sleep disturbances in the institutionalized aged. *J Am Geriatr Soc* 1990;31:79-82.
2. Buysse DJ, Reynolds CF, Monk TH et al. The Pittsburgh Sleep Quality Index: A new instrument for psychiatric practice and research. *Psychiatry Res* 1989;28:193-213.
3. Hoch CC, Reynolds CF, Kupfer DJ et al. Empirical note: Self-report versus recorded sleep in healthy seniors. *Psychophysiology* 1987;24:293-299.
4. Bliwise DL, Bevier WC, Bliwise NG et al. Systematic 24-hr behavioral observations of sleep and wakefulness in a skilled-care nursing facility. *Psychol Aging* 1990;5:6-24.
5. Schnelle JF, Ouslander JG, Simmons MD et al. Nighttime sleep and bed mobility among incontinent nursing home residents. *J Am Geriatr Soc* 1993;41:903-909.
6. Lahey MA, Downey RG, Saal FE et al. Intraclass correlations: There's more than meets the eye. *Psychol Bull* 1983;93:586-595.
7. Landis RJ, Koch GG. The measurement of observer agreement for categorical data. *Biometrics* 1977;33:159-174.
8. O'Toole BI, Battistutta D, Long A, Crouch K. A comparison of costs and data quality of three health survey methods: Mail, telephone and personal home interview. *Am J Epidemiol* 1986;124:317-328.

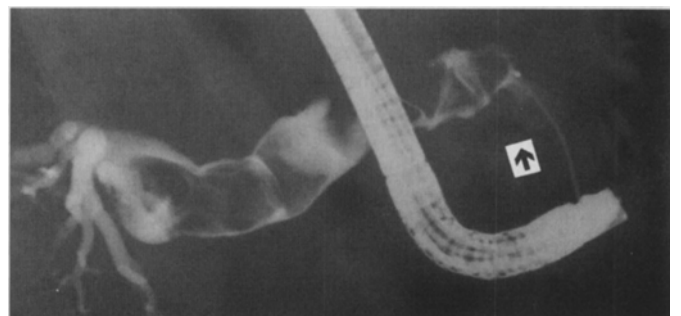
## CHOLEDOCHOLITHIASIS CAUSING OBSTRUCTIVE JAUNDICE 52 YEARS AFTER CHOLECYSTECTOMY

*To the Editor:* Choledocholithiasis following cholecystectomy has been associated with benign postoperative bile duct strictures, remnants of nonabsorbable suture used at cholecystectomy, and the existence of periampullary duodenal diverticula.<sup>1-3</sup> Duodenal diverticula usually lie in close proximity to the ampulla of Vater and may increase the incidence of common duct stones by five times.<sup>2</sup> Described here is the case of a 78-year-old woman who developed acute obstructive jaundice 52 years after a cholecystectomy, who was found to have a large periampullary diverticula and severe choledocholithiasis, and who was successfully treated with endoscopic sphincterotomy followed by extracorporeal shock wave lithotripsy.

A 78-year-old woman with a history of non-insulin-dependent diabetes mellitus and hypertension presented with acute onset of severe epigastric pain and vomiting. She denied fevers, chills, hematemesis, diarrhea, acholic stools, dark urine, or pruritis. She had had an open cholecystectomy 52 years before admission for cholecystitis. She denied alcohol use or blood transfusions. On physical examination, she was afebrile and in mild distress. The sclera were icteric. Abdominal examination revealed a well healed scar and tenderness in the right upper quadrant. There were no peritoneal signs, and the stool was negative for occult blood. The rest of the physical examination was normal. Laboratory evaluation revealed normal serum electrolytes and white blood cell count. Total bilirubin was 6.2 mg/dL, with a conjugated fraction of 4.3 mg/dL. Serum liver chemistries showed an alkaline phosphatase of 386 mg/dL, aspartate aminotransferase of 96 mg/dL, and an alanine aminotransferase of 389 mg/dL. Amylase and lipase were normal. An ultrasound of the right upper quadrant showed biliary dilatation with a common duct measurement of 18 mm; numerous large stones also were visualized. The patient was taken to endoscopic retrograde cholangiopancreatography (ERCP), which revealed numerous large stones and a dilated common bile duct (Figure 1). A large periampullary duodenal diverticula was seen endoscopically. A sphincterotomy was performed, but because of the large number of residual stones, extracorporeal shock wave lithotripsy (ESWL) was carried out. At no time had the patient signs or symptoms of cholangitis. At follow-up ERCP, the residual fragments were removed easily, and the patient was discharged home asymptomatic with normal liver chemistries.

The formation of stones *de novo* in the common bile duct (choledocholithiasis) is a well established event.<sup>1</sup> Predisposing factors to choledocholithiasis include benign posttraumatic stricture, sclerosing cholangitis, congenital cystic disease, Caroli's disease, and periampullary diverticula.<sup>1,2</sup> Choledocholithiasis after cholecystectomy has also been reported to occur secondary to remnants of nonabsorbable suture material used for cystic duct ligation, although this is an uncommon event.<sup>3</sup> Braasch et al. reported a series of patients who presented with symptomatic choledocholithiasis after cholecystectomy.<sup>1</sup> However, the mean duration from surgery to symptom onset was 9 years,<sup>1</sup> much shorter time than the 52 years for this patient.

Periampullary duodenal diverticula have been shown to be associated with a high rate of calcium bilirubinate stone



**Figure 1.** Endoscopic retrograde cholangiopancreatography (ERCP) showing a massively dilated common bile duct with multiple filling defects representing common duct stones. The periampullary diverticula is shown by the arrow.

formation.<sup>2,4</sup> Hall et al.<sup>2</sup> examined the incidence of stones and periampullary diverticula following cholecystectomy and found diverticula to occur more commonly in patients with jaundice. Furthermore, common bile duct stones post-cholecystectomy were strongly associated with the presence of a diverticulum: common duct stones were noted in 43% of patients with a diverticulum but in only 18% of patients without a diverticulum.<sup>2</sup> They also found that cholecystectomy did not prevent choledocholithiasis in the presence of a diverticulum.<sup>2</sup>

The etiology of the formation of common duct stones in the presence of a periampullary diverticulum is thought to be caused by ascending infection of the common bile duct by beta-glucuronidase-producing bacteria.<sup>2,4</sup> Identical bacterial flora have been recovered in the biliary tree and diverticulum in some patients.<sup>2</sup> The stone composition of patients with diverticula is mainly calcium carbonate, not cholesterol.<sup>2,4</sup> Intestinal beta-glucuronidase-producing bacteria split conjugated bilirubin into glucuronic acid and unconjugated bilirubin, which then combine with calcium to form insoluble calcium bilirubinate.<sup>2,4</sup> The presence of the juxtapapillary diverticulum is thought to cause ampullary dysfunction, allowing the migration of these bacteria into the duct.<sup>2</sup>

If an older patient with a history of cholecystectomy presents with biliary pain, the possibility of a periampullary diverticulum should be kept in mind in as much as it seems to increase the likelihood of common duct stone formation.<sup>2,4</sup> The history of a remote cholecystectomy, 52 years in this patient, should not dissuade the clinician from considering the diagnosis of choledocholithiasis. This case illustrates successful nonoperative management of severe choledocholithiasis by ERCP with sphincterotomy and ESWL. Although the optimal treatment of this clinical situation remains to be resolved, consideration of nonoperative treatment in an older patient deserves consideration.

*Mark A. Marinella, MD*  
*University of Michigan Medical Center*  
*Ann Arbor, MI*

## REFERENCES

1. Braasch JW, Fender HR, Bonneval MM. Refractory primary common bile duct stone disease. *Am J Surg* 1980;139:526-530.
2. Hall RI, Ingoldby CJH, Denyer ME. Periampullary diverticula predispose to primary rather than secondary stones in the common bile duct. *Endoscopy* 1990;22:127-128.
3. Newman CE, Hamer JD. Non-absorbable cystic duct ligatures and common bile duct calculi. *Br Med J* 1975;4:504.
4. Lotveit T. The composition of biliary calculi in patients with juxtapapillary duodenal diverticula. *Scand J Gastroenterol* 1982;17:653-656.

## DIAGNOSTIC AND PROGNOSTIC VALUE OF STRESS TESTING IN OLDER PERSONS

*To the Editor:* The excellently presented and organized review "Diagnostic and Prognostic Value of Stress Testing in Older Persons"<sup>1</sup> addressed continuing consternation about this subject. It also focuses strongly on my future concerns regarding our rapidly changing medical socioeconomic climate. Thirty-five years of concentrated observation and experience in internal medicine and cardiology lead me to believe that cardiac stress-scintigraphy, regardless of method, is one of the most overutilized and abused procedures in the history of modern medicine.

Although Dr. Fleg aptly presents personal and additional supporting data for his position on the diagnostic and prognostic value of stress-testing in older patients, I contend that, when reviewed in a realistic manner based on long-term clinical observation, stress testing in older people is usually unnecessary for proper diagnosis and treatment. An excellent review by Bodenheimer concludes that noninvasive testing as an intermediate step to select those patients who require invasive study remains an attractive but unproven hypothesis.<sup>2</sup> In cases of post infarction risk stratification, it has been shown that the only independent predictors of outcome identified were Holter ST shift and Killip class, and when exercise stress testing was able to be performed, it added no additional prognostic value.<sup>3</sup> The usefulness of exercise testing in conjunction with thallium scintigraphy was felt to be of limited value in patients with stable coronary artery disease because of its poor predictive performance in this subset of patients.<sup>4</sup> The authors of this study further opined that stress-thallium testing has a limited role in predicting cardiac events in patients with known coronary artery disease. I realize that an equal or greater number of studies can be found that support the diagnostic and prognostic value of stress-imaging in various subsets of patients.

The preoperative use of dipyridimole-thallium scanning to assess cardiac risk in patients undergoing nonvascular surgery was felt to be unnecessary in half of the patients selected because it was ascertained that simple clinical parameters would serve just as well.<sup>5</sup> In patients with cardiac chest pain, the use of readily available and inexpensive clinical data, including electrocardiographic and roentgenographic parameters, was shown to decrease the need for the more expensive imaging methods.<sup>6</sup> Froelicher concluded that scores derived from natural history studies are accurate and can be used to direct limited healthcare resources to the patients who really need them.<sup>7</sup> In my personal experience, this is rarely the older patient who is unable to perform a routine treadmill study except as mitigated by special or unusual circumstances. It has likewise been demonstrated that when the at-rest electrocardiogram is normal, thallium scintigraphy adds little information to clinical and exercise variables in identifying patients with severe coronary artery disease.<sup>8</sup> I corroborate the opinions that the high cost of this information does not justify the routine use of imaging procedures for this purpose. Furthermore, it has been shown (and not surprisingly) that patients with resting ST-T abnormalities not influenced by digitalis have more extensive stress-induced myocardial perfusion abnormalities on thallium scanning.<sup>9</sup>

In conclusion, it is not my intent to detract from the excellence of Dr. Fleg's work, but to inject personal observation based on much experience, which leads me to conclude that the aphorism often stated by the master clinician Eugene Stead—"What this patient needs is a doctor"—still holds true in our present climate of technologic proliferation, marked limitation of expenditures, and the often heralded, unnecessarily excessive "care" of the elderly. It is absolutely amazing how well the older patient will do on a properly selected therapeutic regimen. All it requires is knowledge based on meaningful and accurately obtained experience, to which a proper doctor-patient relationship must be added.

*Basil M. RuDusky, MD*  
*Wilkes-Barre, PA*