



COMMENTARY

The peri-implant phenotype

Gustavo Avila-Ortiz¹ | Oscar Gonzalez-Martin^{1,2} | Emilio Couso-Queiruga¹ | Hom-Lay Wang³

¹Department of Periodontics, University of Iowa College of Dentistry, Iowa City, IA

²Department of Periodontology, Complutense University of Madrid, Madrid, Spain

³Department of Periodontics and Oral Medicine, University of Michigan School of Dentistry, Ann Arbor, MI

Correspondence

Gustavo Avila-Ortiz, DDS, MS, PhD, Department of Periodontics, University of Iowa College of Dentistry, 801 Newton Road, Iowa City, IA 52242.

Email: gustavo-avila@uiowa.edu

Abstract

This commentary proposes a definition for the term “peri-implant phenotype” and provides a comprehensive description of all its components.

1 | INTRODUCTION

Phenotype can be defined as the observable properties of an organism that are produced by the interaction of the genotype and the environment.¹ The term “phenotype” should not be used interchangeably with “biotype,” which refers to a set of organisms that share a specific genotype.

The 2017 World Workshop on the Classification of Periodontal and Peri-Implant Diseases and Conditions defined the “periodontal phenotype” as the combination of the gingival phenotype, constituted by the keratinized tissue width and the gingival thickness, and the bone morphotype, that is, thickness of the alveolar bone plate (Figure 1).² Meanwhile, a standard definition for the analogous term “peri-implant phenotype” is absent from the currently available literature. Given its relevance in contemporary clinical practice and research, it is imperative to define this term and its components.

2 | DEFINITION OF THE PERI-IMPLANT PHENOTYPE

The peri-implant phenotype can be defined as the morphologic and dimensional features characterizing the clinical presentation of the tissues that surround and support osseointe-

grated implants. The peri-implant phenotype encompasses a soft tissue component, constituted by the peri-implant keratinized mucosa width, the mucosa thickness and the supracrestal tissue height, and an osseous component, characterized by the peri-implant bone thickness (Figure 2). This definition does not only apply to buccal and facial sites, but also to lingual and palatal peri-implant locations. Like the periodontal phenotype, the peri-implant phenotype is site-specific and may change over time in response to environmental factors.

3 | COMPONENTS OF THE PERI-IMPLANT PHENOTYPE

3.1 | Soft tissue

3.1.1 | Keratinized mucosa width

The peri-implant keratinized mucosa width (KMW) is the height of keratinized soft tissue that runs in an apico-coronal direction from the mucosal margin to the mucogingival junction. KMW may be completely absent in specific clinical situations in which there is only non-keratinized oral mucosa surrounding dental implants and their corresponding prosthetic components. If present, it constitutes the most coronal component of the peri-implant soft tissues.

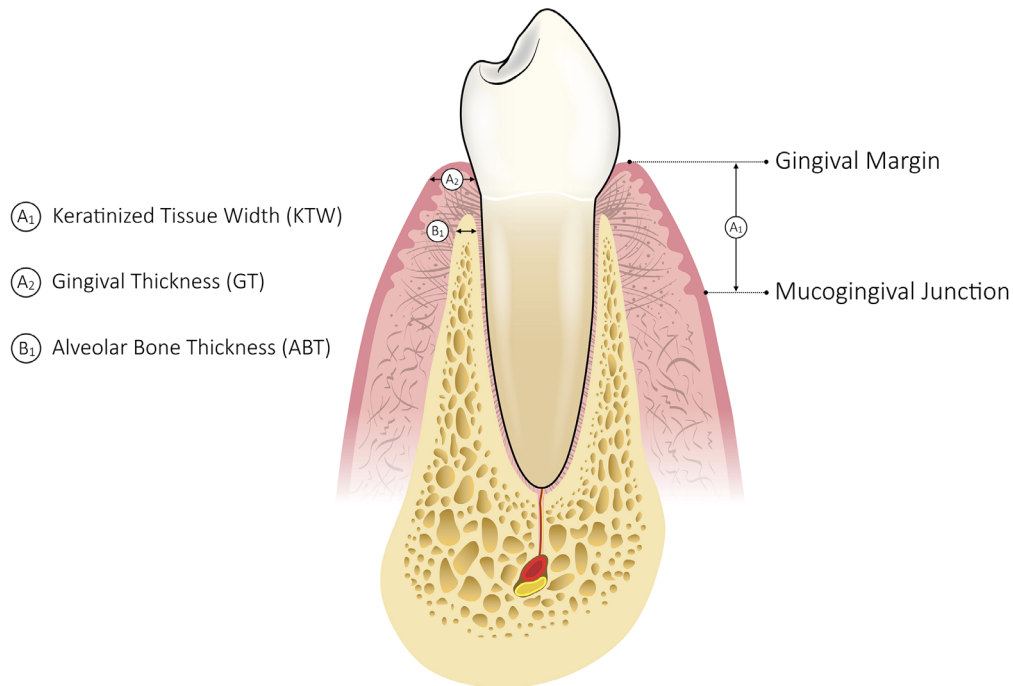


FIGURE 1 The components of the periodontal phenotype

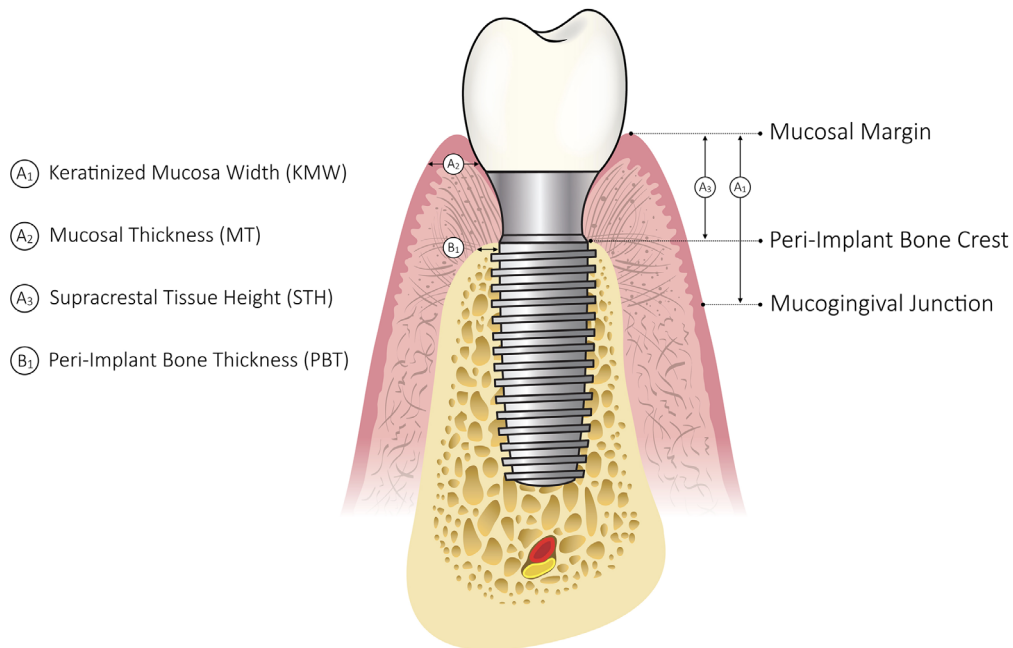


FIGURE 2 The components of the peri-implant phenotype

Clinical relevance

The need for a minimum amount of KMW for peri-implant health maintenance, as well as for functional and esthetic reasons, has been widely investigated and discussed in the literature and scientific forums. According to the consensus of Group 4 at the 2017 World Workshop on the Classification of Periodontal and Peri-Implant Diseases and Conditions, the evidence is equivocal regarding the effect that the presence or

absence of keratinized mucosa has on the long-term health of the peri-implant tissues.³ According to Schwarz et al., although some studies suggest that the absence of or an inadequate amount of KMW may negatively affect self-performed oral hygiene measures,^{4–6} there is limited evidence that this factor constitutes a risk for peri-implantitis.⁷ However, it is worth noting the increasing amount of high-level evidence that associates inadequate KMW (<2 mm) with peri-implant

mucositis,^{8,9} as well as the findings of a recent study in which a minimum amount of 2 mm of KMW was found to be critical to minimize the incidence of peri-implant mucositis and future marginal bone loss in erratic maintenance compliers.¹⁰ Therefore, although further research is needed to determine the minimum amount of KMW required for optimal long-term peri-implant health, function, and esthetics in specific clinical scenarios, on the basis of current evidence, we propose the following KMW categorization for use in future investigations and in daily clinical practice: inadequate KMW (<2 mm) and adequate KMW (≥ 2 mm).

3.1.2 | Mucosal thickness

Peri-implant mucosal thickness (MT) is the horizontal dimension of the peri-implant soft tissue, which may or may not be keratinized. Peri-implant MT may vary at different locations (e.g., buccal versus lingual) and apico-coronal heights respective to the mucosal margin around a given implant.

Clinical relevance

Similar to the KMW, the thickness of the peri-implant soft tissue, particularly at the most coronal segment, may play a critical role on the functional and esthetic outcomes of implant therapy, as well as on the maintenance of peri-implant health. The most frequent indication of surgical interventions aimed at augmenting the MT around implants is to enhance the esthetic results following the delivery of the final implant-supported prosthesis. This is commonly performed in an attempt to attenuate or eliminate the effect of the shade of the abutment (e.g., titanium alloy, gold, or zirconia) on the buccal aspect of the mucosa^{11–16} and/or to compensate for possible underlying bone deficiencies resulting from unfavorable osseous remodeling patterns, prior to or after functional loading.^{17–19} Although the vast majority of studies conducted in this area have focused on the effect of MT augmentation for esthetic purposes, a recent systematic review reported that the performance of soft tissue grafting procedures for gain of MT resulted in significantly less interproximal marginal bone loss over time.²⁰ A consensus on the minimum MT required to achieve predictable long-term functional and esthetic outcomes, and to minimize marginal bone loss and mucosal recession, has not been established.²¹ However, most studies in this topic found that the effect of the abutment shade on the mucosa was negated in sites that exhibited a minimum MT of ≈ 2 mm.^{13–15} Hence, we propose the following MT categorization for use in future investigations and in daily clinical practice: thin MT (<2 mm) and thick MT (≥ 2 mm).

3.1.3 | Supracrestal tissue height

The peri-implant supracrestal tissue height (STH) is the vertical dimension of the soft tissue that surrounds a dental implant

from the mucosal margin to the crestal bone. Different from KMW and MT, this component of the peri-implant soft tissue phenotype can be assessed circumferentially around an implant, including proximal sites. STH should not be used interchangeably with the analogous term “supracrestal tissue attachment,” which only applies to natural teeth, and that has recently replaced the classic term “biologic width.”² Biologic width is a histologic concept that was originally described around natural teeth and can be defined as the vertical distance from the base of the sulcular epithelium to the crestal bone, including the junctional epithelium and the attached connective tissue.²² In a coronal direction, the peri-implant STH encompasses the sulcular epithelium, the junctional epithelium, and the supracrestal connective tissue, which is typically not attached to the abutment surface. As noted by Araujo and Lindhe, several investigations^{23–26} have demonstrated that the STH is usually taller than the supracrestal tissue attachment around teeth to an average magnitude of an additional 1.0 to 1.5 mm in both buccal/lingual and proximal sites.²⁷

Clinical relevance

Understanding the effect of STH on peri-implant bone remodeling is one of the keys to achieving predictable outcomes in the context of tooth replacement therapy via dental implants. Noteworthy, the available evidence is quite robust in this area. According to the findings reported in multiple clinical studies published over the past decade,^{28–34} the STH plays a critical role in marginal bone loss patterns. Short STH at the time of implant placement has been consistently associated with a variable amount of marginal bone loss, likely because of the physiologic establishment of the soft tissue component of the implant-supporting apparatus during the healing period. Current evidence indicates that this concept applies independently of the implant design (e.g., bone versus soft tissue level implant) and the restorative modality (e.g., platform switching). A systematic review aimed at evaluating the effect of STH on marginal bone loss indicated that not all the studies on this topic report a cut-off value to distinguish between short (unfavorable) or tall (favorable) STH, but, those that did, established the threshold at 2 or 3 mm.³⁵ Considering the most recent evidence in this topic,^{36,37} as well as the anatomical differences between anterior and posterior teeth (i.e., anterior teeth tend to exhibit a longer STH), we propose the following STH categorization for use in future investigations and in daily clinical practice: short STH (<3 mm) and tall STH (≥ 3 mm).

A word of caution must be added. According to the results of a recently published study, implants surrounded by a deep mucosal tunnel (≥ 3 mm) above the implant restorative platform were associated with a less favorable pattern of resolution of peri-implant mucositis as compared to sites presenting a mucosal tunnel of ≤ 1 mm.³⁸ As it is commonly stated in



the field of Oral Implantology, dental implants should be placed “as deep as necessary, but as shallow as possible,” accounting for site-specific anatomic and restorative factors.

3.2 | Bone

3.2.1 | Peri-implant bone thickness

The peri-implant bone thickness (PBT) is the horizontal dimension of osseous tissue that supports an osseointegrated implant. PBT may vary at different apico-coronal heights respective to the bone crest around a given implant or even be completely absent in sites exhibiting peri-implant bone defects (e.g. fenestrations or dehiscences).

Clinical relevance

Although it is generally acknowledged that thick peri-implant bone, particularly at the coronal level, is associated with favorable implant therapy outcomes,³⁹ and a recent, highly relevant preclinical study has shed light in this topic,⁴⁰ there is limited clinical evidence to establish a minimum threshold of bone thickness necessary to achieve predictable peri-implant tissue stability, esthetics, and health. In fact, as pointed out by Thoma et al. in a systematic review aimed at evaluating the efficacy of bone augmentation procedures to treat horizontal ridge deficiencies after implant placement, vertical bone defect (dehiscence) resolution appears to be more important than the horizontal bone thickness at the implant shoulder.⁴¹ Even so, this does not necessarily mean that PBT is irrelevant. The most important piece of available clinical evidence pertaining to the role of PBT in the maintenance of peri-implant health emanates from the findings of a large prospective study including >3000 implants placed in 32 different health care centers.⁴² The authors of this study reported that sites presenting a PBT of at least 2 mm at ≈ 0.5 mm apical to the crest at the time of implant placement exhibited a lower rate of vertical bone loss and slightly lower implant failure rate between 6 and 8 months after implant insertion. In spite of its relatively limited scope, short-term follow-up and other methodological limitations pointed out by Merheb et al.,⁴³ the findings of this study should be taken into consideration until further clinical evidence is generated. Hence, we propose the following PBT categorization for use in future investigations and in daily clinical practice: thin PBT (<2 mm) and thick PBT (≥ 2 mm).

4 | SUMMARY AND FINAL REMARKS

The four components of the peri-implant phenotype are the KMW, the MT, the STH, and the PBT. The dimensional thresholds hereby proposed for each of them derive from a meticulous assessment of the available literature filtered through the clinical experience of the authors. Nevertheless,

it is important to remark that these average threshold values may vary depending on tooth location (anterior versus posterior) and may not be applicable in specific situations in which the characteristics of the implant-supporting apparatus deviate from normal, including sites undergoing local inflammatory processes that may directly influence the dimensions, morphology and/or integrity of the peri-implant tissues. Future research is necessary to determine the minimum amount of KMW, MT, STH, and PBT required to obtain optimal short- and long-term outcomes, including maintenance of peri-implant health, function, and esthetics, in specific clinical scenarios (e.g., patients with uncontrolled systemic conditions, the use of different biomaterials and variations in abutment design, among other factors). It is also important to elucidate the role of PBT on peri-implant health and soft tissue stability, and whether there is a dimensional correlation between peri-implant soft and hard tissues.

ACKNOWLEDGMENTS

All authors have actively participated in the preparation of this manuscript and approved the submitted version.

Sources of Support: No external funding was received.

Conflicts of Interest: The authors report no conflicts of interest.


ORCID

Gustavo Avila-Ortiz 

<https://orcid.org/0000-0002-5763-0201>

Oscar Gonzalez-Martin 

<https://orcid.org/0000-0003-3957-4872>

Emilio Couso-Queiruga 

<https://orcid.org/0000-0002-9989-4483>

Hom-Lay Wang  <https://orcid.org/0000-0003-4238-1799>

REFERENCES

1. Phenotype. Available at: <https://www.merriam-webster.com/dictionary/phenotype#medicalDictionary>. Accessed August, 2019.
2. Jepsen S, Caton JG, Albandar JM, et al. Periodontal manifestations of systemic diseases and developmental and acquired conditions: consensus report of workgroup 3 of the 2017 World Workshop on the Classification of Periodontal and Peri-Implant Diseases and Conditions. *J Periodontol*. 2018;89(Suppl 1):S237-S248.
3. Berglundh T, Armitage G, Araujo MG, et al. Peri-implant diseases and conditions: consensus report of workgroup 4 of the 2017 World Workshop on the Classification of Periodontal and Peri-Implant Diseases and Conditions. *J Periodontol*. 2018;89(Suppl 1):S313-S318.
4. Souza AB, Tormena M, Matarazzo F, Araujo MG. The influence of peri-implant keratinized mucosa on brushing discomfort and peri-implant tissue health. *Clin Oral Implants Res*. 2016;27:650-655.
5. Rocuzzo M, Grasso G, Dalmaso P. Keratinized mucosa around implants in partially edentulous posterior mandible: 10-year results

- of a prospective comparative study. *Clin Oral Implants Res.* 2016;27:491-496.
6. Perussolo J, Souza AB, Matarazzo F, Oliveira RP, Araujo MG. Influence of the keratinized mucosa on the stability of peri-implant tissues and brushing discomfort: a 4-year follow-up study. *Clin Oral Implants Res.* 2018;29:1177-1185.
 7. Schwarz F, Derks J, Monje A, Wang HL. Peri-implantitis. *J Periodontol.* 2018;89(Suppl 1):S267-S290.
 8. Lin GH, Chan HL, Wang HL. The significance of keratinized mucosa on implant health: a systematic review. *J Periodontol.* 2013;84:1755-1767.
 9. Gobatto L, Avila-Ortiz G, Sohrabi K, Wang CW, Karimbux N. The effect of keratinized mucosa width on peri-implant health: a systematic review. *Int J Oral Maxillofac Implants.* 2013;28:1536-1545.
 10. Monje A, Blasi G. Significance of keratinized mucosa/gingiva on peri-implant and adjacent periodontal conditions in erratic maintenance compliers. *J Periodontol.* 2019;90:445-453.
 11. Park SE, Da Silva JD, Weber HP, Ishikawa-Nagai S. Optical phenomenon of peri-implant soft tissue. Part I. Spectrophotometric assessment of natural tooth gingiva and peri-implant mucosa. *Clin Oral Implants Res.* 2007;18:569-574.
 12. Bressan E, Paniz G, Lops D, Corazza B, Romeo E, Favero G. Influence of abutment material on the gingival color of implant-supported all-ceramic restorations: a prospective multicenter study. *Clin Oral Implants Res.* 2011;22:631-637.
 13. Jung RE, Holderregger C, Sailer I, Khraisat A, Suter A, Hammerle CH. The effect of all-ceramic and porcelain-fused-to-metal restorations on marginal peri-implant soft tissue color: a randomized controlled clinical trial. *Int J Periodontics Restorative Dent.* 2008;28:357-365.
 14. Kim A, Campbell SD, Viana MA, Knoernschild KL. Abutment material effect on peri-implant soft tissue color and perceived esthetics. *J Prosthodont.* 2016;25:634-640.
 15. Lops D, Stellini E, Sbricoli L, Cea N, Romeo E, Bressan E. Influence of abutment material on peri-implant soft tissues in anterior areas with thin gingival biotype: a multicentric prospective study. *Clin Oral Implants Res.* 2017;28:1263-1268.
 16. Hutton CG, Johnson GK, Barwacz CA, Allareddy V, Avila-Ortiz G. Comparison of two different surgical approaches to increase peri-implant mucosal thickness: a randomized controlled clinical trial. *J Periodontol.* 2018;89:807-814.
 17. Benic GI, Mokti M, Chen CJ, Weber HP, Hammerle CH, Gallucci GO. Dimensions of buccal bone and mucosa at immediately placed implants after 7 years: a clinical and cone beam computed tomography study. *Clin Oral Implants Res.* 2012;23:560-566.
 18. Yoshino S, Kan JY, Rungcharassaeng K, Roe P, Lozada JL. Effects of connective tissue grafting on the facial gingival level following single immediate implant placement and provisionalization in the esthetic zone: a 1-year randomized controlled prospective study. *Int J Oral Maxillofac Implants.* 2014;29:432-440.
 19. Migliorati M, Amorfini L, Signori A, Biavati AS, Benedicenti S. Clinical and aesthetic outcome with post-extractive implants with or without soft tissue augmentation: a 2-year randomized clinical trial. *Clin Implant Dent Relat Res.* 2015;17:983-995.
 20. Thoma DS, Naenni N, Figuero E, et al. Effects of soft tissue augmentation procedures on peri-implant health or disease: a systematic review and meta-analysis. *Clin Oral Implants Res.* 2018;29(Suppl 15):32-49.
 21. Thoma DS, Muhlemann S, Jung RE. Critical soft-tissue dimensions with dental implants and treatment concepts. *Periodontol.* 2000. 2014;66:106-118.
 22. Gargiulo AW, Wentz FM, Orban B. Dimensions and relations of the dentogingival junction in humans. *J Periodontol.* 1961;32:261-267.
 23. Chang M, Wennstrom JL, Odman P, Andersson B. Implant supported single-tooth replacements compared to contralateral natural teeth. Crown and soft tissue dimensions. *Clin Oral Implants Res.* 1999;10:185-194.
 24. Grunder U. Stability of the mucosal topography around single-tooth implants and adjacent teeth: 1-year results. *Int J Periodontics Restorative Dent.* 2000;20:11-17.
 25. Kan JY, Rungcharassaeng K, Umezumi K, Kois JC. Dimensions of peri-implant mucosa: an evaluation of maxillary anterior single implants in humans. *J Periodontol.* 2003;74:557-562.
 26. Parpaiola A, Cecchinato D, Toia M, Bressan E, Speroni S, Lindhe J. Dimensions of the healthy gingiva and peri-implant mucosa. *Clin Oral Implants Res.* 2015;26:657-662.
 27. Araujo MG, Lindhe J. Peri-implant health. *J Periodontol.* 2018;89(Suppl 1):S249-S256.
 28. Puisys A, Linkevicius T. The influence of mucosal tissue thickening on crestal bone stability around bone-level implants. A prospective controlled clinical trial. *Clin Oral Implants Res.* 2015;26:123-129.
 29. Linkevicius T, Apse P, Grybauskas S, Puisys A. Reaction of crestal bone around implants depending on mucosal tissue thickness. A 1-year prospective clinical study. *Stomatologija.* 2009;11: 83-91.
 30. Linkevicius T, Puisys A, Steigmann M, Vindasiute E, Linkeviciene L. Influence of vertical soft tissue thickness on crestal bone changes around implants with platform switching: a comparative clinical study. *Clin Implant Dent Relat Res.* 2015;17:1228-1236.
 31. Linkevicius T, Apse P, Grybauskas S, Puisys A. The influence of soft tissue thickness on crestal bone changes around implants: a 1-year prospective controlled clinical trial. *Int J Oral Maxillofac Implants.* 2009;24:712-719.
 32. Linkevicius T, Puisys A, Linkeviciene L, Peciuliene V, Schlee M. Crestal bone stability around implants with horizontally matching connection after soft tissue thickening: a prospective clinical trial. *Clin Implant Dent Relat Res.* 2015;17:497-508.
 33. Linkevicius T, Apse P, Grybauskas S, Puisys A. Influence of thin mucosal tissues on crestal bone stability around implants with platform switching: a 1-year pilot study. *J Oral Maxillofac Surg.* 2010;68:2272-2277.
 34. Vervaeke S, Dierens M, Besseler J, De Bruyn H. The influence of initial soft tissue thickness on peri-implant bone remodeling. *Clin Implant Dent Relat Res.* 2014;16:238-247.
 35. Suarez-Lopez Del Amo F, Lin GH, Monje A, Galindo-Moreno P, Wang HL. Influence of soft tissue thickness on peri-implant marginal bone loss: a systematic review and meta-analysis. *J Periodontol.* 2016;87:690-699.
 36. Linkevicius T, Linkevicius R, Alkimavicius J, Linkeviciene L, Andrijauskas P, Puisys A. Influence of titanium base, lithium disilicate restoration and vertical soft tissue thickness on bone stability around triangular-shaped implants: a prospective clinical trial. *Clin Oral Implants Res.* 2018;29:716-724.
 37. Diaz-Sanchez M, Soto-Penalozza D, Penarrocha-Oltra D, Penarrocha-Diago M. Influence of supracrestal tissue attachment thickness on radiographic bone level around dental implants:



- a systematic review and meta-analysis. *J Periodontol Res.* 2019;54:573-588.
38. Chan D, Pelekos G, Ho D, Cortellini P, Tonetti MS. The depth of the implant mucosal tunnel modifies the development and resolution of experimental peri-implant mucositis: a case-control study. *J Clin Periodontol.* 2019;46:248-255.
39. Grunder U, Gracis S, Capelli M. Influence of the 3-D bone-to-implant relationship on esthetics. *Int J Periodontics Restorative Dent.* 2005;25:113-119.
40. Monje A, Chappuis V, Monje F, et al. The Critical Peri-implant Buccal Bone Wall Thickness Revisited: An Experimental Study in the Beagle Dog. *Int J Oral Maxillofac Implants.* 2019;34:1328-1336.
41. Thoma DS, Bienz SP, Figuero E, Jung RE, Sanz-Martin I. Efficacy of lateral bone augmentation performed simultaneously with dental implant placement: a systematic review and meta-analysis. *J Clin Periodontol.* 2019;46(Suppl 21):257-276.
42. Spray JR, Black CG, Morris HF, Ochi S. The influence of bone thickness on facial marginal bone response: stage 1 placement through stage 2 uncovering. *Ann Periodontol.* 2000;5:119-128.
43. Merheb J, Quirynen M, Teughels W. Critical buccal bone dimensions along implants. *Periodontol 2000.* 2014;66:97-105.

How to cite this article: Avila-Ortiz G, Gonzalez-Martin O, Couso-Queiruga E, Wang HL. The peri-implant phenotype. *J Periodontol.* 2020;91:283-288. <https://doi.org/10.1002/JPER.19-0566>